

## RELIABILITY OF THE BICAUDATE PARAMETER IN THE REVEALING OF THE ENLARGED LATERAL VENTRICLES IN SCHIZOPHRENIA PATIENTS

Nebojša Milovanović<sup>1</sup>, Aleksandar Damjanović<sup>2,3</sup>, Laslo Puškas<sup>2,4</sup>, Srđan Milovanović<sup>2,3</sup>,  
Dragana Duišin<sup>3</sup>, Miloš Mališ<sup>2,4</sup>, Gordana Stanković<sup>2,4</sup>, Anka Ranković<sup>2,4</sup>, Milan Latas<sup>2,3</sup>,  
Branka F. Filipović<sup>5</sup> & Branislav R. Filipović<sup>2,4</sup>

<sup>1</sup>Clinics for Psychiatry "Laza Lazarević", Belgrade, Serbia

<sup>2</sup>School of Medicine, Belgrade, Serbia

<sup>3</sup>Institute for Psychiatry, Clinical Center of Serbia, Belgrade, Serbia

<sup>4</sup>Institute of Anatomy "Niko Miljanic", Belgrade, Serbia

<sup>5</sup>Clinical and Hospital Center "Bezanijska Kosa", Belgrade, Serbia

received: 26.7.2017;

revised: 8.1.2018;

accepted: 5.2.2018

### SUMMARY

**Introduction:** In schizophrenia patients the lateral ventricle enlargement has mostly been reported in relationship with smaller cortical and/or subcortical brain volumes; and it has been observed that ventricular system growth may be a consequence of the smaller caudate nucleus volume. Bicaudate parameters have been used in the Alzheimer dementia and Huntington's chorea diagnosing in order to evaluate brain changes and the enlargement of the lateral ventricles.

**Subjects and methods:** This study has been carried out on 140 patients out of which 70 patients (30 men and 40 women) who met the ICD 10 criteria for schizophrenia and 70 healthy controls (30 men and 40 women) matched on sex and age with the studied group. All of them underwent direct caudatometry and volume computation based on MRI scans.

**Results:** Except for the bicorporal line, for all the parameters were obtained the statistically highly significant differences between the examined and control groups. Significant correlation was established for the majority of bicaudate parameters and volumes of the caudate nuclei and lateral ventricles.

**Discussion:** Enlargement of the lateral ventricles is one of the most frequent MRI finding in schizophrenia patients. Ventricles are enlarging gradually and frontal horns are more affected than other parts. The increased volumes of the caudate nuclei signaled that ventricular enlargement is not the consequence of the caudate atrophy.

**Conclusion:** Bicaudate parameters are reliable parameters for the quick orientation in order to assess the enlarged ventricles in schizophrenia patients.

**Key words:** lateral ventricles – schizophrenia - basal nuclei – MRI - brain

\* \* \* \* \*

### INTRODUCTION

The lateral ventricles are the largest part of the brain ventricular system. Consisting of the frontal horns, central portion, and the occipital and the temporal horns, which development is related to the brain maturation (Filipovic & Djulejic 2007, Chung et al. 2017, Nopoulos et al. 1995, Kinoshita 2001). In schizophrenia patients the lateral ventricle enlargement has mostly been reported in relationship with smaller cortical and subcortical brain volumes; it has been observed that ventricular system growth may be a consequence of the smaller caudate nucleus volume (McClure & Weinberger 2001, Corson et al. 1999). MRI guided studies and post – mortem investigations lead to the conclusion that the most important morphological abnormality in schizophrenia brains is ventricular enlargement relative to the ventricular size in healthy controls (Lawrie & Abupmail 1998, Shenton et al. 2001). Volumetric reduction of the basal ganglia occurred in patients chronically affected by schizo-

phrenia (Foong et al. 2001). Recent studies provided by Anastasi et al. (2006, 2007) attempted to evaluate the anatomically regions of the basal ganglia applying the technique which provides an alternative to the post – mortem studies and to reliably reproduce the ventricular morphologies. Their studies are representing the base for our 3D volume estimation (Meduri et al. 2010).

Bicaudate parameters have firstly been related to the diagnosis of Huntington's chorea in order to demonstrate the decline caudate nucleus volume (Filipovic 1991). Recently, bicaudate parameters have been used in the Alzheimer dementia diagnosing in order to evaluate brain changes and the enlargement of the lateral ventricles (Chaves et al. 1999).

In this study authors have hypothesized that bicaudate parameters could be used in the quick evaluations of the eventually enlarged ventricles in the schizophrenia suffering patients and the aim was to correlate them with the volumes of the lateral ventricles and caudate nuclei in order to evaluate their reliability.

## SUBJECTS AND METHODS

This study has been carried out on 140 patients out of which 70 patients (30 men and 40 women) who met the ICD 10 criteria for schizophrenia and 70 healthy controls (30 men and 40 women) matched on sex and age with the studied group. The detailed demographic data shown on the table 1.

Schizophrenia suffering patients have been treated by the atypical antipsychotics at the stable dosage for at least six months before their inclusion in the study. The clinical sample underwent the clinical examination in order to exclude significant concurrent mental illnesses, organic brain disorders, history of substance and alcohol abuse and mental retardation. At the same time, all the controls underwent structured psychiatric interview and were screened for mental disorders. Minnesota Multiple Personality Inventory 2<sup>nd</sup> revision in Serbian language (MMPI2, already in the routine use) has been used for the screening of the eventually personality disorders.

The Positive and Negative Syndrome Scale (PANSS), Serbian version, already in routine use, was used to assess the severity of schizophrenia symptoms (Kay et al. 1987, Timotijevic & Paunovic 1992).

### Magnetic resonance imaging procedures

The MRI study was performed using a 3.0 T whole body MRI scanner (Philips Medical Systems, Best, The Netherlands). After the scanning, all the patients were coded in order to blind the volumetric evaluation team, and sent to the subsequent volumetric analysis.

Volume measurements of the basal nuclei were performed on 3D-T1-weighted MR images (acquisition parameters were as follows: TR=1600 ms; TE=3.93 ms; flip angle=80; section thickness =1.2 mm; number of sections =120; no section gap; whole brain coverage; FOV=224 mm; matrix=256, reconstruction matrix=256).

The Medical Imaging and Processing Visualization (MIPAV) software was applied to estimate separately the structures volume in the caudate nucleus and the lateral ventricles. MIPAV is commercially available software for linear measurement, surface computing, volumetry and 3D rendering. During registration, the input data (3D MPRAGE images) were transformed to the

Montreal Neurological Institute (MNI) 152 standard spaces, by means of affine transformations based on 12 degrees of freedom (i.e. three translations, three rotations, three scalings and three skews). After subcortical registration, a subcortical mask was applied, to locate the different subcortical structures, followed by segmentation based on shape models and voxel intensities. The absolute volumes of subcortical structures were calculated, taking into account the transformations made in the first stage. Finally, a boundary correction was used to determine whether boundary voxels belonged or not to the structure examined. In this study, a Z-value of 3 was used, corresponding to a 99.998% certainty that the voxels belonged to the mentioned subcortical structure. After registration and segmentation of all 139 MR scans, all segmented subcortical regions were visually checked for errors in registration and segmentation. For this study we used the absolute volumes generated by the algorithm.

The followed bicaudate parameters have been obtained, measured by the direct caudatometry (Figure 1 and Figure 2):

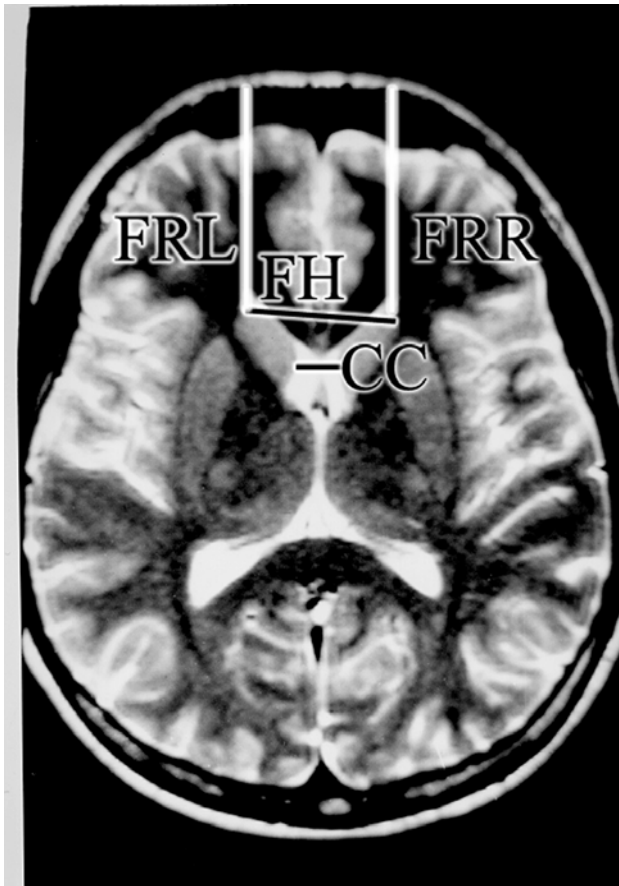
- Bicaudate, or CC line that represents the closed distance between left and right heads of caudate nuclei;
- Frontal horns or FH line that represents the most distance between the most rostral detectable points of the heads of both caudate nuclei;
- Bicorporal line that measure between the most caudal detectable points of caudate nucleus;
- Frontorostral distance, left and right, FRL and FRD, between the most rostral point on the head of both caudate nuclei (CN) and the inner tabula of the skull.
- In order to evaluate CN position to the frontal lobe, all the distances have been measured on all visible slices (10 to 12) and the mean value has been marked in database.

### Statistical analysis

SPSS 13.0 (SPSS Inc, Chicago IL, USA) has been used for data analysis. Analyzed groups have been compared for age, respect volumes of the right and left caudate nuclei and lateral ventricles by Student's t test. Pearson's correlation coefficient and linear regression have been estimated for all the subcortical volumes and volume of the lateral ventricle.

**Table 1.** Demographic characteristics of the observed population

	Examinees N=70	Controls N=70
Age	50.42±14.40	50.75±17
Gender		
Male	30	30
Female	40	40
Length of treatment	25.15±15.03	-
Atypical antipsychotic		
Olanzapine (25 patients)	Mean dose 15.75±2.58 mg/day	
Risperidone (20 patients)	Mean dose 400±2.85 mg/day	
Clozapine (25 patients)	Mean dose 225±35.36 mg/day	
Severity of illness (PANSS)		
Positive	Mean 14.14±2.89	
Negative	Mean 20.07±8.87	



CC – the bicaudate line; FH – the frontal horn line; FRL and FRD – left and right frontorostral distances

**Figure 1.** MRI scan with the linear parameters

## RESULTS

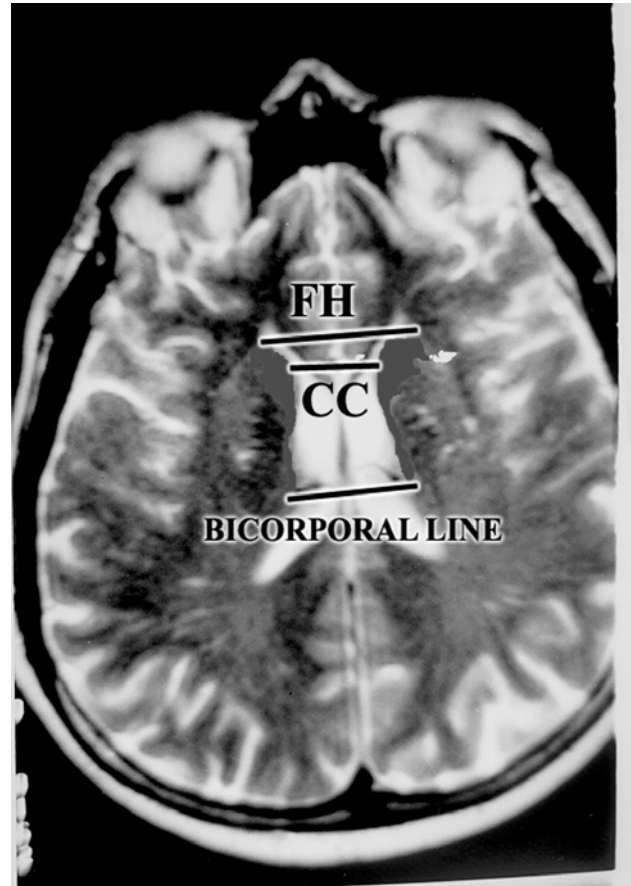
The results of this investigation could be divided into parts: linear parameters, such as bicaudate (CC), bifrontal horns distance (FH), bicorporal line and frontorostral left and right distance (FR). Volumetric parameters observed in this study were volumes of the caudate nuclei on the left and right side (VNCL, VNCR) and volumes of the lateral ventricles on the left and right hemisphere (VLVL, VLVR).

### Linear parameters

The respective values of the linear parameters are shown in the table 2.

For all linear parameters Students t-test revealed highly significant differences except for the bicorporal line.

In the examined group bicaudate line ranged from 3 to 87 mm, while in the control group the range varied from 9 to 27 mm. Almost all bicaudate parameters followed the same intention and FH line took values from 10.20 to 157 mm in the examined and 28 to 48 mm in the control group. In spite of the statistically insignificant difference the diapason between the extreme values of



CC – the bicaudate line; FH – the frontal horn line

**Figure 2.** Caudate nuclei – colored in red in order to demonstrate the bicorporal line

bicorporal lines was 116 mm (7-123 mm) in the examinees and 37 mm (33-70 mm) in the control group. Frontorostral distances in the examined group ranged from 17 to 166 mm on the left and 18 to 170 mm on the right side. In the examined group the differences were much smaller and ranged from 23 to 80 mm on the left and 26 to 82 mm on the right side.

### Volumetric parameters

The volumes of the caudate nuclei varied from 3570 to 4870 mm<sup>3</sup> on the left and from 3760 to 5140 mm<sup>3</sup> on the right side. The values among controls were in the range 2770 to 4870 mm<sup>3</sup> on the left and 2870 to 5140 mm<sup>3</sup> on the right hemisphere.

The volumes of the lateral ventricles in the examined group were between 5980 and 8770 mm<sup>3</sup> on the left, and 5810 to 8810 mm<sup>3</sup> on the right hemisphere. In the control groups obtained volumes of the lateral ventricles were from 5090 to 7780 mm<sup>3</sup> on the left and 5010 to 8450 mm<sup>3</sup> on the right side. Means of all volumetric parameters exhibited highly significant differences among controls and examinees (Table 2).

No gender based or age based differences were obtained for the examined and control groups.

**Table 2.** Examined parameters in the obtained groups (means and standard deviations - SD). Linear measures are in mm, volumes are in mm<sup>3</sup>

Parameter	Group	Mean	SD	Statistics (for all degrees of freedom = 138)
CC	Examinees	25.45	8.22	T=4.201, p=0.000
	Controls	17.90	4.41	
FH	Examinees	80.98	29.01	T=15.48, p=0.000
	Controls	37.33	4.99	
Bicorporal	Examinees	56.48	22.64	NS
	Controls	51.86	10.27	
FRL	Examinees	99.97	26.59	T=15.58, p=0.000
	Controls	53.30	10.85	
FRR	Examinees	101.02	25.21	T=16.75, p=0.000
	Controls	52.90	9.93	
VCNL	Examinees	4122.70	392.01	T=2.78, p=0.006
	Controls	3912.30	578.77	
VCNR	Examinees	4188.20	398.43	T=3.38, p=0.003
	Controls	3958.30	574.16	
VLVL	Examinees	6691.82	496.64	T=7.198, p=0.000
	Controls	6113.27	569.79	
VLVR	Examinees	6660.40	587.5	T=6.44, p=0.000
	Controls	6078.72	621.82	

Abbreviations used in the table: CC – bicaudate line; FH – frontal horns line; FRL and FRD – mean of the left and right fronto rostral distances left; VCNL – volume of the left caudate nucleus; CNR – volume of the right caudate nucleus; VLVL – volume of the left lateral ventricle; VLVR – volume of the right lateral ventricle

**Table 3.** Correlation matrix between the parameters obtained

Parameter	CC	FH	Bicorporal	FRL	FRR	VCNL	VCNR	VLVL	VLVR	Treatment
CC		0.610 <sup>#</sup>	0.602 <sup>#</sup>	0.220 <sup>#</sup>	0.240 <sup>#</sup>	0.054	0.057	0.145 <sup>*</sup>	0.175 <sup>*</sup>	0.051
Pearson CC										NS
FH	0.610 <sup>#</sup>		0.394 <sup>#</sup>	0.585 <sup>#</sup>	0.494 <sup>#</sup>	0.201 <sup>#</sup>	0.213 <sup>#</sup>	0.427 <sup>#</sup>	0.397 <sup>#</sup>	0.046
Pearson CC										NS
Bicorporal	0.602 <sup>#</sup>	0.394 <sup>#</sup>		0.277 <sup>#</sup>	0.389 <sup>#</sup>	0.009	0.002	0.046	0.080	0.177
Pearson CC						NS	NS	NS	NS	NS
FRL	0.220 <sup>#</sup>	0.585 <sup>#</sup>	0.277 <sup>#</sup>		0.636 <sup>#</sup>	0.196 <sup>#</sup>	0.202 <sup>#</sup>	0.387 <sup>#</sup>	0.384 <sup>#</sup>	-0.032
Pearson CC										NS
FRR	0.240 <sup>#</sup>	0.494 <sup>#</sup>	0.389 <sup>#</sup>	0.636 <sup>#</sup>		0.201 <sup>#</sup>	0.204 <sup>#</sup>	0.368 <sup>#</sup>	0.348 <sup>#</sup>	-0.022
Pearson CC										NS
VCNL	0.054	0.201 <sup>#</sup>	0.009	0.196 <sup>#</sup>	0.201 <sup>#</sup>		0.970 <sup>#</sup>	-0.105	-0.100	0.101
Pearson CC	NS		NS					NS	NS	NS
VCNR	0.057	0.195 <sup>#</sup>	0.213 <sup>#</sup>	0.002	0.202 <sup>#</sup>	0.970 <sup>#</sup>		-0.068	-0.065	0.201
Pearson CC				NS				NS	NS	NS
VLVL	0.145 <sup>*</sup>	0.427 <sup>#</sup>	0.046	0.387 <sup>#</sup>	0.368 <sup>#</sup>	-0.105	-0.068		0.971 <sup>#</sup>	0.169
Pearson CC			NS			NS	NS			NS
VLVR	0.175 <sup>*</sup>	-0.086	0.397 <sup>#</sup>	0.080	0.384 <sup>#</sup>	-0.100	0.175 <sup>*</sup>	-0.086		0.169
Pearson CC		NS		NS		NS		NS		NS
Treatment	0.051	0.046	0.177	-0.032	-0.022	0.201	0.178	0.169	0.201	
Pearson CC	NS	NS	NS	NS	NS	NS	NS	NS	NS	NS

Legend: \* - significance at the 0.05 level; # - Significance at the 0.01 level;

Abbreviations used in the table: CC – bicaudate line; FH – frontal horns line; FRL and FRD – mean of the left and right fronto rostral distances left; VCNL – volume of the left caudate nucleus; CNR – volume of the right caudate nucleus; VLVL – volume of the left lateral ventricle; VLVR – volume of the right lateral ventricle

## Correlation analysis

All the parameters underwent Pearson's bivariate correlation analysis. The standard bicaudate parameters CC and FH lines correlated mutually and with the frontorostral distances of both hemispheres. Furthermore FH line correlated with the all volumes observed in this study, VNCL, VNCD, VLVL and VLVR, respectively, while this correlation failed to be obtained for CC line. The same correlations as obtained for CC line were revealed for the bicorporal line. For the frontorostral distances, however, the same kind of correlations, as for FH line, have been revealed. Volumes of the both caudate nuclei did not correlate with the volumes of the lateral ventricles. Although beside left and right correlation between the caudate nuclei the mathematical relationship has been found out for FH and bicorporal lines (Table 3).

No correlation what so ever could be attributed to treatment and obtained parameters.

No correlation has been established between PANSS and parameter changes.

## Discriminant function analysis (DFA)

DFA has been used for the extraction of the parameters valid for the patients classification into either examined or control groups.

The following parameters were outlined as important: FH line, bicorporal line, frontorostral line on the left side and the volume of the left lateral ventricle. The respective equation was:

$$CS = 0.04 \cdot FH - 0.028 \cdot BL + 0.040 \cdot FRL + 0.744 \cdot VLVL - 8.479$$

CS - Classification score; BL - Bicorporal line

The respective centroids for the classifications were: 2.442 for the examined group and -0.709 for the control group. The section point for the classification is the mean between the centroids: 0.3665.

The accuracy of the equations tested on our sample was 96.3%.

## DISCUSSION

In this study we report the attempt to investigate the reliability of the bicaudate parameters in order to estimate potential enlarged lateral ventricles in schizophrenia patients.

The ventricular enlargement is thought to be one of the most consist findings of the brain abnormality in the schizophrenia patients, as reviewed by other investigators and meta – analysis (McCarley et al. 1999, DeLisi et al. 2004, Kempton et al. 2010). It remind unclear are reported changes the consequences of the neurodegeneration, as indicated by Del Re et al. (2016) or whether it maybe a static, trait feature. Brain reduc-

tion in the schizophrenia patients after closure of the vault sutures and consecutive ventricular enlargement might be a consequence of the hypertrophic reaction as compared to age and sex matched controls (Woods et al. 1996, Lawrie & Abukmeil 1998). Although, certain investigations are reporting the larger right than the left lateral ventricles, our investigation failed to confirm those findings. Nonetheless, our values do not surpass already reported volumes of the lateral ventricles (Vita et al. 1995, Meduri et al. 2010). Discriminant function analysis, among outlined parameters important for the subsequent classifications of the newly scanned patients, listed the volume of the left ventricle as important for the prediction. In available literature, we were not able to find the reasonable explanation for the left – right asymmetry in schizophrenia patients. On the other hand, the insignificance in the bicorporal lines differences among examinees and controls, and significant differences in values of bicaudate line, frontal horn line and both frontorostral distances of the caudate nuclei of the tabula interna indirectly lead as to the speculation that frontal horns are more susceptible to the neuroanatomical in schizophrenia patients changes than the central part of the lateral ventricle. Our results are congruent to the findings of Meduri et al. (2010) who also reported the frontal horn enlargement and morphological discrepancies among schizophrenia patients in comparison to the control group. Other studies, however, temporal horns of the lateral ventricles have been outlined as enlarged more than other parts of the ventricular system in schizophrenia patients (Giesel et al. 2006).

The results from the meta analysis provided by Sommer et al. (2001) which included 19 studies of handedness 10 dichotic listening studies and 30 studies of anatomical asymmetry evidenced decrease cerebral lateralization in schizophrenia patients. They showed that schizophrenia patients as compared to healthy controls were characterized by differences in lateralization and decrease asymmetry of the planum temporal and Sylvian fissure. Our results demonstrated that there is no left and right asymmetry in both linear parameters or volumes in schizophrenia patients.

We could not confirm the findings of El - Sayed et al. (2010) who claimed that duration of illness may be critical in determining brain volume deficit, because the volumes in schizophrenia patients, did not corroborate with the length of the treatment. We have faced certainly limitation due to uncertainty of date about the period when illness began. As the average length of the treatment has been reasonable long (about 25 years), we think that our results could be generalized towards the length of the illness, as well.

The bicaudate parameters have been indicated as useful for quick evaluation of the ventricular enlargement due to diffuse tissue loss of the brain in dementia patients (Chaves et al. 1999). Although, many authors

have emphasized the importance of the bicaudate line as the most illustrative parameter for the condition of the caudate nuclei and lateral ventricles (Starkstein et al. 1989). The higher volumes among schizophrenia patients have already been introduced by Okugava et al. (2007) as result of the olanzapine administration. Oppositely, certain investigations manifested reduction of the volume of caudate nucleus in schizophrenia patients (Foong et al. 2001, McClure & Weinberger 2001).

Although, in our sample any kind of correlation with the kind or length of the treatment has not been revealed, maybe we can speculate that the increase of the volume is generally induced by the administration of atypical antipsychotics. During the selection of our sample we have recruited for this investigation only individuals who treated by atypical antipsychotics including olanzapine, clozapine and risperidone. Bicaudate parameters are also of certain use in the diagnosis of the conditions of the lateral ventricles and caudate nuclei on CT scans in epilepsy suffering patients (Duncan et al. 1997). Certain studies revealed unchanged or reduced volume of caudate nuclei in schizophrenia patients (Hannan et al. 2010, Mamah et al. 2007). The increased caudate volume after long-term administration of antipsychotics drugs has been confirmed in the experimental model and it was stated that atypical antipsychotics drugs have stronger influence to the striatal enlargement in rats (Andersson et al. 2002).

## CONCLUSION

In conclusion, we can summarize that frontal horn line as well as the distances between the most rostral points detected on the heads of the caudate nuclei are illustrative parameters for the condition of the caudate nuclei and lateral ventricles in schizophrenia patients. Although, useful for the quick orientation for the state of the ventricles bicaudate parameters, to our opinion, are just introductory measurements before the detailed MRI analysis for ventricular condition. The higher values of FH and FR lines are good indicators for the enlargement of the frontal horns of the lateral ventricles and after the confirmation of their extended distances between the caudate nuclei more minucious investigations should be perform in order to confirm ventricular enlargement and volume increase of the caudate nuclei which, after all, seemed to be the result of the therapy best on atypical antipsychotics, rather than classic neuroleptics.

**Acknowledgements:** None.

**Conflict of interest:** None to declare.

## Contribution of individual authors:

Study design: Branislav R. Filipović;  
Manuscript editing: Nebojša Milovanović;  
Study performance and database establishing: Nebojša Milovanović, Laslo Puškaš, Miloš Mališ;  
Patients selection: Srđan Milovanović, Aleksandar Damjanović, Milan Latas;  
Psychological testing and interpretation: Jasmina Barišić;  
Statistics: Gordana Stanković, Anka Ranković;  
English editing: Branka F. Filipović.

## References

1. Anastasi G, Cutroneo G, Bruschetta D, et al.: Three-dimensional volume rendering of the ankle based on magnetic resonance images enables the generation of images comparable to real anatomy. *J Anat* 2009; 215:592–599
2. Anastasi G, Cutroneo G, Tomasello F et al.: In vivo basal ganglia volumetry through application of NURBS models to MR images. *Neuroradiology* 2006; 48:338–345
3. Andersson C, Hamer RM, Lawler CP, Meilman RB, Liberman JA: Striatal volume changes in the rat following long-term administration of typical and atypical antipsychotic drugs. *Neuropsychopharmacol* 2002; 27:143–151
4. Chaves MLF, Ilha D, Maia ALG, Motta E, Lehmen R, Oliveria LM: Diagnosing dementia and normal aging: clinical relevance of brain ratios and cognitive performance in a Brazilian sample. *Braz J Med Biol Res* 1999; 32:1133–1143
5. Chung Y, Haut KM, He G, et al.: North American Prodrome Longitudinal Study (NAPLS) Consortium. Ventricular enlargement and progressive reduction of cortical gray matter are linked in prodromal youth who develop psychosis. *Schizophr Res* 2017; 189:169–174
6. Corson PW, Nopoulos P, Andreasen NC: Caudate size in first-episode neuroleptic-naïve schizophrenic patients measured using artificial neural network. *Biol Psychiatry* 1999; 46:712–720
7. Del Re EC, Konishi J, Bouix S, et al.: Enlarged lateral ventricles inversely correlate with reduced corpus callosum central volume in first episode schizophrenia: association with functional measures. *Brain Imaging Behav* 2016; 10:1264–1273
8. DeLisi LE, Sakuma M, Maurizio AM, Relja M, Hoff AL: Cerebral ventricular change over the first 10 years after the onset of schizophrenia. *Psychiatry Res* 2004; 15:57–70
9. Duncan JS: *Imaging and Epilepsy*. *Brain* 1997; 120:339–377
10. El-Sayed M, Steen G, Poe MD, et al.: Brain volumes in psychotic youth with schizophrenia and mood disorders. *J Psychiatry Neurosci* 2010; 35:229–236
11. Filipovic B, Djulejic V: *Essentials of the basic and applied anatomy of the central nervous system*. Romanov, Banja Luka, 2007
12. Filipovic B: *Anatomical and radiological study of the caudate nucleus in humans*. Doctoral thesis. School of Medicine, Belgrade, 1991

13. Foong J, Symms MR, Barker GJ, et al.: Neuropathological abnormalities in schizophrenia: evidence from magnetization transfer imaging. *Brain* 2001; 124:882–892
14. Giesel FL, Hahn HK, Thomann PA, et al.: Temporal horn index and volume of medial temporal lobe atrophy using a new semiautomated method for rapid and precise assessment. *Am J Neuroradiol* 2006; 27:1454–1458
15. Hannan KL, Wood SJ, Jyng AR, et al.: Caudate nucleus volume in individuals at ultra – high risk of psychosis: cross-sectional magnetic resonance imaging study. *Psychiatry Res: Neuroimaging* 2010; 182:223–230
16. Kay SR, Fiszbein A, Opler LA: The positive and negative syndrome scale (PANSS) for schizophrenia. *Schizophr Bul* 1987; 13:261–276
17. Kempton MJ, Stahl D, Williams SC, De Lisi L: Progressive lateral ventricular enlargement in schizophrenia: A meta-analysis of longitudinal MRI studies. *Scizophr Res* 2010; 120:54–62
18. Kinoshita Y, Okudera T, Tsuru E, Yokota A: Volumetric analysis of the germinal matrix and lateral ventricles performed using MR images of postmortem fetuses. *American Journal of Neuroradiol* 2001; 22:382–388
19. Lawrie SM, Abukmeil SS: Brain abnormality in schizophrenia: a systematic and quantitative review of volumetric magnetic resonance imaging studies. *Br J Psychiatry* 1998; 172:110–120
20. Mamah D, Wang L, de Erausquin DB, Gado M, Csernansky JG: Structural analysis of the basal ganglia in schizophrenia. *Schizophr Res* 2007; 89:59–71
21. McCarley RW, Wible CG, Frumin M, et al.: MRI anatomy of schizophrenia. *Biol Psychiatry* 1999; 45:1099–1119
22. McClure, RK, Weinberger DR: The neurodevelopmental hypothesis of schizophrenia, a review of the evidence. In: Breier A, Tran PV, Herrera JM, Tollefson GD, Bymaster, F.P. (Eds.) *Current Issues in the Psychopharmacology of Schizophrenia*. Lippincott, Williams and Wilkins, Philadelphia, 2001. pp. 27–56
23. Meduri M, Bramanti P, Ielitto G, et al.: Morphometrical and morphological analysis of lateral ventricles in schizophrenia patients versus healthy controls. *Psychiatry Res: Neuroimaging* 2010; 183:52–58
24. Nopoulos P, Torres I, Flaum M, Andreasen NC, Ehrhardt, JC, Yuh, WT: Brain morphology in first-episode schizophrenia. *Am J Psychiatry* 1995; 152:1721–1723
25. Okugava G, Nobuhara K, Takase K, Saito Y, Yoshimura M, Kinoshita T: Olanzapine increases gray and white matter volumes in the caudate nucleus of patients with schizophrenia. *Neuropsychobiology* 2007; 55:43–46
26. Shenton ME, Dickey CC, Frumin M, McCarley RW: A review of MRI findings in schizophrenia. *Schizophr Res* 2001; 49:1–52
27. Sommer I, Aleman A, Ramsey N, Bouma A, Kahn R: Handedness, language lateralisation and anatomical asymmetry in schizophrenia. Meta-analysis. *Br J Psychiatry* 2001; 178:344–351
28. Starkstein SE, Folstein SE, Brandt J, Pearlson GD, McDonnell A, Folstein M: Brain atrophy in Huntington's disease. A CT-scan study. *Neuroradiol* 1989; 31:156-9
29. Timotijevic I, Paunovic VR: *Instruments of the clinical evaluation in psychiatry*. Naučna Knjiga, Belgrade, 1992
30. Vita A, Dieci M, Giobbio GM, et al.: Language and thought disorder in schizophrenia: brain morphological correlates. *Schizophr Res* 1995; 15:243–251
31. Woods BT, Yurgelun-Todd D, Goldstein JM, Seidman LJ, Tsuang MT: MRI brain abnormalities in schizophrenia: one process or more? *Biol Psychiatry* 1996; 40:585–596

Correspondence:

Prof. Branislav Filipović, MD, D.Sc.  
Institute of Anatomy "Niko Miljanic"  
Dr Subotica 4/2, 11000 Belgrade, Serbia  
E-mail: b.filipovic@med.bg.ac.rs