

Neurologic manifestations and sleep issues in osteogenesis imperfecta

Romana Gjergja Juraški^{1,2}, Mirjana Turkalj^{1,2}, Ivan Mikula³, Dragan Primorac^{1,2,3,4,5,6,7}

Osteogenesis imperfecta (OI) is a rare genetic disorder leading to skeletal fragility, fractures and deformities. The main pathophysiologic effect of OI is reduction in either the quality or the quantity of type I collagen, affecting the structures that normally contain type I collagen. COL1A1 and COL1A2 genes account for 80% of cases. Our aim was to review relevant information on the neurodevelopment, sleep issues and neurologic complications in OI. The nervous system is involved in OI because of softening of bone at the base of the skull, resulting in upwards migration of the upper cervical spine and odontoid process. The disease may directly involve neurovascular structures, leading to cavernous fistulas, dissections, or aneurysms. The brain parenchyma can be affected in OI, with manifestations such as cerebral atrophy, hydrocephalus and cerebellar hypoplasia. Basilar impression/invagination are serious craniocervical junction abnormalities that can be life threatening. There is still no knowledge about sleep phenotype in OI. Neurologic manifestations and sleep disorders are valuable prognostic factors and are highly important features within the phenotypic complexity of OI. The measures of prevention in OI stress the need of regular monitoring of these issues from an early age and education of both OI patients and their families.

Key words: osteogenesis imperfecta, nervous system, neurodevelopment, sleep apnea

INTRODUCTION

Osteogenesis imperfecta (OI) is a rare genetic disorder leading to skeletal fragility, fractures and deformities. The main pathophysiologic effect of OI is reduction in either the quality or the quantity of type I collagen, and it is categorized as a connective-tissue disease, affecting the bones, joints, ears, eyes, skin, and other structures that normally contain type I collagen.

At least seventeen distinct types of OI have been described on the basis of specific genetic mutations so far (1, 2). *COL1A1* and *COL1A2* genes account for 80% of cases of autosomal dominant OI (3, 4), while in other types, mainly autosomal recessive OI mutations in other genes have been found, affecting bone modeling and resorption (5).

Occurrences of OI can be classified into groups or types based on the clinical and radiologic findings. According to the traditional Silience classification system from 1979 (6), type I OI (the most common type) is mild and without significant bone deformation, type II OI is fatal perinatal form, type III is seriously deforming, while type IV OI is less difficult deforming. Accurate clinical classification can be difficult be-

cause the characteristics of types I and IV and those of types II and III are overlapping. In patients with type I, fractures are less common after puberty when ossification is complete and the bones are stronger. The average life expectancy of this type is slightly reduced because of the risks of fatal bone fractures and complications such as basilar invagination.

In utero fractures of the skull, vertebrae and long bones are the main features of type II OI. Other signs of type II include

¹ Srebrnjak Children's Hospital, Zagreb, Croatia

² Josip Juraj Strossmayer University of Osijek, School of Medicine, Osijek, Croatia

³ Sv. Katarina Special Hospital, Zabok/Zagreb, Croatia,

⁴ University of Split, School of Medicine, Split, Croatia,

⁵ University of Rijeka, School of Medicine, Rijeka, Croatia,

⁶ Eberly College of Science, The Pennsylvania State University, University Park, PA, USA,

⁷ The Henry C. Lee College of Criminal Justice and Forensic Sciences, University of New Haven, West Haven, USA

Correspondence to:

Romana Gjergja Juraški, MD, PhD, Srebrnjak Children's Hospital, Srebrnjak 100, HR-10000 Zagreb, Croatia,
E-mail: romana.gjergja@zg.t-com.hr

Primljeno/Received: 5. 9. 2017., Prihvaćeno/Accepted: 7. 11. 2017.

minimal vertebral ossification, beaded ribs, and abnormally small chest. Unfortunately, children with type II OI die within the first year of life because of respiratory failure due to pulmonary hypoplasia or fatal cerebral hemorrhage (7).

Type III is the most severe type of OI seen in children that survive the neonatal period. Patients with type III can have blue sclera, small nose with micrognathism, and soft calvaria. Type III tends to progress over time if left untreated. The average life expectancy for patients with type III OI is slightly lower than that for the general population (8).

The symptoms of type IV may vary in severity from mild (similar to type I) to severe (resembling type III). The sclera appears normal. The average life expectancy for patients with type IV OI might be slightly lower than that for the general population (8). Patients with OI experience hypotonia, ligament laxity, joint hyperflexibility and dental abnormalities (dentinogenesis imperfecta), depending on the type (Table 1). The Sillence clinical classification has been updated with new noncollagen mutations in OI and differential clinical findings (types V-XVI) (9, 10). Using next generation sequencing mutations in other genes implicated in variable OI phenotype has been introduced (11).

The recent changes in classification have been made in order to reduce it to five subtypes of OI based on phenotype only (without significant bone deformation, perinatal lethal, progressively deforming, common variable OI with normal sclera, and OI with calcification of interosseous membranes) (10, 11).

NEURODEVELOPMENTAL ISSUES IN CHILDREN WITH OSTEOGENESIS IMPERFECTA

Children with OI often demonstrate delays in meeting some developmental milestones, but this can improve with age. A delay in adoption of upright position has been documented in children with OI. This delay is most evident in the severe types of OI. The mean age at which standing occurs has been reported to be 11 months in type I, 16 months in type IV, and 40 months in type III OI (12, 13).

Neurodevelopmental delays can be the result of repeated immobilizations after fractures, misalignment of the long bones and joints, and general hypotonia and ligament laxity that are common in OI (14).

The reduced mobility and early wheelchair dependence are serious effects of severe types of OI. Immobilization of the musculoskeletal system is typically followed by loss of muscle mass and progressive loss of bone mass (15). A primary bone disease such as OI leads to secondary osteopenia due to fractures and immobilization (16). Hip and back pain due to poor alignment and leg length discrepancies occur in all

types of OI and pain is an important negative factor in further psychomotor development in children with OI. One long-term follow-up study provided information concerning the natural course of developmental outcome parameters of OI in childhood, and showed that joint range of motion and muscle strength did not change significantly over time, even though the functional ability improved over time, but especially in types III and IV, it still did not reach normative values, possibly because of a plateau phase in functional ability (17).

Muscle mass is decreased in OI, even when short stature is taken into account. Dynamic muscle tests aiming at maximal eccentric force production reveal functional deficits that cannot be explained by low muscle mass alone (18). At present, the determinants of muscle mass and function in OI have not yet been clearly defined (18).

Severe muscle weakness can be the first sign of OI in an early age, presented as metabolic myopathy (19).

Lee et al. describe atypical presentation of a girl with features of OI and Russell Silver syndrome with severe hypotonia and postnatal growth impairment and microcephalia, carrying a missense mutation in *COL1A1* gene (20). Reports like this one support the expanded phenotypic spectrum of type I collagenopathy and the awareness of neurodevelopmental issues in OI.

Mild to significant short stature and slow growth rate occur in OI. Height and weight charts for the child with OI are available (21). The increase in head circumference is most notable between the ages of 2 and 3 years. In a cross-sectional study of 343 patients with different types of OI conducted by *Germain-Lee et al.*, the linear growth patterns, in addition to the marked increase in weight over time, indicated a need for early lifestyle modifications in children with OI, especially the need for weight control (22).

Progressive hearing loss is an important feature of the disease that can have negative effect on neurodevelopment, especially if it is present from an early age. In 7% of children with OI, hearing loss was evident at the age between 5 and 9 years, at first conductive then perceptive hearing loss (23). It seems that bisphosphonate therapy does not influence hearing loss. The authors recommended that audiometry be performed in children with OI even without symptoms of hearing loss at the age of 10 years, and repeated every 3 years (23).

The incidence of autism, hyperactivity and epilepsy is believed to be similar to that in the general population (24, 25), although it was suggested that electroencephalography (EEG) abnormalities (prominent photic driving responses, focal findings over the right hemisphere, of paroxysmal nature) occurred more frequently in patients with OI, possibly related to the underlying metabolic disorder (26). The authors con-

cluded that the implications of EEG findings may be different than in the general population, since changes on EEG findings did not appear to be correlated with the severity of illness and only one patient had a history of seizures (26).

Children with OI have normal intelligence, but they can underachieve in school because of the nature of the disease and physical disability (27, 28).

INVOLVEMENT OF THE NERVOUS SYSTEM IN OSTEOGENESIS IMPERFECTA

The central nervous system is usually involved in OI due to softening of bone at the base of the skull, resulting in upwards migration of the upper cervical spine and odontoid process into the skull base. Upwards migration of the spine can cause compression of the brainstem, mechanical impingement of the spinal canal with restriction of cerebrospinal fluid circulation, and impingement of the cranial nerves (29). Severe forms of OI are presented by debilitating skeletal fractures and progressive neurologic impairments may lead to perinatal death, while milder forms can be almost asymptomatic causing only modest reduction in life span.

Osteogenesis imperfecta may directly involve neurovascular structures, leading to cavernous fistulas of the carotid artery, dissection of the cervical arteries (30), and cerebral aneurysms (31, 32).

The brain parenchyma can be affected in OI, with manifestations such as cerebral atrophy (33), communicating hydrocephalus (34), and cerebellar hypoplasia (35, 36).

CRANIOCERVICAL MANIFESTATIONS AND COMPLICATIONS IN OSTEOGENESIS IMPERFECTA

Cranio-cervical pathology is one of the most serious complications of OI, and it predominantly affects patients with severe OI types. Cranial complications of OI include a wide range of abnormalities of the skull and brain parenchyma. The studies so far indicate that cranial base pathology can develop despite bisphosphonate treatment, but early initiation of bisphosphonate treatment can delay development of cranio-cervical junction pathology, therefore, regular follow-up of cranial base morphology is warranted, particularly in patients with severe OI (37).

Skull and skull base involvement in osteogenesis imperfecta

Patients with OI can have triangular face shape with a prominent forehead (frontal bossing) and mandibular malformation causing malocclusion of the lower and upper incisors. The skull is relatively large compared to the body. The fron-

tal fontanel is wider and can remain open longer than normal. Generalized impairment of membranous and endochondral bone leads to excessive formation of wormian bones (accessory bones along the sutures) with an abnormally thin or thick calvaria and premature/delayed closure of the fontanels and sutures. Multiple wormian bones may persist into adulthood (38). Flattening of the occiput can be present. Premature fusion of the coronal suture is followed by compensatory overgrowth of the sagittal suture laterally and lambdoid sutures caudally, resulting in the skull deformity called brachycephalia.

Neuroparenchymal involvement in osteogenesis imperfecta

Cerebral hemorrhage is a potentially fatal complication of OI. Intracranial hemorrhages are attributed to the vertebral artery damage, vascular fragility, spontaneous intracranial hypotension, and friction between multiple bone fragments of the skull (39-41). Cerebral aneurysms, carotid cavernous fistulas and cervical artery dissection have been reported in OI (40, 42). There are many reports of cerebral hemorrhages and spinal cord injuries in children with OI, but only few case reports of cerebral hemorrhage in adults with OI and with no evident trauma (43). Defective cross-linking of collagen, as that occurring in OI, is presumed to be a major contributor to cerebral artery aneurysms (44).

Generalized cerebral atrophy can develop in OI due to impaired outflow of cerebrospinal fluid, deformation of the skull base, forces generated by neck muscles that hold the head upright, and because of intracranial venous outflow obstruction (45-47). Hydrocephalus (48) or widened basal cistern (49) is not uncommon in OI. There are reports of unilateral cerebellar hypoplasia because of intrauterine vascular compromise due to compression of the posterior circulation secondary to craniocervical anomalies (50). These facts emphasize the need for planning brain MRI in patients with more severe types of OI.

The prenatal ultrasound features of type III OI, such as marked ventricular dilatation, shortening of the long bones and deformity of the femurs, can be severe enough to make prenatal diagnosis possible in the second trimester of pregnancy. Disorders of neuronal migration are described in children with type II OI and can result in significant neurologic decline (28).

Ultrasound prenatal screening is recommended in the presence of a high familial risk of OI.

Craniocervical junction abnormalities in osteogenesis imperfecta

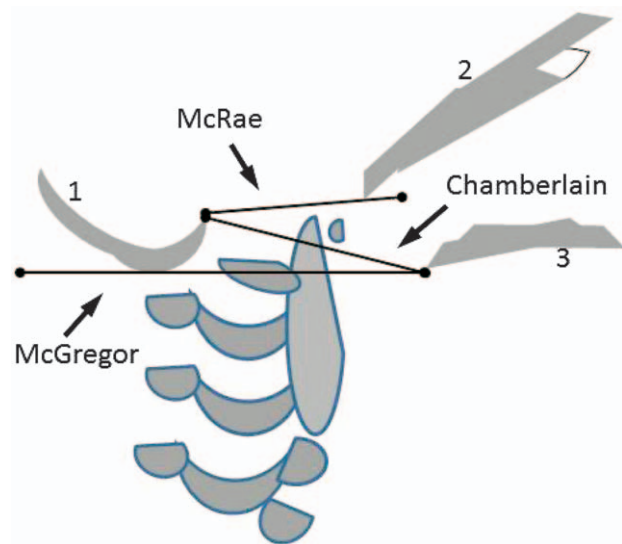
Platybasia, basilar impression and basilar invagination are craniocervical junction abnormalities that can occur in OI

because of bone softening. Basilar impression and basilar invagination are distinct characteristics, although many authors use these two conditions as synonyms. Basilar invagination is a condition in which the odontoid process protrudes upwards into the intracranial space, penetrating the foramen magnum (51). Basilar impression, or upwards infolding of the foramen magnum edge into the skull may lead to medullar and cerebellar displacement.

Clinical picture in patients with basilar impression develops slowly and progressively. Radiologic features may be present for several years before progression of neurologic signs. *Sillence et al.* (52) found that basilar impression was radiologically present long before puberty. Neurologic signs of basilar impression can be present before symptoms and include nystagmus, facial spasms, nerve paresis, pyramidal tract signs, proprioceptive deficits and papilledema in case of hydrocephalus. Neurologic symptoms develop later and include posterior headache (worse on movement), cough, sneezing, trigeminal neuralgia, balance problems, vertigo; weakness of arms and legs; and bladder disorders (53). Vestibular dysfunction and progressive hearing impairment can be expected in OI, but the inexplicable fact is that some of adult patients with OI suffer from vertigo without any hearing impairment or basilar impression (23).

The diagnosis of basilar impression is radiographic. The plain lateral cervical spine and craniogram can show translocation of the upper cervical vertebral column into the posterior fossa. In basilar impression and OI, there are characteristic shapes of the skull; one is "Tam O'Shanter" appearance of the skull with overhang of temporal and occipital bones resembling the floppy beret from Scotland, and the other is "Darth Vader" appearance of the skull, resembling the shape of helmet worn by Darth Vader, a *Star Wars* movie character (54).

Lateral craniometry can be helpful, such as measurement using McRae, Chamberlain, and McGregor lines (55) (Figure 1). McRae line is drawn from the anterior margin (basion) to the posterior margin (opisthion) of the foramen magnum. The tip of the odontoid process should normally be positioned below this line; if it is not below this line, the odontoid process has crossed through the foramen magnum into the intracranial space, and basilar invagination/impresion is present. Chamberlain line is joining the back of the hard palate with the opisthion on lateral view of the craniocervical junction. Pathologic finding is if the tip of the dens is >3 mm above this line. McGregor line is a modification of the Chamberlain line and is used when the opisthion is not identified on plain radiographs. It refers to a line connecting posterior edge of the hard palate to the most caudal point of the occipital curve. It is pathologic if the tip of the dens lies more than 4.5 mm above this line. Magnetic resonance imaging (MRI) is the optimal method for revealing abnor-



1 – OCCIPUT, 2 – CLIVUS, 3 – HARD PALATE

FIGURE 1. Cephalometric lines are important measurements in basilar impression/ invagination: McRae line, Chamberlain line and McGregor line (51). McRae line: tip of clivus (basion) to opisthion (posterior margin of foramen magnum) (this is essentially a measurement across the foramen magnum). It should be >19 mm and no part of odontoid should be above that line. McGregor line: posterior margin of hard palate to the most caudal point of occiput. No more than 4.5 mm of the dens should be above this line. Chamberlain line: posterior portion of hard palate to opisthion. No more than 3 mm of the dens should be above this line (original drawing by the authors).

malities of the brain and spinal cord. Brain MRI is the method of choice for evaluating tonsillar herniation, the early stage of development of a syrinx, and changes in posterior fossa. Tonsillar herniation as a cause of brainstem compression can lead to rapid neurologic deterioration, respiratory arrest and death (56). Platybasia was diagnosed when the anterior cranial base angle was more than 2.5 SD above the average age-specific norms (57). The ligaments and bones of the craniocervical junction allow movements of the head and provide us with support while standing and sitting. Craniocervical instability can develop in OI, where craniocervical junction anomalies have been observed in all types of OI, except for the perinatal lethal type (58). In some patients, the anomaly progressed, but in some improvement was seen (57). When compared with the historical group of OI patients with comparable severity and no exposure to bisphosphonates, a trend towards delayed development of cranial base pathology was observed (57).

The causes of craniocervical pathology in OI include a combination of bone fragility and excessive ligament laxity. The brain compresses the cranial base, causing microfractures and the cervical spine migrates upwards relative to the cranium (59).

Basilar impression and invagination are detected from the age of 2 years, while platybasia may be present from birth

(60). It has been previously suggested that platybasia predisposes to the development of Chiari malformation by overcrowding of the posterior fossa and consequently to tonsillar herniation through the foramen magnum (61). Spontaneous recovery from platybasia in OI can be explained with further growth of the child. The ligaments and vertebral instability are likely to play a major role in the development of craniocervical pathology. The cranial base anomalies develop despite bisphosphonate treatment, but early treatment can delay development of craniocervical junction pathology (62). Concerning natural history of basilar impression in each type of OI, as far as neurologic complications are yet to be established, until then the neurologic and radiographic screening for patients with OI is recommended and follow-up for positive cases should be repeated every two to three years until skeletal maturity (63).

Other spinal manifestations in osteogenesis imperfecta

Abnormal bone structure, poor enchondral and periosteal bone formation, and absence of lamellar bone lead to cortical thinning in patients with OI. Patients with OI have a wide range of radiologic abnormalities in the spine, including diffuse osteopenia, defective cortical bone formation, sclerosis of vertebral endplates, and biconcave vertebral bodies. Patients with OI may be affected by severe kyphoscoliosis or marked lordosis and scoliosis. Generalized loss of height of the thoracic vertebrae (platyspondyly) is another characteristic feature of the disease.

The prevalence of kyphoscoliosis in patients with OI ranges from 39% to 80%, depending on the study (64). Scoliosis is rarely observed in patients below 6 years of age and can progress rapidly after it has been diagnosed (65). The etiology of scoliosis in OI is still controversial, but vertebral fractures are thought to be the leading cause of scoliosis due to severe fragility of the vertebral growth plates and progression with growth (66). The poorer bone quality leads to more severe scoliosis (67). Untreated scoliosis progresses in children with OI, even into adulthood (68). *Ishikawa et al.* found that biconcave vertebrae were common in patients with OI and the presence of six or more biconcave vertebrae before puberty suggested that severe scoliosis would develop (66). Patients with type III OI with bisphosphonate treatment before age 6 had slower curve progression, whereas patients with type I or IV OI had no effect of therapy (69).

LUMBOSACRAL ABNORMALITIES IN OSTEOGENESIS IMPERFECTA

Spondylolysis and spondylolisthesis have been found in patients with OI, mainly at the L5/S1 level, with the incidence of 5% to 10%. (69). The clinical relevance and data on surgi-

cal indications of spondylolysis and spondylolisthesis in patients with OI are still not clear, and can be evaluated from few case reports.

SLEEP IN OSTEOGENESIS IMPERFECTA

For more than 100 years now, sleep has been studied and used as therapy for many illnesses. Today, we are aware of circadian rhythms of many biologic processes and the awareness of the importance of balanced quality and quantity of sleep is growing.

Sleep in rare genetic disorders is being studied, especially in those diseases that affect craniocervical structures such as specific syndromes, e.g., Apert, Crouzon, Pfeiffer syndromes, or respiratory chest wall such as skeletal dysplasias, or spinal deformities and morbid obesity such as Prader Willi syndrome. The patients with OI have abnormal chest wall architecture and abnormal lung collagen and they tend to develop chest wall and spinal deformities due to scoliosis and fractures. Only few studies looked at the effects of abnormal lung collagen and helped explain why patients with mild OI have a higher tendency to asthma and pneumonia (64).

The latest data reveal the prevalence of obstructive sleep apnea (OSA) in the general population (≥ 5 events/h in adults and ≥ 1 events/h in children), with the apnea-hypopnea index (AHI) of 9% to 38% (70).

People with OI seem to have a very high frequency of sleep related breathing problems, especially in cases where there is compromised growth and evident craniofacial and dental dysmorphic features, but there is still no information on the incidence of specific sleep disorders such as sleep apnea, sleep fragmentation, or excessive daily sleepiness in children or adults with OI. All data can only be traced from case reports.

In cases of seriously compromised structures of craniocervical junction in patients with OI, one could expect significant central sleep apnea, but published case reports on central sleep apnea mainly involve Arnold-Chiari malformation in OI and central sleep apnea as its clinical manifestation (71). The pathophysiologic mechanisms of such sleep apnea are a blunted bulbar chemical drive (if hypercapnia is present) or an increased bulbar chemical drive that destabilizes the breathing pattern during sleep (in normocapnic and hypocapnic patients). Other anomalies such as bone malformations (platybasia) or syringobulbomyelia can be involved. Other respiratory manifestations can be observed such as obstructive sleep apnea syndrome (OSAS), diaphragmatic or vocal cord paralysis. One case report showed significant obstructive sleep apnea due to unexpected laryngomalacia in an adult with OI (72).

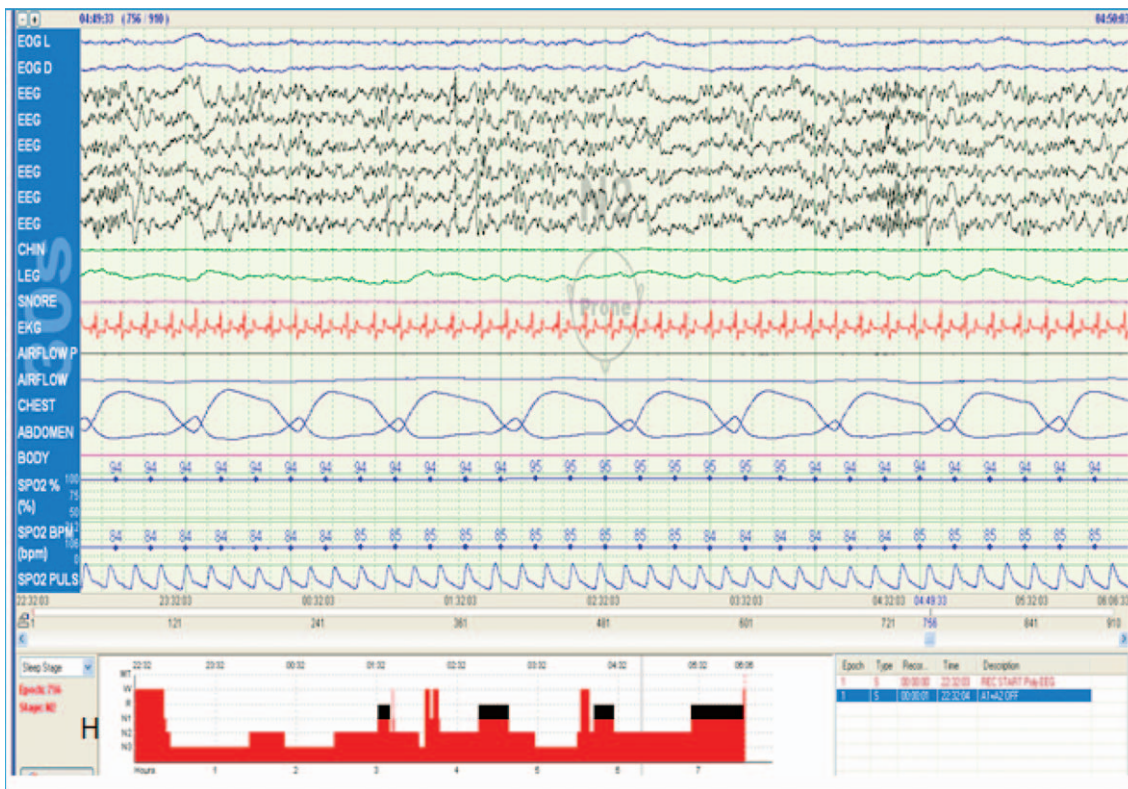


FIGURE 2. Hypnogram and one epoch of the overnight polysomnography (30 seconds) of a 6-year-old boy with osteogenesis imperfecta type I. The patient also has allergic asthma, he sweats a lot during the night, and sleeps restlessly with frequent turnovers. Overnight polysomnography was performed in our sleep laboratory. His apnea-hypopnea score was 0, but he had prolonged REM latency (180 minutes) and lower average oxygen saturation in sleep (95%). The recorded parameters from the top to the bottom are: electroencephalogram (EEG), chin electromyogram (CHIN), leg electromyogram (LEG), snore detector (SNORE), electrocardiogram (ECG), respiratory flow sensors (PRESSURE P, PRESSURE), chest and abdominal plethysmography (CHEST, ABDOMEN), peripheral oxygen saturation (spO2%) and hypnogram (H) with sleep stages at the bottom of polysomnographic finding.

Overnight polysomnography is a noninvasive diagnostic method, but there is a strong need to minimize the possibility of injuries during the night in another environment and to ensure maximal relaxation of the child or adult with OI. We recommend the child with OI in the sleep laboratory to sleep in the position he tends to have at home. Overnight polysomnography in patients with OI should include video infrared camera, microphone for vocalizations, 6-channel EEG, left and right electrooculography, chin and tibial electromyography (surface electrodes), nasal pressure transducer and nasal thermistor, thoracic/abdominal plethysmography (strain gauge), electrocardiography (2nd lead), sensors for pulse, and peripheral blood oxygen saturation (Figure 2). We recommend CO₂ end tidal measurement in children where hypercapnia is suspected. Patients should fill-in a short questionnaire about sleep and sleeping issues. Health professionals should offer overnight polysomnography to the patient with OI as a screening method, especially if there are chronic pulmonary issues such as asthma or frequent respiratory infections and craniocervical/neurologic abnormalities. Parents are not aware of sleep breathing is-

issues in children with chronic and rare diseases such as OI and they frequently underreport sleep apnea, awakenings and sleep fragmentation in their children. There are still no clinical studies analyzing sleep issues in children/adults with OI and there is still no recognizable sleep phenotype in OI. The average apnea/hypopnea scores have not yet been established in children and adults with OI. There are no studies analyzing the possible daily sleepiness in patients with OI. Excessive daily sleepiness is an important risk factor for tendency to traumatic accidents and it can be fatal in OI. There are some insights in sleep polysomnographic parameters in neuromuscular diseases where the authors had one or few patients with OI within the cohort of patients with different neuromuscular diseases (73).

Since there are seventeen genetic types of OI, it is yet to be established the phenotype-genotype correlation not only for skeletal manifestation, but also for other issues such as respiratory manifestations and sleep disturbances. OSAS should be considered as a multifactorial disease with the genetic basis and risk factors such as obesity, central control of ventilation, and craniofacial morphology (74). So far,

many genes are involved in OSAS, from the genes that induce migration of specific cellular groups to the genes leading to structural organizations (75). The association of these genes with sleep disorder in patients with OI has not yet been studied.

PERSPECTIVES IN OSTEOGENESIS IMPERFECTA

The essential pathophysiologic feature of OI is an increased bone turnover. Therefore, the most important advance in medical treatment has been the introduction of bisphosphonate therapy for patients with a moderate to severe form of OI (76). Bisphosphonates are effective in reducing osteoclast-mediated bone resorption. Intravenous pamidronate therapy administered in repeated courses over several years reduces the incidence of bone fractures and increases bone density, vertebral body height, and cortical bone thickness (77). Since patients with type VI OI are known to have poor response to such a bisphosphonate treatment, the experiences with the monoclonal RANKL antibody denosumab are promising (78, 79). In patients with severe basilar invagination, neurosurgery may be necessary with inevitable mobilization leading to diffuse atrophy of the muscles and ankylosis of the joints, and therefore should be avoided. There are no approved physiotherapy treatment approaches available in children with OI yet, but an intensive functional therapeutic approach including home based training approach leads to an increase of mobility in children with OI, which is followed by an increase of bone mineral content and bone mineral density (80).

In conclusion, neurodevelopmental issues, neurologic manifestations and sleep disorders are valuable prognostic factors and highly important features within the phenotypic complexity of OI. The measures of prevention in OI stress the need for regular multidisciplinary monitoring of these issues, as well as of other complications from an early age, along with proper education of patients with OI and their families.

NOVČANA POTPORA/FUNDING

Nema/None

ETIČKO ODOBRENJE/ETHICAL APPROVAL

Nije potrebno/None

SUKOB INTERESA/CONFLICT OF INTEREST

Autori su popunili the *Unified Competing Interest form* na www.icmje.org/coi_disclosure.pdf (dostupno na zahtjev) obrazac i izjavljuju: nemaju potporu niti jedne organizacije za objavljeni rad; nemaju financijsku potporu niti jedne organizacije koja bi mogla imati interes za objavu ovog rada u posljednje 3 godine; nemaju drugih veza ili aktivnosti koje bi mogle utjecati na objavljeni rad./All authors have completed the *Unified Competing Interest form* at www.icmje.org/coi_disclosure.pdf (available on request from the corresponding author) and declare: no support from any organization for the submitted work; no financial relationships with any organizations that might have

an interest in the submitted work in the previous 3 years; no other relationships or activities that could appear to have influenced the submitted work.

REFERENCES

- Shaker JL, Albert C, Fritz J, Harris G. Recent developments in osteogenesis imperfecta (version 1; referees: 3 approved). *F1000Research*. 2015;4(F100 Faculty Rev):681, last updated Dec 2016.
- <https://www.omim.org/>
- Cole WG. Advances in osteogenesis imperfecta. *Clin Orthop Relat Res*. 2002;401:6-16.
- Cole WG. The molecular pathology of osteogenesis imperfecta. *Clin Orthop Relat Res*. 1997;343:235-48.
- Van Dijk FS, Sillence DO. Osteogenesis imperfecta: clinical diagnosis, nomenclature and severity assessment. *Am J Med Genet A*. 2014;164A:1470-81.
- Sillence DO, Rimoin DL. Classification of osteogenesis imperfecta. *Lancet*. 1978;1:1041-2.
- Glorieux FH. Osteogenesis imperfecta. *Best Pract Res Clin Rheumatol*. 2008;22:85-100.
- Paterson CR, Ogston SA, Henry RM. Life expectancy in osteogenesis imperfecta. *BMJ*. 1996;312:351.
- Basel D, Steiner RD. Osteogenesis imperfecta: recent findings shed new light on this once well understood condition. *Genet Med*. 2009;11:375-85.
- Forlino A, Cabral WA, Barnes AM, Marini JC. New perspectives on osteogenesis imperfecta. *Nat Rev Endocrinol*. 2011;7:540-57. doi: 10.1038/nrendo.2011.81.
- Biggin A, Munns CF. Osteogenesis imperfecta: diagnosis and treatment. *Curr Osteoporos Rep*. 2014;12:279-88. doi: 10.1007/s11914-014-0225-0.
- Warman ML, Cormier Daire V, Hall C, et al. Nomenclature and classification of genetic skeletal disorders: 2010 revision. *Am J Med Genet A*. 2011;155A:943-68.
- Engelbert RH, Uiterwaal CS, Gulmans VA, Pruijs H, Helders PJ. Osteogenesis imperfecta in childhood: prognosis for walking. *J Pediatr*. 2000;137:397-402.
- Engelbert RH, Uiterwaal CS, Gulmans VA, Pruijs HE, Helders PJ. Osteogenesis imperfecta: profiles of motor development as assessed by a postal questionnaire. *Eur J Pediatr*. 2000;159:615-20.
- Schoenau E, Neu CM, Beck B, Manz F, Rauch F. Bone mineral content per muscle cross-sectional area as an index of the functional muscle-bone unit. *J Bone Miner Res*. 2002;17:1095-101.
- Schoenau E. The "functional muscle-bone unit": a two-step diagnostic algorithm in pediatric bone disease. *Pediatr Nephrol*. 2005;20:356-9.
- Engelbert RH, Uiterwaal CS, Gerver WJ, van der Net JJ, Pruijs HE, Helders PJ. Osteogenesis imperfecta in childhood: impairment and disability. A prospective study with 4-year follow-up. *Arch Phys Med Rehabil*. 2004;85:772-8.
- Veilleux LN, Trejo P, Rauch F. Muscle abnormalities in osteogenesis imperfecta. *J Musculoskelet Neuronal Interact*. 2017;17:1-7.
- Boot AM, de Coo RF, Pals G, de Muinck Keizer-Schrama SM. Muscle weakness as presenting symptom of osteogenesis imperfecta. *Eur J Pediatr*. 2006;165:392-4. Epub 2006 Mar 14.
- Lee JS, Seo J, Cho A, et al. Severe hypotonia and postnatal growth impairment in a girl with a missense mutation in COL1A1: implication of expanded phenotypic spectrum of type I collagenopathy. *Brain Dev*. 2017;28. pii: S0387-7604(17)30140-7. doi: 10.1016/j.braindev.2017.04.020. [Epub ahead of print].
- Graff K, Syczewska M. Developmental charts for children with osteogenesis imperfecta, type I (body height, body weight and BMI). *Eur J Pediatr*. 2017;176:311-6. doi:10.1007/s00431-016-2839-y.
- Germain-Lee EL, Brennen FS, Stern D, et al. Sectional and longitudinal growth patterns in osteogenesis imperfecta: implications for clinical care. *Pediatr Res*. 2016;79:489-95. doi: 10.1038/pr.2015.230. Epub 2015 Nov 5).

23. Kuurila K, Grénman R, Johansson R, Kaitila I. Hearing loss in children with osteogenesis imperfecta. *Eur J Pediatr.* 2000;159:515-9.
24. Samadi R, Manteghi A, Haghighi M, Assari S. Osteogenesis imperfecta complicated with psychosis secondary to complex partial seizures. *Int J Case Rep Images.* 2015;6:332-7.
25. Pyott SM, Tran TT, Leistriz DF, et al. WNT1 mutations in families affected by moderately severe and progressive recessive osteogenesis imperfecta. *Am J Hum Genet.* 2013;92:590-7.
26. Relte M, Solomons C. The EEG in osteogenesis imperfecta. *Clin Electroenceph.* 1988;118:16-21.
27. Cole DE. Psychosocial aspects of osteogenesis imperfecta: an update. *Am J Med Genet.* 1993;45:207-11.
28. Primorac D, Rowe DW, Mottes M, et al. Osteogenesis imperfecta at the beginning of bone and joint decade. *Croat Med J.* 2001;42:393-415.
29. Wallace MJ, Kruse RW, Sukeno D, Shah A. The spine in patients with osteogenesis imperfecta. *J Am Acad Orthop Surg.* 2017;25:100-9.
30. Albayram S, Kizilkilic O, Yilmaz H, et al. Abnormalities in the cerebral arterial system in osteogenesis imperfecta. *AJNR Am J Neuroradiol.* 2003;24:748-50.
31. Petruzzellis M, De Blasi R, Lucivero V, et al. Cerebral aneurysms in a patient with osteogenesis imperfecta and exon 28 polymorphism of COL1A2. *AJNR Am J Neuroradiol.* 2007;28:397-8.
32. Yoneyama T, Kasuya H, Onda H, et al. Collagen type I $\alpha 2$ (COL1A2) is susceptible gene for intracranial aneurysms. *Stroke.* 2004;35:443-8. Epub 2004 Jan 22.
33. Brooks ML, Gall C, Wang AM, Schick R, Rumbaugh CL. Osteogenesis imperfecta associated with basilar impression and cerebral atrophy: a case report. *Comput Med Imaging Graph.* 1989;13:363-7.
34. Khandanpour N, Connolly DJ, Raghavan A, Griffiths PD, Hoggard N. Craniospinal abnormalities and neurologic complications of osteogenesis imperfecta: imaging overview. *Radiographics.* 2012; 32:2101-12.
35. Syamlal S, Shine S, Kunju M. Brainstem and cerebellar hypoplasia associated with osteogenesis imperfecta type-5. *J Postgrad Med.* 2006;52:152-3.
36. Tabarki B, Al-Malki S, Al Ghamdi H. Severe cerebellar hypoplasia associated with osteogenesis imperfecta type III. *J Pediatr.* 2007;151:325.
37. Arponen H, Vuorimies I, Haukka J, Valta H, Waltimo-Sirén J, Mäkitie O. Cranial base pathology in pediatric osteogenesis imperfecta patients treated with bisphosphonates. *J Neurosurg Pediatr.* 2015;15:313-20.
38. Glass RB, Fernbach SK, Norton KI, Choi PS, Naidich TP. The infant skull: a vault of information. *Radiographics.* 2004;24:507-22.
39. Eddeine HS, Dafer RM, Schneck MJ, Biller J. Bilateral subdural hematomas in an adult with osteogenesis imperfecta. *J Stroke Cerebrovasc Dis.* 2009;18:313-5.
40. Hathaway WE, Solomons CC, Ott JE. Platelet function and pyrophosphates in osteogenesis imperfecta. *Blood.* 1972;39:500-9.
41. Albayram S, Kizilkilic O, Yilmaz H, Tuysuz B, Kocer N, Islak C. Abnormalities in the cerebral arterial system in osteogenesis imperfecta. *AJNR Am J Neuroradiol.* 2003;24:748-50.
42. Emery SC, Karpinski NC, Hansen L, Masliah E. Abnormalities in central nervous system development in osteogenesis imperfecta type II. *Pediatr Dev Pathol.* 1999;2:124-30.
43. Sasaki-Adams D, Kulkarni A, Rutka J, Dirks P, Taylor M, Drake JM. Neurosurgical implications of osteogenesis imperfecta in children: report of 4 cases. *J Neurosurg Pediatr.* 2008;1:229-36.
44. Kaliaperumal C, Walsh T, Balasubramanian C, Wyse G, Fanning N, Kaar G. Osteogenesis imperfecta presenting as aneurysmal subarachnoid haemorrhage in a 53-year-old man. *BMJ Case Reports.* 2011;2011:bcr1020114910. doi:10.1136/bcr.2011.4910
45. Brooks ML, Gall C, Wang AM, Schick R, Rumbaugh CL. Osteogenesis imperfecta associated with basilar impression and cerebral atrophy: a case report. *Comput Med Imaging Graph.* 1989;13:363-7.
46. Charnas LR, Marini JC. Communicating hydrocephalus, basilar invagination, and other neurologic features in osteogenesis imperfecta. *Neurology.* 1993;43:2603-8.
47. Berg JW, Goadsby PJ. Significance of atypical presentation of symptomatic SUNCT: a case report. *J Neurol Neurosurg Psychiatry.* 2001;70:244-6.
48. Hayes M, Parker G, Eil J, Sillence D. Basilar impression complicating osteogenesis imperfecta type IV: the clinical and neuroradiological findings in four cases. *J Neurol Neurosurg Psychiatry.* 1999;66:357-64.
49. Jensen BL, Lund AM. Osteogenesis imperfecta: clinical, cephalometric, and biochemical investigations of OI types I, III, and IV. *J Craniofac Genet Dev Biol.* 1997;17:121-32.
50. Zhou LJ, Khong PL, Wong KY, Ooi GC. A case of cerebellar hypoplasia in a Chinese infant with osteogenesis imperfecta. *Hong Kong Med J.* 2004;10:211-3.
51. Cronin CG, Lohan DG, Mhuirheartigh JN, Meehan CP, Murphy J, Roche C. CT evaluation of Chamberlain's, McGregor's, and McRae's skullbase lines. *Clin Radiol.* 2009;64:64-9.
52. Sillence DO, Wilson M, Morley K, Onik E, Kozłowski K, Eil J. Basilar impression complicating osteogenesis imperfecta: natural history and correlation with OI type. In: *Proceedings of the Fifth International Conference on Osteogenesis Imperfecta*; 1993 Sep 27-30; Oxford, UK. p. 139-41.
53. Sillence DO. Craniocervical abnormalities in osteogenesis imperfecta: genetic and molecular correlation. *Pediatr Radiol.* 1994;24:427-30.
54. Lubicky JP. The spine in osteogenesis imperfecta. In: Weinstein SL, editor. *The Pediatric Spine: Principles and Practice.* New York (NY): Raven Press; 1994. p. 943-58.
55. Copley LA, Dormans JP. Cervical spine disorders in infants and children. *J Am Acad Orthop Surg.* 1998;6:204-14.
56. McAllison SJ, Paterson CR. Causes of death in osteogenesis imperfecta. *J Clin Pathol.* 1996;49:627-30.
57. Arponen H, Vuorimies I, Haukka J, Waltimo-Sirén HVJ, Mäkitie O. Cranial base pathology in pediatric osteogenesis imperfecta patients treated with bisphosphonates. *J Neurosurg Pediatr.* 2015;15:313-20.
58. Ivo R, Fuerderer S, Eysel P. Spondylolisthesis caused by extreme pedicle elongation in osteogenesis imperfecta. *Eur Spine J.* 2007;16:1636-40.
59. Sawin PD, Menezes AH. Basilar invagination in osteogenesis imperfecta and related osteochondrodysplasias: medical and surgical management. *J Neurosurg.* 1997;86:950-60.
60. Arponen H, Mäkitie O, Haukka J, et al. Prevalence and natural course of craniocervical junction anomalies during growth in patients with osteogenesis imperfecta. *J Bone Miner Res.* 2012;27:1142-9.
61. Fernandes YB, Ramina R, Campos-Herrera CR, Borges G. Evolutionary hypothesis for Chiari type I malformation. *Med Hypotheses.* 2013;81:715-9.
62. Rauch F, Travers R, Glorieux FH. Pamidronate in children with osteogenesis imperfecta: histomorphometric effects of long-term therapy. *J Clin Endocrinol Metab.* 2006;91:511-6.
63. Hayes M, Parker G, Eil J, Sillence D. Basilar impression complicating osteogenesis imperfecta type IV: the clinical and neuroradiological findings in four cases. *J Neurol Neurosurg Psychiatry.* 1999;66:357-6.
64. Widmann RF, Bitan FD, Laplaza FJ, Burke SW, DiMaio MF, Schneider R. Spinal deformity, pulmonary compromise, and quality of life in osteogenesis imperfecta. *Spine (Phila Pa 1976)* 1999;24:1673-8.
65. Benson DR, Newman DC. The spine and surgical treatment in osteogenesis imperfecta. *Clin Orthop Relat Res.* 1981;159:147-53.
66. Ishikawa S, Kumar SJ, Takahashi HE, Homma M. Vertebral body shape as a predictor of spinal deformity in osteogenesis imperfecta. *J Bone Joint Surg Am.* 1996;78:212-9.
67. Watanabe G, Kawaguchi S, Matsuyama T, Yamashita T. Correlation of scoliotic curvature with Z-score bone mineral density and body mass index in patients with osteogenesis imperfecta. *Spine (Phila Pa 1976)* 2007;32:488-94.
68. Yong-Hing K, MacEwen GD. Scoliosis associated with osteogenesis imperfecta. *J Bone Joint Surg Br.* 1982;64:36-43.
69. Hatz D, Esposito PW, Schroeder B, Burke B, Lutz R, Hasley BP. The incidence of spondylolysis and spondylolisthesis in children with osteogenesis imperfecta. *J Pediatr Orthop.* 2011;31:655-60.

70. Senaratna CV, Perret JL, Lodge CJ, et al. Prevalence of obstructive sleep apnea in general population. A systematic review. *Sleep Med Rev.* 2017;34:70-81.
71. Reybet-Degat O. Pathology of craniocervical junction and sleep disorders. *Rev Neurol (Paris).* 2001;157(11 Pt 2):156-60.
72. Hseuh-Yu L, Tuan-Jen F, Ju-Li L, Zhon-Liau L, Li-Ang L. Laryngomalacia causing sleep apnea in an osteogenesis imperfecta patient. *Am J Otolaryngol.* 2002;23:378-81.
73. Pradella M. Sleep polygraphic parameters in neuromuscular diseases. *Arq Neuropsiquiatr.* 1994;52:476-83.
74. Taheri S, Mignot E. The genetics of sleep disorders. *Lancet Neurol.* 2002;1:242-50.
75. Casale M, Pappacena M, Rinaldi V, Bressi F, Baptista P, Salvinelli F. Obstructive sleep apnea syndrome: from phenotype to genetic basis. *Curr Genomics.* 2009;10:119-26.
76. Semler O, Beccard R, Palmisano D, et al. Reshaping of vertebrae during treatment with neridronate or pamidronate in children with osteogenesis imperfecta. *Horm Res Paediatr.* 2011;76:321-7.
77. Semler O, Garbes L, Keupp K, et al. A mutation in the 5'-UTR of IFITM5 creates an in-frame start codon and causes autosomal-dominant osteogenesis imperfecta type V with hyperplastic callus. *Am J Hum Genet.* 2012;91:349-57.
78. Hoyer-Kuhn H, Netzer C, Koerber F, Schoenau E, Semler O. Two years' experience with denosumab for children with osteogenesis imperfecta type VI. *Orphanet J Rare Dis.* 2014;9:145. doi: 10.1186/s13023-014-0145-1.
79. Boyce AM. Denosumab: an emerging therapy in pediatric bone disorders. *Curr Osteoporos Rep.* 2017;15:283-92. doi: 10.1007/s11914-017-0380-1.
80. Hoyer-Kuhn H, Semler O, Stark C, Struebing N, Goebel O, Schoenau E. A specialized rehabilitation approach improves mobility in children with osteogenesis imperfecta. *J Musculoskelet Neuronal Interact.* 2014;14:445-53.

SAŽETAK

Neurološke manifestacije i osobitosti spavanja u osteogenesis imperfecta

Romana Gjergja Juraški, Mirjana Turkalj, Ivan Mikula, Dragan Primorac

Osteogenesis imperfecta (OI) je rijedak genetički poremećaj koji dovodi do krhkosti kostiju, prijeloma i deformiteta. Glavni patofiziološki učinak OI je smanjenje u kvaliteti ili kvantiteti kolagena tip I te su stoga zahvaćene strukture koje normalno sadrže kolagen tip I. U 80% slučajeva postoje promjene u genima COL1A1 i COL1A2. Naš cilj je bio pretražiti relevantne podatke o neurorazvoju, spavanju i neurološkim komplikacijama u OI. Živčani sustav je zahvaćen u OI zbog omekšavanja kosti na bazi lubanje, što rezultira migracijom gornjeg dijela cervikalne kralježnice i odontoidnog procesusa. Bolest može izravno zahvatiti neurovaskularne strukture pa nastaju kavernoze fistule, disekcije ili aneurizme. Moždani parenhim je zahvaćen u OI, s kliničkim entitetima kao što su cerebralna atrofija, komunicirajući hidrocefalus i cerebelarna hipoplazija. Bazilarna impresija/invaginacija su ozbiljne abnormalnosti kranio-cervikalne veze i mogu biti životno ugrožavajuće. Zasad postoji vrlo malo saznanja o obrascima spavanja u OI. Neurološke komplikacije i poremećaji spavanja su korisni prognostički čimbenici i izrazito važne manifestacije unutar složenog fenotipa u OI. Mjere prevencije u OI ukazuju na potrebu redovitog praćenja ove problematike od rane dobi i edukacije bolesnika s OI i njihovih obitelji.

Ključne riječi: osteogenesis imperfecta, živčani sustav, neurorazvoj, apneja u spavanju