

COLORECTAL CANCER - PATHOHISTOLOGICAL STANDARDS

SANDA ŠITIĆ¹, MARIJA MILKOVIĆ PERIŠA¹, IVA BOBUŠ KELČEC², TAJANA SILOVSKI³,
HRVOJE SILOVSKI⁴ and TOMISLAV OREŠIĆ⁵

¹Department for Pathology Ljudevit Jurak, Unit for Oncological Pathology,
University Hospital Center Sestre milosrdnice, Zagreb, Croatia

²Department for Cytology, University Hospital Center Sestre milosrdnice, Zagreb, Croatia

³Department of Radiotherapy, University Hospital for Tumors,
University Hospital Center Sestre milosrdnice, Zagreb, Croatia

⁴Department for Gastrointestinal Surgery, University Hospital Center Zagreb, Zagreb, Croatia

⁵Department for Surgical Oncology, University Hospital for Tumors,
University Hospital Center Sestre milosrdnice, Zagreb, Croatia

Summary

Colorectal carcinoma is the third most common cancer site in Croatia, according to the data published by the The Croatian National Cancer Registry. In the last decade, the knowledge about pathogenesis and molecular background of colorectal carcinoma has increased dramatically. More than 90% of colorectal carcinomas are adenocarcinomas originating from epithelial cells of the colorectal mucosa. Tumor staging is the most important prognostic predictor of clinical outcome for patients with colorectal carcinoma. The TNM classification has nowadays replaced other classification systems (Dukes, Astler-Coller) and serves as golden standard in everyday practise. In 2012, 5th Croatian Congress for Pathology resulted in uniform standard for pathologic reporting for all cancer sites. The future for colorectal cancer prognosis and therapy is to discover new molecular subtypes of colorectal cancer which represents the future of personalized oncology and will guide drug-development strategies.

KEY WORDS: *colorectal cancer, TNM classification, personalized oncology*

KOLOREKTALNI KARCINOM - PATOHISTOLOŠKI STANDARDI

SAŽETAK

Prema podacima Registra za rak karcinom kolorektuma je treće najčešće tumorsko sjelo u Hrvatskoj. U zadnjih deset godina imamo brojna nova saznanja o patogenezi i molekularnim karakteristikama karcinoma kolorektuma. Više od 90% kolorektalnih karcinoma su adenokarcinomi po histološkom tipu, porijekla epitelnih stanica kolorektalne mukoze. Stadij tumora je najbitniji prognostički čimbenik za pacijente s tom bolešću. U današnje je vrijeme TNM klasifikacija zamijenila druge klasifikacijske sustave (Dukes, Astler-Coller) i koristi se kao zlatni standard u svakodnevnoj praksi. 2012. na Hrvatskom kongresu patologa, doneseni su standardi za sva tumorska sjela, koje mora zadovoljavati svaki patohistološki nalaz. Budućnost prognoze i terapije kolorektalnog karcinoma je otkriće novih molekularnih podtipova prema kojima bi se određivala personalizirana onkološka terapija te odredile nove strategije liječenja.

KLJUČNE RIJEČI: *karcinom kolorektuma, TNM klasifikacija, personalizirana terapija*

INTRODUCTION

Colorectal carcinoma is the third most common cancer site in Croatia, according to the data published by the The Croatian National Cancer Registry, with the 9% of incidence in men and 8% of incidence in women in 2013, after prostate and lung/bronchus cancers in men and after breast and lung/bronchus cancers in women. It is also the third leading cause of cancer-related death in Croatia after lung/bronchus and prostate cancers in men and after lung/bronchus and breast cancers in women in the same year (1). With the rapid therapeutic advancement in the era of personalized medicine, the role of pathologists in the management of patients with colorectal carcinoma has expanded from traditional morphologists to clinical consultants for gastroenterologists, colorectal surgeons, oncologists and medical geneticists. Nowadays, pathologists are not only responsible for providing accurate histopathologic diagnosis, but also for assessing pathologic staging, analyzing surgical margins, searching for prognostic parameters that are not included in the staging such as lymphovascular and perineural invasion, and assessing therapeutic effect in patients who have received neoadjuvant therapy.

In the last decade, the knowledge about pathogenesis and molecular background of colorectal carcinoma has increased dramatically. As a result, pathological diagnosis of colorectal carcinoma is now more complex and includes analyzing histologic features of the tumours that are suggestive of microsatellite instability (MSI) and selecting appropriate tissue sections for MSI for identification of patients with increased risk for Lynch syndrome (2). Introduction of specific targeted therapies requires implementation of results of additional mutation analysis tests, such as analysis of the BRAF and KRAS genes mutations (3). Pathologists also play a central role in selecting appropriate tissue sections for these two mutations analysis.

HISTOPATHOLOGIC DIAGNOSIS

According to the 4th Edition of WHO Classification of Tumours of the Digestive system, several histopathological variants of colorectal carcinoma can be distinguished (4). More than 90% of colorectal carcinomas are adenocarcinomas originating

from epithelial cells of the colorectal mucosa (5). Other histopathological variants of colorectal carcinoma, some of which associated with specific molecular characteristics include mucinous, signet ring cell, medullary, serrated, cribriform comedo-type, micropapillary, neuroendocrine, squamous cell, adenosquamous, spindle cell and undifferentiated carcinomas. Conventional adenocarcinoma is characterized by glandular formation, which is the basis for histologic tumor grading. In well differentiated adenocarcinoma >95% of the tumor is gland forming. Moderately differentiated adenocarcinoma shows 50-95% gland formation. Poorly differentiated adenocarcinoma is mostly solid with <50% gland formation. The terms "low-grade" and "high-grade" are nowadays in clinical, as well histopathologic, use due to the similar behaviour of well- and moderately differentiated carcinomas. Morphological grading of tumours applies only to adenocarcinoma, "NOS" (Figure 1), because other morphological variants carry their own prognostic significance.

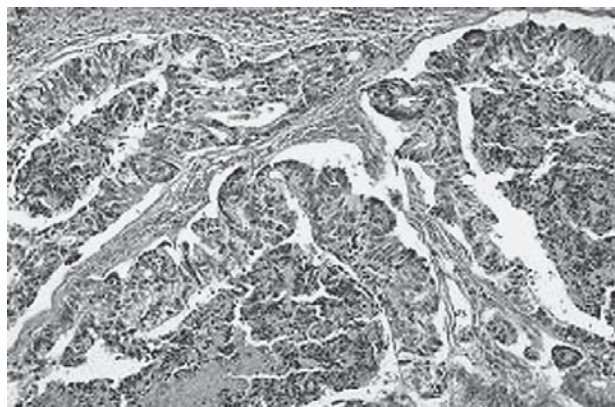

Figure 1. Adenocarcinoma ("NOS"), (original magnification X200)

Most of colorectal carcinomas are initially diagnosed by endoscopic biopsy or polypectomy. The major aspect of microscopic examination is the evidence of invasion. This is very difficult in every day practise especially when the biopsy is superficial or poorly oriented. Material is sometimes insufficient. If the muscularis mucosae can be identified, it is important to determine whether it is disrupted by neoplastic cells. Invasive carcinoma invades through the muscularis mucosae at least into the submucosa. If carcinoma is subjected

to mucosa only, it is classified as carcinoma *in situ*. Another important feature of invasion is the presence of desmoplasia, a type of fibrous proliferation surrounding tumor cells.

The major difference between colorectal and other gastrointestinal carcinomas is the following: in the colorectum, submucosal invasion is required for the diagnosis of a pT1 tumor and in other parts of the gastrointestinal tract (esophagus, stomach and small intestine), mucosal invasion is sufficient for the diagnosis of invasive carcinoma (pT1). For reasons that are not entirely clear but generally thought to be due to the relative paucity of lymphatics, invasion confined to the lamina propria and muscularis mucosae has no risk of nodal or distant metastasis(6). No matter what term is used by pathologists, the identification of high grade dysplasia or intramucosal carcinoma in a biopsy specimen should not affect the decision-making for patient management. The decision to perform surgical resection should be determined by the gross appearance of the lesion, endoscopic ultrasound findings, and endoscopic resectability.

HISTOLOGIC VARIANTS

Mucinous adenocarcinoma

This special type of colorectal carcinoma is used if >50% of the lesion is composed of pools of extracellular mucin that contain malignant epithelial cells, either individual or forming clusters, aci-

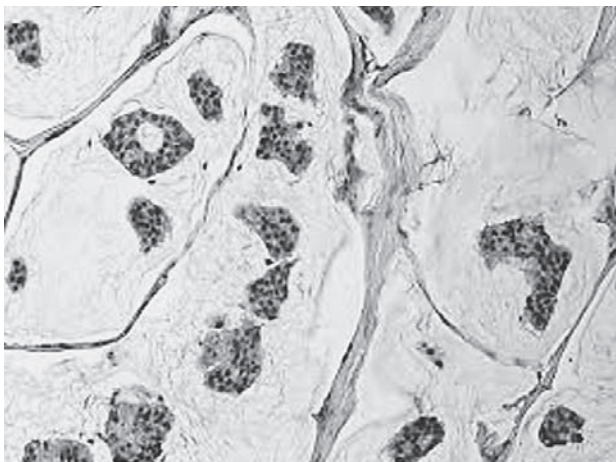


Figure 2. Mucinous adenocarcinoma showing abundant extracellular mucin (original magnification $\times 200$)

nar structures or layers. Tumors with a significant mucinous component (>10%) but <50% are categorized as adenocarcinomas with mucinous features or mucinous differentiation. (Figure 2). The prognosis of mucinous adenocarcinoma in comparison with conventional adenocarcinoma has been controversial (7,8). Some of them occur in patients with hereditary nonpolyposis colorectal cancer (HNPCC or Lynch syndrome) and thus represent high-level MSI (MSI-H) tumors with expected better clinical outcome (9). In contrast, mucinous adenocarcinomas that are microsatellite stable (MSS) are expected to behave more aggressively.

Signet ring cell adenocarcinoma

Signet ring cell adenocarcinoma is rare in the colorectum, with frequency <1% of all colorectal carcinomas. It is defined by the presence of >50% of tumor cells with prominent intracytoplasmic mucin, displacing the nucleus to the periphery. Signet ring cells may show an infiltrative growth pattern or are present within the pools of extracellular mucin. Most of them are poorly differentiated (high grade) and have worse outcome than conventional adenocarcinoma (10-12). However, some signet ring cell carcinomas may be MSI-H tumors and thus may behave as low grade tumors biologically (4).

Neuroendocrine carcinoma

Neuroendocrine carcinomas (NEC) are morphologically similar to small cell carcinoma and

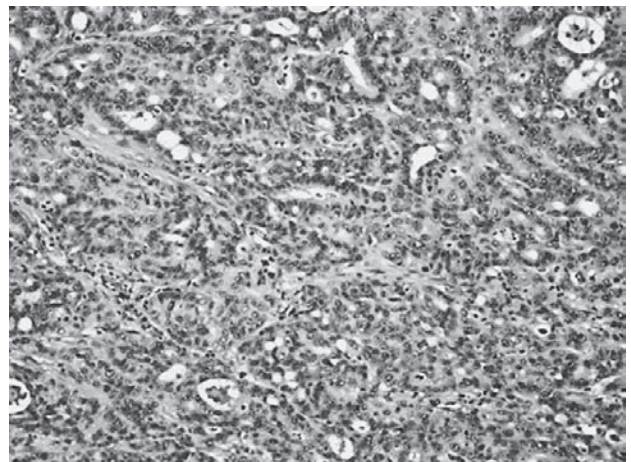


Figure 3. Neuroendocrine carcinoma, (original magnification $\times 200$)

large cell neuroendocrine carcinomas of the lung, they are usually found in the right colon, and are frequently associated with an overlying adenoma or adenocarcinoma, but not associated with neuroendocrine tumours (carcinoid tumours) (Figure 3). Primary NECs in the colon without an associated adenoma should be distinguished from pulmonary neuroendocrine carcinoma metastasis or cutaneous Merkel cell carcinoma metastasis. According to the cell morphology, small cell NEC and large cell NEC are differentiated.

Medullary carcinoma

Medullary carcinoma is extremely rare, constituting approximately 5-8 cases for every 10,000 colorectal cancers diagnosed, with a mean annual incidence of 3.47 (± 0.75) per 10 million population (13). It is characterized by sheets of malignant cells with vesicular nuclei, prominent nucleoli, and abundant eosinophilic cytoplasm exhibiting prominent infiltration by intraepithelial lymphocytes. It is strongly associated with MSI-H (14,15) and usually has a favorable prognosis despite its poorly differentiated histology.

Colorectal adenocarcinomas are immunohistochemically positive for CK20 and negative for CK7. However, up to 20% of the tumors may exhibit a CK7-positive/CK20 negative or CK7-negative/CK20-negative staining pattern. It has been suggested that reduced or absent CK20 expression in colorectal carcinoma is associated with MSI-H (16).

PATHOLOGIC STAGING

Tumor staging is the most important prognostic predictor of clinical outcome for patients with colorectal carcinoma. The TNM classification has nowadays replaced other classification systems (Dukes, Astler-Coller) and serves as golden standard in everyday practise. Several modification systems have exchanged in the last decade. (T) determines the depth of tumor invasion; T1 (tumor invades submucosa), T2 (tumor invades muscularis propria), T3 (tumor invades subserosa or into non-peritonealized pericolic or perirectal tissues) and T4 subcategorized as T4a (tumor penetrates to the surface of the visceral peritoneum) and T4b (tumor directly invades or is adherent to other organs or structures) which can sometimes be problematic because serosal surface (visceral peritoneum) involvement can sometimes be missed if the

specimen is not adequately sampled for histologic examination or it can also be replaced with the circumferential (radial) or mesenteric margin, which is a nonperitonealized surface created surgically.

(N) is the extent of nodal metastasis. According to NCCN guidelines for treatment of cancer by site, AJCC and College of American Pathologists, a minimum of 12 lymph nodes are recommended to identify early-stage colorectal cancer (17-19). The number of lymph nodes retrieved can vary with age of the patient, gender, tumour grade and tumour site (20). For stage II (pN0) cancer, if fewer than 12 lymph nodes are initially indentified, it is recommended that the pathologist goes back to the specimen and thoroughly examines tissue once again. If 12 lymph nodes are still not indentified, a comment in the report should indicate that an extensive search for lymph nodes was undertaken.

The mean number of lymph nodes retrieved for rectal cancers treated with neoadjuvant therapy is significantly less than those treated by surgery alone. To date, the number of lymph nodes needed to accurately stage neoadjuvant-treated cases is unknown.

Tumour deposits (TD) are also in N category. They are defined as discrete foci of tumor in pericolic or mesenteric fat away from the main tumor but without identifiable residual lymph node tissue. They should be in lymph drainage area. The TD's must be mentioned (by number) in pathologic report and also in N1c category in case of T1 or T2 stage.

The prognostic significance of isolated tumor cells (ITCs), defined as single tumor cells or small clusters of tumor cells ≤ 0.2 mm, detected by either immunohistochemical staining or standard hematoxylin and eosin staining in regional lymph nodes remains unclear at present.

M0 category cannot be documented on pathological evaluation, but only clinical according to TNM7. M1 has been subdivided in M1a (metastasis confined to one organ or site) and M1b (metastasis in more than one organ/site or the peritoneum).

PATHOLOGY REPORTING

In 2012, 5th Croatian Congress for Pathology resulted in uniform standard for pathologic reporting for all cancer sites. The details that should be included in the report for colorectal cancer are specimen type and size, tumor site and size, mac-

roscopic tumor perforation, macroscopic mesorectal infiltration, histologic type and grade, microscopic tumor extension, margins (proximal, distal, radial, and lateral for nonradial transanal excision), treatment effect (for tumors treated with neoadjuvant therapy), lymphovascular and perineural invasion, tumor deposits, TNM staging, total number of lymph nodes examined, size of lymph nodes examined and the total number of nodes involved, type of polyp precursor of carcinoma (if present), assessment of histologic features that are suggestive of MSI such as tumor-infiltrating lymphocytes, peritumoral Crohn-like lymphoid response and subtype and differentiation of the tumour, *k-ras* gene analysis..

PROGNOSTIC FACTORS

During the last 20 years, there have been significant advances in understanding of colorectal cancer pathogenesis. Different mechanisms of carcinogenesis underly these tumours (21). We have often seen that patients at the same stage of the disease, after radical surgery, have a completely different course of disease and outcome. Therefore, we are constantly looking for new parameters that will more accurately provide prognosis of the disease along with optimal therapy for each patient. It has become clear that the most accurate prognostic information will be achieved by combining clinico-pathological and molecular data. Unfortunately, many patients with colorectal cancer receive treatment unnecessarily, because they would either be cured even without treatment, or relapse despite of the treatment.

Seven new factors have been included in the latest TNM staging system, none of them required for staging but all of them with major prognostic and predictive values. According to the results of latest researches, all of these factors are useful for new molecular targeted therapy and personalized medicine.

Tumour deposits, mentioned above are recorded numerically.

Circumferential resection margin (CRM) represents the adventitial soft tissue closest to the deepest penetration of the tumour. It is created surgically by sharp excision and it corresponds to any aspect of the colon that is not covered by a serosal layer or mesothelial cells. The serosal (peritoneal) surface does not constitute a surgical margin. The

radial margins should be assessed in all colonic specimens with non-peritonealized surfaces. In transverse colon specimen which is completely encased with peritoneum, the mesenteric resection margin is the only relevant radial margin (22). On pathologic examination it is very difficult to assess the demarcation between the peritonealized surface and non-peritonealized surface. Therefore, surgeons are highly encouraged to mark the area of non-peritonealized surface with a clip or suture. The pathologist should measure the distance between the closest tumour margin and resection margin expressed in mm. A margin less than 1 mm is considered positive.

Perineural invasion must be recorded. Several studies have shown that the presence of perineural invasion is associated with a significantly worse prognosis (23-25).

Tumour regression grade is a marker of response to neoadjuvant therapy. The system used to grade tumour response is modified from Ryan et al. (26).

- 0 (complete response) - no remaining viable tumour cells
- 1 (moderate response) - only small clusters or single cancer cells remaining
- 2 (minimal response) - residual cancer remaining, but with predominant fibrosis
- 3 (poor response) - minimal or no tumour kill; extensive residual cancer

k-ras gene analysis detects *k-ras* gene mutation which is associated with lack of response to treatment with anti-EGFR antibody, currently recommended for the patients with metastatic colorectal cancer.

Microsatellite instability (MSI) Hereditary non-polyposis colorectal cancer (HNPCC), also known as Lynch syndrome, is a common autosomal dominant syndrome characterized by early age at onset, neoplastic lesions, and microsatellite instability (28). It is characterized by increased lifetime cancer risks primarily in the gastrointestinal and gynecologic tracts, with colorectal and endometrial carcinomas being most common. Lynch syndrome results from germline mutation in one of the four DNA mismatch repair (MMR) genes (MLH1, MSH2, MSH6, PMS2). Lynch syndrome tumours screening (immunohistochemically or MSI), according to NCCN recommendations, should be considered for colorectal carcinoma patients diagnosed at ≤ 70 years and also those older than 70 years who meet the Bethesda guidelines.

CONCLUSIONS

Colorectal adenocarcinoma is a heterogeneous disease that involves multiple tumorigenic pathways. The future for colorectal cancer prognosis and therapy is promising, but we must concentrate on optimising current methods, most of all histopathology and discover new molecular subtypes of colorectal cancer which represents the future of personalized oncology and will guide drug-development strategies.

REFERENCES

1. Croatian National Institute of Public Health, Croatian National Cancer Registry, Cancer incidence in Croatia, 2011, Zagreb, 2013. Bulletin No. 36.
2. Lynch HT, Lynch JF, Lynch PM. Toward a consensus in molecular diagnosis of hereditary nonpolyposis colorectal cancer (Lynch syndrome). *J Natl Cancer Inst.* 2007;99:261-3.
3. Pritchard C, Gredy W. Colorectal cancer molecular biology moves into clinical practice. *Gut* 2011;60:116-129.
4. Bosman FT, Carneiro F, Hruban RH, Theise ND. WHO Classification of Tumours of the Digestive System. Lyon: IARC; 2010.
5. Boyle P, Levin B (eds). World Cancer Report. Lyon: IARC; 2008.
6. Fleming M, Ravula S et al. Colorectal carcinoma: Pathologic aspects. *J Gastrointest Oncol* 2012; 3(3): 153–173.
7. Jass JR, Atkin WS, Cuzick J, et al. The grading of rectal cancer: historical perspectives and a multivariate analysis of 447 cases. *Histopathology* 1986;10:437-59.
8. Compton CC. Pathology report in colon cancer: what is prognostically important? *Dig Dis* 1999;17:67-79.
9. Edge SB, Byrd DR, Compton CC, et al. *AJCC Cancer Staging Handbook*, 7th edition. New York: Springer; 2010: str.173-206.
10. Kang H, O'Connell JB, Maggard MA, et al. A 10-year outcomes evaluation of mucinous and signet-ring cell carcinoma of the colon and rectum. *Dis Colon Rectum* 2005;48:1161-8.
11. Chen JS, Hsieh PS, Chiang JM, et al. Clinical outcome of signet ring cell carcinoma and mucinous adenocarcinoma of the colon. *Chang Gung Med J* 2010;33:51-7.
12. Makino T, Tsujinaka T, Mishima H, et al. Primary signet-ring cell carcinoma of the colon and rectum: report of eight cases and review of 154 Japanese cases. *Hepato-gastroenterology* 2006;53:845-9.
13. Thirunavukarasu P, Sathaiha M, Singla S, et al. Medullary carcinoma of the large intestine: a population based analysis. *Int J Oncol* 2010;37:901-7.
14. Hinoi T, Tani M, Lucas PC, et al. Loss of CDX2 expression and microsatellite instability are prominent features of large cell minimally differentiated carcinomas of the colon. *Am J Pathol* 2001;159:2239-48.
15. Alexander J, Watanabe T, Wu TT, et al. Histopathological identification of colon cancer with microsatellite instability. *Am J Pathol* 2001;158:527-35.
16. McGregor DK, Wu TT, Rashid A, et al. Reduced expression of cytokeratin 20 in colorectal carcinomas with high levels of microsatellite instability. *Am J Surg Pathol* 2004;28:712-8.
17. Compton CC, Fielding LP, Burgardt LJ et al. Prognostic factors in colorectal cancer. College of American pathologists consensus statement. *Arch Patol Lab Med* 2000;124: 979-994.
18. Compton CC and Greene FL. The staging of colorectal cancer: 2004 and beyond. *Ca Cancer J Clin* 2004;54: 295-308.
19. Sobin HL and Greene FL. TNM classification. Clarification of number of regional lymph nodes for N0. *Cancer* 2001;92:452.
20. Goldstein NS. Lymph node recurrences from 2427 pT3 colorectal resection specimens spanning 45 years. Recommendations for a minimum number for recovered lymph nodes based on predictive probabilities. *Am J Surg Pathol* 2002;26:179-189.
21. Quirke P, Williams GT, Ectors N, Ensari A, Piard F, Negtegaal I. The future of the TNM staging system in colorectal cancer: time for a debate? *Lancet Oncol* 2007;8:651-657.
22. Washington MK, Berlin J, Branton P et al. Protocol for examination of specimens from patients with primary carcinoma of the colon and rectum. *Arch Pathol Lab Med* 2009;133: 1539-1551.
23. Fujita S, Shimoda T, Yoshimura K et al. Prospective evaluation of prognostic factors in patients with colorectal cancer undergoing curative resection. *J Surg Oncol* 2003;84:127-131.
24. Liebig C, Ayala G, Wilks J et al. Perineural invasion is an independent predictor of outcome in colorectal cancer. *J Clin Oncol* 2009;27:5131-5137.
25. Quah HM, Chou JF, Gonen M et al. Identification of patients with high-risk stage II colon cancer for adjuvant therapy. *Dis Colon Rectum* 2008;51:503-507.
26. Ryan R, Gibbons D et al. Pathological response following long-course neoadjuvant chemoradiotherapy for locally advanced rectal cancer. *Histopathology* 2005; 47:141-6.
27. Pathological response following long-course neoadjuvant chemoradiotherapy for locally advanced rectal cancer. *Histopathology.* 2005;47:141-146.
28. Umar AC, Boland R, Terdiman JP et al. Revised Bethesda Guidelines for Hereditary non Polyposis Colorectal Cancer (Lynch Syndrome) and Microsatellite Instability. *Journal of the National Cancer Institute.* 2004;4:261-268.

Author's address: Sanda Šitić, Department for Pathology Ljudevit Jurak, Unit for Oncological Pathology, University Hospital Center Sestre milosrdnice, Ilica 197, 10000 Zagreb, Croatia. E-mail: sanda.sitic@yahoo.com