

Atrophic and Annular Scarring Alopecia of the Scalp as a Finding in Underlying Systemic Sarcoidosis

Cutaneous sarcoidosis is not an uncommon disorder, and the skin can be the sole manifestation in about 10% of patients. However, when the involved anatomical area of the cutaneous sarcoidosis is the scalp and it presents as a scarring alopecia, there is an increased risk of a systemic disease (1,2).

A 79-year-old Caucasian male patient presented to our Institute with annular and painless plaques of the scalp, with variable diameter, showing a reddish and yellowish color (Figure 1, a). Furthermore, a scleroderma-like atrophy of the skin with an exposure of the

underlying vasculature was present (Figure 1, b). The patient reported that these lesions began to appear 2 years ago, with a worsening in the last 6 months. He also reported a chronic cough and dyspnea.

According to the patient's medical history, he was treated for tinea capitis with radiotherapy of the scalp at the age of 7, with temporary hair-loss and subsequent total re-growth. Additionally, during the last 7 years he was diagnosed with mental depression and treated accordingly.

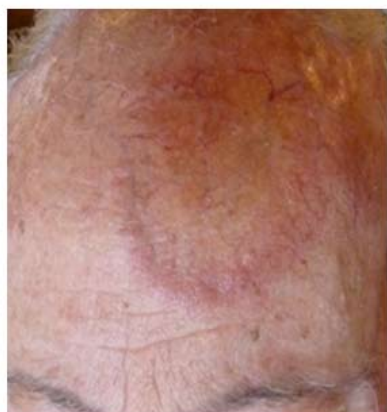

Fig.1a

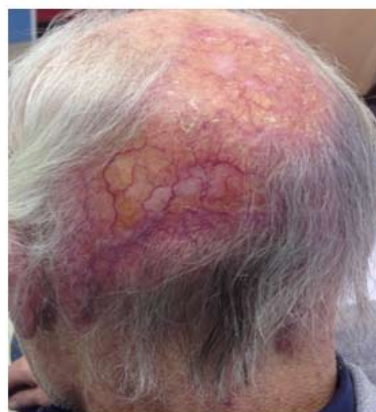

Fig.1b

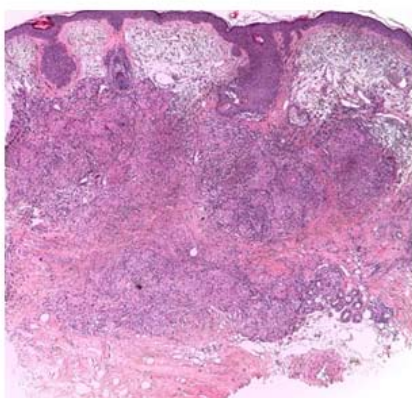


Fig.1c

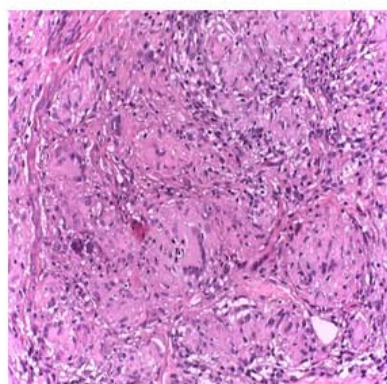


Fig.1d

Figure 1. (a) Annular and painless plaques of the scalp. (b) Scleroderma-like atrophy of the skin with an exposure of the underlying vasculature. (c) Granulomatous reaction pattern characterized by multiple granulomas in the upper dermis, elastosis, ectatic vessels, sclerosis, and edema (hematoxylin and eosin, $\times 10$). (d) Epithelioid cell granulomas, without central necrosis in association with a sparse lymphocytic infiltrate (hematoxylin and eosin, $\times 30$).

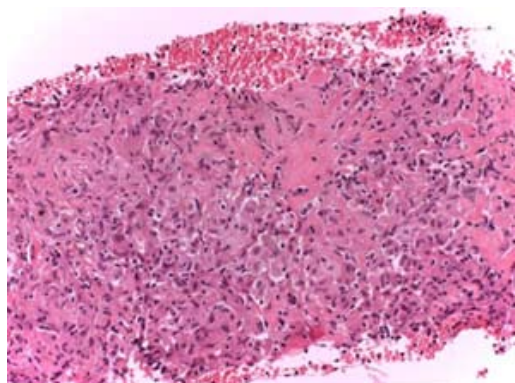


Figure 2. Biopsy of the lung showing the presence of epithelioid cell granulomas, without central necrosis (hematoxylin and eosin, $\times 10$).

The histology revealed typical epithelioid cell granulomas without central necrosis in association with a sparse lymphocytic infiltrate. Elastosis with ectatic vessels, sclerosis, and edema was also present in the upper dermis (Figure 1, c, d). A diagnosis of cutaneous sarcoidosis of the scalp was established. Laboratory investigations, including hepatitis B and C viral serology, anti-nuclear antibodies, antibodies to extractable nuclear antigen, cardiolipin, beta2 glycoprotein immunoglobulin G antibodies, and lymphoid subsets were all in normal ranges, whereas the angiotensin converting enzyme level was 124 (range: 65-114) IU/L. The chest radiography showed diffuse interstitial nodulations with bilateral and right para-tracheal lymphadenopathies, and the histology revealed pulmonary sarcoidosis (Figure 2). As of this writing, the patient is undergoing steroidal treatment with periodical clinical and instrumental follow-up, with poor response from the cutaneous lesions but an improvement of the pulmonary symptoms.

Scalp sarcoidosis is a not frequent finding (1). Most of the reported cases are Afro-American female patients. Although the main clinico-pathological differential diagnosis is atypical necrobiosis lipoidica, this entity differs from cutaneous sarcoidosis by an absence of scalp scarring alopecia and by the fact that the annular lesions are often limited to the face, without involving the scalp (1-4). Additionally, histologically atypical necrobiosis lipoidica does not reach the typical features of a sarcoid granuloma. Other potential misdiagnoses are morphea, discoid lupus erythematosus, and lichen plano-pilaris (1-4).

Sarcoidosis is most likely driven by a putative antigen in genetically susceptible individuals (5). Although radiation exposure is one of the possible causes of sarcoidosis, the radiotherapy used for the fungal infection did not have any role in the onset of the disease in our patient, as confirmed by the normal total regrowth of the hairs and the long-time interval.

Regarding the therapy (mainly steroids, azathioprine, and hydroxychloroquine), if compared to other anatomical sites, the grade of atrophy in the scalp is always too high to allow an objective clinical response, as observed in our patient.

This case emphasizes that in cutaneous annular sarcoidosis of the scalp, an underlying systemic sarcoidosis is often present.

References:

1. La Placa M, Vincenzi C, Misciali C, Tosti A. Scalp sarcoidosis with systemic involvement. *J Am Acad Dermatol.* 2008;59(5 Suppl):S126-7.
2. Katta R, Nelson B, Chen D, Roenigk H. Sarcoidosis of the scalp: a case series and review of the literature. *J Am Acad Dermatol.* 2000;42:690-2.
3. Dowling GB, Jones EW. Atypical (annular) necrobiosis lipoidica of the face and scalp. A report of the clinical and histological features of 7 cases. *Dermatologica.* 1967;135:11-26.
4. Cheraghi N, Robinson A, O'Donnell P, Belazarian L. Scalp sarcoidosis: a sign of systemic sarcoidosis. *Dermatol Online J.* 2014;17:20.
5. Loke WS, Herbert C, Thomas PS. Sarcoidosis: Immunopathogenesis and Immunological Markers. *Int J Chronic Dis.* 2013;2013:928601.

**Giovanni Paolino¹, Chiara Panetta²,
Dario Didona³, Michele Donati⁴, Pietro Donati²**

¹*Clinica Dermatologica, La Sapienza University of Rome, Rome, Italy*

²*San Gallicano Institute of Rome Dermatopathological Laboratory, Rome, Italy*

³*Prima Divisione Dermatologica, Istituto Dermopatico dell'Immacolata-IRCCS, Rome, Italy*

⁴*Department of Pathology, Campus Biomedico, Rome, Italy*

Corresponding Author:

Dario Didona, MD

Prima Divisione Dermatologica

Istituto Dermopatico dell'Immacolata-IRCCS

Via dei Monti di Creta 104

00167 Rome

Italy

didona.dermatology@gmail.com

Received: April 26, 2016

Accepted: November 4, 2017