

# Coexistence of synchronous bilateral Wilms tumor and trisomy 21 – first report and review of literature

## Koegzistencija sinkronog bilateralnog Wilmsova tumora i trisomije 21 – prvi prikaz i pregled literature

Jure Pupić-Bakrač<sup>1\*</sup>, Tomica Božić<sup>2</sup>, Ana Pupić-Bakrač<sup>3</sup>, Azer Rizikalović<sup>4</sup>, Petra Kovačević<sup>5</sup>

**Abstract. Aim:** The bilateral form of the Wilms tumor appears only in 5% of cases, and the incidence in children under the age of 15 is about 1: 250,000. Contrary to the expectations, large population-based studies have shown that the incidence of Wilms tumor is much lower in the population with trisomy 21 than in the general population. To our knowledge, this is the first reported case of synchronous bilateral Wilms tumor appearing in a patient with trisomy 21. **Case report:** A 19-month-old male, previously known for trisomy 21, was admitted to hospital because of chronic constipation and abdominal pain. A month before the child started to cry and suffer pain during defecation. He had the last stool seven days before the examination. Abdominal palpation in the left hypochondriac region revealed a solid mass of about 6x6 cm in size. Ultrasound and Multislice Computed Tomography showed a tumor on both kidneys; the right was smaller, and the left was larger – destroying most of the parenchyma and causing the bowel obstruction. After 3 weeks of chemotherapy, the radical left nephrectomy and the partial right nephrectomy were made. 28-week chemotherapy continued postoperatively. Histopathology tests confirmed the diagnosis of Wilms tumor. After recovery, the patient had a sufficient renal function. **Conclusion:** The conventional treatment with a combination of chemotherapy and surgical resection showed a good long-term outcome. However, in these cases a special caution should be focused on the quantity of preserved renal tissue, because of an increased risk of renal failure.

**Key words:** Down syndrome; Wilms tumor

**Sažetak. Cilj:** Bilateralna forma Wilmsova tumora javlja se u samo 5 % slučajeva, a incidencija kod djece do 15. godine života iznosi oko 1 : 250 000. Suprotno očekivanjima, velike populacijske studije pokazale su da je incidencija Wilmsova tumora kod trisomije 21 mnogo manja nego kod opće populacije. Prema našim saznanjima, ovo je prvi prijavljeni slučaj sinkronog bilateralnog Wilmsova tumora kod pacijenta s trisomijom 21. **Prikaz slučaja:** Muško dijete u dobi od 19 mjeseci, od ranije poznato zbog trisomije 21, dovedeno je zbog kronične opstipacije i bola u trbuhu. Prije mjesec dana dječak se počeo mučiti i plakati za vrijeme defekacije. Nije imao stolicu 7 dana pred pregled. Kliničkim pregledom palpacijom se lijevo hipohondralno pipala tvorba veličine 6 x 6 cm. Ultrazvuk i višeslojna kompjutorizirana tomografija pokazali su u svakom bubregu po jednu tumorsku tvorbu; desno manju, a lijevo veću – koja destruiira veći dio parenhima i uzrokuje opstrukciju kolona. Nakon 3 tjedna kemoterapije napravljena je ljevostrana radikalna nefrektomija i desnostrana parcijalna nefrektomija. Postoperativno je nastavljena kemoterapija u trajanju od 28 tjedana. Patohistološka analiza potvrdila je dijagnozu Wilmsova tumora. Nakon oporavka pacijent je imao zadovoljavajuću renalnu funkciju. **Zaključak:** Konvencionalno liječenje kombinacijom kemoterapije i kirurške resekcije imalo je dobar dugoročni ishod. Ipak, u ovakvim slučajevima poseban oprez potrebno je usmjeriti na količinu očuvanog renalnog tkiva zbog povećanog rizika od bubrežnog zatajenja.

**Ključne riječi:** Down sindrom; Wilmsov tumor

<sup>1</sup>Department of Emergency Medicine, University Clinical Hospital Mostar, Mostar, Bosnia and Herzegovina

<sup>2</sup>Department of Pediatrics, University Clinical Hospital Mostar, Mostar, Bosnia and Herzegovina

<sup>3</sup>Department of Family Medicine, Health Centre Mostar, Mostar, Bosnia and Herzegovina

<sup>4</sup>Department of Urology, University Clinical Hospital Mostar, Mostar, Bosnia and Herzegovina

<sup>5</sup>Faculty of Medicine, University of Mostar, Mostar, Bosnia and Herzegovina

**\*Corresponding author:**

Jure Pupić-Bakrač, MD  
Department of Emergency Medicine  
University Clinical Hospital Mostar  
Bijeli brijeg bb, 88 000 Mostar  
Bosnia and Herzegovina  
e-mail: jureppbkr2@gmail.com

<http://hrcak.srce.hr/medicina>

## INTRODUCTION

Wilms tumor (WT) is the most common intrabdominal malignancy in children (incidence of 1:10 000 in children before the age of 15 years), and there are 450-500 newly diagnosed cases of illness in the United States (US) every year<sup>1,2</sup>. Contrary to the unilateral, bilateral form of malignancy is rare – it is reported in only about 5% of cases, or 1: 250,000 children before the age of 15 years<sup>3,4</sup>. Most WT cases are sporadic, but in one

There is no optimal approach for all bilateral WT, because the manifestation of the illness is unique in each patient, so the treatment should be individually adjusted too.

of ten cases WT is associated with genetic syndromes or other congenital malformations. In available literature, an increased incidence of WT is described in many syndromes, among others in: WAGR, Denys-Drash, Fraiser, Beckwith-Wiedemann, Trisomy 18, etc<sup>5</sup>.

Trisomy 21 generally has an increased risk of developing malignancies in relation to the risk for the general population. Results of previous studies have shown that patients with trisomy 21 karyotype have a 10-20 times higher risk of developing acute lymphoblastic and acute myeloid leukemia<sup>6,7</sup>. As opposed, none of the studies showed an elevated risk of developing solid tumors. Contrary to expectations, large population-based studies and a review of tumor registers showed that the incidence of WT is lower in trisomy 21 patients than in general population<sup>8,9</sup>.

So far, several authors reported rare cases of WT appearing in the trisomy 21<sup>10,11</sup>, but to our knowledge, not bilateral WT. Below we present a case of this rare and clinically challenging coexistence of trisomy 21 and malignancy on both kidneys.

## CASE REPORT

A 19-months-old male was admitted to hospital due to chronic constipation and abdominal pain. The patient was the second child from second pregnancy. In the 33rd week of pregnancy the expectant mother was hospitalized for vaginal

bleeding and polyhydramnion. During pregnancy there was no evidence of teratogen exposure. The baby was born by Caesarean section, one day before the estimated date of delivery. The mother was 41 years old and the father 55 years old. Birth weight was 3700 g, birth length 53 cm, Apgar score 10/10. Clinical examination of the newborn detected phenotypic features of Down syndrome. Cytogenetic analysis using GTG-banding technique confirmed trisomy 21 and karyotype was: 47,XY,+21. Screening on congenital malformations detected secundum atrial septal defect (7 mm), patent ductus arteriosus (3 mm) and umbilical hernia, which were regularly monitored. At age of 4 months, the diagnosis of primary hypothyroidism was established, and at age of 10 months, diagnosis of right hearing loss of 50%.

Patient was admitted to Department of Pediatrics because of abdominal pain and stool absence 7 days before the examination. It was acknowledged that the patient previously had stool every 3-4 days, but a month before the examination, he began to suffer pain and cry during defecation. There was no blood or mucus in the stool. He did not vomit and had no fever.

Clinical examination showed that abdomen was soft, diffuse painful on palpation, without peritoneal stimulation. Auscultation of abdomen showed normal peristalsis. Palpation in the umbilical region revealed reducible umbilical hernia and in left hypochondriac region solid formation measuring about 6x6 cm. Lumbar succussion was negative. Examination of other body regions was without a pathological substrate. The vital parameters were within the normal range.

Results of laboratory tests (complete blood count (CBC), differential blood count (DBC), standard biochemical tests, urine) were within the reference values. Ultrasound of the abdomen showed tumor formation 31x27 mm in size in upper pole of right kidney, homogeneous (Figure 1). The left kidney was significantly reduced to a tumor formation sized 67x55 mm, homogeneous (Figure 2). Ultrasound did not show pathological substrates on other intraabdominal organs. The abdominal Multislice Computed Tomography (MSCT) scan showed the following specifics: in the cranial part of the right kidney naturally iso-

dense, and a postcontrastively moderately hypodense tumor formation, with well-limited edges, sized about 3.2 cm in largest diameter (Figure 3a); in the area of the left kidney, tumor formation of similar characteristics, sized 5-6.3 cm in diameter in transverse cross-sections, and 7.6 cm in the craniocaudal cross-section, which destroyed most of the left renal parenchyma and caused bowel obstruction (Figure 3b); within the described changes no signs of calcification; no ascites nor enlargement of the regional lymph nodes; other intraabdominal and intrapelvic organs without the presence of focal pathology. Considering that described characteristics were suspicious on synchronous bilateral Wilms tumor, patient was transferred to a surgical reference center for pediatric solid tumors. Preoperatively, he received chemotherapy with Actinomycin D and Vincristin for 3 weeks, after which he underwent surgery. The operation was accessed with transverse subcostal incision. Enucleation of the tumor and partial nephrectomy (with the maintenance of 3/4 of renal parenchyma) on the right side, radical nephrectomy on the left side and extirpation of paraaortic lymph nodes were performed. After the surgery, chemotherapy with Actinomycin D and Vincristin continued for 28 weeks. Histopathology confirmed diagnosis of bilateral Wilms tumor (stage I and II according to National Wilms Tumor Study (NWTs)). Cytogenetic analysis of tumor tissue was not performed. After recovery, the patient had a satisfactory renal function, with normal values of CBC, DBC, urea, creat-

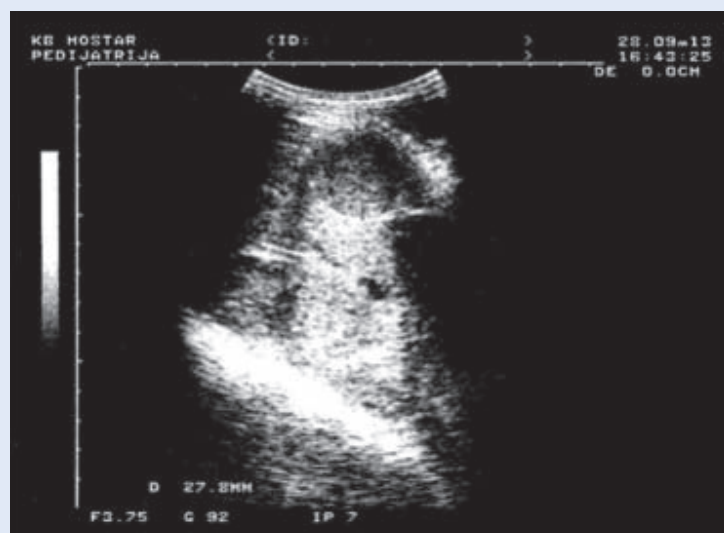

Figure 1. Ultrasound scan of Wilms tumor in right kidney

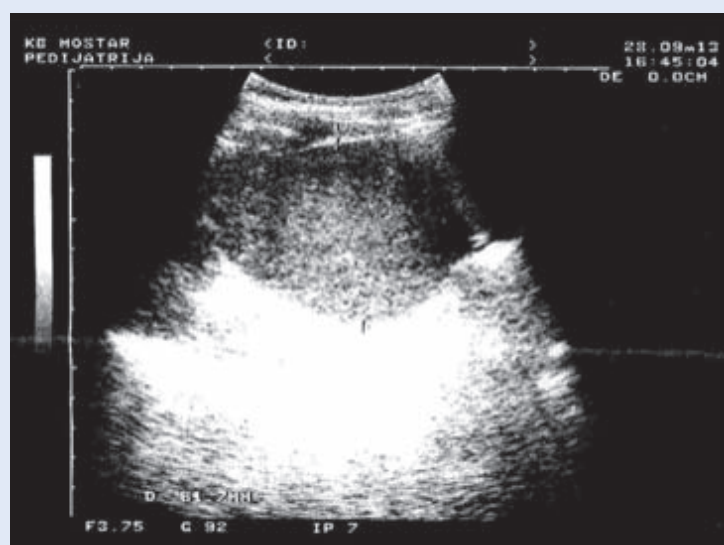

Figure 2. Ultrasound scan of Wilms tumor in left kidney

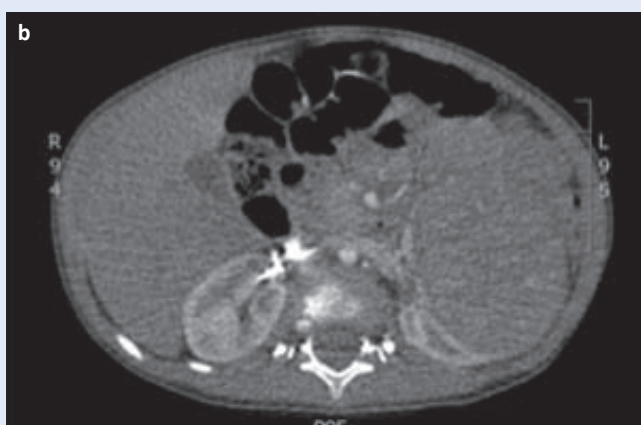
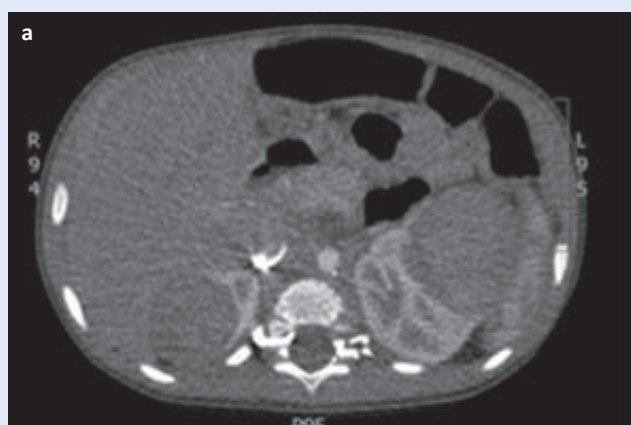

Figure 3. MSCT of abdomen (transverse section); a) scan of Wilms tumor in right kidney – largest diameter; b) scan of Wilms tumor in left kidney – largest diameter

ine, minerals, C-reactive protein (CRP), urine and other parameters. He was discharged to home 18 days after surgery, with ordered regular oncological controls. In the 4-year follow up period he had a normal clinical course, without relapse of illness.

Patients with trisomy 21 generally have a lesser reserve and the ability to adapt to renal tissue resection. Therefore, when performing unilateral radical nephrectomy, we recommend at least 3/4 of contralateral's renal parenchyma to be preserved, unlike for the general population, where 2/3 is sufficient.

## DISCUSSION

The occurrence of Wilms tumor in the population of trisomy 21 patients is a very rare phenomenon, and by reviewing literature we have found only two such reports<sup>10,11</sup>. The exact incidence of WT in this group of patients is still unknown, but how rare its' occurrence is, showed the research of authors from US, who analyzed the National Wilms Tumor Study Registers<sup>12-16</sup>. Reviewing registers, they found 5854 cases of WT, none of which associated with trisomy 21. Considering the prevalence of trisomy 21 of 1: 660 in live-borns, at least 7.6 to 9.9 cases were expected<sup>17</sup>. The possibility for a bilateral WT in trisomy 21 is minimal, and to our knowledge, no such case has been reported so far.

WT is a genetically heterogeneous neoplasia, characterized by a number of genetic abnormalities, involving tumor suppressor genes, oncogenes and genes related to the Wnt signaling pathway. For a long time only one WT gene was known – WT1 at 11p13. However, various studies discovered that WT1 is altered in only approximately 20% of WT. Recently a novel gene mutations of WTX at Xq11.1 and CTNNB1 at 3p22.1 were reported to be present in WT. WT1, WTX and CTNNB1 mutations account for the genetic basis of 30-50% of WT<sup>18-20</sup>. Most of WT cases are sporadic, and approximately 5-10% of patients with WT have an underlying predisposing genetic syndrome. It is well known that genetic syndromes related to loci mapped to the short arm

of chromosome 11 (WAGR, Denys-Drash, Frasier, Beckwith-Wiedemann) are characterized by an increased risk of WT. Several 11p-linked syndromes result from a disruption of the WT1 gene, which encodes the transcription factor WT1, crucial for renal and gonadal embryogenesis. Disruption of the WT1 gene typically results in genitourinary abnormalities and predisposition to early WT (almost always under five years of age), often associated with intralobar and rhabdomyoblastic change within the tumor<sup>5,21</sup>.

Microdeletion of the WT1, along with the neighbouring PAX6 leads to WAGR syndrome, missense mutations of the WT1, typically in the zinc finger domains, result in Denys-Drash syndrome, and WT1 mutation in intron 9 can result in abnormal splicing leading to Frasier syndrome.

In Beckwith-Wiedemann syndrome different chromosomal region – 11p15 band (WT2 locus) is disrupted in a number of ways, most commonly as a result of hypomethylation or uniparental disomy. Non 11p-linked syndromes are less often associated to WT, and their specific co-occurrence remains unclear. Some non 11p-linked syndromes, such as Perlman syndrome, Sotos syndrome, Simpson-Golabi-Behmel syndrome, Bloom syndrome, Li-Fraumeni syndrome, trisomy 18 etc., have a slightly higher incidence of WT compared to general population; and some, such as trisomy 21, have lower<sup>2,5,9</sup>. Various theories explain generally decreased incidence of solid tumors in trisomy 21 by enhanced expression of tumor suppressor genes on chromosome 21. Endostatin – protein that inhibits angiogenesis and neoplastic growth in human and animal models is encoded by the COL18A1, which is located on the chromosome 21. S-100b protein, also encoded by one of the genes on chromosome 21, inhibits growth and induces apoptosis of human and murine neuroblastoma cell lines. Both endostatin and S-100b protein have increased level in the blood of trisomy 21 patients, compared to general population<sup>22,23</sup>. Other potentially protective chromosome 21 genes include DCRS-1 gene and ETS 2 oncogene, which block blood vessel formation and tumor development in murine models of DS<sup>24,25</sup>.

In clinical terms, the bilateral form of WT is a major therapeutic challenge. So far, there have not been unique attitude in the surgical community

about the treatment strategy for the occurrence of malignancy in both kidneys. Nowadays, most clinic centers practice preoperative treatment with chemotherapy/radiotherapy (for tumor tissue reduction), as well in the postoperative period. Some authors prefer expolarization and biopsy of renal parenchyma and regional lymph nodes before the definitive surgery, but such an approach is often avoided because of the risk of the formation of tumor fragments and potential iatrogenic metastases. As for the surgical approach, there are several surgical resection techniques, and most commonly used are: unilateral radical nephrectomy with contralateral partial nephrectomy (with preservation of at least 2/3 renal parenchyma), bilateral partial nephrectomy, and unilateral radical nephrectomy with aggressive chemotherapy and radiation of the contralateral kidney. The common feature of all of these approaches is surgery of preservation, with the aim of preserving adequate long-term renal function<sup>26-28</sup>. Our attitude is that there is no optimal approach for all bilateral WT, because the manifestation of the illness is unique in each patient, so the treatment should be individually adjusted too. In our case, WT caused complete tissue destruction on one kidney, while on the other kidney it was localized and limited from healthy tissue. Given the sufficient amount of renal parenchyma on right kidney, the approach with unilateral radical and contralateral partial resection was a logical solution. In the postoperative period of 4 years, patient had no complications, and we can conclude that we have accomplished a task of satisfying both criteria – complete extirpation of pathological tissue and maintaining an adequate kidney function. However, monitoring of these patients should be life-long, because WT can relapse after several years, and renal function can worsen – even 20 or more years after diagnosis (patients with genetic syndromes in basics have lower renal function compared to non-syndromes population).

### CONCLUSION

Considering that many congenital urological defects have been associated with trisomy 21, an underrepresentation of WT diagnosis is very in-

teresting. This case demonstrates that, although probability is low, synchronous bilateral WT can occur in trisomy 21 patients. Like in the general population, treatment with a combination of chemotherapy and surgical resection showed good long-term outcome. However, preservation of renal tissue should be carefully planned because these patients have lower functional reserve. Apart from establishing clinical approach to treatment, informations on various cases of solid tumors in trisomy 21 could have a great value in discovering etiopathogenesis of cancer, especially WT which is genetically heterogeneous.

**Conflicts of interest statement:** the authors report no conflicts of interest.

### REFERENCES

1. Breslow N, Olshan A, Beckwith JB, Green DM. Epidemiology of Wilms tumor. *Med Pediatr Oncol* 1993;21: 172-81.
2. Szychot E, Apps J, Pritchard-Jones K. Wilms' tumor: biology, diagnosis and treatment. *Transl Pediatr* 2014;3: 12-24.
3. Montgomery BT, Kelalis PP, Blute ML, Bergstralh EJ, Beckwith JB, Norkool P et al. Extended followup of bilateral Wilms tumor: results of the National Wilms Tumor Study J *Urol* 1991;146:514-8.
4. Sulkowski J, Kolon T, Mattei P. Nephron-sparing partial nephrectomy for bilateral Wilms' tumor. *J Pediatr Surg* 2012;47:1234-8.
5. Scott RH, Stiller CA, Walker L, Rahman N. Syndromes and constitutional chromosomal abnormalities associated with Wilms tumour. *J Med Genet* 2006;43:705-15.
6. Rabin KR, Whitlock JA. Malignancy in Children with Trisomy 21. *Oncologist* 2009;14:164-73.
7. Hasle H, Clemmensen IH, Mikkelsen M. Risks of leukaemia and solid tumours in individuals with Down's syndrome. *Lancet* 2000;355:165-9.
8. Narod SA, Stiller C, Lenoir GM. An estimate of the heritable fraction of childhood cancer. *Br J Cancer* 1991; 63:993-9.
9. Xavier AC, Ge Y, Taub JW. Down Syndrome and Malignancies: A Unique Clinical Relationship. *J Mol Diagn* 2009;11:371-80.
10. Spreafico F, Terenziani M, Lualdi E, Scarfone P, Collini P, Fossati-Bellani F et al. Non-chromosome 11-p syndromes in Wilms tumor patients: Clinical and cytogenetic report of two Down syndrome cases and one Turner syndrome case. *Am J Med Genet A* 2007; 143A:85-8.
11. Kusumakumary P, Ninan M, Chellam VG, Jacob R, Nair MK. Wilms tumor in a child with Down syndrome. *J Pediatr Hematol Oncol* 1995;17:276.
12. D'Angio GJ, Evans AE, Breslow N, Beckwith B, Bishop H, Feigl P et al. The treatment of Wilms' tumor: Results of the national Wilms' tumor study. *Cancer* 1976; 38:633-46.

13. D'Angio GJ, Evans A, Breslow N, Beckwith B, Bishop H, Farewell V et al. The treatment of Wilms' tumor: results of the Second National Wilms' Tumor Study. *Cancer* 1981;47:2302-11.
14. D'Angio GJ, Breslow N, Beckwith JB, Evans A, Baum H, deLorimier A et al. Treatment of Wilms' tumor. Results of the Third National Wilms' Tumor Study. *Cancer* 1989;64:349-60.
15. Green DM, Breslow N, Beckwith JB, Finklestein JZ, Grundy PE, Thomas PR et al. Comparison between single-dose and divided-dose administration of Dactinomycin and Doxorubicin for patients with Wilms tumor: A report from the National Wilms' Tumor Study Group. *J Clin Oncol* 1998;16:237-45.
16. Grundy PE, Breslow NE, Li S, Perlman E, Beckwith JB, Ritchey ML et al. Loss of heterozygosity for chromosomes 1p and 16q is an adverse prognostic factor in favorable-histology Wilms tumor: a report from the National Wilms Tumor Study Group. *J Clin Oncol* 2005; 23:7312-21.
17. Olson JM, Hamilton A, Breslow NE. Non-11p constitutional chromosome abnormalities in Wilms' tumor patients. *Med Pediatr Oncol* 1995;24:305-9.
18. Cardoso LC, De Souza KR, De O Reis AH, Andrade RC, Britto AC Jr, De Lima MA et al. WT1, WTX and CTNNB1 mutation analysis in 43 patients with sporadic Wilms' tumor. *Oncol Rep* 2013;29:315-20.
19. Wang H, Shen Y, Sun N, Jiang YP, Li ML, Sun L. Identification and analysis of mutations in WTX and WT1 genes in peripheral blood and tumor tissue of children with Wilms' tumor. *Chin Med J (Engl)* 2012;125:1733-9.
20. Ruteshouser EC, Robinson SM, Huff V. Wilms tumor genetics: mutations in WT1, WTX, and CTNNB1 account for only about one-third of tumors. *Genes Chromosomes Cancer* 2008;47:461-70.
21. Scott RH, Stiller CA, Walker L, Rahman N. Syndromes and constitutional chromosomal abnormalities associated with Wilms tumor. *J Med Genet* 2006;43: 705-15.
22. Satgé D, Sasco AJ, Carlsen NL, Stiller CA, Rubie H, Hero B et al. A lack of neuroblastoma in Down syndrome: a study from 11 European countries. *Cancer Res* 1998; 58:448-52.
23. Zorick TS, Mustacchi Z, Bando SY. High serum endostatin levels in Down syndrome: implications for improved treatment and prevention of solid tumours. *Eur J Hum Genet* 2001;9:811-4.
24. Minami T, Horiuchi K, Miura M, Abid MR, Takabe W, Noguchi N et al. Vascular endothelial growth factor- and thrombin-induced termination factor. Down syndrome critical region-1, attenuates endothelial cell proliferation and angiogenesis. *J Biol Chem* 2004;279: 50537-54.
25. Sussan TE, Yang A, Li F, Ostrowski MC, Reeves RH. Trisomy represses Apc(Min)-mediated tumours in mouse models of Down's syndrome. *Nature* 2008;451:73-5.
26. Duarte RJ, Denes FT, Cristofani LM, Giron AM, Filho VO, Arap S. Laparoscopic nephrectomy for wilms tumor after chemotherapy: initial experience. *J Urol* 2004;172: 1438-40.
27. Holcomb GW 3rd, Tomita SS, Haase GM, Dillon PW, Newman KD, Applebaum H et al. Minimally invasive surgery in children with cancer. *Cancer* 1995;76: 121-8.
28. Della Rocca G, Lugano M. Renal function and icu. *Signa vitae* 2007;2 Suppl 1:S11-8.