

Carotid artery resection and reconstruction for recurrent laryngeal carcinoma with carotid artery involvement: case report

Resekcija i rekonstrukcija karotidne arterije za rekurentni karcinom larinksa s uključenjem karotidne arterije: prikaz slučaja

Thevagi Maruthamuthu¹, Nadarajah Sanjeevan¹, Mohd Ezane Aziz², Arman Zaharil Mat Saad³, Baharudin Abdullah^{1*}

¹Department of Otorhinolaryngology-Head & Neck Surgery, School of Medical Sciences, Universiti Sains Malaysia Health Campus, Kelantan, Malaysia

²Department of Radiology, School of Medical Sciences, Universiti Sains Malaysia Health Campus, Kelantan, Malaysia

³Department of Reconstructive and Surgery, School of Medical Sciences, Universiti Sains Malaysia Health Campus, Kelantan, Malaysia

Abstract. Aim: The management of advanced head and neck cancer is challenging and it presents a considerable risk. The carotid artery involvement is considered inoperable. We would like to highlight the benefit of carotid artery resection and reconstruction in achieving the control of the disease along with the improved survival rate. **Case report:** A 60-year-old male patient with the history of total laryngectomy with a selective neck dissection and adjuvant chemo-radiation therapy for a laryngeal carcinoma developed a right sided neck recurrence after being disease free. The recurrent tumour mass encased the right carotid artery circumferentially. He underwent a radical right neck dissection, the right carotid artery resection and the reconstruction. **Conclusions:** Recent advances in surgical management have enabled surgeons to perform the carotid artery resection and bypass with a notable success and reduced complications.

Key words: carotid artery disease; laryngeal cancer; vascular surgical procedure

Sažetak. Cilj: Upravljanje uznapredovalim rakom glave i vrata izazovno je i posjeduje znatan rizik. Uključivanje karotidne arterije smatra se neoperabilnim. Željeli bismo istaknuti prednost resekcije i rekonstrukcije karotidne arterije u postizanju izvrsne lokalne kontrole bolesti s poboljšanom kvalitetom preživljavanja. **Prikaz slučaja:** 60-godišnji gospodin s poviješću ukupne laringektomije sa selektivnom disekcijom vrata i adjuvantnom kemoterapijom i zračenjem za karcinom grkljana razvio je recidiv na desnoj strani vrata nakon razdoblja bez bolesti. Rekurentna tumorska masa okružila je desnu karotidnu arteriju po obodu. Podvrgnut je uspješnoj radikalnoj disekciji desne strane vrata, resekciji i rekonstrukciji desne karotidne arterije. **Zaključci:** Napredak kirurgije vrata omogućio je kirurzima obavljanje opsežnijih zahvata, uključujući i resekciju karotidne arterije u slučaju recidivnih karcinoma, te time produženje života pacijenta.

Ključne riječi: karotidna arterija; neoplazme grkljana; vaskularni kirurški zahvati

***Corresponding author:**

Professor Dr Baharudin Abdullah
Department of Otorhinolaryngology –
Head and Neck Surgery
School of Medical Sciences,
Universiti Sains Malaysia
16150 Kubang Kerian, Kelantan, Malaysia
e-mail: baharudin@usm.my,
profbaha@gmail.com

<http://hrcak.srce.hr/medicina>

INTRODUCTION

Carotid artery may get involved in patients with head and neck cancer and this presents a challenge to the surgeon as well as oncologist due to the considerable risk involved in the management of such patients. Non-surgical treatment includes radiation therapy in combination with chemotherapy or interstitial radiation brachytherapy¹. Surgical options in locoregional recurrent laryngeal carcinoma with carotid involvement are limited to either carotid artery resection and bypass or stripping the tumour from vessel wall²⁻³. The potential risk for stroke, myocardial infarction and high mortality or morbidity rate has to be taken into consideration. Nevertheless, superior oncological outcome favours carotid artery resection rather than stripping⁴. Furthermore, microvascular invasion and weakening by stripping may pose a risk of carotid artery rupture¹. In the majority of the cases, surgical salvage may be the only option available for patient with carotid artery involvement.

CASE REPORT

A 60-year-old gentleman with history of total laryngectomy with selective neck dissection and adjuvant chemo-radiation 5 years ago for laryngeal carcinoma (T1bN0M0) developed a right sided neck recurrence after being disease free for almost 4 years.

He presented with enlarging right neck mass for five months duration. The lesion was painless and hard on palpation, with blisters on the overlying skin (Figure 1). Fine needle aspiration cytology (FNAC) of the mass was reported as metastatic squamous cell carcinoma. Contrast-enhanced computed tomography (CECT) scan of neck clearly showed the recurrent tumour mass at right infrahyoid region, encasing the right common carotid artery circumferentially with an intact lumen and multiple enlarged lymph nodes at right level I to V (Figure 2). The length of encasement was 5.6 cm and it started 0.6 cm just below the bifurcation of the common carotid artery.

He underwent right radical neck dissection, right carotid artery resection and reconstruction of the resected artery with polytetrafluoroethylene

(PTFE) graft, which was performed by combined team of head and neck and reconstructive plastic surgeons. This procedure was done under general anaesthesia as it was a complicated and high-risk procedure.

The main focus of the ablative surgery was centered at identifying the safe proximal and distal margin of the carotid artery clear of the tumour. The external carotid artery was tied off and anastomosis made between common carotid artery distally and internal carotid artery proximally for

- Carotid artery involvement in advanced head and neck cancer is challenging
- Surgical salvage may be the only option available
- Growing evidence of the benefit of carotid artery resection and reconstruction
- Excellent local control of the disease with improved quality of survival

optimal tumour clearance and to reduce the length of arterial suture length. The tumour was resected en bloc with the involved carotid artery segment (Figure 3).

Polytetrafluoroethylene (PTFE) graft was used for carotid arterial reconstruction and temporary in-

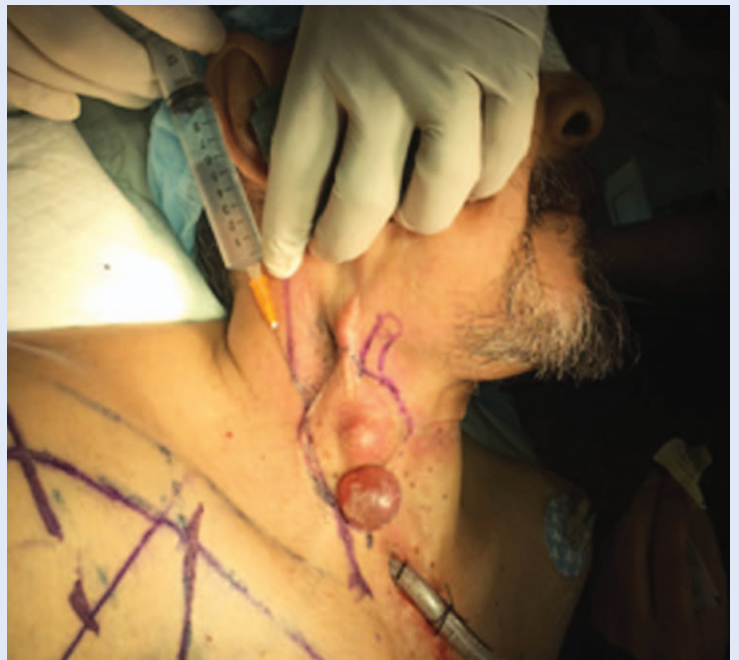

Figure 1. Recurrent neck tumour with skin involvement

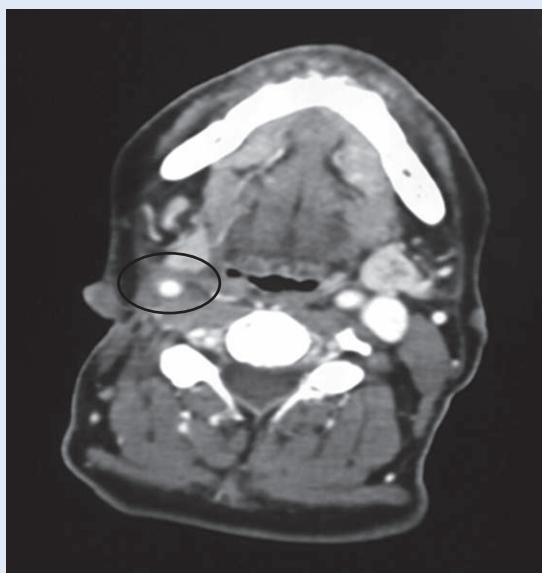


Figure 2. Cervical CT scan (axial view at infrahyoid level) showed encasement of the right common carotid artery circumferentially.

tra-operative shunt was used to reduce the clamping time of the carotid artery which may affect perfusion and caused cerebral ischemia (Figure 4). The initial ischemic time was four minutes for the carotid artery ligation and shunting, followed by second period of ischemic time lasted about sixteen minutes for the anastomosis of the proximal carotid artery. Prior to clamping of the carotid artery, patient's blood pressure was increased by 10-20% and a bolus intravenous heparin 5000 i.u. was given to reduce any risk of cerebral event. A 6mm diameter PTFE graft was used to reconstruct the resected segment. The shunt was placed through the PTFE and introduced into the internal carotid artery first and secured with a vessel loop. The blood from the distal circulation was allowed to fill in the shunt and removing all the air within the shunt prior to insertion to the proximal common carotid artery. This will eliminate the risk of air embolism to the brain. The distal anastomosis was performed under loupe magnification using 7 / 0 double needle prolene sutures. Subsequently, at the proximal anastomosis, back-wall sutures were placed first until no more space available and shunt was removed to allow completion of the distal anastomosis while the carotid artery was completely clamped for a very brief period. The involved skin was resected and a pectoralis major pedicled rotational flap was

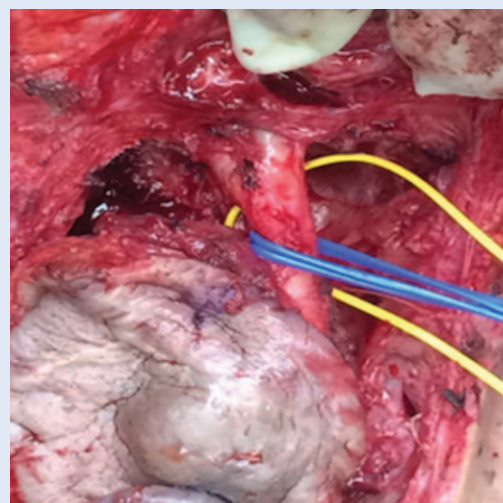


Figure 3. Tumour resected en bloc with the carotid artery

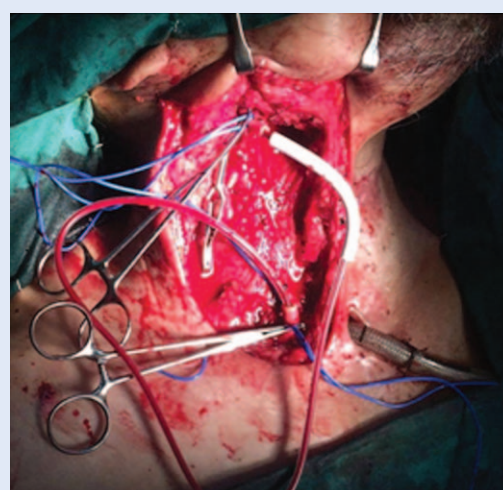

Figure 4. Shunting of the carotid artery was performed.

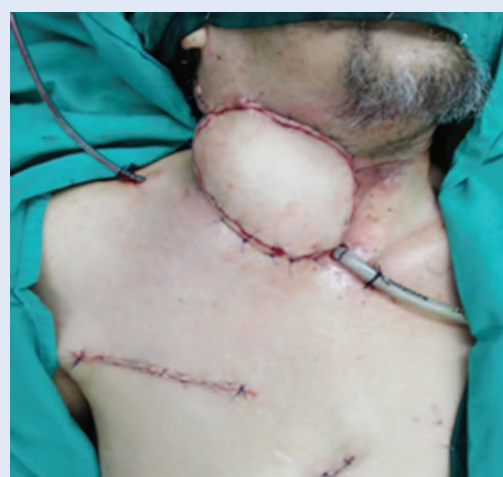

Figure 5. Pectoralis major myocutaneous flap used to cover the skin defect.

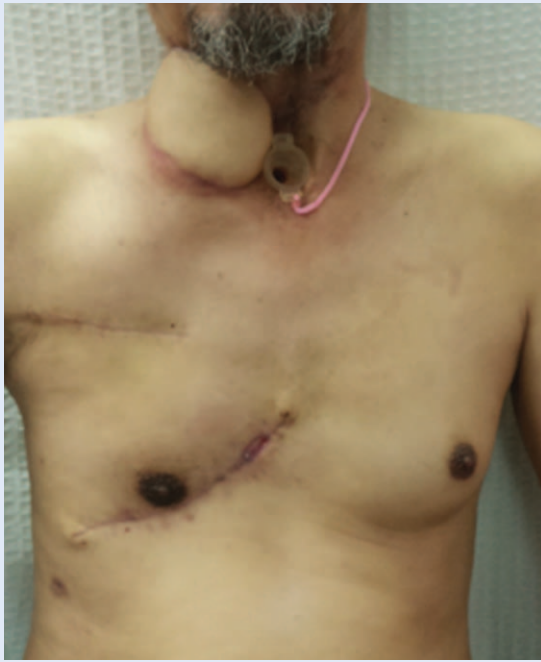

Figure 6. Tumour free and without any neurological deficits on followup

used to cover the defect (Figure 5). The total operative time was 7 hours. Immediate postoperative care includes keeping the patient's head at neutral (supine) position with mean arterial pressure range between 60-70 mmHg and was monitored at intensive care unit for three days. The patient was extubated at day two post operation. A higher mental status examination, cranial nerve examination and peripheral neurological examination (sensation, motor and reflex) was performed when patient regained full consciousness at four hour post extubation and showed no general neurological deficit. Intravenous cefuroxime was given to the patient on induction and continued post-surgery as an antibiotic prophylaxis for major surgery. The wound drain was removed after 4 days. The patient was discharged at day 10 post-surgery. Subsequent follow up at 9 months post operation showed no evidence of tumour recurrence clinically and the patient continued to enjoy good quality of life (Figure 6).

DISCUSSION

Advanced head and neck cancer with carotid artery involvement is considered stage IVB disease and carries poor prognosis. Carotid artery resection and reconstruction may be the only option

available as patients usually have already completed chemoradiation. Tumour invasion into carotid artery vessel wall may compromise the integrity of the artery and increases the risk of tumour spread and recurrence. The most feared complication is carotid artery blow out. It has been shown that risk of tumour recurrence in patients whose carotid artery were resected is lower as compared to patients whose carotid artery were preserved¹. A cohort analysis by Roh et al⁵ showed that head and neck malignancy with carotid involvement has zero survival at 15 months and treatment is only for palliative intent. However, surgical resection of carotid artery involved by tumour may prolong the survival up to 24.5% at 2 years⁵.

Despite the growing evidence of the benefit of carotid artery resection and reconstruction, the management of patients with recurrent neck cancer invading the carotid artery is still controversial. However, resection of recurrent neck cancer with carotid artery reconstruction can lead to excellent local control of the disease with improved quality of survival, as shown in this case.

CONCLUSION

Carotid artery involvement by head and neck cancer is no longer a limiting factor in surgical management. Treatment should be strategized towards curative rather than palliative intent in ensuring a better outcome and survival rate.

Conflicts of interest statement: the authors report no conflicts of interest.

REFERENCES

1. Mourad M, Saman M, Stroman D, Lee T, Ducic Y. Carotid artery sacrifice and reconstruction in the setting of advanced head and neck cancer. *Otolaryngol Head Neck Surg* 2015;153:225-30.
2. Meleca RJ, Marks SC. Carotid artery resection for cancer of the head and neck. *Arch Otolaryngol Head Neck Surg* 1994;120:974-8.
3. Natasha M, Vivian G, Randal SW. Management of patients after elective carotid artery resection, *Am J Otolaryngol* 1999;20:37-42.
4. Kroeker TRT, O'Brien JCI. Carotid resection and reconstruction associated with treatment of head and neck cancer. *Proc (Bayl Univ Med Cent)* 2011;24:295-8.
5. Roh JL, Ra Kim M, Choi SH, Hyun Lee J, Cho KJ, Yuhl Nam S et al. Can patients with head and neck cancers invading carotid artery gain survival benefit from surgery? *Acta Oto-laryngologica* 2008;128:1370-4.