



Vanja Vučićević Boras¹, Dragana Gabrić², Ljiljana Smiljanić Tomičević³, Sven Seiwerth⁴, Krešimir Gršić⁵, Božena Šarčević⁶, Božana Lončar Brzak¹, Emilija Marunica⁷, Ana Glavina¹

Pogrešna dijagnoza tuberkuloze usne šupljine kao prekancerozne lezije

Tuberculosis of the Oral Cavity Misdiagnosed as Precancerous Lesion

- ¹ Zavod za oralnu medicinu Stomatološkog fakulteta Sveučilišta u Zagrebu, Zagreb, Hrvatska
Department of Oral Medicine, School of Dental Medicine, University of Zagreb, Zagreb, Croatia
- ² Zavod za oralnu kirurgiju Stomatološkog fakulteta Sveučilišta u Zagrebu, Zagreb, Hrvatska
Department of Oral Surgery, School of Dental Medicine, University of Zagreb, Zagreb, Croatia
- ³ Zavod za kliničku imunologiju i reumatologiju Klinike za unutarnje bolesti Medicinskog fakulteta Sveučilišta u Zagrebu – Klinički bolnički centar Zagreb, Zagreb, Hrvatska
Department of Clinical Immunology and Rheumatology, Clinic for Internal Medicine, School of Medicine, University of Zagreb, Clinical Hospital Centre Zagreb, Zagreb, Croatia
- ⁴ Zavod za patologiju Medicinskog fakulteta Sveučilišta u Zagrebu – Klinički bolnički centar Zagreb, Zagreb, Hrvatska
Department of Pathology, School of Medicine, University of Zagreb, Clinical Hospital Centre Zagreb, Zagreb, Croatia
- ⁵ Odjel za kirurgiju glave i vrata Klinike za tumore Kliničkoga bolničkog centra Sestre milosrdnice, Zagreb, Hrvatska
Department of Head and Neck Surgery, Clinic for Tumors, Clinical Hospital Centre "Sestre milosrdnice", Zagreb, Croatia
- ⁶ Zavod za onkološku patologiju Klinike za tumore Kliničkoga bolničkog centra Sestre milosrdnice, Zagreb, Hrvatska
Department of Pathology, Clinic for Tumors, Clinical Hospital Centre "Sestre milosrdnice", Zagreb, Croatia
- ⁷ Klinika za plućne bolesti Jordanovac Kliničkoga bolničkog centra Zagreb, Zagreb, Hrvatska
Clinic for Lung Diseases Jordanovac, Clinical Hospital Centre Zagreb, Zagreb, Croatia

Sažetak

Svrha ovog prikaza slučaja bila je opisati vrlo rijetku oralnu leziju kao posljedicu primarne plućne tuberkuloze. **Prikaz slučaja:** Opisan je bolesnik s refraktornom bezbolnom ulceracijom ventralne površine jezika. Pacijentu je uzeta detaljna medicinska anamneza te obavljen klinički pregled sluznice usne šupljine i palpacija regionalnih limfnih čvorova. Kliničkim pregledom ustanovljena je ulceracija na ventrolateralnoj površini jezika promjera oko dva centimetra. Palpacijom regionalnih limfnih čvorova nije otkriveno njihovo povećanje. Toluidinski test sumnjive lezije učinjen je tijekom svakoga kontrolnog pregleda. Biopsijski uzorci za histopatološku analizu uzeti su tri puta. Histopatološka analiza prvoga biopsijskog uzorka pokazala je nespecifičnu upalu, druga kazeoznu nekrozu bez pozitivnog bojenja prema Ziehl-Neelsenu, a treća granulomatoznu upalu visoko sumnjivu na sarkoidozu. Pacijent je tijekom hospitalizacije obavio cjelovit fizikalni pregled, te laboratorijsku i radiološku dijagnostiku. Fizikalni pregled prsnog koša pokazao je bilateralno prisutne grube krepitacije, a laboratorijski nalazi krvne slike normocitnu anemiju kronične bolesti. Na rendgenskoj snimci pluća uočeni su mali multipli čvorovi bilateralno, a nalaz direktnog sputuma bio je pozitivan. **Zaključak:** Iako je oralna tuberkuloza rijetko stanje, mora se uzeti u obzir u diferencijalnoj dijagnozi refraktornih bezbolnih oralnih ulkusa.

Zaprimljen: 2. svibnja 2017.
Prihvaćen: 2. studenoga 2017.

Adresa za dopisivanje

doc. dr. sc. Dragana Gabrić
Sveučilište u Zagrebu Stomatološki
fakultet
Zavod za oralnu kirurgiju,
Klinički bolnički centar Zagreb
HR-10 000 Zagreb, Gundulićeva 5
tel: +38514802138
faks: +38514802159
dgabric@sfg.hr

Ključne riječi

oralna tuberkuloza; jezik; oralni ulkus;
dijagnostičke pogreške, tuberkuloza
pluća

Uvod

Unatoč napretku u dijagnostičkim i terapijskim mogućnostima, tuberkuloza (TB) i dalje ostaje jedan od vodećih uzroka smrti diljem svijeta. Svjetska zdravstvena organizacija (WHO) izvijestila je u 2014. godini o incidenciji tuberkuloze u svijetu od 9,6 milijuna slučajeva, pretežno u jugoistočnoj Aziji i zapadnim pacifičkim zemljama (1). U posljednjih deset godina prevalencija TB-a se smanjila. Incidencija te bolesti u Hrvatskoj je niža od prosječne u europskoj regiji WHO-a (12/00 000 u 2013. godini), ali još se ne uspijeva

Introduction

Despite advances in diagnostic and therapeutic opportunities, tuberculosis (TB) still remains one of the leading causes of death around the world. The World Health Organization (WHO) reported the incidence of 9.6 million global cases of TB in 2014, predominantly in South-East Asia and Western Pacific nations (1). In the last ten years, the prevalence of TB has decreased. The incidence of TB in Croatia is lower than the average incidence in the European region of the WHO (12.4/100 000 in 2013), but it still falls short of

smanjiti morbiditet u razvijenim zemljama (2). Rizični čimbenici za razvoj TB-a uključuju medicinska stanja koja slabe imunost sustava domaćina, kao što su dijabetes ili rak, uzimanje immunosupresivnih lijekova, infekcija HIV-om i starija dob (3). TB je kronična zarazna, granulomatозна bolest uzrokovana *Mycobacterium tuberculosis* i obično je ograničena na pluća, iako može biti zahvaćen bilo koji organ u tijelu (koža, bubrezi, ždrijelo, kosti, gastrointestinalni sustav, središnji živčani sustav i limfni sustav) (4). Obično se pojavljuje u sekundarnom obliku kao rezultat reaktiviranja latentne infekcije. Procjenjuje se da je trećina svjetske populacije pogođena *Mycobacterium tuberculosis*, a to su većinom asimptomatske infekcije (3). Primarni oralni TB rijetko je opisan i taj je oblik obično sekundarna manifestacija plućne tuberkuloze posredstvom kontaminiranog sputuma ili hematogenog širenja. Oralne lezije, kao početna manifestacija tuberkuloze, također su opisane i smatraju se posljedicom aktivnoga plućnog TB-a (5). Oralni TB vrlo je rijedak u Hrvatskoj, a može se također vidjeti u većini drugih zemalja, poput Japana (6). Oralne lezije TB-a pojavljuju se u 0,05 do 5 posto zaraženih bolesnika, uglavnom kao bezbolni kronični ulkus (7, 8). Sekundarni oralni TB uglavnom se pojavljuje na jeziku, usnama, sluznici obraza, nepcu, gingivi i jezičnom frenulumu (9 – 11). Protokol liječenja, kad je riječ o odraslima, sastoji se od dvomjesečne intenzivne faze liječenja antituberkuloticima, poput izoniazida, rifampicina, etambutola, pirazinamida, nakon čega slijedi kontinuirana faza liječenja izoniazidom i rifampicinom tijekom četiri mjeseca (12).

Svrha ovog prikaza slučaja bila je pokazati ekstremno rijetku oralnu leziju kao posljedicu primarne plućne tuberkuloze koja je najprije pogrešno dijagnosticirana kao prekancerозна oralna lezija.

Prikaz bolesnika

Pacijent u dobi od 68 godina upućen je u Zavod za oralnu medicinu Stomatološkog fakulteta Sveučilišta u Zagrebu zbog bolne ulceracije jezika (slika 1.). Tijekom prvog pregleda uzeta je detaljna medicinska anamneza te obavljen klinički pregled sluznice usne šupljine i palpacija regionalnih limfnih čvorova. Toluidinski test sumnjive lezije učinjen je tijekom svakog kontrolnog pregleda. Histopatološka analiza prvoga i drugoga biopsijskog uzorka obavljena je u Zavodu za oralnu kirurgiju. Histopatološka analiza prvoga biopsijskog uzorka pokazala je nespecifičnu upalu, a drugoga kazeoznu nekrozu bez pozitivnog bojenja prema Ziehl-Neelsenu. Treća biopsija učinjena je na Odjelu za kirurgiju glave i vrata Klinike za tumore Kliničkoga bolničkog centra Sestre milosrdnice. Nakon uzimanja trećeg biopsijskog uzorka, histopatološka analiza pokazala je granulomatозnu upalu visoko sumnjivu na sarkoidozu (slika 2.), a pacijent je nakon toga upućen na daljnje pretrage u Zavod za kliničku imunologiju i reumatologiju Kliničkoga bolničkog centra Zagreb, gdje je postavljena sumnja na aktivnu tuberkulozu.

Tijekom hospitalizacije u Zavodu za kliničku imunologiju i reumatologiju Kliničkoga bolničkog centra Zagreb, pacijent je bio podvrgnut cjelovitom fizikalnom pregledu te laboratorijskoj i radiološkoj dijagnostici. Detaljna medicinska

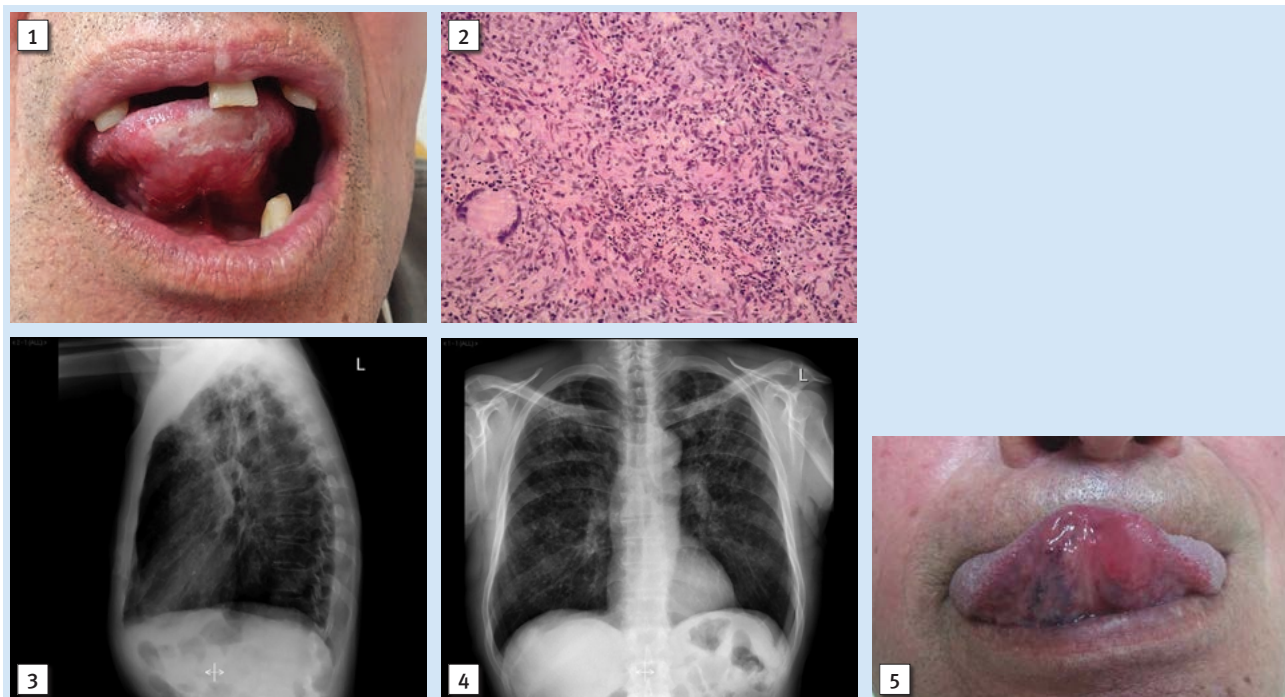
morbidity in developed countries (2). Risk factors for developing TB include medical conditions that reduce host immunity, such as diabetes or cancer, taking immunosuppressive drugs, HIV infection, elderly age (3). TB is a chronic infectious, granulomatous disease caused by *Mycobacterium tuberculosis* which is usually confined to the lungs, albeit it may affect almost any organ in the body (skin, kidneys, pharynx, bones, gastrointestinal tract, central nervous system and lymphatic system) (4). Tuberculosis usually occurs in its secondary form, as a result reactivation of a latent infection. It is estimated that one third of the world population, or about 2 billion people, have been affected with *Mycobacterium tuberculosis*, which are mainly asymptomatic infections (3). Primary oral TB has rarely been described and usually oral TB is secondary manifestation of pulmonary TB through contaminated sputum or hematogenous spread. Oral lesions as initial manifestations of TB have also been described and are thought to be consequence of active pulmonary TB (5). Oral TB is very rare in Croatia, as is the case in other countries such as Japan (6). Oral TB lesions are found in 0.05%-5% of infected patients, mostly as chronic painless ulcers (7, 8). Secondary oral TB is usually seen on the tongue, lips, buccal mucosa, palate, gingiva and lingual frenulum (9-11). The preferred regimen for treating adults with TB consists of intensive phase of antituberculosis agents with isoniazid, rifampicin, ethambutol, pyrazinamide during two months followed by a continuous phase with isoniazid and rifampicin during four months (12).

The aim of this case report was to describe an extremely rare oral lesion as a result of primary pulmonary tuberculosis, which was initially misdiagnosed as precancerous oral lesion.

Case report

The present case report describes a 68-year-old male patient who was referred to Department of Oral Medicine, School of Dental Medicine, University of Zagreb. He was complaining about painless tongue ulceration (Figure 1). A detailed medical history, clinical examination of the oral mucosa and palpation of regional lymph nodes were performed during the first examination. The toluidine test of suspected lesion was performed at each control examination. The first and second biopsy samples for histopathologic analysis were taken at the Department of Oral Surgery. The analysis of the first biopsy sample for histopathology revealed a non-specific inflammation, the second sample revealed caseous necrosis without positive Ziehl-Neelsen staining. The third biopsy was taken at the Department for Head and neck Surgery, Clinic for Tumors, Clinical Hospital Center "Sisters of Mercy". After taking the third biopsy sample, histopathology revealed granulomatous inflammation, which was highly suspected to be sarcoidosis (Figure 2), and the patient was further referred to the Department of Clinical Immunology and Rheumatology, Clinical Hospital Centre Zagreb where active TB was suspected.

During hospitalization at the Department of Clinical Immunology and Rheumatology, Clinical Hospital Centre Za-



Slika 1. Ulceracija jezika pacijenta s aktivnom plućnom tuberkulozom

Figure 1 Tongue ulceration of the patient with active lung tuberculosis

Slika 2. Histopatološka analiza pokazuje granulom sa središnjom kazeoznom nekrozom

Figure 2 Microphotograph showing granuloma with central caseous necrosis

Slika 3. Rendgenska snimka prsnog koša pokazuje male multiple čvorove bilateralno

Figure 3 Chest radiograph demonstrating multiple small nodules bilaterally

Slika 4. Anteroposterior (AP) rendgenska snimka prsnog koša

Figure 4 Antero-posterior (AP) view of chest radiograph

Slika 5. Lezija na jeziku povukla se nakon liječenja antiburkulinskim lijekovima

Figure 5 Lesion of the tongue rapidly improved along with pulmonary status after therapy with antituberculosis agents.

anamneza pokazala je da je riječ o zdravom pacijentu koji ne uzima nikakve lijekove i dosad nema zabilježene alergijske reakcije, osim što je pušač i konzumira alkohol. Izvijestio je samo o laganom gubitku težine, ali bez općih simptoma poput vrućice, kašlja ili boli u prsima. Klinički pregled sluznice usne šupljine otkrio je ulceraciju na ventrolateralnoj površini jezika promjera oko dva centimetra. Preostala oralna sluznica bila je uredna, bez ikakvih kliničkih promjena i simptoma. Palpacija regionalnih limfnih čvorova nije otkrila povećanje. Toluidinski test sumnjive lezije obavljen je tijekom svakoga kontrolnog pregleda, ali uvijek je bio negativan. Fizikalni pregled prsnog koša otkrio je bilateralno prisutne grube krepitacije tijekom hospitalizacije u Zavodu za kliničku imunologiju i reumatologiju Kliničkog bolničkog centra Zagreb, a laboratorijski nalazi kompletne krvne slike pokazali su normocitnu anemiju kronične bolesti. Na rendgenskoj snimci pluća uočeni su mali multipli čvorovi bilateralno, a pozitivan direktni sputum potvrdio je dijagnozu aktivnoga primarnog plućnog TB-a (slike 3. i 4.).

Pacijent je liječen četirima standardnim antituberkuloticima kako slijedi – izoniazidom (1x 400 mg), rifampicinom (2x 300 mg), etambutolom (3x 400 mg) i pirazinamidom (3x 500 mg), pa se njegova ulcerozna lezija jezika brzo poboljšala istodobno s plućnim statusom (slika 5.).

greb the patient underwent a complete physical examination, and laboratory and radiological diagnostics. From a detailed medical history of the patient, we found out that he was healthy, was not taking any medication, and had no registered allergy. He was a cigarette smoker and alcohol consumer. He only reported a slight weight loss, but without signs of fever, cough or chest pain. Clinical examination revealed ulceration on his ventro-lateral surface of the tongue, approximately two centimeters in diameter. The remaining oral mucosa was without any clinical changes and symptoms. Palpation of regional lymph nodes has not revealed any enlargements. The toluidine test of the suspected lesion was performed at each control examination but it was always negative. During hospitalization at the Department of Clinical Immunology and Rheumatology, Clinical Hospital Centre Zagreb, physical chest examination revealed a bilaterally coarse crepitation and laboratory findings of his complete blood count revealed normocytic anemia of chronic disease. Radiographic examination of lungs showed multiple small nodules bilaterally and positive direct sputum smear confirmed the diagnosis of active primary lung TB (Figures 3-4).

The patient was treated with four standard antituberculosis agents as following isoniazid (1x 400 mg), rifampicin (2x 300 mg), ethambutol (3x 400 mg) and pyrazinamide (3x 500 mg) and his ulcerated lesion of the tongue rapidly improved along with pulmonary status (Figure 5).

Rasprava

Iako se bilježi porast incidencije ekstrapulmonalnog TB-a, zbog rijetkih kliničkih prikaza ta je bolest i dalje nedovoljno dijagnostičiran klinički entitet (13). Ovaj prikaz slučaja opisuje bezbolan oralni ulkus kao sekundarnu leziju aktivnoga primarnoga TB-a pluća, bez drugih specifičnih plućnih simptoma. Na početku smo mislili da pacijent nije bio svjestan svoje loše navike guranja jezika na preostali zub 33 i/ili na neodgovarajuću protezu, te je u terapiji dobio topikalnu kortikosteroidnu mast (betametazon) u orabazi koju je primjenjivao četiri puta na dan i lezija je zacijelila. Štoviše, lezija je zacijelila nakon dva tjedna liječenja topikalnim kortikosteroidima i ponovno se pojavila nakon jednog mjeseca kada je uzet prvi biopsijski uzorak. Ponovno je ordinirana ista topikalna kortikosteroidna terapija i lezija je zacijelila. Tada se opet pojavila i uzet je drugi biopsijski uzorak. Zanimljivo je istaknuti da je samo u drugom biopsijskom uzorku otkrivena kazeozna nekroza, a bojenje prema Ziehl-Neelsenu bilo je negativno i nisu bili identificirani acidorezistentni bacili. Nakon uzimanja trećega biopsijskog uzorka, kada je identificirana granulomatозна upala koja je bila visoko sumnjiva na sarkoidozu, pacijent je upućen na daljnju hospitalizaciju tijekom koje je postavljena sumnja na aktivnu tuberkulozu. Tijekom boravka u bolnici liječen je kombinacijom četiriju standardnih antituberkulotika – izoniazidom, rifampicinom, etambutolom i pirazinamidom. Nakon provedenog liječenja ulcerozna lezija jezika brzo se poboljšala, istodobno s plućnim statusom.

Oralni TB rijedak je u kliničkoj praksi i uglavnom se prepoznaje zahvaljujući prikazima slučajeva. Infekcija se širi respiratornim kapljicama. Mehanizam inokulacije u sluznicu usne šupljine slabo je poznat (14). Očito da intaktna sluznica, zajedno sa slinom i njezinim antimikrobnim enzimima, može djelovati inhibitorno na mnoge mikrobnne tvari kao što je HIV i ostale. Klinički ove promjene, poput ulceracija ili čvorova, nisu specifične, ali mogu se manifestirati i kao lezije čeljusti, poput osteomijelitisa ili radiolucencije (15, 16). Biopsija oralne lezije često nije dovoljna za postavljanje dijagnoze jer granulomatозна promjena ne moraju biti prisutne u ranoj fazi bolesti, a acidorezistentni bacili teško se dokazuju u uzorku (17). Podatci u literaturi pokazuju da se samo mali broj histopatoloških uzoraka oboji pozitivno za acidorezistentne bacile, pa negativan rezultat ne bi trebao isključivati dijagnozu TB-a (17).

Većina ostalih prikaza slučajeva bila je visoko sumnjiva na oralni TB zbog kronične prirode nezacjeljujućih ulkusa, nalaz koji je također vidljiv u ovom prikazu slučaja. Nadalje, u većini objavljenih prikaza slučajeva oralne tuberkulozne lezije bile su bolne, no to nije bio slučaj kod našeg pacijenta.

Diferencijalna dijagnoza u ovom je slučaju obuhvaćala oralni karcinom, traumatsku leziju, veliku rekurentnu aftoznu ulceraciju, orofacijalnu granulomatozu, Wegenerovu granulomatozu, lezije kao posljedicu samoozljeđivanja, sarkoidozu, reakcije na ozljedu stranim tijelom, tercijarni sifilis, duboke gljivične infekcije (histoplazmoza), Behçetovu bolest i oralne manifestacije Crohnove bolesti (18, 19).

Ovaj prikaz slučaja upućuje na nužnost da liječnici ostanu svjesni rijetke manifestacije oralne tuberkuloze. Kao što se

Discussion

Although there has been an increase in the incidence of extrapulmonary TB due to rare clinical presentations, it is still an underdiagnosed entity (13). This case report describes a painless oral ulcer as secondary lesion of active primary lung TB without other specific pulmonary symptoms. In the beginning, we thought that patient was unaware of the tongue thrusting either on remaining tooth 33 and/or inadequate denture and he was given a topical steroid (betamethasone) unguent in orabase to be applied four times a day and the lesion subsided. Moreover, the lesion subsided after two weeks of topical steroid treatment, only to reappear again after one month when the first biopsy was taken. The lesion subsided again on the same topical steroid treatment. After that, the lesion reappeared and the second biopsy was taken. It is interesting to mention that caseous necrosis was revealed only in the second biopsy sample, while Ziehl-Neelsen staining was negative and no acid-fast bacilli were identified. After taking the third biopsy of the sample, it was confirmed that a highly suspected granulomatous inflammation was sarcoidosis and the patient was further referred to hospital where active TB was suspected. During hospitalization the patient was treated by a combination of four standard antituberculosis agents: isoniazid, rifampicin, ethambutol and pyrazinamide. After the treatment, his ulcerated lesion of the tongue rapidly improved along with pulmonary status.

Oral TB is rarely seen and mostly recognized through case reports. This infection spreads via respiratory droplets. The mechanism of oral mucosa inoculation with TB is poorly understood (14). Obviously, an intact mucosa together with saliva and its antimicrobial enzymes is known to inhibit many microbial agents such as HIV. Clinically, these changes are non-specific, such as ulcers or nodules, but can also manifest as lesions within the jaw, such as osteomyelitis or radiolucency (15, 16). A biopsy of oral lesion is often insufficient to establish a diagnosis because granulomatous changes may not be present in early stages of the disease and acid-fast bacilli are hard to prove in sample (17). The literature data show that only a small number of histopathological specimens stain have been positive for acid-fast bacilli, hence a negative result should not be exclusive for a diagnosis of TB (17).

Oral TB malignancy was highly suspected due to the chronic nature of non-healing ulcers in a large number of case reports on oral tuberculosis, a finding which was also seen in the present case. Furthermore, oral TB lesions were painful in most of the published case reports. However, in our case, there was no evidence of painful lesions.

Differential diagnosis regarding this case was as follows: oral cancer, traumatic lesion, major recurrent aphthous ulcer, orofacial granulomatosis, Wegener's granulomatosis, self-inflicted lesions, sarcoidosis, foreign body reaction, tertiary syphilis, deep fungal infections (histoplasmosis), Behçet's disease, and oral manifestation of Crohn's disease (18, 19).

This case report highlights the necessity for physicians to remain cognizant of the rare manifestation of oral tuberculosis. As seen also in other case reports on oral TB, refractory ulcerative tongue lesions should be highly suspicious for

vidi i u drugim prikazima slučajeva o oralnoj tuberkulozi, re-frakторne ulcerozne lezije jezika trebale bi biti vrlo sumnjive za oralni TB. Detaljna medicinska anamneza, te klinički i histopatološki pregled, mogu biti nedostadni za postavljanje dijagnoze. Radiološko ispitivanje i laboratorijska potvrda obvezni su u utvrđivanju dijagnoze (20).

Zaključak

Možemo zaključiti da, iako je riječ o rijetkoj manifestaciji tuberkuloze, oralne lezije treba uključiti u diferencijalnu dijagnozu lezija u usnoj šupljini općenito, posebno u slučaju onih koje ne pokazuju odgovor na konvencionalni antibiotik, protuupalno liječenje ili čiji biopsijski uzorci isključuju zloćudnost. S obzirom na to da uključivanje tuberkuloze kao dio diferencijalne dijagnoze kroničnih oralnih lezija može rezultirati ranijom dijagnozom i liječenjem, time se otvara mogućnost prevencije daljnjeg širenja bolesti.

Sukob interesa

Autori nisu bili u sukobu interesa.

oral TB. A detailed medical patient history, clinical and histopathological examination can be insufficient for establishing diagnosis. Radiological examination and laboratory confirmation are mandatory for establishing diagnosis (20).

Conclusion

In conclusion, despite being a rare manifestation of tuberculosis, oral lesions should be included in differential diagnosis of lesions in the oral cavity in general, especially for lesions not responding to conventional antibiotic, anti-inflammatory treatment, or for lesions with biopsy negative for malignancy. Considering the possibility of tuberculosis as part of differential diagnosis for chronic oral lesions may lead to earlier diagnosis and treatment, thus preventing further dissemination of disease.

Conflict of interest

Authors declare they have no conflict of interest.

Abstract

Introduction: The aim of this case report was to discuss an extremely rare oral lesion as a result of primary pulmonary tuberculosis. **Case report:** In this case report, the patient with refractory painless ulceration at ventral surface of the tongue was described. Detailed medical history was taken followed by clinical examination of the oral mucosa and palpation of regional lymph nodes. Clinical examination revealed ulceration on the patient's ventro-lateral surface of the tongue, approximately two centimeters in diameter. Palpation of regional lymph nodes has not revealed enlargement. The toluidine blue test of the suspected lesion was performed at each control examination. Biopsy samples for histopathologic diagnosis were taken three times. The analysis of the first biopsy sample for histopathology revealed a non-specific inflammation, the second biopsy revealed a caseous necrosis without positive Ziehl-Neelsen staining and the third biopsy revealed a granulomatous inflammation which was highly suspicious of sarcoidosis. During hospitalization, the patient underwent a complete physical examination, and laboratory and radiological diagnostics. Physical chest examination revealed bilaterally coarse crepitations and laboratory findings of his complete blood count revealed normocytic anemia of chronic disease. Radiographic examination of lungs showed multiple small nodules bilaterally and positive direct sputum smear. **Conclusion:** Although oral tuberculosis is a rare condition, it must be taken into account in differential diagnosis of refractory painless oral ulcers.

Received: May 2, 2017

Accepted: November 2, 2017

Address for correspondence

Assistant Professor Dragana Gabrić, DDM, PhD
Department of Oral Surgery, School of Dental Medicine, University of Zagreb, University Hospital center Zagreb HR-10 000 Zagreb
Gundulićeva 5
tel:+38514802138
fax: +38514802159
dgabric@sfzg.hr

Key words

Tuberculosis, Oral; Tongue, Oral Ulcer; Diagnostic Errors, Tuberculosis, Pulmonary

References

1. MeSH Browser [database on the Internet]. World Health Organization website. Geneva: World Health Organization. Accessed 8 March 2017. Available from: http://www.who.int/tb/publications/global_report/gtbr15_main_text.pdf.
2. MeSH Browser [database on the Internet]. Zavod za javno zdravstvo Dubrovačko-neretvanske županije website. Accessed 8 March 2017. Available at: <http://www.zzjzdnz.hr/hr/zdravlje/prevenicija-zaraznih-bolesti/586>.
3. Mehta JB, Dutt AK. Epidemiology and host factors. *Microbiol Spectr*. 2016 Dec;4(6).
4. Aoun N, El-Hajj G, El Toum S. Oral ulcer: an uncommon site in primary tuberculosis. *Aust Dent J*. 2015 Mar;60(1):119-22.
5. Garg RK, Singhal P. Primary tuberculosis of the tongue: a case report. *J Contemp Dent Pract*. 2007 May 1;8(4):74-80.
6. Kashiwagi H, Ibe T, Takahashi Y, Teramura S, Hamaguchi Y, Taguchi O. A case of oral tuberculosis suspected malignancy. *Kekkaku*. 1993 Jul;68(7):495-9.
7. Mahajan S, Srikant N, George T. Atypical presentation of oral tuberculosis ulcer. *N Y State Dent J*. 2007 Nov;73(6):48-50.
8. Venkat Baghirath P, Bhargavi Krishna A, Ashlata P, Sanjay Reddy P. Primary tuberculosis osteomyelitis of the mandible - a rare case report. *OMPJ*. 2011;2(1):117-22.
9. Kumar V, Singh AP, Meher R, Raj A. Primary tuberculosis of oral cavity: a rare entity revisited. *Indian J Pediatr*. 2011 Mar;78(3):354-6.
10. Kamala R, Sinha A, Srivastava A, Srivastava S. Primary tuberculosis of the oral cavity. *Indian J Dent Res*. 2011 Nov-Dec;22(6):835-8.
11. Pasticci MB, Floridi P, Schiarolli E, Stagni GM, De Socio GV, Longari F et al. Lingual tuberculosis: a rare disease in Western countries. *New Microbiol*. 2012 Apr;35(2):233-7.
12. Nahid P, Dorman SE, Alipanah N, Barry PM, Brozek JL, Cattamanchi A, et al. Official American Thoracic Society/Centers for Disease Control and Prevention/Infectious Diseases Society of America Clinical Practice Guidelines: Treatment of Drug-Susceptible Tuberculosis. *Clin Infect Dis*. 2016 Oct 1;63(7):e147-e195.
13. Al-Serhani AM. Mycobacterial infection of the head and neck: presentation and diagnosis. *Laryngoscope*. 2001 Nov;111(11 Pt 1):2012-6.
14. Smolka W, Burger H, Iizuka T, Smolka K. Primary tuberculosis of the oral cavity in an elderly non-immunosuppressed patient. *Arch Otolaryngol Head Neck Surg*. 2008 Oct;134(10):1107-9.
15. Sierra C, Fortún J, Barros C, Melcon E, Condes E, Cobo J et al. Extra-laryngeal head and neck tuberculosis. *Clin Microbiol Infect*. 2000 Dec;6(12):644-8.

16. Weir MR, Thornton GF. Extrapulmonary tuberculosis. Experience of a community hospital and review of the literature. *Am J Med.* 1985 Oct;79(4):467-78.
17. Jain P, Jain I. Oral manifestations of tuberculosis: step towards early diagnosis. *J Clin Diagn Res.* 2014 Dec;8(12):ZE18-21.
18. Hussaini J, Mutusamy S, Omar R, Rajagopalan R, Narayanan P. Base of tongue tuberculosis: a case report. *Acta Med Iran.* 2012;50(2):151-2.
19. Yadav SP, Agrawal A, Gulia JS, Singh S, Gupta A, Panchal V. Tuberculoma of the tongue presenting as hemimacroglossia. *Case Rep Med.* 2012;2012:548350.
20. Popescu MR, Plesea IE, Olaru M, Strambu IR, Fronie AI, Petrescu IO et al. Morphological aspects in tuberculosis of oral cavity – our experience and a review of the literature attempt. *Rom J Morphol Embryol.* 2015;56(3):967-87.