

Michael Leunig · John B. Sledge · Thomas J. Gill  
Reinhold Ganz

## Traumatic labral avulsion from the stable rim: a constant pathology in displaced transverse acetabular fractures

Received: 3 June 2002 / Published online: 23 August 2003

© Springer-Verlag 2003

**Abstract** *Introduction:* During the treatment of a malunited transverse acetabular fracture, a hitherto undescribed extended avulsion of the labrum from the stable acetabular fragment was found. Based on the labral pathomorphology present in this case, the hypothesis was put forward that traumatic acetabular labral avulsions are a constant phenomenon in transverse acetabular fractures. *Patients and methods:* Fourteen patients underwent capsulotomy and/or surgical dislocation of the involved hip to facilitate open reduction and internal fixation of transverse acetabular fractures. *Results:* In all cases, the labrum was partially or completely detached from the superior acetabular rim. In eight cases with bucket-handle tears of the labrum from the stable superior fragment, the injured portion was resected back to normal margins. In one case the labrum was avulsed with an attached piece of bone and was repaired by screw fixation. Small separations of the labrum from the underlying acetabular rim occurred at the level of the fractures in five cases with minor displacement and received no treatment. *Conclusion:* With displaced transverse acetabular fractures, consideration should be given to opening the joint at the time of open reduction and internal fixation to look for associated intracapsular injuries. An avulsed portion of the labrum should be left if stable and undamaged. If unstable and damaged, it is probably better resected and if unstable but intact and/or attached to a bony fragment, it should be repaired.

**Keywords** Hip joint · Acetabulum · Trauma · Fracture · Surgery

### Introduction

This study is based on the treatment experience in a patient who developed a malunion 6 months after a transverse acetabular fracture. To surgically address the malunion, it was necessary to perform an intraarticular osteotomy. The intra-operative assessment of the joint revealed that the labrum was avulsed from the bony acetabular rim along the entire length of the superior fragment. Moreover, the labrum was interposed between the superior contour of the head closed to the fracture area of the acetabular roof. The labrum remained attached to the medially translated inferior fragment. There was a full thickness chondral defect on the superior aspect of the femoral head with well-demarcated borders that appeared to have been caused by the superior fragment during the medial displacement of the femoral head. A large band-like area of partial thickness cartilage loss with indistinct borders, which matched the region where the avulsed labrum had abraded the articular surfaces of both the femoral head and the acetabulum, was present.

The labral pathomorphology present in this case and observed in fourteen consecutive cases thereafter suggests that traumatic acetabular labral avulsions may interfere with an anatomic reduction and/or contribute to the unsatisfactory late results in acetabular fractures [10, 11, 13]. It is the scope of this paper to report on pathomorphologies identified during open surgery of transverse acetabular fractures, which provides evidence that labral injuries are part of the intracapsular pathology and may contribute to pain and progressive arthritis.

### Patients and methods

Six female and eight male patients underwent open reduction and internal fixation for a transverse acetabular fracture revealing a significant displacement (>5 mm) [11] in nine patients (7 transtectal and 2 infratectal fractures) and a minor displacement (<5 mm) [11] in five patients (4 transtectal and 1 infratectal fractures). Surgery was performed between day 1 and day 9 after the fracture (Table 1); time for the surgery ranged between 2 and 8.5 h (Table 2).

M. Leunig (✉) · J. B. Sledge · T. J. Gill · R. Ganz  
Department of Orthopedic Surgery, University of Berne,  
Inselspital, CH-3010 Berne, Switzerland  
Tel.: +41-31-6328920, Fax: +41-31-6323600,  
e-mail: michael.leunig@insel.ch

**Table 1** Patient and fracture characteristics

Case	Patient		Fracture			Delay of surgery
	Gender	Age	Classification	Location	Dislocation	
1	male	18 yrs	B1.1	transtectal	>5 mm	9d
2	male	19 yrs	B2.3	transtectal	>5 mm	3d
3	male	21 yrs	B2.2	transtectal	<5 mm	1d
4	female	31 yrs	B1.1	transtectal	>5 mm	1d
5	female	59 yrs	B2.1	infratectal	>5 mm	4d
6	male	47 yrs	B3.3	transtectal	<5 mm	8d
7	female	47 yrs	B1.3	transtectal	>5 mm	2d
8	female	52 yrs	B2.1	transtectal	<5 mm	8d
9	male	62 yrs	B1.3	infratectal	>5 mm	8d
10	female	23 yrs	B1.1	transtectal	>5 mm	1d
11	female	41 yrs	B2.3	transtectal	>5 mm	2d
12	male	19 yrs	B1.2	infratectal	<5 mm	2d
13	male	29 yrs	B1.2	transtectal	>5 mm	4d
14	male	25 yrs	B2.3	transtectal	<5 mm	2d

**Table 2** Surgical management

Case	Time for surgery	Approach	Joint inspection	Labrum tear		
				Location	Stable	Treatment
1	3.5 h	SP	capsulotomy	superior	no	Resection
2	3.5 h	KL	dislocation	superior	no	Repair
3	4.0 h	SP	capsulotomy	anterior	yes	No
4	6.0 h	ExIF	capsulotomy	superior	no	Resection
5	4.5 h	SP	capsulotomy	superior	no	Resection
6	2.5 h	KL	dislocation	posterior	yes	No
7	3.5 h	KL	dislocation	superior	no	Resection
8	4.0 h	SP	capsulotomy	posterior	yes	No
9	6.0 h	ExIF	dislocation	superior	no	Resection
10	4.0 h	KL	dislocation	superior	no	Resection
11	8.5 h	KL	capsulotomy	superior	no	Resection
12	3.0 h	KL	capsulotomy	posterior	yes	No
13	4.0 h	SP	dislocation	superior	no	Resection
14	2.0 h	KL	capsulotomy	superior	yes	No

SP Smith-Peterson, KL Kocher-Langenbeck, ExIF extended Iliofemoral

The hip joint was explored by extending the traumatic capsular tear (six patients) or by extending the traumatic capsular tear and performing a surgical dislocation (eight patients) (Table 2). When surgical dislocation was performed using an anterior or posterior approach, the femoral head was dislocated anteriorly by flexion, adduction and external rotation of the lower extremity [5]. The round ligament, if not traumatically sheared off, had to be transected to optimize visualization during dislocation.

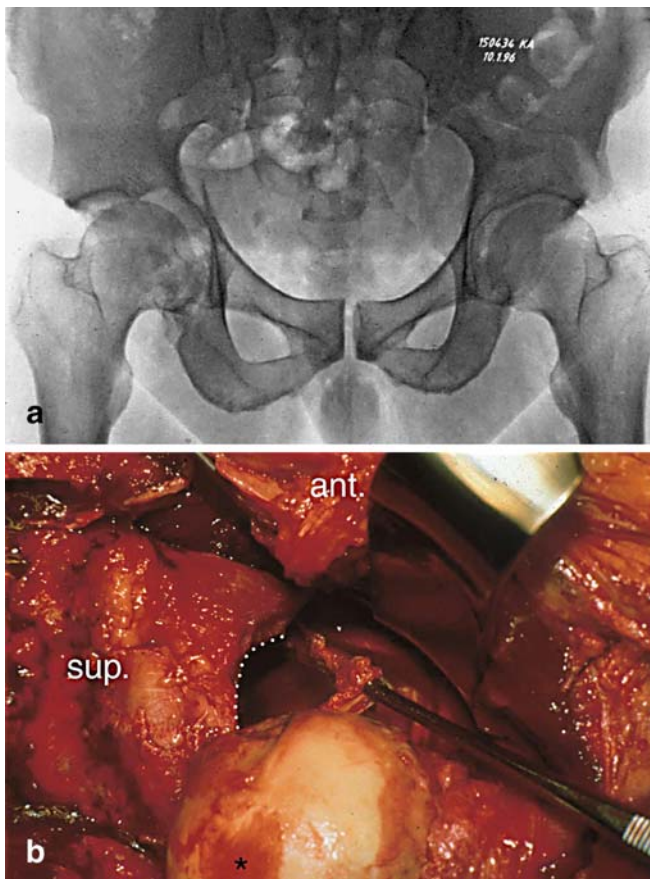
Labral lesions were characterized according to location, size, stability and evidence of intra-substance damage. Depending on the type of labral damage, lesions were resected, reattached or left untreated (Table 2). Anatomic reconstruction of the articular surface was attempted before or after treatment of the labral pathology, depending on whether the labrum had to be repaired or resected (displacement <2 mm) [7]. The post-operative treatment included partial weight bearing for at least 8 weeks and was dependent on the degree of the radiographic consolidation of the fracture. Follow-up (ranging from 4.6 to 6.9 years) was performed clinically, reflected by the Merle d'Aubigne score [1], and radiographically, reflected by the Tönnis score [14].

## Results

At the time of surgery the labrum was in one piece in all 14 cases, but was at least partially avulsed from the ac-

etabular rim. Nine lesions (all in displaced fractures) were defined as unstable, e.g., able to interpose the avulsed portion of the labral between the articular surfaces, and five were defined as stable. The type and location of the unstable avulsions were consistent in each patient (Table 2). Eight of the nine unstable labral avulsions were at the junction of the labrum with the bony acetabular rim, while one was avulsed with an attached fragment of bone. All nine disrupted labra remained attached to the medially displaced acetabular fragment, but were detached from the stable superior fragment along its entire length (Fig. 1). The damaged intrasubstance portion of the bucket-handle tears and the five stable tears all occurred at the fracture site through the acetabular rim. All femoral heads had some degree of traumatic chondral injury in the superior region, caused by impaction of the head against the jagged inferior border of the superior fragment at the time of the medial dislocation.

The eight unstable avulsions that separated at the junction of the labrum to the acetabular rim had all more or less severe damage to the labral substance and were therefore resected. The avulsed portions were resected back to



**Fig. 1** a Anteroposterior pelvic radiograph of a male patient (case 11) with medially displaced femoral head and inferior fragment in a transverse acetabular fracture of the right hip. b Intraoperative photograph of the same patient showing a hemicircular labral avulsion (probed by a forceps) from the superior acetabular rim (white dots). Note the cartilage lesion (case 11) seen on the femoral head (black star)

their stable attachment on the inferior fragment with tapering of the corners to produce a stable transition. One labrum with an attached fragment of bone was reduced and secured with screw-osteosynthesis. The five stable tears were left untreated. After internal fixation, but prior to capsular closure, the patients had a 2-mm drill hole made in the femoral head to assess vascularity [6]. In all cases bleeding was identified, demonstrating continued perfusion of the femoral head.

After a mean follow-up of 5.6 years (range 4.6–6.9 years), four patients received a THA (highest age group), two further patients revealed a low Merle d'Aubigne and radiographic score despite a good postoperative reduction (exception: case 9) (Table 3). In three of the four patients requiring a THA (two osteoporotic postmenopausal women, one psychotic woman), there was a loss of reduction early during the postoperative period. One patient had significant traumatic femoral head damage (Fig. 1). Of the remaining ten patients, seven patients had a good to excellent Merle d'Aubigne score. Two of those patients who had a fair Merle d'Aubigne score, had low radiographic

**Table 3** Follow-up

Case	Postoperative reduction	Follow-up yrs	Md'A pts	OA Grade
1	<2 mm	6.9 yrs	18	0
2	<2 mm	6.0 yrs	18	0
3	<2 mm	6.7 yrs	16	0
4	<2 mm	6.6 yrs	18	0
5	<2 mm <sup>a</sup>	6.4 yrs	16 (THA)	3 <sup>b</sup>
6	<2 mm	6.0 yrs	16	1–2 <sup>c</sup>
7	>2 mm	<sup>d</sup>	<sup>d</sup>	<sup>d</sup>
8	<2 mm <sup>a</sup>	5.6 yrs	16 (THA)	3
9	>2 mm	5.5 yrs	14 (THA)	3
10	<2 mm	4.9 yrs	18	0
11	<2 mm <sup>e</sup>	4.8 yrs	15 (THA)	2
12	<2 mm	4.7 yrs	11	1–2
13	<2 mm	4.6 yrs	17	0
14	<2 mm	4.6 yrs	11	1–2

THA total hip arthroplasty, OA osteoarthritis

<sup>a</sup>early (<2 months) postoperative loss of reduction

<sup>b</sup>preexisting bilateral OA (grade 2)

<sup>c</sup>preexisting bilateral pistol grip deformity

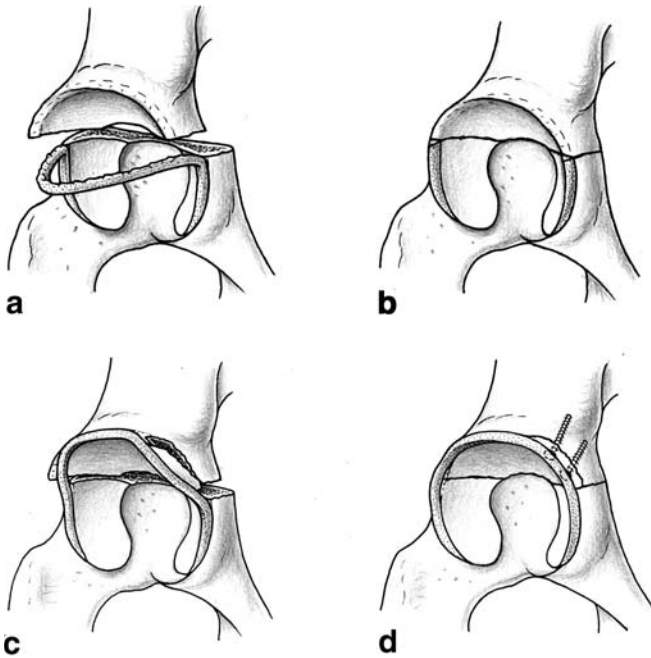
<sup>d</sup>lost to follow up

<sup>e</sup>significant femoral head damage documented at surgery

scores. One patient was lost to follow-up. Until the last follow-up, there was no apparent avascular necrosis.

## Discussion

Traumatic labral damage was found in all patients of this study, suggesting that it may be important to consider the possible contribution of intracapsular pathology when treating acetabular fractures. When the acetabular fracture is significantly displaced, the attached labrum must either be torn at the fracture site or avulsed from the stable fracture fragment. Based on our experience, the attachment of the labrum to the bony acetabular rim appears to be the primary site of failure since all patients revealed labral avulsions, which has not ever been reported in large series [10]. This is different from two column fractures, where tensile properties of the labrum, which is still attached to the bone, may contribute to the so-called apparent congruency. With both column fractures, the acetabulum no longer has bony continuity to the remainder of the pelvis, so the labrum is most likely the structure that minimizes fragment displacement, maintaining the correct relationship irrespective of the displacement from the remainder of the pelvis [10]. Considering the physiologic function of the labrum in the maintenance of the joint sealing function, which is required for sufficient cartilage lubrication and distribution of joint pressures, labral pathologies should be addressed [2, 3]. Moreover, the labrum is known to contain nociceptive fibers [9] and thus might cause symptoms if left untreated. Although the labrum reveals a rich peripheral vascularity possessing the potential to heal [9], the literature reports mixed results for the non-operative treatment of labral pathologies, most of them being nontraumatic.



**Fig. 2a–d** Schematic drawings of unstable (a, b) and stable (c, d) avulsion. In unstable labral avulsion (a) the labrum is not attached to the acetabular rim and prone to dislocate into the joint. In such cases the labrum had to be resected (b). In stable labral avulsions (c), partial attachment of the labrum to the acetabular rim was present. In cases of osseous avulsions, refixation was attempted (d)

Based on our findings the question arises, which strategy should be followed for treating labral injuries associated with transverse acetabular fractures. Ikeda et al. did have seven of eight patients respond to non-operative care with protected weight bearing [8], while Fitzgerald only had seven of 56 patients respond to non-operative treatment [4]. Since only those patients whose non-operative treatment failed had their labral lesions examined, it is not known how the lesions in those who responded to non-operative treatment differed from those who did not. Operative resection of the damaged portion of the labrum, however, has been reported to provide excellent pain relief and good range of motion, but its effect on the long-term function of the hip has yet to be defined [4, 12].

In this study, eight unstable avulsions were resected back to stable margins (Fig. 2a, b), one labrum and its attached piece of bone was reduced and stabilized (Fig. 2c, d), and five lesions were stable and were thought to require no treatment. The risk to the vascularity of the acetabular fragments was minimized by utilizing the traumatic capsular rents to perform the capsulotomy. The follow-up of 5.6 years should be sufficient to propose that capsulotomy and/or anterior surgical dislocation at the time of surgery do not increase the risk of avascular necrosis of the femoral head or of the acetabular fracture fragments. The overall clinical result of the current study showed good to excellent Merle d'Aubigne scores in 11 of 13 cases (one case was lost to

follow-up). However, four of the 11 cases were converted into THA, revealing good to excellent results after osteosynthesis in seven of 13 cases only. If fractures converted into THA are considered as surgery-, patient- (three cases of early loss of fracture reduction) or trauma-related (one case of femoral head damage) failures, seven of the nine patients available for follow-up (78%) showed good to excellent results. Despite the fact that the data match those reported from the classical studies [10, 11], we believe our series is too small to perform conclusive comparisons with other studies.

In summary, significantly displaced transverse acetabular fractures constantly revealed avulsions of the labrum from the stable rim. Although not all labral injuries cause reduction problems or later symptoms, as shown by the excellent classical studies obtained with this group of acetabular fractures [10, 11], we recommend evaluating and treating intra-capsular injuries at the time of open reduction and internal fixation of severely displaced transverse acetabular fractures. The high incidence of extended labral injuries found and the possibility of interposition between the head and the repaired acetabulum suggest that these injuries may negatively impact the outcome if neglected.

## References

1. d'Aubigne R, Postel M (1954) Functional results of hip arthroplasty with acrylic prosthesis. *J Bone Joint Surg* 36-A:451–475
2. Ferguson S, Bryant J, Ganz R, Ito K (2000) The influence of the acetabular labrum on hip joint cartilage consolidation: a poroelastic finite element model. *J Biomech* 33:953–960
3. Ferguson SJ, Bryant JT, Ganz R, Ito K (2000) The acetabular labrum seal: a poroelastic finite element model. *Clin Biomech* 15:463–468
4. Fitzgerald RH Jr (1995) Acetabular labrum tears. Diagnosis and treatment. *Clin Orthop* 311:60–68
5. Ganz R, Gill TJ, Gautier E, Ganz K, Krügel N, Berlemann U (2001) Surgical dislocation of the adult hip. A technique with full access to femoral head and acetabulum without the risk of avascular necrosis. *J Bone Joint Surg* 83-B:1119–1124
6. Gill T, Sledge J, Ekkernkamp A, Ganz R (1998) Intraoperative assessment of femoral head vascularity after femoral neck fracture. *J Orthop Trauma* 12:474–478
7. Heeg M, Klasen H, Visser J (1990) Operative treatment for acetabular fractures. *J Bone Joint Surg* 72-B:383–386
8. Ikeda T, Awaya G, Suzuki S, Okada Y, Tada H (1988) Torn acetabular labrum in young patients. Arthroscopic diagnosis and management. *J Bone Joint Surg* 70-B:13–16
9. Kim YT, Azuma H (1995) The nerve endings of the acetabular labrum. *Clin Orthop* 320:176–181
10. Letournel E, Judet R (1993) Fractures of the acetabulum. Springer, Berlin Heidelberg New York
11. Matta JM (1996) Fractures of the acetabulum: accuracy of reduction and clinical results in patients managed operatively within three weeks after injury. *J Bone Joint Surg* 78-A:1632–1645
12. Nelson MC, Lauerman WC, Brower AC, Wells JR (1990) Avulsion of the acetabular labrum with intraarticular displacement. *Orthopedics* 13:889–891
13. Tile M (1995) Fractures of the pelvis and acetabulum. Williams and Wilkins, Baltimore
14. Tonnis D (1976) Normal values of the hip joint for the evaluation of X-rays in children and adults. *Clin Orthop* 119:39–47