

Concise Report

Successful mycophenolate mofetil therapy in nine patients with idiopathic retroperitoneal fibrosis

S. Adler^{1,2}, S. Lodermeier¹, J. Gaa³ and U. Heemann¹

Objective. To assess the therapeutic benefit of mycophenolate mofetil (MMF) in retroperitoneal fibrosis (RF).

Methods. MMF 2g/day and prednisone 1 mg/kg were initiated in nine patients with radiological (9/9) and histological verification (2/9) of idiopathic RF. Out of nine patients, seven needed bilateral ureteral stenting due to extensive hydronephrosis.

Results. All patients experienced regression of radiological extension. Out of seven patients, five were free of ureteral catheters after a mean of 5.6 months and two remained on stenting due to secondary stenosis. Within 6 months mean creatinine and CRP fell from 2.5 to 1.2 mg/dl and from 4.0 to 1.4 mg/dl, respectively. MMF was discontinued after a mean of 27 months. Prednisone was tapered to zero after a mean of 7 months. Side-effects were urinary tract infections in 7/9 patients and impaired glucose tolerance in 3/9. No recurrence occurred after withdrawal of glucocorticoids and MMF in 7/9 patients after a mean overall follow-up of 55 months (range 12–120).

Conclusions. Treatment with MMF and glucocorticoids was successful in inducing partial or complete and lasting remission in RF. The results suggest the use of MMF as additional immunosuppressive option.

KEY WORDS: Mycophenolate mofetil, Retroperitoneal fibrosis, Glucocorticoids, Connective tissue disease.

Introduction

Idiopathic retroperitoneal fibrosis (IRF) is a rare disease with an estimated incidence of 0.2–0.5 per 100 000, first described by Albarran in 1905 and completely recognized by Ormond in 1948 [1, 2].

Characteristic finding is a retroperitoneal mass around the aorta mostly extending from the renal hilus to the iliac vessels with possible extension to extra-abdominal organs [1, 3]. The caval vein and one or both ureters are most often involved in this process leading to obstruction, hydronephrosis and renal insufficiency.

CT or MRI are mostly able to distinguish from lymphoma, haemorrhage, other inflammatory processes or tumours [4].

Histological examinations show signs of an immune-mediated origin with infiltrates of IgG4-positive plasma cells, CD20-positive B cells and CD4- and CD45-positive T cells in the active phase, finally leading to fibrotic replacement [5, 6]. Meanwhile IRF is described as an autoimmune disease with questionable antigenic induction [3].

Treatment strategy has changed from surgery to immunomodulating agents like corticosteroids, cyclosporin, AZA, tamoxifen or in part cyclophosphamide. Their usefulness is mostly limited by recurrence or side-effects [3, 7].

According to histology of IRF it can be useful to quickly stop the inflammatory action by the use of glucocorticoids. In order to then block the T- and B-cell proliferation more specifically, a concomitant use of MMF appears to be a promising option. MMF has shown to be effective as antilymphocytic proliferative drug. It is clinically used in the prevention of transplant rejection and in autoimmune diseases like lupus nephritis and vasculitides [8, 9]. The use in IRF patients was described in a few single-case reports for initiation as well as maintenance therapy and in two recently reported cohorts for observational periods of <10 yrs [10–14].

We describe our experiences with a combination therapy of corticosteroids and MMF in nine patients with IRF since 1996.

Patients and methods

Between 1996 and 2005, nine patients (seven males and two females, age at diagnosis 41–75 yrs, mean age 58.5 yrs) were referred to our outpatient clinic with either confirmed or suspected IRF. One patient had already been treated with a 4-month cycle of prednisone and presented another 4 months after cessation of therapy with the recurrence of ureteral obstruction.

All patients showed signs of systemic inflammation with either positive CRP (maximum 13.3 mg/dl, minimum 0.5 mg/dl; normal range <0.5 mg/dl) or ESR (maximum 70 mm/h) or both. Creatinine values ranged from 12.8 to 0.8 mg/dl prior to therapy. Thorough clinical examination and additional chest X-ray was performed in all patients to rule out additional malignancy. Out of nine patients, six had been treated with antihypertensive medication consisting of β -blockers in two of six patients and calcium channel blockers and diuretics in three patients; one patient was without antihypertensive therapy. There was no history of methyldopa, ergotamine, radiation, surgery except in one (see subsequently) or asbestos exposure.

This case series meets and is in compliance with ethical standards in medicine and informed consent was obtained from all patients. For patient overview please see Table 1.

Biopsies

Histology in 2/9 patients during laparotomy ruled out malignancy in one patient with a history of bladder cancer and an abdominal aortic aneurysm in a second one. It showed signs of IRF with proliferating B- and T-cell infiltrates.

Radiological diagnosis

Abdominal ultrasound showed signs of an undefined periaortic mass. There was mild hydronephrosis in one and moderate to severe hydronephrosis in seven patients. All patients underwent either abdominal CT between 1996 and 2001 or MRI thereafter for diagnosis and follow-up. It initially showed periaortic inflammatory tissue beginning inferior to the renal hili and extending to the iliac vessels with various extensions into the retroperitoneal area.

¹Department of Internal Medicine II/Nephrology, Technical University of Munich, Munich, Germany, ²Department of Rheumatology and Clinical Immunology/Allergology, Inselspital, University of Bern, Bern, Switzerland and ³Department of Radiology, Technical University of Munich, Munich, Germany.

Submitted 13 April 2008; revised version accepted 25 June 2008.

Correspondence to: S. Adler, Department of Rheumatology and Clinical Immunology/Allergology, Inselspital, University of Bern, Freiburgstrasse 3010, Bern, Switzerland. E-mail: sabine.adler@lrz.tu-muenchen.de

TABLE 1. Overview of patient characteristics

Patient number	Sex	Age at diagnosis	Leading symptom(s)	Initial hydronephrosis	Double J stenting	Duration of stenting (months)	Radiological diagnosis	Histology months	Steroids months	MMF	Creatinine pre- and post-treatment (mg/dl)	Side-effects/ complications
1	F	57	Abdominal pain	Severe	Yes	Ongoing	CT and MRI	No	24	96	1.2–1.3	UTI
2	M	61	Back pain	Moderate to severe	Yes	3	CT	Yes	6	36	0.8–0.8	UTI
3	M	58	Malaise	Severe	Yes	8	CT	No	3	24	4.3–1.6	UTI
4	M	55	Back pain	Moderate to severe	Yes	5	MRI	No	4	11	1.0–0.9	UTI
5	M	41	Malaise	Severe	Yes	Ongoing	MRI	No	3	24	12.8–2.6	UTI, diabetes
6	M	53	Back pain	Moderate	Yes	6	MRI	No	8	12	2.0–1.1	UTI
7	M	74	Malaise	Mild	No	No	MRI	No	6	14	0.9–1.1	None
8	F	75	Malaise	Moderate to severe	Yes	6	MRI	No	4	12	1.2–1.2	UTI, diabetes conjunctivitis
9	M	53	Abdominal pain	None	No	No	MRI	Yes	5	12	1.1–1.1	Diabetes

F: female; M: male; UTI: urinary tract infection.

Initial diagnosis and follow-up considered the grade of inflammation as radiological enhancement as well as the extension and regression of RF.

Ureteral stenting

Seven patients with moderate to severe hydronephrosis underwent bilateral double-J stenting of both their ureters. Two patients without hydronephrosis did not need any stenting.

Medication

Pharmacological treatment consisted of oral prednisone in a dosage of 1 mg/kg bodyweight for 2 months and was then tapered to zero within the next 4 months to a planned overall duration of 6 months. MMF was started concomitantly in a dosage of 1 g twice daily.

Follow-up

During therapy and after cessation of immunosuppression it consisted of serum creatinine, blood urea nitrogen, electrolytes, blood glucose, CRP, lipase, ALT, AST, ESR, blood smear, urinalysis and abdominal ultrasound. Within the first 6 months after initiation of therapy, intervals of investigation were 2 weeks, gradually extending to every 3 months after having achieved a stable situation. Additional CT or MRI scans were performed every 4–6 months during therapy and every 12 months after cessation of immunosuppression. Ureteral stents were removed according to radiological regression of IRF extension and reinserted in case of recurrent hydronephrosis after removal.

Results

All patients experienced regression of IRF on CT or MRI that led to removal of ureteral catheters in five of seven stented patients with a mean duration of 5.6 months (range 3–8). The two remaining patients have repeatedly been stented due to recurrence of hydronephrosis after stent removal. Patient 7 is free of his initially mild hydronephrosis. Creatinine declined from 2.8 to 1.3 mg/dl mean.

MMF treatment was discontinued after a mean of 27 months, range 11–96 months.

Corticosteroid treatment was discontinued after a mean of 7 months, range 3–24 months. CRP declined from a mean of 5.5 (range 0.5–13.3 mg/dl) to 0.8 mg/dl (range <0.5–1.8, normal values <0.5 mg/dl), ESR values declined from a mean of 36 to 9 mm/first hour.

Special patient characteristics

Patient 1 was planned for operative lateralization of her ureters due to extreme hydronephrosis but refused surgical treatment. With recurrent intermittent stenting and a continuous MMF treatment her renal function remained stable with a creatinine

of 1.2 mg/dl despite a remnant kidney function of 10% on the left side. In order to avoid surgery she refused to stop MMF for 8 yrs.

Patient 3 presented with extensive hydronephrosis and a creatinine level of 3.6 mg/dl. Under immunosuppression and concomitant ureteral stenting he experienced a marked regression of IRF and then stopped corticosteroids after 3 months in fear of side-effects. He repeatedly became hydronephrotic after stent removal and underwent surgical ureterolysis 5 months after initiation of medical treatment with immediate postoperative relief of hydronephrosis. MMF was continued for 2 yrs due to the fact of a monotherapy in an extensive disease. Creatinine fell to 1.4 mg/dl.

Patient 9 underwent emergency admission to a tertiary care centre due to abdominal pain and radiological suspicion of an extensive abdominal aortic aneurysm. Emergency surgery the next day did not show an aortic aneurysm. Fast-track histology revealed signs of RF. Surgery was discontinued without any further procedure and the patient was transferred for medical treatment. Immunosuppression was begun after completion of wound healing. Radiological regression of IRF is shown prior to immunosuppression and 4 months after initiation of therapy (Figs 1 and 2).

Side-effects

During ureteral stenting all seven patients experienced recurrent urinary tract infections and were sufficiently treated with antibiotics according to microbial testing. Three patients were found to have abnormal glucose tolerance within the first 3 months. Corticosteroids were therefore reduced prior to schedule in combination with dietary modification and part-time oral antidiabetics. Due to unspecific upper gastrointestinal disturbance in one patient, MMF was given in four applications per day and finally had to be reduced to 50%, which was well tolerated.

No side-effects were seen with regard to the haematopoietic system or tumour induction in the long run.

Overall follow-up ranged from 2 to 11 yrs with respect to the time of diagnosis and from 1 to 4 yrs after cessation of immunosuppression.

Discussion

We could demonstrate the effectiveness of MMF and corticosteroids in the induction and maintenance therapy of IRF in nine patients over the last 10 yrs with minor side-effects and no case of recurrence after cessation of therapy.

Suspecting an autoimmune-mediated disease with immunohistochemistry of CD20+ B lymphocytes and some CD4+ and CD45+ T lymphocytes, MMF in this case appears to be a specific antiproliferative drug. As there is evidence that MMF is able to have additional direct antifibrotic effects this explains its use in the early phase to stop the B- and T-cell cycle as well as initiating

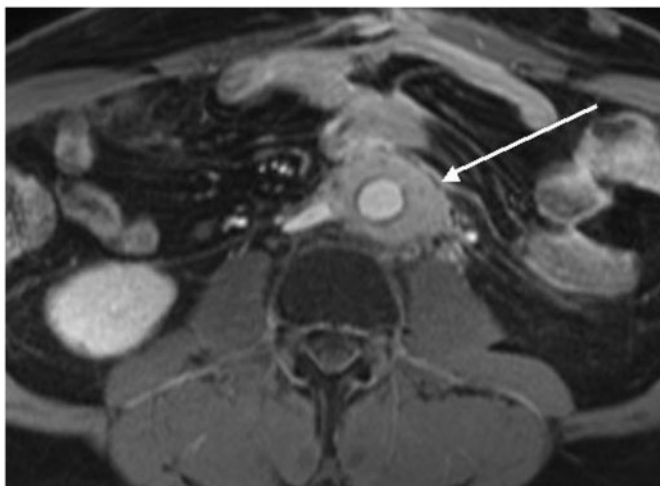

FIG. 1. Abdominal MRI pre-treatment showing a periaortic mass encasing aorta, inferior caval vein and in part the left ureter.

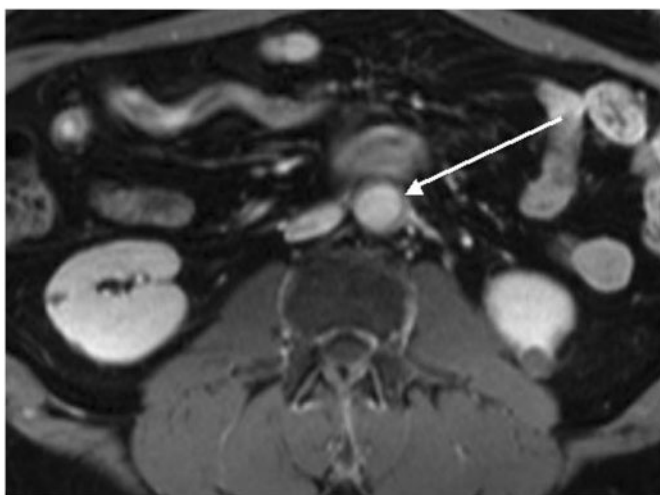


FIG. 2. Abdominal MRI 4 months after initiation of MMF and glucocorticoid treatment showing regression of the periaortic mass to a minimal extent. Inferior caval vein and left ureter are almost free of surrounding tissue (one section distal in comparison with Fig. 1 due to technical reasons). Please note the scar tissue in both the figures after surgery for a questionable abdominal aortic aneurysm.

it at any time of disease activity to reduce fibrogenesis [15]. Furthermore, we learned from organ transplantation that due to its high immunosuppressive potency the use of MMF can lead to a faster reduction of concomitant steroids that appears useful with regard to Patients 5, 8 and 9 who all experienced an intermittent diabetic situation [8].

Mean duration of MMF application in our patient group was 27 months, which is in congruence with the data from Scheel *et al.* [12] taking into account Patient 1 who refused to stop MMF for many years in fear of surgical ureterolysis. Furthermore, it seems reasonable to continue on MMF for more than 12 months in patients with a suspected long-standing or severe extension of disease like in Patients 1 and 5 or in patients with MMF monotherapy due to early corticosteroid cessation.

For an unspecific fast reduction of acute inflammation it appears reasonable to begin MMF in combination with corticosteroids and reduce or even stop the steroid application after about 3 months when MMF should have developed antiproliferative potency. We would not suggest starting with corticosteroid therapy alone. Apart from high recurrence rates, a high dosage

appears to be necessary to control inflammation that goes along with known side-effects [16]. This is in accordance with Patient 8 who after a 4-month cycle of corticosteroids relapsed early after cessation and experienced a diabetic situation after initiation of combination treatment.

In retrospect, the overall dosage and duration of glucocorticoids might have been too high and too long in a combination therapy with a high immunosuppressive potency. Therefore, early reduction of glucocorticoids in a controlled and reduced inflammatory situation might be more reasonable in favour of a longer duration of MMF where necessary.

Whether ESR and CRP levels are reliable parameters for surveillance remains a matter of debate. Whereas Warnatz *et al.* [17] could not find a good correlation of disease activity with CRP levels but with radiology, Scheel *et al.* [12] demonstrated a positive correlation of ESR as well as CRP. We could not find a reliable course as some patients had normal CRP values despite radiologically detectable inflammation and a good response to immunosuppressive treatment.

With regard to the side-effects we emphasize the need for a short duration of ureteral stenting as all stented patients experienced urinary tract infections. In patients with mild hydronephrosis, without elevation of creatinine a ureteral stenting might be unnecessary like in Patient 7.

As CT and MRI are able to identify RF we suggest histology for query cases only keeping in mind a possibly misleading cytology of fine needle aspirates and the risk of intervention itself [18]. A PET might be helpful in the future for differentiation and follow-up of inflammation *vs* remnant scar tissue [19]. Combination with CT or MRI might verify ureteral fibrosis due to repeated ureteral stenting and lead to surgical treatment—as probably will become necessary in Patients 1 and 5.

A future steroid-sparing option could be the use of other anti-inflammatory drugs for induction therapy like TNF- α inhibitors or anti-CD20 drugs. Yet for the time being, we would favour the combination of MMF and corticosteroids as optional therapy at any stage of IRF leaving surgery for insufficient treatment responses or secondary distal ureteral stenoses. As our study—like many others—is limited by the number of patients we ask for the establishment of a multicentre-driven study protocol comparing various immunosuppressive regimens to optimize therapeutic outcome.

Rheumatology key message

- A combination therapy of glucocorticoids and MMF could reduce extension and inflammation in IRF with few side-effects. There were no recurrences after cessation of immunosuppression.

Disclosure statement: The authors have declared no conflicts of interest.

References

- 1 Monev S. Idiopathic retroperitoneal fibrosis: prompt diagnosis preserves organ function. *Cleve Clin J Med* 2002;69:160–6.
- 2 Ormond JK. Bilateral ureteral obstruction due to envelopment and compression by an inflammatory retroperitoneal process. *J Urol* 1948;59:1072–9.
- 3 Vaglio A, Salvarani C, Buzio C. Retroperitoneal fibrosis. *Lancet* 2006;367:241–51.
- 4 Engelken JD, Ross PR. Retroperitoneal MR imaging. *MRI Clin North Am* 1997;5:165–78.
- 5 Zen Y, Sawazaki A, Miyayama S, Notsumata K, Tanaka N, Nakanuma Y. A case of retroperitoneal and mediastinal fibrosis exhibiting elevated levels of IgG 4 in the absence of sclerosing pancreatitis (autoimmune pancreatitis). *Hum Pathol* 2006;37:239–43.
- 6 Dash C, Liu K, Sheafor D, Dodd L. Fine-needle aspiration findings in idiopathic retroperitoneal fibrosis. *Diagn Cytopathol* 1999;21:22–6.
- 7 Marcolongo R, Tavolini IM, Laveder F *et al.* Immunosuppressive therapy for idiopathic retroperitoneal fibrosis: a retrospective analysis of 26 cases. *Am J Med* 2004;116:194–7.

- 8 Hamour IM, Lyster HS, Burke MM, Rose ML, Banner NR. Mycophenolate mofetil may allow cyclosporine and steroid sparing in de novo heart transplant patients. *Transplantation* 2007;83:570–6.
- 9 Koukoulaki M, Jayne DR. Mycophenolate mofetil in anti-neutrophil cytoplasm antibodies-associated systemic vasculitis. *Nephron Clin Pract* 2006; 102:c100–7.
- 10 Grotz W, von Zedwitz I, Andre M, Schollmeyer P. Treatment of retroperitoneal fibrosis by mycophenolate mofetil and corticosteroids. *Lancet* 1998;352:1195.
- 11 Jois RN, Kerrigan N, Scott DGI. Mycophenolate mofetil for maintenance of remission in idiopathic retroperitoneal fibrosis. *Rheumatology* 2007;46:718–9.
- 12 Scheel P, Piccini J, Rahman M, Lawler L, Jarett T. Combined prednisone and mycophenolate mofetil treatment for retroperitoneal fibrosis. *J Urol* 2007; 178:140–4.
- 13 Khalil F, Mir MA, Venuto RC. Mycophenolate mofetil in the treatment of retroperitoneal fibrosis. *Clin Rheumatol* 2008;27:679–81.
- 14 Swartz RD, Lake AM, Roberts WW, Faerber GJ, Wolf JS Jr. Idiopathic retroperitoneal fibrosis: a role for mycophenolate mofetil. *Clin Nephrol* 2008;69:260–8.
- 15 Roos N, Poulalhon N, Farge D, Madeleine I, Mauviel A, Verrecchia F. In vitro evidence for a direct antifibrotic role of the immunosuppressive drug mycophenolate mofetil. *J Pharmacol Exp Ther* 2007;321:583–9.
- 16 Van Bommel EF, Siemes C, Hak LE, van der Veer SJ, Hendricksz TR. Long-term renal and patient outcome in idiopathic retroperitoneal fibrosis treated with prednisone. *Am J Kidney Dis* 2007;49:615–25.
- 17 Warnatz K, Keskin AG, Uhl M *et al.* Immunosuppressive treatment of chronic periaortitis: a retrospective study of 20 patients with chronic periaortitis and a review of the literature. *Ann Rheum Dis* 2005;64:828–3.
- 18 Jogai S, Al-Jassar A, Temmim L. Idiopathic retroperitoneal fibrosis – a potential pitfall for fine needle aspiration cytology. *Cytopathology* 2005;16:49–50.
- 19 Vaglio A, Versari A, Fraternali A, Ferozzi F, Salvarani C, Buzio C. 18F-Fluorodeoxyglucose positron emission tomography in the diagnosis and follow-up of idiopathic retroperitoneal fibrosis. *Arthritis Rheum* 2005;53:122–5.