

Magnetic resonance angiography in giant cell arteritis: results of a randomized controlled trial of tocilizumab in giant cell arteritis

Stephan Reichenbach^{1,2,*}, Sabine Adler^{1,*}, Harald Bonel³, Jennifer L. Cullmann³, Stefan Kuchen¹, Lukas Bütikofer^{2,4}, Michael Seitz¹ and Peter M. Villiger¹

Abstract

Objective. To analyse magnetic resonance angiographic (MRA) vessel wall signals from a randomized controlled trial of tocilizumab (TCZ) to treat GCA.

Methods. Participants were assigned in a 2:1 ratio to receive either TCZ+glucocorticoids (GCs) or placebo+GC infusions at 4-week intervals for 52 weeks. GCs were started at 1 mg/kg/day, then tapered to 0.1 mg/kg/day at week 12 and thereafter down to zero. Patients with initial positive MRA findings underwent control MRA at weeks 12 and 52. Vessel wall signals were scored from 0 (normal) to 3 (intense late enhancement). Outcomes were the number of patients with complete MRA remission at weeks 12 and 52, and changes in vasculitis score, vessel anatomy and atherosclerosis.

Results. Of the 30 randomized participants, nine TCZ and two placebo patients had no vessel wall enhancement on initial MRA. At week 12, MRAs were performed in nine TCZ and four placebo patients (nine and three in clinical remission, respectively). Three (33%) TCZ patients showed normalization of vessel wall signals compared with one (25%) placebo patient. At week 52, there was additional MRA improvement in some TCZ patients, but one-third showed persistent or increased late vessel wall enhancement. There was no formation of aneurysms or stenosis and no increase in atherosclerosis.

Conclusions. Although TCZ resulted in complete clinical and laboratory remission of GCA over 52 weeks, MRA signals in vessel walls normalized in only one-third of patients. Whether these signals are of prognostic importance remains to be determined.

Key words: giant cell arteritis, tocilizumab, relapse, glucocorticoids, MRA

Rheumatology key messages

- Tocilizumab induces and sustains clinical and laboratory remission of GCA.
- Tocilizumab does not completely suppress signals of vessel inflammation in magnetic resonance angiography.
- The significance of persistent vessel wall anomalies in magnetic resonance angiography remains to be determined.

¹Department of Rheumatology, Immunology and Allergology, University Hospital, ²Institute for Social and Preventive Medicine, ³Institute of Diagnostic, Interventional and Pediatric Radiology, Inselspital and ⁴CTU Bern, University of Bern, Bern, Switzerland

Submitted 24 July 2017; revised version accepted 16 January 2018

Stephan Reichenbach and Sabine Adler contributed equally to this study.

Correspondence to: Peter M. Villiger, Department of Rheumatology, Immunology and Allergology, University Hospital and University of Bern, CH3010 Bern, Switzerland.
E-mail: peter.villiger@insel.ch

Introduction

GCA is the most common vasculitis in elderly people in Western countries [1]. The condition involves a destructive, granulomatous inflammation of the walls of medium- and large-sized arteries. Glucocorticoids (GCs) are used to control the disease, but the high doses and lengthy treatments invariably lead to high treatment morbidity and mortality [2]. Remission has not been shown to be inducible by conventional immunosuppressive drugs or by biologic

agents [3, 4], and the degree of their steroid-sparing effect during maintenance remains controversial [5].

IL-6 plays a primary role in the pathogenesis of GCA [6]. Tocilizumab (TCZ), an established therapy for RA, is a humanized immunoglobulin G1 kappa mAb that binds to the alpha chain of the human IL-6 receptor and thereby blocks signalling [7].

We recently published the clinical results of a randomized, placebo-controlled trial on the efficacy and safety of TCZ in the treatment of patients with newly diagnosed or recurrent GCA [8]. That study demonstrated that TCZ allowed for the reduction and cessation of GCs and maintained remission in monotherapy over 52 weeks in doses used to treat RA.

There is no information so far about the effect of TCZ on vessel signals seen in magnetic resonance angiography (MRA). This study reports on the findings in large vessel walls as assessed with MRA within the framework of our randomized controlled trial (RCT).

Methods

Design

We performed an investigator-initiated, single-centre, randomized, double-blind, placebo-controlled phase 2 trial at the University Hospital Bern, Switzerland (ClinicalTrials.gov NCT01450137) [8] approved by the local ethics committee. All patients gave written informed consent prior to study enrolment. This study did not require additional approval.

Patients and treatment

Eligible patients were those aged ≥ 50 years who had either relapsing or new-onset GCA and who met the 1990 ACR criteria. Confirmation of GCA was required by either temporal artery biopsy or MRA diagnosis of large vessel vasculitis. For MRA, patients were excluded when they had non-compatible, non-removable implants. Patients, investigators and study personnel were blinded to treatment assignments throughout the study.

Patients were randomly assigned in a 2:1 ratio to treatment with oral GCs as well as either intravenous TCZ at 8 mg/kg body weight or intravenous placebo. A total of 13 infusions were administered at 4-week intervals. Prednisolone was begun at 1 mg/kg/day and tapered weekly by 0.1 mg/kg/day until week 8, then weekly by 0.05 mg/kg until a final dosage of 0.1 mg/kg/day was reached by week 12. Thereafter, the dosage was reduced monthly by 1 mg/day to 0 mg.

The clinical primary end point was prespecified as complete remission at week 12 without clinical signs or symptoms of GCA, and a normal ESR and CRP level at a prednisolone dosage of 0.1 mg/kg/day.

MRA protocol and grading of large vessel vasculitis

All MRA examinations were performed with either a 1.5 or a 3 tesla system of very similar technical standards (Aera/Skyra, Siemens, Erlangen, Germany), using an 18-channel phased-array body coil and a 32-channel spine array. Patients were allocated to either scanner based on

scanner availability (see MRA Protocol in the [supplementary data](#), available at *Rheumatology* online).

To quantify the inflammation of the vessel wall, we adopted a cerebral vasculitis score from 0 to 3 [9] as follows: 0 = no mural thickening (maximal vessel wall thickness < 2.3 mm), no enhancement; 1 = no thickening, slight mural enhancement; 2 = mural thickening (> 2.3 mm), significant mural enhancement; 3 = strong thickening (> 3 mm), strong mural and perivascular enhancement [10]. Scores 2 and 3 were prespecified as representing active mural inflammation ([supplementary Fig. S1](#), available at *Rheumatology* online). Thickening due to wall oedema and/or extraluminal aortic soft tissue enlargement without late wall enhancement was not counted as vasculitis. Aortic wall thickness defining atherosclerosis was determined according to the modified American Heart Association classification of atherosclerotic plaque [11]: types I and II: near-normal wall thickness, no calcification; type III: diffuse intimal thickening or small eccentric plaque with no calcification; types IV and V: plaque with a surrounding lipid or necrotic core; type VI: complex plaque with possible surface defect, haemorrhage or thrombus; type VII: calcified plaque; type VIII: fibrotic plaque without lipid core and with possible small calcifications. In addition, the presence or absence of the following anatomical alterations was assessed: stenosis, occlusions, aneurysms and dissections. Localization was assessed according to the following arterial territories [12]: thoracic root, arch, descending thoracic aorta, suprarenal abdominal aorta, infrarenal abdominal aorta and common carotid, innominate, subclavian, axillary, mesenteric, renal and iliac arteries.

All MRA images, as well as image quality, were assessed independently by two experienced radiologists (H.B., J.C.) who were blinded regarding treatment allocation and serological parameters. Interrater agreement was substantial for the vasculitis score, with a Krippendorff's α of 0.64 (95% CI: 0.45, 0.81), and moderate for the atherosclerosis score (Krippendorff's $\alpha = 0.27$ (95% CI: 0.18, 0.28)). All discrepancies were resolved in a consensus meeting.

Statistical analysis

The primary outcome of this analysis was the number of patients with complete remission on MRA based on the vasculitis score at week 12 (GC dose of 0.1 mg/kg/day). The secondary outcomes were the number of patients with complete MRA remission at week 52 and the change in the vasculitis score. Complete remission was defined as a vasculitis score ≤ 1 , partial remission as a vasculitis score reduction ≥ 1 compared with baseline, and relapse after complete remission as a vasculitis score > 1 after complete remission in a previous visit (i.e. vasculitis score ≤ 1).

Continuous variables are presented as median and interquartile range, and categorical variables as number and percentage of patients. The number of non-missing observations was used as a denominator.

The interrater agreement regarding the vasculitis and atherosclerosis scores was quantified using Krippendorff's α [13] with bias-corrected bootstrap 95% CI.

Results

Enrolment and patient characteristics

Patients were randomly assigned to treatment groups between May 2011 and September 2014, specifically 20 to the TCZ and GC group, and 10 to the placebo and GC group. Sixteen (80%) and seven (70%) patients, respectively, were diagnosed with new-onset GCA. In two patients, this was confirmed by biopsy without MRA. All patients with negative temporal artery biopsy had positive MR angiographic results. MRA was performed in all patients in the TCZ group, and in eight patients in the placebo group (supplementary Fig. S2, available at *Rheumatology* online). Eleven patients (nine in the TCZ group and two in the placebo group) had no signs of vasculitis on MRA at baseline and were no longer followed up. Two patients in the TCZ group and two in the placebo group withdrew from the study prior to week 12. Between weeks 12 and 52, in the placebo group one patient died and one withdrew consent after having a clinical relapse of GCA. Patients in the placebo group with at least one MRA follow-up had a higher BMI compared with those in the TCZ group, but all other baseline characteristics were balanced (supplementary Table S1, available at *Rheumatology* online).

MRA

Interrater agreement was substantial for the vasculitis score, with a Krippendorff's α of 0.64 (95% CI: 0.45, 0.81), and moderate for the atherosclerosis score [Krippendorff's α = 0.27 (95% CI: 0.18, 0.28)]. All discrepancies were resolved in a consensus meeting.

The median vasculitis score at baseline was 3 in the TCZ group and 2 in the placebo group (Table 1). At week 12, three out of nine patients (33%) in the TCZ group were in complete remission and three out of nine patients (33%) were in partial remission, while in the placebo group one patient out of four patients (25%) was in complete remission and one out of four patients was in partial remission (25%). Clinically, all patients in the TCZ group were in remission, while three out of four patients in the placebo group (75%) were in remission.

At week 52, in the TCZ group there was additional improvement on MRA in four patients, but no complete remission, and there was one relapse in one patient, resulting in a median change in the vasculitis score of -1.0 compared with baseline (supplementary Fig. S3, available at *Rheumatology* online). There was no improvement in one patient in the placebo group, and one patient changed from a vasculitis grade of 0 to 1.

The distribution of vasculitis localization is displayed in Fig. 1. All patients showed involvement of the descending thoracic aorta and the suprarenal aorta at baseline. All other vessels were involved as well, but less frequently.

For atherosclerosis, the median score was 2 for both groups at baseline. Only three patients had type III lesions, indicating diffuse intimal thickening or small eccentric plaque with no calcification. For all available MRI at any given time point, atherosclerosis was judged to be the same. None of the MR angiographs showed any stenosis, occlusions, aneurysms or dissections.

Discussion

As part of a RCT of TCZ in patients with GCA, MR angiographs were performed to assess the potential of MR in monitoring local disease activity. At baseline, all patients showed involvement of the descending thoracic aorta and the suprarenal aorta. After 12 weeks, one-third of the patients in the TCZ group and one-fourth in the placebo group were in complete remission as defined by MRA. After 1 year of treatment, improvement was still seen on MR angiographs, but one-third of the patients on TCZ did not improve at all from baseline. These data show that MRA signals of vessel wall hyperaemia do not parallel clinically defined disease activity, and the value of MRA in monitoring disease activity in GCA should be questioned.

The main limitation of this study is its small sample size. We had decided that study participants with normal initial MRA findings would not be followed up. Assessing MR angiographs within the framework of an RCT, however, reduces potential biases compared with observational studies.

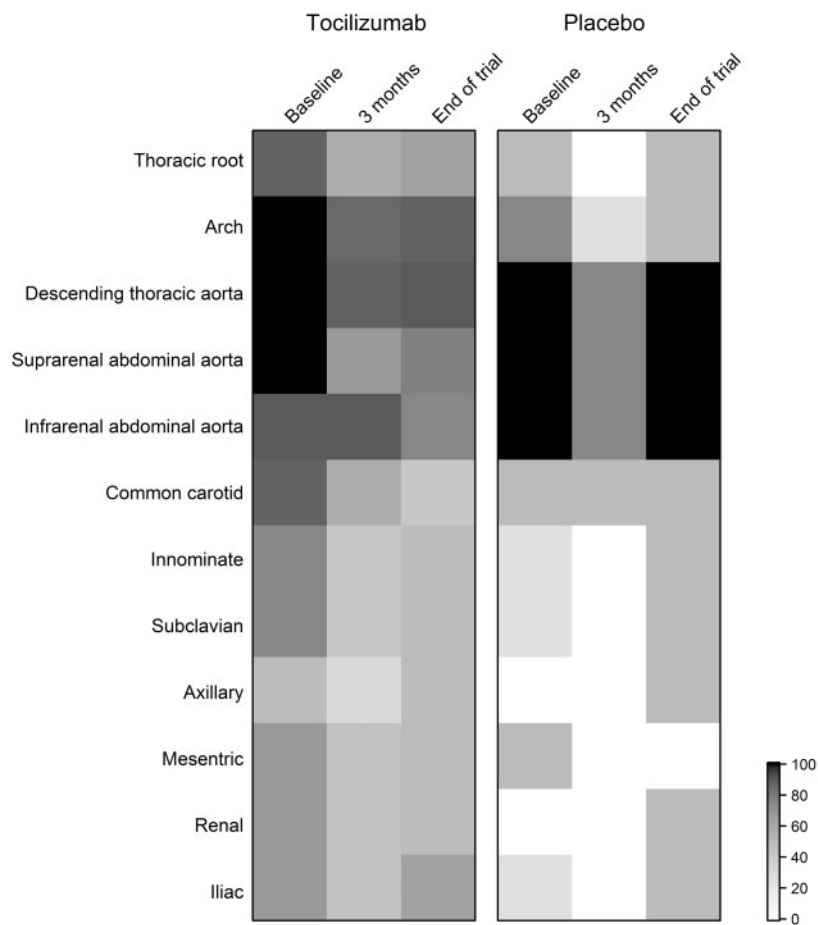
Imaging methods such as MRA, PET-CT and Doppler sonography have recently been used to diagnose large vessel vasculitis [14–16], and recruitment of patients for recent RCTs was based either on positive histological findings in biopsies of temporal arteries or on unambiguous signs of vessel wall inflammation. It is unknown, however, how effective these methods are in assessing disease activity while patients are under treatment. Recently published data have shown persistent signals on PET-CT [17] as well as Doppler ultrasonography in cases of full clinical remission [18].

Our data show for the first time in the setting of an RCT that MRA signals do not disappear if there is lasting complete remission, defined as the complete absence of symptoms and normalization of ESR and CRP. Thus MRA is most likely not a reliable tool to monitor clinical disease activity. However, the question remains as to what these persistent signals signify. There are several hypotheses. (i) There are data showing a reduction of wall signals within a few days of high-dose treatment with GCs [9, 19], implying that the signals reflect local inflammation but that drugs, GCs and/or TCZ were not sufficiently dosed and did not completely stop the disease process. Indeed, the presence of an initial reduction (week 12) of signals in some patients, followed by a subsequent increase (week 52), supports this hypothesis. (ii) There might be a significant qualitative difference between GCs and TCZ regarding their effect on local vessel wall inflammation. However, our data on changes in both the vasculitis score over time and the locations of

TABLE 1 Vasculitis and atherosclerosis scores of patients with at least one MR angiography follow-up

Vasculitis and atherosclerosis score	Tocilizumab (<i>n</i> = 9)		Placebo (<i>n</i> = 4)	
At baseline				
Vasculitis score, median (IQR)	<i>n</i> = 9	3.00 (2.00–3.00)	<i>n</i> = 4	2.00 (2.00–2.50)
Atherosclerosis score, median (IQR)	<i>n</i> = 9	2.00 (1.00–2.00)	<i>n</i> = 4	2.00 (1.00–3.00)
At 3 months				
Vasculitis score, median (IQR)	<i>n</i> = 9	3.00 (1.00–3.00)	<i>n</i> = 4	2.00 (1.00–2.50)
Complete remission of vasculitis	<i>n</i> = 9	3 (33)	<i>n</i> = 4	1 (25)
Complete or partial remission of vasculitis	<i>n</i> = 9	3 (33)	<i>n</i> = 4	1 (25)
Atherosclerosis score, median (IQR)	<i>n</i> = 9	2.00 (1.00–2.00)	<i>n</i> = 4	2.00 (1.00–3.00)
Complete clinical remission	<i>n</i> = 9	9 (100)	<i>n</i> = 4	3 (75)
At end of trial				
Vasculitis score, median (IQR)	<i>n</i> = 9	2.00 (1.00–2.00)	<i>n</i> = 2	1.50 (1.00–2.00)
Complete remission of vasculitis	<i>n</i> = 9	3 (33)	<i>n</i> = 2	1 (50)
Complete or partial remission of vasculitis	<i>n</i> = 9	7 (78)	<i>n</i> = 2	1 (50)
Relapse of vasculitis on MRA after complete remission	<i>n</i> = 3	1 (33)	<i>n</i> = 1	0 (0)
Atherosclerosis score, median (IQR)	<i>n</i> = 9	2.00 (1.00–2.00)	<i>n</i> = 2	2.00 (1.00–3.00)
Complete clinical remission	<i>n</i> = 9	9 (100)	<i>n</i> = 4	2 (50)

Values listed as *n* (%) unless otherwise stated. MR: magnetic resonance; MRA: magnetic resonance angiography.

Fig. 1 Percentages of patients with vasculitis at different locations at baseline, 12 and 52 weeks

inflammation do not support this idea. (iii) The lasting wall signals may reflect persistent hyperperfusion caused by vessel formation in the context of the initial local inflammation. There are no biopsies to prove or dismiss this hypothesis. However, prospective monitoring of vessel wall anatomy will answer this question.

Conclusions

TCZ induces and sustains clinical remission of GCA but does not completely suppress MR signals of vessel inflammation. Whether these signals are of prognostic importance remains to be determined and should be further evaluated in long-term studies.

Funding: This subsequent analysis of the initial trial has been funded by the University of Bern.

Disclosure statement: P.M.V. received honoraria and research support from Roche. All other authors have declared no conflicts of interest.

Supplementary data

Supplementary data are available at *Rheumatology* online.

References

- Nordborg C, Johansson H, Petursdottir V, Nordborg E. The epidemiology of biopsy-positive giant cell arteritis: special reference to changes in the age of the population. *Rheumatology* 2003;42:549–52.
- Weyand CM, Goronzy JJ. Clinical practice. Giant-cell arteritis and polymyalgia rheumatica. *N Engl J Med* 2014;371:50–7.
- Hoffman GS, Cid MC, Rendt-Zagar KE *et al.* Infliximab for maintenance of glucocorticosteroid-induced remission of giant cell arteritis: a randomized trial. *Ann Intern Med* 2007;146:621–30.
- Seror R, Baron G, Hachulla E *et al.* Adalimumab for steroid sparing in patients with giant-cell arteritis: results of a multicentre randomised controlled trial. *Ann Rheum Dis* 2014;73:2074–81.
- Mahr AD, Jover JA, Spiera RF *et al.* Adjunctive methotrexate for treatment of giant cell arteritis: an individual patient data meta-analysis. *Arthritis Rheum* 2007;56:2789–97.
- Roche NE, Fulbright JW, Wagner AD *et al.* Correlation of interleukin-6 production and disease activity in polymyalgia rheumatica and giant cell arteritis. *Arthritis Rheum* 1993;36:1286–94.
- Mihara M, Kasutani K, Okazaki M *et al.* Tocilizumab inhibits signal transduction mediated by both mL-6R and sIL-6R, but not by the receptors of other members of IL-6 cytokine family. *Int Immunopharmacol* 2005;5:1731–40.
- Villiger PM, Adler S, Kuchen S *et al.* Tocilizumab for induction and maintenance of remission in giant cell arteritis: a phase 2, randomised, double-blind, placebo-controlled trial. *Lancet* 2016;387:1921–7.
- Klink T, Geiger J, Both M *et al.* Giant cell arteritis: diagnostic accuracy of MR imaging of superficial cranial arteries in initial diagnosis—results from a multicenter trial. *Radiology* 2014;273:844–52.
- Li AE, Kamel I, Rando F *et al.* Using MRI to assess aortic wall thickness in the multiethnic study of atherosclerosis: distribution by race, sex, and age. *Am J Roentgenol* 2004;182:593–7.
- Buhk JH, Finck-Wedel AK, Buchert R *et al.* Screening for atherosclerotic plaques in the abdominal aorta in high-risk patients with multicontrast-weighted MRI: a prospective study at 3.0 and 1.5 tesla. *Br J Radiol* 2011;84:883–9.
- Kermani T, TADIab, S, Sreih, A *et al.* Arterial lesions in giant cell arteritis. *Arthritis Rheumatol* 2016;68(Suppl 10):Abstract 863.
- Krippendorff K. Estimating the reliability, systematic error and random error of interval data. *Educ Psychol Meas* 1970;30:61–70.
- Bley TA, Weiben O, Uhl M *et al.* Assessment of the cranial involvement pattern of giant cell arteritis with 3T magnetic resonance imaging. *Arthritis Rheum* 2005;52:2470–7.
- Martinez-Rodriguez I, Martinez-Amador N, Banzo I *et al.* Assessment of aortitis by semiquantitative analysis of 180-min ¹⁸F-FDG PET/CT acquisition images. *Eur J Nucl Med Mol Imaging* 2014;41:2319–24.
- Schmidt WA. Imaging in vasculitis. *Best Pract Res Clin Rheumatol* 2013;27:107–18.
- de Boysson HLE, Lambert M, Boutemy J *et al.* Is there a place for repetitive 18f-fluorodeoxyglucose positron emission tomography in giant-cell arteritis with large-vessel involvement? *Arthritis Rheumatol* 2016;68(Suppl 10):Abstract 858.
- Germano G, Monti S, Ponte C *et al.* The role of ultrasound in the diagnosis and follow-up of large-vessel vasculitis: an update. *Clin Exp Rheumatol* 2017;35(Suppl 103):194–8.
- Adler S, Sprecher M, Wermelinger F *et al.* Diagnostic value of contrast-enhanced magnetic resonance angiography in large-vessel vasculitis. *Swiss Med Wkly* 2017;147:w14397.