



P-ISSN: 2304-3075; E-ISSN: 2305-4360

International Journal of Veterinary Science

[www.ijvets.com](http://www.ijvets.com); [editor@ijvets.com](mailto:editor@ijvets.com)

## Research Article

# Investigation of Sciatic Nerve Surgical Anatomy in Dogs and Cats: A Comparative Cadaveric Study

Thomas Dayer<sup>1</sup>, Helene Rohrbach<sup>2</sup>, Simone Forterre<sup>1</sup>, Michael Stoffel<sup>3</sup> and Franck Forterre<sup>1\*</sup><sup>1</sup>Department of Small Animal Surgery; <sup>2</sup>Department of Anesthesiology; <sup>3</sup>Department of Anatomy, Vetsuisse Faculty, Bern, Switzerland\*Corresponding author: [franck.forterre@vetsuisse.unibe.ch](mailto:franck.forterre@vetsuisse.unibe.ch)

Article History: Received: February 23, 2017 Revised: March 24, 2017 Accepted: April 02, 2017

### ABSTRACT

**Objective:** Dogs and cats with traumatic or iatrogenic partial sciatic nerve lesions frequently have disparate clinical signs. Cats commonly walk with a plantigrade posture in the affected pelvic limb, which is rarely observed in dogs. We hypothesized that the tibial nerve would be localized more laterally in cats and medially in dogs, and that the tibial nerve would be larger than the peroneal nerve in cats, which may result in a greater susceptibility of the tibial nerve to iatrogenic trauma in cats. Goal of the present cadaveric study was to investigate differences present in pelvic sciatic nerve anatomy between dogs and cats.

**Methods:** This is an anatomic cadaveric study. Dogs (n=7) and cats (n=7); n=28 hindlimbs. A simple suture was placed without nerve mobilization on the lateral aspect of the lumbosacral trunk at the level of the mid-body of the ilium. A caudolateral approach to the femur was then performed. The lumbosacral trunk was transected in the intrapelvic area cranial to the suture marking the lateral aspect. The peroneal and tibial branches of the sciatic nerve were separated. The proximal lateral knot was identified as being part of the tibial or peroneal nerve, respectively, and the diameter of the tibial and peroneal branches at the level of the suture (mid-ilium) were measured.

**Results:** No difference in relative size of the tibial compared to the peroneal nerve was found between dogs and cats. The tibial nerve was not found to be localized lateral to the peroneal nerve more frequently in cats compared to dogs.

**Conclusions:** Findings suggest that the intrapelvic anatomy of the lumbosacral trunk cannot fully explain the plantigrade posture observed in cats with traumatic or iatrogenic partial sciatic nerve injury.

**Key words:** Lumbosacral trunk, Sciatic nerve, Anatomy, Plantigrade stance

### INTRODUCTION

Dogs and cats with partial traumatic/ iatrogenic sciatic nerve or lumbosacral trunk lesions frequently have disparate clinical signs. Cats commonly walk with a plantigrade posture in the affected pelvic limb which is rarely observed in dogs (Forterre *et al.*, 2007; Nghiem *et al.*, 2009). Further in the author's experience, a plantigrade stance can frequently be observed in cats after surgical treatment of iliosacral joint dislocation. This finding is very seldom in dogs. Based on neuroanatomical considerations, this abnormal posture could result either from a lesion in the lumbar intumescence (L6-S1) or from a lesion of the tibial branch of the sciatic nerve. Therefore, it appears that local conditions might induce more severe dysfunction of the tibial than the peroneal nerve in cats.

Anatomical differences of the sciatic nerve between the two species may explain these findings. The anatomy

of the lumbosacral plexus is grossly similar in the dog and the cat with some small but possibly important differences (Bennett, 1976). The major branches of the sciatic nerve arise from L6, L7, S1 and S2. The peroneal component in the cat is composed of fibers arising from L6 and L7, and the tibial of fibers from L6, L7, S1 and in some cases, S2. In the dog, the S1 nerve roots distribute fibers to both the peroneal and the tibial branches (Bennett, 1976). Whether or not this species difference has any impact on functional neural anatomy remains unclear. Moreover, the intrapelvic anatomy of the lumbosacral trunk beneath the sacrum has not been previously investigated and possible species differences at this level are unknown. The differences in clinical signs after treatment of iliosacral joint dislocation observed in a previous study dealing with iatrogenic pelvic sciatic nerve injury suggests that anatomical differences might exist in the subsacral area (Forterre *et al.*, 2007). In dogs, the most commonly

**Cite This Article as:** Dayer T, H Rohrbach, S Forterre, M Stoffel and F Forterre, 2017. Investigation of sciatic nerve surgical anatomy in dogs and cats: a comparative cadaveric study. *Inter J Vet Sci*, 6(3): 131-135. [www.ijvets.com](http://www.ijvets.com) (©2017 IJVS. All rights reserved)

described clinical signs of peroneal nerve injury include hyperextension of the tarsus, knuckling of the digits and cutaneous analgesia on the dorsal paw and cranial aspect of the leg. In cats, however, signs of tibial nerve dysfunction associated with an overextension of the digits and a dropped hock, as well as analgesia of the caudal and plantar aspect of the paw, were more frequent. These clinical signs are reversible within 6 weeks in most cases and might be explained by an impingement of the lumbosacral trunk beneath the sacrum with the tip of the Hohmann elevator or periost elevator used to reduce the iliosacral joint dislocation.

The objective of the present study was to examine the anatomical localization and diameters of the tibial and peroneal components of the lumbosacral trunk beneath the sacrum to determine whether anatomical variations might be responsible for the clinical differences observed. We hypothesized that the tibial nerve would be localized laterally in cats and medially in dogs and that the tibial nerve would be larger than the peroneal nerve in cats, both of which may result in a higher susceptibility of the tibial nerve to iatrogenic trauma in cats.

**MATERIALS AND METHODS**

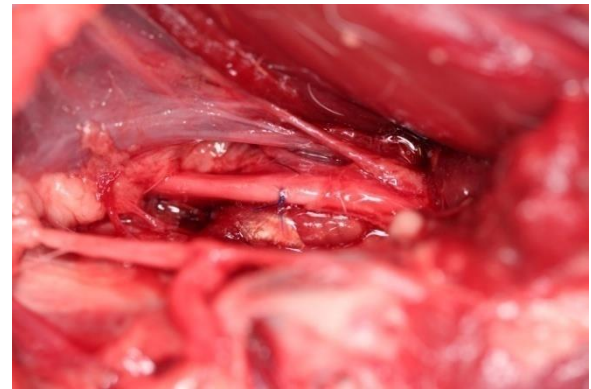
**Animals**

Cadavers of mature European shorthaired cats (n=7) and mature beagles (n=7) that were euthanized for reasons unrelated to the present study were used. A total of 28 (14 feline, 14 canine) sciatic nerves were investigated.

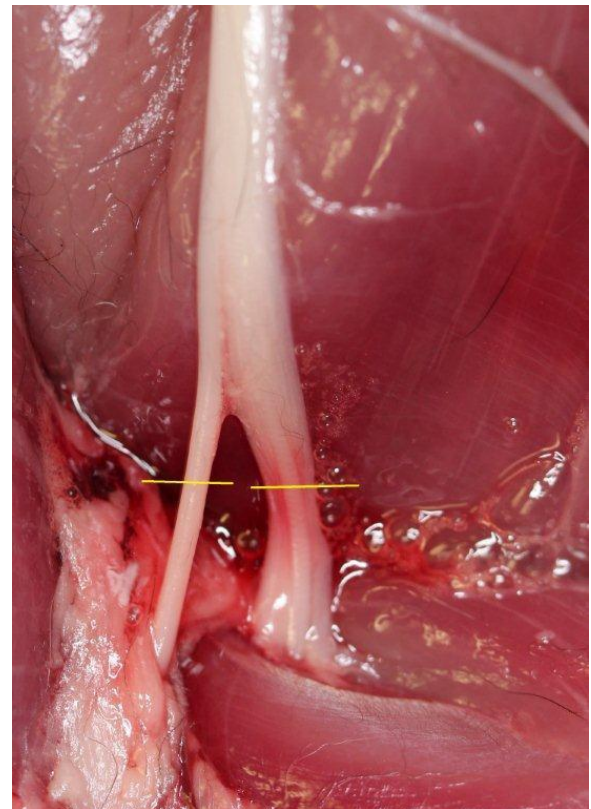
**Exposure of the sciatic nerve**

**Intrapelvic exposure:** A ventral median skin incision extending from the caudal third of the abdomen to the caudal border of the pubis was performed. The caudal part of the linea alba was opened and the incision was prolonged caudally through the prepubic tendon to the surface of the pubic symphysis. The gracilis and adductor muscles were elevated from the pubic symphysis using a Langenbeck periosteal elevator. The ischium and pubis were then osteotomized using an oscillating saw. The first osteotomy was performed bilaterally from the iliopubic eminence to the cranio-lateral aspect of the obturator foramen. The second bilateral osteotomy was performed from the caudolateral aspect of the obturator foramen to the lateral edge of the sciatic arch. The osteotomized pubis and ischium were removed, and the lumbosacral trunk was identified running medially to the body of the ilium. The diameter of the lumbosacral trunk was determined with a Vernier Caliper, taking care to avoid displacement of the nerve during measurement, and a simple suture (5-0 Prolene) was placed on the lateral aspect of the lumbosacral trunk at the level of the midbody of the ilium determined by palpation (Fig. 1).

**Femoral caudolateral exposure:** In a second step, a caudolateral approach to the femur was performed. The skin was incised from the greater trochanter to the proximal aspect of the tibia. The subcutaneous fascia was incised in the same line as the skin incision. The fascia lata was opened along the cranial border of the biceps femoris muscle which was retracted caudally allowing visualization of the sciatic nerve. Caudal to the stifle joint, the peroneal branch was identified as running cranially



**Fig. 1:** Photograph showing the subsacral exposure of the sciatic nerve. A surgical suture marks the lateral aspect of the nerve.



**Fig. 2:** Photograph showing the lateral view of the bifurcation of the sciatic nerve. The peroneal nerve is visible on the left (cranial aspect) and the tibial nerve on the right (caudal aspect). Measurements of nerve diameters were performed at the level marked by a yellow line.

**Table 1:** Diameters of the proximal/distal part of the tibial nerve and of the proximal/ distal part of the peroneal nerve in dogs and cats. Ratio of diameters of tibial/peroneal nerves in the proximal intrapelvic area beneath the sacrum. Number of tibial nerve positioned laterally beneath the sacrum

	Dogs (n=7)	Cats (n=7)
Tibial distal (mm)	3.22±0.37	2.18±0.29
Peroneal distal (mm)	1.68±0.28	1.31±0.25
Tibial proximal (mm)	3.32±0.37	2.29±0.29
Peroneal proximal (mm)	1.72±0.29	1.32±0.25
Ratio proximal tibial/ proximal peroneal nerves†	1.94 [1.64-2.22]	1.68 [1.47-2.07]

Values are expressed as mean ± standard deviation if they were normally distributed and as median [95% confidence intervals] if they were not normally distributed†.

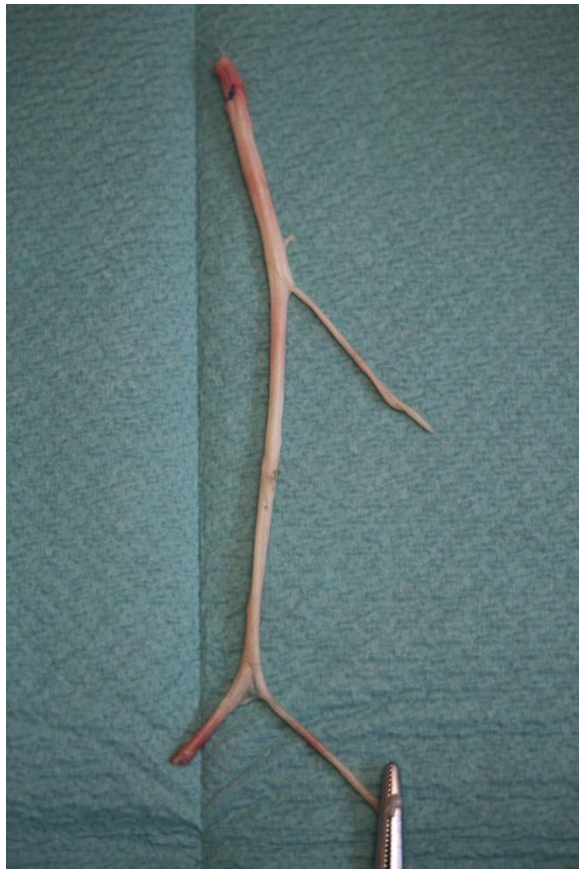


Fig. 3: Photograph showing the sciatic nerve after removal.



Fig. 4: Photograph showing the peroneal and the tibial components of the sciatic nerve after separation. Note the blue suture on the peroneal branch (white arrow).

Table 2: Anatomical position of the tibial and peroneal nerve in the proximal intrapelvic area beneath the sacrum in dogs and cats

	Lateral localization in dogs (n=7)* Total (right / left side)	Lateral localization in cats (n=7) Total (right / left side)	p-values
Tibial nerve	4 (3/1)	1 (0/1)	0.094
Peroneal nerve	8 (3/5)	13 (7/6)	0.098

Distribution of the tibial and the peroneal nerve in the proximal intrapelvic area beneath the sacrum was not significantly different between cats and dogs.

and innervating the tibialis cranialis muscle, and the tibial branch as running distally between the two heads of the gastrocnemius muscle (Fig. 2). The diameters of the tibial and peroneal nerves were measured from their lateral aspect 0.5 cm distal to the sciatic bifurcation using a

Vernier Caliper, avoiding nerve manipulation prior to measurement. A mosquito forceps was placed on the distal aspect of the peroneal branch in order to identify both branches after transection.

The peroneal branch was transected distal to the mosquito forceps and the tibial and other caudofemoral sciatic muscular branches were transected from distal to proximal until the nerve could be freely mobilized. The sciatic nerve was then transected beneath the sacrum cranial to the suture marking the lateral aspect (Fig. 3). After dissection of the common epineural sheath, the peroneal and tibial components of the sciatic nerve were easily separated over the entire length. The proximal lateral suture was identified as being part of the tibial or peroneal nerve (Fig. 4). Finally, the diameter of the tibial and peroneal branches at the level of the suture (mid-ilium) was measured with the Vernier Caliper.

### Statistical analysis

The statistical analysis was performed using commercially available software, NCSS2007 (Number Cruncher Statistical Systems, Kaysville, UT). Data were analyzed for normality. In case of normal distribution values were expressed as mean ± standard deviation (SD), if data were not normally distributed the median and the 95% confidential interval was given. For the statistical comparisons between dogs and cats data were analyzed based on either the two sample t-test for normally distributed data or nonparametric tests (wilcoxon rank-sum test). Data were considered significant with P<0.05.

### RESULTS

The dogs body weight varied between 11-14 kg, with a mean of 12.75. The cats body weight varied between 3-5 kg with a mean body weight of 4.14 kg. The dogs age as well as the cats age varied between 4-6 years. Of the 28 hindlimbs (7 cats, 7 dogs) included in the study, one canine limb was excluded because the sciatic nerve was accidentally injured during dissection. In one other dog, the suture was accidentally removed during the separation of the tibial and peroneal nerves. In this dog, evaluation of the lateral placement of the nerves could not be conducted.

Based on results of this study, the tibial nerve does not appear to be more frequently localized lateral to the peroneal nerve in the cat compared to the dog (P=0.098). In cats the peroneal nerve was located laterally in 13/14 limbs. A similar finding was made in dogs (8/12). In 4 canine limbs the tibial nerve ran laterally. Moreover, the tibial nerve/ peroneal nerve ratio in cats does not appear to be greater than the ratio in dogs (P=0.159). The mean ratio was 1.68 in cats and 1.94 in dogs. Our hypotheses, therefore, cannot be substantiated.

### DISCUSSION

The results of the present study do not support the theory of anatomical differences of the lumbosacral trunk in cats and dogs. Corroborating findings of a previous study, the tibial nerve is larger than the peroneal nerve in both dogs and cats (Bennett, 1976; De Lahunta and Glass, 2009; Budras *et al.*, 2007; Evans and De Lahunta 2013;

Mahler and Adogwa, 2008). The peroneal nerve seems to run more laterally than the tibial nerve in cats, refuting our first working hypothesis. Furthermore there were no statistically significant differences between the species regarding the ratios of the nerve diameters, indicating a similar relative diameter of the tibial branch within the sciatic nerve. A more medial localization of the tibial nerve in cats may also predispose it to iatrogenic injury during surgical treatment of sacroiliac luxation in cats, in contradiction with our primary hypothesis. Indeed, the concave shape of the ventrolateral aspect of the sacrum, along which the sciatic nerve runs, and the deeper ventral border of the sacral wing may protect the lateral aspect of the nerve from compression with a retracting instrument, such as a Hohmann retractor. (Forterre *et al.*, 2007; Budras *et al.*, 2007) Moreover, the medial part might be more susceptible to impingement with the tip of the retracting instrument during reduction of the dislocation. However, if this were true, tibial nerve injury would also occur in dogs, albeit less frequently. However, in one previous study, investigating iatrogenic sciatic nerve injury, clinical signs of tibial nerve injury were recorded in all cats (N=4) but in none of the dogs (n=3) with iliosacral joint dislocation (Forterre *et al.*, 2007). The greater size of the tibial nerve compared to the peroneal nerve found in the present study could also be expected to increase its relative vulnerability. However, nerve ratios were similar in both species. This increased size cannot therefore explain the differences generally observed in clinical findings.

In conclusion, the results of the current study do not support the hypothesis that the disparate clinical signs observed in dogs and cats suffering from a lumbosacral trunk iatrogenic/traumatic lesion are due to neuroanatomical differences. (Forterre *et al.*, 2007; De Lahunta and Glass, 2009; Budras *et al.*, 2007; Evans and De Lahunta 2013; Mahler and Adogwa, 2008) However, further comparative experimental neurophysiological studies are needed to fully rule this out. Differences between the species in biomechanics and muscle anatomy of the pelvic limb could also result in differing clinical signs. Indeed, the more closed tarsal angle (115 to 125°) in cats compared to dogs (135 to 145°) and the presence of the soleus muscle in cats may support this hypothesis. In a previous study of the biomechanics of the caudotibial musculature, the authors concluded that the gastrocnemius and plantaris muscles are primarily responsible for the control of the direction of the ground reaction forces, while the soleus muscle primarily acts as the sole anti-gravity muscle in the cat (Kaya *et al.*, 2006; Burke *et al.*, 1974). The soleus muscle, which is absent in the dog, is a mono-articular muscle, originating at the proximal extremity of the fibula, running down to the level of the calcaneal tendon and closely connected to the gastrocnemius muscle (De Lahunta and Glass, 2009; Budras *et al.*, 2007; Kaya *et al.*, 2006; Burke *et al.*, 1974). Functional differences between the soleus and gastrocnemius/plantaris in the cat may be explained by the distribution of fiber types; the latter are fast twitch muscles and the soleus is a slow twitch muscle (Kaya *et al.*, 2006; Ariano *et al.*, 1973). The soleus is therefore the only fatigue-resistant muscle and is more suitable for continuous force generation (Ariano *et al.*, 1973). Its

innervation arises from the tibial nerve (L5, S1 spinal segments). (De Lahunta and Glass, 2009) Injury to the tibial nerve may therefore result in diminished soleus muscle tone, increased tarsal joint angle and a plantigrade posture. (De Lahunta and Glass, 2009) To the authors' knowledge, biomechanical studies of the function of the gastrocnemius muscle in dogs are lacking but it has been demonstrated that canine gastrocnemius muscle fibers are, contrary to fibers in cats, composed of 46-75% Type 1 fibers, containing a slow twitch contraction time with a high resistance to fatigue comparable to the properties of the soleus muscle fibers in the cat (Burke *et al.*, 1974; Armstrong *et al.*, 1982). This large number of fatigue-resistant fibers indicates that the canine gastrocnemius muscle may have an important role as an anti-gravity muscle. It might be argued that because of its large bicephalic volume, the gastrocnemius muscle might be more resistant to denervation-induced elongation than the feline soleus muscle. Combined with the greater tarsal angle, these findings may explain why the lever arm exerted by the gastrocnemius muscle on the tarsal joint might be lower in dogs (Armstrong *et al.*, 1982). Accordingly, an incomplete tibial nerve lesion might not elicit a plantigrade posture as observed in cats.

One limitation of the present study was the small number of cases examined. Furthermore, greater anatomical variation may be expected if different breed dogs had been included in the study. Nerve diameter may also be different in cadavers than in living animals and the measurements reported in this study should be considered approximate. The effect of the cadaveric condition should however have little bearing on the measurement of the relative differences in size of the two nerves. The reading error of Vernier caliper is 1/20mm (0.05mm) and possible inaccuracy with measuring should also be interpreted as a possible weakness. A pathological exam of the nerves was not performed in the current study. This further investigation would have permitted an axon count and certainly would have enabled an assessment of the axon size, leading to a more precise determination of the nerve diameters.

In summary, the anatomy of the lumbosacral trunk beneath the sacrum cannot fully explain the plantigrade posture observed in cats with partial sciatic nerve lesions. Muscular and biomechanical factors might explain this posture but further biomechanical and neurophysiological studies are needed to confirm or refute this supposition.

The typical plantigrade gait observed in cats after iatrogenic sciatic injury is also commonly observed in association with other neurological conditions, such as diabetic neuropathy, myopathies, and lesions within the lumbosacral intumescence (Johnson *et al.*, 1983; Katherman and Braund, 1983; Anderson *et al.*, 1983; Misselbrook, 1987; Mizisin *et al.*, 2007; Morgan *et al.*, 2008; Nghiem *et al.*, 2009).

## REFERENCES

- Anderson PG, KG Braund, and AR Dillon, 1983. Polyneuropathy and hormone profiles in a chow puppy with hypoplasia of the islets of langerhans. *Vet Pathol*, 23: 28-531.
- Ariano MA, RB Armstrong, and VR Edgerton, 1973. Hindlimb muscle fiber populations of five mammals. *J Histochem Cytochem*, 21: 51-55.

- Armstrong RB, CW Saubert, and HJ Seeherman, 1982. Distribution of fiber types of locomotory muscles of dogs. *Am J Anat*, 163: 87-98.
- Bennett D, 1976. An anatomical and histological study of the sciatic nerve relating to peripheral nerve injuries in the dog and the cat. *J Small Anim Pract*, 17: 379-386.
- Budras KD, PH McCarthy, A Horowitz, 2007. Pelvic Diaphragm, Ischiorectal Fossa; Associated Arteries, Veins and Nerves In: Budras K-D, editor. *Anatomy of the Dog*. 5<sup>th</sup> ed. Hannover, Germany: Schlütersche Verlagsgesellschaft mbH & Co KG, pp: 72-75.
- Burke RE, DN Levine, M Salzman, and P Tsairis, 1974. Motor units in cat soleus muscle: physiological, histochemical and morphological characteristics. *J Physiol*, 238: 503-514.
- De Lahunta A, and EN Glass, 2009. Lower Motor Neuron In: De Lahunta A, editor. *Veterinary Neuroanatomy and Clinical Neurology*. 3rd ed. St.Louis, Missouri: Saunders Elsevier, pp: 77-124.
- Evans HE and A De Lahunta 2013. Spinal nerves In: *Miller's Anatomy of the Dog*. 4th ed. St. Louis, Missouri: Saunders Elsevier, pp: 650-52.
- Forterre F, A Tomek, U Rytz, L Brunnberg, A Jaggy, D Spreng, 2007. Iatrogenic sciatic nerve injury in eighteen dogs and nine cats. *Vet Surg*, 36: 464-471.
- Johnson CA, MD Kittleson, and RJ Indrier 1983. Peripheral neuropathy and hypotension in a diabetic dog. *J Am Vet Med Assoc*, 183: 1007-1009.
- Katherman AE, and KG Braund, 1983. Polyneuropathy associated with diabetes mellitus in a dog. *J Am Vet Med Assoc*, 182: 522-524.
- Kaya M, TR Leonard, and W Herzog 2006. Control of ground reaction forces by hindlimb muscles during cat locomotion. *J Biomech*, 39: 2752-2766.
- Mahler SP, and AO Adogwa 2008. Anatomical and experimental studies of brachial plexus, sciatic, and femoral nerve-location using peripheral nerve stimulation in the dog. *Vet Anaesth Analg*, 35: 80-89.
- Misselbrook NG, 1987. Peripheral neuropathy in diabetic bitch (short communication). *Vet Rec*, 121: 287.
- Mizisin AP, RW Nelson, BK Sturges, KM Vernau, RA Lecouteur, DC Williams, ML Burgers, and GD Shelton 2007. Comparable myelinated nerve pathology in the feline and human diabetes mellitus. *Acta Neuropathol*, 113: 431-442.
- Morgan MJ, VH Vite Charles, A Radhakrishnan, and RS Hess, 2008. Clinical peripheral neuropathy associated with diabetes mellitus in 3 dogs. *Can Vet J*, 49: 583-586.
- Nghiem PP, SR Platt, and S Schatzberg, 2009. The weak cat, Practical approach and common neurological differentials. *J Feline Med Surg*, 11: 373-383.