

WHAT'S NEW IN INTENSIVE CARE



Ten reasons for performing hemodynamic monitoring using transesophageal echocardiography

Philippe Vignon^{1,2,3*}, Tobias M. Merz⁴ and Antoine Vieillard-Baron^{5,6}

© 2017 Springer-Verlag Berlin Heidelberg and ESICM

Introduction

Echocardiography is increasingly used in the intensive care unit (ICU) as a diagnostic imaging modality and for discontinuous hemodynamic monitoring [1]. A recent large American data-based study reported that echocardiography may have a prognostic impact in different clinical fields, such as sepsis [2]. Critical care echocardiography mainly relies on surface examination, whereas transesophageal echocardiography (TEE) is markedly less frequently performed in most ICUs [3]. Nevertheless, TEE shares most of the key properties defining an “ideal” hemodynamic monitoring system [4]. We herein describe 10 good reasons for using TEE to monitor hemodynamics in unstable ventilated patients.

Reason 1: TEE provides a unique window to the heart and great vessels

Owing to the proximity of the high-frequency esophageal transducer and both the heart and great vessels, TEE provides a consistently higher image quality than transthoracic echocardiography (TTE) as it is not hampered by the numerous limitations of surface ultrasonography (e.g., obesity, emphysema, high PEEP levels, fluid overload, dressings, drains etc.). Accordingly, TEE is more accurate than TTE for the diagnosis of various acute conditions and has a higher therapeutic impact in ventilated ICU patients [5]. TEE is safe and well tolerated in ventilated patients as long as contraindications are scrupulously respected. It remains less invasive than other monitoring modalities which require deep vascular access.

Reason 2: TEE provides unparalleled information on the mechanism of circulatory failure

In specific clinical settings, TEE rapidly identifies the cause of shock. After open-heart surgery or severe chest trauma, TEE allows accurate and prompt diagnosis of loculated pericardial hematomas responsible for localized cardiac tamponade. In patients resuscitated after cardiac arrest, TEE may precisely depict a thrombus in transit or entrapped in the proximal pulmonary arteries which is consistent with a massive pulmonary embolism. In other clinical settings such as septic shock, TEE rapidly identifies the leading mechanism of associated circulatory failure, including sustained hypovolemia, vasoplegia, right or left ventricular systolic dysfunction [6]. TEE is ideally suited to accurately identify intricate and evolving mechanisms of circulatory compromise associated with septic shock [6].

Reason 3: TEE allows reproducible and sequential hemodynamic assessments

TEE may be used with two distinct approaches (Fig. 1). The first approach is quantitative and based on the measurement and calculation of conventional hemodynamic parameters, including left ventricular ejection fraction, stroke index, or collapsibility index of the superior vena cava (see video in the electronic supplementary material, ESM). Owing to high image quality, inter- and intra-observer reproducibility of measurements remains typically below 10%. The second approach is a qualitative estimation and grading of hemodynamic parameters. Accordingly, left ventricular systolic function may be graded as normal (and supra-normal), moderately depressed or severely depressed; respiratory variation of superior vena cava size may be graded as nil, moderate (partial inspiratory collapse), or marked (complete

*Correspondence: philippe.vignon@unilim.fr

¹ Medical-surgical Intensive Care Unit, University Hospital Dupuytren, Limoges, France

Full author information is available at the end of the article

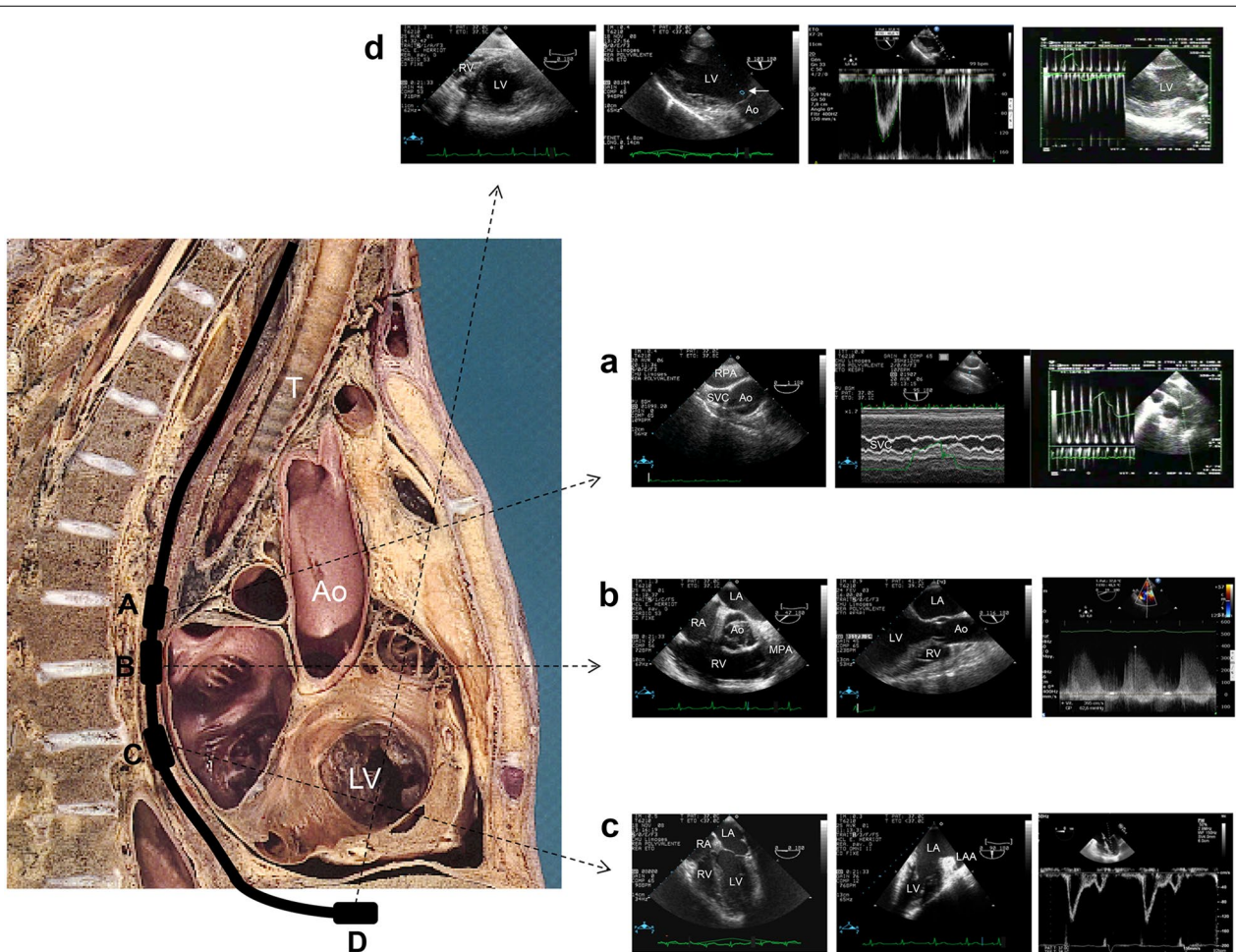


Fig. 1 Main transesophageal echocardiographic views used to assess hemodynamics in patients with cardiopulmonary compromise. The progression of the tip of the echocardiographic probe from the upper esophagus to the stomach is depicted. *A* Upper transesophageal view of the great vessels: respiratory variations of the superior vena cava in both the short axis (*left panel*) and long axis (M-mode, *middle panel*) of the vessel and Doppler profile within the main pulmonary artery (*right panel*) can be assessed. *B* Transesophageal 40° view depicts the aortic, tricuspid, and pulmonary valves as well as right cardiac cavities (*left panel*); Transesophageal 120° view depicts the left ventricular outflow tract and both aortic and mitral valves (*middle panel*); Tricuspid regurgitation can be quantified in the 20–60° view (*right panel*). *C* Transesophageal four-chamber view (*left panel*) and two-chamber view (*middle panel*): both right and left ventricular systolic function and size can be assessed, as well as mitral Doppler profile (*right panel*). *D* Transgastric views: the short axis view of the heart allows assessing left ventricular systolic function and interventricular septal motion (*left panel*); Transgastric long axis 110–120° view allows one to measure Doppler velocities in the left ventricular outflow tract (*middle left panel, arrow*), which time velocity integral reflects stroke volume (*middle right panel*), and to assess respiratory variations of maximal Doppler velocity as an index of fluid responsiveness (*right panel*). Ao aorta, LA left atrium, LAA left atrial appendage, LV left ventricle, RA right atrium, RPA right pulmonary artery, RV right ventricle, SVC superior vena cava, T trachea Anatomical picture adapted from Atlas Anatomique Sandoz

inspiratory collapse); right ventricular cavity may be qualified as normal or moderately or severely dilated. This qualitative approach has been shown to efficiently guide therapy in septic patients. The reproducibility of TEE measurements allows for the accurate monitoring of both the efficacy and tolerance of any therapeutic interventions. For example, the stroke index and the collapsibility index of the superior vena cava may be serially measured before and after a fluid challenge, and left

ventricular systolic function may be reassessed after the initiation of a vasopressor or an inotropic support.

Reason 4: TEE predicts fluid responsiveness

Among parameters which could predict fluid responsiveness in ventilated patients without respiratory effort, TEE provides an accurate assessment of respiratory variations of both the maximal Doppler velocity measured in the left ventricular outflow tract ($\Delta V_{\max Ao}$) and superior

vena cava diameter (Δ SVC). Whereas $\Delta V_{\max Ao}$ may also be obtained using TTE, Δ SVC requires TEE (see video in ESM). In 540 mechanically ventilated patients with shock of any origin, $\Delta V_{\max Ao}$ was the most sensitive parameter to predict fluid responsiveness whereas Δ SVC was the most specific dynamic index [7]. The authors suggest using distinct threshold values to optimize either the sensitivity or the specificity of TEE dynamic indices in accordance with the clinical context [7]. When compared to the Surviving Sepsis Campaign recommendations, TEE has been shown to identify septic shock patients with fluid responsiveness who were not accurately detected by the sole measurement of mean arterial pressure and central venous pressure [8].

Reason 5: TEE is best suited to quantitatively assess cardiac function

Echocardiography is the reference method for assessing cardiac function in patients presenting with cardiogenic shock [9]. Beyond its ability to accurately measure cardiac output, echocardiography provides unparalleled information on left ventricular systolic and diastolic function. TEE provides real-time monitoring of left ventricular function and depicts trends of quantitative indices under acute therapy, whether cardiac dysfunction is acute and reversible, such as septic cardiomyopathy [6], or not. When compared to the Surviving Sepsis Campaign recommendations, TEE identifies potentially severe left ventricular systolic dysfunction with high lactate, which is not accurately suspected on the basis of ScvO₂ monitoring in septic shock patients [8]. In addition, TEE has been shown to depict potential sources of inaccuracy of thermodilution-based hemodynamic monitoring (e.g., severe valvulopathy, left ventricular outflow tract obstruction, low flow states) in ventilated septic shock patients [10].

Reason 6: TEE is key to identifying right ventricular dysfunction at the origin of low flow states

In the absence of fluid responsiveness, “blind” thermodilution-based hemodynamic monitoring cannot ascribe a low cardiac output to either a left or right ventricular failure. TEE is the only hemodynamic monitoring which yields relevant information on right ventricular function and allows accurate diagnosis of acute cor pulmonale (ACP), its most severe presentation. TEE has a better performance than TTE in the diagnosis of ACP and clearly identifies false positive results of pulse pressure variation or of $\Delta V_{\max Ao}$ in ventilated patients with right ventricular dysfunction [11]. To help the front-line intensivist to screen high-risk patients undergoing protective ventilation for moderate-to-severe ARDS, a dedicated score has been validated with a value ≥ 2 indicating

a probability of underlying ACP $\geq 20\%$ [12]. Finally, TEE helps to guide ventilator strategy in ARDS patients, since positive-pressure ventilation may have additional detrimental effects on right ventricular function.

Reason 7: TEE is the only possibility to monitor hemodynamic status in the context of the use of extracorporeal membrane oxygenation

In patients with intractable circulatory failure, TEE allows a comprehensive examination of cardiac function and anatomy prior to the implantation of extracorporeal membrane oxygenation (ECMO). In this specific clinical setting, the precise assessment of dimension and function of both ventricles, and accurate quantification of pre-existing left-sided valvular insufficiency, which can be worsened by ECMO, are crucial. In patients with intractable acute respiratory failure, TEE helps in the choice between veno-venous and veno-arterial ECMO according to the severity of right ventricular failure. Insertion of guide wires and ECMO cannulae under direct TEE guidance allows for the optimal positioning for maximal venous drainage and is a safer procedure to avoid potential injuries to cardiac structures. Monitoring of hemodynamic status using thermodilution-based monitoring systems is inaccurate in patients undergoing veno-arterial ECMO since the pulmonary circulation is partially bypassed and aortic pulsatility is attenuated. Regular TEE examinations are required to monitor cardiac performance under ECMO, identify potential mechanical complications of the circulatory assistance, and to best guide ECMO weaning.

Reason 8: TEE is quicker and easier to initiate than other monitoring modalities, and less operator-dependent than TTE

TEE can be performed in less than 15 min and is the recommended monitoring modality for assessing circulatory shock, as opposed to more invasive monitoring systems requiring time-consuming insertion [1]. Competence in TEE to assess central hemodynamics can be reached after approximately 35 examinations, whereas a minimum of 100 studies is required to master advanced level TTE [13]. Critical care societies recommend that critical care echocardiography be included in the training of ICU physicians and competency standards have been thoroughly defined [13].

Reason 9: Miniaturized TEE probes allow prolonged hemodynamic monitoring

The recently developed miniaturized TEE probes can be left inserted in the esophagus for a prolonged period without relevant side effects. When compared to conventional TEE in ventilated patients who were

hemodynamically assessed for a cardiopulmonary compromise, a miniaturized multiplane TEE probe has been shown to provide similar information, despite a substantially lower imaging quality [14]. Similarly, a miniaturized monoplane, single-use TEE probe has been successfully tested for prolonged (72 h) hemodynamic monitoring in unstable ventilated patients [15]. A qualitative approach for assessment of central hemodynamics using such miniaturized TEE probes promises to allow for almost continuous hemodynamic monitoring in the most unstable ICU patients.

Reason 10: TEE potentially improves ICU performance

Introduction of a TEE program in an ICU has to be accompanied by adequate training, case discussions, and quality management initiatives. Accordingly, it offers a unique teaching opportunity for doctors in training and nurses. Establishing close interactions with the cardiology, cardiac surgery, and cardiac anesthesia departments allows beneficial cooperation and improves the acute management of these severely ill patients. The implementation of TEE in the ICU results in a deeper knowledge and understanding of circulatory failure pathophysiology, thus potentially improving decision-making. The startup costs for a TEE program are limited to the cost of the ultrasound system and the resources for training of dedicated operators. This is compensated by low maintenance costs and negligible cost of disposables, resulting in a low net cost per patient. However, clinical studies on the impact on prognosis of systematic TEE use in hemodynamically unstable patients are still lacking.

Electronic supplementary material

The online version of this article (doi:[10.1007/s00134-017-4716-1](https://doi.org/10.1007/s00134-017-4716-1)) contains supplementary material, which is available to authorized users.

Author details

¹ Medical-surgical Intensive Care Unit, University Hospital Dupuytren, Limoges, France. ² INSERM CIC 1435, University Hospital Dupuytren, Limoges, France. ³ University of Limoges, Limoges, France. ⁴ Department of Intensive Care Medicine, Bern University Hospital, University of Bern, Bern, Switzerland. ⁵ Medical-surgical Intensive Care Unit, University Hospital Ambroise Paré, Assistance Publique-Hôpitaux de Paris, Boulogne-Billancourt, France. ⁶ INSERM U-1018, CESP, Team 5, University of Versailles Saint-Quentin en Yvelines, Villejuif, France.

Compliance with ethical standards

Conflicts of interest

On behalf of all authors, the corresponding author states that there is no conflict of interest.

Received: 3 February 2017 Accepted: 6 February 2017

Published online: 17 February 2017

References

1. Cecconi M, De Backer D, Antonelli M, Beale R, Bakker J, Hofer C, Jaeschke R, Mebazaa A, Pinsky MR, Teboul JL, Vincent JL, Rhodes A (2014) Consensus on circulatory shock and hemodynamic monitoring. Task force of the European Society of Intensive Care Medicine. *Intensive Care Med* 40:1795–1815
2. Papolos A, Narula J, Bavishi C, Chaudhry FA, Sengupta PP (2016) US hospital use of echocardiography: insights from the Nationwide Inpatient Sample. *J Am Coll Cardiol* 67(5):502–511
3. Zielekiewicz L, Muller L, Lakhali K, Meresse Z, Arbelot C, Bertrand PM, Bouhemad B, Chollet B, Demory D, Duperret S, Duranteau J, Guerville C, Hammad E, Ichai C, Jaber S, Langeron O, Lefrant JY, Mahjoub Y, Maury E, Meaudre E, Michel F, Muller M, Nafati C, Perbet S, Quintard H, Riu B, Vigne C, Chaumoitre K, Antonini F, Allaouchiche B, Martin C, Constantin JM, De Backer D, Leone M, CAR'Echo and AzuRea Collaborative Networks (2015) Point-of-care ultrasound in intensive care units: assessment of 1073 procedures in a multicentric, prospective, observational study. *Intensive Care Med* 41(9):1638–1647
4. Vincent JL, Rhodes A, Perel A, Martin GS, Della Rocca G, Vallet B, Pinsky MR, Hofer CK, Teboul JL, de Boode WP, Scolletta S, Vieillard-Baron A, De Backer D, Walley KR, Maggiorini M, Singer M (2011) Clinical review: update on hemodynamic monitoring: a consensus of 16. *Crit Care* 15(4):229
5. Vignon P, Mentec H, Terré S, Gastinne H, Guéret P, Lemaire F (1994) Diagnostic accuracy and therapeutic impact of transthoracic and transesophageal echocardiography in mechanically ventilated patients in the ICU. *Chest* 106(6):1829–1834
6. Aneman A, Vieillard-Baron A (2016) Cardiac dysfunction in sepsis. *Intensive Care Med* 42(12):2073–2076
7. Vignon P, Repessé X, Bégot E, Léger J, Jacob C, Bouferrache K, Slama M, Prat G, Vieillard-Baron A (2016) Comparison of echocardiographic indices used to predict fluid responsiveness in ventilated patients. *Am J Respir Crit Care Med*. doi:[10.1164/rccm.201604-0844OC](https://doi.org/10.1164/rccm.201604-0844OC)
8. Bouferrache K, Amiel JB, Chimot L, Caille V, Charron C, Vignon P, Vieillard-Baron A (2012) Initial resuscitation guided by the Surviving Sepsis Campaign recommendations and early echocardiographic assessment of hemodynamics in intensive care unit septic patients: a pilot study. *Crit Care Med* 40(10):2821–2827
9. Mebazaa A, Tolppanen H, Mueller C, Lassus J, DiSomma S, Baksyte G, Cecconi M, Choi DJ, Cohen Solal A, Christ M, Masip J, Arrigo M, Noura S, Ojji D, Peacock F, Richards M, Sato N, Sliwa K, Spinar J, Thiele H, Yilmaz MB, Januzzi J (2016) Acute heart failure and cardiogenic shock: a multidisciplinary practical guidance. *Intensive Care Med* 42(2):147–163
10. Riu-Poulenc B, Begot E, Mari A, Clavel M, Chimot L, Delour P, Vargas F, Filloux B, Vandroux D, Jabot J, Silva S, Genestal M, François B, Pichon N, Vignon P (2014) Agreement of therapeutic proposals derived from early hemodynamic assessment using transpulmonary thermodilution and transesophageal echocardiography in septic shock patients. *Intensive Care Med* 40(Suppl 1):S209
11. Vieillard-Baron A, Matthay M, Teboul JL, Bein T, Schultz M, Magder S, Marini JJ (2016) Experts' opinion on management of hemodynamics in ARDS patients: focus on the effects of mechanical ventilation. *Intensive Care Med* 42(5):739–749
12. Mekontso Dessap A, Boissier F, Charron C, Bégot E, Repessé X, Legras A, Brun-Buisson C, Vignon P, Vieillard-Baron A (2016) Acute cor pulmonale during protective ventilation for acute respiratory distress syndrome: prevalence, predictors, and clinical impact. *Intensive Care Med* 42(5):862–870
13. Expert Round Table on Echocardiography in ICU (2014) International consensus statement on training standards for advanced critical care echocardiography. *Intensive Care Med* 40(5):654–666
14. Begot E, Dalmay F, Etchecopar C, Clavel M, Pichon N, Francois B, Lang R, Vignon P (2015) Hemodynamic assessment of ventilated ICU patients with cardiorespiratory failure using a miniaturized multiplane transesophageal echocardiography probe. *Intensive Care Med* 41(11):1886–1894
15. Vieillard-Baron A, Slama M, Mayo P, Charron C, Amiel JB, Esterez C, Leleu F, Repesse X, Vignon P (2013) A pilot study on safety and clinical utility of a single-use 72-hour indwelling transesophageal echocardiography probe. *Intensive Care Med* 39(4):629–635