

## CASE REPORT

## Pyogenic granuloma in the jejunum successfully removed by single-balloon enteroscopy

Cristina Romero-Mascarell<sup>1</sup>, Juan Carlos García-Pagán<sup>2</sup>, Isis Karina Araujo<sup>1</sup>, Josep Llach<sup>1</sup> and Begoña González-Suárez<sup>1</sup>

<sup>1</sup>Endoscopy Unit. Gastroenterology Department. ICMDiM. Hospital Clínic. Barcelona, Spain. <sup>2</sup>Barcelona Hepatic Hemodynamic Laboratory. Liver Unit. ICDM Hospital Clinic-IDIBAPS and CIBERehd. University of Barcelona. Barcelona, Spain

### ABSTRACT

Pyogenic granuloma is a non-infectious and non-granulomatous lesion. Its location in the small bowel is very rare. We present a 46 year-old woman with a chronic liver disorder that had a severe chronic anemia with occult blood losses. Upper endoscopy and colonoscopy were normal. A small bowel capsule endoscopy showed a pyogenic granuloma in jejunum that was resected endoscopically with single balloon enteroscopy with no major complications. The patient recovered from anemia and six months latter capsule endoscopy did not show lesions.

**Key words:** Anemia. Capsule endoscopy. Enteroscopy. Pyogenic granuloma.

### INTRODUCTION

Pyogenic granuloma (PG) is a common inflammatory vascular tumor that typically affects the skin, appearing occasionally in the oral cavity mucosa. It very rarely appears in the gastrointestinal tract. We report a case of PG in the jejunum in a young patient with obscure gastrointestinal bleeding (OGIB). It was diagnosed by small bowel capsule endoscopy (SBCE) and treated, successfully, by single balloon enteroscopy (SBE).

### CASE REPORT

We present a 46-year-old woman with chronic hepatitis C and AIDS infection diagnosed at 17 years of age. Antiviral treatment was initiated in 2006 obtaining negative HCV RNA.

Since 2007, she presented iron deficiency anemia requiring blood transfusion and endovenous iron therapy. Upper endoscopy showed small esophageal varices and portal hypertensive gastropathy. Colonoscopy was normal. Imaging studies evidenced the presence of a chronic liver disorder with portal hypertension.

In 2012, she suffered a severe gastrointestinal bleeding due to esophageal varices requiring transjugular intrahepatic portosystemic shunt (TIPS) placement. Despite TIPS patency and an adequate reduction in portal pressure below the threshold value of 12 mmHg, the patient developed severe anemia in May 2014. Upper and lower endoscopies were negative. SBCE was performed, and it revealed an image lesion with an adhered clot and active bleeding.

A SBE was performed, showing a sessile tumor of about 15 mm diameter in mild jejunum, with violet coloration and ulcerated surface (Fig. 1). Near the lesion, an ink tattoo had been performed and biopsies were taken. Histological examination reported granulation tissue and blood material, underrepresented surface glandular epithelium, and no histological evidence of malignancy.

A second SBE was performed for mucosectomy. After submucosal injection with saline solution plus adrenaline and indigo carmine a minor bleeding happened; it was controlled by new adrenaline injection. Mucosectomy with polypectomy snare was finally successfully performed (Fig. 2).

Histological examination reported a granulation tissue suggestive of PG without evidence of malignancy. Immunohistochemistry for detection of HV8 was negative in order to rule out Kaposi sarcoma.

After endoscopic treatment, the patient improved from anemia. Six months later a control with SBCE was done, showing the ink tattoo in mild jejunum with no residual lesions (Fig. 3).

### DISCUSSION

PG is a non-infectious and non-granulomatous lesion. It is a lobular capillary hemangioma that mostly occurs on the skin or on the mucosal surface of the oral cavity. PG

Received: 15-12-2015  
Accepted: 24-02-2016

Correspondence: Begoña González-Suárez. Endoscopy Unit. Gastroenterology Department. Hospital Clínic de Barcelona. Villarroel, 170. 08036 Barcelona, Spain  
e-mail: bgonzals@clinic.ub.es

Romero-Mascarell C, García-Pagán JC, Araujo IK, Llach J, González-Suárez B. Pyogenic granuloma in the jejunum successfully removed by single-balloon enteroscopy. *Rev Esp Enferm Dig* 2017;109(2):152-154.

DOI: 10.17235/reed.2016.4153/2015

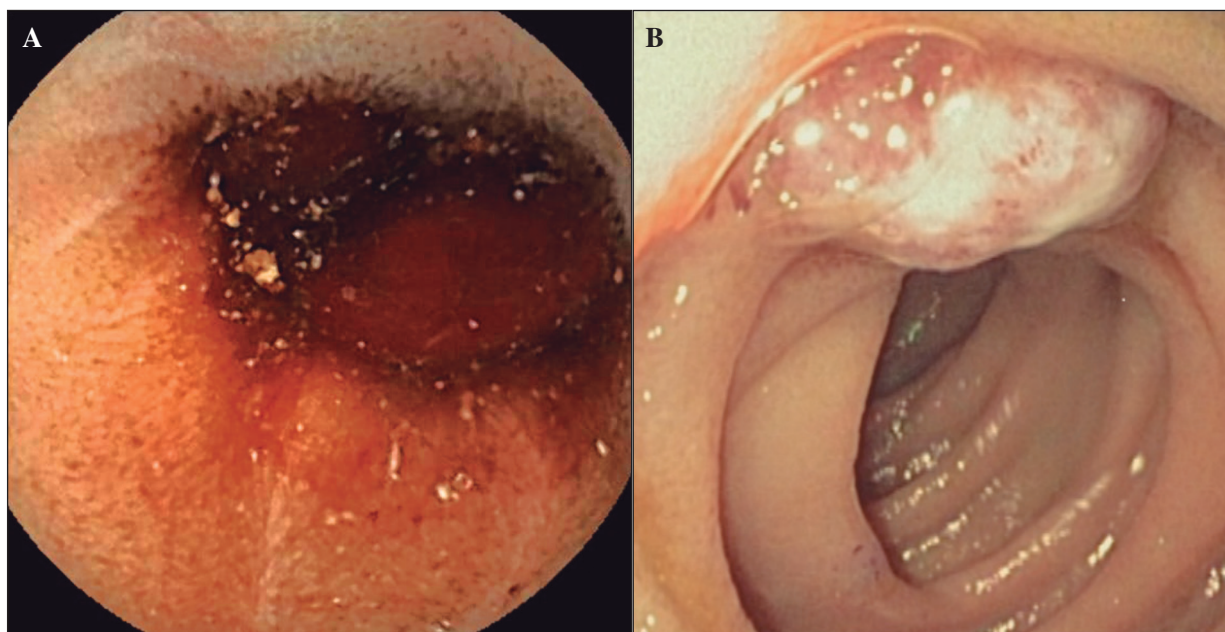


Fig. 1. A. Adhered clot in jejunum visualized with capsule endoscopy. B. Pyogenic granuloma with single balloon enteroscopy.

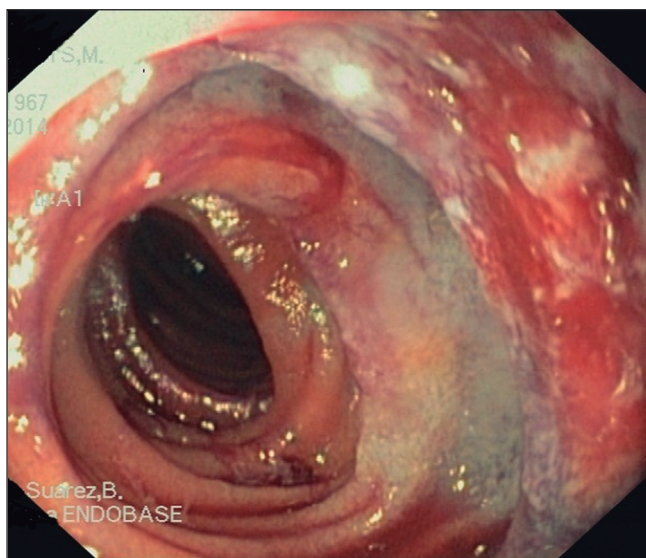


Fig. 2. After snare mucosectomy.

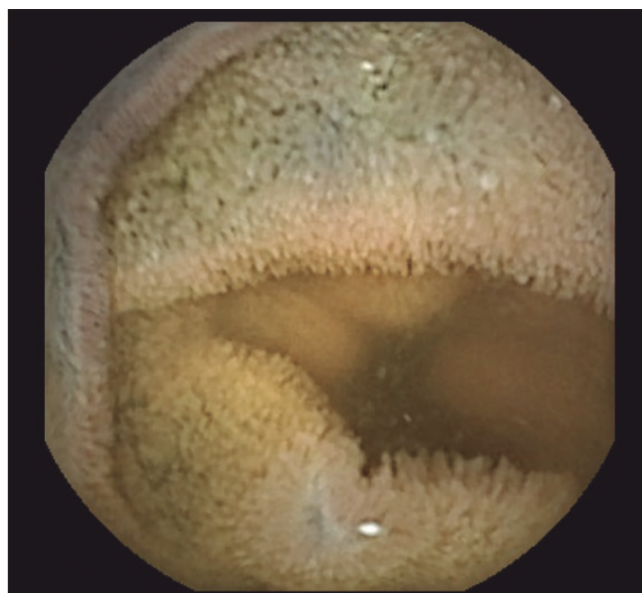


Fig. 3. Follow up with capsule endoscopy six months later. Ink tattoo without residual lesion.

in the small bowel (SB) is generally described as a red, polypoid mass, friable and of apparent granulation tissue that bleeds easily (1).

In the GI tract, it must be distinguished from the Kaposi sarcoma. The pathological features of PG include proliferation and lobular arrangement of capillary sized vessels with inflamed and edematous stroma and endothelial cell swelling. It is frequently accompanied by ulceration on its surface and granulation with infiltration of inflamma-

tory cells, including neutrophils. It is originated from the mucosa or submucosa only (1,2).

The etiology of PG is not clear, but it is a benign lesion. It is considered that a damaged dense part of an arteriovenous anastomosis could develop capillary proliferation as a reaction to injury (2).

Its location in the SB is rare but must be considered as a rare cause of obscure gastrointestinal bleeding. Few cases can be found in the literature. Surgical (3-5), endoscopic

resection (1,2,6-9), angiographic embolization and laser ablation have been described (10). In our knowledge, this is the first case that has been reported and treated with SBE.

Endoscopic resection is relatively easy and safe for small size PG of the SB. It is necessary to remove the lesion endoscopically, including arteriovenous anastomosis under tumor, because incomplete resection might cause recurrence. After resection it is difficult to identify this part under the submucosal layer. Surveillance is necessary, but the prognosis of PG is good. There are no reports of malignant changes so far (2).

Mucosectomy in SB has been previously described with DBE but no with SBE. Indications may be benign tumors regardless of the epithelial or subepithelial type, localizing in the mucosal layer, which are symptomatic. Submucosal injection before mucosectomy is recommended to avoid complications (bleeding, perforation, and abdominal pain) because the SB wall is very thin. It is not a difficult technique and can help us in different situations, namely Peutz-Jeghers syndrome, which is the most frequent cause of SB tumors. In our patient complete resection was not performed during the first SBE in order to rule out malignancy (11).

In conclusion, PG is a rare cause of OGIB and it should be considered in the differential diagnosis of these patients. Surgical treatment could be an option, but endoscopic resection is safer and more useful.

## REFERENCES

1. Shirakawa K, Nakamura T, Endo M, et al. Pyogenic granuloma of the small intestine. *Gastrointest Endosc* 2007;66:827-8. DOI: 10.1016/j.gie.2007.04.018
2. Nagoya H, Tanaka S, Tatsuguchi A, et al. Rare cause of obscure gastrointestinal bleeding due to pyogenic granuloma in the ileum detected by capsule endoscopy. *Dig Endosc* 2010;22:71-3. DOI: 10.1111/j.1443-1661.2009.00928.x
3. Kikuchi A, Sujino T, Yamaoka M, et al. Pyogenic granuloma of the ileum diagnosed by double-balloon enteroscopy. *Intern Med* 2014;53:2057-9. DOI: 10.2169/internalmedicine.53.2468
4. Yamashita K, Arimura Y, Saito M, et al. Pyogenic granuloma of the small bowel. *Endoscopy* 2013;45(Suppl. 2). DOI: 10.1055/s-0032-1326119
5. Egea Valenzuela J, Alajarín M, Hernández Q, et al. Gastrointestinal bleeding due to a small bowel pyogenic granuloma. *Gastroenterol Hepatol* 2014;37:384-5. DOI: 10.1016/j.gastrohep.2013.11.005
6. Mizutani Y, Hirooka Y, Watanabe O, et al. Pyogenic granuloma of the small bowel treated by double-balloon enteroscopy. *Gastrointest Endosc* 2015;81:1023-4. DOI: 10.1016/j.gie.2014.11.005
7. Hirakawa K, Aoyagi K, Yao T, et al. A case of pyogenic granuloma in the duodenum: Successful treatment by endoscopic snare polypectomy. *Gastrointest Endosc* 1998;47:538-40. DOI: 10.1016/S0016-5107(98)70260-3
8. Kuga R, Furuya CK, Fylyk SN, et al. Solitary pyogenic granuloma of the small bowel as the cause of obscure gastrointestinal bleeding. *Endoscopy* 2009;41(Suppl. 2):E76-7. DOI: 10.1055/s-0029-1214428
9. Kawasaki K, Kurahara K, Matsumoto T. Pyogenic granuloma of the ileum depicted by small-bowel radiography, capsule endoscopy and double balloon enteroscopy. *Dig Liver Dis* 2015;47:436. DOI: 10.1016/j.dld.2014.11.014
10. Kusakabe A, Kato H, Hayashi K, et al. Pyogenic granuloma of the stomach successfully treated by endoscopic resection after transarterial embolization of the feeding artery. *J Gastroenterol* 2005;40:530-5. DOI: 10.1007/s00535-004-1579-3
11. Ohmiya N, Nakamura M, Tahara T, et al. Management of small-bowel polyps at double-balloon enteroscopy. *Ann Transl Med* 2014;2:30.