

Swallowing Physiology after Anterior and Posterior Cervical Spine Surgery: A Comparison on Videofluoroscopy Pre- and Post-surgery

Stefanie Duchac^{1,*}, Martina Hielscher-Fastabend², Horst M. Müller³, Christina Aere⁴,
Beate Schumann⁵, Michael Ruf⁶, Tobias Pitzen⁶

¹Department of Speech and Language Therapy, SRH Hospital Karlsbad, Karlsbad, Germany

²Faculty of Linguistics and Literary Studies, Clinical Linguistics, Bielefeld University, Bielefeld, Germany

³Faculty of Linguistics and Literary Studies, Neurolinguistics, Bielefeld University, Bielefeld, Germany

⁴Dysphagia Centre Bruchsal, Fürst Stirum Klinik, Bruchsal, Germany

⁵Department of Neurology, RWTH Aachen University Hospital, Aachen, Germany

⁶Center for Spinal Surgery, Orthopaedics, Traumatology, Department of Spine Surgery, SRH Hospital Karlsbad, Karlsbad, Germany

Copyright©2017 by authors, all rights reserved. Authors agree that this article remains permanently open access under the terms of the Creative Commons Attribution License 4.0 International License

Abstract Dysphagia is a common complication following anterior cervical spine surgery and may occur in over 70% of patients. There is an emerging evidence that dysphagia also appears after posterior cervical spine surgery. Nevertheless, hardly any study is focusing on changes in swallowing physiology with regard to surgical approach. **Aim of this study:** To investigate changes in swallowing physiology following: 1. anterior cervical spine surgery, and 2. posterior cervical spine surgery. **Methods:** A standardized videofluoroscopic swallowing study (VFSS) was performed in 28 patients who underwent cervical spine surgery (anterior approach $n = 19$, $M_{age} 56 \pm 14$; posterior approach $n = 9$, $M_{age} 58 \pm 17$) one day before surgery and after surgery (mean 4 days). Data were analyzed retrospectively with the Modified Barium Swallow Impairment Profile (MBSImPTM). **Results:** 1. In the anterior group, pharyngeal sum score was significantly higher after surgery ($p < .001$). Significant changes were found in 4 out of 8 analyzed pharyngeal components. 2. In the posterior group, pharyngeal sum score was significantly higher after surgery ($p = .015$). No significant changes were found in the oral or pharyngeal components. **Conclusions:** Whereas more changes in swallowing physiology occurred following anterior surgery, there were also overall changes in the posterior group. Understanding the swallowing pathophysiology associated with cervical spine surgery is indispensable to decrease the rate of secondary complications and improve quality of life for this patients.

Keywords Anterior Cervical Spine Surgery, Posterior Cervical Spine Surgery, Swallowing Physiology, Videofluoroscopic Swallowing Study

1. Introduction

Dysphagia is a common complication following anterior cervical spine surgery. It may occur in over 70% of patients having undergone anterior cervical spine procedures [1-8]. Even so, not only patients having undergone anterior cervical spine surgery incur swallowing problems. Recently, it has been determined that dysphagia is also observed following posterior cervical spine surgery [9-11]. Mechanical aspects such as esophagus or soft tissue retraction, postoperative swelling or hematoma, however, can be excluded as causes for dysphagia in posterior surgical patients. The role that alternative mechanisms, neurogenic or other, play in dysphagia following posterior cervical spine surgery, however, is not yet clear. Etiology aside, the importance of swallowing physiology changes post-operatively in both anterior and posterior surgical approaches should not be overlooked.

Swallowing as a complex process involves several different anatomical oral (e.g., tongue), pharyngeal (e.g., hyolaryngeal complex, pharyngoesophageal segment) and esophageal structures. Pharynx, hyoid and larynx act together in a highly defined timing of sequential events, allowing food to travel securely from the mouth to the stomach. Dysphagia may be described as an interruption of this complex process, which can lead to e.g. pharyngeal residue (see Figure 1) or penetration/aspiration [12].

Currently, there is no standardized definition for dysphagia following anterior cervical spine surgery, which could contribute to the wide variety, from 2% to over 70%, of reported incidence [1,3-7,13,14,15]. The high incidence of over 70% occurs within the first two weeks after surgery, but gradually decreases during the following months. However,

12% to 14% of patients may experience persistent dysphagia one year after surgery [9]. Despite its common appearance, dysphagia is still a poorly understood and underestimated complication of cervical spine surgery. This could be due to the use of exclusively subjective methods such as questionnaires or interviews in several investigations [6,10,16,17], which otherwise have been shown to be neither valid nor reliable [9]. Use of objective measures such as Videofluoroscopic Swallowing Studies (VFSS) or the Fiberoptic Endoscopic Evaluation of Swallowing (FEES) are used in only few studies [2,7,8,9]. Furthermore, only one of these studies conducted a pre-post comparison [9].

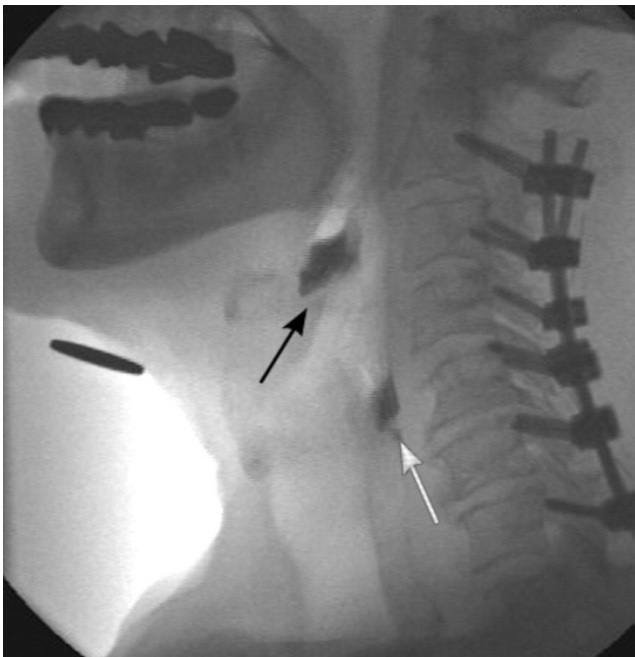


Figure 1. Pharyngeal residue within the valleculae (black arrow) and the piriform sinuses (white arrow) after posterior cervical spine surgery

Additionally, there has been a sparsity of investigations into the biomechanics of swallowing. Few studies have examined the components of swallowing physiology following anterior cervical spine surgery outside of residue scores or penetration/aspiration status [2,8]. Some of the studies were based on retrospective analysis of medical reports, which were shown to underrepresent dysphagia [18] and could not be compared with preoperative swallowing physiology [1-5, 8]. In order to provide patients with the correct swallowing techniques or diet modifications that enable swallowing safety and quicken recovery, it is necessary to understand the underlying pathophysiology [12].

The aim of this study was to investigate changes in swallowing physiology following anterior and posterior cervical spine surgery.

Research questions:

1. Does anterior cervical spine surgery cause changes in swallowing physiology?
2. Does posterior cervical spine surgery cause changes in swallowing physiology?

2. Materials and Methods

This study was performed with approval from the ethical review committee from the Faculty of Medicine at the University of Heidelberg, Germany. To improve care for patients who received cervical spine surgery procedures, a standard operating procedure (SOP) was implemented [19].

During one year period, 97 patients' data-sets were collected within the SOP project. Fifty-five data sets were excluded due to either non-existing pre- and/or post-surgical instrumental swallowing examination or other exclusion criteria including anterior osteophytes, pre-existing dysphagia or other neurologic disorders. A total of 28 patients remained for data analysis in the current study (Figure 2, Table 1).

All surgeries were performed by the same experienced team of surgeons.

Swallowing physiology was investigated by performing a Videofluoroscopic Swallowing Study (VFSS), a radiographic evaluation of swallowing function, before and after surgery.

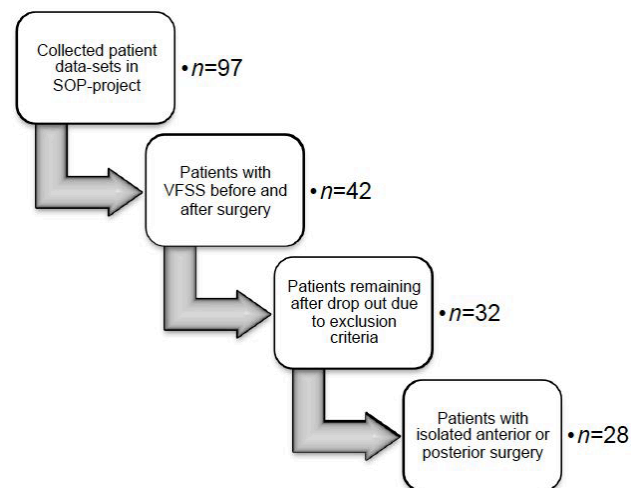


Figure 2. Drop out of patients due to exclusion criteria

2.1. Videofluoroscopic Swallowing Study (VFSS)

All Videofluoroscopic Swallowing Studies were executed using the x-ray apparatus AXIOM-Artis (Co. Siemens AG, Erlangen, Germany). The pulsed radiation dose of the x-ray tube was 30 frames/second (fps). Conversion into 25 fps was carried out directly by the AXIOM-Artis-processor, to provide real-time digital video material for further processing in PAL (Phase Alternating Line) Standard. For data transfer, archival storage, as well as data analysis, the software program rpScene 9.3b, ©2006-2013 (Co. Rehder/Partner GmbH, Hamburg, Germany) was used [20]. A standardized procedure for VFSS was implemented and included the following: 1 teaspoon (5ml) liquid, 1 patient sized cup sip, 1 teaspoon (5ml) purée (Humana™ apple purée mixed with a contrast medium), and 1 patient sized bite of barium-bread. Visipaque 270 was used as the contrast medium for liquid and semi-liquid consistencies.

Table 1. Demographic data of all included patients

Pat Code	sex	Age (Years)	Diagnosis	Surgery
CS01	f	72	Cervical spinal canal stenosis	Anterior fusion C3-5
CS02	f	33	Disc prolapse C5/C6	Anterior fusion C5/6
CS03	m	80	Z Cervical spinal canal stenosis	Anterior corpectomy C4
CS04	m	51	Spondylodesis C3-C7; Foramen stenosis C5-7; cervical myelopathy C3/4, cervical spinal canal stenosis C3/4,	Posterior decompression C5-C6
CS05	m	54	Traumatic Ruptur of anterior longitudinal ligament C6/7	Anterior Fusion C6/7
CS06	f	70	Posttraumatic cervical myelopathy cervical spinal canal stenosis C5-7	Posterior decompression C5/6, Instrumentation C4-C7
CS07	f	73	Pannus C1/2	Posterior decompression C1-2, foraminotomy C3
CS08	f	24	Spondyloepiphyseal dysplasia; Instability of C1/2; myelopathy	Posterior instrumentation C0-C3
CS09	f	39	Disc prolaps C5/6	Anterior fusion C5-C7
CS10	m	72	Cervical myelopathy	ACDF C3/4, Resection C6
CS11	m	53	Multisegmental degenerative structural changes C4-C6	Anterior fusion C4-C6
CS12	m	79	Neuroforaminal stenosis C3/4	ACDF C3/4
CS13	f	75	Severe degenerative structural changes of subaxial CS with Instability	Anterior corpectomy C5, C6
CS14	f	57	Cervical myelopathy	ACDF C5/6, 6/7
CS15	f	46	Pain C6, C7; cervical reticulomyelopathy before surgery; spondylosis C5/C6, Disc prolapse C7/Th1	ACDF C5/6, 6/7
CS16	f	45	Pseudoarthrosis C6/7 (after external fusion C6/7) o.s.Apnea due to opiate overdose	ACDF C6/7
CS17	m	58	Multisegmental Osteochondrosis C3-7	ACDF C5-7
CS18	m	49	Fraktures of des articular process and lamina C7	Anterior fusion C7/T1
CS19	f	71	Atlantodental instability; rheumatoid arthritis	Posterior stabilization C0-C3
CS20	m	52	Cervical myelopathy	Anterior corpectomy C5
CS21	m	56	Pseudoarthrosis	Posterior decompression and instrumentation C3-7
CS22	m	73	Cervical myelopathy next to multisegmental cervical stenosis	Posterior decompression and instrumentation C3-7
CS23	m	75	Cervical myelopathy next to multisegmental cervical stenosis	Posterior decompression and instrumentation C3/4, instrumentation C2-4
CS24	f	38	Cervical stenosis C5/C6	ACDF C5/6
CS25	f	73	Multisegmental osteochondrosis, uncarthrosis C3-C6	Posterior decompression C2-7; Lamiectomy C3-6
CS26	f	65	Cervical myelopathy next to osteochondrosis with stenosis C6/7	ACDF C6/7
CS27	m	46	Advanced osteochondrosis C5/C6 with retrospondylosis and uncovertebralarthrosis	ACDF C5/6
CS28	m	55	Cervical stenosis C5/C6	ACDF C5/6

2.1. Patient Procedure

Patients were seated upright in front of the c-arm x-ray apparatus in a lateral position. VFSS was operated as a tandem examination by a speech and language therapist and a radiologist as recommended in the literature [12]. The speech and language therapist asked each patient to swallow on command (i.e., cued swallow), in order to reduce radiation exposure and minimize radiation time. In addition, the request to hold the bolus in the mouth prior to being asked to swallow, allowed the speech therapist to gain valuable information about patients' volitional ability to hold

the bolus in the oral cavity and judge the effectiveness of relevant swallowing techniques in case of impairment [21]. Each consistency was tested once.

2.2. Data Analysis

All data were analyzed retrospectively using the Modified Barium Swallow Impairment Profile (MBSImP™) by a certified MBSImP™ speech and language therapist. The MBSImP™ demonstrates clinical practicality, favorable inter- and intrater reliability following standardized training, content, and external validity [22]. It is an ordinal

based tool, in which every component is judged using a 3 to 5 point scale; a score of 0 represents no impairment with every increasing score representing a greater degree of impairment.

2.3. Swallowing Components

Potential at-risk structures involved in swallowing that could be affected during surgery are the hypoglossal, recurrent, and superior laryngeal nerves [23], as well as the ansa cervicalis and pharyngeal plexus. In addition, due to mechanical exposure during surgery the aero-digestive tracts, as well as prevertebral areas, are vulnerable regions (Table 2). The following MBSImP™ swallowing components which are associated with these structures were identified as potential at-risk components and included in the data analysis:

To assess the oral domain, tongue control, mastication (for solid bolus), bolus transport, oral residue and initiation of the pharyngeal swallow were analyzed. The pharyngeal domain included laryngeal elevation, anterior hyoid excursion, epiglottic movement, laryngeal vestibular closure, pharyngeal stripping wave, pharyngoesophageal segment (PES) opening, tongue base retraction, and pharyngeal residue [21]. In addition, the Penetration-Aspiration Scale (PAS) was scored, to determine if and how far bolus material enters the airway [24].

2.4. Statistical Analysis

2.4.1. Pharyngeal Sum Score

To obtain an overall impression of changes in pharyngeal swallow performance, a summarized pharyngeal sum score

was calculated. This included the addition of all MBSImP™ values within the pharyngeal domain. The range of the pharyngeal sum score was between 0 (i.e., no impairment in any one of the analyzed components) and 104 (i.e., each swallowing component was scored with the most severe value across the four swallows). Due to many missing oral domain values (i.e., no visible oral structures on video), no oral sum score could be calculated.

2.4.2. Impaired Swallows

In order to analyze changes with respect to individual swallowing components, the changes of impaired swallows was calculated. That is, each component and PAS value was scaled for impaired swallow versus non impaired swallow [25].

To calculate interrater-reliability 25% (n=56) randomly chosen videos were analyzed by a second MBSImP™ certified speech and language therapist. To calculate intrarater-reliability the same 56 videos were reanalyzed by the primary researcher after a time period of 3 month. To calculate correlation, Kendall's tau-b coefficient was used. Statistical analyses were performed using IBM SPSS Statistics 22.0. A p -value $< .05$ was used to indicate a statistically significant difference with respect to pharyngeal sum score. To address the question of statistical significance for individual components, $p < .01$ was used for oral components and $p < .006$ was used for pharyngeal components after Bonferroni-correction. To analyze changes before and after surgery the Wilcoxon-signed rank test was used due to ordinal data.

Table 2. Vulnerable areas through cervical spine surgery and associated at-risk swallowing components

Vulnerable Areas through Anterior Approach	Associated Anatomical Structures	At-risk Swallowing Components
Glossopharyngeal nerve (CN IX)	Glossopharyngeal arches Stylopharyngeus	Initiation of pharyngeal swallow Laryngeal elevation
Superior laryngeal nerve, internal branch (CN X)	Pharyngeal sensory receptive fields	Initiation of pharyngeal swallow
Recurrent laryngeal nerve (CN X)	Intrinsic muscles of the larynx	Laryngeal elevation Laryngeal vestibular closure
Hypoglossal nerve (CN XII)	Intrinsic tongue muscles Tongue base muscles	Bolus preparation/Mastication Bolus transport/Lingual motion Epiglottic movement; Laryngeal vestibular closure
Ansa cervicalis	Suprahyoid muscles Infrahyoid muscles	Tongue control during bolus hold; Bolus preparation/Mastication; Bolus transport/Lingual motion; Anterior hyoid excursion Pharyngoesophageal segment opening; Epiglottic movement; Laryngeal elevation; Pharyngoesophageal segment opening
Pharyngeal plexus (CN IX und X)	Extrinsic tongue muscles Tongue base muscles Pharyngeal constrictors Pharyngoesophageal segment	Tongue control during bolus hold; Bolus preparation/Mastication; Bolus transport/Lingual motion Tongue base retraction; Epiglottic movement Laryngeal vestibular closure; Pharyngeal stripping wave; Tongue base retraction Pharyngeal contraction Pharyngoesophageal segment opening
Prevertebral swelling	Epiglottis Prevertebral area	Epiglottic movement Pharyngeal stripping wave
Esophageal retraction	Pharyngoesophageal segment	Pharyngoesophageal segment opening

3. Results

Ninety-seven patients were involved during the data collection period. A total number of 28 patients were included in this study. See Figure 2 for more detailed information of drop out. All patients underwent either anterior ($n = 19$; 9 females, 10 males; $M_{age} 56 \pm 14$ years) or posterior ($n = 9$; 5 females, 4 males; $M_{age} 63 \pm 14$ years) cervical spine surgery. Demographic and clinical characteristics are provided in Table 1. Pre-surgical VFSS was performed the day before surgery; post-surgical VFSS was conducted a median of 4 days after surgery (range 1-15 days).

3.1. Anterior Group

In the anterior group, pharyngeal sum score was significantly higher after surgery ($U(19) = -3.67$; $p < .001$), with a median of 11 before surgery and a median of 21 after surgery (Figure 3).

3.1.1. Impaired Swallows

No significant changes with respect to the oral components were observed after surgery. Significant

post-operative changes, however, were reported for the pharyngeal components hyoid excursion ($p = .002$), pharyngeal stripping wave ($p = .001$), pharyngoesophageal segment opening ($p = .002$) and pharyngeal residue ($p = .003$) (Table 3). There were no statistically significant changes to penetration/aspiration scores ($p = .32$).

3.2. Posterior Group

In the posterior group, pharyngeal sum score was significantly higher after surgery ($U(9) = -2.44$; $p = .015$), with a median of 5 before surgery and a median of 17 after surgery (Figure 3).

3.2.1. Impaired Swallows

No significant changes with respect to oral components were observed after surgery (Table 4). Likewise, no significant changes with respect to pharyngeal components were observed post-operatively. By trend, laryngeal elevation ($p = .02$), hyoid excursion ($p = .03$) and pharyngeal stripping wave ($p = .02$) were more often impaired. Furthermore, there were no significant changes in penetration/aspiration scores ($p > .99$).

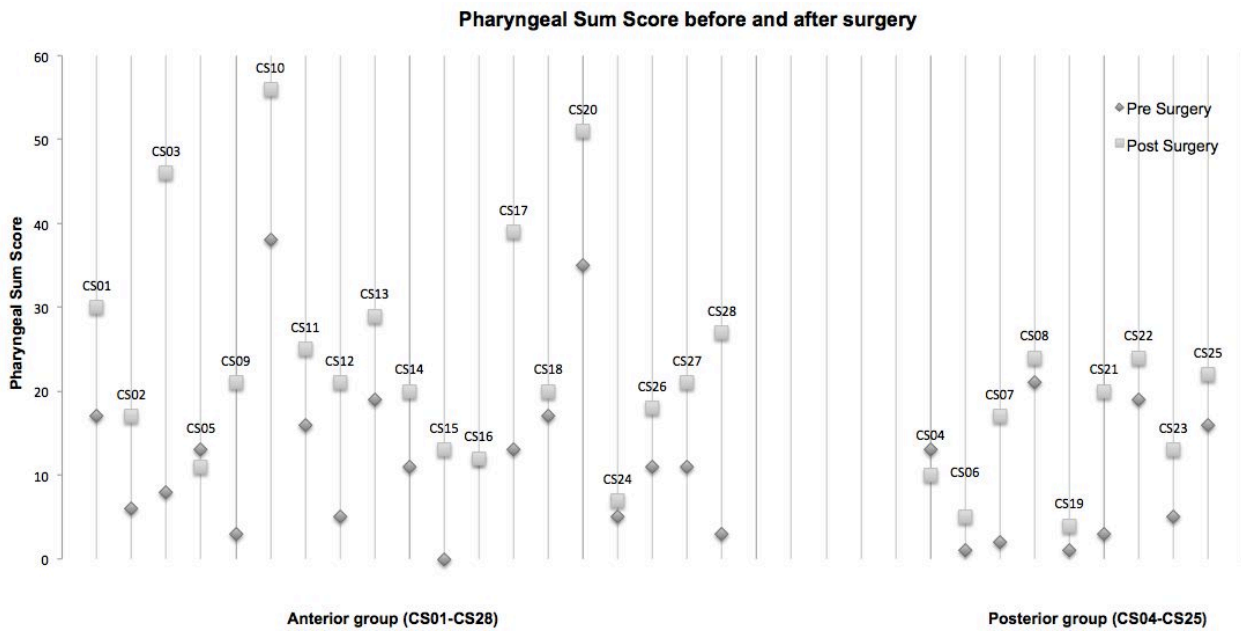


Figure 3. Pharyngeal Sum Score of anterior group (left side) and posterior group (right side)

Table 3. Impaired swallowing components before and after surgery in the anterior group

Anterior group	Median Pre	Median Post	<i>p</i>
Tongue control during bolus hold	0,00	0,00	0.99
Bolus preparation/ Mastication	1,00	1,00	0.32
Bolus transport/ Lingual motion	2,00	2,00	0.99
Oral residue	0,50	0,00	0.66
Initiation of pharyngeal swallow	3,00	3,00	0.19
Laryngeal elevation	3,00	4,00	0.04
Anterior hyoid excursion	1,00	3,00	0.002*
Epiglottic movement	0,00	1,00	0.012
Laryngeal vestibular closure	0,00	0,00	0.058
Pharyngeal stripping wave	1,00	4,00	0.001*
Pharyngoesophageal segment opening	0,00	1,00	0.002*
Tongue base retraction	0,00	1,00	0.017
Pharyngeal residue	1,00	2,00	0.003*
Penetration/Aspiration	0,00	0,00	0.32

Table 4. Impaired swallowing components before and after surgery in the posterior group

Posterior group	Median Pre	Median Post	<i>p</i>
Tongue control during bolus hold	0,00	1,00	0.25
Bolus preparation/ Mastication	0,00	1,00	0.32
Bolus transport/ Lingual motion	1,00	2,00	0.02
Oral residue	0,00	0,00	0.32
Initiation of pharyngeal swallow	2,00	3,00	0.08
Laryngeal elevation	1,00	3,00	0.02
Anterior hyoid excursion	0,00	2,00	0.03
Epiglottic movement	1,00	1,00	0.15
Laryngeal vestibular closure	0,00	0,00	0.56
Pharyngeal stripping wave	1,00	3,00	0.02
Pharyngoesophageal segment opening	0,00	0,00	>0.99
Tongue base retraction	0,00	0,00	>0.99
Pharyngeal residue	0,00	0,00	0.32
Penetration/Aspiration	0,00	0,00	>0.99

3.3. Inter- /Intrarater Reliability

The interrater reliability for 25% of all videos ($n = 56$ videos) was $\tau_b = .766$ ($p < .001$). The intrarater reliability for 25% of all videos ($n = 56$ videos) was $\tau_b = .902$ ($p < .001$).

4. Discussion

4.1. Patterns of Swallowing Pathophysiology

In this study, changes in swallowing physiology appeared

following both anterior and posterior intervention, with, however, more components affected following anterior cervical spine surgery. These results are consistent with the results of a study by Smith-Hammond et al. (2004) who showed that patients had swallowing impairments after posterior cervical spine surgery as well [9]. Indeed, not as many patients were affected in the posterior group as in the anterior group, nonetheless, roughly 20% of patients reported swallowing difficulties, which was consistent with our study.

4.2. Anterior Group

In the anterior group, the components anterior hyoid excursion, pharyngeal stripping wave, pharyngoesophageal segment opening, and pharyngeal residue worsened significantly. Similar results were reported in two other studies that retrospectively analyzed swallowing physiology after anterior cervical spine surgery [2, 8].

Impairment of the pharyngeal stripping wave is a similar finding to those of Leonard & Belafsky (2011). They detected in 71% of patients that pharyngeal contraction was impaired in an early post-surgery group (< 2 months) [2]. Martin et al. (1997), likewise, found pharyngeal stripping wave to be impaired after surgery, likely due to decreased pharyngeal motility of the pharyngeal constrictors caused by posterior pharyngeal wall edema [8]. This in turn, lead to reduced bolus flow and a reduction in the pressure required to squeeze the bolus through the pharyngoesophageal segment [2,8]. Soft tissue swelling of the prevertebral area leading to a mechanical inability of the epiglottis to deflect also was observed, thus causing impairment in epiglottic movement [2,8]. Decreased opening of the pharyngoesophageal segment, likewise, was described in both other studies [2,8]. Attention to differences in duration and diameter of opening was not focused on in this study, however, but rather on functional impairment. Future studies should consider analyzing both, duration and diameter of segment opening.

The possibility of a neurogenic contribution to the aforementioned swallowing patho-mechanisms has been discussed [8,13]. The vulnerability of the superior laryngeal and recurrent laryngeal nerves to injury through the anterior surgical route needs to be considered [23]. Additionally, nerve branches of the ansa cervicalis innervate, in part, the infrahyoid muscles and one of the suprahyoid muscles which are involved in hyoid excursion [26,27]. In our anterior group, hyoid movement was significantly more impaired following surgery and laryngeal elevation was more impaired by trend. It may be assumed that traction of the respective nerve branches affected both laryngeal elevation and hyoid excursion. The hypoglossal nerve is similarly vulnerable to injury in the anterior neck. Its involvement in tongue base retraction [21] could be a possible explanation for the by trend change observed post-operatively in the anterior group.

None of the oral components showed significant changes following surgery. Martin et al. (1997) stated that a higher cervical approach was likely to cause oral impairments, whereas lower cervical surgeries cause pharyngeal impairments [8]. A lack of oral involvement, therefore, could be due to the wanting cases of upper cervical spine involvement in the anterior group in this cohort.

4.3. Posterior Group

Although no statistically significant differences were observed in the posterior group, the oral component lingual motion and the pharyngeal components laryngeal elevation, anterior hyoid excursion and pharyngeal stripping wave were more often affected following surgery. Given that pharyngeal swelling and mechanical side effects can be excluded in surgeries following a posterior approach, other reasons for these changes in swallowing physiology were assumed.

In comparison to the anterior group, one oral parameter (lingual motion) was more often affected following surgery within the posterior group. Lingual movement (responsible for bolus transport through the oral cavity), similarly, was reported to be impaired in one case study where a hypoglossal nerve palsy was reported following posterior screw placement on the C-1 lateral mass [28].

The components laryngeal elevation, anterior hyoid excursion, and pharyngeal stripping wave were also shown to be impaired in another reported case study [11]. Bekelis et al. (2010) reported hypokinesis of the pharyngeal wall and decreased hyolaryngeal elevation after a posterior C1–C3 fusion and instrumentation. The authors attributed their finding to a transient dysfunction of the vagal nerves as a result of trauma to the vagal trunks in the area between C1 and the jugular foramen [11]. Given that 5 of the 9 patients (56%) in our posterior group had involvement of the upper cervical spine (i.e., C0-C3), this could possibly explain our findings of impaired laryngeal elevation and anterior hyoid excursion. This explanation is plausible given that the vagal nerves run close to each other near the skull base and a traction injury at a lower cervical level is unlikely [29]. To what extent the ansa cervicalis is involved in the case of a posterior surgical approach should be considered in further studies [26, 27].

4.4. Swallowing Physiology before Surgery

Several swallowing components were shown to be impaired prior to surgery in both groups. In general, a greater number of swallowing components were affected more often in the anterior group but still occurred in the posterior group. Radcliff et al. (2013) found similar findings and identified 11% of patients to have a baseline dysphagia following posterior cervical spine surgery [10]. Conversely, Smith-Hammond et al. (2004) did not observe preoperative dysphagia in this patient population [9]. Pre-operative findings of dysphagia

suggest that dysphagia may be a preexisting condition that then becomes exclusively caused by surgical maneuvers or postsurgical edema.

To what extent conspicuous swallowing findings can be attributed to compensatory strategies due to pain or postural changes needs to be investigated [30,31]. It may be that a little imbalance disturbs function. Local injuries are often not the cause of a disorder per se, but rather it is the combination of several injuries that may lead to post-operative, transient or persistent complications [23].

Pain in the cervical region may contribute to dysphagia observed in anterior and posterior cervical spine surgery patients [9,10]. However, if pain is a relevant contributing factor with respect to dysphagia following anterior or posterior surgery, it is unclear as to why anterior patients experience a higher incidence of dysphagia than posterior patients particularly when anterior surgical patients report less pain than posterior surgical patients [33].

4.5. Limitations

That there are observable changes in swallowing physiology following cervical spine surgery and, in particular, even prior to surgery is an important finding. Some consideration, however, needs to be taken when interpreting these findings on account of study design (i.e., retrospective study) and a small patient sample. Furthermore, these results refer only to the short period of time following cervical spine surgery (*mean* = 4 days post-surgery). A later follow-up would be necessary to differentiate between transient dysphagia due to postoperative edema and chronic pathophysiological changes to the swallowing system due to nerve traction during surgery. Finally, several videofluoroscopies partially omitted the oral phase of swallowing which, subsequently, led to missing values and an oral sum score could be not be obtained.

4.6. Clinical Relevance

It may be reasonable to involve a speech and language therapist in the pre- and postoperative evaluation of cervical spine surgery patients, particularly in the case of older patients [9,15] or patients undergoing revision surgery [15] who are at higher risk of developing dysphagia post-operatively. The early involvement of a speech and language therapist may, likewise, improve recovery rates given that patients can be provided with swallowing techniques to improve swallowing function and, subsequently, quality of life [9].

The focus of this study was on the observable changes in swallowing physiology following cervical spine surgery. As important as this may be, it is equally important to consider the clinical implications. Given the retrospective nature of this study, we were unable to identify the outcomes on oral intake or other aspects of quality of life. Further investigations ought to combine subjective, objective,

reliable and valid measurement tools to better define dysphagia in this patient group.

Nonetheless, this study provides valuable information, given that, to our knowledge, it is the first study that analyzes swallowing physiology and its specific components, in an anterior and posterior group, before and after surgery in a standardized way.

5. Conclusions

It is well known that dysphagia is the most frequent complication following anterior cervical spine surgery. In the majority of patients, dysphagia will be temporary, however, a minority of patients may experience permanent dysphagia. Proposed mechanisms leading to dysphagia include direct surgical trauma, neuropraxia from nerve traction, and postoperative edema [33]. In this study, changes in swallowing physiology were observed after anterior and posterior cervical spine surgery. Therefore all risks concerning dysphagia post-operatively should be conveyed in the pre-operative consultation.

Future studies should distinguish between transient and persistent dysphagia and between mild alterations in swallowing physiology and clinically significant dysphagia. Understanding the patterns of pathophysiology in this patient population is necessary in order to develop specific treatment approaches or preventive programs that may quicken recovery and improve quality of life in patients who undergo anterior and posterior cervical spine surgery.

Acknowledgements

We would like to acknowledge the members of the CS-Swal-Track project group who put a lot of effort into data collection on which this study is based.

REFERENCES

- [1] Singh, K., Marquez-Lara, A., Nandyala, S.V., Patel, A. A., & Fineberg, S. J. (2013). Incidence and risk factors for dysphagia after anterior cervical fusion. *Spine*, 38(21), 1820-1825.
- [2] Leonard, R., & Belafsky, P. (2011). Dysphagia following cervical spine surgery with anterior instrumentation: Evidence from fluoroscopic swallow studies. *Spine*, 36(25), 2217-2223.
- [3] Rihn, J. A., Kane, J., Albert, T. J., Vaccaro, A. R., & Hilibrand, A. S. (2011). What is the incidence and severity of dysphagia after anterior cervical surgery? *Clinical Orthopaedics and Related Research*, 469(3), 658-665.
- [4] Fountas, K. N., Kapsalaki, E. Z., Nikolakakos, L. G., Smisson, H. F., Johnston, K. W., Grigorian, A. A., Robinson, J. S. (2007). Anterior cervical discectomy and fusion associated complications. *Spine*, 32(21), 2310-2317.
- [5] Riley, L. H., Skolasky, R. L., Albert, T. J., Vaccaro, A. R., & Heller, J. G. (2005). Dysphagia after anterior cervical decompression and fusion: Prevalence and risk factors from a longitudinal cohort study. *Spine*, 30(22), 2564-2569.
- [6] Bazaz, R., Lee, M. J., & Yoo, J. U. (2002). Incidence of dysphagia after anterior cervical spine surgery: A prospective study. *Spine*, 27(22), 2453-2458.
- [7] Frempong-Boadu, A., Houten, J. K., Osborn, B., Oplencia, J., Kells, L., Guida, D. D., & Le Roux, P. D. (2002). Swallowing and speech dysfunction in patients undergoing anterior cervical discectomy and fusion: A prospective, objective preoperative and postoperative assessment. *Journal of Spinal Disorders & Techniques*, 15(5), 362-368.
- [8] Martin, R. E., Neary, M. & Diamant, N. E. (1997). Dysphagia following anterior cervical spine surgery. *Dysphagia*, 12(1), 2-8.
- [9] Smith-Hammond, C. A., New, K. C., Pietrobon, R., Curtis, D. J., Scharver, C. H., & Turner, D. A. (2004). Prospective analysis of incidence and risk factors of dysphagia in spine surgery patients lumbar procedures. *Spine*, 29(13), 1441-1446.
- [10] Radcliff, K. E., Koyonos, L., Clyde, C., Sidhu, G. S., Fickes, M., Hilibrand, A. S., Albert, T. J., Vaccaro, A. R. & Rihn, J. A. (2013). What is the incidence of dysphagia after posterior cervical surgery? *Spine*, 38(13), 1082-1088.
- [11] Bekelis, K., Gottfried, O. N., Wolinsky, J.P., Gokaslan, Z. L., & Omeis, I. (2010). Severe dysphagia secondary to posterior C1-C3 instrumentation in a patient with atlantoaxial traumatic injury: A case report and review of the literature. *Dysphagia*, 25(2), 156-160.
- [12] Logemann, J. A. (1998). *Evaluation and treatment of swallowing disorders*. Austin, TX: ProEd.
- [13] Riley, L. H., Vaccaro, A. R., Dettori, J. R., & Hashimoto, R. (2010). Postoperative dysphagia in anterior cervical spine surgery. *Spine*, 35(9), 76-85.
- [14] Zeng, J.H., Zhong, Z.M., & Chen, J.T. (2013). Early dysphagia complicating anterior cervical spine surgery: Incidence and risk factors. *Archives of Orthopaedic and Trauma Surgery*, 133(8), 1067-1071.
- [15] Cho, S. K., Lu, Y., & Lee, D.H. (2013). Dysphagia following anterior cervical spinal surgery: A systematic review. *The Bone & Joint Journal*, 95(7), 868-873.
- [16] Chin, K. R., Eiszner, J. R., & Adams, S. B. (2007). Role of plate thickness as a cause of dysphagia after anterior cervical fusion. *Spine*, 32(23), 2585-2590.
- [17] Siska, P. A., Ponnappan, R. K., Hohl, J. B., Lee, J. Y., Kang, J. D., & Donaldson, W. F. (2011). Dysphagia after anterior cervical spine surgery. *Spine*, 36(17), 1387-1391.
- [18] Edwards, C. C., Karpitskaya, Y., Cha, C., Heller, J. G., Laurysen, C., Yoon, S. T., & Riew, K. D. (2004). Accurate identification of adverse outcomes after cervical spine surgery. *The Journal of Bone and Joint Surgery*, 86-A(2), 251-256.
- [19] Fix, C., Drumm, J., Wilmskötter, J., Pitzen, T., Duchac, S., Schuhmann, B. & Stanschus, S. (2015). Dysphagien nach ventralen Halswirbelsäulenoperationen. *Forum HNO(17)*, 126-133.

- [20] Fechler, A., Farr, A., Duchac, S., Wasilesku, A. & Stanschus, S. (2011). Die digitale Videofluoroskopie – technische Möglichkeiten und Realisierung im klinischen Alltag. In: Hofmayer, A./Stanschus, S (Hrsg.) *Strukturierte Praxis und Forschung in der klinischen Dysphagiologie; Reihe DysphagieForum Band 7*, Schulz-Kirchner Verlag, Idstein, 19-28.
- [21] Martin-Harris, B. (2015). Standardized Training in Swallowing Physiology - Evidence Based Assessment Using the Modified Barium Swallow Impairment Profile (MBSImP) Approach. Gaylord, Michigan: Nothern Speech Services.
- [22] Martin-Harris, B., Brodsky, M. B., Michel, Y., Castell, D. O., Schleicher, M., Sandidge, J., Maxwell, R. & Blair, J. (2008). MBS measurement tool for swallow impairment-MBSImp: Establishing a standard. *Dysphagia*, 23(4), 392-405.
- [23] Liguoro, D., Vital, J. M., Guerin, J., & Senegas, J. (1992). Anatomical basis of the anterior cervical spine approach: Topographic study of the nerve structure. *Surgical and Radiologic Anatomy*, 14(3), 203-208.
- [24] Rosenbek, J. C., Robbins, J. A., Roecker, E. B., Coyle, J. L., & Wood, J. L. (1996). A penetration-aspiration scale. *Dysphagia*, 11(2), 93-98.
- [25] Martin-Harris, B., McFarland, D., Hill, E. G., Strange, C. B., Focht, K. L., Wan, Z., Blair, J. McGrattan, K. (2015). Respiratory-swallow training in patients with head and neck cancer. *Archives of Physical Medicine and Rehabilitation*, 96(5), 885-893.
- [26] D'Souza, A. S., & Ray, B. (2010). Study of the formation and distribution of the ansa cervicalis and its clinical significance. *European Journal of Anatomy*, 14(3), 143-148.
- [27] Banneheka, S. (2008). Anatomy of the ansa cervicalis: Nerve fiber analysis. *Anatomical Science International*, 83, 61-67.
- [28] Hong, J. T., Lee, S. W., Son, B. C., Sung, J. H., Kim, I. S., & Park, C. K. (2006). Hypoglossal nerve palsy after posterior screw placement on the C-1 lateral mass. *Journal of Neurosurgery: Spine*, 5(1), 83-85.
- [29] Tekdemir, I., Tuccar, E., Aslan, A., Elhan, A., Ph, D., Deda, H., Ciftci, E. & Akyar, S. (1998). The jugular foramen. *Neurology*, 3019(98), 557-562.
- [30] Papadopoulou, S., Exarchakos, G., Beris, A., & Ploumis, A. (2013). Dysphagia associated with cervical spine and postural disorders. *Dysphagia*, 28(4), 469-80.
- [31] Zerhouni, E., Bosma, J., & Donner, M. (1987). Relationship of cervical spine disorders to dysphagia. *Dysphagia*, 1(3), 129-144.
- [32] Zhang, J., Tsuzuki, N., Hirabayashi, S., Saiki, K., & Fujita, K. (2003). Surgical anatomy of the nerves and muscles in the posterior cervical spine: A guide for avoiding inadvertent nerve injuries during the posterior approach. *Spine (Phila Pa 1976)*, 28(13), 1379-1384.
- [33] Apfelbaum, R. I., Kriskovich, M. D., & Haller, J. R. (2000). On the incidence, cause, and prevention of recurrent laryngeal nerve palsies during anterior cervical spine surgery. *Spine*, 25(22), 2906-2912.