

# Lack of association between venous hemodynamics, venous morphology and the postthrombotic syndrome after upper extremity deep venous thrombosis

M Czihal<sup>1</sup>, S Paul<sup>1</sup>, A Rademacher<sup>1</sup>, C Bernau<sup>2</sup> and U Hoffmann<sup>1</sup>

Phlebology  
2015, Vol. 30(2) 105–112  
© The Author(s) 2013  
Reprints and permissions:  
sagepub.co.uk/journalsPermissions.nav  
DOI: 10.1177/0268355513517226  
phl.sagepub.com  


## Abstract

**Objectives:** To explore the association of the postthrombotic syndrome with venous hemodynamics and morphological abnormalities after upper extremity deep venous thrombosis.

**Methods:** Thirty-seven patients with a history of upper extremity deep venous thrombosis treated with anticoagulation alone underwent a single study visit (mean time after diagnosis:  $44.4 \pm 28.1$  months). Presence and severity postthrombotic syndrome were classified according to the modified Villalta score. Venous volume and venous emptying were determined by strain-gauge plethysmography. The arm veins were assessed for postthrombotic abnormalities by ultrasonography. The relationship between postthrombotic syndrome and hemodynamic and morphological sequelae was evaluated using univariate significance tests and Spearman's correlation analysis.

**Results:** Fifteen of 37 patients (40.5%) developed postthrombotic syndrome. Venous volume and venous emptying of the arm affected by upper extremity deep venous thrombosis did not correlate with the Villalta score ( $\rho = 0.17$  and  $0.19$ ;  $p = 0.31$  and  $0.25$ , respectively). Residual morphological abnormalities, as assessed by ultrasonography, did not differ significantly between patients with and without postthrombotic syndrome (77.3% vs. 86.7%,  $p = 0.68$ ).

**Conclusions:** Postthrombotic syndrome after upper extremity deep venous thrombosis is not associated with venous hemodynamics or residual morphological abnormalities.

## Keywords

Postthrombotic syndrome, strain-gauge plethysmography, ultrasonography, upper extremity deep venous thrombosis, venous hemodynamics

## Introduction

Upper extremity deep venous thrombosis (UEDVT) accounts for up to 11% of all cases of deep venous thrombosis.<sup>1</sup> While primary UEDVT occurs without apparent risk factors (idiopathic UEDVT) or after strenuous exercise of the upper extremities (Paget-von Schroetter syndrome), secondary UEDVT is a consequence of clinically apparent risk factors, predominantly cancer and indwelling central venous catheters.<sup>2</sup> The cornerstone of UEDVT treatment is anticoagulation.<sup>3</sup> Although the clinical benefit is unclear, many authors advocate additional treatment with thrombolysis with or without a staged interventional or surgical approach, aiming to restore venous patency and to prevent the postthrombotic syndrome (PTS).<sup>4,5</sup>

This concept implies a correlation between the presence of morphological and hemodynamic abnormalities after UEDVT with the clinical outcome, i.e. the PTS. However, literature provides only scarce and in part conflicting data on this correlation.<sup>6–9</sup> Against this background, we aimed to determine the association

<sup>1</sup>Division of Vascular Medicine, Medical Clinic and Policlinic IV, Munich University Hospital, Germany

<sup>2</sup>Department of Medical Informatics, Biometry and Epidemiology, Munich University Hospital, Germany

### Corresponding author:

Michael Czihal, Division of Vascular Medicine, Medical Clinic and Policlinic IV, Munich University Hospital, Pettenkoferstrasse 8a, D-80336 Munich, Germany.

Email: michael.czihal@med.uni-muenchen.de

between PTS, residual morphological vein alterations as determined by ultrasonography and venous function as assessed by strain-gauge plethysmography in a cohort of patients with UEDVT treated with anticoagulation alone.

## Patients and methods

Patients who were first diagnosed with UEDVT at our institution between 1999 and 2008 were retrospectively identified from an electronic database and invited for a single study visit. Patients were eligible for the study if they had a history of a first, symptomatic UEDVT involving the subclavian, axillary and/or brachial veins that was objectively confirmed by ultrasonography and was treated conservatively. Subjects who had undergone interventional treatment (i.e. thrombolysis, angioplasty with stenting and/or surgical decompression of the thoracic outlet) were excluded. A minimal time interval of 6 months was required to be elapsed between diagnosis and the study visit.<sup>10</sup> The study protocol was approved by the local ethics committee, and patients gave written informed consent.

Information on demographic characteristics, risk factors for UEDVT, affected venous segments and treatment duration were recorded. Assessment of the character and severity of venous symptoms of the affected arm was performed using a validated PTS-scale adapted to the upper extremities (modified Villalta score).<sup>8–12</sup> The scale consists of 11 items, 5 of which are symptoms rated subjectively by the patient. Six items are clinical signs evaluated by the physician (Table 1). Every item is graded on a scale from 0 (absent) to 3 (severe), with a maximum overall score of 33. A score below 5 is classified as no PTS, a score of 5–14 is classified as mild to moderate PTS and a score between 15 and 33 is classified as severe PTS.

Venous plethysmography was performed by one of the authors (S.P.) using the Vasolab 5000 system (ELCAT GmbH, Wolfratshausen, Germany). The plethysmographic examinations were done with the patient in a supine position and the arms resting in an elevated position at the level of the shoulder. Tourniquets were placed on each upper arm, and strain-gauge wires were placed on each forearm. Venous volume (ml/100 ml) was measured as the maximal volume changes after occluding the brachial veins for 3 min by inflation of the arm cuffs to a pressure of 60 mmHg. Venous emptying (ml/100 ml/min) was determined as the rate of volume outflow within one second after release of the venous occlusion.<sup>9</sup> Lower normal limits of 3 ml/100 ml for venous volume and 68 ml/100 ml/min for venous emptying were applied as reference values.<sup>9,13</sup> Both values were calculated as mean values from three repeated measurements.

All sonographic examinations were performed by an experienced Vascular Medicine specialist (A.R.), using the LOGIC<sup>TM</sup>9 (General Electric Medical Systems, Milwaukee, Wisconsin, USA) ultrasound device with a 5–10 MHz linear transducer. The brachiocephalic, subclavian, axillary, brachial, internal jugular, cephalic and basilic vein were visualized using the B-mode (with and without vein compression) and the pulsed wave and colour-duplex mode. Venous morphology and flow in the subclavian vein were analyzed with the patient in a supine position and the arm slightly abducted. Venous segments were categorized in (a) normal vein, (b) abnormal vein with residual thrombus or residual postthrombotic wall thickening but visible blood flow and (c) completely occluded vein. Valvular patency was assessed in the brachial, cephalic and basilic vein with the patient in an upright sitting position and the arm hanging down. Venous reflux was provoked by distal manual compression, and a duration of the venous reflux of more than 0.5 s was considered to be pathological.<sup>13</sup>

Statistical analysis was performed using the R software for statistical computing (R Development Core Team, Vienna, Austria). Results for categorical variables are presented as frequency (in percent), and continuous variables are displayed as mean  $\pm$  standard deviation. Univariate comparisons between two groups were performed using Fisher's exact test (categorical variables) and Mann–Whitney U-test (continuous variables). In the case of paired samples, the McNemar test (categorical variables) and the Wilcoxon test (continuous variables) for paired samples were applied. For univariate comparison of continuous variables between more than two groups, the Kruskal–Wallis rank sum test was applied. Two-sided p-values  $< 0.05$  were considered significant.

**Table 1.** Items and scoring-system of the modified Villalta-score.<sup>8–12</sup>

Subjective symptoms	Clinical signs
Pain	Edema
Cramps	Prominent subcutaneous arm veins
Heaviness	Prominent collateral veins (shoulder/anterior chest wall)
Pruritus	Tenderness
Paresthesia	Redness
	Dependent cyanosis
<i>Scoring system: every item is graded on a scale from 0 (absent) to 3 (severe)</i>	
0–4	No PTS
5–14	Mild to moderate PTS
15–33	Severe PTS

Spearman's correlation analysis was used to explore the relationship between the Villalta score and hemodynamic parameters (venous volume and venous emptying) and between the Villalta score and the time between diagnosis and the study visit, respectively.

## Results

### Patient characteristics

Fifty-eight patients were identified of whom 37 patients could be included in the study, all of them having a history of a first episode of objectively verified unilateral UEDVT. Twenty-one patients were not included because of patient's death or inability to contact the patient (11 patients), refusal to take part in the study (9 patients) and interventional treatment of UEDVT with thrombolysis and angioplasty (1 patient). The clinical characteristics of the 37 study subjects are shown in Table 2. The demographic data of the 25 patients with primary UEDVT have been published previously.<sup>12</sup> Within the subgroup of 12 patients with secondary UEDVT, 6 patients suffered from catheter-associated thrombosis (4 patients with malignancy and port catheters and 2 patients with central venous catheters during critical illness), 2 patients had local venous compression due to lymphoma, 2 patients had undergone osteosynthesis of a clavicle fracture, 1 patient had thrombosis after implantation of pacemaker leads and 1 patient was diagnosed with antiphospholipid antibody syndrome.

Diagnosis of UEDVT was initially confirmed by ultrasonography in all patients. Additional imaging methods (computed tomography, venography) contributed to the diagnosis in 7 of 37 patients (18.9%). The subclavian, axillary and brachial veins were involved in 97.3%, 32.4% and 5.4%, respectively. The brachiocephalic and internal jugular veins were additionally

affected in 10.8% and 17.9% of patients, respectively. Involvement of the basilic vein was noticed in two patients. Two or more venous segments were affected in 45.9% of patients. Subjects with secondary UEDVT tended to have more frequent involvement of more than one venous segment (58.3% vs. 40%,  $p = 0.48$ ).

The mean duration of anticoagulation was  $5.6 \pm 11.5$  months, and the mean interval between diagnosis and the study visit was  $44.4 \pm 28.1$  months (minimum 6 months, maximum 115 months). None of the patients had developed symptomatic recurrent UEDVT or symptomatic pulmonary embolism until the follow-up visit.

### Postthrombotic syndrome

According to the modified Villalta score, the following signs and symptoms of the arm affected by UEDVT were present at the follow-up visit: dilated subcutaneous collateral veins (73.0%), heaviness (59.5%), paresthesia (51.4%), pain (43.2%), intermittent swelling (37.8%), redness or cyanosis (21.6%), pruritus (18.9%) and cramps (13.5%). Symptoms at the contralateral arm were not reported by any of the patients.

The mean Villalta score was  $5.0 \pm 4.2$  and did not differ significantly between patients with secondary UEDVT compared to those with primary UEDVT ( $6.5 \pm 4.7$  vs.  $4.2 \pm 3.8$ ,  $p = 0.14$ ). Of note, the Villalta score did not correlate with the time interval between diagnosis and the study visit (Spearman's  $\rho$  0.15,  $p = 0.39$ ). Fourteen out of the 37 patients (37.8%) suffered from mild to moderate PTS, but only one patient with secondary UEDVT met the criteria for severe PTS. Venous ulceration did not occur. Patients with secondary UEDVT more frequently suffered from PTS although this difference was not statistically significant (58.3% vs. 32.0%,  $p = 0.16$ ). The frequency of PTS did not differ with regard to occupation (physically

**Table 2.** Clinical characteristics of the 37 patients with UEDVT and comparison between patients with and without PTS.

	Overall cohort; n = 37	PTS; n = 15	No PTS; n = 22	p
Age, mean $\pm$ SD, years	45.2 $\pm$ 17.6	50.3 $\pm$ 15.6	41.8 $\pm$ 18.3	0.15
Female sex, no. (%)	18 (48.6)	10 (66.7)	8 (36.4)	0.10
Dominant hand affected, No. (%)	17 (45.9)	7 (46.7)	10 (45.5)	1.00
Physically demanding job, No. (%) <sup>a</sup>	16 (53.3)	9 (64.3)	7 (43.8)	0.30
Duration of anticoagulation, mean $\pm$ SD, months	5.6 $\pm$ 11.5	3.2 $\pm$ 1.4	6.7 $\pm$ 13.9	0.47
Time interval between diagnosis and study visit, mean $\pm$ SD, months	44.4 $\pm$ 28.1	52.5 $\pm$ 31.8	29.8 $\pm$ 25.4	0.22
Secondary UEDVT, no. (%)	12 (32.4)	7 (46.7)	5 (22.7)	0.16

<sup>a</sup>Data available for 30 patients.

PTS: postthrombotic syndrome; UEDVT: upper extremity deep venous thrombosis.

demanding vs. physically non-demanding job), the arm affected (dominant vs. non-dominant arm), age and sex (Table 2).

**Venous hemodynamics**

The mean values for venous emptying and venous volume are listed in Table 3. There were no significant differences between the arm affected by thrombosis and the contralateral arm with respect to venous volume and venous emptying. The percentage of patients with venous volume and venous emptying below the lower normal limit did not differ significantly between the arm

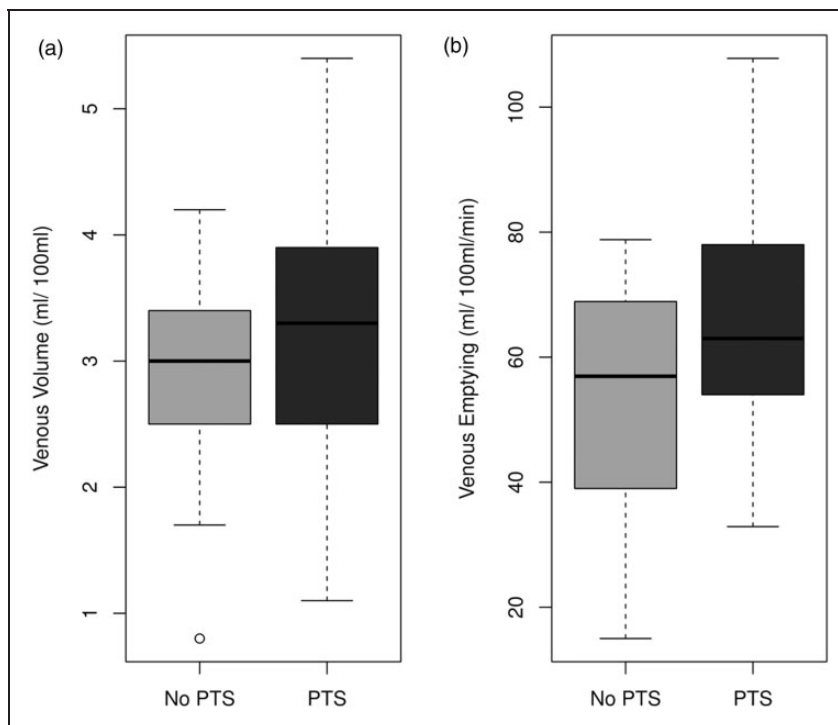
affected by thrombosis and the contralateral arm (venous volume: 45.9% vs. 35.1%,  $p=0.38$ ; venous emptying: 62.2% vs. 58.8%,  $p=0.80$ ).

While venous volume and venous emptying of the arm with thrombosis correlated well ( $\rho=0.84$ ,  $p<0.01$ ), both parameters did not correlate with the modified Villalta score ( $\rho=0.17$  and  $0.19$ ;  $p=0.31$  and  $0.25$ , respectively). Surprisingly, patients with PTS exhibited a higher-mean venous volume and venous emptying of the arm affected as compared with patients without PTS. However, differences reached significance for venous emptying only ( $p=0.03$ , Table 3, Figure 1). The percentage of patients

**Table 3.** Mean values of venous volume and venous emptying in different subgroups.

	Venous volume, mean $\pm$ SD, ml/100 ml	$p$	Venous emptying, mean $\pm$ SD, ml/100 ml/min	$P$
UEDVT arm (n = 37) vs. contralateral arm (n = 37)	3.0 $\pm$ 0.9	0.13	60.0 $\pm$ 19.7	0.09
	3.3 $\pm$ 0.9		71.0 $\pm$ 20.9	
UEDVT arm: with PTS (n = 15) vs. without PTS (n = 22)	3.2 $\pm$ 1.1	0.15	70.6 $\pm$ 18.1	0.03
	2.8 $\pm$ 0.8		54.4 $\pm$ 17.7	
UEDVT arm: no residual thrombosis (n = 7) vs. residual thrombosis (n = 21) vs. complete occlusion (n = 9)	2.9 $\pm$ 1.1	0.38	50.0 $\pm$ 2.3	0.48
	2.8 $\pm$ 0.8		60.6 $\pm$ 1.9	
	3.5 $\pm$ 0.5		66.3 $\pm$ 1.8	

PTS: postthrombotic syndrome; UEDVT: upper extremity deep venous thrombosis.



**Figure 1.** Box plot diagram showing the differences in venous volume (a) and venous emptying (b) between patients with and without PTS.

with venous volume or venous emptying below the lower normal limit did not differ significantly between patients with PTS and those without PTS (venous volume: 46.7% vs. 45.5%,  $p=1.0$ ; venous emptying: 46.7% vs. 68.2%,  $p=0.49$ ).

### Venous morphology and valvular function

Follow-up ultrasonography showed normal venous morphology in 7 patients (18.9%), whereas 21 patients (56.8%) exhibited residual postthrombotic changes and 9 (24.3%) had complete venous occlusion. Mean venous volume and venous emptying were not significantly different in postthrombotic extremities with either sonographically normal, abnormal or occluded deep veins (venous volume:  $p=0.38$ ; venous emptying:  $p=0.48$ ; Table 3, Figure 2). The Villalta score was not different in the three sonographic categories ( $p=0.32$ ; Figure 3). Residual morphological abnormalities (wall thickening, residual thrombosis or occlusion) were not found to be more common in patients with PTS than in patients without PTS (77.3% vs. 86.7%,  $p=0.68$ ). The number of venous segments affected initially and at the follow-up visit, respectively, did not correlate with venous hemodynamics and the clinical outcome in terms of the PTS (data not shown).

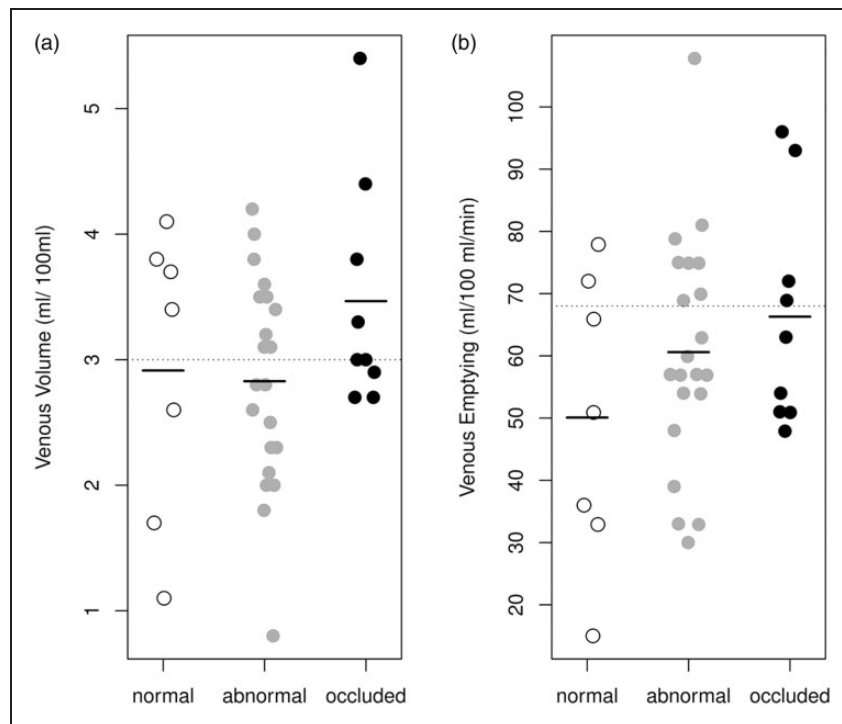
Valvular dysfunction in terms of deep or superficial venous reflux was not found in any of the patients.

### Discussion

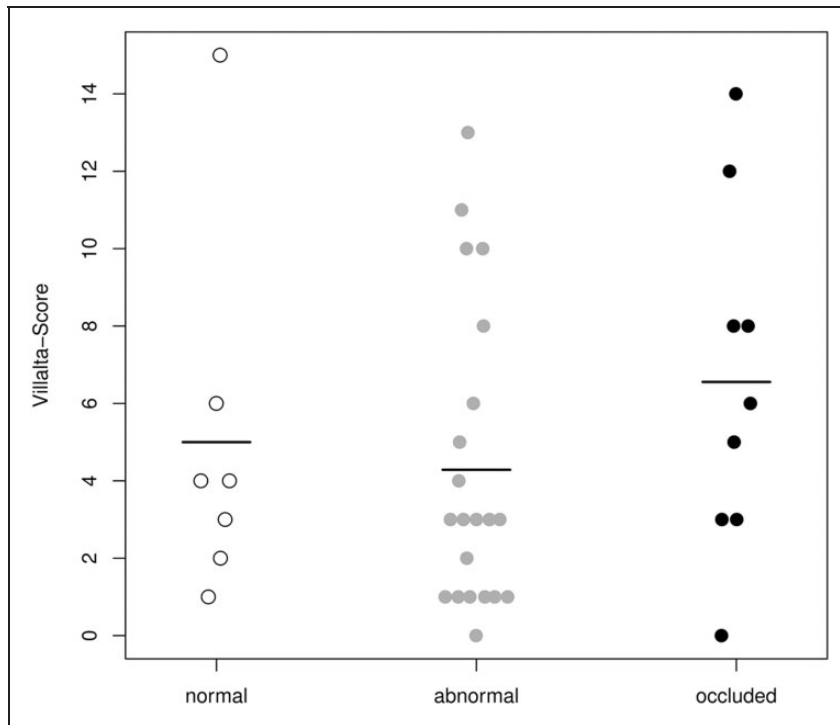
In the present study on 37 patients with a history of UEDVT treated with anticoagulation alone, we assessed the correlation between morphological and hemodynamic parameters and the occurrence of the PTS after a mean follow up of almost 4 years. Our study did not show any significant association between morphological (postthrombotic changes assessed by ultrasonography) and hemodynamic parameters (venous volume and venous emptying assessed by venous plethysmography) in the arm affected by UEDVT. Most importantly, both venous hemodynamics and venous morphology were not correlated to the presence of PTS, which occurred in 40.5% of our patients.

Persson et al.<sup>9</sup> previously investigated the correlation of venous volume and venous emptying with the occurrence of PTS in subjects with a history of UEDVT. In agreement with our findings, the authors<sup>9</sup> were also not able to show an association between venous hemodynamics and the clinical outcome (PTS). The fact that, in our cohort, venous hemodynamics did not differ significantly between the arm affected by UEDVT, and the contralateral arm may indicate an excellent venous collateralization particularly in patients with residual venous obstructions.

Few studies reported on the correlation between morphological sequelae of UEDVT, as determined by



**Figure 2.** Distribution of the values for venous volume (a) and venous emptying (b) of the arm affected by UEDVT in patients with normal veins, veins with residual postthrombotic changes and occluded veins.



**Figure 3.** Distribution of the values for the modified Villalta score in patients with normal veins, veins with residual postthrombotic changes and occluded veins of the arm affected by UEDVT.

ultrasonography, and the occurrence of PTS. While Prandoni et al.<sup>8</sup> documented a significantly increased risk of PTS in patients exhibiting residual thrombosis, others did not find an association between the presence of postthrombotic vein alterations depicted by ultrasonography and the frequency of PTS.<sup>6</sup> Moreover, in a large retrospective study, Sabeti et al. documented a markedly improved venous patency after systemic thrombolysis compared to anticoagulation alone, but found no difference in the occurrence of PTS between both treatment groups. These results fit well to the findings of our study, as we did not observe any significant differences in the frequency of PTS in patients with normal, abnormal and occluded veins. Vice versa, the frequency of residual morphological abnormalities was similar (about 80%) in our patients with and without PTS.

Taking the currently available evidence together, neither venous plethysmography nor ultrasonography allow the prediction of the clinical outcome after UEDVT in terms of the PTS. Whether other diagnostic methods may be more appropriate in this clinical setting, for instance by visualizing the collateral system or by measuring other parameters of venous insufficiency (e.g. arm volumetry and skin thickness) remains to be investigated. In addition, our findings put a question

mark behind the often advocated treatment strategy of restoring venous patency with thrombolysis or with staged multidisciplinary approaches after UEDVT for the prevention of PTS.<sup>4,5</sup> Although several authors have reported good to excellent success of thrombolytic therapy in terms of early and late venous patency, it is actually unknown whether thrombolytic treatment reduces the incidence of the PTS and improves the clinical outcome after UEDVT.<sup>2,3,14</sup>

Due to the varying criteria applied for classification of PTS and the differences in the patient populations investigated, the frequency of PTS in patients with conservatively treated UEDVT varied in previous studies within a wide range from 7 to 46%.<sup>14</sup> Studies applying the modified Villalta score, including our study, reported more consistent prevalence rates of PTS between 27 and 41%.<sup>8-10,12</sup> Whether primary versus secondary UEDVT is associated with different rates of PTS is unclear. We found a trend towards a higher rate of PTS in patients with secondary UEDVT compared to primary UEDVT. The limited literature available suggests that PTS may occur less frequently after catheter-associated UEDVT.<sup>14</sup> By contrast to Kahn and coworkers, we did not observe a higher frequency of PTS in patients suffering from UEDVT of the dominant versus the non-dominant arm.<sup>9,12</sup>

Most of the patients with UEDVT and PTS report only mild to moderate symptoms. Summing up the results from the above-mentioned studies using the modified Villalta score for definition of PTS, less than 3% of patients fulfilled the criteria for severe PTS.<sup>8–10,12</sup> Venous ulceration is virtually unknown after UEDVT, which is apparently different to lower extremity DVT, where loss of valvular function and venous obstruction with resulting venous hypertension are closely associated to the development and progression of PTS.<sup>15,16</sup> By contrast, the pathophysiological key elements resulting in PTS after lower extremity DVT obviously do not seem to play the same role in the development of PTS after UEDVT.<sup>9</sup> This may explain the less severe degrees of PTS observed after UEDVT compared to lower extremity DVT. Nonetheless, mild to moderate PTS may result in impairment of upper extremity function and health-related quality of life in patients with UEDVT.<sup>10,12</sup>

Our study is limited by the small sample size and the retrospective patient identification, which did not allow us to include consecutive patients. Diagnosis of UEDVT was primarily based on ultrasonography and not on venography, which is considered the diagnostic reference standard.<sup>2</sup> However, ultrasonography has been shown to have a specificity of 96% for diagnosis of UEDVT in a recent systematic review.<sup>17</sup> Another shortcoming is that, as of today, no validated reference standard has been established for the diagnosis of upper extremity PTS.<sup>2,14</sup> Finally, in our study, a time interval of at least 6 months was required to be elapsed between diagnosis and follow-up, as done previously.<sup>10</sup> However, according to the data from the lower extremities, the onset of a PTS may occur later during the follow-up, and symptoms of PTS may fluctuate over time.<sup>18</sup> Although the mean time between diagnosis and follow-up was  $44.4 \pm 28.1$  in our cohort, it thus seems possible that we may have underestimated the frequency of the PTS.

In summary, PTS is a common long-term complication of UEDVT, but most patients report only mild to moderate symptoms. According to our results, the occurrence of upper extremity PTS is not associated to venous hemodynamics or to residual morphological abnormalities.

### Funding

This research received no specific grant from any funding agency in the public, commercial, or not-for-profit sectors.

### Conflict of Interest

None declared.

### References

1. Joffe HV, Kucher N, Tapson VF, et al. Upper-extremity deep vein thrombosis: a prospective registry of 592 patients. *Circulation* 2004; 110(12): 1605–1611.
2. Czihal M and Hoffmann U. Upper extremity deep venous thrombosis. *Vasc Med* 2011; 16: 191–202.
3. Kearon C, Kahn SR, Agnelli G, et al. Antithrombotic therapy for venous thromboembolic disease: American College of Chest Physicians Evidence-Based Clinical Practice Guidelines. 8th ed. *Chest* 2008; 133(6 Suppl): 454S–545S.
4. Thomas IH and Zierler BK. An integrative review of outcomes in patients with acute primary upper extremity deep venous thrombosis following no treatment or treatment with anticoagulation, thrombolysis, or surgical algorithms. *Vasc Endovasc Surg* 2005; 39: 163–174.
5. Illig KA and Doyle AJ. Paget-Schroetter syndrome: a comprehensive review. *J Vasc Surg* 2010; 51: 1538–1547.
6. Heron E, Loziquez O, Emmerich J, et al. Long-term sequelae of spontaneous axillary-subclavian venous thrombosis. *Ann Intern Med* 1999; 131: 510–513.
7. Sabeti S, Schillinger M, Mlekusch W, et al. Treatment of subclavian-axillary vein thrombosis: long-term outcome of anticoagulation versus systemic thrombolysis. *Thromb Res* 2002; 108: 279–285.
8. Prandoni P, Bernardi E, Marchiori A, et al. The long term clinical course of acute deep vein thrombosis of the arm: prospective cohort study. *BMJ* 2004; 329: 484–485.
9. Persson LM, Arnhjort T, Larfars G, et al. Hemodynamic and morphologic evaluation of sequelae of primary upper extremity deep venous thrombosis treated with anticoagulation. *J Vasc Surg* 2006; 43: 1230–1235.
10. Kahn SR, Elman EA, Bornais C, et al. Post-thrombotic syndrome, functional disability and quality of life after upper extremity deep venous thrombosis in adults. *Thromb Haemost* 2005; 93: 499–502.
11. Villalta S, Bagatella P, Piccioli A, et al. Assessment of validity and reproducibility of a clinical scale for the post-thrombotic syndrome (abstract). *Haemostasis* 1994; 24(Suppl 1): 158a.
12. Czihal M, Paul S, Rademacher A, et al. Impact of the postthrombotic syndrome on quality of life after primary upper extremity deep venous thrombosis. *Vasa* 2012; 41(3): 200–204.
13. Persson LM, Arnhjort T, Haneby C, et al. A methodological study of computerized venous strain-gauge plethysmography of the upper extremities. *Clin Physiol Funct Imaging* 2005; 25: 281–285.
14. Elman EE and Kahn SR. The post-thrombotic syndrome after upper extremity deep venous thrombosis in adults: a systematic review. *Thromb Res* 2006; 117: 609–614.
15. Latella J, Desmarais S, Miron MJ, et al. Relation between D-dimer level, venous valvular reflux and the

- development of post-thrombotic syndrome after deep vein thrombosis. *J Thromb Haemost* 2010; 8: 2169–2175.
16. Yamaki T, Hamahata A, Soejima K, et al. Factors predicting development of post-thrombotic syndrome in patients with a first episode of deep vein thrombosis: preliminary report. *Eur J Vasc Endovasc Surg* 2011; 41: 126–133.
  17. Di Nisio M, Van Sluis GL, Bossuyt PM, et al. Accuracy of diagnostic tests for clinically suspected upper extremity deep vein thrombosis: a systematic review. *J Thromb Haemost* 2010; 8(4): 684–692.
  18. Kahn SR, Shrier I, Julian JA, et al. Determinants and time course of the postthrombotic syndrome after acute deep venous thrombosis. *Ann Intern Med* 2008; 149: 698–707.