

Neoadjuvant or adjuvant sirolimus for malignant metastatic or locally advanced perivascular epithelioid cell tumors: two case reports

Christiane Batereau^a, Thomas Knösel^{e,f,g}, Martin Angele^{b,f,g}, Hans Roland Dürr^{c,f,g}, Melvin D'Anastasi^d, Eric Kampmann^a, Bernhard Ismann^a, Veit Bücklein^a and Lars H. Lindner^{a,f,g}

Perivascular epithelioid cell tumors (PEComas) are very rare mesenchymal tumors, characterized by the presence of perivascular epithelioid cells. Despite their often benign nature, malignant variants with a locally aggressive growth pattern and even distant metastases are known. We describe two cases of malignant PEComas. The first patient had an extensive peritoneal spread and a history of multiple resections, and received the mechanistic target of rapamycin inhibitor sirolimus in a postoperative setting as maintenance therapy. The second patient presented with locally advanced disease in the iliac fossa and was treated with sirolimus in a neoadjuvant setting and achieved complete remission. Both patients have been under treatment for 18 and 52 months, respectively, and are currently in complete remission. These two cases indicate that mechanistic target of rapamycin inhibition for malignant PEComas could be a safe and successful

Introduction

Sarcomas represent a very heterogeneous group of tumors of mesenchymal origin with variable malignant potential. Perivascular epithelioid cell tumors (PEComas) encompass a very rare subgroup and not a specific entity, rather a whole tumor family including angiomyolipomas, lymphangiomyomatosis of the lung, and the clear cell 'sugar' tumor of the lung or extrapulmonary sites. Histologically, they all have one similarity: the presence of perivascular epithelioid cells. These cells have an epithelioid appearance without a known normal counterpart, usually located adjacent to blood vessels [1]. Immunohistochemically, myogenic (actin, vimentin, less common desmin) as well as melanocytic markers (HMB45, Melan A, S100) are often expressed [2].

Angiomyolipomas of the kidney represent the most common of the PEComas. In their sporadic form, detected most often as a benign solitary incidentaloma, there is usually no need for therapy, but surgical treatment may be required to prevent complications such as hemorrhage [3].

Ten percent of the tumors are associated with the tuberous sclerosis complex (TSC), an autosomal dominant inherited disease, characterized by the development of a variety of benign tumors in multiple organs,

treatment strategy in a neoadjuvant setting with an acceptable toxicity profile. *Anti-Cancer Drugs* 27:254–258
Copyright © 2016 Wolters Kluwer Health, Inc. All rights reserved.

Anti-Cancer Drugs 2016, 27:254–258

Keywords: neoadjuvant therapy, perivascular epithelioid cell neoplasms, sirolimus

Departments of ^aInternal Medicine III, ^bGeneral, Visceral, Transplantation, Vascular, and Thoracic Surgery, ^cOrthopaedic Surgery, Orthopaedic Oncology, ^dClinical Radiology, ^eInstitute of Pathology, ^fCenter for Bone and Soft Tissue Sarcoma (SarkUM) and ^gComprehensive Cancer Center, Ludwig-Maximilians-University of Munich, Munich, Germany

Correspondence to Lars H. Lindner, MD, Department of Internal Medicine III University of Munich – Campus Grosshadern, Ludwig-Maximilians-University, Marchioninistr. 15, 81377 Munich, Germany
Tel: +49 89 4400 74768; fax: +49 89 4400 74776;
e-mail: lars.lindner@med.uni-muenchen.de

Received 6 October 2015 Revised form accepted 5 November 2015

including the brain, heart, skin, eyes, kidney, lung, and liver, skin lesions, seizures, and learning disability. The associated angiomyolipomas tend to be larger, more aggressive, and often multifocal; thus, renal failure, local invasive growth, and even metastases are possible consequences [4].

Lymphangiomyomatosis is a benign but progressive disease of the lung in premenopausal women, often presenting clinically with dyspnea, pleural effusion, pneumothorax, and a slowly progressive pulmonary failure. It can be associated with the TSC, but most cases are sporadic without germline mutations [5].

Despite their mostly benign behavior, PEComas with locally aggressive growth as well as cases with distant metastases, most commonly located in the lungs, are known. Malignant PEComas are usually not associated with TSC. This spindle and epithelioid cell malignancy typically arises at gynecological sites, the gastrointestinal tract, in the retroperitoneal space, or in soft tissue. Firm criteria to make the diagnosis of a PEComa with malignant potential are not well established. However, Folpe and Kwiatkowski [6] describe a tumor size more than 50 mm, a mitotic index of more than 1 per 50 high-power fields, infiltrative growth, marked hypercellularity with

pleomorphism, and nuclear atypia to be associated with high risk for local recurrence and metastasis.

As the activation of the mechanistic target of rapamycin (mTOR) pathway seems to play a role in the pathogenesis, sirolimus as a selective inhibitor of the mTOR complex is a possible approach as a targeted therapy. According to Bissler *et al.* [7], who observed a significant tumor volume reduction in patients with malignant angiomyolipomas associated with TSC treated with sirolimus, and Wagner *et al.* [8], who published a case series of three patients with malignant PEComa successfully treated with sirolimus, we decided to treat a patient with recurrent peritoneal metastasis and a patient with locally advanced malignant PEComa with sirolimus.

Case reports

Case 1

A 26-year-old woman was first referred to a local clinic in 2001 with localized abdominal pain. A tumor associated with the transverse colon was diagnosed and resected. The tumor was examined by a local pathologist and the diagnosis of a benign mesenchymal tumor was made. Seven years later, in 2008, another tumor associated with her greater omentum was detected during a routine gynecological visit. Following resection, the pathological examination showed a spindle cell and epithelioid cell mesenchymal tumor with an immunohistological strong positivity for CD 117, classified as a gastrointestinal stromal tumor (GIST). An adjuvant therapy with imatinib over 1 year was administered.

In 2010, a computed tomographic (CT) scan indicated multiple tumor nodules disseminated in the abdominal cavity including the pelvis, associated with the bladder and both ovaries. All visible tumor tissue was macroscopically resected and a diagnosis of a relapsed GIST was made by the local pathologist. The tumor tissue showed the same features as the tumor from 2008, but the Ki-67 proliferative index was now increased to 30% compared with 2–3% 2 years before.

In 2011, another recurrence with a tumor associated with the right ovary was found. Again, a laparotomy with tumor resection was performed. This time, an extended immunohistological examination by a reference pathologist followed. The tumor tissue showed a malignant spindle and epithelioid cell neoplasm with high mitotic activity (54/50 high-power fields) this time also, and 10% necrosis (Fig. 1). However, no GIST marker could be found (CD 117, DOG-1, and CD 34 all negative). Focal positivity for actin and a strong continuous positivity for HMB45 was present. Together with negativity for S100, desmin, pancytokeratin, EMA, CD 56, CD 57, CD 10, inhibin, and WT1, the diagnosis of an unusual PEComa was made and was confirmed by a second pathologist. The tumor was classified as malignant because of local necrosis,

tumor size, high mitotic activity, and multiple relapses in the past.

Six months later, another recurrence was found on a follow-up PET scan in the lower right pelvis (Fig. 2a). Distant metastases were excluded. The patient was referred to the Sarcoma Center of Ludwig-Maximilian University of Munich (SarKUM). In the interdisciplinary sarcoma conference, the case was discussed and deemed resectable. However, in the context of the patient's history, we considered the risk of another relapse as very high. We decided to commence with sirolimus as a neoadjuvant treatment approach on the basis of previous case reports with successful treatment of malignant PEComas with mTOR inhibition.

The therapy was well tolerated, without relevant side effects. Sirolimus plasma concentration was measured regularly and found to be always within the therapeutic window, defined as 10–15 µg/l as suggested by Bissler *et al.* [7].

During treatment, we performed a CT scan every 3 months. The first scan indicated a progressive central necrosis and after 6 months of therapy, a partial remission was achieved (Fig. 2b). An extended surgery followed and the main tumor as well as some small peritoneal nodules were resected. Histologically, the diagnosis of a malignant PEComa was confirmed by our institute of pathology. The resection was classified as marginal. On the basis of the intraoperative situs with the detection of a peritoneal sarcomatosis, we decided to continue the treatment with sirolimus. To date, 3 years after the last resection, the patient remains stable without macroscopically detectable tumor (Fig. 2c) and is still undergoing therapy with sirolimus, which is well tolerated.

Case 2

A 49-year-old woman presented with local pressure in the right groin. A CT scan indicated a 10 × 4 × 3 cm mass in the right iliac fossa (Fig. 3a), as well as enlarged para-aortic and parailiac lymph nodes. A first ultrasound-guided biopsy showed only unspecific altered and necrotic tissue; a second biopsy indicated a mesenchymal epithelioid cell neoplasm with uniform small nuclei and a light cytoplasm (Fig. 4). No mitoses were present and the Ki-67 proliferation index was low (2–3%). On the basis of the typical immunohistological profile with strong expression of HMB45 and without expression of S100, the diagnosis of a PEComa was made.

The tumor was classified as unresectable in a nonacademic peripheral hospital and the patient was referred to our sarcoma center (SarKUM). On MRI, the neoplasm showed no definite signs of local organ infiltration. However, because of the presence of large areas of necrosis and pathologically enlarged lymph nodes, in combination with the size more than 5 cm, we suspected a PEComa with malignant potential despite its histological

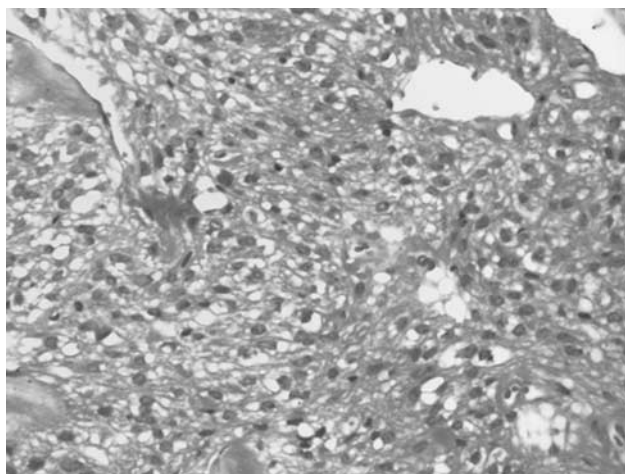
homogenous and low proliferative nature. At our interdisciplinary sarcoma conference, the tumor was classified as resectable only with mutilating surgery. Because of the size and localization of the tumor next to the femoral and sciatic nerve, and because of its contact to the sacrum, the only possible surgical option for a complete resection was a hemipelvectomy. The patient refused mutilating surgery; thus, treatment with sirolimus was commenced. As in the first case, we performed regular CT scans every 3 months. The patient was closely monitored clinically by a local oncologist, which included regular checks of plasma levels of sirolimus. Plasma levels were found to be between 11 and 20 $\mu\text{g/l}$, and the therapy was tolerated without relevant toxicity. To date, no interruption of the therapy has been necessary. During follow-up, the scans showed a steady decrease in tumor size, leading to a complete remission (CR) after 1 year (Fig. 3b). The patient still refuses surgery and is therefore being maintained on sirolimus therapy.

Discussion

Loss-of-function mutations in the tumor-suppressor genes *TSC1* or *TSC2* seem to play an important role in the pathomechanism of multiple benign as well as malignant neoplasms, including TSC-associated tumors such as angiofibromas and hamartomas as well as tumors of the PEComa family.

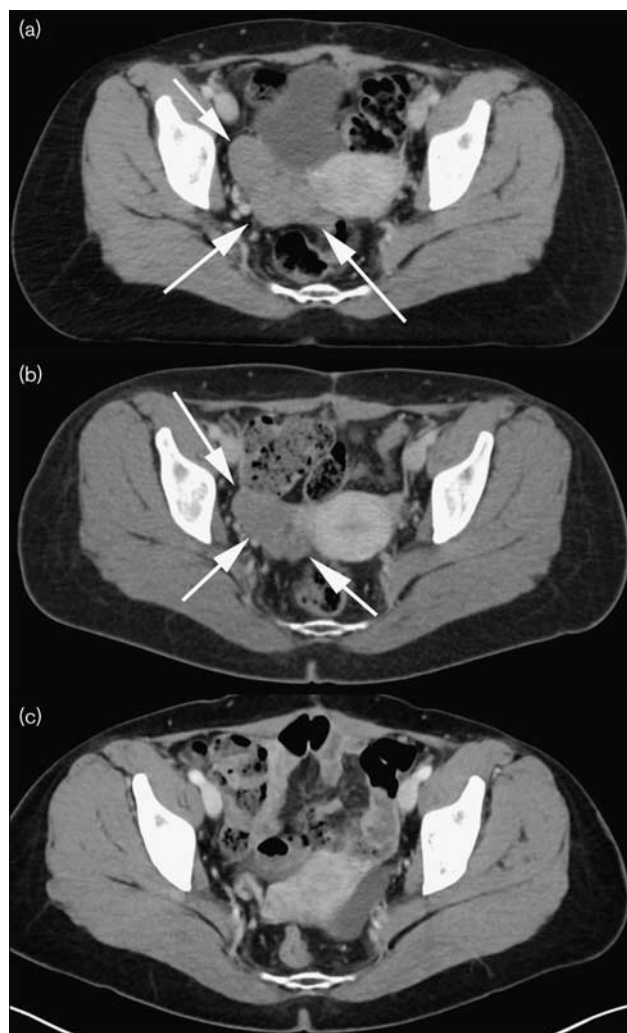
In 70–90% of all patients with the TSC, a germline mutation in the *TSC2* gene or, less often the *TSC1* gene, can be observed. Nevertheless, most PEComas occur sporadically and there is no known association between TSC and malignant PEComa. *TSC2* aberrations are commonly detected in sporadic PEComa [9]. Mutations in the *TSC1* and *TSC2* genes result in hyperactivation of

Fig. 1



Hematoxylin and eosin staining of malignant perivascular epithelioid cell tumor (patient 1).

Fig. 2

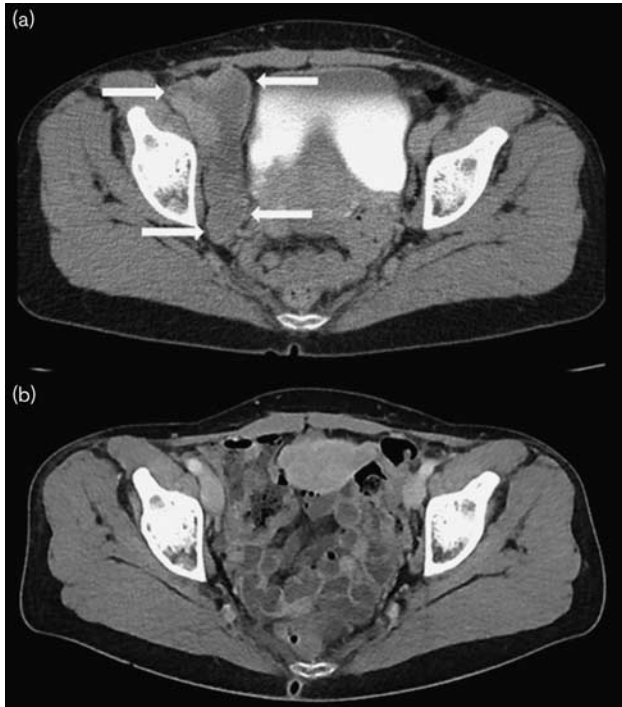


(a) Computed tomography (CT) image at baseline shows the maximal size of the main lesion in the right pelvis. (b) CT image after 6 months of treatment showing a significant decrease in size, consistent with a partial remission. (c) No residual mass or local recurrence after resection and under maintenance therapy with sirolimus. Small amount of fluid in the pelvis.

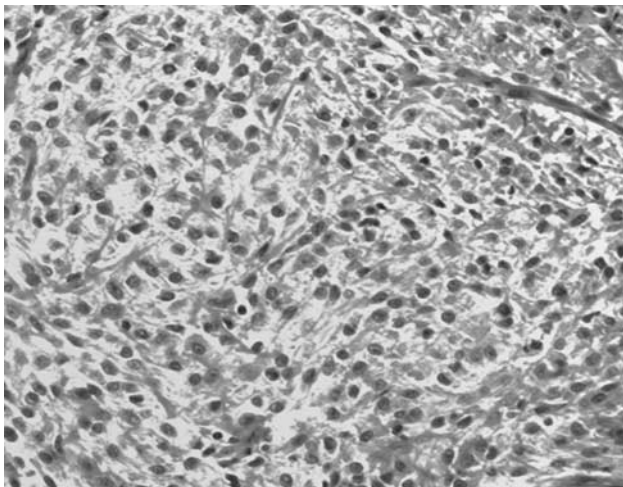
the mTOR signaling pathway and subsequent abnormalities in numerous cell processes.

Kenerson *et al.* [10] first described an aberrant mTOR activity in angiofibromas, CCSTs, LAM, and also in PEComas. As a specific and targeted therapy, the inhibition of the mTOR complex 1 should be a promising therapeutic approach. Sirolimus as a selective mTOR complex 1 inhibitor is approved as an immunosuppressant and used widely to prevent acute and chronic rejection after organ transplantation [11].

As we initiated the therapy of our first patient, only two relevant small series had been published, which indicated

Fig. 3

(a) Computed tomographic image at baseline shows the maximal size of the main lesion in the right iliac fossa. (b) Complete remission after 1 year of treatment with sirolimus. Arrows indicate tumor in the right iliac fossa.

Fig. 4

Hematoxylin and eosin staining of perivascular epithelioid cell tumor (patient 2).

a possible positive effect of sirolimus on patients with tumors of the PEComa family.

Bissler and colleagues published a study of metastatic or locally unresectable, TSC-associated angiomyolipomas in 2008 and showed a significant but nondurable regression

in tumor volume following therapy with sirolimus. In patients with pulmonary lymphangiomyomatosis, he showed a slightly improved lung function [7].

In 2010, the first successful case of treatment of extra-renal malignant PEComa with the mTOR inhibitor sirolimus was published. Three patients were treated; one near CR of a multifocal retroperitoneal disease was observed [8].

Spurred by these promising results, we decided to treat patients in a similar manner. On the basis of the rarity of the disease, there are no current guidelines for treatment. Usually, if possible, a complete resection is recommended. For different reasons, resection was not an option. The first patient had undergone several extensive abdominal resections in the past, whereas for the second patient, a complete resection meant a mutilating surgery.

The results of a successful maintenance therapy with more than 2 years of progression-free survival and a near CR of locally advanced disease with prevention of mutilating surgery are analogous to the results of the early case reports. To date, several small series have been published, mostly with positive results [12]. Dickson *et al.* [9] treated five malignant PEComas and achieved long durable responses including two CR of four of the five treated patients. Currently, the largest series of malignant PEComas treated with sirolimus has been published by Benson *et al.* [13]. Of seven evaluable patients treated with sirolimus five showed partial remission, one showed stable disease, and one showed progressive disease.

Only one report describes the administration of sirolimus in a neoadjuvant setting. Bergamo and colleagues reported a successful neoadjuvant treatment of a localized hepatic PEComa with subsequent resection, but without maintenance therapy.

Our findings confirm the positive results of sirolimus for the treatment of malignant PEComas either in the neoadjuvant setting or as postsurgical maintenance therapy. It has to be mentioned that sirolimus is not labeled for the described use.

Acknowledgements

Conflicts of interest

There are no conflicts of interest.

References

- Martignoni G, Pea M, Reghellin D, Zamboni G, Bonetti F. PEComas: the past, the present and the future. *Virchows Arch* 2008; **452**:119–132.
- Folpe AL, Mentzel T, Lehr HA, Fisher C, Balzer BL, Weiss SW. Perivascular epithelioid cell neoplasms of soft tissue and gynecologic origin: a clinicopathologic study of 26 cases and review of the literature. *Am J Surg Pathol* 2005; **29**:1558–1575.
- Halpenny D, Snow A, McNeill G, Torreggiani WC. The radiological diagnosis and treatment of renal angiomyolipoma – current status. *Clin Radiol* 2010; **65**:99–108.
- Eijkemans MJ, van der Wal W, Reijnders LJ, Roes KC, van Waalwijk van Doorn-Khosrovani SB, Pelletier C, *et al.* Long-term follow-up assessing renal angiomyolipoma treatment patterns, morbidity, and mortality: an

- observational study in tuberous sclerosis complex patients in the Netherlands. *Am J Kidney Dis* 2015; **66**:638–645.
- 5 Taveira-DaSilva AM, Moss J. Clinical features, epidemiology, and therapy of lymphangioleiomyomatosis. *Clin Epidemiol* 2015; **7**:249–257.
 - 6 Folpe AL, Kwiatkowski DJ. Perivascular epithelioid cell neoplasms: pathology and pathogenesis. *Hum Pathol* 2010; **41**:1–15.
 - 7 Bissler JJ, McCormack FX, Young LR, Elwing JM, Chuck G, Leonard JM, et al. Sirolimus for angiomyolipoma in tuberous sclerosis complex or lymphangioleiomyomatosis. *N Engl J Med* 2008; **358**:140–151.
 - 8 Wagner AJ, Malinowska-Kolodziej I, Morgan JA, Qin W, Fletcher CD, Vena N, et al. Clinical activity of mTOR inhibition with sirolimus in malignant perivascular epithelioid cell tumors: targeting the pathogenic activation of mTORC1 in tumors. *J Clin Oncol* 2010; **28**:835–840.
 - 9 Dickson MA, Schwartz GK, Antonescu CR, Kwiatkowski DJ, Malinowska IA. Extrarenal perivascular epithelioid cell tumors (PEComas) respond to mTOR inhibition: clinical and molecular correlates. *Int J Cancer* 2013; **132**:1711–1717.
 - 10 Kenerson H, Folpe AL, Takayama TK, Yeung RS. Activation of the mTOR pathway in sporadic angiomyolipomas and other perivascular epithelioid cell neoplasms. *Hum Pathol* 2007; **38**:1361–1371.
 - 11 Augustine JJ, Bodziak KA, Hricik DE. Use of sirolimus in solid organ transplantation. *Drugs* 2007; **67**:369–391.
 - 12 Bergamo F, Maruzzo M, Basso U, Montesco MC, Zagonel V, Gringeri E, Cillo U. Neoadjuvant sirolimus for a large hepatic perivascular epithelioid cell tumor (PEComa). *World J Surg Oncol* 2014; **12**:46.
 - 13 Benson C, Vitell-Rasmussen J, Maruzzo M, Fisher C, Tunariu N, Mitchell S, et al. A retrospective study of patients with malignant PEComa receiving treatment with sirolimus or temsirolimus: the Royal Marsden Hospital experience. *Anticancer Res* 2014; **34**:3663–3668.