

## RESEARCH PAPER

## Antibodies to MOG and AQP4 in children with neuromyelitis optica and limited forms of the disease

Christian Lechner,<sup>1</sup> Matthias Baumann,<sup>1</sup> Eva-Maria Hennes,<sup>2</sup> Kathrin Schanda,<sup>3</sup> Klaus Marquard,<sup>2</sup> Michael Karenfort,<sup>4</sup> Steffen Leiz,<sup>5</sup> Daniela Pohl,<sup>6</sup> Sunita Venkateswaran,<sup>6</sup> Martin Pritsch,<sup>7</sup> Johannes Koch,<sup>8</sup> Mareike Schimmel,<sup>9</sup> Martin Häusler,<sup>10</sup> Andrea Klein,<sup>11</sup> Astrid Blaschek,<sup>12</sup> Charlotte Thiels,<sup>13</sup> Thomas Lücke,<sup>13</sup> Ursula Gruber-Sedlmayr,<sup>14</sup> Barbara Kornek,<sup>15</sup> Andreas Hahn,<sup>16</sup> Frank Leypoldt,<sup>17,18</sup> Torsten Sandrieser,<sup>19</sup> Helge Gallwitz,<sup>20</sup> Johannes Stoffels,<sup>21</sup> Christoph Korenke,<sup>22</sup> Markus Reindl,<sup>3</sup> Kevin Rostásy<sup>23</sup>

► Additional material is published online only. To view please visit the journal online (<http://dx.doi.org/10.1136/jnnp-2015-311743>)

For numbered affiliations see end of article.

**Correspondence to**

Dr Kevin Rostásy, Department of Pediatric Neurology, Children's Hospital Datteln, University Witten/Herdecke, Dr Friedrich Steiner Str 5, Datteln 45711, Germany; [k.rostasy@kinderklinik-datteln.de](mailto:k.rostasy@kinderklinik-datteln.de)

CL and MB contributed equally to this work.

Received 13 July 2015  
Revised 2 November 2015  
Accepted 11 November 2015  
Published Online First  
8 December 2015



CrossMark

**To cite:** Lechner C, Baumann M, Hennes E-M, et al. *J Neurol Neurosurg Psychiatry* 2016;**87**:897–905.

**ABSTRACT**

**Objective** To determine the frequency and clinical-radiological associations of antibodies to myelin oligodendrocyte glycoprotein (MOG) and aquaporin-4 (AQP4) in children presenting with neuromyelitis optica (NMO) and limited forms.

**Methods** Children with a first event of NMO, recurrent (RON), bilateral ON (BON), longitudinally extensive transverse myelitis (LETM) or brainstem syndrome (BS) with a clinical follow-up of more than 12 months were enrolled. Serum samples were tested for MOG- and AQP4-antibodies using live cell-based assays.

**Results** 45 children with NMO (n=12), LETM (n=14), BON (n=6), RON (n=12) and BS (n=1) were included. 25/45 (56%) children had MOG-antibodies at initial presentation (7 NMO, 4 BON, 8 ON, 6 LETM). 5/45 (11%) children showed AQP4-antibodies (3 NMO, 1 LETM, 1 BS) and 15/45 (33%) were seronegative for both antibodies (2 NMO, 2 BON, 4 RON, 7 LETM). No differences were found in the age at presentation, sex ratio, frequency of oligoclonal bands or median EDSS at last follow-up between the three groups. Children with MOG-antibodies more frequently (1) had a monophasic course (p=0.018) after one year, (2) presented with simultaneous ON and LETM (p=0.004) and (3) were less likely to receive immunosuppressive therapies (p=0.0002). MRI in MOG-antibody positive patients (4) less frequently demonstrated periependymal lesions (p=0.001), (5) more often were unspecific (p=0.004) and (6) resolved more frequently (p=0.016).

**Conclusions** 67% of all children presenting with NMO or limited forms tested positive for MOG- or AQP4-antibodies. MOG-antibody positivity was associated with distinct features. We therefore recommend to measure both antibodies in children with demyelinating syndromes.

**INTRODUCTION**

Neuromyelitis optica (NMO) is characterised by episodes of recurrent unilateral or bilateral optic neuritis (BON) and transverse myelitis (TM).<sup>1</sup> Further diagnostic criteria are the presence of a spinal cord lesion extending over three or more

vertebral segments on MRI, a brain MRI that does not meet the criteria for multiple sclerosis (MS) and the presence of serum aquaporin-4 (AQP4) antibodies. Atypical clinical manifestations such as brainstem syndromes (BS) have been observed in adults and children with AQP4 antibodies, and are included under the umbrella term: NMO spectrum disorders (NMOSD).<sup>2–3</sup> In sera of adult patients with NMOSD, AQP4 antibodies are found in up to 80% of cases and are associated with future relapses or even linked with the conversion to NMO.<sup>4–8</sup> Nevertheless, a subgroup of patients, particularly children with NMO or limited forms such as BON thought to be associated with a subsequent development of NMO, have no detectable AQP4 antibodies. Several studies recently showed that patients with AQP4 antibody seronegative NMO or relapsing optic neuritis (RON) present with antibodies against the myelin oligodendrocyte glycoprotein (MOG). Presence of these antibodies was associated with younger age at presentation, fewer relapses and better outcome.<sup>9–14</sup> MOG antibodies—predominantly of IgG1 isotype—are directed against multiple, extracellular conformational epitopes of MOG on the outmost surface of the myelin sheath, induce complement-mediated cytotoxicity in vitro<sup>15</sup> and appear to transiently disrupt oligodendrocytic microtubule organisation.<sup>16–17</sup> We report the frequency of serum IgG MOG and AQP4 antibodies in children with a first inflammatory, demyelinating event with symptoms potentially indicative of NMO or limited forms of the disease, and further describe their clinical and neuroradiological characteristics.

**METHODS****Patients and samples**

Children referred to our attention with suspected acute inflammatory demyelinating episodes from 12 university hospitals and 8 large community hospitals in Austria, Canada, Germany, Italy and Switzerland, were tested for serum MOG and AQP4 antibodies, and subsequently included in an ongoing prospective study.

From this prospectively followed cohort with a total of 295 patients including children with acute disseminated encephalomyelitis (ADEM), clinical isolated syndromes (eg, ON) or MS, 48 children with the following criteria were selected: (1) initial diagnosis of NMO or limited forms such as isolated longitudinally extensive TM (LETM), BON, BS, recurrent optic neuritis (RON) (2) combined with an MRI non-diagnostic for MS, (3) age of the patient <18 years at time of inclusion, (4) a follow-up interval of at least 12 months and (5) exclusion of alternative diagnoses. Five previously published patients were included as new follow-up information including clinical, imaging and antibody status was obtained.<sup>13 14</sup> Three patients were finally diagnosed with an alternative diagnosis and excluded (mitochondrial encephalomyopathy, lactic acidosis, and stroke-like episodes (n=1), MS (n=2) (figure 1).

Diagnosis of NMO was made according to Wingerchuk *et al*<sup>2</sup> revised diagnostic criteria, requiring ON and acute myelitis, either simultaneously or subsequently, and two of three supportive criteria (LETM, non-MS-like cerebral MRI, AQP4 antibody seropositivity).

Clinical details of the first event were obtained, with a case report form sent to all referring physicians. Clinical follow-up information including neurological symptoms and other sequelae (eg, epilepsy) was obtained via medical reports or a standardised questionnaire filled out by the referring physicians every 6–12 months or at relapses. The Expanded Disability Status Scale (EDSS) scoring system was used to estimate the disability at onset and the clinical outcome.<sup>18</sup>

**Antibody assays**

All serum samples were analysed for the presence of IgG antibodies to MOG and AQP4 by recombinant live cell-based immunofluorescent assays with HEK293A cells, as previously described.<sup>15 19</sup> Initial samples were obtained before anti-inflammatory therapy with steroids was started, in the majority of cases. Screening was performed at dilutions of 1:20 and 1:40 by at least two independent clinically blinded investigators (MR and KS), and antibody titres of positive serum samples were

determine by serial dilutions. MOG antibody titre levels of ≥1:160 were classified as seropositive, as previously described.<sup>19</sup> Serum follow-up samples were available from 28/30 children with MOG or AQP4 antibodies.

**Neuroimaging**

MRI studies from 44/45 children were sent for further evaluation (MB and KR). Only written MRI reports were available in one case with RON. Forty-two of 44 children had a spinal and cerebral MRI. In 38/44 children, MRI was performed on scanners with a field strength of 1.5 T, in 4/44 with 1.5 and 3.0 T scanners, and in 2/44, with 3.0 T scanners. MRI studies were assessed including the following sequences: T2 axial, fluid-attenuated inversion recovery axial, T2 sagittal, T1 axial with contrast medium, spinal cord T2 sagittal and T1 sagittal with contrast medium. MRI follow-up studies were available from 28/45 children and compared in the same fashion as the initial MRIs. In order to compare the initial with the follow-up MRI results, the findings were categorised into four subgroups: complete resolution, mild residuals (few remaining T2 signal changes, but much improved), moderate residuals (only minor improvement of T2 signal changes) and severe residuals (eg, atrophy).

**Statistical analysis**

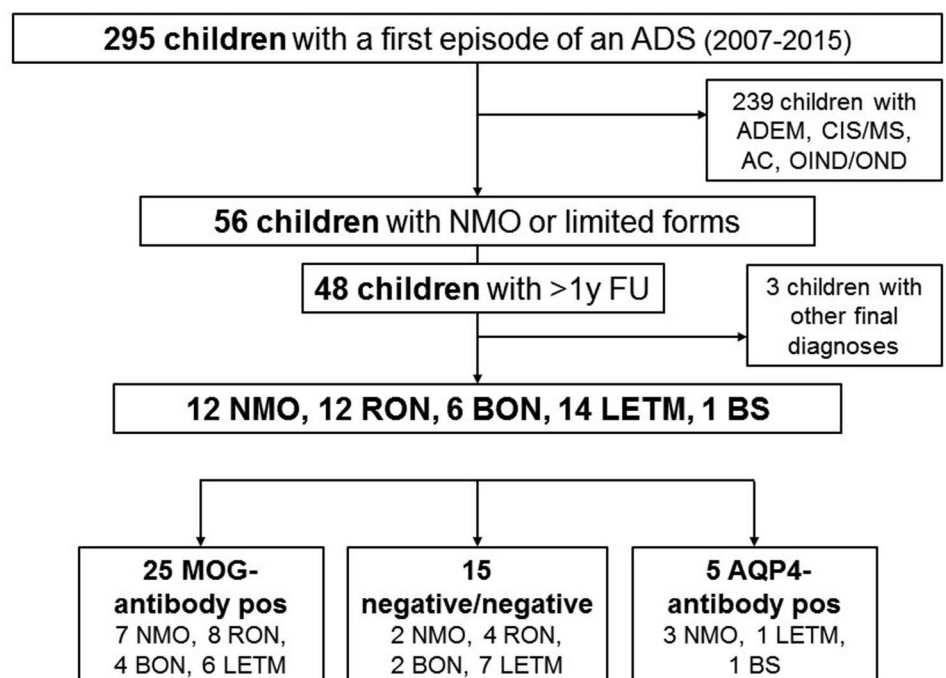
Statistical analysis was performed using IBM SPSS, release V22.0 (IBM Corporation). We compared clinical, demographic, neuroradiological and serological data using the Kruskal-Wallis test and  $\chi^2$  test. Corrected Fisher's exact contingency table analysis was calculated using an online calculator ([http://www.physics.csbsju.edu/stats/exact\\_NROW\\_NCOLUMN\\_form.html](http://www.physics.csbsju.edu/stats/exact_NROW_NCOLUMN_form.html)). Statistical significance was defined as a two-sided p value of <0.05.

**RESULTS**

**Clinical characteristics of children with NMO and limited forms**

Forty-five children were included in the study (23 female/22 male) with a median age at initial presentation of 9 years (range:

**Figure 1** Flow chart study profile (AC, acute cerebellitis; ADEM, acute demyelinating encephalomyelitis; ADS, acquired demyelinating syndromes; AQP4, aquaporin-4; BON, bilateral optic neuritis; BS, brainstem syndrome; CIS, clinical isolated syndrome; FU, follow-up; LETM, longitudinally extensive transverse myelitis; MOG, myelin oligodendrocyte glycoprotein; MS, multiple sclerosis; NMO, neuromyelitis optica; OIND, other inflammatory neurological disease; ON, optic neuritis; OND, other neurological disease; pos, positive; RON, recurrent optic neuritis).



0.75–17 years). The majority of children were Caucasian (n=41/45). Only four children were non-Caucasian (2 Arabs, 1 Pakistani, 1 Tamilian).

At baseline, six children had NMO, 16 LETM, 8 BON and 3 presented with symptoms suggestive of a BS. Twelve children who had initially presented with unilateral ON developed further episodes of ON (n=11) or LETM (n=1), and were retrospectively included and assigned the diagnosis, recurrent ON (RON or NMO (figure 2 and table 1). Cerebrospinal fluid (CSF) studies showed that 24 of 45 (53%) children had a CSF pleocytosis (>4 cells/ $\mu$ L). Six of 45 children had oligoclonal bands (OCBs) in CSF. Forty-four of 45 (98%) children were treated with intravenous methylprednisolone (20 mg/kg/day for 3–5 days). Seven of 44 (16%) children received two or more courses of IVMP. Six of 44 (13%) children were treated additionally with intravenous immunoglobulin. Four of 45 (9%) children also had plasma exchange therapy. One child was exclusively treated with a one-time prednisolone bolus.

All children had a follow-up of at least 12 months. Median overall follow-up of all children was 33 months (range: 12–113 months). During the first 12 months, 17/45 children had further demyelinating episodes and were either assigned the diagnosis RON (n=8) or NMO (n=4), or maintained their initial diagnoses (n=5). Four of eight children with RON had additional relapses after 12 months (see eTable 1).

Another 7/45 children had further demyelinating episodes more than 12 months later and were diagnosed subsequently with NMO (n=2) or RON (n=4) (see eTable 1). One

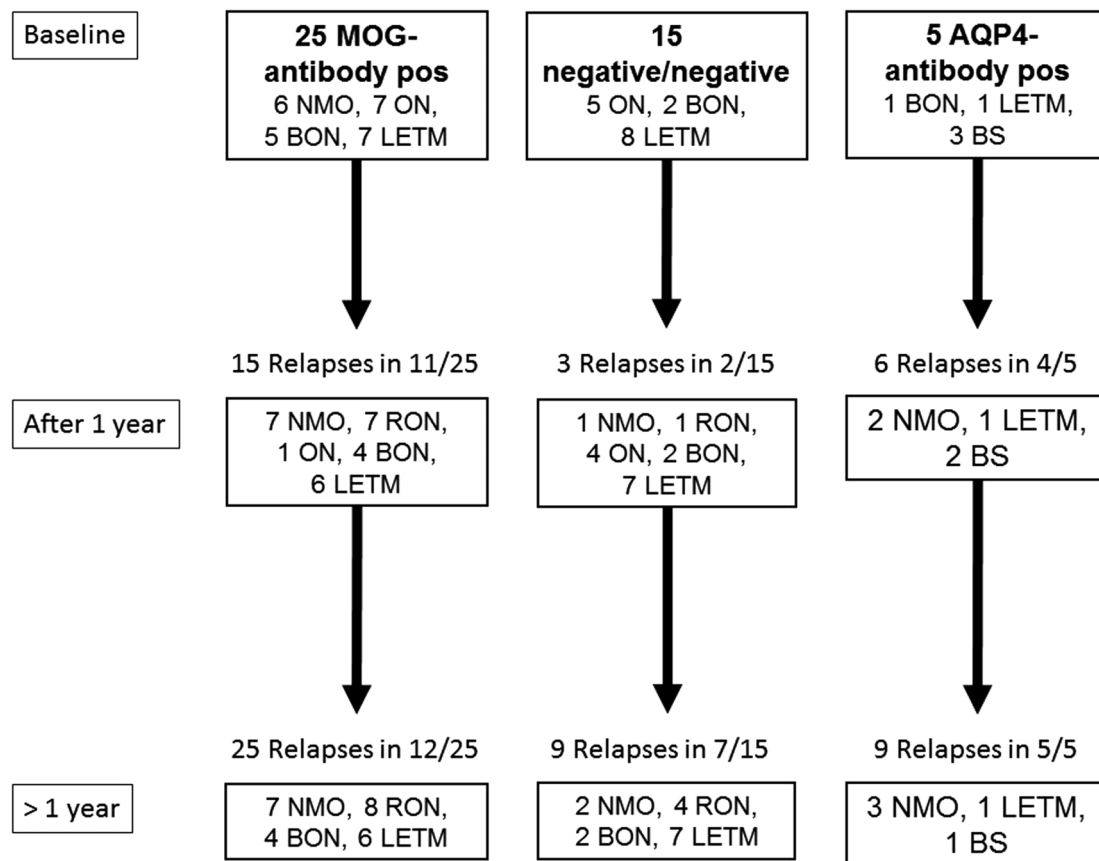
seronegative patient with LETM had two further episodes of LETM (see figure 2 and see eTable 1).

More than half of the children (26/45) showed a good recovery with an EDSS of 0 at final follow-up. Nine of 45 patients had various degrees of visual impairment ranging from a visual acuity (VA) between 0.6 and 0.8 (n=8) or <0.6 (n=1). Nine of 45 children had a range of neurological sequelae such as brisk reflexes (n=2), bladder dysfunction (n=3), abducens nerve palsy (n=1), monoplegia (n=1) or respiratory insufficiency (n=2). One patient with respiratory insufficiency died (pat. 39, see eTables 1 and 2). Another patient (pat. 40) had severe bilateral visual loss and a paraparesis.

Very recently, new international consensus diagnostic criteria for NMOSD were published.<sup>20</sup> We applied these criteria retrospectively on our study group (see eTable 3) with the relevant finding that all AQP4 antibody-positive patients could be diagnosed as NMOSD with AQP4 antibodies. The other nine NMO patients (7 with MOG antibodies, 2 without MOG or AQP4 antibodies) fulfilled criteria for NMOSD without AQP4 antibodies. The remaining patients (6 BON, 12 RON, 13 LETM) could not be diagnosed as NMOSD using the new criteria.

### Serum MOG and AQP4 antibody status at initial clinical presentation and follow-up

Twenty-five (55%) of 45 children (13 female/12 male) with NMO (n=6), ON (n=7), BON (n=5) or LETM (n=7), had a median titre of serum MOG antibodies of 1:1280 (range: 1:160–1:5120). Follow-up serum samples from different time points (range: 1–86 months) were available from 23/25



**Figure 2** Diagnoses at baseline, after 1 year and after more than 1 year (AQP4, aquaporin-4; BON, bilateral optic neuritis; BS, brainstem syndrome; LETM, longitudinally extensive transverse myelitis; MOG, myelin oligodendrocyte glycoprotein; NMO, neuromyelitis optica; ON, optic neuritis; pos, positive; RON, recurrent optic neuritis).

**Table 1** Comparison of demographic data, clinical features and outcome of 45 children with NMO or limited forms of the disease with MOG-IgG, AQP4-IgG or absent antibodies

	MOG-IgG positive (n=25)	AQP4-IgG positive (n=5)	Seronegative (n=15)	p Value
<i>At baseline</i>				
BL MOG-IgG	25 (100.0%)	0 (0.0%)	0 (0.0%)	
Titre	1280 (160–5120)*	0 (0–20)	0 (0–40)	
BL AQP4-IgG	0 (0.0%)	5 (100.0%)	0 (0.0%)	
Titre	0 (0)	320 (20–5120)*	0 (0)	
Females	13 (52.0%)	4 (80.0%)	6 (40.0%)	0.298†
Age at onset (y)	7 (2–15)*	12 (6–14)*	11 (1–17)*	0.193*
Clinical FU (mo)	33 (12–112)*	27 (12–68)*	40 (12–113)*	0.604*
Serological FU (mo)	20 (1–86)*	16 (8–47)*	25 (3–33)*	0.990*
EDSS at BL	5 (2–8.5)*	4 (3–6.5)*	4 (2–9)*	0.803*
<i>Initial diagnosis</i>				
NMO	6 (24.0%)	0 (0.0%)	0 (0.0%)	0.004‡
Unilateral ON	7 (28.0%)	0 (0.0%)	5 (33.3%)	
BON	5 (20.0%)	1 (20.0%)	2 (13.3%)	
LETM	7 (28.0%)	1 (20.0%)	8 (53.3%)	
BS	0 (0.0%)	3 (60.0%)	0 (0.0%)	
Visual acuity at BL	0.06 (0.02–0.7)* n=15	0.2* n=1	0.6 (0.01–0.8)* n=5	0.440*
CSF OCB	2 (8.0%)	2 (40.0%)	2/14 (14.3%)	0.163†
CSF cells >4/μL	13 (52.0%)	5 (100.0%)	6/14 (42.9%)	0.082†
CSF cell count/μL	17 (0–331)*	28 (10–100)*	2 (0–90)*	0.108*
<i>After 12 months</i>				
NMO	7 (28.0%)	2 (40.0%)	1 (6.7%)	0.010‡
Mono ON	1 (4.0%)	0 (0.0%)	4 (26.7%)	
BON	4 (16.0%)	0 (0.0%)	2 (13.3%)	
RON	7 (28.0%)	0 (0.0%)	1 (6.7%)	
LETM	6 (24.0%)	1 (20.0%)	7 (46.7%)	
BS	0 (0.0%)	2 (40.0%)	0 (0.0%)	
Monophasic 1 year	14 (56.0%)	1 (20.0%)	13 (86.7%)	0.018†
Relapses 1 year	1 (1–4)*	2 (1–4)*	1 (1–3)*	0.027*
<i>At last follow-up</i>				
FU MOG-IgG	17/23 (74%)	0/5 (0.0%)	0/6 (0.0%)	
Titre	160 (40–2560)*	0 (0)	0 (0–80)	
FU AQP4-IgG	0/23 (0.0%)	4/5 (80.0%)	0/6 (0.0%)	
Titre	0 (0)	80 (0–5120)*	0	
EDSS at last FU	0 (0–6)*	1 (0–4)*	1 (0–7)*	0.146*
No ON ever	6 (24.0%)	2 (40.0%)	7 (46.7%)	0.402†
Unilateral ON ever	9 (36.0%)	2 (40.0%)	6 (40.0%)	
BON ever	10 (40.0%)	1 (20.0%)	2 (13.3%)	
Myelitis ever	13 (52.0%)	4 (80.0%)	9 (60.0%)	0.500†
LETM ever	13 (52.0%)	3 (60.0%)	9 (60.0%)	0.866†
Brainstem ever	1 (4.0%)	3 (60.0%)	1 (6.7%)	0.001†
<i>Final diagnosis</i>				
NMO	7 (28.0%)	3 (60.0%)	2 (13.3%)	0.169‡
BON	4 (16.0%)	0 (0.0%)	2 (13.3%)	
RON	8 (32.0%)	0 (0.0%)	4 (26.7%)	
LETM	6 (24.0%)	1 (20.0%)	7 (46.7%)	
BS	0 (0.0%)	1 (20.0%)	0 (0.0%)	
<i>NMO</i>				
Simultaneous	6 (85.7%)	0 (0.0%)	0 (0.0%)	0.015‡
Sequential	1 (14.3%)	3 (100.0%)	2 (100.0%)	
<i>Systems affected</i>				
NMO	7 (28.0%)	3 (60.0%)	2 (13.3%)	0.042‡
Isolated ON	12 (48.0%)	0 (0.0%)	6 (40.0%)	
Isolated LETM	6 (24.0%)	1 (20.0%)	7 (46.2%)	
Isolated brainstem	0 (0%)	1 (20.0%)	0 (0.0%)	
Monophasic	13 (52.0%)	0 (0.0%)	8 (53.3%)	0.095‡
Relapses	1 (1–5)*	2 (2–4)*	1 (1–3)*	0.107*

Continued

Table 1 Continued

	MOG-IgG positive (n=25)	AQP4-IgG positive (n=5)	Seronegative (n=15)	p Value
Recovery				
Complete	17 (68.0%)	3 (60.0%)	6/14 (42.8%)	0.478‡
Minor residuals	7 (28.0%)	2 (40.0%)	6/14 (42.8%)	
Severe residuals	1 (4.0%)	0 (0.0%)	2/14 (14.3%)	
No therapy	16 (64.0%)	0 (0.0%)	13 (86.7%)	0.0002‡
Immunosuppression	3 (12.0%)	5 (100.0%)	2 (13.3%)	
Immunomodulation	6 (24.0%)	0 (0.0%)	0 (0.0%)	
Visual acuity at FU	1.0 (0.8–1.0)* n=18	1* n=1	0.9 (0.3–1.0)* n=8	0.207*

\*Median (range), Kruskal-Wallis test.

† $\chi^2$  test.

‡Corrected Fisher's exact contingency table analysis.

AQP4, aquaporin-4; BL, baseline; BON, bilateral optic neuritis; BS, brainstem syndrome; CSF, cerebrospinal fluid; EDSS, Expanded Disability Status Scale; FU, follow-up; LETM, longitudinally extensive transverse myelitis; MOG, myelin oligodendrocyte glycoprotein; NMO, neuromyelitis optica; OCB, oligoclonal band; ON, optic neuritis; RON, recurrent optic neuritis.

children, revealing that 17 children were still seropositive for MOG antibodies with a median titre of 1:160 (range: 1:40–1:2560) after median serological follow-up of 20 months (table 1).

Five (9%) of 45 patients with LETM, BON or BS (n=3) had detectable serum AQP4 antibodies (median titre: 1:320; range: 1:20–1:5120). Four of five AQP4 antibody seropositive patients still showed antibodies after a median serological follow-up of 16 months (range: 9–47), with a median titre of 1:80 (range: 0–1:5120).

Fifteen (33%) of 45 children had neither MOG nor AQP4 antibodies at initial presentation. From six children, follow-up samples (median 25 months; range: 3–33) were available and remained negative for serum MOG and AQP4 antibodies.

### Neuroimaging features at disease onset and follow-up of children with MOG, AQP4 or with absent antibodies

Cerebral MRI was performed in all patients at initial presentation. Thirty-nine of 45 children also underwent a spinal MRI (table 2).

All characteristic MRI findings of NMO, such as medullary lesions (figure 3A), hypothalamic and periaqueductal lesions (figure 3B), LETM (figure 3C), ON (figure 3D), area postrema and corpus callosum lesions (figure 3E), and unspecific periventricular lesions (figure 3F), were found in the five AQP4 antibody-positive patients, although in one patient, not all types of lesions were found. The lesions appeared sequentially (figure 3A–D), or were detected only partially (figure 3E–H). Also, in MOG antibody-positive patients, typical lesions for NMOSD, such as periependymal lesions or rostral extending LETM, were found (figure 3I–K). All patients with an acute myelitis showed lesions extending over three vertebral segments (LETM). LETM was detected in 1/5 AQP4 antibody-positive (figure 3G), 13/25 MOG antibody-positive (figure 3K) and in 8/15 seronegative patients at baseline (table 2). Lesions spanned more than 10 vertebral segments in 1/1 AQP4 antibody-positive, in seven (54%) of 13 MOG antibody-positive and in five (63%) of eight seronegative patients. Rostral extension of cervical lesions into the medulla oblongata was found in 3/13 MOG antibody-positive (figure 3K) and in none of the AQP4 antibody-positive patients. Involvement of the conus was found in 5/13 MOG antibody-positive patients, 4/8 seronegative patients, and not in the AQP4 antibody-positive patient with LETM at baseline. One AQP4 antibody-positive patient, who initially had no spinal lesion but

subsequently developed a LETM, also showed involvement of the conus (pat. 27).

Characteristic lesions around the third ventricle, the aqueduct, or adjacent to the fourth ventricle, were found only in 3/5 AQP4 antibody-positive (figure 3B), 2/25 MOG antibody-positive children (figure 3I, J), and in none of the seronegative children. Small and well-defined lesions were found in 3/5 AQP4 antibody-positive (figure 3F, H), 1/25 MOG antibody-positive

Table 2 Comparison of MRI of 45 children with NMO or limited forms of the disease with MOG-IgG, AQP4-IgG or absent antibodies

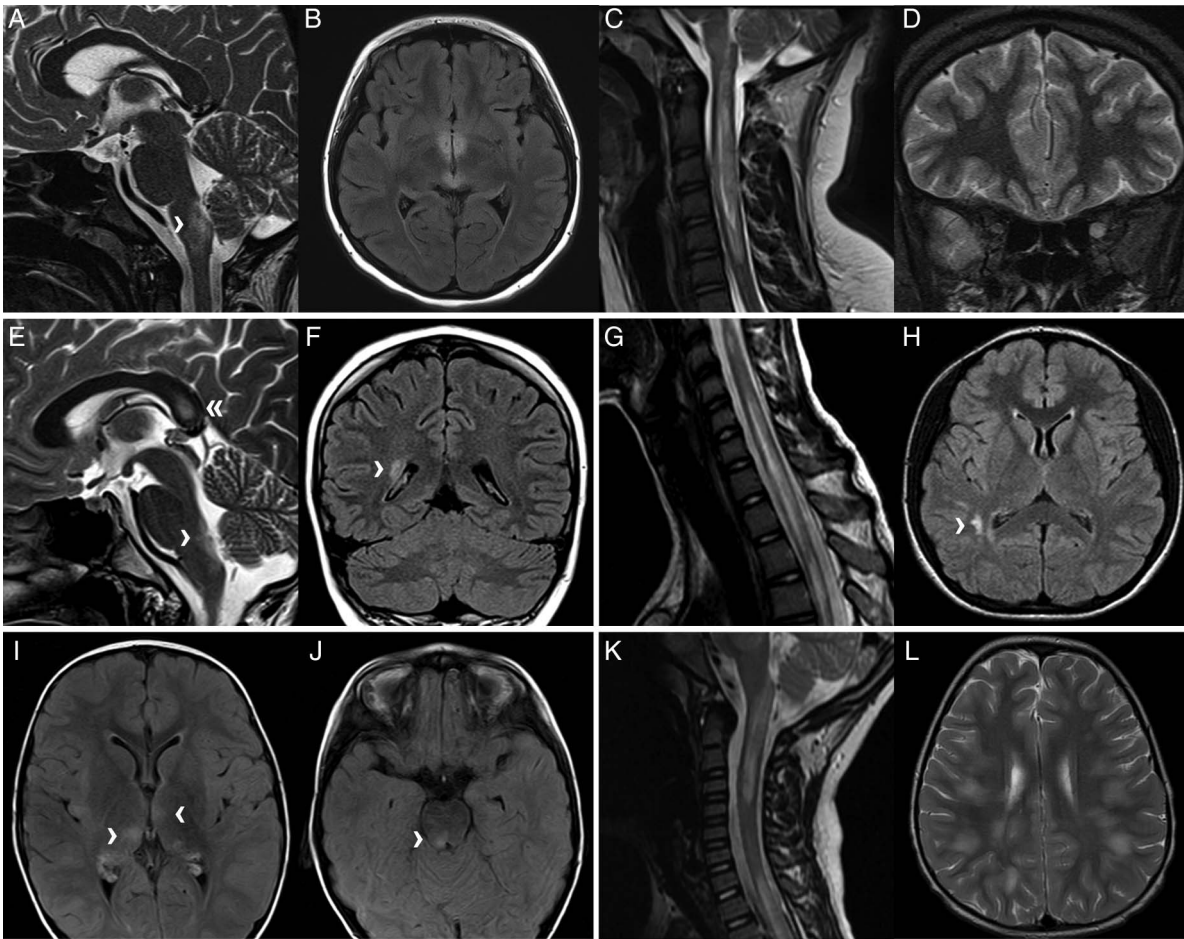
	MOG-IgG positive (n=25)	AQP4-IgG positive (n=5)	Seronegative (n=15)	p Value
MRI at baseline				
Normal MRI	6 (24.0%)	0 (0.0%)	5 (33.3%)	0.012*
ON	3 (12.0%)	1 (20.0%)	1 (6.7%)	
LETM	5 (20.0%)	1 (20.0%)	7 (46.7%)	
NMO like	1 (4.0%)	3 (60.0%)	0 (0.0%)	
Unspecific lesions	1 (4.0%)	0 (0.0%)	1 (6.7%)	
Blurred+ON or LETM	9 (36.0%)	0 (0.0%)	1 (6.7%)	
MRI-ON	6 (24.0%)	1 (20.0%)	1 (6.7%)	0.378*
MRI-LETM	13 (52.0%)	1 (20.0%)	8 (53.3%)	0.390*
Periependymal	2 (8.0%)	3 (60.0%)	0 (0.0%)	0.001*
Blurred lesions	9 (36.0%)	0 (0.0%)	1 (6.7%)	0.043*
Unspecific lesions	1 (4.0%)	3 (60.0%)	2 (13.3%)	0.004*
MRI at follow-up				
MRI follow-up				
BL+FU normal	4/15 (26.7%)	0/4 (0.0%)	4/9 (44.4%)	0.246‡
FU normal	6/15 (40.0%)	1/4 (25.0%)	2/9 (22.2%)	
Mild residuals	5/15 (33.3%)	1/4 (25.0%)	2/9 (22.2%)	
Moderate residuals	0/15 (0.0%)	1/4 (25.0%)	0/9 (0.0%)	
Severe residuals	0/15 (0.0%)	1/4 (25.0%)	1/9 (11.1%)	
Moderate/severe MRI residuals	0/15 (0.0%)	2/4 (50.0%)	1/9 (11.1%)	0.018‡

\* $\chi^2$  test.

†Median (range), Kruskal-Wallis test.

‡Corrected Fisher's exact contingency table analysis.

AQP4, aquaporin-4; BL, baseline; FU, follow-up; LETM, longitudinally extensive transverse myelitis; MOG, myelin oligodendrocyte glycoprotein; NMO, neuromyelitis optica; ON, optic neuritis.



**Figure 3** MRI of children with neuromyelitis optica (NMO) and related disorders. (A–D) Imaging of a 12-year-old girl (pat. 27, see eTables 1 and 2) with aquaporin-4 (AQP4) antibody-positive NMO, who presented with vomiting, lower cranial nerve dysfunction, paraesthesia of the arms and legs and paraparesis. The initial MRI (A, sagittal T2) revealed a medullary lesion (arrowhead). Three months later, hypothalamic and periaqueductal lesions appeared (B, axial fluid-attenuated inversion recovery (FLAIR)), 4 months later a longitudinally extensive transverse myelitis (LETM) was noted (C, sagittal T2), and 7 months later an optic neuritis was seen (D, coronar T2). (E and F) The cerebral MRI of a 14-year-old boy (pat. 28) with AQP4 antibody-positive NMOSD, who presented with left facial sensory and motor deficit, vomiting and singultus, showed lesions in the area postrema (arrowhead) and corpus callosum (double arrowhead) (E, sagittal T2), and an unspecific periventricular lesion (arrowhead) (F, coronar-FLAIR). (G and H) MRI of a 13-year-old girl (pat. 29) with AQP4 antibody-positive LETM, who presented with paraparesis and bladder dysfunction, showed an LETM extending over more than 10 segments (G, sagittal T2), and unspecific right parietal lesions (arrowhead) (H, axial-FLAIR). (I and J) MRI of a 4-year-old boy (pat. 8) with myelin oligodendrocyte glycoprotein (MOG) antibody-positive LETM, who presented with paraparesis and dysesthesia, revealed in addition to the LETM lesions around the third (I) and fourth ventricle (arrowheads) (J, both axial-FLAIR). (K and L) MRI of a 5-year-old boy (pat. 6) with MOG antibody-positive LETM, who presented with weakness and pain in the lower limbs, and bowel and bladder dysfunction, showed a LETM extending rostral into the medulla (K, sagittal T2) and blurred supratentorial lesions (L, axial T2).

and 2/15 seronegative patients. Blurred, hazy and large (ADEM-like) lesions in supratentorial white matter, basal ganglia, thalamus, or brainstem, were not present in AQP4 antibody positive, but were seen in 9/25 of the MOG antibody-positive (figure 3L) and, rarely, in seronegative children (n=1). In MOG antibody-positive patients, blurred lesions were combined with LETM in 7/9 and with ON in 2/9 patients.

MRI follow-up at least 1 month after the first event was available for 4/5 AQP4 antibody-positive, 15/25 MOG antibody-positive and 9/15 seronegative patients. Residual findings were grouped as mild, moderate or severe.

Spinal MRI follow-up showed that the AQP4 antibody-positive patient with LETM at initial presentation still had severe residual lesions 5 months later. In the MOG antibody-positive patients with LETM, MRI follow-up revealed a complete resolution of the lesions in 6/8 patients and minor residuals in 2/8. Three of four seronegative patients had a complete

resolution of the LETM and one child still had severe residual lesions (table 2).

Brainstem lesions around the third ventricle, aqueduct, or fourth ventricle, resolved in all AQP4 and MOG antibody-positive patients with a MRI follow-up (n=4). Supratentorial lesions almost completely resolved in all MOG antibody-positive patients (n=6), while only 2/4 AQP4 antibody-positive patients had complete resolution of parenchymal lesions (table 2).

#### Comparison of clinical and radiological features of MOG, AQP4 positive and seronegative children

At initial manifestation, children with AQP4 antibodies were slightly older, although not statistically significantly, than MOG antibody-positive or seronegative patients (table 1). Also, no differences were found between the three groups with regard to the frequency of OCBs, number of CSF cells, male to female

ratio, EDSS at follow-up evaluation, or severity of visual loss at initial presentation or at recovery (table 1).

Depending on the antibody studies, however, the following important differences between the three groups of children were noted (table 1): (1) Children with involvement of the optic nerve including NMO, BON and unilateral ON with subsequent recurrent attacks of ON were more likely to have MOG than to have AQP4 or absent antibodies. (2) None of the five children with AQP4 antibodies presented with simultaneous ON and TM. (3) All children presenting with sole symptoms suggestive of a BS had AQP4 antibodies. (4) Children with AQP4 antibodies were less likely to have a monophasic course, had more demyelinating episodes after 1 year and were treated more often with immunosuppressive/immunomodulating therapies. (5) MRI at baseline of children with MOG antibodies was much more likely to show (1) a normal cerebral MRI or (2) an ADEM-like pattern with hazy, blurry, widespread lesions in the context of limited forms of the disease and (3) a significantly better resolution of MRI signal changes, compared to children with AQP4 seropositive NMOSD.

## DISCUSSION

We report the frequency of serum MOG and AQP4 antibodies in 45 children with NMO or with limited forms of the disease. More than half of all children including those presenting with an NMO phenotype had serum MOG antibodies, while AQP4 antibodies were only detected in a small subgroup of children, all of whom presented initially with only a single clinical core feature of NMOSD.

MOG antibodies have been recently reported in a variety of paediatric demyelinating disease phenotypes including children with ADEM and recurrent ON, and in a group of young patients with ADEM-like onset followed by monophasic or recurrent ON (ADEM-ON).<sup>14 21 22</sup> MOG seropositivity has also been reported in a subset of adults and children with AQP4 antibody seronegative NMO and NMOSD.<sup>10-13</sup> Reported frequencies of positive MOG antibodies in adult cohorts of patients with NMOSD vary between 7.4% and 39%, which is most likely also influenced by different MOG antibody assays and referral bias.<sup>11 12</sup> Taken together, these studies indicate that patients with NMOSD with MOG antibodies have fewer attacks, BON and more caudal myelitis, and tend to better recover than patients with AQP4 antibodies and those who were seronegative for both antibodies.<sup>11 23</sup> In our cohort, children with MOG antibodies were also less likely to have relapses, less often treated with immunosuppressive or immunomodulating therapies and less likely to have residual lesions on MRI follow-up studies.

In the past, MOG antibodies have been thought to be associated with the pathological events leading to MS. However, two studies have shown that MOG antibodies are nearly exclusively found in children with monophasic or relapsing events other than MS.<sup>24 25</sup> Ketelslegers *et al* found only one of 47 children who were finally diagnosed with MS as having MOG antibodies at initial presentation, pleading strongly against a MS diagnosis in children with acquired demyelinating syndromes and positive MOG antibodies.<sup>25</sup>

Two-thirds of all children with MOG antibodies had involvement of the optic nerves in our cohort, suggesting that the optic nerves are prime targets in the disease process for reasons that are not entirely resolved. MOG antibodies were also detected in children with LETM, which is in contrast to adults with LETM, who show higher frequencies of AQP4 antibodies in addition to a higher relapse rate and a high risk for sequential NMO.<sup>26</sup> In

our cohort, the majority of children with LETM and MOG antibodies (5/7) had a single episode and no further relapses such as ON or LETM after a median follow-up of 30 months. Only one child with LETM and MOG antibodies had a second episode of LETM and another MOG antibody-positive patient with LETM had a subsequent episode of ON and was thus diagnosed as NMO (see eTable 1). MRI findings in children with AQP4 antibodies and NMOSD in contrast to children with MOG antibodies have recently been reported in more detail. Children with NMOSD and AQP4 antibodies, similarly to adults, have lesions that follow the distribution of AQP4-rich areas in the brain.<sup>27-29</sup> Brain lesions are primarily found in the periventricular region of the third ventricle, in the periaqueductal grey matter and in the dorsal brainstem adjacent to the fourth ventricle. In our series, all AQP4 antibody-positive patients had a range of signal changes including the characteristic lesions around the third ventricle and fourth ventricle or aqueduct. However, two children with MOG antibodies and LETM also had periependymal lesions near the third and fourth ventricle, indistinguishable from AQP4 antibody-positive NMO. A recent study of adult patients with NMOSD also found that lesions adjacent to the fourth ventricle were common in MOG antibody-positive patients.<sup>23</sup>

LETM is the most specific radiological finding supporting the diagnosis of NMO in adults and usually prompts the clinician to test for AQP4 antibodies. In children, however, LETM appears to be less specific and can also be found in ADEM or MS.<sup>30 31</sup> In our cohort, LETM was found in all three patient groups with some important associated features in children with MOG antibodies, such as widespread and rostral extension into the medulla in addition to blurred, hazy and widespread lesions reminiscent of ADEM. This pattern of blurred, hazy and widespread lesions also affecting the spinal cord was recently described in children with ADEM and high titre MOG antibodies.<sup>31</sup> The spinal lesions in MOG antibody-positive patients did not involve the conus more frequently, unlike in adult cases.<sup>11 23</sup> As in MOG antibody-positive ADEM, the MRI lesions in children with NMO phenotype and MOG antibodies resolved whereas AQP4 antibody-positive patients still showed major signal alterations on follow-up studies.

Our findings in children with an NMO phenotype, MOG antibodies and an ADEM-like MRI underscore the point that MOG antibody-positive demyelinating diseases are not separate disease entities. More likely they represent a continuum with overlapping features including children with BON and LETM, and should be classified in the future under the umbrella MOG antibody-positive diseases. This is in line with a recent paper by Zamvil and Slavin,<sup>32</sup> who also suggested that MOG-positive NMO phenotype should not be included under the term NMOSD.

In our study, we focused on children presenting with NMO and limited forms, and the respective antibody status, and found that MOG antibodies are present in a substantial number of patients. In order to better define the whole spectrum of MOG-positive disease manifestations, one possibility would have been to include all children with an acute demyelinating event and positive MOG antibodies, which will be the focus of an ongoing research project.

Very recently, an international panel of experts published new consensus guidelines for adults and children with NMOSD. The new guidelines appreciate the wider spectrum of symptoms in the context of AQP4 antibody positivity, and demand more stringent clinical and MRI criteria for patients who are AQP4 antibody negative.<sup>20</sup>

We retrospectively analysed our clinical data and found that all our children with AQP4 antibodies fulfilled the criteria for NMOSD (see eTable 3). In addition, MOG antibody-positive children with the core symptoms of ON and TM with LETM also fulfilled the additional MRI criteria recommended by the new guidelines and can therefore be grouped as NMOSD without AQP4 antibodies. The new guidelines also appreciate that limited forms such as BON appear to have a higher risk of subsequent demyelinating episodes other than MS and that the presence of LETM in children is not pathognomonic for NMOSD.

We believe that, particularly in children with NMOSD and limited forms such as sole BON or LETM, a larger proportion than previously thought have other autoantibodies including MOG antibodies and that in the future the antibody status should be considered for the clinical diagnosis.

## CONCLUSIONS

As more than half of the included children had MOG antibodies, we recommend MOG antibody testing in patients with suspected NMOSD. As case numbers are small due to the rarity of these disorders in paediatric patients, further collaborative studies, especially regarding outcome, relapse rate and the appropriate treatment, are needed.

## Author affiliations

<sup>1</sup>Division of Pediatric Neurology, Department of Pediatrics I, Medical University of Innsbruck, Innsbruck, Austria

<sup>2</sup>Department of Pediatric Neurology, Olgahospital Stuttgart, Stuttgart, Germany

<sup>3</sup>Clinical Department of Neurology, Medical University of Innsbruck, Innsbruck, Austria

<sup>4</sup>Department of Pediatric Neurology, University Children's Hospital Dusseldorf, Dusseldorf, Germany

<sup>5</sup>Department of Pediatric Neurology, Children's Hospital Dritter Orden, Munich, Germany

<sup>6</sup>Division of Neurology, Children's Hospital of Eastern Ontario, Ottawa, Canada

<sup>7</sup>Department of Pediatric Neurology, DRK Children's Hospital Siegen, Siegen, Germany

<sup>8</sup>Department of Pediatrics, Paracelsus Medical University Salzburg, Salzburg, Austria

<sup>9</sup>Department of Pediatric Neurology, Children's Hospital Augsburg, Augsburg, Germany

<sup>10</sup>Division of Neuropediatrics and Social Pediatrics, University Hospital, RWTH Aachen, Aachen, Germany

<sup>11</sup>Department of Pediatric Neurology, University Children's Hospital Zurich, Zurich, Switzerland

<sup>12</sup>Department of Pediatric Neurology and Developmental Medicine, Dr von Hauner's Children's Hospital, Ludwig Maximilian University of Munich, Munich, Germany

<sup>13</sup>Department of Pediatric Neurology with Social Pediatrics, Children's Hospital, Ruhr University Bochum, Bochum, Germany

<sup>14</sup>Department of Pediatrics, Medical University of Graz, Graz, Austria

<sup>15</sup>Department of Neurology, Medical University of Vienna, Vienna, Austria

<sup>16</sup>Department of Pediatric Neurology, University Children's Hospital Giessen, Giessen, Germany

<sup>17</sup>Department of Neuroimmunology, Institute of Clinical Chemistry, Kiel, Germany

<sup>18</sup>Department of Neurology, University Hospital Schleswig-Holstein Campus Kiel, Kiel, Germany

<sup>19</sup>Department of Pediatric Neurology, Children's Hospital Koblenz, Koblenz, Germany

<sup>20</sup>Department of Pediatric Neurology, Children's Hospital Memmingen, Memmingen, Germany

<sup>21</sup>Department of Pediatric Neurology, Children's Hospital Neuburg, Neuburg, Germany

<sup>22</sup>Department of Pediatric Neurology, University Children's Hospital Oldenburg, Oldenburg, Germany

<sup>23</sup>Department of Pediatric Neurology, Children's Hospital Datteln, University Witten/Herdecke, Datteln, Germany

**Contributors** CL and MB were involved in design, data acquisition, drafting and revising the manuscript, and final approval of the version to be published. E-MH, KS, KM, MK, SL, DP, SV, MP, JK, MS, MH, AK, AB, CT, TL, UG-S, BK, AH, FL, TS, HG, JS and CK were responsible for data acquisition, revising the manuscript and final approval. MR and KR participated in design, data acquisition, analysis, final

approval of the version to be published and the data in the study and take responsibility for the integrity of the data and the accuracy of the data analysis.

**Funding** Supported by grant number 14158 from the Jubilaeumsfonds of the Austrian National Bank (KR) and research grant 'BIG WIG MS' from the Austrian Federal Ministry of Science, Research and Economy (MR).

**Competing interests** KS, MR received payments for antibody assays (AQP4 and other antineuronal and antiglial antibodies). MR is the academic editor for *PLoS ONE*, research support from the Austrian Science Fund and the Austrian Federal Ministry of Science, Research and Economy. KR received grant from the Austrian National Bank (Jubilaeumsfonds). FL received speaker's honoraria from Biogen, Teva and Grifols.

**Ethics approval** The study was approved by the Ethics Committee of the Innsbruck Medical University, Austria (study number AM4059). All parents and patients (older than 12 years) consented to the study with consent forms issued by the study centre.

**Provenance and peer review** Not commissioned; externally peer reviewed.

## REFERENCES

- 1 Wingerchuk DM, Lennon VA, Lucchinetti CF, *et al.* The spectrum of neuromyelitis optica. *Lancet Neurol* 2007;6:805–15.
- 2 Wingerchuk DM, Lennon VA, Pittock SJ, *et al.* Revised diagnostic criteria for neuromyelitis optica. *Neurology* 2006;66:1485–9.
- 3 Arrambide G, Rovira A, Tur C, *et al.* NMO spectrum disorders: how wide is the spectrum? *Mult Scler* 2014;20:1417.
- 4 Jarius S, Probst C, Borowski K, *et al.* Standardized method for the detection of antibodies to aquaporin-4 based on a highly sensitive immunofluorescence assay employing recombinant target antigen. *J Neurol Sci* 2010;291:52–6.
- 5 Jarius S, Frederikson J, Waters P, *et al.* Frequency and prognostic impact of antibodies to aquaporin-4 in patients with optic neuritis. *J Neurol Sci* 2010;298:158–62.
- 6 Weinschenker BG, Wingerchuk DM, Vukusic S, *et al.* Neuromyelitis optica IgG predicts relapse after longitudinally extensive transverse myelitis. *Ann Neurol* 2006;59:566–9.
- 7 Chang KH, Lyu RK, Chen CM, *et al.* Distinct features between longitudinally extensive transverse myelitis presenting with and without anti-Aquaporin 4 antibodies. *Mult Scler* 2013;19:299–307.
- 8 Nishiyama S, Ito T, Misu T, *et al.* A case of NMO seropositive for aquaporin-4 antibody more than 10 years before onset. *Neurology* 2009;72:1960–1.
- 9 Kitley J, Woodhall M, Waters P, *et al.* Myelin-oligodendrocyte glycoprotein antibodies in adults with a neuromyelitis optica phenotype. *Neurology* 2012;79:1273–7.
- 10 Höftberger R, Sepulveda M, Armangue T, *et al.* Antibodies to MOG and AQP4 in adults with neuromyelitis optica and suspected limited forms of the disease. *Mult Scler* 2015;21:866–74.
- 11 Sato DK, Callegaro D, Lana-Peixoto MA, *et al.* Distinction between MOG antibody-positive and AQP4 antibody-positive NMO spectrum disorders. *Neurology* 2014;82:474–81.
- 12 Ramanathan S, Reddel SW, Henderson A, *et al.* Antibodies to myelin oligodendrocyte glycoprotein in bilateral and recurrent optic neuritis. *Neurol Neuroimmunol Neuroinflamm* 2014;1:e40.
- 13 Rostásy K, Mader S, Hennes EM, *et al.* Persisting myelin oligodendrocyte glycoprotein antibodies in aquaporin-4 antibody negative pediatric neuromyelitis optica. *Mult Scler* 2013;19:1052–9.
- 14 Rostásy K, Mader S, Schanda K, *et al.* Anti-myelin oligodendrocyte glycoprotein antibodies in pediatric patients with optic neuritis. *Arch Neurol* 2012;69:752–6.
- 15 Mader S, Gredler V, Schanda K, *et al.* Complement activating antibodies to myelin oligodendrocyte glycoprotein in neuromyelitis optica and related disorders. *J Neuroinflammation* 2011;8:184.
- 16 Mayer MC, Breithaupt C, Reindl M, *et al.* Distinction and temporal stability of conformational epitopes on myelin oligodendrocyte glycoprotein recognized by patients with different inflammatory central nervous system diseases. *J Immunol* 2013;191:3594–604.
- 17 Dale RC, Tantsis EM, Merheb V, *et al.* Antibodies to MOG have a demyelination phenotype and affect oligodendrocyte cytoskeleton. *Neurol Neuroimmunol Neuroinflamm* 2014;1:e12.
- 18 Kurtzke JF. Rating neurologic impairment in multiple sclerosis: an expanded disability status scale (EDSS). *Neurology* 1983;33:1444–52.
- 19 Di Pauli F, Mader S, Rostásy K, *et al.* Temporal dynamics of anti-MOG antibodies in CNS demyelinating diseases. *Clin Immunol* 2011;138:247–54.
- 20 Wingerchuk MD, Banwell B, Bennett JF, *et al.* International consensus diagnostic criteria for neuromyelitis optica spectrum disorders. *Neurology* 2015;85:177–89.
- 21 Huppke P, Rostásy K, Karenfort M, *et al.* Acute disseminated encephalomyelitis followed by recurrent or monophasic optic neuritis in pediatric patients. *Mult Scler* 2013;19:941–6.



- 22 Pittock SJ, Lennon VA, Krecke K, *et al.* Brain abnormalities in neuromyelitis optica. *Arch Neurol* 2006;63:390–6.
- 23 Kitley J, Waters P, Woodhall M, *et al.* Neuromyelitis optica spectrum disorders with aquaporin-4 and myelin-oligodendrocyte glycoprotein antibodies: a comparative study. *JAMA Neurol* 2014;71:276–83.
- 24 Ketelslegers IA, Van Pelt DE, Bryde S, *et al.* Anti-MOG antibodies plead against MS diagnosis in an Acquired Demyelinating Syndromes cohort. *Mult Scler* 2015;21:1513–20.
- 25 Hacohen Y, Absoud M, Deiva K. Myelin oligodendrocyte glycoprotein antibodies are associated with a non-MS course in children. *Neurol Neuroimmunol Neuroinflamm* 2015;2:e81.
- 26 Jiao Y, Fryer JP, Lennon VA, *et al.* Aquaporin 4 IgG serostatus and outcome in recurrent longitudinally extensive transverse myelitis. *JAMA Neurol* 2014;71:48–54.
- 27 McKeon A, Lennon VA, Lotze T, *et al.* CNS aquaporin-4 autoimmunity in children. *Neurology* 2008;71:93–100.
- 28 Kim HJ, Paul F, Lana-Peixoto MA, *et al.* MRI characteristics of neuromyelitis optica spectrum disorder: an international update. *Neurology* 2015;84:1165–73.
- 29 Tillema JM, McKeon A. The spectrum of neuromyelitis optica (NMO) in childhood. *J Child Neurol* 2012;27:1437–47.
- 30 Banwell B, Tenenbaum S, Lennon VA, *et al.* Neuromyelitis optica-IgG in childhood inflammatory demyelinating CNS disorders. *Neurology* 2008;70:344–52.
- 31 Baumann M, Sahin K, Lechner C, *et al.* Clinical and neuroradiological differences of paediatric acute disseminating encephalomyelitis with and without antibodies to the myelin oligodendrocyte glycoprotein. *J Neurol Neurosurg Psychiatry* 2015;86:265–72.
- 32 Zamvil SS, Slavin AJ. Does MOG Ig-positive AQP4-seronegative opticospinal inflammatory disease justify a diagnosis of NMO spectrum disorder? *Neurol Neuroimmunol Neuroinflamm* 2015;2:e62.