

# The detrimental potential of arrhythmia-induced cardiomyopathy

Jörg Eiringhaus<sup>1</sup>, Okka W. Hamer<sup>2</sup>, David Hollemann<sup>3</sup>, Christoph Brochhausen<sup>3</sup>, Dirk Vollmann<sup>4</sup>, Lars S. Maier<sup>1</sup> and Samuel Sossalla<sup>1\*</sup>

<sup>1</sup>Klinik und Poliklinik für Innere Medizin II, Universitätsklinikum Regensburg, Franz-Josef-Strauß-Allee 11, 93053, Regensburg, Germany; <sup>2</sup>Institut für Röntgendiagnostik, Universitätsklinikum Regensburg, Regensburg, Germany; <sup>3</sup>Institut für Pathologie, Universität Regensburg, Regensburg, Germany; <sup>4</sup>Herz- & Gefäßzentrum Göttingen, Göttingen, Germany

## Abstract

Here we discuss a case of arrhythmia-induced cardiomyopathy (AIC) with consecutive severe multiple organ failure. In relation to this imposing case, we discuss the significance of this potentially underestimated cause of newly occurred left-ventricular systolic dysfunction and concomitant arrhythmia. We further delineate the diagnostic algorithm and differential diagnoses of AIC.

**Keywords** Arrhythmia-induced cardiomyopathy; Tachymyopathy; Heart failure; Tachycardia

Received: 26 March 2018; Revised: 31 May 2018; Accepted: 22 June 2018

\*Correspondence to: Samuel Sossalla, Klinik und Poliklinik für Innere Medizin II, Universitätsklinikum Regensburg, Franz-Josef-Strauß-Allee 11, 93053 Regensburg, Germany. Tel: +49 941 944 7210; Fax: +49 941 944 7211. Email: samuel.sossalla@ukr.de

## Introduction

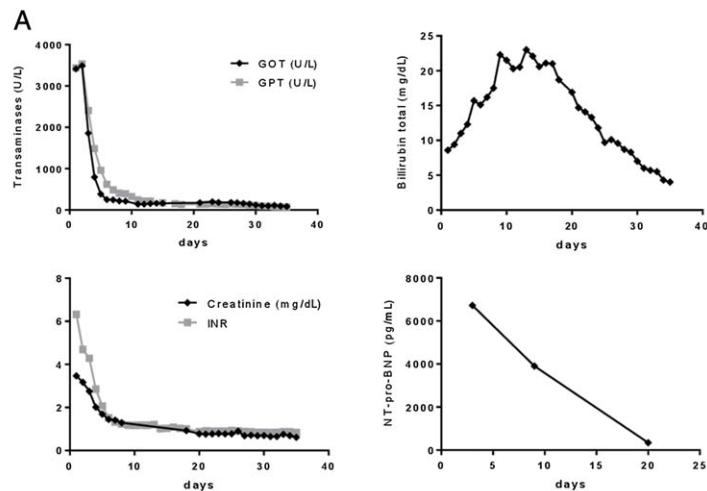
Arrhythmia-induced cardiomyopathy (AIC) represents a potentially reversible condition of left-ventricular (LV) systolic dysfunction (LVSD), which is caused by atrial or ventricular tachycardia/arrhythmias.<sup>1,2</sup> As rhythm disorders are often regarded as consequences of LVSD in daily clinical practice, AIC appears to be an underestimated cause of heart failure, particularly when ‘idiopathic dilated cardiomyopathy’ with concomitant arrhythmia is diagnosed. Here, we present a drastic case of AIC-induced multiple organ failure, underlining the importance of AIC as a differential diagnosis that requires quick initiation of an indispensable aggressive anti-arrhythmic therapy.

## Case report

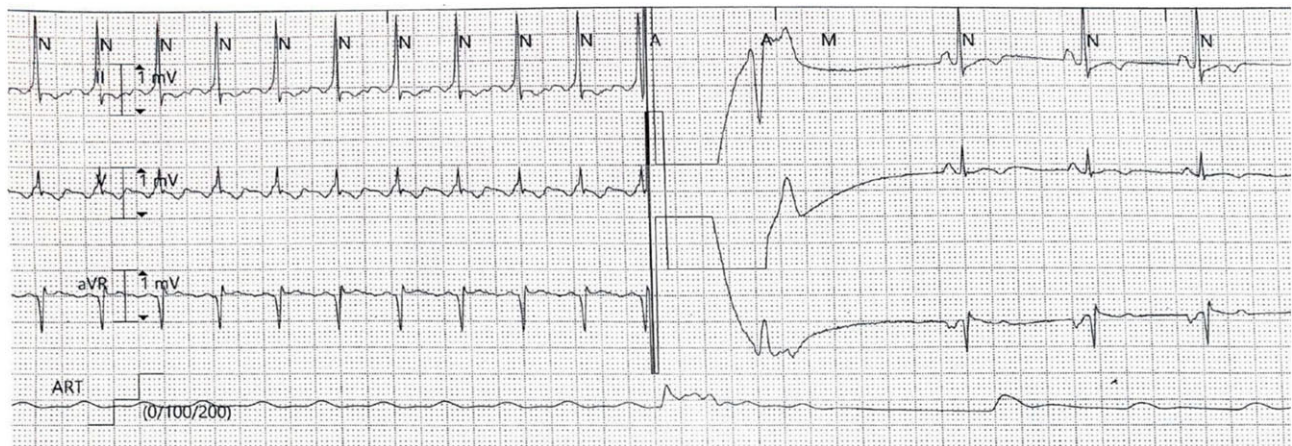
We report the case of a 51-year-old man with acute onset of multiple organ failure who was transferred to our clinic from an external hospital with the diagnosis acute liver failure with

decreasing vigilance, jaundice, hypoglycaemia, and oedema. During emergency transferral, hypotension and tachycardia (190 bpm) were noted. In the emergency department, vasopressor therapy was initiated and tracheal intubation was necessary because of depressed level of consciousness. Abdominal ultrasound imaging revealed bilateral pleural effusion and hepatic vein congestion. A prominent acute hepatocellular injury, acute renal failure, coagulation disorder, and high levels of NT-pro-BNP were found (*Figure 1A*). While the general state of health of the patient did not improve despite medical treatment, the patient was considered for listing as high urgency liver transplantation candidate. The calculated MELD score (Model of End-Stage Liver Disease) was 40 points, signifying a very high risk of 3 month mortality in patients awaiting liver transplantation.<sup>3,4</sup> However, thoracic and abdominal contrast-enhanced computed tomography showed cardiac enlargement, ascites, anasarca, and inhomogeneous contrast enhancement of the liver (nutmeg liver), pointing to hepatic venous congestion due to cardiac failure. In light of this finding, echocardiography was performed and a severely impaired left-ventricular ejection fraction (LVEF) of 10–15% was found. Moreover, as biomarkers

**Figure 1** (A) Time course of important laboratory findings revealing a recovery of initially affected organ functions. (B) Surface electrocardiogram showing tachycardiac atrial flutter and successful restoration of normofrequent sinus rhythm after electrical cardioversion. GOT, glutamic oxaloacetic transaminase; GPT, glutamic pyruvic transaminase; INR, international normalized ratio.



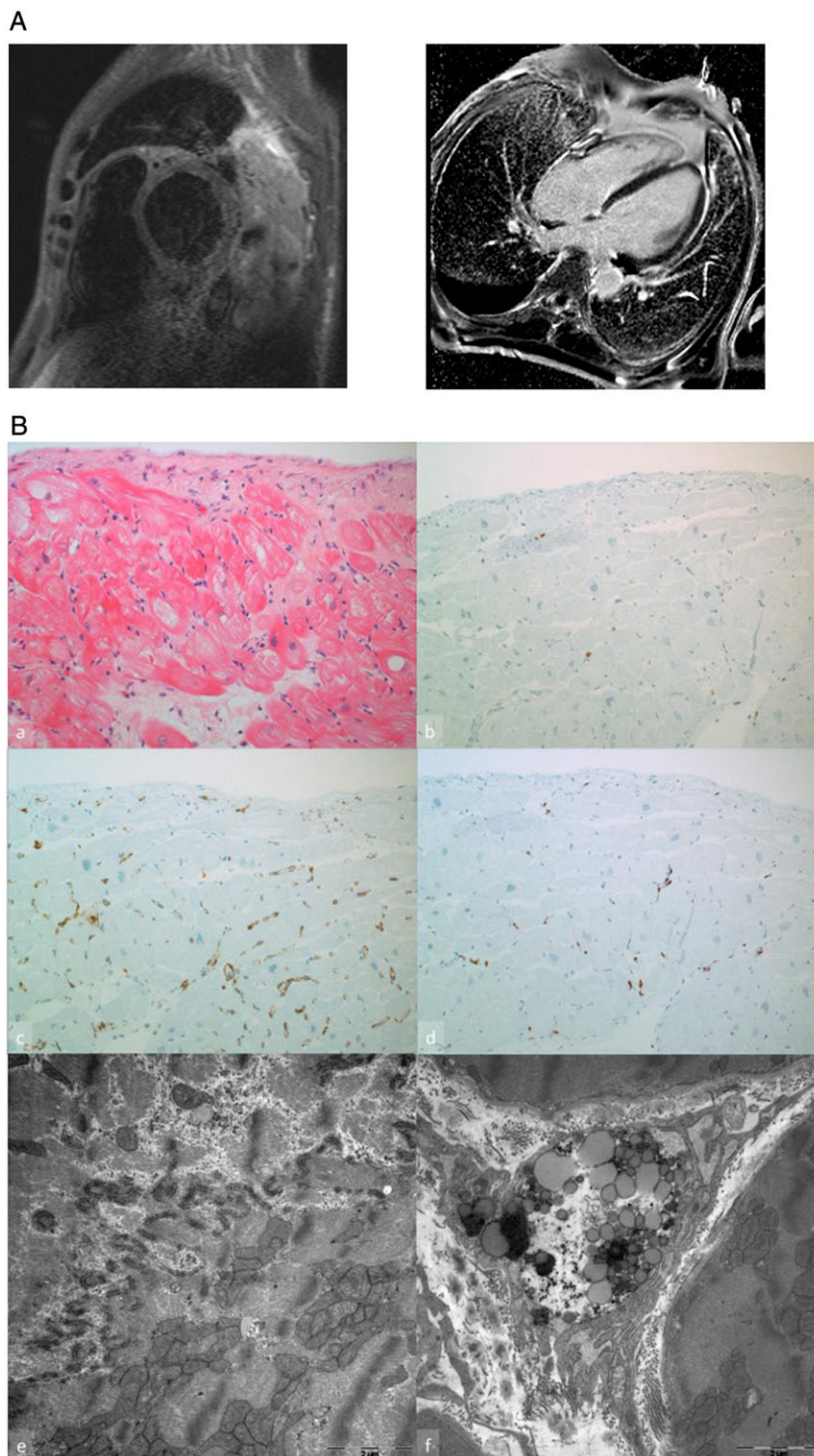
## B



for cardiac ischaemia (hs-Troponin I, CK-MB, and CK) were markedly elevated, timely coronary angiography was realized and coronary artery disease as a cause of LVSD was excluded. In addition, upon careful electrocardiogram inspection, the cardiologist suspected typical atrial flutter and not sinus tachycardia to be the cause of the persistent elevation in heart rate (now ~130 bpm). As rhythm disorders are known to constitute an underlying cause of LVSD, electrical cardioversion was conducted (*Figure 1B*) after exclusion of left-atrial thrombi by transesophageal echocardiography on Day 3. Cardiac magnetic resonance imaging (MRI) performed on Day 5 showed a dilation of all four cavities (LV end-diastolic diameter of 6.8 cm and right-ventricular end-diastolic diameter of 5.7 cm), relevant tricuspid and mitral valve regurgitation, a severely impaired LVEF (16%) with global hypokinesia, but no myocardial oedema or significant ventricular late gadolinium enhancement (*Figure 2* and Supporting

Information, *Video S1*). Left-ventricular endomyocardial biopsy, performed on Day 6, could further rule out myocarditis, rheumatological, or lysosomal storage disease and showed mild hypertrophic myocardium with enlarged nuclei and irrelevant subendocardial accentuated fibrosis. Furthermore, no significant increase of CD3 positive lymphocytes was observed, but higher numbers of CD68 positive macrophages were detected in immunohistological stainings. The expression of major histocompatibility complex II was moderately enhanced. Ultrastructurally, an increased number of mitochondria was obvious in the neighbourhood of the intercalated discs (*Figure 2B*). The clinical state of the patient as well as liver function, coagulation, and renal function rapidly improved after restoration of sinus rhythm (*Figure 1A*). The patient was extubated on Day 8. During the following days, medical heart failure therapy was adjusted and the clinical state of the patient subsequently further improved. An

**Figure 2** (A) Short tau inversion recovery sequence in short cardiac axis of initial magnetic resonance imaging (left). Despite artefacts due to large pleural effusions, myocardial oedema can be excluded. Late-enhancement sequence in four-chamber view of follow-up magnetic resonance imaging (right). There is no pathological late enhancement, hence no evidence of myocardial scar or fibrosis. (B) Histology revealed mild hypertrophic cardiomyocytes with enlarged nuclei and a mild subendocardial fibrosis in the haematoxylin and eosin staining (a,  $\times 200$ ); immunohistologically isolated CD3 positive lymphocytes could be found in the interstitium (b,  $\times 200$ ); an increased positivity for major histocompatibility complex II was evident (c) as well as a slight increased number of CD68 positive macrophages (d). Ultrastructurally, increased number of mitochondria near the intercalated discs was found (e); in the interstitium, macrophages could be shown (f).





echocardiographic control on Day 11 also revealed an improvement of LVEF (34%). On Day 18, first adequate communication was possible. Detailed anamnesis revealed that the patient had been physically healthy beforehand but was suffering from daily 'panic attacks' with sudden intense palpitations and heart race during the past 12 months. An outpatient electrocardiogram has never been performed. Interestingly, the patient did not experience any similar episodes after conversion to sinus rhythm. Another cardiac MRI on Day 25 showed further improvement in LVEF (40%; Supporting Information, *Video S2*) as well as a reduction of cardiac chamber dilation (LV end-diastolic diameter of 6.3 cm and right-ventricular end-diastolic diameter of 4.8 cm). Tricuspid and mitral valve regurgitation was not detectable anymore. As other causes of LVSD were ruled out and diagnostic criteria for AIC were fulfilled, AIC due to sustained atrial flutter was regarded as cause of LVSD and consecutive multiple organ failure. To ensure long-term rhythm control, radiofrequency ablation of the cavotricuspid isthmus was performed on Day 33. Finally, the patient was introduced to our outpatient clinic and was discharged from hospital on Day 36.

## Discussion

This case report demonstrates that severe LVSD can be caused by AIC and may eventually lead to multiple organ failure.<sup>1,5</sup> Diagnostic criteria for AIC are unexplained LVSD with concomitant arrhythmia and partial or complete recovery of LV function after restoration of sinus rhythm.<sup>1,2</sup> In the present case, these criteria were fulfilled and alternative causes of LVSD were carefully ruled out. Absence of ventricular late gadolinium enhancement on cardiac MRI served as supportive diagnostic criteria for AIC, as it was shown to be associated with a greater improvement of LV function in this context (Supporting Information, *Videos S1* and *S2*).<sup>6</sup> Furthermore, increased infiltration of CD68 positive macrophages, enhanced major histocompatibility complex II expression, and increased numbers of mitochondria at the intercalated discs were found in LV endomyocardial biopsy samples of the patient. These were also recently shown to be specific for AIC.<sup>2</sup> Conclusively, diagnosis of AIC was confirmed after restoration of sinus rhythm and early improved LV function within days to weeks. Nevertheless, it is well accepted that full recovery of LV function may last from weeks to months up to more than a year.<sup>1</sup> Importantly, rhythm control and subsequent increment of LV function also resulted in a fast recovery of the other compromised organ functions, illustrating the closed connection of the liver, kidney, and AIC.

In most of the cases of newly diagnosed LVSD, rhythm disorders are regarded as consequences of LVSD. Although

typical atrial flutter as it occurs in this case report is rarely caused by LVSD, AIC generally raises a 'chicken or egg' question. Frequently, the arrhythmia is considered secondary and is not treated effectively when, in fact, arrhythmia control may be necessary for recovery of LV function.<sup>1</sup> Accordingly, AIC appears to be an underestimated cause of LVSD. In the present case, the diagnosis of AIC was discarded several times and replaced by 'idiopathic dilated cardiomyopathy'. This approach is in our opinion typical for the disease and may be explained by a lack of awareness and/or knowledge about AIC. Very recent trials underline the relevant incidence and importance of AIC. In fact, in the CAMERA-MRI study, 54% of enrolled patients with previous structural heart disease and 88% of patients with idiopathic DCM, all suffering from atrial fibrillation (AF) and LVSD, finally turned out to have a relevant component of AIC.<sup>6</sup> In another study of 1269 patients who underwent atrial flutter ablation, AIC was observed in 56% of the patients with concomitant LVSD.<sup>7</sup> Furthermore, it was recently demonstrated that restoration of sinus rhythm with catheter ablation in patients with AF and LVSD results in significant improvements in LVEF compared with sole frequency control.<sup>6</sup> The CASTLE-AF study further revealed that catheter ablation for AF in patients with LVSD is associated with significant reduction of death from any cause and hospitalization for worsening heart failure.<sup>8</sup> Therefore, early and effective treatment of cardiac arrhythmias seems to be very important in the context of suspected AIC.<sup>9</sup>

In summary, this case report illustrates that

- (i) severe AIC can induce multiple organ failure;
- (ii) the diagnosis of AIC appears to be difficult for many physicians in clinical practice;
- (iii) a careful evaluation of patients with LVSD and rhythm disorders is essential to distinguish other causes from reversible AIC;
- (iv) an early aggressive anti-arrhythmic therapy in the context of LVSD and concomitant rhythm disorders is crucial for the patient's outcome; and
- (v) causal rhythm therapy leads to improvement of LV function when AIC is present.

## Conflict of interest

None declared.

## Supporting information

Additional supporting information may be found online in the Supporting Information section at the end of the article.

**Video S1.** Initial MRI.

**Video S2.** Follow-up MRI.

## References

1. Gopinathannair R, Etheridge SP, Marchlinski FE, Spinale FG, Lakkireddy D, Olshansky B. Arrhythmia-induced cardiomyopathies: mechanisms, recognition, and management. *JACC* 2015; **66**: 1714–1728.
2. Mueller KAL, Heinzmann D, Klingel K, Fallier-Becker P, Kandolf R, Kiliass A, Walker-Allgaier B, Borst O, Kumbink J, Kirchner T, Langer H, Geisler T, Schreieck J, Gramlich M, Gawaz M, Seizer P. Histopathological and immunological characteristics of tachycardia-induced cardiomyopathy. *JACC* 2017; **69**: 2160–2172.
3. Roth JA, Chrobak C, Schädelin S, Hug BL. MELD score as a predictor of mortality, length of hospital stay, and disease burden: a single-center retrospective study in 39,323 inpatients. *Medicine* 2017; **96**: e7155.
4. Wiesner R, Edwards E, Freeman R, Harper A, Kim R, Kamath P, Kremers W, Lake J, Howard T, Merion RM, Wolfe RA, Krom R. Model for End-Stage Liver Disease (MELD) and allocation of donor livers. *Gastroenterology* 2003; **124**: 91–96.
5. Saner FH, Heuer M, Meyer M, Canbay A, Sotiropoulos GC, Radtke A, Treckmann J, Beckebaum S, Dohna-Schwake C, Oldedamink SW, Paul A. When the heart kills the liver: acute liver failure in congestive heart failure. *Eur J Med Res* 2009; **14**: 541–546.
6. Prabhu S, Taylor AJ, Costello BT, Kaye DM, McLellan AJA, Voskoboinik A, Sugumar H, Lockwood SM, Stokes MB, Pathik B, Nalliah CJ, Wong GR, Azzopardi SM, Gutman SJ, Lee G, Layland J, Mariani JA, Ling L-h, Kalman JM, Kistler PM. Catheter ablation versus medical rate control in atrial fibrillation and systolic dysfunction: the CAMERA-MRI study. *JACC* 2017; **70**: 1949–1961.
7. Brembilla-Perrot B, Ferreira JP, Manenti V, Sellal JM, Olivier A, Villemin T, Beurrier D, De Chillou C, Louis P, Brembilla A, Juillière Y, Girerd N. Predictors and prognostic significance of tachycardiomyopathy: insights from a cohort of 1269 patients undergoing atrial flutter ablation. *Eur J Heart Fail* 2016; **18**: 394–401.
8. Marrouche NF, Brachmann J, Andresen D, Siebels J, Boersma L, Jordaens L, Merkely B, Pokushalov E, Sanders P, Proff J, Schunkert H, Christ H, Vogt J, Bansch D. Catheter ablation for atrial fibrillation with heart failure. *N Engl J Med* 2018; **378**: 417–427.
9. Sossalla S, Vollmann D. Arrhythmia-Induced Cardiomyopathy. *Dtsch Arztebl Int* 2018; **11**: 335–341.