

**AN INTERNATIONAL UROGYNECOLOGICAL  
ASSOCIATION (IUGA) / INTERNATIONAL CONTINENCE  
SOCIETY (ICS) JOINT REPORT ON THE TERMINOLOGY  
FOR FEMALE ANORECTAL DYSFUNCTION**

**Abdul H Sultan<sup>^</sup>, Ash Monga # <sup>^</sup>, Joseph Lee\*<sup>^</sup>, Anton Emmanuel<sup>^</sup>, Christine Norton<sup>^</sup>,  
Giulio Santoro<sup>^</sup>, Tracy Hull<sup>^</sup>, Bary Berghmans #<sup>^</sup>, Stuart Brody<sup>^</sup>, Bernard T. Haylen \*<sup>^</sup>,**

**Standardization and Terminology Committees IUGA\* & ICS#,  
Joint IUGA / ICS Working Group on Female Anorectal Terminology<sup>^</sup>**

**Abdul H Sultan**, MB ChB, MD, FRCOG Urogynaecologist and Obstetrician  
Croydon University Hospital, Croydon. United Kingdom

**Ash Monga**, MB ChB, FRCOG Urogynaecologist  
Princess Anne Hospital, Southampton. United Kingdom

**Joseph Lee**, MB ChB, FRANZCOG, CU Urogynaecologist  
Associate Professor, University of Melbourne  
Mercy Hospital for Women, Monash Health, Melbourne. Victoria. Australia

**Anton Emmanuel**, Gastroenterologist  
University College Hospital, London. United Kingdom

**Christine Norton**, Professor of Nursing  
Kings College London, London. United Kingdom

**Giulio Santoro**, Colorectal surgeon  
Regional Hospital, Treviso. Italy

**Tracy Hull**, Professor of Surgery  
Cleveland Clinic Foundation, Cleveland. Ohio. U.S.A.

**Bary Berghmans**, Clinical epidemiologist and physiotherapist  
Maastricht University Hospital, Maastricht. Netherlands

**Stuart Brody**, Professor of Psychology  
Charles University, Prague, Czech Republic

**Bernard T. Haylen**, Professor  
University of New South Wales, Sydney. N.S.W. Australia

Correspondence to:

Mr Abdul H Sultan,  
Urogynaecology and Pelvic Floor Reconstruction Unit,  
Croydon University Hospital  
London Road,  
Croydon, Surrey, CR7 7YE  
United Kingdom  
TEL" # 44 208 401 3161   abdulsultan@NHS.net

## **ABSTRACT**

**Introduction:** The terminology for anorectal dysfunction in women has long been in need of a specific clinically-based Consensus Report.

**Methods:** This Report combines the input of members of the Standardization and Terminology Committees of two International Organizations, the International Urogynecological Association (IUGA) and the International Continence Society (ICS), assisted on Committee by experts in their fields to form a Joint IUGA/ICS Working Group on Female Anorectal Terminology. Appropriate core clinical categories and sub classifications were developed to give an alphanumeric coding to each definition. An extensive process of twenty rounds of internal and external review was developed to exhaustively examine each definition, with decision-making by collective opinion (consensus).

**Results:** A Terminology Report for anorectal dysfunction, encompassing over 130 separate definitions, has been developed. It is clinically based with the most common diagnoses defined. Clarity and user-friendliness have been key aims to make it interpretable by practitioners and trainees in all the different specialty groups involved in female pelvic floor dysfunction. Female-specific anorectal investigations and imaging (ultrasound, radiology and MRI) has been included whilst appropriate figures have been included to supplement and help clarify the text.

Interval review (5-10 years) is anticipated to keep the document updated and as widely acceptable as possible.

**Conclusion:** A consensus-based Terminology Report for female anorectal dysfunction terminology has been produced aimed at being a significant aid to clinical practice and a stimulus for research.

<b>WORDS</b>	<i>Abstracts:</i>	225
	<i>Introduction – section 6:</i>	11164
	<i>Footnotes:</i>	1591
<b>Tables</b>	<i>Introduction – section 6:</i>	3
<b>FIGURES</b>	<i>Introduction – section 6:</i>	21
	<i>Footnotes:</i>	2

***RELEVANT DISCLOSURES:***

**AH Sultan:** Speaker for Astellas, SEP

**A Monga:** Consultant for Gynecare and AMS. Speaker for Astellas and Pfizer and advisor for Allergan.

**J Lee:** Received honoraria for talks and preceptor work from AMS and BSCI.

Member of Department that administer AMS & BSCI grant for investigator led studies

**A Emmanuel:** Served on advisory boards for Coloplast, Shire, Pfizer. Honoraria for talks from these companies as well as Ferring and Astra-Zeneca.

**C Norton:** Consultancy for SCA, Coloplast, Shire, Dr Falk, Clinimed

**G Santoro:** Speaker for BK Medical

**T Hull:** No disclosures

**B Berghmans:** No disclosures

**S Brody:** No disclosures

**B Haylen:** No disclosures

## **INTRODUCTION**

The anatomical configuration of the anorectum is complex. The mechanisms that control continence and allow defecation are multifactorial and dependent on many factors such as the consistency of stool, bowel transit, rectal compliance and sensitivity, intact neurological function and integrity of the pelvic floor and anal sphincters.

Historically, anorectal physiological investigations have quite often produced inconsistent results. Until the advent of imaging techniques such as endoanal ultrasound, the etiology of fecal incontinence was largely attributed to pudendal neuropathy<sup>1</sup>. We now better understand the contribution of vaginal delivery to anal sphincter trauma<sup>2</sup>. Imaging has taught us that training in clinical digital assessment can improve detection and repair of obstetric anal sphincter injuries and thereby minimise the risk of developing fecal incontinence<sup>3</sup>. Obstructive defecation is another common embarrassing problem and imaging techniques that attempt to capture the defecation process are often inconclusive<sup>4</sup>. Artificial contrast material replicating normal fecal consistency for defecating proctography is not available and magnetic resonance imaging requires an upright scanner.

When multiple conditions such as fecal incontinence, obstructive defecation, urinary incontinence, neurological diseases, medical conditions etc. co-exist, management becomes increasingly difficult and multidisciplinary assessment becomes important<sup>5</sup>. As the pelvic organs (bowel, bladder and vagina) are in close proximity to each other, clinicians need to be aware of the impact of dysfunction and surgery of one organ may have on the neighbouring structures. It is therefore important for clinicians and pelvic surgeons to have more global knowledge and adopt a holistic approach to pelvic floor dysfunction.

There is a need for standardized terminology in female anorectal dysfunction to accumulate accurate prevalence data, perform the appropriate investigations, institute management and conduct audit and research. Lack of a unified definition of anal incontinence has resulted in variations in prevalence data from epidemiological data. "Pseudo incontinence" with mucoid leakage (usually caused by organic colonic disease, dietary sensitivity or fecal impaction) is often mistaken as fecal incontinence as questionnaires do not quite differentiate them<sup>6</sup>. There is indeed the need for a general terminology, forming a "backbone" or "core" terminology to which more specific terminologies can be attached<sup>7</sup>.

This Terminology Report is inherently and appropriately a definitional document, collating the definitions of those terms, i.e. words used to express a defined concept, in a particular branch of study. Emphasis has been on comprehensively including those terms in current use in the relevant peer-reviewed literature. The aim is to assist clinical practice and research. Some new and revised terms have been included. Explanatory notes on definitions have been referred, where possible, to the “Footnotes section”.

Similar to a previous report<sup>7</sup> the female-specific terminology report should be:

**(1) User-friendly:** It should be able to be understood by all clinical and research users.

**(2) Clinically-based:** Symptoms, signs and validated investigations should be presented for use in forming workable diagnoses. The first three Sections will address symptoms, signs and assessment tools. The next two sections will describe anorectal physiological investigations and currently used pelvic imaging modalities routinely used in the office or anorectal laboratory to make those diagnoses. A number of related radiological investigations as well as magnetic resonance imaging (MRI) have also been included. The value of electromyography and related nerve conduction, reflex latency and sensory investigations will be outlined.

**(3) Origin:** Where a term’s existing definition (from one of multiple sources used) is deemed appropriate, that definition will be included and duly referenced. A number of terms in female anorectal function and dysfunction, because of their long-term use, have now become generic, as apparent by their listing in medical dictionaries.

**(4) Able to provide explanations:** Where a specific explanation is deemed appropriate to explain a change from earlier definitions or to qualify the current definition, this will be included as an addendum to this paper (*Footnote [FN] 1,2,3....*). Wherever possible, evidence-based medical principles will be followed.

It is suggested that acknowledgement of these standards in written publications related to female anorectal dysfunction, be indicated by a footnote to the section “Methods and Materials” or its equivalent, to read as follows: “Methods, definitions and units conform to the standards jointly recommended by the International Urogynecological Association and the International Continence Society, except where specifically noted”. It should be noted that the Working Group for this document was formed and started generation of this document prior to the Rosier statement<sup>8</sup>.

## Section 1: SYMPTOMS

- 1.1 Anorectal Incontinence symptoms
- 1.2 Anorectal storage symptoms
- 1.3 Anorectal sensory symptoms
- 1.4 Defecatory and post-defecatory symptoms
- 1.5 Anorectal prolapse symptoms
- 1.6 Anorectal pain symptoms
- 1.7 Anorectal sexual dysfunction symptoms
- 1.8 Miscellaneous anorectal symptoms

**Symptom:** Any morbid phenomenon or departure from the normal in structure, function, or sensation, experienced by the woman and indicative of disease<sup>9</sup> or a health problem. Symptoms are either volunteered by, or elicited from the individual, or may be described by the individual's caregiver<sup>7,10-11</sup>

### 1.1 Anorectal Incontinence symptoms

**Anal incontinence (symptom)<sup>7</sup>:** Complaint of involuntary loss of feces or flatus

(i) **Fecal incontinence<sup>7</sup>:** Complaint of involuntary loss of feces

(a) Solid

(b) Liquid

(ii) **Flatus Incontinence<sup>7</sup>:** Complaint of involuntary loss of flatus (gas)

(iii) **Double incontinence (NEW):** complaint of both anal incontinence and urinary incontinence [FN1]

(iv) **Coital fecal (flatal) incontinence (NEW):** fecal (flatal) incontinence occurring with vaginal intercourse (see related definition "Coital fecal urgency") [FN2]

(v) **Passive fecal leakage (NEW):** involuntary soiling of liquid or solid stool without sensation or warning or difficulty wiping clean [FN3]

(vi) **Overflow fecal incontinence (NEW):** seepage of stool due to fecal impaction

### 1.2 Anorectal Storage symptoms

(i) **Increased daytime defecation (NEW):** complaint that defecation occurs more frequently during waking hours than previously deemed normal by the woman.

(ii) **Nocturnal defecation (NEW)**: complaint of interruption of sleep one or more times because of the need to defecate.

(iii) **Fecal (rectal) urgency<sup>7</sup>**: Complaint of a sudden compelling desire to defecate that is difficult to defer

(a) Fecal urgency warning time: time from first sensation of urgency to voluntary defecation or fecal incontinence

(iv) **Fecal (flatal) urgency incontinence<sup>7</sup>**: Complaint of involuntary loss of feces (gas) associated with (fecal) urgency.

(v) **Tenesmus: (NEW)**: a desire to evacuate the bowel, often accompanied by pain, cramping, and straining, in the absence of feces in the rectum.

(vi) **Coital Fecal Urgency (NEW)**: Feeling of impending bowel action during vaginal intercourse.

### 1.3 Anorectal Sensory symptoms

(i) **Diminished rectal sensation<sup>7</sup>**: Complaint of diminished or absent sensation in the rectum.

(ii) **Increased rectal sensation (NEW)**: Complaint of a desire to defecate (during rectal filling) that occurs earlier or more persistent to that previously experienced.

### 1.4 Defecatory and post-defecatory symptoms

(i) **Constipation<sup>7</sup> (Updated)**: Complaint that bowel movements are infrequent and/or incomplete and/or there is a need for frequent straining or manual assistance to defecate [FN4]

(a) slow transit: infrequent bowel motions due to delay in transit of bowel contents to reach rectum

(b) obstructed defecation: Complaint of difficulty in evacuation [FN5]

(ii) **Feeling of incomplete bowel evacuation<sup>7</sup>**: Complaint that the rectum does not feel empty after defecation and may be accompanied by a desire to defecate again

(iii) **Straining to defecate<sup>7</sup>**: Complaint of the need to make an intensive effort (by abdominal straining or Valsalva) to either initiate, maintain or improve defecation

(iv) **Sensation of blockage (NEW)**: Complaint suggestive of anorectal obstruction

(v) **Digitation (NEW)**: use of fingers in rectum or vagina to manually assist in evacuation of stool contents

(a) rectal digitation: use of fingers in rectum to physically extract stool contents to assist in evacuation

(b) vaginal digitation: use of thumb or fingers in the vaginal to assist in evacuation of stool.

(vi) **Splinting (NEW)**: Support perineum or buttocks manually (usually with thumb or fingers) to assist in evacuation of stool content

(vii) **Post defecatory soiling (NEW)**: Soiling occurring after defecation

### 1.5 **Anorectal prolapse symptoms**

(i) **Anorectal prolapse (updated)**: Complaint of a “bulge” or “something coming down” towards or through the anus/rectum. The woman may state she can either feel the bulge by direct palpation or see it aided with a mirror [FN 6]

### 1.6 **Anorectal pain symptoms (NEW)** [FN 7]:

(i) **Pain during straining/defecation**: Complaint of pain during defecation or straining to defecate

(ii) **Inflammatory anorectal pain**: Complaint of pain characterized by burning or stinging [FN8] (fissure, inflammation, sepsis)

(iii) **Non-inflammatory anorectal pain**: Complaint of blunted anorectal pain, as opposed to sharp stinging or burning type of pain (proctalgia fugax, Levator ani syndrome, pudendal neuralgia<sup>13</sup>) See Section 6.5.

### 1.7 **Anorectal sexual dysfunction symptoms** [FN9]

**Symptoms of sexual dysfunction**<sup>7</sup>: A departure from normal sensation and/or function experienced by a woman during sexual activity.

**Female sexual dysfunction**<sup>22</sup>: complaint of dyspareunia or impairment of sexual desire, arousal, or orgasm.

(i) **Receptive anal intercourse (NEW)**: having a penis penetrating one’s anus [FN 10]

(ii) **Other anal sexual practices with body parts**: stimulation of the anus and/or rectum with bodily parts other than the penis (e.g. finger, fist) for sexual purposes by the recipient and/or a partner

(iii) **Other anal sexual practices with non-living objects**: stimulation of the anus and/or rectum with non-living objects (e.g. dildo) for sexual purposes by the recipient and/or a partner.

(iv) **Anodyspareunia (NEW)**: Complaint of pain or discomfort associated with attempted or complete anal penetration<sup>12</sup>. [FN11]

(v) **Anal laxity (NEW)**: Complaint of the feeling of a reduction in anal tone [FN 12]

### 1.8 **Miscellaneous anorectal symptoms**



- (i) **Rectal bleeding / mucus<sup>7</sup>**: complaint of the loss of blood / mucus per rectum [FN 11]
- (ii) **Perianal itching / pruritus ani (NEW)**: complaint of itchy anus [FN13]
- (iii) **Flaturia (NEW)**: Complaint of passage of gas per urethra
- (iv) **Fecaluria (NEW)**: Complaint of passage of fecal material per urethra
- (v) **Vaginal flatus/feces (NEW)**: Complaint of passage of flatus or feces per vagina

## Section 2: SIGNS

### 2.1 Vaginal and anorectal inspection

- 2.2 Vaginal examination
- 2.3 Anorectal examination
- 2.4 Examination of Pelvic Floor muscle function
- 2.5 Squeeze pressure
- 2.6 General examination
- 2.7 Neurological examination
- 2.8 Abdominal examination

**Sign:** Any abnormality indicative of disease or health problem, discoverable on examination of the patient: an objective indication of disease or health problem<sup>7</sup>.

### 2.1 **Vaginal and anorectal inspection**<sup>23</sup>

- (i) **Excoriation:** Perianal excoriation, skin rashes
- (ii) **Soiling:** Perianal fecal soiling or vaginal fecal soiling
- (iii) **Discharge:** Perianal or vaginal bloody or mucus discharge
- (iv) **Gaping anus:** non-coaptation of anal mucosa at rest
- (v) **Scars, sinuses, deformities, condylomata, papillomata, hematoma:** [FN 14]
- (vi) **Deficient perineum/cloacal-like defect:** a spectrum of tissue loss from the perineal body and rectovaginal septum with variable appearance. There can be a common cavity made up of the anterior vagina and posterior rectal walls or just an extremely thin septum between the anorectum and vagina.
- (vii) **Anal Fissures:** Longitudinal split in the skin of the anal canal, exposing the internal anal sphincter muscle. The majority of fissures are found in the mid-line posteriorly and there may be a skin tag associated with them.
- (viii) **Hemorrhoids:** abnormality of the normal cushion of specialized, highly vascular tissue in the anal canal in the submucosal space. Hemorrhoids can be divided into those originating above the dentate line which are termed internal and those originating below the dentate line which are termed external. Internal hemorrhoids are graded as follows
  - Grade I - bleeding without prolapse
  - Grade II - prolapse with spontaneous reduction
  - Grade III - prolapse with manual reduction
  - Grade IV - incarcerated, irreducible prolapse

Grade II and Grade III hemorrhoids will become evident on asking the patient to bear down and grade 4 hemorrhoids are obvious at the time of the examination. A proctoscopy is essential in examining for hemorrhoids unless they are completely prolapsed.

(ix) **Anorectal prolapse:** Full thickness eversion of the lower part of the rectum and anal canal. The exposed mucosa is red with circumferential folds around the central pit, which is the lumen of the rectum. Look for associated utero-vaginal prolapse, fistulas, sepsis and ulcers.

(x) **Fistula in ano:** An anal fistula is an abnormal connection between the anal canal epithelium (or rarely rectal epithelium) and the skin epithelium. Patients may complain of pain, swelling, intermittent discharge of blood or pus from the fistula and recurrent abscesses formation.

(xi) **Rectovaginal fistula:** is a communication from the rectum to the vagina

(xii) **Ano-rectal/vaginal/perineal fistula:** is an abnormal communication from the anal canal to the vagina or perineal area

## 2.2 Vaginal examination

All examinations for pelvic organ prolapse should be performed with the woman's bladder empty (and if possible an empty rectum)<sup>7</sup>, straining to maximally reveal the prolapse. All compartments should be examined for prolapse but of particular relevance to ano-rectal dysfunction is posterior vaginal wall prolapse.

(i) **Posterior vaginal wall prolapse<sup>7</sup>:** Observation of descent of the posterior vaginal wall. Commonly, this would represent rectal protrusion into the vagina (rectocele). Higher stage posterior vaginal wall prolapse after prior hysterectomy would generally involve some vaginal vault (cuff scar) descent and possible enterocele formation. Posterior vaginal wall prolapse can be a rectocele, enterocele or a perineocele. Enterocele formation can also occur in the presence of an intact uterus.

(ii) **Rectocele:** Bulge in posterior vaginal wall associated with herniation of anterior wall of the rectum.

(iii) **Enterocele:** Bulge of upper wall of the vagina associated with herniation of the peritoneal sac and loops of small bowel

(iv) **Perineocele:** Bulge in the perineum associated with herniation of the anterior wall of the rectum

## 2.3 Anorectal Examination:

The patient lies in the left lateral position with hips flexed and ankles away from the examiner. Dorsal lithotomy position could also be used.

(i) **Perianal sensation/reflex:** In patients with possible neurogenic pelvic floor dysfunction there should be particular note of those neurological signs related to S2-4 but these should be

complimented by a more general neurological examination as indicated. Specific to ano-rectal dysfunction, assessment of anal reflex and perianal sensation should be performed.

(ii) **Digital rectal examination:** The gloved finger should be placed in the center of the anus with the finger parallel to the skin of the perineum in the midline. The finger should then be pressed gently into the anal canal but at the same time pressed backwards against the skin of the posterior wall of the anal canal and underlying sling of the puborectalis muscle. This overcomes most of the tone of anal sphincter and allows the finger to straighten and slip into the rectum. This will allow assessment of:

- (a) Resting anal tone, voluntary squeeze of the anal sphincter as well as the levator muscles, sustained squeeze over 5 seconds and involuntary contraction elicited during a cough.
- (b) Obvious hemorrhoids can be palpated but grade II and grade III. Hemorrhoids are better assessed by proctoscopy. Painful examination may be associated with fistula in ano, fissure in ano, infection or pilonidal abscess.
- (c) Palpable anal sphincter gap. An assessment can be made of palpable anal sphincter gap to assess if there has been previous obstetric or surgical damage. The perineal body can be assessed for deficiency.
- (d) Rectal contents. The contents of the rectum can be assessed. The feces may be hard or soft, the rectum may be empty or collapsed and sometimes ballooned out. This allows assessment of fecal impaction.
- (e) Confirmation of presence of rectocele, enterocele or perineocele. Use of POP- Q for staging of prolapse. [See FN15]
- (f) Bidigital examination may be carried out with the patient supine in a gynecological examining position. By inserting the index finger in the vagina and the middle finger in the rectum, the rectovaginal septum and any intervening small bowel loops can be palpated to differentiate a rectocele from an enterocele, during a Valsalva maneuver.
- (g) Rectal lesions such as carcinoma, intussusception or recto-vaginal fistula. If a mass is felt on a fingertip, the patient should be asked to strain, and this will often move the mass down to bring it within reach.
- (h) An assessment can be made of the rectovesico/recto uterine pouch to look for extra rectal masses.

**2.4 Examination of Pelvic Floor Muscle Function<sup>7</sup>** Pelvic floor muscle function can be qualitatively defined by the tone at rest and the strength of a voluntary or reflex contraction as strong, normal, weak, or absent or by a validated grading symptom. Voluntary pelvic floor

muscle contraction and relaxation may be assessed by visual inspection, by digital palpation (vaginal or anorectal) (circumferentially), electromyography, dynamometry, manometry, or ultrasound. Factors to be assessed include muscle strength (static and dynamic) (graded as strong, normal, weak or absent), voluntary muscle relaxation (graded as absent, partial, complete, delayed), muscular endurance (ability to sustain maximal or near maximal force), repeatability (the number of times a contraction to maximal or near maximal force can be performed), duration, co-ordination, and displacement<sup>24</sup>. Assessment can be made of each side of the pelvic floor separately to allow for any unilateral defects and asymmetry<sup>23</sup>. Assessment of displacement (perineal elevation or descent) of the pelvic floor can be made during cough or Valsalva. Normally, there is some downward movement of the pelvic floor muscles or there is a ventral movement (perineal elevation, inward (cephalad) and upward movement of vulva, perineum and anus). Rectal examination observations can include:

- (a) Anal sphincter tone and strength: given the absence of a formal quantitative assessment via the rectal route, assessment of anal tone and strength on digital examination, can be graded using the same convention used when grading transvaginally - as strong, normal, weak, or absent or by a validated grading symptom.
- (b) Anal sphincter tear: may be recognized as a clear “gap” in the anal sphincter on digital examination.

## **2.5 Squeeze pressure**

Measurement of squeeze pressure involves the exertion of pressure, compressing the assessor’s finger during digital palpation or using a mechanical device. The patient is asked to squeeze the PFM as hard as possible (maximum strength), to sustain the squeeze contraction (endurance), or to repeat squeeze contractions (repetitions). The measurement can be done in the anorectum using manual muscle testing with digital rectal palpation or pressure manometry in the vagina using manual muscle testing with digital vaginal palpation or pressure manometry, or dynamometry. So far, not all quantitative assessments and scales of pelvic floor squeeze pressure have the same methodological qualities, like validity, reproducibility and responsiveness<sup>24-28</sup>.

Pelvic floor muscle **spasm** was defined as persistent contraction of striated pelvic floor muscle that cannot be released voluntarily. If the contraction is painful, this is usually described as a cramp<sup>29</sup>. Spasm over days or weeks may lead to a contracture.

Pelvic floor muscle **tenderness**: sensation of discomfort with or without pain; discomfort of pelvic floor muscle elicited through palpation. Tenderness can be scored<sup>30</sup> during a digital rectal (or vaginal) examination of levator ani, piriformis and internal obturator muscles bilaterally, according to each subject's reactions: 0, no pain; 1, painful discomfort; 2, intense pain; with a maximum total score of 12.

Although not universally accepted, pelvic floor muscle **traction** is the use of a pulling force to examine or treat pelvic floor muscles, postulated to end pelvic muscle spasm or relieve pain<sup>31</sup>.

**2.6 General examination:** Anorectal dysfunction may be associated with systemic disease and intestinal malignancy and a thorough medical examination should observe for signs relating to conditions such as anaemia, jaundice, lymphadenopathy etc.

**2.7 Neurological examination:** In patients with possible neurogenic pelvic floor dysfunction there should be particular note of those neurological signs related to S2-4 but these should be complimented by a more general neurological examination as indicated. Specific to ano-rectal dysfunction, assessment of anal reflex and perianal sensation should be performed.

**2.8 Abdominal examination:** A thorough abdominal examination should evaluate for the following

- (i) Abdominal masses or distension
- (ii) Scars indicating previous relevant surgery or trauma
- (iii) tenderness

### **3. Assessment tools and questionnaires (non invasive)**

3.1 Pictorial stool chart

3.2 Bowel Diary

3.3 Symptom scores and Questionnaires

### **3.1 Pictorial stool chart**

It is a pictorial chart of stool consistencies. First described (but not published as a pictorial instrument) by Heaton et al<sup>32,33</sup>, the “Bristol stool chart” seems to have widespread face validity and recognition and is useful in conversations with patients about their stool consistency, despite little validation work. It has not been validated as an outcome measure and a reported change in category may not represent sufficient degree of precision for use as a trial end point.

### **3.2 Bowel diary**

It is a recording of bowel actions. Bowel diaries have been widely used in diagnostic and intervention studies. Patient recall is less accurate than a diary<sup>34,35</sup>. Patients tend to underestimate symptom frequency, in one study by over 50%<sup>36</sup>. However, there are few published examples and no consensus on what should be included. Elements that might be included:

- Urgency
- Fecal incontinence (amount, consistency)
- Flatus incontinence
- Passive staining/soiling (tends not be discrete episodes)
- Pads (changes, degree of soiling)
- Straining/difficulty/time in the toilet
- Unsuccessful attempts to defecate
- Assistive measures (e.g. digital stimulation, manual evacuation, irrigation)
- Laxative or rectal evacuant use
- Diet and fluids (type and/or timing)

Patients often need careful and detailed instructions on how to complete a diary, and still many are poorly completed. An incomplete diary is difficult to interpret and is liable to misinterpretation as a low bowel/event frequency.

### **3.3 Symptom scores and questionnaires**

#### **(i) Fecal incontinence (FI)**

The International Consultation on Incontinence (ICI) chapter 5B<sup>37</sup> has reviewed FI questionnaires and found none with a grade A recommendation (validity, reliability and responsiveness established with rigor). The ICI grades B (validity and reliability established

with rigor, or validity, reliability and responsiveness indicated) and C (early development – further work required) are noted where available in the text below.

The Cleveland Clinic Score<sup>38</sup>, often termed the “Wexner” score, was the first attempt to have a score based on both the frequency and consistency of FI and effect on lifestyle. In the original version it was physician-completed, although in subsequent literature it has also been completed by patients (grade C). The St Mark’s score<sup>39</sup> was an adaptation of the original Wexner score, adding scores for urgency and use of anti-diarrheals (grade C). This has been found to correlate reasonably well to patients’ global assessment of their bowel function<sup>40</sup>.

The Fecal Incontinence Quality of Life Scale<sup>41</sup> (grade B) and Fecal Incontinence Severity Index<sup>42</sup> (FISI) (grade B) were developed using items suggested by experts and then proposed to patients for ranking.

The international consultation on incontinence questionnaire – bowels (ICIQ-B)<sup>43</sup> has 23 items developed by literature review, expert opinion and in-depth qualitative interviews with patients, to include items of greatest importance to both clinicians and people with symptoms<sup>44</sup>. It has been validated up to the point of responsiveness to change, but further work is needed.

## ***(ii) Constipation***

There has been no exercise similar to the ICI Chapter 5B<sup>37</sup> which has graded constipation questionnaires.

The Patient Assessment of Constipation Quality of Life questionnaire<sup>45</sup> (PAC-QOL) and the PAC-SYM<sup>46</sup> are the best validated and most widely used tools for idiopathic constipation<sup>47</sup>. The PAC-SYM items were developed from the literature and patient focus group interviews. The validation process was robust and the instrument has 12 items grouped into three subscales (stool symptoms, rectal symptoms and abdominal symptoms), each scored 0-4. It has also been validated for use with constipated older people in a care home environment<sup>47</sup> and opioid-induced constipation<sup>48</sup>.

The Cleveland Clinic constipation score gives a simple numerical total score<sup>49</sup> based on symptoms and physiological findings. Values allocated to symptoms and findings appear to be arbitrary. Validation has been limited.



Altomare has developed a scoring system specifically for the Obstructed Defecation Syndrome<sup>50</sup>, but this has not been formally validated.

**Table 1.** Patient Reported Outcome Questionnaires for female anorectal dysfunction

<b>CONDITIONS</b>	<b>Tools</b>	<b>Clinical</b>	<b>Research</b>
<b>Bowel dysfunction</b>	<b>Bristol Stool Chart</b>	<b>R</b>	<b>R</b>
<b>Bowel dysfunction</b>	<b>Bowel Diary</b>	<b>R</b>	<b>R</b>
<b>Fecal incontinence</b>	<b>Cleveland Clinic Score /</b>	<b>R</b>	<b>R</b>
	<b>Wexner</b>	<b>R</b>	<b>R</b>
	<b>St Marks Score</b>	<b>R</b>	<b>R</b>
	<b>FI QoL</b>	<b>O</b>	<b>R</b>
	<b>FISI</b>	<b>O</b>	<b>R</b>
	<b>ICIQ-B</b>	<b>O</b>	<b>R</b>
<b>Constipation</b>	<b>PAC-QoL</b>	<b>R</b>	<b>R</b>
	<b>PAC-SYM</b>	<b>R</b>	<b>R</b>
	<b>Altomare</b>	<b>O</b>	<b>R</b>

R=recommended; O=optional

## **4. Anorectal Physiological Investigations**

4.1 Investigations to exclude organic disease

4.2 Anorectal physiology tests

4.2.1 Manometry

4.2.1.1 Functional anal length

- 4.2.1.2 Maximum resting pressure
- 4.2.1.3 Maximum squeeze pressure
- 4.2.1.4 Involuntary maximum squeeze pressure
- 4.2.1.5 Endurance squeeze pressure
- 4.2.1.6 Rectoanal inhibitory reflex
- 4.2.1.7 Balloon expulsion pressure
- 4.2.1.8 Advanced Manometric techniques
  - 4.2.1.8.1 Vector manometry
  - 4.2.1.8.2 High resolution manometry
  - 4.2.1.8.3 Ambulatory anorectal manometry
- 4.2.2 Sensory measurements
  - 4.2.2.1 Assessment of rectal sensation to distension
  - 4.2.2.2 Mucosal electrosensitivity
- 4.2.3 Rectal Dynamics
  - 4.2.3.1 Rectal compliance
  - 4.2.3.2 Rectal Impedance planimetry
- 4.2.4 Attempted Defecation and Balloon Expulsion
- 4.2.5 Neurophysiology
  - 4.2.5.1 Single fiber EMG
  - 4.2.5.2 Concentric fiber EMG
  - 4.2.5.3 Surface EMG
  - 4.2.5.4 Pudendal nerve terminal motor latencies (PNTMLs)
- 4.3 Clinical role of anorectal physiological measurements

Anorectal physiological assessment is a key part of the assessment of some patients with pelvic floor symptoms<sup>51,52</sup> providing a clinically meaningful, quantitative measure of a specific anorectal function. It is only in the context of the patient's symptoms, thorough examination and radiological investigations that physiological measurements can be correctly interpreted.

#### **4.1 Investigations to exclude organic disease**

(i) Anoscopy or proctoscopy is the inspection of the anal canal to identify anal fissure, fistula or hemorrhoids as a cause of anal symptoms.

(ii) Rigid sigmoidoscopy is a bedside test to inspect the rectal mucosa, with no bowel preparation.

(iii) Flexible sigmoidoscopy refers to the inspection of the distal colonic mucosa, typically up to the splenic flexure, with a 60cm flexible endoscope following enema preparation. Colonoscopy examines the entire colon following a full oral preparation to clear the bowel to allow this.

## **4.2 Anorectal Physiology Tests**

Functional assessment tests of fecal incontinence and evacuatory disorders aim to qualify and quantify function, determine the etiology, guide management and monitor progress.

### **4.2.1 Manometry**

Anal manometry is a test to assess the mechanical strength of the anal sphincters<sup>53,54</sup>. A range of methods is available, including water perfused, solid state and micro-balloon systems. The length of the canal is measured either by station pull-through or continuous pull-through. Station pull-through involves inserting the catheter to six centimeters from the anal verge, withdrawing the catheter at five to ten millimeter intervals and measuring for one to five minutes at each 'station' (see Figure 1). Continuous pull-through involves withdrawing the catheter at a set speed by hand or by a mechanical puller. As normal values can differ substantially between laboratories according to the style of catheter used, each unit is encouraged to generate its own normal data<sup>51,52</sup>.

In patients with fecal incontinence the value of manometry is:

- a) to define functional weakness of one or both sphincter muscles (as a compliment to anal endosonography);
- b) to support findings of other tests and to monitor outcome and predict response to biofeedback training;
- c) in cases where anal endosonography is not available, vector manometry may help identify anatomic defects of the anal sphincter complex.

In constipated patients the value of manometry is

- a) to exclude Hirschsprung's disease.
- b) to identify and predict responses to biofeedback training (pelvic floor dyssynergia = failure to expel a water-filled balloon).

#### **4.2.1.1 Functional anal length**

Functional anal canal length is defined as the length of the anal canal over which resting pressure exceeds that of the rectum by greater than 5 mmHg or, alternatively, as the length of the anal canal over which pressures are greater than half of the maximal pressure at rest

#### **4.2.1.2 Maximum Resting Pressure**

The maximum resting pressure is the maximum resting pressure generated in the anal canal at rest. Strictly speaking, it is defined as the difference between the intrarectal pressure and the highest recorded rectal pressure at rest. However rectal contents may affect the accuracy of rectal pressure measurements. The internal anal sphincter (IAS) exhibits continuous tonic activity and is responsible for 55-85% of the resting anal canal pressure (see Figure 1). Its contribution to resting tone is variable along the length of the anal canal with the proximal two thirds being more reliant on IAS tone to maintain adequate resting pressures<sup>55,56</sup>. The range of maximal resting pressure is typically between 60 -120 cmH<sub>2</sub>O. The EAS has constant tonic activity contributing to the resting anal canal pressure.

#### **4.2.1.3 The Maximum Squeeze Pressure**

The maximum squeeze pressure is the maximum pressure generated in the anal canal during a voluntary contraction. Although the EAS contributes to the resting pressure the specific function of the EAS can be assessed during the *squeeze* and *cough* maneuvers. The pressure increment above resting pressures during these maneuvers is a direct representation of EAS function. The normal range, as stated above, varies according to measurement modality in each laboratory, but is approximately above 60cmH<sub>2</sub>O<sup>57,58</sup>. Typically, higher values are obtained by automated pull-through rather than station withdrawal methodologies<sup>51</sup>.

#### **4.2.1.4 Involuntary maximum Squeeze Pressure**

A common maneuver is a maximal cough to measure this involuntary increment, usually reported as a present or absent response, rather than numerically.

#### **4.2.1.5 Endurance Squeeze pressure**

The endurance squeeze pressure is the length of time the individual is able to maintain the pressure during a voluntary contraction. To assess the endurance squeeze pressure, measurements are taken during a 5 – 10 second squeeze (normal  $\geq$  5 seconds). Incontinent patients typically have fatigue rate of greater than two-thirds of initial pressure at the end of the sustained squeeze. By calculating fatigability, the fatigue rate (using linear regression on the mean pressure over one second periods throughout the endurance squeeze) can be derived.

#### **4.2.1.6 Rectoanal Inhibitory Reflex**

The recto-anal inhibitory reflex (RAIR) is a relaxation response in the IAS following rectal distension. A drop of at least 25% of resting pressure has to occur with subsequent restoration to at least two thirds of resting pressure for it to be deemed present. It is elicited by rapid insufflation and disinflation of 50mls of air into a balloon positioned in the distal rectum during anal manometry at the level of the proximal high pressure zone<sup>52</sup>. This reflex is absent in Hirschsprung's disease: of greater physiological meaning, this reflex is thought to underlie the sampling response that allows rectal content to be sensed by the anal mucosa, thus ensuring continence of flatus and stool<sup>59</sup>.

#### **4.2.1.7 Balloon Expulsion Pressure**

The balloon expulsion pressure is the anal canal pressure during straining with a filled balloon in the rectum. Balloon expulsion can be performed on patients with evacuatory difficulty. An inappropriate increase in sphincter pressure on attempted voiding evacuation is usually reported as a present or absent response, rather than numerically. Such increased pressure is referred to as "anismus" or "paradoxical sphincter contraction".

#### **4.2.1.8 Advanced manometric techniques**

##### **4.2.1.8.1 Vector manometry**

Vector manometry is a quantitative measure of radial symmetry and volume of the anal sphincter. It involves withdrawing (commonly using a mechanical puller) a radially arranged multi-channel anorectal manometry catheter through the length of the anal canal<sup>60,61</sup>. The following parameters are identified:

- Radial asymmetry index (RAI) is a quantitative measure of the radial symmetry and can be calculated at any level in the anal canal but most commonly refers to the level at which the highest resting pressure is generated. The principle is that an asymmetrical sphincter is more likely to have a sphincter defect.
- The vector volume is the volume of the 3D shape generated and provides a value which reflects the overall length and symmetry of the sphincter.

##### **4.2.1.8.2 High resolution manometry**

In this technique, a catheter with a large number of pressure sensors spaced less than 0.5mm apart along the length of the catheter. This allows complete definition of the intra-anal pressure environment. The resulting data is displayed on a topographical three dimensional plot to allow easier pattern recognition. It is a measurement with the variables of pressure (displayed as

the color), distance into the anal canal (y-axis) and time (x-axis). Normal ranges are slightly higher than measured with standard manometry, but the readings agree well with each other<sup>62</sup>.

#### **4.2.1.8.3 Ambulatory anorectal manometry**

Using solid-state catheters, prolonged ano-rectal motor events have been recorded, including in ambulant subjects. The clinical applicability of these techniques has not been established<sup>63-65</sup>.

### **4.2.2 Sensory Measurements**

#### **4.2.2.1 Assessment of rectal sensation to distension**

Rectal sensation to distension is most commonly assessed by manually inflating an intrarectal domestic balloon at a rate of approximately 5ml/second<sup>56,66</sup>. The following are elicited:

- volume which elicits the first sensation of balloon expansion (threshold) [typical normal range 12-25ml]
- volume to get an urge to defecate (typical normal range 35-65ml)
- maximal tolerated volume (typical normal range 120-300 ml).

[normal ranges for the latter two sensations are highly variable due to lack of consensus on measurement technique especially of the nature and speed of inflation of the balloon]

The pressure required to elicit these sensations can also be measured using an electro-mechanical barostat and may be more reproducible. The barostat measures the volume and the pressure required to elicit these volumes sensations<sup>67,68</sup>. Typically distension thresholds with a barostat are higher, with larger volumes being required to elicit the same sensation. However, again, the published ranges vary widely between units: typically distension volumes 1.5 to 3 times are published for thresholds with a barostat compared to manual balloon inflation. Distension sensitivity testing is of proven value in:

- a) patients with fecal incontinence to help with biofeedback training by normalization of the initial sensation sensory thresholds;
- b) identifying visceral hypersensitivity, poor rectal compliance, or rectal irritability if maximal tolerated volumes are low<sup>51,52</sup>.

There is no evidence to support use of the sensory thresholds for diagnosis and biofeedback training of patients with constipation. Compliance testing has also not proven valuable in identifying candidates for specific therapies.

#### **4.2.2.2 Mucosal Electrosensitivity**

This is test to measure anal and rectal sensory thresholds. Mucosal electrical stimulation is performed using a probe with two ring electrodes between which a small electrical potential is applied generating an alternating square wave with a variable frequency.. Normal ranges have been established as anal electrosensation <10mA, and rectal as <30mA<sup>69</sup>. In general, prolonged anal electrosensation is suggestive of damage to the sensory fibers of pudendal nerve, and prolonged rectal electrosensation is suggestive of autonomic neuropathy.

#### **4.2.3 Rectal Dynamics**

##### **4.2.3.1 Rectal Compliance**

Rectal compliance is the term that describes the relationship between pressure and volume, reflecting the ability of the rectum to act as a reservoir and is assessed using a barostat, Inflating the bag within the rectum prior to the recording inflation protocol, known as conditioning, has been shown to improve the precision of compliance testing<sup>59</sup>. Typically, compliance figures between 4 and 11 mmHg/ml are quoted as the normal range.

##### **4.2.3.2 Rectal impedance planimetry**

These studies are the preserve of research institutions rather than clinical practice. The rationale is to calculate the diameter or cross sectional area of an intra rectal bag during a distension sequence. Impedance planimetry measures the cross sectional area which enables the circumferential wall tension to be calculated<sup>70</sup>.

#### **4.2.4 Attempted Defecation and Balloon Expulsion**

Patients with symptoms of prolapse and elderly patients with a history of constipation who present with passive incontinence should be thoroughly examined for the presence of a full thickness rectal prolapse. Patients are asked to strain as they would to pass stools whilst on a toilet or commode and given enough time to reproduce the prolapsing lump before examination.

Expulsion of a water-filled balloon can be used in the assessment of constipated patients. The ability to expel the balloon within 1 minute may be a useful tool in demonstrating the absence of pelvic floor dyssynergia.

#### **4.2.5 Neurophysiology**

##### **4.2.5.1 Single fiber EMG**

A single fiber needle EMG technique is used to measure the muscle fiber density in the external sphincter and puborectalis. A raised fiber density indicates re-innervation in the muscles, which may occur following partial denervation. Calculating EAS fiber density is another method of assessing denervation and re-innervation of the EAS. It is used almost exclusively as a research tool. Conventional EMG can be used to quantify the re-innervation of the EAS by detecting prolongation in the duration of the motor unit potential.

#### **4.2.5.2 Concentric fiber EMG**

Concentric needle EMG can be used to record activity in the external sphincter and puborectalis. The responses of these muscles to voluntary contraction, coughing and straining can be displayed. The data is qualitative and compared to appearances in these muscles at rest. The muscles can also be studied at several sites to define areas of functioning muscle and identify sites of muscle injury (sphincter mapping) although this has now been superseded by anal endosonography.

#### **4.2.5.3 Surface EMG**

Electrodes placed on the skin of the perineum or inside the vagina or rectum. Surface recordings from the sphincter show increased activity with body actions and decreased activity in sleep. Needle EMG however is regarded as superior<sup>71</sup>. Some centers use surface EMG as an indicator of anal sphincter activity to provide feedback for patients undergoing behavioral biofeedback training for fecal incontinence or constipation.

#### **4.2.5.4 Pudendal nerve terminal motor latencies (PNTMLs)**

The PNTML is a measurement of the delay between the electrical stimulation of the pudendal nerve and the EMG activity of the EAS. The pudendal nerve is stimulated as it passes over the ischial spine using a specially designed electrode attached to the index finger of the assessor in the rectum<sup>71</sup>. The surface EMG recording electrode which sits on the base of the assessor's index finger and measures external sphincter activity. The test does not reliably reflect the pudendal nerve damage. This may be because PNTMLs measure the speed of nerve conduction, which involves the fastest nerve fibers that are least susceptible to damage. The latencies are reported as normal if below 2.2msec, but are also very operator dependent, with poor reproducibility and hence not recommended for general clinical use<sup>72</sup>.

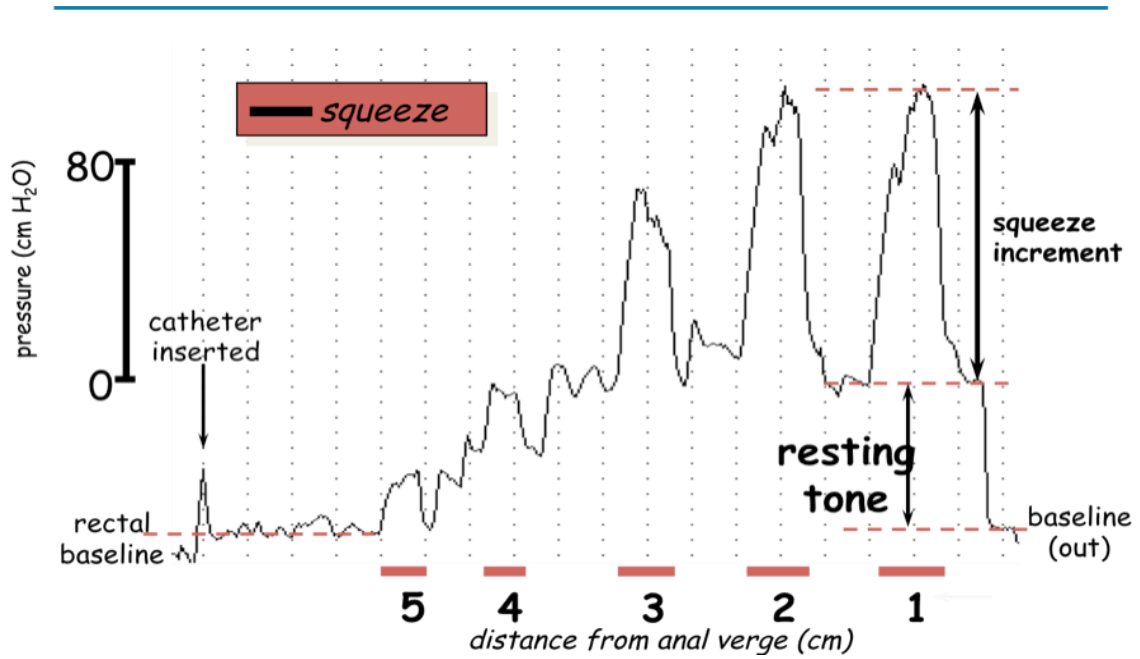
### **4.3 Clinical Role of Anorectal Physiological Measurements**

As can be seen from the above, the reliability, reproducibility, and clinical validity of these tests are unproven, owing to the variety of methodologies of measurement undertaken.

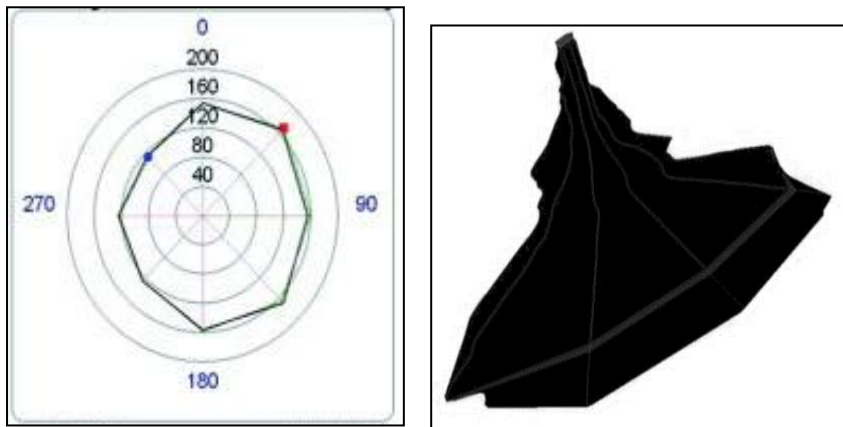


Standardization in each individual laboratory, with normal ranges from each laboratory, is therefore the required standard.

**Figure 1:** Typical station pull through manometry trace on a patient, with explanations



**Figure 2:** Vector volume anal manometry trace. The left hand panel illustrates the shape of the contour curve at a fixed point, and the right hand figure shows the integrated whole across the length of the sphincter (from proximal to distal). It is evident that the greatest pressure is exerted in the distal canal.



**Table 2.** Anorectal physiology tests for female anorectal dysfunction

<b>Anorectal physiological tests</b>	<b>Conditions</b>	<b>Clinical</b>	<b>Research / optional</b>
<b>Anorectal Manometry</b>	<b>anal sphincter function</b>	<b>R</b>	<b>R</b>
<b>Defecography</b>	<b>Extent of rectal intussusception /rectocele</b>	<b>O</b>	<b>R</b>
<b>Neurophysiological testing PTNML<sup>73</sup> CN-EMG</b>	<b>Preoperative before sphincteroplasty or SNM; or in patients with possible pudendal neuralgia  when USS or MRI equivocal</b>	<b>O</b>	<b>R</b>

R=recommended; O=optional

## **5: IMAGING.**

### 5.1 Ultrasonography of posterior compartment

5.1.1 Endoanal ultrasonography (EAUS)

5.1.2 Transperineal ultrasonography (TPUS)

5.1.3 Transvaginal ultrasonography (TVUS)

5.1.4 Clinical application of ultrasonography of posterior compartment

5.1.4.1 Fecal incontinence

5.1.4.2 Levator ani injuries

5.1.4.3 Obstructed defecation syndrome (ODS)

5.1.4.4 Perianal Abscesses and fistulas

### 5.2 MRI for anal sphincters and pelvic floor

5.2.1 Static MRI

5.2.2 Dynamic MRI

5.2.3 Clinical applications of MRI of posterior compartment

5.2.3.1 Fecal incontinence

5.2.3.2 Levator ani injuries

5.2.3.3 Obstructed defecation syndrome (ODS)

5.2.3.4 Perianal abscesses and fistulas

### 5.3 Defecating proctography

5.3.1 Clinical applications of defecating proctography

5.3.1.1 Pelvic floor descent

5.3.1.2 Intussusception and prolapse

5.3.1.3 Rectocele

5.3.1.4 Enterocele

5.3.1.5 Dyssynergic defecation

### 5.4 Contrast Enema

5.4.1 Single – contrast barium enema

5.4.2 Double – contrast or air – contrast barium enema

### 5.5 Colonic transit studies

5.5.1 Radiological transit (shapes) study

5.5.2 Nuclear transit study

## **5.1 Ultrasonography (2D/3D/4D) of the posterior compartment including anal sphincters, pelvic floor muscles and prolapse (Endoanal, Transperineal, Transvaginal)**

Ultrasound is increasingly being incorporated as an investigation of posterior compartment disorders<sup>7,74</sup> (Table 3). An integrated multi-compartmental pelvic floor ultrasonography with a combination of different modalities has been described to assess pelvic floor dysfunction for a global and multi-compartmental perspective<sup>75,76</sup>.

Modalities in current routine clinical use:

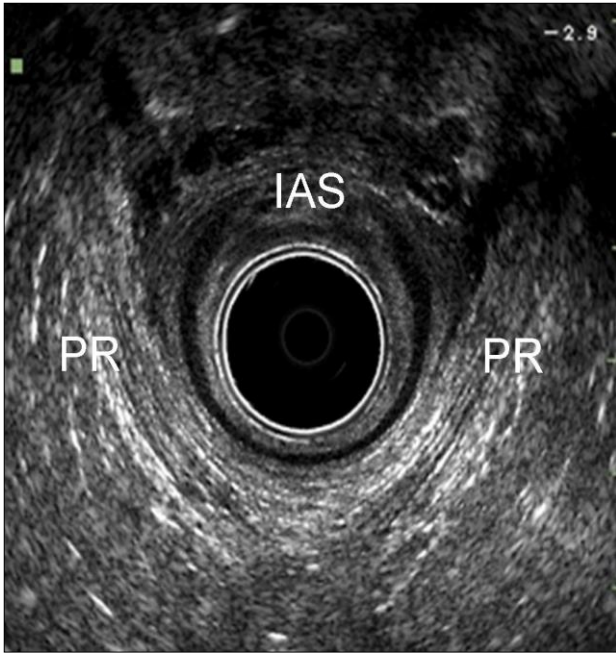
- (a) **Endoanal:** intra-anal 360° sector scanning using rotational mechanical probe or radial electronic probe;
- (b) **Transperineal:** curved array probe applied in the perineum between the mons pubis and the anal margin. This term incorporates trans-labial ultrasound. Introital ultrasound is usually assumed to imply the placement of transducer with smaller footprints (such as end-firing endo-vaginal probe) within the introitus;
- (c) **Transvaginal:** intra-vaginal curvilinear, linear array, or 360°sector scanning.

### **5.1.1 Endoanal ultrasonography (EAUS)**

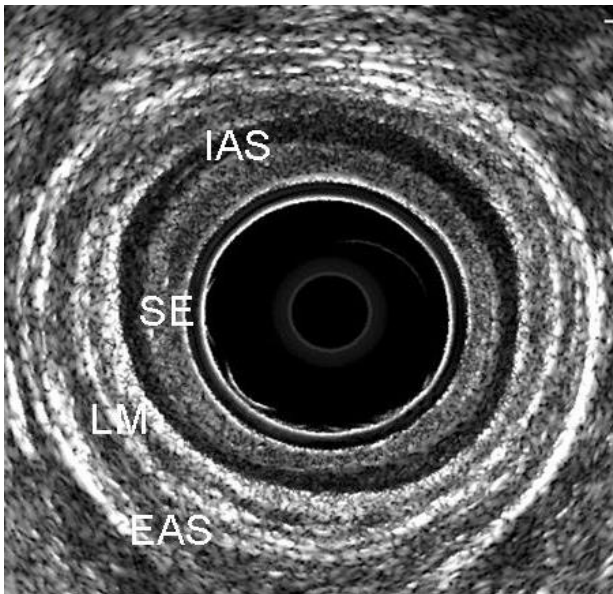
The majority of current systems provide **2D & 3D Imaging** which give a 360° axial view of the anal canal and of the rectal wall<sup>4,77,78</sup>. Endoanal ultrasound can be performed with the patient placed in the dorsal lithotomy, left lateral or prone position. Irrespective of the position, the probe should be rotated so that the anterior aspect of the anal canal is superior (12 o'clock) and left lateral is right (3 o'clock) on the screen. The anal canal is divided into three levels of assessment in the axial plane referring to the following anatomical structures:

- **Upper level:** the hyperechoic sling of the puborectals muscle (PR) and the complete ring of the internal anal sphincter (IAS) are visualized (FIGURE 1a).
- **Middle level:** corresponds to the superficial part of the EAS (concentric band of mixed echogenicity), the conjoined longitudinal layer, the IAS (concentric hypoechoic ring), and the transverse superficial perinei muscles (FIGURE 1b);
- **Lower level:** corresponds to the subcutaneous part of the EAS where the IAS is absent (FIGURE 1c).

**Fig 1a**



**Fig 1b**



**Fig.1c**

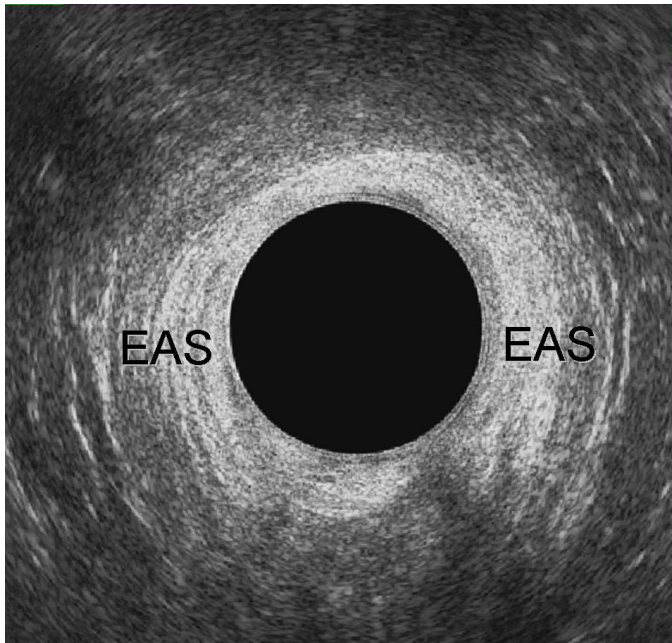

Figure 1: Endoanal ultrasonography. (a) Upper level of the anal canal; (b) Middle level of the anal canal; (c) Lower level of the anal canal. PR= puborectalis; IAS= internal anal sphincter; EAS= external anal sphincter; LM= longitudinal muscle; SE= sub epithelium

The acquisition of a three-dimensional data volume (**3D ultrasound**) and the underlying techniques vary. Acquisition may be “**free-hand**” (**low resolution 3D**) or “**automatic computer-controlled**” (**high resolution 3D**).<sup>79,80</sup>

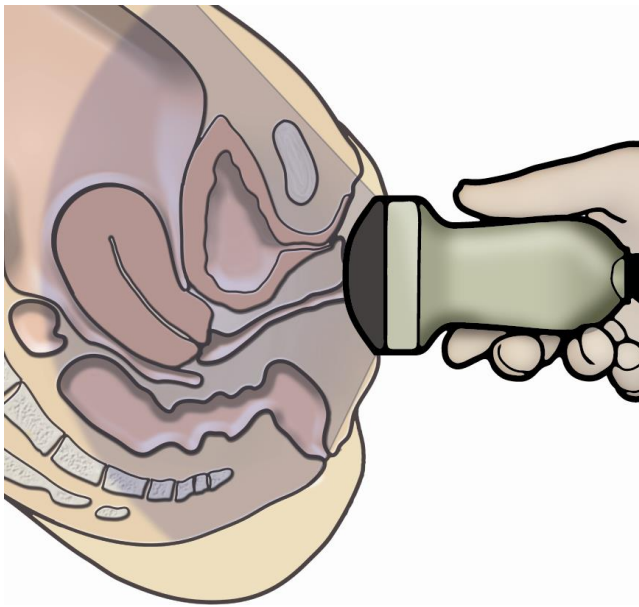
### **5.1.2 Transperineal ultrasonography (TPUS)**

Conventional convex transducers (frequencies between 3 and 6 MHz and field of view at least 70°) provide 2D imaging of the pelvic floor<sup>81,82</sup>. Transperineal ultrasound is performed with the patient placed in the dorsal lithotomy position, with the hips flexed and abducted. If necessary, the patient can be examined standing, to maximise descent of pelvic organs, especially if the patient finds it difficult to produce an effective Valsalva maneuver. No rectal or vaginal contrast is used. Perineal ultrasound provides sagittal, coronal and oblique sectional imaging, with the mid-sagittal plane being the most commonly used as this gives an overall assessment of all anatomical structures (bladder, urethra, vaginal walls, anal canal and rectum) between the posterior surface of the symphysis pubis (SP) and the posterior part of the levator ani (LA) (FIGURE 2a-2b). The imaging is usually performed at rest, on maximal Valsalva maneuver and on pelvic floor muscle contraction (PFMC). The access to the mid-sagittal plane allows the following evaluations<sup>83</sup>:

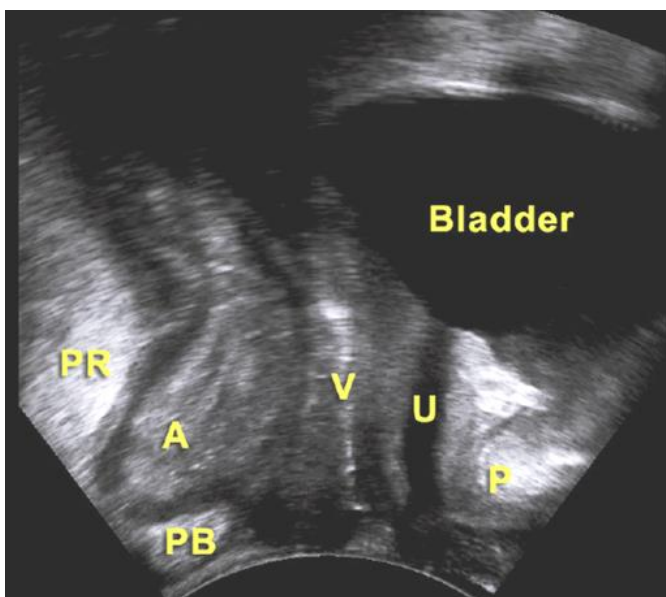
- Integrity of the perineal body: appearing as a triangular shaped, slightly hyperechoic structure anterior to the anal sphincter;

- Measurement of the anorectal angle (ARA): formed by the longitudinal axis of the anal canal and the posterior rectal wall;
- Dynamic assessment of the posterior compartment. During Valsalva it is possible to visualize descent of an enterocele, to assess the movement of the anterior rectal wall to detect a rectocele, and to evaluate movement of the PR and ARA to diagnose pelvic floor dyssynergy (FIGURE 2c).

**Fig 2a**



**Fig 2b**



**Fig 2c**

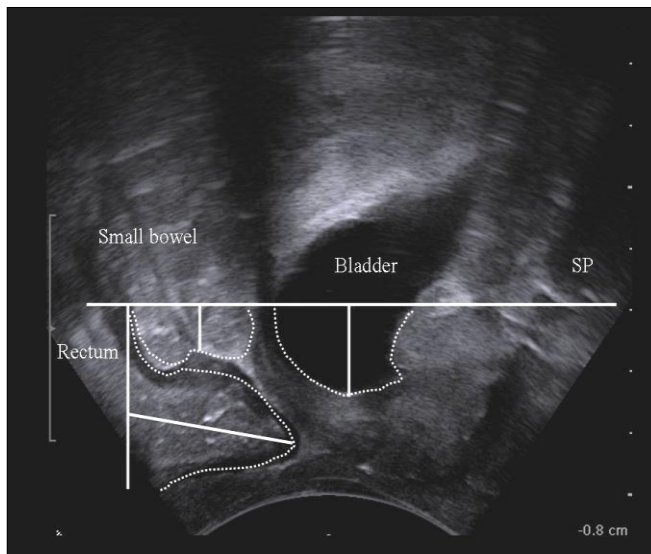


Figure 2: 2D-Transperineal ultrasound. (a) Schematic drawing; (b) Pelvic organs at rest; (c) Pelvic organs descend below the symphysis pubis line after Valsalva maneuver (cystocele, enterocele, rectocele). PR: puborectalis muscle; A: anal canal; PB: perineal body; V: vagina; U: urethra; P/SP: symphysis pubis

3D TPUS may be performed with volumetric probes (electronic curved array of 4–8 MHz). An advantage of this technique is the opportunity to obtain tomographic or multi-slice imaging, e.g. in the axial plane, in order to assess the entire PR and its attachment to the pubic rami<sup>84</sup> (FIGURE 3). It is also possible to measure the diameter and area of the levator hiatus (LH) and determine the degree of hiatal distension on Valsalva. Four dimensional (4D) imaging indicates real-time acquisition of volume ultrasound data.



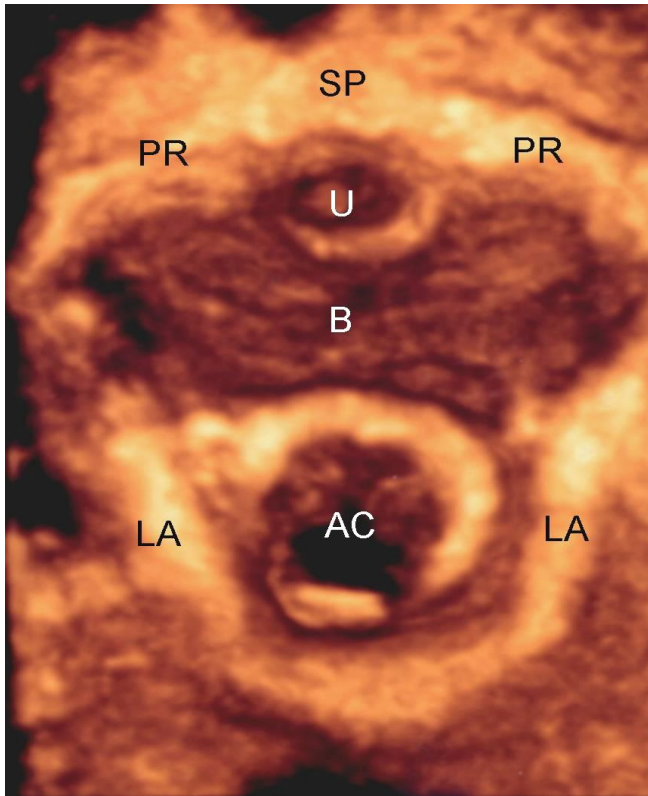


Figure 3: 3D-Transperineal ultrasound. Axial image of the pelvic floor at rest showing the LA attachment to the pubic rami (PR). AC: anal canal; LA: levator ani; B: bladder; U: urethra; SP: symphysis pubis

### 5.1.3 Transvaginal ultrasonography (TVUS)

Transvaginal ultrasound is performed with the patient placed in the dorsal lithotomy position. Currently, the transducers used for pelvic floor 3D TVUS are high multi-frequency (9-16 MHz), 360° rotational mechanical probe or radial electronic probe (FIGURE 4a). The pelvic floor is divided into four levels of assessment in the axial plane referring to the following anatomical structures<sup>85</sup>: (*not to be confused with Delancey's description of vaginal Levels of supports*)

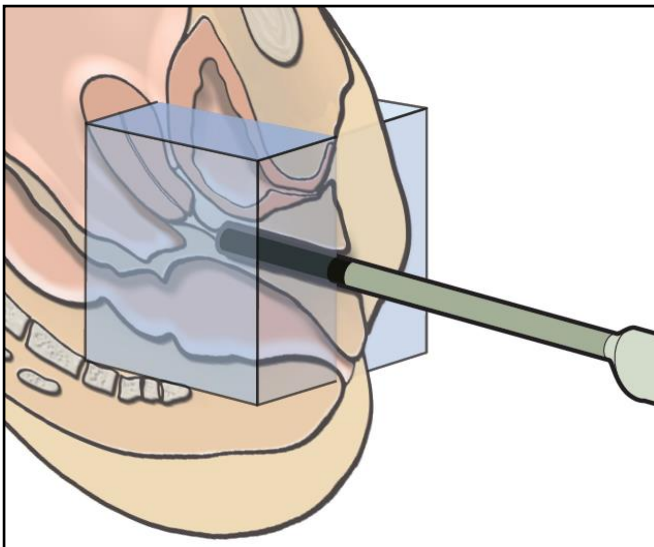
- **Level I:** at the highest level the bladder base is visualized on the screen at 12 o'clock position and the inferior third of the rectum at 6 o'clock position;
- **Level II:** corresponds to the bladder neck, the intramural region of the urethra and to the anorectal junction. At this level the subdivisions of the LA (pubovaginalis, puboperinealis, puboanalis, puborectalis, and iliococcygeus) may be identified;
- **Level III:** corresponds to the midurethra and to the upper third of the anal canal. At this level the LA is visualized as a multilayer hyperechoic sling coursing lateral to the vagina and posteriorly to the anal canal and attaching to the inferior pubic ramus (FIGURE 4b). In the axial plane of minimal hiatal dimensions, identified as the minimal distance between the inferior edge of the SP and the anterior border of the LA at the ARA, the biometric indices

(anteroposterior and transverse diameters, area) of the LH can be determined (FIGURE 4c)<sup>86</sup>;

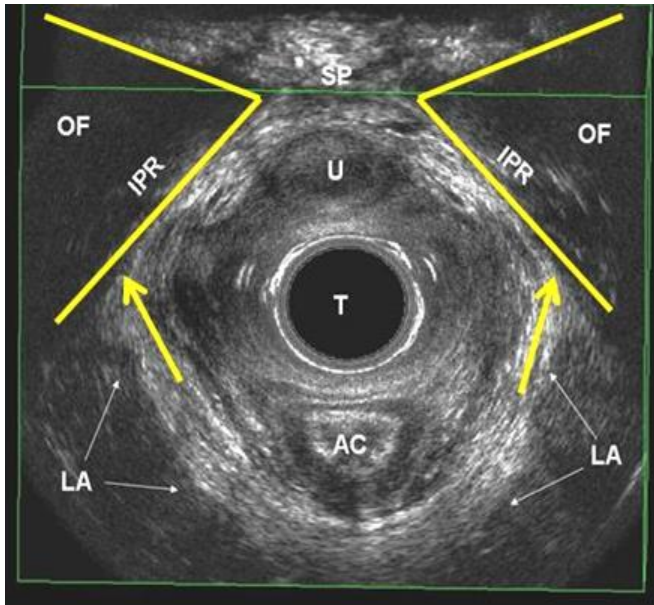
- **Level IV:** at the outer level, the perineal muscles (bulbospongiosus, ischiocavernosus and superficial transverse perineii muscles), the perineal body, the distal urethra and the middle and inferior third of the anal canal are visualized. The anterior-posterior diameter of the urogenital hiatus (UGH), corresponding to the SP-perineal body distance, can be determined<sup>87</sup>.

Transvaginal ultrasound may be also performed with electronic probes with linear array, which provide mid-sagittal image of the posterior compartment<sup>76</sup>. The main advantage of this technique is the dynamic assessment of the anorectal region, during Valsalva and pelvic floor muscle contraction (PFMC).

**Fig 4a**



**Fig 4b**



**Fig 4c**

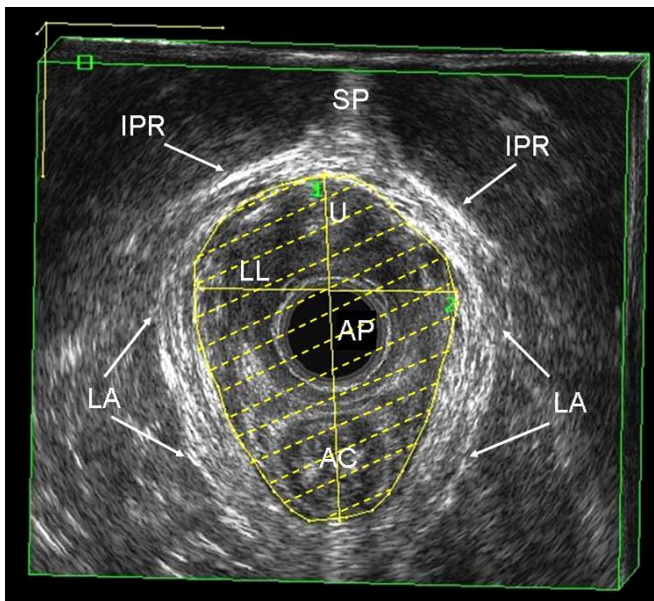


Figure 4: 3D-Endovaginal ultrasound. (a) Schematic drawing; (b) Axial image of the pelvic floor at Level III, showing the LA attachment to the inferior pubic rami (IPR) and (c) the levator hiatus. AC: anal canal; LA: levator ani; B: bladder; U: urethra; SP: symphysis pubis; OF: obturator foramen; T: transducer; AP: anteroposterior diameter of the levator hiatus; LL: laterolateral diameter of the levator hiatus

## **5.1.4 Clinical applications of ultrasonography of the posterior compartment**

### **5.1.4.1 Fecal incontinence**

Anal inspection and digital rectal examination can give information about internal and external anal sphincter function but are inaccurate for determining external anal sphincter defects <90 degrees and internal sphincter defects. Therefore, a sufficient diagnostic work-up should comprise at least rectal examination, anal inspection and endoanal ultrasonography<sup>88</sup>. EAUS has become the gold standard for morphological assessment of the anal canal<sup>75</sup>. The International Consultation on Incontinence (ICI)<sup>89</sup> has recommended EAUS as the first line imaging investigation for fecal incontinence to differentiate between those with intact anal sphincters and those with sphincter lesions (defects, scarring, thinning, thickening and atrophy). Routine use of transperineal, transvaginal and translabial ultrasonography to image the anal sphincter complex are not recommended<sup>89</sup>, although research is ongoing. The operator should identify if there is a combined or isolated lesion of the IAS and EAS and report the number of defects, as well as the extent of the defect circumferentially (radial angle in degrees or in hours of the clock) and longitudinally (proximal, distal or full length)<sup>89-91</sup>. Using 3D EAUS, two scoring systems have been proposed to define the severity of anal sphincter damage<sup>92,93</sup>.

EAUS has an important role in detecting undiagnosed anal sphincter injuries following vaginal delivery<sup>2</sup> and can be useful in the management of subsequent pregnancies following OASIS (119). It is also useful to evaluate the results of treatment (anterior sphincter repair, bulking agent injections)<sup>75,89</sup>.

### **5.1.4.2 Levator ani injuries**

Levator avulsion is the disconnection of the muscle from its insertion on the inferior pubic ramus and the pelvic sidewall, whereas tears may occur in any part of the muscle. Avulsion is a common consequence of overstretching of the levator ani during the second stage of labor and it is detectable by 3D TVUS and 3D TPUS imaging as the lateral attachments of the levator ani to the pubic bone are clearly visualized<sup>94</sup>. Defects are usually visualized most clearly on maximal PFMC. Tomographic ultrasound imaging is particularly useful. Levator ani injuries affect the size of the levator hiatus, with a hiatal enlargement to over 25cm<sup>2</sup> on Valsalva maneuver defined as 'ballooning', and are related to symptoms and signs of prolapse.

### **5.1.4.3 Obstructed defecation syndrome (ODS)**

The term obstructed defecation syndrome (synonym: "outlet obstruction") encompasses all pelvic floor dysfunctions, which are responsible for an incomplete evacuation of fecal contents

from the rectum, straining at stool and vaginal digitations. During maximal Valsalva maneuver, dynamic TPUS and TVUS may be used to demonstrate<sup>82,95</sup>

- **Rectocele:** herniation of a depth of over 10 mm of the anterior rectal wall;
- **Rectal intussusception:** invagination of the rectal wall into the rectal lumen, into the anal canal or exteriorized beyond the anal canal (rectal prolapse);
- **Enterocoele:** herniation of bowel loops into the vagina. It can be graded as small, when the most distal part descends into the upper third of the vagina, moderate, when it descends into the middle third of the vagina, or large, when it descends into the lower third of the vagina;
- **Dyssynergic defecation:** the ARA becomes narrower, the LH is shortened in the anteroposterior dimension, and the PR muscle thickens as a result of contraction.

#### **5.1.4.4. Perianal abscesses and fistulas**

**5.2 MRI for anal sphincters and pelvic floor** (*static, dynamic, endocoil*) upright, supine, left lateral position

##### **5.2.1 Static MRI**

Static MRI provides detailed information of the pelvic floor anatomy<sup>96</sup>. Current state-of-the-art MR imaging of the pelvic floor includes imaging at a magnetic field strength of 1.5 Tesla (T), using pelvic or phased-array coils and T2-weighted fast-spin echo (FSE) sequences. The spatial resolution can be enhanced by using endoluminal (endorectal, endovaginal) coils. In combination with T2-weighted FSE sequences, endoluminal coils provide improved signal-to-noise ratio (SNR) and high resolution images<sup>97</sup>. Based on T2-weighted turbo spin-echo sequences, muscles are relative hypointense, ligaments and fascia hypointense while fat and smooth muscle are hyperintense. The prominent pelvic floor structures of the posterior compartment visualized at MRI are (FIGURE 5):

- Perineal body and superficial perineal muscles
- Anal sphincters: the IAS is easily recognized as a circular hyperintense structure. It is approximately 2.9 mm thick on endoluminal MRI. The inter-sphincteric space is seen as a bright line on T2-weighted MRI. The EAS has a thickness of 4.1 mm on endoluminal imaging;
- Puborectalis muscle and levator ani;
- Superficial perineal muscles;
- Rectum and rectal support.

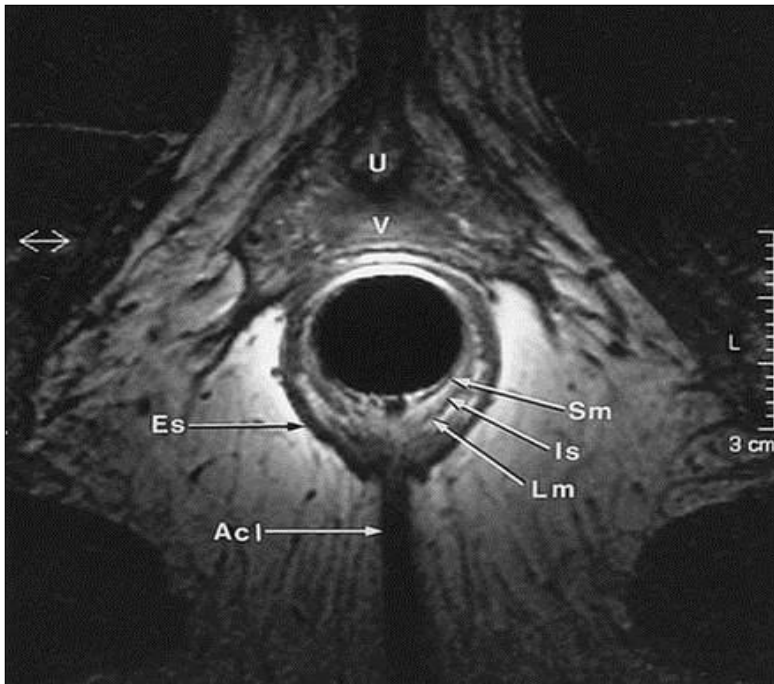


Figure 5: Static MRI. Axial image of the anal canal. U: urethra; V: vagina; SM: submucosa; IS: internal sphincter; LM: longitudinal muscle; ES: external sphincter; ACL: anococcygeal ligament

### 5.2.2 Dynamic MRI

With the development of fast multi-slice sequences MR imaging has gained increasing acceptance for dynamic imaging of pelvic floor. Because the posterior compartment is traditionally in the focus of interest, dynamic MR imaging of the pelvic floor is often called “**MR defecography**”<sup>98</sup>.

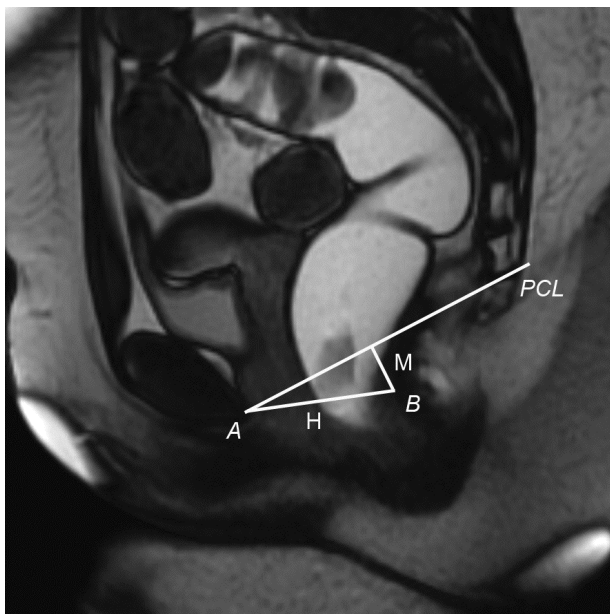
Dynamic pelvic imaging may be performed in an open-configuration MR system in the sitting position, or in a closed-configuration MR-system in the supine position. Both techniques are equally effective in identifying most of the clinically relevant abnormalities of the pelvic floor<sup>98</sup>. For evaluation of the posterior compartment of the pelvic floor, the rectum should be filled with a contrast agent (ultrasound gel or mashed potatoes, gadolinium-based MR contrast agent) to study the actual act of defecation.

The use of reference lines for image evaluation is helpful<sup>99,100</sup>. The most used reference line is the pubococcygeal line (PCL), which is defined on mid-sagittal images as the line joining the inferior border of the symphysis pubis to the last or second last coccygeal joint (FIGURE 6a). The anorectal junction (ARJ) is defined as the cross point between a line along the posterior wall of the distal part of the rectum and a line along the central axis of the anal canal.

To determine pathologic pelvic floor descent, the measurements are made on the images, which show maximal organ descent, usually during maximal straining or during evacuation (FIGURE 6b). The anorectal angle (ARA) is defined as the angle between the posterior wall of the distal part of the rectum and the central axis of the anal canal and can be measured at rest, squeezing and straining. The extent of rectoceles and enteroceles are measured.

The degree of pelvic floor relaxation is measured with two reference lines (FIGURE 6a): the H line which represents hiatal widening and extends from the inferior aspect of the symphysis pubis to the posterior wall of the rectum at the level of the ARJ and the M line which represents hiatal descent and extends perpendicularly from the PCL to the posterior end of the H line. Lesions of the pelvic musculofascial support result in widening of the hiatus and descent of the levator plate. Thus, the H and M lines tend to elongate with pelvic floor relaxation, widening the levator plate descent. Abnormal pelvic floor relaxation is present, when the H line exceeds 6 cm, and when the M line exceeds 2 cm in length.

**Fig 6a**



**Fig 6b**

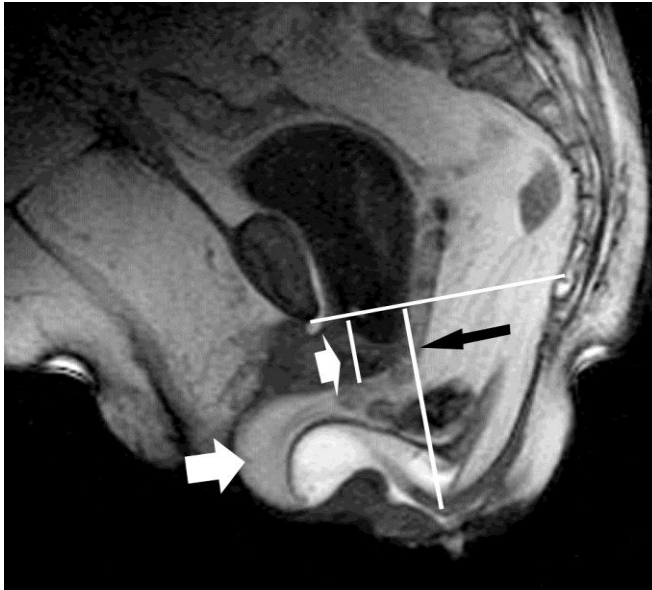


Figure 6: Dynamic MRI. (a) Mid-sagittal steady state free precession T2-weighted image obtained at straining shows landmarks used in the HMO-system. The landmarks are the inferior aspect of the symphysis pubis (*A*) and the posterior wall of the rectum at the level of the anorectal junction (*B*). The H line (*H*) represents the anteroposterior hiatal width and extends from *A* to *B*. The M line (*M*) represents hiatal descent and extends perpendicularly from the pubococcygeal line (*PCL*) to the posterior end of the H line. (b) During Valsalva maneuver, there is a bladder descent below the *PCL* (small white arrow), with a perineal descent (black arrow) and a rectocele developing with a posterior vaginal wall prolapse (long white arrow)

### **5.2.3 Clinical applications of MRI of the posterior compartment**

#### **5.2.3.1 Fecal incontinence**

Endoanal ultrasound and endoanal magnetic resonance imaging (MRI) have been demonstrated to be comparable in the detection of external sphincter defects<sup>101</sup>. External phased array coil MRI can replace endoluminal MRI with comparable results<sup>102</sup>.

#### **5.2.3.2 Levator ani injuries**

Abnormalities of the LA are identified on MRI as present or absent<sup>103</sup>. Defect severity is further scored in each muscle from 0 (no defect) to 3 (complete loss). A summed score for the 2 sides (0 to 6) is assigned and grouped as minor (0-3) or major (4-6).

#### **5.2.3.3 Obstructed defecation**

During maximal Valsalva maneuver, dynamic MRI may be used to demonstrate:

- **Rectocele:** measured as the depth of wall protrusion beyond the expected margin of the normal anorectal wall. Based on sagittal MR-sections through mid of pelvis,



rectoceles are graded as small (< 2cm), moderate (from 2 to 4cm), and large (> 4cm).

- **Rectal intussusception:** the infolding of the rectal mucosa occurring during defecation. Depending on the location, an intrarectal intussusception, limited to the rectum, is distinguished from an intra-anal intussusception extending into the anal canal. The location of the intussusception may be anteriorly, posteriorly, or circumferentially. The intussusception either involves only the mucosa or the full thickness of the rectal wall;
- **Enterocoele:** defined as a herniation of the peritoneal sac, which contains omental fat (peritoneocoele), small bowel (enterocoele) or sigmoid (sigmoidocoele), into the rectovaginal or rectovesical space below the PCL. The largest distance between the PCL and the most inferior point of the enterocoele is measured with a perpendicular line. Depending on this distance, small (< 3cm), moderate (3-6cm), and large (> 6cm) enterocoeles are distinguished;
- **Dyssynergic defecation:** different structural imaging findings can be seen on dynamic pelvic MRI, including prominent impression of the puborectal sling, narrow anal canal, prolonged evacuation, a lack of descent of the pelvic floor and thus a failure to increase the ARA.

In comparison with clinical examination (POP-Q), dynamic MRI has no additional value in the prediction of symptoms with increasing degree of POP<sup>104</sup>.

#### **5.2.3.4 Perianal abscesses and fistulas**

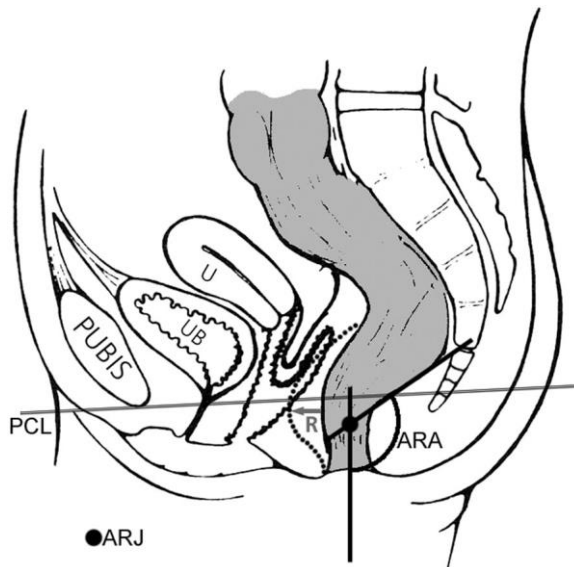
### **5.3 Defecating proctography**

Evaluates in real time the morphology of rectum and anal canal in correlation with pelvic bony components both statically and dynamically by injection of a thick barium paste into the rectum and its subsequent evacuation<sup>105</sup>. Contrast administration into the bladder and vagina provides a more comprehensive assessment of the pelvic organs and has been labelled “**dynamic cystoproctography**”<sup>104</sup>.

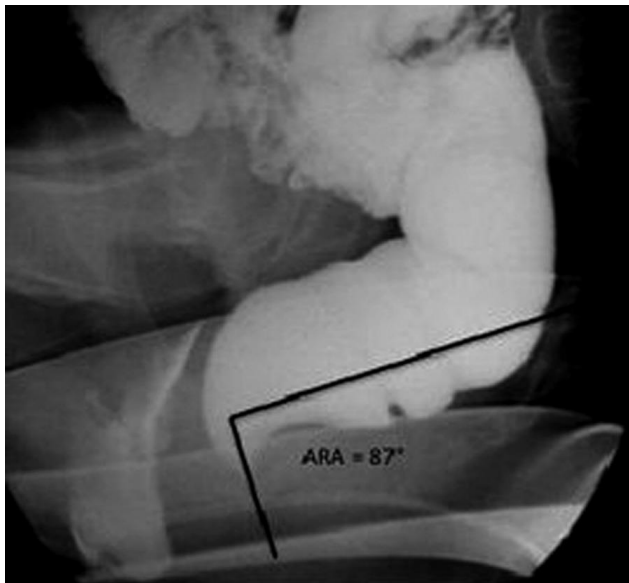
At rest, the anal canal is closed and rectum assumes its normal upright configuration. The position of the pelvic floor is inferred by reference to the PCL (inferior margin of pubic symphysis to the sacro-coccygeal junction) (FIGURE 7a). Perineal descent is measured from this line to the ARJ, and may be up to 1.8cm at rest. Some pelvic floor descent during evacuation is considered normal, and a descent of up to 3cm from the rest position to anal canal opening is acceptable. The ARA is defined as the angle between the anal canal axis and the posterior rectal wall, and on average is around 90° (FIGURE 7b). The puborectalis

length (PRL) can be estimated by measuring the distance between the ARA and symphysis pubis.

**Fig 7a**



**Fig 7b**



**Fig 7c**

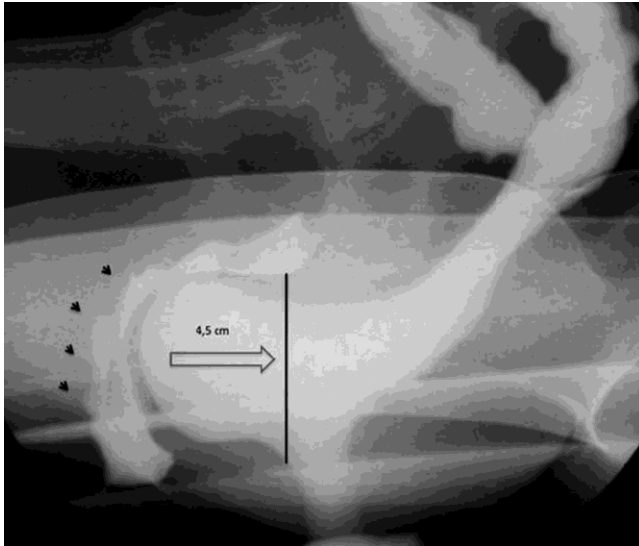


Figure 7: Defecating proctography. (a) Schematic drawing; (b) Measurement of the anorectal angle at rest (ARA); (c) Image during Valsalva manouever, showing the displacement of the anterior rectal wall (rectocele) with posterior vaginal wall prolapse (black arrows). PCL: pubococcygeal line; UB: urinary bladder; U: uterus; ARJ: anorectal junction; R: rectocele

A normal emptying phase at the proctogram is described by five elements:

- Increase in the ARA by around 20 to 30 degrees;
- Obliteration of the puborectalis impression and the PRL should increase by around 3 to 4cm;
- Wide opening of the anal canal within a couple of seconds;
- Evacuation of rectal contents proceeding promptly and to completion;
- Lack of significant pelvic floor descent.

After evacuation is complete, the anal canal should close, the ARA recover and the pelvic floor return to its normal baseline position. Post toilet imaging may be required, particularly in those suspected of retained barium within rectoceles (FIGURE 7c).

### **5.3.1 Clinical applications of defecating proctography**

Assuming that posterior wall prolapse and rectocele can be considered the same anatomic entity, clinical examination is not accurate in diagnosing anatomical defects of posterior vaginal wall and enteroceles compared to defecography as reference standard. Clinical examination overestimates the presence of the posterior wall defects (large false positive rates) but misses enterocele in patients with primary POP (large false negative rates)<sup>106-107</sup>. The major function of proctography is not merely to document evacuatory abnormalities, but also to classify those abnormalities into those potentially surgically relevant, those likely to benefit from behavioral biofeedback therapy alone, or indeed those which are incidental<sup>108</sup>.

#### **5.3.1.1 Pelvic floor descent**

Pelvic floor descent, defined as the distance moved by the ARJ or ARA at rest to the point of anal canal opening, is considered abnormal if it exceeds 3cm<sup>105</sup>.

#### **5.3.1.2 Intussusception and prolapse**

Intussusception refers to infolding of the rectal wall into the rectal lumen. It may be described as intra-rectal, intra-anal or external to form a complete rectal prolapse.

#### **5.3.1.3 Rectocele**

Rectocele diagnosis on evacuation proctography is defined as any anterior rectal bulge (FIGURE 7c). The depth of a rectocele is measured from the anterior border of the anal canal to the anterior border of the rectocele. A distance of <2cm is classified as small, 2-4cm as moderate and >4cm as large. Of more relevance however is barium trapping at the end of evacuation (defined as retention of >10% of the area, and this itself is related the size of the rectocele).

#### **5.3.1.4 Enterocele**

An enterocele is diagnosed when small bowel loops enter the peritoneal space between the rectum and vagina. Diagnosis of an enterocele on proctography is only really possible if oral contrast has been administered before the examination<sup>105</sup>. Herniation of the sigmoid into the rectogenital space (sigmoidocele) is significantly less common than an enterocele.

#### **5.3.1.5 Dyssynergic defecation**

Various proctographic abnormalities have been described including prominent puborectal impression, a narrow anal canal, and acute anorectal angulation. However these observations may be found in normal controls and are in themselves unreliable distinguishing features.

### **5.4 Contrast enema**

Contrast enema is used to identify colon pathology (benign and malignant lesions, diverticular disease, inflammatory conditions, congenital anomalies, intrinsic and extrinsic abnormalities).

#### **5.4.1 Single-contrast barium enema**

Using an appropriate catheter, a barium-water mixture or a water-soluble solution of diatrizoate sodium (Gastrografin) is inserted into the colon with the patient in the prone position until the column of barium reaches the splenic flexure.

#### **5.4.2 Double-contrast or air-contrast barium enema**

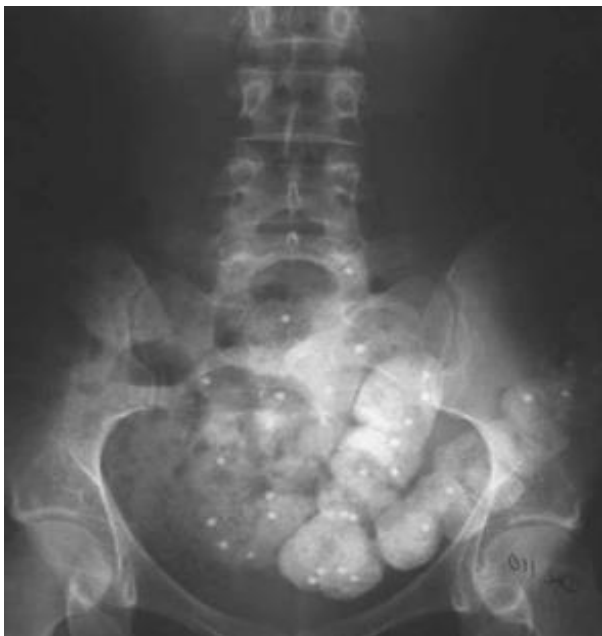This procedure has become the routine study for evaluation of the bowel<sup>108</sup>. With the double-contrast examination, the colon is coated with a thin layer of contrast material and the bowel is distended with air so that the entire mucosal circumference is visualized.

#### **5.5 Colonic transit studies (radio-opaque oral markers, pill transit, nuclear medicine scintigraphy)**

Slow transit constipation can be distinguished by colonic transit studies<sup>109,110</sup>.

##### **5.5.1 Radiological transit (shapes) study**

Segmental and total colonic transit time is assessed with the use of radio-opaque markers and sequential abdominal X-rays. There are different protocols. Most frequently used, utilizes a capsule containing 24 markers of 1x4.5mm. Patient takes one capsule on day 0 by mouth and X-ray is performed on day 5 (FIGURE 8). Patients who expel at least 80% markers on day 5 have normal colonic transit. Patients who retain 6 or more markers may have follow-up abdominal X-rays within several days. If remaining markers are scattered about the colon, the condition is slow transit or colonic inertia. If the remaining markers are accumulated in the rectum or rectosigmoid, this suggests functional outlet obstruction.



**Figure 8:** Radiologic transit study. On day 5, the remaining markers are more than 80%, suggesting functional outlet obstruction

### **5.5.2 Nuclear transit study**

Colon scintigraphy is performed at 6, 24, and 48 hours in ventral and dorsal projection after oral administration of methacrylate-coated capsule of non-resorbable <sup>111</sup>In-dium-labeled polystyrene (<sup>111</sup>In-DTPA) micropellets<sup>109</sup>. The geometric center, as the sum of products of colon segment activity and colon segment number (1= ascending colon, 2= transverse colon, 3= descending colon, 4= rectosigmoid, and 5= evacuated feces) dividing by the total counts is used to determine the velocity of colonic transit. Meals normally reach the cecum at 6 hours and are evacuated in 30 to 58 hours. Retention of radioactivity in the proximal colon at 48 hours, indicates slow colonic transit while retention in the rectum indicates anorectal dysfunction.

**Table 3.** Imaging modalities for female anorectal dysfunction

<b>CONDITIONS</b>	<b>IMAGING TECHNIQUES</b>	<b>LEVELS OF EVIDENCE</b>	<b>GRADE OF RECOMMENDATION</b>
<b>Fecal incontinence</b>	<b>Endoanal US</b>	<b>Level II</b>	<b>Grade B</b>
	<b>Static MRI</b>	<b>Level II</b>	<b>Grade B</b>
	<b>Defecating proctography</b>	<b>Level III</b>	<b>Grade C</b>
<b>Pelvic organ prolapse</b>	<b>Dynamic MRI</b>	<b>Level II</b>	<b>Grade B</b>
	<b>Transperineal US</b>	<b>Level II</b>	<b>Grade B</b>
	<b>Defecating proctography</b>	<b>Level II</b>	<b>Grade B</b>
<b>Obstructed defecation</b>	<b>Dynamic MRI</b>	<b>Level II</b>	<b>Grade B</b>
	<b>Defecating proctography</b>	<b>Level II</b>	<b>Grade B</b>
	<b>Transperineal US</b>	<b>Level III</b>	<b>Grade C</b>
<b>Perianal sepsis</b>	<b>Static MRI</b>	<b>Level II</b>	<b>Grade B</b>
	<b>Endoanal US</b>	<b>Level II</b>	<b>Grade B</b>
	<b>Fistulography</b>	<b>Level III</b>	<b>Grade C</b>
<b>Chronic pelvic pain</b>	<b>Static MRI</b>	<b>Level III</b>	<b>Grade C</b>

## **6. DIAGNOSIS** (most common) [defined as prevalence >10%]

Diagnosis is based on symptoms, signs, examination, and any relevant diagnostic investigations

### **6.1 Local (fissures, hemorrhoids)**

Fissure: Is a break in the lining of the anal canal

Hemorrhoids: abnormality of the normal cushion of specialized, highly vascular tissue in the anal canal in the submucosal space.

### **6.2 Fecal incontinence**

Fecal incontinence: involuntary loss of solid or liquid stool and could be due to

**6.2.1** Anal sphincter disruption is due to discontinuity of the external anal sphincter, internal anal sphincter or both.

**6.2.2** Hypocontractile/acontractile sphincter is due to neuropathy or atrophy

**6.2.3** Combined anal sphincter disruption and hypocontractile/acontractile sphincter

**6.2.4** Rectal overactivity due to exaggerated smooth muscle contraction of the rectum could also be associated with hypersensitivity<sup>110,111</sup>

**6.2.5** Overflow incontinence seepage of stool due to fecal impaction

### **6.3 Obstructed defecation Syndrome**

Obstructed defecation: incomplete evacuation of fecal contents from rectum due to physical blockage of the fecal stream during defecation attempts. It includes symptoms such as straining to defecate, sensation of blockage, digitation and splinting. Constipation due to slow transit, irritable bowel syndrome, Hirschsprung's disease, megarectum, anismus are not within the remit of this standardization document. Associated features of obstructed defecation are:

**6.3.1 Rectocele:** bulge in posterior vaginal wall associated with herniation of anterior wall of the rectum (See FN 16)

**6.3.2 Enterocele/sigmoidocele:** bulge of upper wall of vagina associated with herniation of peritoneal sac and small bowel (enterocele) or sigmoid colon (sigmoidocele)

**6.3.3 Intussusception:** full thickness invagination of the upper rectum without extrusion through the anus leading to interruption of flow of the fecal stream

**6.3.4 Internal mucosal prolapse:** Mucosal prolapse of the anterior, posterior or circumferential mucosal layer.

**6.3.5 External rectal prolapse:** Full thickness rectal prolapse outside the anal canal

### **6.4 Sepsis**



#### **6.4.1 Abscess:**

Infection in a (non Crohn's) anal gland, located at the base of the dentate line, that initially forms an abscess, which can be located in one of the potential spaces surrounding the anus and rectum.

#### **6.4.2 Ano-rectal/vaginal/perineal fistula:**

Rectovaginal fistula is a communication from the rectum to the vagina and rarely the perineal area. An anovaginal/perineal fistula is an abnormal communication from the anal canal to the vagina or perineal area.

### **6.5 Pain Syndromes**

#### **6.5.1 Levator ani syndrome**

Episodic rectal pain caused by spasm of the levator ani muscle. Proctalgia fugax (fleeting pain in the rectum) and coccydynia (pain in the coccygeal region) are variants of levator ani syndrome. (See FN 17)

#### **6.5.2 Proctalgia fugax**

Definition: Proctalgia fugax (or Levator syndrome) is a severe, episodic, rectal and sacrococcygeal pain<sup>112</sup>. It can be caused by cramp of the pubococcygeus or levator ani muscles. (See FN 18)

#### **6.5.3 Pudendal neuralgia**

Pudendal Neuralgia (PN) is a painful condition that is caused by inflammation of the pudendal nerve involving its dermatome<sup>115</sup>. It can affect both men and women. (See FN 20)

### **6.6 Obstetric Anal Sphincter Injuries (OASIS)**

OASIS are reported to occur in 0.5 to 14% of vaginal deliveries (2.9 to 19% of primiparous vaginal deliveries)<sup>116</sup>. It has previously been shown in a prospective study that about one third of OASIS can be diagnosed 8 weeks after delivery by endoanal ultrasound alone. As these were not identified clinically, the injuries were believed to be "occult"<sup>2</sup>. However, it has subsequently been proven that such injuries are not necessarily occult but in fact undiagnosed due to lack of expertise of midwives and doctors<sup>3</sup>.

Training in diagnosis and management of perineal trauma has been shown to be suboptimal<sup>117</sup> and dedicated hands-on courses have shown significant improvements in diagnosis and classification of OASIS<sup>118</sup>. Sultan therefore proposed a more descriptive classification of OASIS (Fig 9, 10)<sup>119</sup> that has now been accepted internationally to support consistency in

reporting<sup>120-122</sup>. To avoid underestimation of the injury, if there is uncertainty regarding the full extent of the injury it should be classified as the greater degree eg. if one is unsure as to whether an injury is a Grade 3a or 3b it should be classified as 3b. This classification also has clinical relevance as it ensures increased vigilance for internal sphincter injuries that are best repaired soon after delivery<sup>123</sup> as persistent internal sphincter defects are associated with fecal incontinence<sup>124</sup>. Examination techniques to improve detection of these injuries and avoiding pitfalls in diagnosis have been described in detail<sup>116</sup>.

**Fig 9** Classification of perineal trauma<sup>116</sup>

**First degree:** laceration of the vaginal epithelium or perineal skin only.

**Second degree:** involvement of the perineal muscles but not the anal sphincter.

**Third degree:** disruption of the anal sphincter muscles that should be further subdivided into:

**3a:** <50% thickness of external sphincter torn.

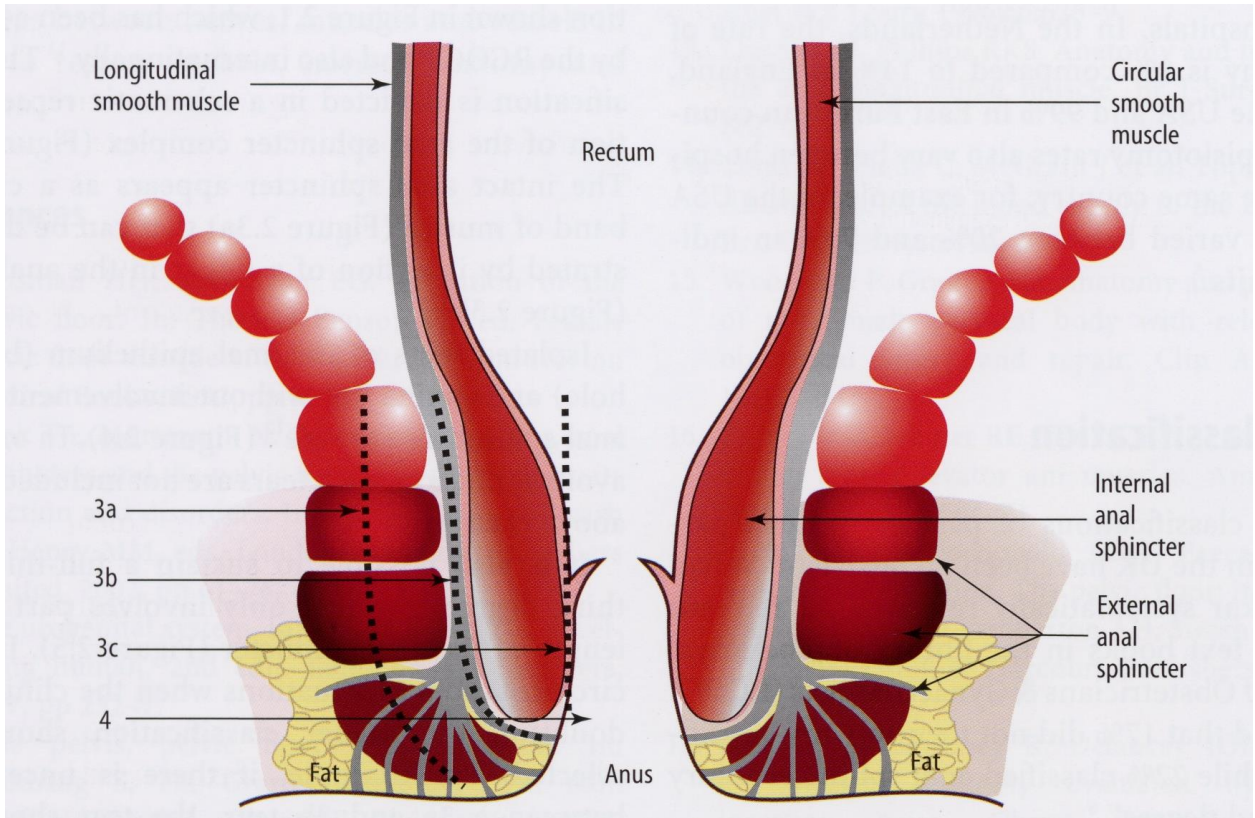
**3b:** >50% thickness of external sphincter torn.

**3c:** internal sphincter also torn.

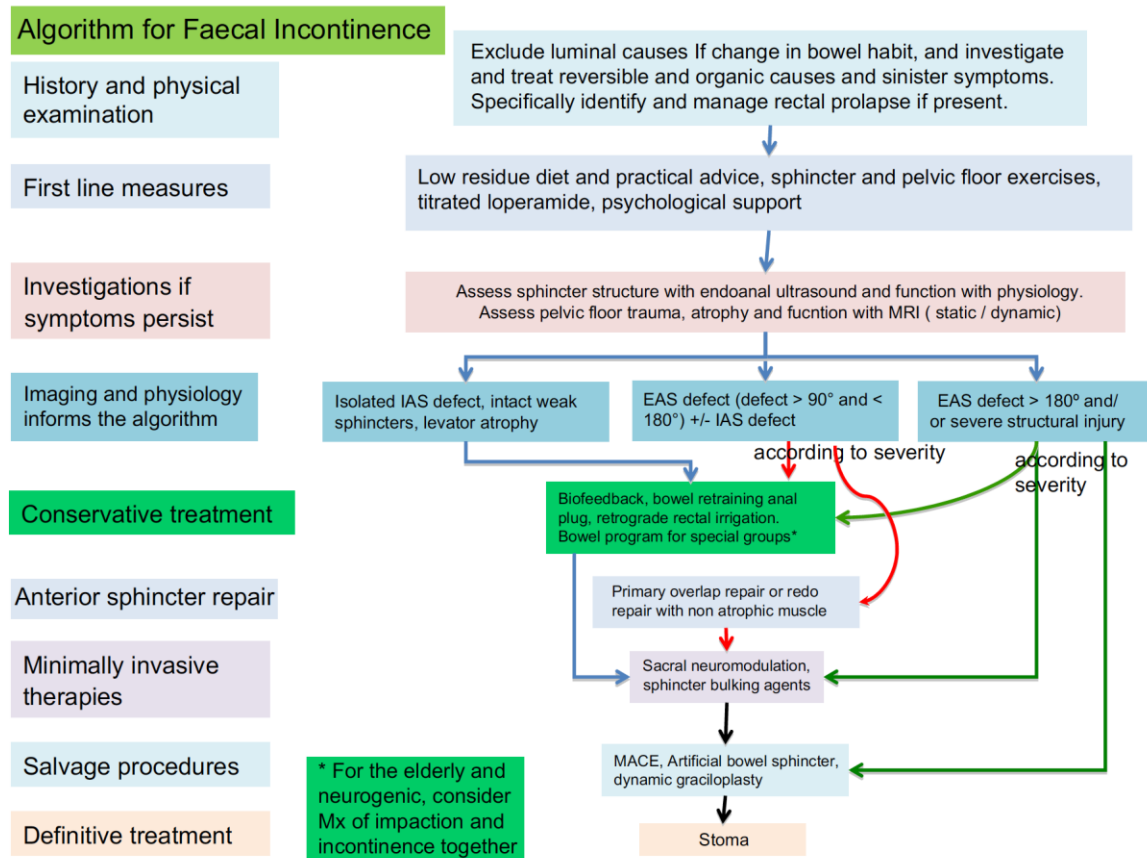
**Fourth degree:** a third degree tear with disruption of the anal epithelium as well.

**Button hole tear of rectum:** Isolated tear of rectum without involvement of the anal sphincter

**Fig 10** Classification of 3<sup>rd</sup> and 4<sup>th</sup> degree tears (with permission from Springer)

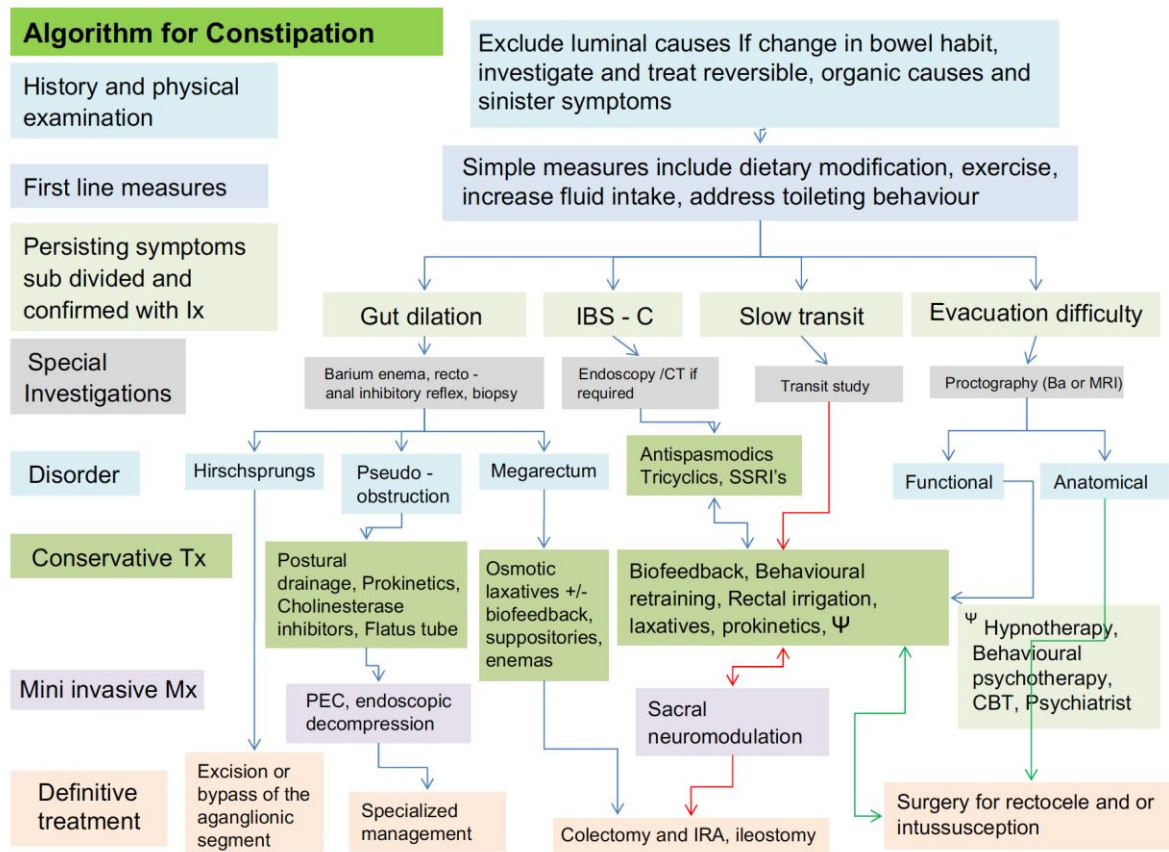


## Flow Chart for Fecal incontinence



**Fig. 11(adapted from<sup>125</sup>).** Algorithm: faecal incontinence. Abbreviations: IAS – internal anal sphincter, EAS – external anal sphincter, SNM – sacral neuromodulation, MACE – malone antegrade continence enema. Adapted from

## Flow Chart for constipation



**Fig. 12 (adapted from<sup>125</sup>).** Algorithm: constipation. Abbreviations: IBS-C – irritable bowel constipation predominant, IRA – ileorectal anastomosis, J – hypnotherapy, behavioural psychotherapy, CBT, psychiatrist management, CBT – cognitive behavioural therapy, Ix – investigations, Mx – management, Tx – treatment.

### Footnotes

**FN1:** in regards to definition of various types of urinary incontinence, the interested reader can refer to (Haylen 2010)<sup>7</sup>

**FN2:** a history of receptive anal intercourse has been shown to increase the risk of anal incontinence<sup>12</sup>

**FN3:** Soiling is a bothersome disorder characterized by continuous or intermittent liquid anal discharge. It should be differentiated from discharge due to fistulae, proctitis, hemorrhoids and prolapse. Patients complain about staining of underwear and often wear protection.

- The discharge may cause inflammation of the perineal skin with excoriation, perianal discomfort, burning sensation, and itching.

- It often indicates the presence of an impaired internal sphincter function or a solid fecal mass in the rectum but could also be due to the inability to maintain hygiene due to hemorrhoids

**FN4:** *Rome III criteria for functional constipation:*

1. Must include *two or more* of the following:

- a. Straining during at least 25% of defecations
- b. Lumpy or hard stools in at least 25% of defecations
- c. Sensation of incomplete evacuation for at least 25% of defecations
- d. Sensation of anorectal obstruction/ blockage for at least 25% of defecations
- e. Manual maneuvers to facilitate at least 25% of defecations (e.g., digital-evacuation, support of the pelvic floor)
- f. Fewer than three defecations per week

2. Loose stools are rarely present without the use of laxatives

3. Insufficient criteria for irritable bowel syndrome

\* Criteria fulfilled for the last 3 months with symptom onset at least 6 months prior to diagnosis

**FN5:** Difficulty evacuating stool, requiring straining efforts at defecation often associated with lumpy or hard stools, sensation of incomplete evacuation, feeling of anorectal blockage/obstruction or manual assistance to defecate (or inability to relax EAS / dyssynergic defecation)

**FN6:** Anorectal prolapse can be due to hemorrhoidal, mucosal, rectal prolapse or rectal intussusception. These definitions are further explained under "Signs"

**FN7:** this refers to pain localized to the anorectal region, and may include pain, pressure, or discomfort in the region of the rectum, sacrum, and coccyx that may be associated with pain in the gluteal region and thighs

**FN8:** Fissure pain during, and particularly after, defecation is commonly described as passing razor blades or glass shards. See FN10

**FN9:** Receptive anal intercourse is associated with increased risk of both any female sexual dysfunction<sup>14</sup>, as well as with specifically female sexual arousal disorder with distress<sup>15</sup> ("a persistent or recurrent inability to attain [or to maintain until completion of the sexual activity] an adequate wetness and vaginal swelling response of sexual excitement"). The association of receptive anal intercourse with sexual dysfunction might be due to physiological and/or psychological processes. The psychological factors including emotional development problems<sup>16</sup>, poorer mood<sup>17</sup>, poorer intimate attachment<sup>18</sup> as well as general dissatisfaction are associated with women's receptive anal intercourse<sup>19</sup>. Physiologic factors could include that: 1) mechanical stimulation of the anus and rectum during anal intercourse increases hemorrhoid risk, 2) women with hemorrhoidectomy have impaired sexual function, and 3) persons with hemorrhoids who have not yet had hemorrhoidectomy "are more likely to have abnormal perineal descent with pudendal neuropathy" <sup>20,21</sup>. Thus, pudendal nerve

dysfunction could be one mechanism leading to sexual dysfunction, and this might be the case even in the absence of diagnosed haemorrhoids<sup>13</sup>

**FN10:** a history of receptive anal intercourse has been shown to increase the risk of anal incontinence, rectal bleeding and anal fissure<sup>12</sup>

**FN11:** Unlike dyspareunia (from coitus), it might be normal to experience pain or discomfort during receptive anal intercourse

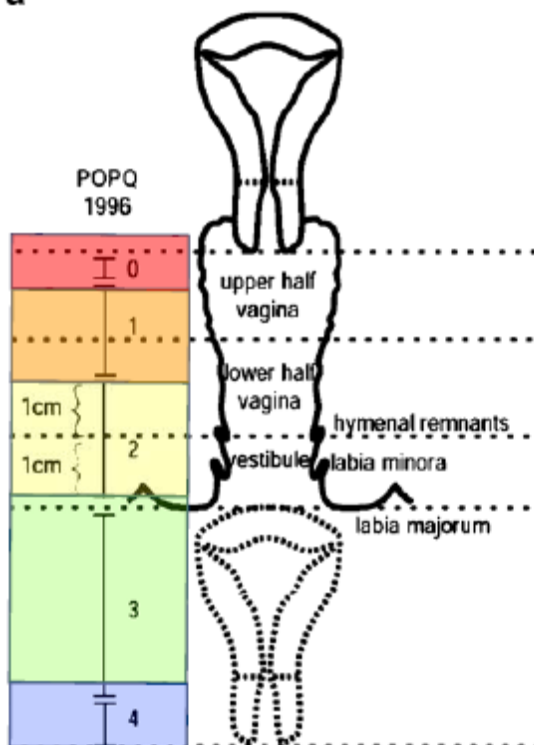
**FN12:** this may be accompanied by a finding of decreased anal resting tone (in some cases, the result of anal intercourse) – see under Signs. Damage to the internal anal sphincter is the likely basis for the laxity. Unlike stool passage, receptive anal intercourse is not likely to elicit reflex relaxation of the internal sphincter

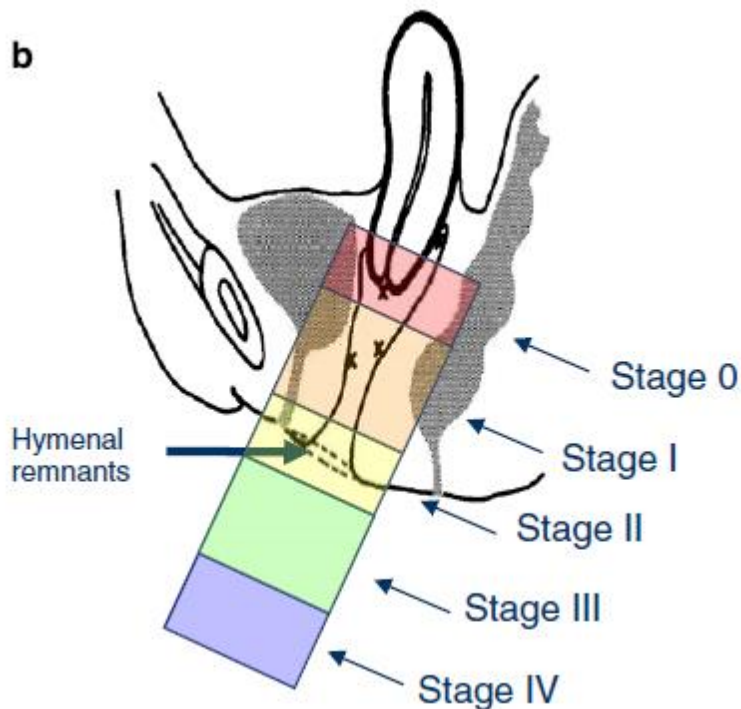
**FN13:** Pruritus ani has been classified into primary and secondary. The primary form is the classic syndrome of idiopathic pruritus ani. The secondary form implies an identifiable cause or a specific diagnosis

**FN 14:** With perianal hematomas, the lump may be anywhere around the anal margin and may be multiple. Pilonidal sinuses are usually a small mid-line pit with epithelialized edges

**FN15:** Figure to be used from Pelvic floor dysfunction document<sup>7</sup> (figure a, b)

**a**





**Fig. a and b** shows prolapse staging—0, I, II, III, and IV (uterine by the position of the leading edge of the cervix)

**FN16:** a transverse defect rectocele occurs simply by a detachment of the perineal body from the rectovaginal fascia. The hammock of rectovaginal fascia supporting the rectum remains intact but separates from the perineal body. A midline vertical defect is created by a midline separation of the rectovaginal fascia, and a separation of the rectovaginal fascia can occur from its lateral attachments. Rectoceles are more commonly situated in the mid to distal aspect of the posterior vaginal wall

**FN17:** Symptoms of levator ani syndrome are painful rectal spasm, typically unrelated to defecation, usually lasting >20 min. The pain may be brief and intense or a vague ache high in the rectum. It may occur spontaneously or with sitting and can waken the patient from sleep and occurs more often on the left. The pain may feel as if it would be relieved by the passage of gas or a bowel movement. In severe cases, the pain can persist for many hours and recur frequently. During clinical evaluation: a dull ache to the left 5 cm above the anus or higher in the rectum and a feeling of constant rectal pressure or burning. Physical examination can exclude other painful rectal conditions (eg, thrombosed hemorrhoids, fissures, abscesses, scarring from previous surgery). Physical examination is often normal, although tenderness or tightness of the levator muscle, usually on the left, may be present. Occasionally the cause can be low back disorders. Coccydynia (coccygodynia) is complaint of pain and point tenderness of the coccyx (this is NOT anorectal pain)

**FN18:** Proctalgia fugax most often occurs in the middle of the night and lasts for seconds to 20 minutes. During an episode, which sometimes occurs after orgasm, the patient feels spasm-like, sometimes



excruciating pain in the anus, often misinterpreted as a need to defecate. Because of the high incidence of internal anal sphincter thickening with the disorder, it is thought to be a disorder of the internal sphincter or that it is a neuralgia of pudendal nerves. It tends to occur infrequently (once a month or less). Like all ordinary muscle cramps, it is a severe, deep rooted pain. Defecation can worsen the spasm, but may relieve it<sup>113</sup>, or provide a measure of comfort. The pain might subside by itself as the spasm disappears on its own, or may persist or recur during the same night. Patients with proctalgia fugax are usually asymptomatic during the anorectal examination, leaving no signs or findings to support the condition, which is based on symptoms by history taking, diagnostic criteria, described above, and the exclusion of underlying organic disease (anorectal or endopelvic) with proctalgia<sup>114</sup>.

**FN19:** The condition is also known as pudendal neuropathy, pudendal nerve entrapment, cyclist's syndrome, pudendal canal syndrome, or Alcock's syndrome. The Nantes criteria<sup>13</sup> includes

1. pain in the anatomical region of pudendal nerve innervation
2. pain that is worse with sitting
3. no waking at night with pain
4. no sensory deficit on examination
5. relief of symptoms with a pudendal block
- 6.

Primary symptoms of PN include:

- a) Pelvic pain with sitting that may be less intense in the morning and increase throughout the day. Symptoms may decrease when standing or lying down. The pain can be perineal, rectal or in the clitoral / penile area; it can be unilateral or bilateral.
- b) Sexual dysfunction. In women, dysfunction manifests as pain or decreased sensation in the genitals, perineum or rectum. Pain may occur with or without touch. It may be difficult or impossible for the woman to achieve orgasm.
- c) Difficulty with urination / defecation. Patients may experience urinary hesitancy, urgency and/or frequency. Post-void discomfort is not uncommon. Patients may feel that they have to 'strain' to have a bowel movement and the movement may be painful and/or result in pelvic pain after. Constipation is also common among patients with PN. In severe cases, complete or partial urinary and/or fecal incontinence may result.
- d) Sensation of a foreign object being within the body. Some patients will feel as though there is a foreign object sitting inside the vagina or the rectum.

It is important to note PN is largely a "rule out" condition. In other words, because its symptoms can be indicative of another problem, extensive testing by physical examination, assessment by touch, pinprick, bimanual pelvic palpation with attention to the pelvic floor muscles, in particular the levator and obturator muscles, tenderness of the bladder and sacrospinous ligaments are required to ensure that symptoms are not related to another condition. Maximum tenderness, or a trigger point can be produced

by applying pressure to the ischial spine. Palpation of this area can reproduce pain and symptoms as a positive Tinel's sign<sup>115</sup>.

As PN is a diagnosis of exclusion, other conditions that should be excluded include coccygodynia, piriformis syndrome, interstitial cystitis, vulvodynia, vestibulitis, chronic pelvic pain syndrome, proctalgia, anorectal neuralgia, pelvic contracture syndrome/pelvic congestion, proctalgia fugax or levator ani syndrome.

In addition to eliminating other diagnoses, it is important to determine if the PN is caused by a true entrapment or other compression / tension dysfunctions. In almost all cases, pelvic floor dysfunction accompanies PN. Electrodiagnostic studies will help the practitioner determine if the symptoms are caused by a true nerve entrapment or by muscular problems and neural irritation.

### **Acknowledgements**

We gratefully acknowledge contributions from Dr Helen Frawley, Beth Shelley following ICS (V29 Jan 2015) IUGA website presentation of Version 30 (Aug15, Dr Alexis Schizas and Kari Bo at ICS Montreal (V33 8Oct15).

### **References**

1. Snooks SJ, Setchell M, Swash M, Henry MM. Injury to innervation of pelvic floor sphincter musculature in childbirth. *Lancet*. 1984 Sep 8;2(8402):546-50. PubMed PMID: 6147604.
2. Sultan AH, Kamm MA, Hudson CN, Thomas JM, Bartram CI. Anal-sphincter disruption during vaginal delivery. *The New England Journal of Medicine*. 1993 Dec 23;329(26):1905-11. PubMed PMID: 8247054.
3. Andrews V, Sultan AH, Thakar R, Jones PW. Occult anal sphincter injuries--myth or reality? *BJOG : an international journal of obstetrics and gynaecology*. 2006 Feb;113(2):195-200. PubMed PMID: 16411998.
4. Dal Corso HM, D'Elia A, De Nardi P, Cavallari F, Favetta U, Pulvirenti D'Urso A, et al. Anal endosonography: a survey of equipment, technique and diagnostic criteria adopted in nine Italian centers. *Techniques in coloproctology*. 2007 Mar;11(1):26-33. PubMed PMID: 17357863.
5. Kapoor DS, Sultan AH, Thakar R, Abulafi MA, Swift RI, Ness W. Management of complex pelvic floor disorders in a multidisciplinary pelvic floor clinic. *Colorectal disease : the official journal of the Association of Coloproctology of Great Britain and Ireland*. 2008 Feb;10(2):118-23. PubMed PMID: 18199292.
6. Milsom I, Altman D, Lapitan MC, Nelson R, Sillen U, Thom D. Epidemiology of Urinary (UI) and Faecal (FI) Incontinence and Pelvic Organ Prolapse (POP). In: P Abrams L Cardozo S Khoury A Wein, Editors. 4th International Consultation on Incontinence. Paris: Health Publication Ltd 2009. Chapter 1, page 35-111.

7. Haylen BT, de Ridder D, Freeman RM, Swift SE, Berghmans B, Lee J, et al. An International Urogynecological Association (IUGA)/International Continence Society (ICS) joint report on the terminology for female pelvic floor dysfunction. *International urogynecology journal*. 2010 Jan;21(1):5-26. PubMed PMID: 19937315.
8. Rosier PF, de Ridder D, Meijlink J, Webb R, Whitmore K, Drake MJ. Developing evidence-based standards for diagnosis and management of lower urinary tract or pelvic floor dysfunction. *Neurourol Urodyn*. 2012 Jun;31(5):621-4. doi: 10.1002/nau.21253. PubMed PMID: 22396134.
9. Stedman's Medical Dictionary 28<sup>th</sup> Edition Baltimore, Maryland USA: (2006) Lippincott, Williams and Wilkins 2006. p1884
10. Abrams P, Blaivas JG, Stanton SL, Andersen JT. The standardisation of terminology of lower urinary tract function. The International Continence Society Committee on Standardisation of Terminology. *Scandinavian journal of urology and nephrology Supplementum*. 1988;114:5-19. PubMed PMID: 3201169.
11. Abrams P, Cardozo L, Fall M, Griffiths D, Rosier P, Ulmsten U, et al. The standardisation of terminology of lower urinary tract function: report from the Standardisation Sub-committee of the International Continence Society. *Neurourology and urodynamics*. 2002;21(2):167-78. PubMed PMID: 11857671.
12. Miles AJ, Allen-Mersh TG, Wastell C. Effect of anoreceptive intercourse on anorectal function. *Journal of the Royal Society of Medicine*. 1993 Mar;86(3):144-7. PubMed PMID: 8459377. Pubmed Central PMCID: 1293903.
13. Labat JJ, Riant T, Robert R, Amarenco G, Lefaucheur JP, Rigaud J. Diagnostic criteria for pudendal neuralgia by pudendal nerve entrapment (Nantes criteria). *Neurourology and urodynamics*. 2008;27(4):306-10. PubMed PMID: 17828787.
14. Brody S, Weiss P. Heterosexual anal intercourse: increasing prevalence, and association with sexual dysfunction, bisexual behavior, and venereal disease history. *Journal of sex & marital therapy*. 2011;37(4):298-306. PubMed PMID: 21707331.
15. Weiss P, Brody S. Female sexual arousal disorder with and without a distress criterion: prevalence and correlates in a representative Czech sample. *The journal of sexual medicine*. 2009 Dec;6(12):3385-94. PubMed PMID: 19758283.
16. Costa RM, Brody S. Immature defense mechanisms are associated with lesser vaginal orgasm consistency and greater alcohol consumption before sex. *The journal of sexual medicine*. 2010 Feb;7(2 Pt 1):775-86. PubMed PMID: 19889144.
17. Hensel DJ, Fortenberry JD, Orr DP. Factors associated with event level anal sex and condom use during anal sex among adolescent women. *The Journal of adolescent health : official publication of the Society for Adolescent Medicine*. 2010 Mar;46(3):232-7. PubMed PMID: 20159499. Pubmed Central PMCID: 2824616.
18. Costa RM, Brody S. Anxious and avoidant attachment, vibrator use, anal sex, and impaired vaginal orgasm. *The journal of sexual medicine*. 2011 Sep;8(9):2493-500. PubMed PMID: 21676179.

19. Brody S, Costa RM. Satisfaction (sexual, life, relationship, and mental health) is associated directly with penile-vaginal intercourse, but inversely with other sexual behavior frequencies. *The journal of sexual medicine*. 2009 Jul;6(7):1947-54. PubMed PMID: 19453891.
20. Bruck CE, Lubowski DZ, King DW. Do patients with haemorrhoids have pelvic floor denervation? *International journal of colorectal disease*. 1988 Nov;3(4):210-4. PubMed PMID: 3198991.
21. Lin YH, Stocker J, Liu KW, Chen HP. The impact of hemorrhoidectomy on sexual function in women: a preliminary study. *International journal of impotence research*. 2009 Nov-Dec;21(6):343-7. PubMed PMID: 19693018.
22. Toozs-Hobson P, Freeman R, Barber M, Maher C, Haylen B, Athanasiou S, et al. An International Urogynecological Association (IUGA)/International Continence Society (ICS) joint report on the terminology for reporting outcomes of surgical procedures for pelvic organ prolapse. *International urogynecology journal*. 2012 May;23(5):527-35. PubMed PMID: 22476543.
23. Messelink B, Benson T, Berghmans B, Bo K, Corcos J, Fowler C et al. Standardization of terminology of pelvic floor muscle function and dysfunction: report from the Pelvic Floor Clinical Assessment Group of the International Continence Society. *Neurourol Urodyn* 2005; 24(4):374–380. PubMed PMID: 195977259.
24. Laycock J. Clinical evaluation of pelvic floor. In: Schussler B, Laycock J, Norton P, Stanton S, editors. *Pelvic floor re-education*. London: Springer-Verlag; 1994. p. 42–8.
25. Bo K, Finckenhagen HB. Vaginal palpation of pelvic floor muscle strength: inter-test reproducibility and comparison between palpation and vaginal squeeze pressure. *Acta obstetrica et gynecologica Scandinavica*. 2001 Oct;80(10):883-7. PubMed PMID: 11580731.
26. Morin M, Dumoulin C, Bourbonnais D, Gravel D, Lemieux MC. Pelvic floor maximal strength using vaginal digital assessment compared to dynamometric measurements. *Neurourology and urodynamics*. 2004;23(4):336-41. PubMed PMID: 15227651.
27. Isherwood PJ, Rane A. Comparative assessment of pelvic floor strength using a perineometer and digital examination. *BJOG : an international journal of obstetrics and gynaecology*. 2000 Aug;107(8):1007-11. PubMed PMID: 10955433.
28. Jeyaseelan S, Haslam J, Winstanley J, Roe BH, Oldham JA. Digital vaginal assessment: an inter-tester reliability study. *Physiotherapy*. 2001;87:243–250.
29. Mumenthaler M, Appenzeller O. *Neurologic Differential Diagnosis*, 2nd ed, Thieme, New York. 1992, pg 122
30. Montenegro ML, Mateus-Vasconcelos EC, Rosa e Silva JC, Nogueira AA, Dos Reis FJ, Poli Neto OB. Importance of pelvic muscle tenderness evaluation in women with chronic pelvic pain. *Pain medicine*. 2010 Feb;11(2):224-8. PubMed PMID: 20002593.
31. Kotarinos RK. CP/CPPS Pelvic Floor Dysfunction, Evaluation and treatment. In: Jeannette M. Potts (Ed). *Genitourinary Pain and Inflammation: Diagnosis and Management*, Humana Press 2008: Chapter 20, page 303-314
32. Heaton KW, Radvan J, Cripps H, Mountford RA, Braddon FE, Hughes AO. Defecation frequency and timing, and stool form in the general population: a prospective study. *Gut*. 1992 Jun;33(6):818-24. PubMed PMID: 1624166. Pubmed Central PMCID: 1379343.

33. Lewis SJ, Heaton KW. Stool form scale as a useful guide to intestinal transit time. *Scandinavian journal of gastroenterology*. 1997 Sep;32(9):920-4. PubMed PMID: 9299672.
34. Manning AP, Wyman JB, Heaton KW. How trustworthy are bowel histories? Comparison of recalled and recorded information. *Br Med J*. 1976 Jul 24;2(6029):213-4. PubMed PMID: 974496. Pubmed Central PMCID: 1687305.
35. Bharucha AE, Seide BM, Zinsmeister AR, Melton LJ, 3rd. Insights into normal and disordered bowel habits from bowel diaries. *The American journal of gastroenterology*. 2008 Mar;103(3):692-8. PubMed PMID: 18021288. Pubmed Central PMCID: 2557101.
36. Ashraf W, Park F, Lof J, Quigley EM. An examination of the reliability of reported stool frequency in the diagnosis of idiopathic constipation. *The American journal of gastroenterology*. 1996 Jan;91(1):26-32. PubMed PMID: 8561138.
37. Kelleher C, Staskin D, Cherian P, Cotterill N, Coyne K, Kopp Z, Symonds T. Patient-Reported Outcome Assessment. In: P Abrams L Cardozo S Khoury A Wein, Editors. 5th International Consultation on Incontinence. Paris: ICUD-EAU2013.Chapter 5B, page 389-427.
38. Jorge JM, Wexner SD. Etiology and management of fecal incontinence. *Diseases of the colon and rectum*. 1993 Jan;36(1):77-97. PubMed PMID: 8416784.
39. Vaizey CJ, Carapeti E, Cahill JA, Kamm MA. Prospective comparison of faecal incontinence grading systems. *Gut*. 1999 Jan;44(1):77-80. PubMed PMID: 9862829. Pubmed Central PMCID: 1760067.
40. Maeda Y, Pares D, Norton C, Vaizey CJ, Kamm MA. Does the St. Mark's incontinence score reflect patients' perceptions? A review of 390 patients. *Diseases of the colon and rectum*. 2008 Apr;51(4):436-42. PubMed PMID: 18219532.
41. Rockwood TH, Church JM, Fleshman JW, Kane RL, Mavrantonis C, Thorson AG, et al. Fecal Incontinence Quality of Life Scale: quality of life instrument for patients with fecal incontinence. *Diseases of the colon and rectum*. 2000 Jan;43(1):9-16; discussion -7. PubMed PMID: 10813117.
42. Rockwood TH, Church JM, Fleshman JW, Kane RL, Mavrantonis C, Thorson AG, et al. Patient and surgeon ranking of the severity of symptoms associated with fecal incontinence: the fecal incontinence severity index. *Diseases of the colon and rectum*. 1999 Dec;42(12):1525-32. PubMed PMID: 10613469.
43. Cotterill N, Norton C, Avery KN, Abrams P, Donovan JL. Psychometric evaluation of a new patient-completed questionnaire for evaluating anal incontinence symptoms and impact on quality of life: the ICIQ-B. *Diseases of the colon and rectum*. 2011 Oct;54(10):1235-50. PubMed PMID: 21904138.
44. Cotterill N, Norton C, Avery KN, Abrams P, Donovan JL. A patient-centered approach to developing a comprehensive symptom and quality of life assessment of anal incontinence. *Diseases of the colon and rectum*. 2008 Jan;51(1):82-7. PubMed PMID: 18008106.
45. Marquis P, De La Loge C, Dubois D, McDermott A, Chassany O. Development and validation of the Patient Assessment of Constipation Quality of Life questionnaire. *Scandinavian journal of gastroenterology*. 2005 May;40(5):540-51. PubMed PMID: 16036506.

46. Frank L, Kleinman L, Farup C, Taylor L, Miner P, Jr. Psychometric validation of a constipation symptom assessment questionnaire. *Scandinavian journal of gastroenterology*. 1999 Sep;34(9):870-7. PubMed PMID: 10522604.
47. Frank L, Flynn J, Rothman M. Use of a self-report constipation questionnaire with older adults in long-term care. *The Gerontologist*. 2001 Dec;41(6):778-86. PubMed PMID: 11723346.
48. Slappendel R, Simpson K, Dubois D, Keininger DL. Validation of the PAC-SYM questionnaire for opioid-induced constipation in patients with chronic low back pain. *European journal of pain*. 2006 Apr;10(3):209-17. PubMed PMID: 15914049.
49. Agachan F, Chen T, Pfeifer J, Reissman P, Wexner SD. A constipation scoring system to simplify evaluation and management of constipated patients. *Diseases of the colon and rectum*. 1996 Jun;39(6):681-5. PubMed PMID: 8646957.
50. Altomare DF, Spazzafumo L, Rinaldi M, Dodi G, Ghiselli R, Piloni V. Set-up and statistical validation of a new scoring system for obstructed defaecation syndrome. *Colorectal disease : the official journal of the Association of Coloproctology of Great Britain and Ireland*. 2008 Jan;10(1):84-8. PubMed PMID: 17441968.
51. Diamant NE, Kamm MA, Wald A, Whitehead WE. AGA technical review on anorectal testing techniques. *Gastroenterology*. 1999 Mar;116(3):735-60. PubMed PMID: 10029632.
52. Rao SS, Azpiroz F, Diamant N, Enck P, Tougas G, Wald A. Minimum standards of anorectal manometry. *Neurogastroenterology and motility : the official journal of the European Gastrointestinal Motility Society*. 2002 Oct;14(5):553-9. PubMed PMID: 12358684.
53. Gundling F, Seidl H, Scalercio N, Schmidt T, Schepp W, Pehl C. Influence of gender and age on anorectal function: normal values from anorectal manometry in a large caucasian population. *Digestion*. 2010;81(4):207-13. PubMed PMID: 20110704.
54. Rao SS, Hatfield R, Soffer E, Rao S, Beaty J, Conklin JL. Manometric tests of anorectal function in healthy adults. *The American journal of gastroenterology*. 1999 Mar;94(3):773-83. PubMed PMID: 10086665.
55. Read NW, Harford WV, Schmulen AC, Read MG, Santa Ana C, Fordtran JS. A clinical study of patients with fecal incontinence and diarrhea. *Gastroenterology*. 1979 Apr;76(4):747-56. PubMed PMID: 422003.
56. Caruana BJ, Wald A, Hinds JP, Eidelman BH. Anorectal sensory and motor function in neurogenic fecal incontinence. Comparison between multiple sclerosis and diabetes mellitus. *Gastroenterology*. 1991 Feb;100(2):465-70. PubMed PMID: 1985043.
57. Orkin BA, Hanson RB, Kelly KA, Phillips SF, Dent J. Human anal motility while fasting, after feeding, and during sleep. *Gastroenterology*. 1991 Apr;100(4):1016-23. PubMed PMID: 2001798.
58. McHugh SM, Diamant NE. Effect of age, gender, and parity on anal canal pressures. Contribution of impaired anal sphincter function to fecal incontinence. *Digestive diseases and sciences*. 1987 Jul;32(7):726-36. PubMed PMID: 3595385.
59. Rao SS, Singh S. Clinical utility of colonic and anorectal manometry in chronic constipation. *Journal of clinical gastroenterology*. 2010 Oct;44(9):597-609. PubMed PMID: 20679903.

60. Schizas AM, Emmanuel AV, Williams AB. Vector volume manometry--methods and normal values. *Neurogastroenterology and motility : the official journal of the European Gastrointestinal Motility Society*. 2011 Sep;23(9):886-e393. PubMed PMID: 21722268.
61. Schizas AM, Emmanuel AV, Williams AB. Anal canal vector volume manometry. *Diseases of the colon and rectum*. 2011 Jun;54(6):759-68. PubMed PMID: 21552063.
62. Jones MP, Post J, Crowell MD. High-resolution manometry in the evaluation of anorectal disorders: a simultaneous comparison with water-perfused manometry. *The American journal of gastroenterology*. 2007 Apr;102(4):850-5. PubMed PMID: 17397410.
63. Kumar D, Waldron D, Williams NS, Browning C, Hutton MR, Wingate DL. Prolonged anorectal manometry and external anal sphincter electromyography in ambulant human subjects. *Digestive diseases and sciences*. 1990 May;35(5):641-8. PubMed PMID: 2331956.
64. Ferrara A, Pemberton JH, Grotz RL, Hanson RB. Prolonged ambulatory recording of anorectal motility in patients with slow-transit constipation. *American journal of surgery*. 1994 Jan;167(1):73-9. PubMed PMID: 8311143.
65. Ferrara A, Pemberton JH, Levin KE, Hanson RB. Relationship between anal canal tone and rectal motor activity. *Diseases of the colon and rectum*. 1993 Apr;36(4):337-42. PubMed PMID: 8458258.
66. Chiarioni G, Scattolini C, Bonfante F, Vantini I. Liquid stool incontinence with severe urgency: anorectal function and effective biofeedback treatment. *Gut*. 1993 Nov;34(11):1576-80. PubMed PMID: 8244147. Pubmed Central PMCID: 1374425.
67. Wald A, Tunuguntla AK. Anorectal sensorimotor dysfunction in fecal incontinence and diabetes mellitus. Modification with biofeedback therapy. *The New England journal of medicine*. 1984 May 17;310(20):1282-7. PubMed PMID: 6717494.
68. Merkel IS, Locher J, Burgio K, Towers A, Wald A. Physiologic and psychologic characteristics of an elderly population with chronic constipation. *The American journal of gastroenterology*. 1993 Nov;88(11):1854-9. PubMed PMID: 8237932.
69. Kamm MA, Lennard-Jones JE. Rectal mucosal electrosensory testing--evidence for a rectal sensory neuropathy in idiopathic constipation. *Diseases of the colon and rectum*. 1990 May;33(5):419-23. PubMed PMID: 2328631.
70. Andersen IS, Michelsen HB, Krogh K, Buntzen S, Laurberg S. Impedance planimetric description of normal rectoanal motility in humans. *Diseases of the colon and rectum*. 2007 Nov;50(11):1840-8. PubMed PMID: 17762962.
71. Wiesner A, Jost WH. EMG of the external anal sphincter: needle is superior to surface electrode. *Diseases of the colon and rectum* 2000;43(1): 116-117
72. Kiff ES, Swash M. Slowed conduction in the pudendal nerves in idiopathic (neurogenic) faecal incontinence. *The British journal of surgery*. 1984 Aug;71(8):614-6. PubMed PMID: 6743983.
73. Bliss DZ, Mellgren A, Whitehead WE, Chiarioni G, Emmanuel A, Santoro GA, Zbar A, Peden-McAlpine C, Northwood M, Slieker-ten Hove M, Berghmans B, Mimura. Assessment and Conservative Management of Faecal Incontinence and Quality of Life in Adults. In: P Abrams L Cardozo S Khoury A

Wein, Editors. 5th International Consultation on Incontinence. Paris: ICUD-EAU 2013. Chapter 16, page 1443-1486.

74. Stoker J, Bartram CI, Halligan S. Imaging of the posterior pelvic floor. *European radiology*. 2002 Apr;12(4):779-88. PubMed PMID: 11960226.

75. Tubaro A, Vodusek DB, Amarenco G, Doumouchtsis SK, DeLancey JOL, Fernando R, Khullar V, Puccini F, Podnar S. Imaging, neurophysiological testing and other tests. In: P Abrams L Cardozo S Khoury A Wein, Editors. 5th International Consultation on Incontinence. Chapter 7, page 507-622. Paris: ICUD-EAU.2013

76. Santoro GA, Wieczorek AP, Dietz HP, Mellgren A, Sultan AH, Shobeiri SA, Stankiewicz A, Bartram C. State of the art: an integrated approach to pelvic floor ultrasonography. *Ultrasound Obstet Gynecol*. 2011; 37(4):381-96.

77. Frudinger A, Halligan S, Bartram CI, Price AB, Kamm MA, Winter R. Female anal sphincter: age-related differences in asymptomatic volunteers with high-frequency endoanal US. *Radiology*. 2002 Aug;224(2):417-23. PubMed PMID: 12147837.

78. Sultan AH, Kamm MA, Talbot IC, Nicholls RJ, Bartram CI. Anal endosonography for identifying external sphincter defects confirmed histologically. *The British journal of surgery*. 1994 Mar;81(3):463-5. PubMed PMID: 8173933.

79. Williams AB, Bartram CI, Halligan S, Spencer JA, Nicholls RJ, Kmiot WA. Anal sphincter damage after vaginal delivery using three-dimensional endosonography. *Obstetrics and gynecology*. 2001 May;97(5 Pt 1):770-5. PubMed PMID: 11339932.

80. Williams AB, Cheetham MJ, Bartram CI, Halligan S, Kamm MA, Nicholls RJ, et al. Gender differences in the longitudinal pressure profile of the anal canal related to anatomical structure as demonstrated on three-dimensional anal endosonography. *The British journal of surgery*. 2000 Dec;87(12):1674-9. PubMed PMID: 11122183.

81. Santoro GA, Fortling B. The advantages of volume rendering in three-dimensional endosonography of the anorectum. *Diseases of the colon and rectum*. 2007 Mar;50(3):359-68. PubMed PMID: 17237912.

82. Dietz HP. Ultrasound imaging of the pelvic floor. Part I: two-dimensional aspects. *Ultrasound in obstetrics & gynecology : the official journal of the International Society of Ultrasound in Obstetrics and Gynecology*. 2004 Jan;23(1):80-92. PubMed PMID: 14971006.

83. Braekken IH, Majida M, Ellstrom-Eng M, Dietz HP, Umek W, Bo K. Test-retest and intra-observer repeatability of two-, three- and four-dimensional perineal ultrasound of pelvic floor muscle anatomy and function. *International urogynecology journal and pelvic floor dysfunction*. 2008 Feb;19(2):227-35. PubMed PMID: 17599234.

84. Dietz HP. Ultrasound imaging of the pelvic floor. Part II: three-dimensional or volume imaging. *Ultrasound in obstetrics & gynecology : the official journal of the International Society of Ultrasound in Obstetrics and Gynecology*. 2004 Jun;23(6):615-25. PubMed PMID: 15170808.

85. Santoro GA, Wieczorek AP, Stankiewicz A, Wozniak MM, Bogusiewicz M, Rechberger T. High-resolution threedimensional endovaginal ultrasonography in the assessment of pelvic floor anatomy: a preliminary study. *Int Urogynecol J* 2009; 20: 1213–1222



86. Santoro GA, Wieczorek AP, Shobeiri SA, Mueller ER, Pilat J, Stankiewicz A, Battistella G. Interobserver and interdisciplinary reproducibility of 3D endovaginal ultrasound assessment of pelvic floor anatomy. *Int Urogynecol J Pelvic Floor Dysfunct* 22:53–59
87. Wagenlehner FME, Del Amo E, Santoro GA, Petros PE. Live anatomy of the perineal body in patients with 3rd degree rectocele. *Colorectal Dis* 2013 (in press).
88. Dobben AC, Terra MP, Deutekom M, Gerhards MF, Bijnen AB, Felt-Bersma RJ, Janssen LW, Bossuyt PM, Stoker J. Anal inspection and digital rectal examination compared to anorectal physiology tests and endoanal ultrasonography in evaluating fecal incontinence. *Int J Colorectal Dis* 2007;22:783-90
89. Tubaro A, Vodusek DB, Amarenco G, Doumouchtsis SK, DeLancey JOL, Fernando R, Khullar V. Imaging, Neurophysiological testing and other tests. In: P Abrams L Cardozo S Khoury A Wein, Editors. 5th International Consultation on Incontinence. Paris: ICUD-EAU 2013. Chapter 7, page 507-622.
90. Sultan AH, Kamm MA, Nicholls RJ, Bartram CI. Prospective study of the extent of internal anal sphincter division during lateral sphincterotomy. *Diseases of the colon and rectum*. 1994 Oct;37(10):1031-3. PubMed PMID: 7924711.
91. Richter HE, Fielding JR, Bradley CS, Handa VL, Fine P, FitzGerald MP, et al. Endoanal ultrasound findings and fecal incontinence symptoms in women with and without recognized anal sphincter tears. *Obstetrics and gynecology*. 2006 Dec;108(6):1394-401. PubMed PMID: 17138772.
92. Starck M, Bohe M, Fortling B, Valentin L. Endosonography of the anal sphincter in women of different ages and parity. *Ultrasound in obstetrics & gynecology : the official journal of the International Society of Ultrasound in Obstetrics and Gynecology*. 2005 Feb;25(2):169-76. PubMed PMID: 15685668.
93. Norderval S, Markskog A, Rossaak K, Vonen B. Correlation between anal sphincter defects and anal incontinence following obstetric sphincter tears: assessment using scoring systems for sonographic classification of defects. *Ultrasound in obstetrics & gynecology : the official journal of the International Society of Ultrasound in Obstetrics and Gynecology*. 2008 Jan;31(1):78-84. PubMed PMID: 18059077.
94. Dietz HP, Moegni F, Shek KL. Diagnosis of levator avulsion injury: a comparison of three methods. *Ultrasound in obstetrics & gynecology : the official journal of the International Society of Ultrasound in Obstetrics and Gynecology*. 2012 Dec;40(6):693-8. PubMed PMID: 22605560.
95. Dietz HP, Steensma AB. Posterior compartment prolapse on two-dimensional and three-dimensional pelvic floor ultrasound: the distinction between true rectocele, perineal hypermobility and enterocele. *Ultrasound in obstetrics & gynecology : the official journal of the International Society of Ultrasound in Obstetrics and Gynecology*. 2005 Jul;26(1):73-7. PubMed PMID: 15973648.
96. Stoker J. Anorectal and pelvic floor anatomy. *Best practice & research Clinical gastroenterology*. 2009;23(4):463-75. PubMed PMID: 19647683.
97. Tan E, Anstee A, Koh DM, Gedroyc W, Tekkis PP. Diagnostic precision of endoanal MRI in the detection of anal sphincter pathology: a meta-analysis. *International journal of colorectal disease*. 2008 Jun;23(6):641-51. PubMed PMID: 18330582.

98. Morteale KJ, Fairhurst J. Dynamic MR defecography of the posterior compartment: Indications, techniques and MRI features. *European journal of radiology*. 2007 Mar;61(3):462-72. PubMed PMID: 17145152.
99. Lakeman MM, Zijta FM, Peringa J, Nederveen AJ, Stoker J, Roovers JP. Dynamic magnetic resonance imaging to quantify pelvic organ prolapse: reliability of assessment and correlation with clinical findings and pelvic floor symptoms. *International urogynecology journal*. 2012 Nov;23(11):1547-54. PubMed PMID: 22531955. Pubmed Central PMCID: 3484313.
100. Bolog N, Weishaupt D. Dynamic MR imaging of outlet obstruction. *Romanian journal of gastroenterology*. 2005 Sep;14(3):293-302. PubMed PMID: 16200243.
101. Dobben AC, Terra MP, Slors JF, Deutekom M, Gerhards MF, Beets-Tan RG, et al. External anal sphincter defects in patients with fecal incontinence: comparison of endoanal MR imaging and endoanal US. *Radiology*. 2007 Feb;242(2):463-71. PubMed PMID: 17255418.
102. Terra MP, Beets-Tan RG, van Der Hulst VP, Dijkgraaf MG, Bossuyt PM, Dobben AC, et al. Anal sphincter defects in patients with fecal incontinence: endoanal versus external phased-array MR imaging. *Radiology*. 2005 Sep;236(3):886-95. PubMed PMID: 16014438.
103. DeLancey JO, Sorensen HC, Lewicky-Gaupp C, Smith TM. Comparison of the puborectal muscle on MRI in women with POP and levator ani defects with those with normal support and no defect. *International urogynecology journal*. 2012 Jan;23(1):73-7. PubMed PMID: 21822711. Pubmed Central PMCID: 3508430.
104. Broekhuis SR, Fütterer JJ, Hendriks JC, Barentsz JO, Vierhout ME, Kluivers KB. Symptoms of pelvic floor dysfunction are poorly correlated with findings on clinical examination and dynamic MR imaging of the pelvic floor. *Int Urogynecol J Pelvic Floor Dysfunct* 2009;20:1169-74
105. Brennan D, Williams G, Kruskal J. Practical performance of defecography for the evaluation of constipation and incontinence. *Seminars in ultrasound, CT, and MR*. 2008 Dec;29(6):420-6. PubMed PMID: 19166039.
106. Maglinte DD, Hale DS, Sandrasegaran K. Comparison between dynamic cystocolpoproctography and dynamic pelvic floor MRI: pros and cons: Which is the "functional" examination for anorectal and pelvic floor dysfunction? *Abdominal imaging*. 2012 Mar 24. PubMed PMID: 22446896.
107. Groenendijk AG, Birnie E, de Blok S, Adriaanse AH, Ankum WM, Roovers JP, et al. Clinical-decision taking in primary pelvic organ prolapse; the effects of diagnostic tests on treatment selection in comparison with a consensus meeting. *International urogynecology journal and pelvic floor dysfunction*. 2009 Jun;20(6):711-9. PubMed PMID: 19434388.
108. Rollandi GA, Biscaldi E, DeCicco E. Double contrast barium enema: technique, indications, results and limitations of a conventional imaging methodology in the MDCT virtual endoscopy era. *European journal of radiology*. 2007 Mar;61(3):382-7. PubMed PMID: 17161931.
109. Ghoshal UC, Sengar V, Srivastava D. Colonic Transit Study Technique and Interpretation: Can These Be Uniform Globally in Different Populations With Non-uniform Colon Transit Time? *Journal of neurogastroenterology and motility*. 2012 Apr;18(2):227-8. PubMed PMID: 22523737. Pubmed Central PMCID: 3325313.

110. Chan CLH, Lunniss PJ, Wang D, Williams NS, Scott SM. Rectal sensorimotor dysfunction in patients with urge faecal incontinence: evidence from prolonged manometric studies. *Gut* 2005;54:1263-1272 PubMed PMID: 15914573.
111. Santoro GA, Eitan BZ, Pryde A, Bartolo DC. Open study of low-dose amitriptyline in the treatment of patients with idiopathic fecal incontinence. *Diseases of the colon and rectum*. 2000 Dec;43(12):1676-81; discussion 1681-2. PubMed PMID: 11156450.
112. Whitehead WE, Wald A, Diamant NE, Enck P, Pemberton JH, and Rao SS. Functional disorders of the anus and rectum. *Gut*. 1999;45 Suppl 2:II55–9)
113. Hibner M, Desai N, Robertson LJ, Nour M. Pudendal Neuralgia *Journal of Minimally Invasive Gynecology* 2010 Mar-Apr;17(2): 148-153. PubMed PMID: 20071246.
114. Potter MA, Bartolo DC. Proctalgia fugax. *Eur J Gastroenterol Hepatol* 2001 Nov;13(11): 1289-1290. PubMed PMID: 11692052.
115. Robert R, Prat-Pradal D, Labat JJ, Bensignor M, Raoul S, Rebai R, et al. Anatomic basis of chronic perineal pain: role of the pudendal nerve. *Surgical and radiologic anatomy* : SRA. 1998;20(2):93-8. PubMed PMID: 9658526.
116. Sultan AH, Thakar R, Fenner D. *Perineal and anal sphincter trauma*. London: Springer. 2007
117. Sultan AH, Kamm MA, Hudson CN. Obstetric perineal tears: an audit of training. *J Obstet Gynaecol* 1995;15:19-23.
118. Andrews V, Thakar R, Sultan AH. Structured hands-on training in repair of obstetric anal sphincter injuries (OASIS): an audit of clinical practice. *International urogynecology journal and pelvic floor dysfunction*. 2009 Feb;20(2):193-9. PubMed PMID: 19015800.
119. Sultan AH. Editorial: Obstetric perineal injury and anal incontinence. *Clinical Risk* 1999;5 (5):193-6
120. Norton C, Christiansen J, Butler U, Harari D, Nelson RL, Pemberton J, Price K, Rovnor E, Sultan A. Anal Incontinence. In Abrams P, Cardozo L, Khoury, Wein A (eds). *Incontinence* 2nd ed. Plymouth: Health Publication Ltd 2002:985-1044
121. Royal College of Obstetricians and Gynaecologists. *The Management of Third and Fourth Degree Perineal Tears*. London: RCOG Press: 2007. RCOG Guideline No. 29
122. Fernando R, Sultan A, Kettle C, Thakar , Radley S. Methods of repair for obstetric anal sphincter injury. *Cochrane Systematic Reviews* 2006 July 19;3:CD002866
123. Sultan AH, Monga AK, Kumar D, Stanton SL. Primary repair of obstetric anal sphincter rupture using the overlap technique. *British journal of obstetrics and gynaecology*. 1999 Apr;106(4):318-23. PubMed PMID: 10426237.
124. Mahony R, Behan M, Daly L, Kirwan C, O'Herlihy C, O'Connell PR. Internal anal sphincter defect influences continence outcome following obstetric anal sphincter injury. *American journal of obstetrics and gynecology*. 2007 Mar;196(3):217 e1-5. PubMed PMID: 17346526.
125. Chatoor D, Soligo M, Emmanuel A. Organising a clinical service for patients with pelvic floor disorders. *Best Practice & Research Clinical Gastroenterology* 2009; 23: 611–620 PubMed PMID: 19647693