



<https://theses.gla.ac.uk/>

Theses Digitisation:

<https://www.gla.ac.uk/myglasgow/research/enlighten/theses/digitisation/>

This is a digitised version of the original print thesis.

Copyright and moral rights for this work are retained by the author

A copy can be downloaded for personal non-commercial research or study, without prior permission or charge

This work cannot be reproduced or quoted extensively from without first obtaining permission in writing from the author

The content must not be changed in any way or sold commercially in any format or medium without the formal permission of the author

When referring to this work, full bibliographic details including the author, title, awarding institution and date of the thesis must be given

Enlighten: Theses

<https://theses.gla.ac.uk/>
research-enlighten@glasgow.ac.uk

EXPERIMENTAL PARASCARIS EQUORUM

INFECTION IN THE FOAL

--oOo--

A THESIS submitted for

THE DEGREE OF DOCTOR OF PHILOSOPHY

in

THE FACULTY OF VETERINARY MEDICINE

of

THE UNIVERSITY OF GLASGOW

by

HILARY MARY CLAYTON BVMS, MRCVS.

Department of Veterinary Pathology,
University of Glasgow,
Glasgow.

MAY 1978.

ProQuest Number: 10647687

All rights reserved

INFORMATION TO ALL USERS

The quality of this reproduction is dependent upon the quality of the copy submitted.

In the unlikely event that the author did not send a complete manuscript and there are missing pages, these will be noted. Also, if material had to be removed, a note will indicate the deletion.



ProQuest 10647687

Published by ProQuest LLC (2017). Copyright of the Dissertation is held by the Author.

All rights reserved.

This work is protected against unauthorized copying under Title 17, United States Code
Microform Edition © ProQuest LLC.

ProQuest LLC.
789 East Eisenhower Parkway
P.O. Box 1346
Ann Arbor, MI 48106 – 1346

ACKNOWLEDGEMENTS

I wish to record my appreciation for all the help and encouragement I have received during the course of this work.

I am particularly grateful to Professor G.M. Urquhart, under whose supervision this work was carried out, to Dr. J. Duncan for his constant help and support during the last three years and to other colleagues in the Wellcome Laboratories for Experimental Parasitology for their valuable advice and suggestions.

I am indebted to Dr. P. Brown and Ms. J. Nicholls, Department of Veterinary Pathology and to Mr. G. Baker and Dr. R. Lee, Department of Veterinary Surgery, with whom I collaborated in the histopathological, endoscopic and radiographic studies, and also to Ms. E. Abbott and Dr. D. Powell, Equine Research Station, Newmarket, for their expert assistance in the serological procedures.

My thanks go to the laboratory staff in the Wellcome Laboratories for Experimental Parasitology for their skilled technical assistance, to Mr. J. Murphy and Mr. R. Irvine for their help in the post-mortem room, to Mrs. J. Clayton who typed the manuscript, and to Mr. A. Finnie and his colleagues in the Photography Department, who prepared the illustrations for this thesis.

All of the work described in this thesis depended entirely on the financial support of the Horserace Betting Levy Board, to whom I am indebted.

C O N T E N T S

	<u>Page</u>
General Introduction	1
Review of the Literature	2
Materials and Methods	10
<u>Chapter 1</u> Preliminary Experimental Studies	22
<u>Chapter 2</u> The Life Cycle and Migration of <u>Parascaris equorum</u>	34
<u>Chapter 3</u> The Pathogenesis of <u>Parascaris equorum</u> infection	48
<u>Chapter 4</u> Experimental <u>Parascaris equorum</u> infection in 6 to 12 month-old foals	89
General Discussion and Conclusions	103
Appendices	105
References	116

CONTENTS - MATERIALS AND METHODS

	<u>Page</u>
A Experimental Animals	10
(1) Stabling facilities	10
(2) Production and maintenance of worm-free foals	10
(3) Naturally infected foals	10
B Parasitological Techniques	11
(1) Culture of infective <u>P. equorum</u> eggs	11
(2) Administration of infective doses	11
(3) Gross examination of faeces for the presence of parasites	11
(4) Faecal egg count	12
(5) Recovery of parasites from the liver	12
(6) Recovery of parasites from the lungs	12
(7) Recovery of parasites from the gastrointestinal tract	13
(8) Recovery of parasites from tracheal washings	13
(9) Preservation of parasites	13
(10) Measurement of parasites	13
C Clinical Examination	14
D Ancillary Aids to Clinical Examination	14
(1) Endoscopy	14
(2) Tracheal washings	15
(3) Radiography	15

CONTENTS - MATERIALS AND METHODS (contd.)

	<u>Page</u>
E Post-mortem Examination	16
(1) Euthanasia and routine post-mortem examination	16
(2) Special post-mortem techniques	16
(a) Liver	16
(b) Lungs	16
(c) Gastrointestinal tract	17
F Pathological Techniques	17
G Haematological and Biochemical Techniques	17
(1) Collection and storage of samples	17
(2) Packed cell volume	18
(3) Haemoglobin concentration	18
(4) Total red and white blood cell counts	18
(5) Differential white blood cell counts	19
(6) Total serum protein concentration	19
(7) Serum protein fractionation	19
(8) Normotest	20
(9) Antibody titres	20

CONTENTS - CHAPTER 1

	<u>Page</u>
Summary	22
Introduction	22
Materials and Methods	23
Results	24
Clinical findings	24
Haematological changes	24
Parasitology	25
Establishment of patency	28
Pathology	28
Discussion	29
Conclusions	33

CONTENTS - CHAPTER 2

	<u>Page</u>
Summary	34
Introduction	34
Materials and Methods	35
Experimental design	35
Recovery of parasites	36
Faecal examination	36
Recovery of larvae from the trachea	36
Results	37
Recovery of parasites	37
Recovery of parasites from faeces	40
Development of patency	41
Examination of tracheal washings	41
Discussion	41
Conclusions	47

CONTENTS - CHAPTER 3

	<u>Page</u>
Summary	48
Introduction	49
Experimental Design	49
(a) Experiment 1	49
(b) Experiment 2	50
Section I Clinical Signs	51
Materials and Methods	51
(a) Experiment 1	51
(b) Experiment 2	51
Results	51
(a) Experiment 1	51
Rectal temperatures	51
Respiratory signs	52
Body weights	53
Other clinical signs	54
Development of patency	54
(b) Experiment 2	54
Discussion	55

CONTENTS - CHAPTER 3 (contd.)

	<u>Page</u>
Section II Pathology	63
Materials and Methods	63
(1) Pathology of the Liver	63
Results	63
Discussion	65
(2) Pathology of the Lungs	68
Results	68
Discussion	72
(3) Pathology of the Intestinal Tract	76
Results	76
Discussion	76

CONTENTS - CHAPTER 3 (contd.)

	<u>Page</u>
Section III Clinical Pathology	77
(1) Haematology	77
Materials and Methods	77
Results	77
Discussion	78
(2) Serum protein estimations	81
Materials and Methods	81
Results	81
Discussion	82
(3) Liver function as estimated by the Normotest	84
Materials and Methods	84
Results	85
Discussion	86
Conclusions	87

CONTENTS - CHAPTER 4

	<u>Page</u>
Summary	89
Introduction	89
Materials and Methods	90
Experimental design	90
Parasitology	91
Clinical examination	91
Haematology	91
Pathology	91
Results	92
Parasitology	92
Clinical findings	95
Pathology	96
Haematology	98
Discussion	98
Conclusions	102

SUMMARY

This thesis describes the results of a series of experimental studies of the life-cycle and pathogenic effects of one of the most common helminths of the foal, Parascaris equorum.

The investigations showed that the larvae of P. equorum migrate through the liver and the lungs before returning to the predilection site in the cranial part of the small intestine, 2 to 4 weeks after infection. In foals under one month of age a high percentage of the infective dose completed this migration, regardless of the magnitude of the infection and subsequently the worms grew rapidly in the intestinal lumen. Following a small infection (160 eggs) most of the parasites developed to maturity during the ensuing 2 months, whereas after a large infection (8,000 eggs) there was an expulsion of worms in the faeces from the seventh week onwards, resulting in a progressive decrease in the number of worms present in the small intestine.

The studies on the pathogenesis of P. equorum infection in young foals showed that the pulmonary migration was accompanied by mild respiratory signs of coughing and a nasal discharge. During the later stages of infection the development of substantial numbers of ascarids in the intestinal lumen was associated with unthriftiness and poor weight gains.

Histological examination of the liver revealed the presence of an infiltration of eosinophils and lymphocytes and a fibrotic reaction around the portal triads, but there was no indication of any impairment of hepatic function in these experiments. In the lungs a cellular

infiltration, consisting primarily of eosinophils which were later replaced by lymphocytes, was particularly marked around the small blood vessels and airways. An increasing number of raised, spherical, lymphocytic nodules developed during the fourth to sixth weeks, a few of which were still evident several months later.

The only significant haematological change was the development of a circulating eosinophilia 3 to 5 weeks after infection, which corresponded to the periods of hepatic and pulmonary eosinophilia. Alterations in the serum protein levels were not recorded.

After studying the effects of P. equorum infection in young foals, further experiments were designed to investigate the development of immunity to this parasite. Experimental infections of worm-free and naturally reared foals, aged 6 to 12 months, showed that, compared with the younger animals, only a small number of larvae returned to the gastrointestinal tract but the hepatic and pulmonary lesions were increased in number and severity. The findings were identical in the worm-free and naturally reared groups and suggested the development of an age-dependent immune reaction operating at the level of the parenchymatous organs. Although the respiratory syndrome was more severe in the older animals, unthriftiness was not a feature due to the reduced number of worms present in the small intestine.

The prepatent periods ranged from 80 to 104 days, but the length of the prepatent period could not be correlated with either the age of the foal or the magnitude of the infection. In foals over 6 months of age patent infections occurred less frequently and the faecal egg counts tended to remain low.

GENERAL INTRODUCTION

Horses may be infected by many species of gastrointestinal nematodes but research in the field of equine helminthology has been limited by the practical and financial problems involved in rearing worm-free foals. Over the past ten years, however, there have been advances in the knowledge of the various strongyle species in the horse. In particular the life cycles and pathogenicity of the two common large strongyles Strongylus edentatus (McCraw and Slocombe, 1974) and Strongylus vulgaris (Duncan and Pirie, 1975) have been investigated, and the epidemiology of horse strongyle infection has been discussed by Ogbourne and Duncan (1977). There are other nematode parasites of the horse, however, about which little information is available, including the large roundworm, Parascaris equorum.

In recent years the number of horses and ponies kept for pleasure purposes has increased dramatically, but there has not been a comparable increase in the pasture available for maintenance of these animals. The development of helminthiasis has been favoured by the high stocking densities in small fields and paddocks and consequently there is an increasing demand for the veterinary surgeon to provide information and advice on the effective control of these infections.

REVIEW OF THE LITERATURE

Surveys in various parts of the world have shown that P. equorum is a ubiquitous parasite in the equine population and that the incidence of patent infections decreases with age (Table 1).

The first large-scale survey of the incidence of the common nematode parasites of the horse in the United Kingdom was published by Poynter in 1970. He examined over 16,000 faecal samples from 3,227 horses of different ages and found an overall incidence of 27.4% for P. equorum. A breakdown of his results, however, showed a negative correlation with age, the incidence falling from 58.3% in foals to 10.4% in 4 year-olds. Earlier work by Russell (1948) on the development of helminth infections in foals from 7 English studs showed that all of the foals developed patent P. equorum infections between 9 and 16 weeks of age, usually at 12 to 13 weeks. The ascarid faecal egg count then rose rapidly to reach a peak at 16 to 18 weeks after which there was a steady decline and many foals ceased to pass eggs from 6 months onwards. Russell (1948) was unable to detect the presence of ascarid eggs in the faeces of mares and she concluded that infection was maintained on a stud by the foals and yearlings.

Author	Geographical Location	Incidence of <u>P. equorum</u> Infection	
		per cent positive	age range
de Jesus & Uichanco (1939)	Philippines	15.96 26.82 14.94 12.28	all ages < 2 years 3-7 years 8-12 years
Antipin (1940)	U.S.S.R.	59-85 39-56	< 1 year 1-2 years
Hadley (1943)	Wisconsin	76	ages not specified
Russell (1948)	U.K.	100	< 6 months
Egyed & Hollo (1956)	Hungary	15 50-60	all ages foals
Langenegger, Matamoros & Urbina (1967)	Rio de Janeiro State	25 4.5 0	1-5 years 5-12 years > 12 years
Poynter (1970)	U.K.	27.4 58.3 36.8 20.3 19.8 10.4	all ages foals 1 year 2 years 3 years 4 years
O'Nuallain (1973)	Eire	38	all ages
Tolobaev (1975)	U.S.S.R.	82	< 1 year

TABLE 1 Surveys recording the incidence of P. equorum infection.

Field studies in other parts of the world have supported the findings of Poynter (1970) and Russell (1948) regarding the prevalence of infection. O'Nuallain (1973) recorded an overall incidence of P. equorum infection in Eire of 38%, while in Switzerland, Eckert (1973) quoted a figure of 25% in horses of all ages with an increased prevalence of 65% in young animals.

Egyed and Hollo (1956) undertook faecal examinations of 16,000 horses on state-owned farms near Budapest and found that 15% of these animals had ascariasis, although the incidence in foals was estimated to be between 50 to 60%. More recently Varga (1973) stated that parascariasis was frequently diagnosed in Hungary and affected predominantly young horses.

In North America Hadley (1943) examined 71 horses of unrecorded ages on a single stud in Wisconsin and found that 76% harboured ascarids. A later survey of ranches in Rio de Janeiro State (Langenegger, Matamoros and Urbina, 1967), in which the animals were divided into three age groups, recorded an incidence of 25% at 1-5 years, falling to 0% in horses over 12 years. In the Philippines 15.96% of all horses were infected with P. equorum (de Jesus and Uichanco, 1939), but again there was a negative correlation with the age of the host.

Antipin (1940) investigated the incidence of parascariasis in animals maintained under various systems of management and in different geographical areas in Russia. In foals he found an infection rate of 59-85%, while in older animals (1-2 years old) the range was 35-56%. Also in the U.S.S.R. Tolobaev (1975) noted a cyclic pattern with a decreased incidence in the spring in all groups followed by a rise during the winter months to reach the highest values in December.

All species of equidae are susceptible to P. equorum infection. Rashek (1964) reported the occurrence of ascariasis in the Asiatic wild ass on the Barsa-Kelmes Island in the Aral Sea, whilst in a study of infection in 19 tarpans near Bialowieze, Poland, Kondak (1964) noted that ascarid egg production was independent of season but decreased with age. In 1959 necropsy examination of an adult zebra, which had lived in a Glasgow Zoo for several years, revealed the presence of over 700 P. equorum (Dunn, personal communication).

The life cycle of P. equorum has received little attention. The infective egg hatches only after ingestion by a suitable host. There is evidence (Hadwen, 1925; Lyons, Drudge and Tolliver, 1976) that the larvae migrate through the body tissues before eventually returning to their predilection site in the small intestine. Hadwen (1925) described degeneration of liver cells, which he suggested was due to ascarid migration, but no attempt was made to recover parasites from this site. The same author found larvae approximately 2 mm long in the air passages of the lungs and also in the duodenum 20 days after primary experimental infection with P. equorum, but on day 54 larvae could only be recovered from the small intestine. More recently Lyons et al. (1976) have used monospecific parasitic infections to assess the efficiency of various anthelmintics. Fourteen days after a single ascarid infection they found larvae in the lungs only, whereas by day 17 few larvae remained in this site, the majority having returned to the intestinal tract. On both occasions the larvae were approximately 2 mm long.

A hepatic-tracheal migration of parasitic larvae has been demonstrated in other ascaridoid species such as Ascaris suum (Douvres, Tromba and Malakatis, 1969) and a similar life cycle has

been attributed to P. equorum (Drudge and Lyons, 1977) despite the lack of supportive experimental work.

The length of the prepatent period of P. equorum, determined by the first appearance of ascarid eggs in the faeces, is variable. Following monospecific infection Lyons et al. (1976) reported the development of patency in 72-110 days, whilst Bello, Amborski, Torbert and Greer (1973) found that 3 out of 10 foals already had ascarid eggs in the faeces when first examined 84 days after experimental infection and the remainder had become positive by day 105. After infection of a single worm-free donkey foal patency developed in 81 days (Wetzel and Enigk, 1938).

Under field conditions the average age at which ascarid eggs appeared in foals faeces was found to be 101 days (Antipin, 1940), 84 to 91 days (Russell, 1948), 77 to 98 days (Todd, Hanson, Kelley, Wyant and Hull, 1949), and 98 days (Poynter, 1970). If the prepatent period is taken to be 72 to 110 days, then infection must occur soon after birth. One possible method of transmission during the perinatal period is through the dam's colostrum or milk, as in the related species Toxocara cati in cats (Swerczek, Nielsen and Helmboldt, 1971) and Toxocara vitulorum in cattle (Warren, 1971). The only equine parasite known to be transmitted in the milk is Strongyloides westeri (Enigk, Dey-Hazra and Batke, 1974).

Ascarid eggs have occasionally been found in the faeces of foals which were too young to have acquired patent infections after birth (Salisbury, Baker and Britton, 1940; Russell, 1948). A possible explanation for this was suggested by the work of Anschau and Exner (1953), who fed adult P. equorum to foals, then recovered ascarid ova from the faeces from 4 to 48 hours later. Young foals frequently indulge in the habit of coprophagia (Francis-Smith and

Wood-Gush, 1977) and if, during this activity, they ingest immature ascarid eggs, which are unable to respond to the usual hatching stimuli, then these eggs may appear unchanged, in the faeces.

The possibility of prenatal infection in the foal has been suggested by Salisbury et al. (1940), Russell (1948) and Wiltshire (1954). It is well known, for example, that the larvae of Toxocara canis migrate from the tissues of the bitch to the foetal lungs during the sixth week of pregnancy, leading to a shorter prepatent period than that observed in pups infected by ingestion (Yutuc, 1954). To investigate whether prenatal infection with P. equorum occurred in the horse Matoušek (1937), Enigk (1951) and Poynter (1970) examined the body organs of a total of 37 equine foetuses and neonates, but no evidence of prenatal parasitic infection was found.

The length of time for which patent P. equorum infections are maintained in young animals is variable, and, as previously mentioned, the tendency is for the incidence to decrease with age. Lyons et al. (1976), for example, recorded egg production for 35 days in an experimentally infected yearling and for 119 days in a 5 month-old foal. In foals reared naturally Bello et al. (1973) found that excretion of ascarid eggs tended to disappear around 6 months of age.

The infrequency of parascariasis in older horses together with the failure of Wetzel and Enigk (1938) and Antipin and Stepanova (1948) to establish patent infections in mature animals reared under natural conditions suggested the presence of an age or acquired immunity. Although age, per se, may confer immunity there have been no reports of experimental infections in mature worm-free animals and it is, therefore, impossible to exclude the possibility that an acquired immunity develops following infection, which is widespread amongst foals.

Unlike the strongyloids which have a free-living preparasitic stage able to migrate away from the dung pats, the infective stage of the ascaridoids is the egg containing a larva which is unable to spread by active means. Compensatory mechanisms include firstly, the fecundity of the adult worm, secondly, the ability of the egg to survive for many years due to the protective lipid and chitinous layers of the shell and thirdly, the adhesive properties of the outer proteinaceous layer of the egg shell (Fairbairn, 1957). Russell (1948) found that infection of foals was equally prevalent under the different systems of management on the 7 studs in her survey, while Hadwen (1925) felt that infection was more readily acquired by foals maintained indoors. Antipin (1940), in an extensive study of the epidemiology of parascariasis, concluded that the major source of infection for the foal was the stable, and of lesser importance were the grazing areas.

In field cases of parascariasis there have been several reports of deaths due to intestinal impaction, with or without subsequent rupture and peritonitis (Lebailly and Cadillac, 1957; Wiltshire, 1954; Rylands, 1971; Orr, 1972). Drudge and Lyons (1977) felt that intestinal rupture was the primary danger, but that this was not necessarily related to the number of worms. These authors also noted a seasonal incidence, in that fatal cases occurred in the fall or early winter, with the number of cases varying from year to year. Under experimental conditions, Bello et al. (1973) infected worm-free foals with 5,000 P. equorum eggs as part of an anthelmintic trial and found that 2 out of 5 untreated controls died between 14 and 18 weeks after infection.

Rylands (1971) and Orr (1972) each recorded a case in which a foal died within 24 hours of the onset of an acute illness and was found, at post mortem examination, to have an intestinal perforation

associated with the presence of ascarids. Lebailly and Cadillac (1957) also described a fatal case of septic peritonitis following rupture of the small intestine with two P. equorum encysted in the mesentery. In their discussion these authors quoted Carpentier (1939) who had reported 23 cases of intestinal rupture due to P. equorum, whilst Wiltshire (1954) recalled at least one death each year due to intestinal impaction by masses of ascarids.

There have been few observations of the clinical signs associated with monospecific P. equorum infections. Wetzel and Enigk (1938) noted sporadic coughing from 10 to 18 days after infection of a donkey foal, while Bello et al. (1973) recorded increasing weakness in their foals as the infections developed and became patent. In Russia massive challenge infections of P. equorum in foals with pre-existing helminth burdens, resulted in pyrexia and coughing during the "acute phase" of the disease followed by emaciation and retarded development during the later stages (Antipin and Stepanova, 1948; Chebotar'ov, 1950; Ryazantsev, 1956). These authors also described enteritis, abdominal pain and nervous disturbances, which they attributed to the presence of ascarids in the small intestine.

From his experiences in practice, Wiltshire (1954) described parascariasis as a debilitating disease, causing lung damage and a slight cough and Russell (1948) stated that the presence of a cough and a sticky nasal discharge at weaning time was often attributed, by the owners, to parascariasis. Although difficult to understand it has been suggested that the masses of P. equorum recovered from the small intestine at necropsy of a mare may have been responsible for bouts of epilepsy (McBarron, 1948).

The gross and histopathological changes following larval migration through the body tissues are poorly described. Hadwen (1925) observed a granular degeneration of the hepatic cells with

grouping of eosinophils beneath Glisson's capsule and around the blood vessels, which led to the suggestion that larvae travelled through the connective tissue adjacent to the vessels. In the lungs the same author recorded hepatisation in the cranial lobes, oedema of the pulmonary tissue and the presence of many small, white nodules beneath the pleura. In the small intestine Hadwen (1925) found large amounts of white mucus associated with the presence of many P. equorum. During a study of the treatment of parascariasis, Ryazantsev (1956) noted the occurrence of sites of atelectasis in the lungs and the presence of haemorrhagic foci in the intestine with profuse discharge of mucus.

Several workers have described the haematological changes which follow experimental P. equorum infection. A fall in the total red cell count and haemoglobin values were seen by Antipin and Stepanova (1948) and Ryazantsev (1956), whilst Chebotar'ov (1950) found no significant changes in these parameters. Alterations in the total white cell count have been reported by Antipin and Stepanova (1948) and Ryazantsev (1956), who found a leucocytosis, whilst Chebotar'ov (1950) noted leucopaenia. Despite this, all of these workers recorded similar changes in the differential white cell count involving neutropaenia and a relative lymphocytosis. A circulating eosinophilia, which is a feature of the migratory phase of many helminth infections (Pick and Turk, 1972), has been recorded in P. equorum infections by Hadwen (1925), Antipin and Stepanova (1948), Chebotar'ov (1950) and Ryazantsev (1956).

MATERIALS AND METHODS

A. EXPERIMENTAL ANIMALS

(1) Stabling facilities

The experimental animals were housed in a unit of ten brick-built loose boxes with a common air-space. Prior to the start of the foaling season, the stables were thoroughly disinfected with 5% lysol. Nevenic (1952) has shown this to be lethal to Parascaris equorum eggs. Whilst the boxes were in use they were cleaned out daily and hosed weekly with a high-pressure steam washer (Warwick 5000S, Warwick Pump & Engineering Co., Oxford, England).

(2) Production and maintenance of worm-free foals

Cross-bred pony mares were brought indoors to foal in clean loose boxes that had been disinfected and maintained in the manner described above. The mares were treated on admission and thereafter every 14 days with pyrantel embonate (Strongid-P Granules, Pfizer Ltd., Sandwich, Kent), at a rate of 19 mg/kg to prevent contamination of the stables with parasite eggs.

The foals were weaned at 6 to 8 weeks of age, then housed in pairs in clean loose boxes. They were offered a diet of good quality hay ad libitum, plus a concentrate ration of proprietary stud cubes (Spillers Stud Cubes, London, England) and milk pellets (Equivite Milk Pellets, Beecham Animal Health Products, Glasgow, Scotland).

(3) Naturally infected foals

Pony mares foaled out of doors in a 2 acre paddock which had been grazed by ponies of all ages for several years. Foals reared

in this paddock in previous years were known to have acquired heavy ascarid and strongyle worm burdens.

B. PARASITOLOGICAL TECHNIQUES

(1) Culture of infective P. equorum eggs

Mature female P. equorum worms were collected from the small intestines of naturally infected ponies immediately after death and placed in warm saline at 37°C for 24 hours. The eggs produced by these worms were collected, mixed with silver sand in petri dishes and incubated at 27°C for 10 days. The sand containing the eggs was then covered with a filter paper soaked in 5% copper sulphate to prevent fungal contamination and stored at 4°C. The eggs were harvested by adding 0.1% lissapol solution to the petri dishes and then collecting the supernatant after sedimentation to remove the sand. This procedure was repeated, and the eggs recovered were examined microscopically to confirm that a high percentage contained larvae. Only those batches of eggs in which over 60% of the eggs were larvated were retained for use.

Infective doses were prepared by dilution from a single batch of eggs and made up to 30 ml using 0.1% lissapol.

(2) Administration of infective doses

The animals were restrained by two assistants to allow the passage of a polythene stomach tube (Portex Ltd., Hythe, Kent, England). The infective dose was poured into this tube then flushed through with water.

(3) Gross examination of faeces for the presence of parasites

Total daily faecal collections were made by bedding the foals on clean shavings or sawdust and removing the droppings twice daily. The faecal balls were crumbled manually when the worms could be seen and picked out.

(4) Faecal egg count

Faecal samples were collected from the rectum and examined by a modified McMaster technique (Gordon & Whitlock, 1939). In this method 3 g of faeces were homogenised in 42 ml water, passed through a 100 mesh sieve, and the filtrate collected. A 15 ml flat-bottomed test tube was filled with the well-mixed filtrate then spun in a centrifuge at 2,000 r.p.m. for 2 minutes. The supernatant was poured off, the sediment agitated and the tube filled to the previous level with saturated salt (NaCl) solution. The tube was inverted six times and sufficient fluid removed in a pipette to fill both chambers of a McMaster slide. As the eggs rise rapidly in the flotation fluid, the pipetting must be accomplished rapidly. The number of eggs in both chambers of the McMaster slide was multiplied by 50 to give the count in eggs per gram (e.p.g.) of faeces.

(5) Recovery of parasites from the liver

Portions of liver were taken from all lobes to 25% of the total weight of the organ. The blocks were minced in a Kenwood Mixer KNM.1 (Peerless & Ericsson, Birmingham, England), wrapped in a double layer of gauze and suspended in a large funnel filled with water. This apparatus was maintained at 37°C for two hours, then 50 ml were drawn from the funnel and concentrated by centrifugation at 1,500 r.p.m. for 3 minutes. The sediment was examined microscopically, any larvae being collected and preserved.

(6) Recovery of parasites from the lungs

(a) From the parenchyma

Blocks of tissue were taken from all lobes of one lung to 25% of the total lung weight. This tissue was treated as described above for the liver.

(b) From the airways

The airways of the second lung were opened by cutting along the

bronchi with scissors. The lung was floated with the cut surface down for 12 hours in a bucket of warm saline, after which the tissue was removed and the supernatant syphoned off. The remainder was spun in a centrifuge at 1,500 r.p.m. for 3 minutes and the sediment examined microscopically for the presence of larvae.

(7) Recovery of parasites from the gastrointestinal tract

The entire gastrointestinal tract was removed and ligatures applied to allow the contents of the stomach, small intestine, caecum and colon to be collected separately.

Each organ was opened along its length, the contents emptied out and the mucosa rinsed clean with water. At this stage any large parasites were picked out and preserved. The entire contents of the small intestine and aliquots of the contents of the stomach, caecum and colon were then fixed in 10% formaldehyde and 20% of the total volume from each organ was examined microscopically for the presence of small parasites.

(8) Recovery of parasites from tracheal washings

The tracheal washings were collected using a flexible fiberoendoscope and placed in sterile bottles. The samples were examined microscopically on the day of collection.

(9) Preservation of parasites

Parasites recovered from the liver, lungs and gastrointestinal tract were prepared in an ascending series of alcohol. Small specimens were mounted in neutral glycerine jelly and the larger worms stored in glycerine alcohol.

(10) Measurement of parasites

Large parasites (> 1 cm long) were measured with a perspex ruler. Smaller larvae were measured microscopically with the aid of a measuring eye-piece.

C. CLINICAL EXAMINATIONS

Clinical examinations were performed at 9.00 a.m. each day. Rectal temperatures were taken using a clinical thermometer calibrated in degrees fahrenheit. These readings were converted to the centigrade scale. The external nares were examined for the presence of a nasal discharge and the induction of a cough by pinching the trachea was taken as evidence of tracheal irritation. The lung fields were auscultated with a stethoscope and in some cases the respiratory rate was measured, but in most foals this proved difficult as any form of restraint caused an increase in heart and respiratory rates and when loose in the stable the foals seldom stood still long enough for the respirations to be counted.

The animals were observed for prolonged periods each day during which the appetite, general demeanour and frequency of spontaneous coughing of individual foals were monitored, together with the development of any other clinical signs.

Body weights were measured using a Gascoigne calf weighing machine (Precision Weighers, Reading, England).

D. ANCILLARY AIDS TO CLINICAL EXAMINATION

(1) Endoscopy

Endoscopic examinations of the trachea and bronchial tree were performed using a flexible fiberendoscope, which allowed detailed visual and photographic records of the respiratory passageways to be taken. During the early experiments the fiberendoscope used (Colonoscope, Olympus CF Type LB2, Keymed, Southend, England) had an external diameter of 14 mm which necessitated its introduction via the oral pharynx under general anaesthesia. For this purpose anaesthesia was induced using 5% Methohexitone Sodium (Brietal Sodium Veterinary, Elanco Products Ltd., London, England)

intravenously at a rate of 10 mg/kg. After induction the animals were intubated and stabilised on a halothane (Fluothane, I.C.I. Ltd., Pharmaceuticals Division, Macclesfield, England) and oxygen mixture until a steady state of anaesthesia was attained. The endotracheal tube was then withdrawn and the endoscope passed via the oral pharynx into the trachea and as far into the bronchial tree as its diameter would allow.

For the later experiments a smaller diameter fiberoendoscope (Paediatric gastroscope, Olympus GIF Type P2, Keymed, Southend, England) was available, which could be passed via the ventral nasal meatus. In this case the foals were tranquillised with Acepromazine Maleate (Acetylpromazine Injection 10 mg/ml, C-VET Ltd., Braintree, England) at a rate of 0.1 mg/kg intravenously and restrained in the standing position.

(2) Tracheal washings

Tracheal washings were collected by means of a canula inserted through the endoscope. The endoscope was passed to the level of the thoracic inlet then 20 to 30 ml of sterile saline injected through the plastic tube. The washings were sucked into a syringe and emptied into sterile bottles for parasitological examination or into EDTA tubes for cytology.

(3) Radiography

Lateral thoracic radiographs were taken in the standing position with an Elema-Schonander Triplex Optimatic 1023 (Elema-Schonander, Stockholm, Sweden) unit. Kodak-Omat H film (Kodak Ltd., London, England) was used with high speed calcium tungstate screens (Siemens Special Screens, Siemens Akhengesellschaft Medical Division, Erlangen, Germany). The exposure factors were approximately 16 mAs and 70 Kv, but varied slightly in different animals.

E. POST-MORTEM EXAMINATION

(1) Euthanasia and routine post-mortem examination

Young foals were killed by an intravenous injection of Pentobarbitone Sodium (Euthatal, May & Baker Ltd., Dagenham, England) at a rate of 15 mg/kg. Larger animals were shot using a humane killer then bled out. A routine post-mortem examination of the carcass and viscera was performed and any organ showing evidence of gross pathological change was photographed before taking blocks of tissue for histological preparation.

(2) Special post-mortem techniques

In all cases the respiratory and digestive systems, including the liver, were removed intact and examined in detail.

(a) Liver

The liver was examined superficially and after making a series of incisions into the parenchyma. Tissue blocks were taken at random from all parts of the liver and in addition selected blocks were taken from areas showing gross pathological changes.

(b) Respiratory system

The lungs were examined both visually and by palpation. The number, size and distribution of any superficial lesions were noted before making incisions into the substance of one lung to examine the pulmonary parenchyma and airways. Tissue blocks for histological examination were taken from all lobes of the lungs, both from areas of pathological change and from areas of apparently normal lung tissue, and also from the mediastinal lymph nodes.

The trachea was opened by cutting along the tracheal membrane when the presence of an exudate or changes of the mucosa could be seen.

(c) Gastrointestinal tract

The serosal surface of the entire gastrointestinal tract was examined before the application of ligatures to allow the contents of each part of the tract to be collected separately. After emptying and washing out the intestinal contents the mucosal surface was observed and tissue blocks taken from the small intestine only at 1 metre intervals.

The associated lymph nodes were examined both grossly and histologically.

F. PATHOLOGICAL TECHNIQUES

Samples of tissue were taken for histological examination both from areas showing gross pathological changes and also from apparently normal areas of the liver, lungs and small intestine.

The tissue was fixed in Carnoy's fluid (absolute alcohol, chloroform and glacial acetic acid), 10% formol saline or corrosive formol, and then dehydrated and cleared in a double embedding series and finally embedded in paraffin wax under a vacuum. Sections, cut at 6 μ m, were stained with haematoxylin and eosin and in addition selected sections were stained with carbol chromatrope, astra blue-safranin, toluidene blue and Martius scarlet blue.

Tracheal washings for cytological examination were collected into EDTA bottles. A thin smear was made on a glass slide, dried in air, then fixed in absolute alcohol for 10 minutes. All smears were stained with haematoxylin and eosin and selected smears were stained with alcian blue-PAS and carbol chromatrope.

G. HAEMATOLOGICAL AND BIOCHEMICAL TECHNIQUES

(1) Collection and storage of samples

Foals were bled from the jugular vein into sterile vacutainers (Becton-Dickinson, Rutherford, New Jersey, U.S.A.). Heparin was

used as anti-coagulant for haematological estimations, which were performed within a few hours of collection of samples.

For estimations requiring serum, 10 ml of blood was drawn into a plain vacutainer and left to stand for several hours to allow the formation of a firm clot. The serum which had separated was pipetted into plastic tubes, frozen and stored at -5°C .

All parameters were either measured in, or the results converted into, SI units.

(2) Packed Cell Volume (PCV)

The packed cell volume was determined by the microhaematocrit method. The heparinised blood sample was agitated gently before filling 2 capillary tubes, which were sealed by heat at one end. The tubes were spun for 6 minutes in a microhaematocrit centrifuge (Hawksley & Sons Ltd., London, England), the percentage PCV determined from the scale on a Hawksley Microhaematocrit Reader and converted to a 1/1 ratio.

(3) Haemoglobin concentration (Hb)

The oxyhaemoglobin method (Dacie & Lewis, 1966) was used for the estimation of haemoglobin concentration. Heparinised blood was diluted 1 in 200 in 0.04% ammonium hydroxide and mixed thoroughly to form a solution of oxyhaemoglobin, which was read in a colorimeter (Evans Electro-selenium Ltd., Harlow, England) using a yellow green filter (Ilford No. 625). A standard cyanmethaemoglobin solution (C. Davis Keeler Ltd., London, England) was used to calibrate the colorimeter and the results were expressed in grams per decilitre (g/dl).

(4) Total red and white blood cell counts (RBCs, WBCs)

An electronic particle counter (Coulter Model "D", Coulter Industrial Sales Co., Elmhurst, Illinois, U.S.A.) was used to determine the total red blood cell count ($\times 10^{12}/\text{l}$) and total

white blood cell count ($\times 10^9/1$).

(5) Differential white blood cell counts

Differential white cell counts were carried out on smears made from heparinised blood samples, fixed in methyl alcohol and stained with a 1 in 10 solution of Geimsa's stain R66 (G.T. Gurr, London, England) for 20 minutes. A minimum of 200 cells per slide were counted from an area between the centre and the edge of the smear. The various classes of leucocytes were then expressed as a percentage of the total number of cells counted.

(6) Total serum protein concentration

Total serum protein concentration was estimated by the biuret method of Weichselbaum (1946).

(7) Serum protein fractionation

The serum protein fractions were separated by electrophoresis on cellulose acetate strips (Oxoid Ltd., London, England), which were soaked in barbitone buffer (pH 8.6), blotted lightly to remove excess buffer and supported in an electrophoresis tank (Shandon Scientific Co., London, England). A micro-pipette was used to apply 0.003 ml serum 4 cm from the cathode end of the strip. A Vokam power pack (Shandon Scientific Co., London, England), provided a constant voltage of 150 volts for one hour after which the strips were removed and dried in a hot air oven (80-100°C) for 10 minutes to "fix" the proteins. The strips were stained in 0.2% Ponceau S (G.T. Gurr Ltd., London, England) in 3% trichloroacetic acid for 5 minutes, then washed in 5% acetic acid until the background was white. The strips were evaluated automatically as described by Neill (1963) using a Chromoscan recording densitometer (Joyce Loebel & Co. Ltd., Gateshead, England). The results were expressed in grams per litre (g/l).

(8) Normotest

5 ml blood samples were mixed with EDTA in sterile tubes and the PCV measured by the haematocrit method. The samples were then posted to the Equine Research Station, Balaton Lodge, Newmarket, where Ms E. Abbott performed the Normotest estimations using the method described by Allen and Archer (1972). These workers have shown that a delay of 5 days and 2 postings did not change the results significantly.

Briefly, 250 μ l of Normotest reagent (BDH Chemicals Ltd., Poole, Dorset) was placed in a plastic test tube in a water bath at 37.5°C. 5 μ l of whole blood was added and, after the first 20 seconds, the tube was tilted every second or so until a clot formed. The time was measured from the addition of the blood until the clot formed.

The Normotest time was dependent upon the PCV since the red cells did not take part in the reaction, so a correction factor curve was prepared to allow for the effect of the differing PCVs of the samples tested. It was also necessary, using plasma from normal horses, to prepare a calibration curve for the varying batches of reagent. The results were expressed as the per cent. Normotest.

(9) Antibody Titres

Paired serum samples were collected 6 weeks apart, the first sample being taken during an acute bout of respiratory illness with the second sample taken during the convalescent phase. The serum was stored at -20°C before being examined by Dr. D. Powell, Equine Research Station, Balaton Lodge, Newmarket.

The following serological tests were carried out after inactivation of the samples at 56°C for 30 minutes.

Influenza virus. Serum haemagglutination inhibition tests were carried out in round-bottomed, microtitre plates, using 0.05 ml volumes of reactants. Adult chicken erythrocytes (0.8%) were used with phosphate-buffered saline as the diluent. Eight haemagglutinating units of antigen were employed. The standard virus strains used were A/equine/Prague/1/56 (A/Equi 1 type) and A/equine/Miami 1/63 (A/Equi 2 type).

Rhinopneumonitis virus and Rhinovirus type 1. Neutralising antibody levels were determined by a plaque reduction test (Burrows, 1966) using the H-45 strain of rhinopneumonitis virus (equine herpes type 1) and the NM-11 strain (Burrows, 1968) of equine rhinovirus type 1.

Adenovirus. Precipitating antibody was detected in undiluted serum, using an agar gel precipitin test (Darbyshire and Pereira, 1964). The antigen was a crude infected tissue culture harvest of the Sol 25 strain (Todd, 1969).

CHAPTER 1

PRELIMINARY EXPERIMENTAL STUDIES

SUMMARY

Six worm-free pony foals, 2 to 4 months old, were infected with Parascaris equorum eggs using 3 different dosage regimes and killed at either 40 or 95-100 days after infection. Coughing and a circulating eosinophilia were features of large infections from which only a small number of worms developed to maturity. In small infections a high percentage of the parasites matured in the small intestine and this was associated with unthriftiness. Prepatent periods of 80 and 83 days were recorded.

INTRODUCTION

Since experimental studies on P. equorum infection had not been attempted previously in this laboratory a preliminary experiment was designed using a small group of worm-free foals to provide a general picture of the pattern of infection.

The aims of this first experiment were as follows:

1. To assess the efficiency of the methods employed for the collection, cultivation, storage and administration of infective eggs.
2. To study the relationship between the magnitude of the infection and the number of worms which subsequently developed in the small intestine.
3. To establish patent infections and determine the length of the prepatent period.
4. To investigate the clinical, haematological and pathological changes associated with the migration and development of P. equorum.

MATERIALS AND METHODS

A plan of the experiment is shown in Table 2. Eight worm-free pony foals were divided on an age basis into 2 groups of 4, a younger group aged 2 to 3 months and an older group aged 4 to 6 months. From each age group one foal received a single infection of 8,000 P. equorum eggs ("large dose"), one received a single infection of 160 P. equorum eggs ("small dose"), one received 10 infections of 160 P. equorum eggs administered on alternate days ("repeated small dose") and the fourth acted as an uninfected control to monitor clinical and haematological changes.

4 worm-free foals 2-3 months old		4 worm-free foals 4-6 months old
1 foal	Single small infection 160 <u>P. equorum</u> eggs	1 foal
1 foal	Single large infection 8,000 <u>P. equorum</u> eggs	1 foal
1 foal	Repeated small infections 10 x 160 <u>P. equorum</u> eggs on alternate days	1 foal
1 foal	Uninfected Controls	1 foal

TABLE 2 Experimental Design

The infected animals in the younger age group were killed on day 40 to provide information on the pathological changes during the early stages of parasitic development. The older group was kept to establish the prepatent period and to determine the number of worms which developed to maturity.

Throughout the experimental period clinical examinations were performed daily. Heparinised blood samples for haematological estimations were collected weekly and from day 30, faecal samples were examined twice weekly for the presence of ascarid eggs.

Routine post-mortem examinations were performed. Blocks of tissue for histological preparation were taken from any organ showing pathological changes. The contents of each part of the gastrointestinal tract were collected separately for the recovery of parasites, firstly by scanning with the naked eye when large worms could be picked out and then microscopically for the recovery of small worms.

RESULTS

Clinical Findings

During the experimental period rectal temperatures of all animals remained within the normal range of 37 to 38.8°C. A cough was present from day 12 to day 17 after infection in the younger "large dose" foal and on day 17 in both foals which received repeated infections, but no other signs of respiratory disease were observed.

Each animal maintained a good appetite throughout the experiment, but in spite of this both "small dose" foals became depressed and unthrifty. This was particularly marked in the younger animal which, by day 35 after infection, had become very thin. Figure 1 compares the bodily condition of the older "large dose" and "small dose" foals on day 95.

Haematological Changes

The foals were infected early in November 1975. During December the packed cell volumes (PCVs) of both experimental and control foals declined steadily from a mean of 0.35 to a mean of



FIGURE 1: Bodily condition of foal which received 160 P. equorum eggs (left) compared with foal which received 8,000 P. equorum eggs (right), 95 days after infection.

0.29, then rose to pre-experimental values by mid-January. The total red and white blood cell counts (RBCs and WBCs) and haemoglobin (Hb) values reflected the changes in PCVs, but all of these variations would appear to be seasonal, as similar results have been recorded previously in this laboratory during long-term haematological monitoring of worm-free pony foals. The PCVs, Hb values, total RBC counts and total WBC counts of the individual animals are shown in Appendices 1 to 4 respectively.

Significant changes occurred only in the eosinophil fraction of the differential WBC count (Figure 2). The controls were found to have consistently low values of less than 0.2×10^9 eosinophils per litre (eosinophils/l), whereas marked elevations occurred from day 12 after infection in the "large dose" foals and from day 22 in the "repeated small dose" foals. In both of these groups maximum counts of over 1.0×10^9 eosinophils/l were recorded, followed by a return to normal values by day 40. The "small dose" group had slightly raised eosinophil counts, up to 0.3×10^9 eosinophils/l, between days 20 to 30 after infection. During the later stages of infection, from day 40 onwards, circulating eosinophilia was not a feature in any animal.

Parasitology

(1) Foals killed on day 40

The worm burdens of the younger group of foals killed on day 40 are presented in Table 3.

The foal which received only 160 P. equorum eggs was depressed and unthrifty from around day 30 and at necropsy examination its small intestine was partially obstructed by a mass of large ascarids. On gross examination of the intestinal contents 140 worms, with a size range of 8 to 14 cm, were picked out. Subsequent microscopical

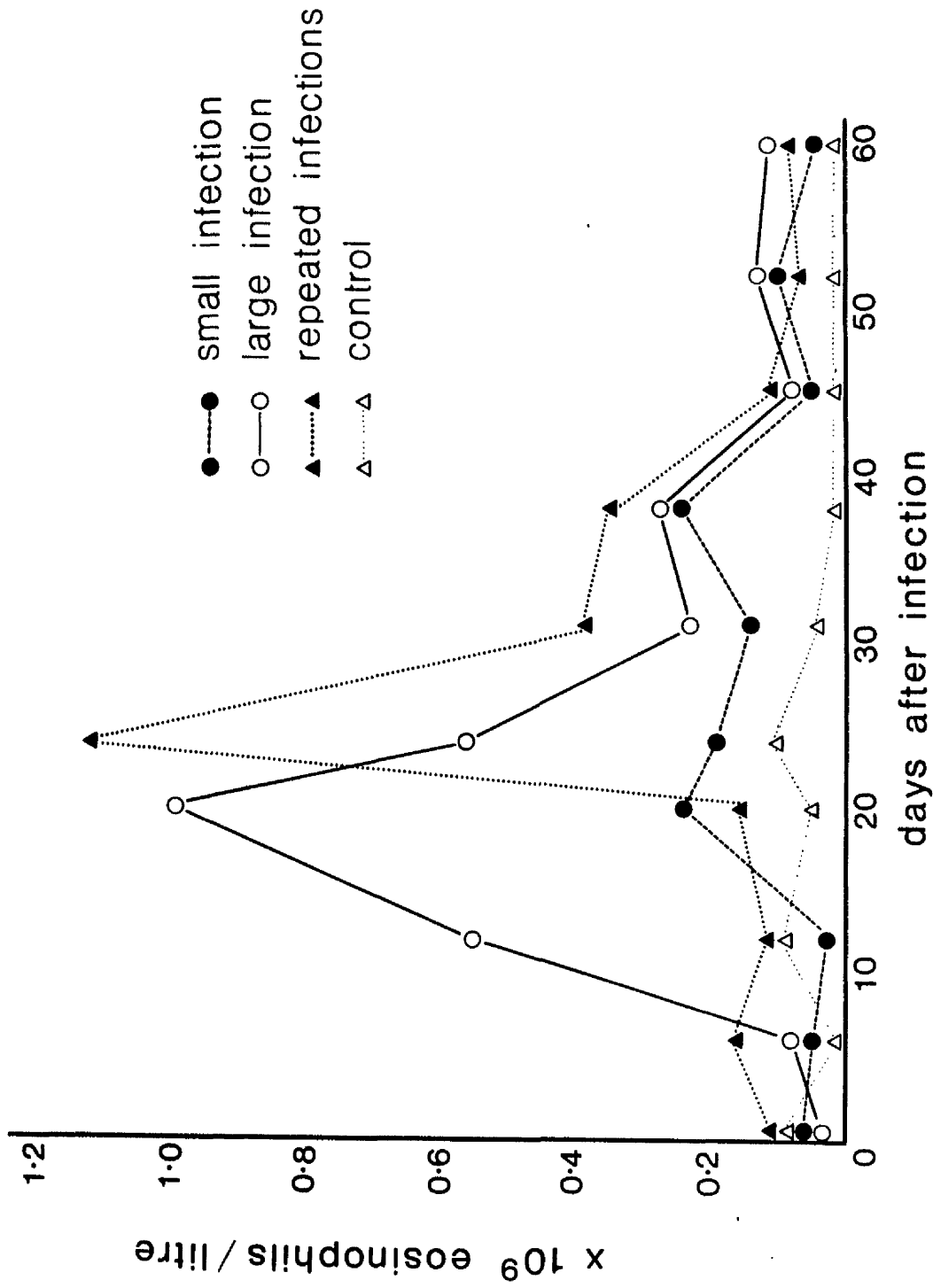


FIGURE 2: Circulating eosinophil counts of foals after experimental *P. equorum* infection.

examination was negative but this total, i.e. 140, represented 87.5% of the infective dose.

The single large and repeated small infections, on the other hand, produced no large parasites, but in both cases many small active worms could be seen moving among the small intestinal contents. From the foal which received 8,000 eggs, 6,350 worms were recovered, i.e. 79.4% of the infective dose, while the foal given a total of 1,600 eggs by repeated infection had 810 parasites, i.e. 50.6%. None of these specimens was more than 2.5 cm in length.

No. of <u>P. equorum</u> eggs administered	No. of <u>P. equorum</u> recovered from intestinal tract	Percentage take	Mean size (range) cm
160	140	87.5	10.8 (8.0-14.0)
8,000	6,350	79.4	1.57 (0.7-2.1)
10 x 160	810	50.6	1.36 (0.5-2.4)

TABLE 3 Parasite Recoveries from Foals killed on day 40

Figure 3 illustrates the remarkable differences firstly in the sizes of the individual parasites and secondly in the total volume occupied by the worms recovered from each of the three foals killed on day 40. At this stage the "small dose" foal had the smallest number of worms, but these occupied such a large volume that the volume of small intestinal contents was markedly reduced. However, where greater numbers of worms were present (from the single large

and repeated small infections) the individual parasites were small and occupied a comparatively small volume.

(2) Foals killed on days 95 and 100

The numbers and sizes of the worms recovered from the older group of foals killed on days 95 and 100 after infection are presented in Table 4.

No. of <u>P. equorum</u> eggs administered	No. of <u>P. equorum</u> recovered from intestinal tract	Percentage take	Mean size (range) cm
160 (patent day 80)	102	63.8	15.8 (11.5-28.5)
8,000 (patent day 83)	46	0.6	10.2 (7.5-13.8)
10 x 160	58	3.6	7.6 (6.5-12.0)

TABLE 4 Parasite Recoveries from Foals killed on days 95 and 100

At this time the "small dose" foal had 102 P. equorum, from 11.5 to 28.5 cm in length, a "take" of 63.8%. The foal which received 8,000 eggs had only 46 worms, from 7.5 to 13.5 cm long, while the foal which received 1,600 eggs by repeated doses had 58 worms, from 6.5 to 12 cm long. The percentage takes in these two animals were thus only 0.6 and 3.6% respectively.

Compared with the ascarids found on day 40, the 95 to 100 day recoveries from each foal were smaller in number but greater in volume. These changes were particularly marked in the "large dose" and "repeated small dose" animals as shown in Figure 4.




FIGURE 3: Parasites recovered from the foals killed 40 days after experimental P. equorum infection.



FIGURE 4: Parasites recovered from the foals killed 95 to 100 days after experimental P. equorum infection.

Establishment of Patency

Patency was established first in the single small infection foal on day 80 with a count of 450 ascarid eggs per gram (asc. e.p.g.), which rose rapidly to a maximum of 1,650 asc. e.p.g. on day 90. The single large infection became patent on day 83 with a count of 100 asc. e.p.g. rising slowly to reach 350 asc. e.p.g. on day 95. The pattern of the faecal egg outputs of these 2 animals is shown in Figure 5. The "repeated small dose" foal had not developed a patent infection when it was killed on day 100, but the specimens recovered from its small intestine were only slightly smaller than those found in the other 2 foals and worms of both sexes were present. It seems likely, therefore, that if this animal had been allowed to survive it would have developed a positive ascarid faecal egg count within a very short time. Routine examinations of faecal samples from the two control foals were consistently negative. The complete results of the faecal examinations are given in Appendix 5.

Pathology

Gross pathological changes were seen in the lungs of all 6 infected foals and in the livers of the foals killed on day 40.

(a) Liver - The 3 animals examined at post mortem on day 40 had multiple, small, white spots, up to 2 mm in diameter, scattered over the surface of the liver (Figure 6). Histologically these lesions were composed of subcapsular aggregates of lymphoid cells. The hepatic tissue was infiltrated by lymphocytes, with eosinophils and mast cells present, especially in the connective tissue. No lesions were detected on gross or microscopical examination of the liver on days 95 or 100.

(b) Lungs - The lungs of all 6 infected foals showed red, collapsed, pneumonic areas around the interlobar fissures of both

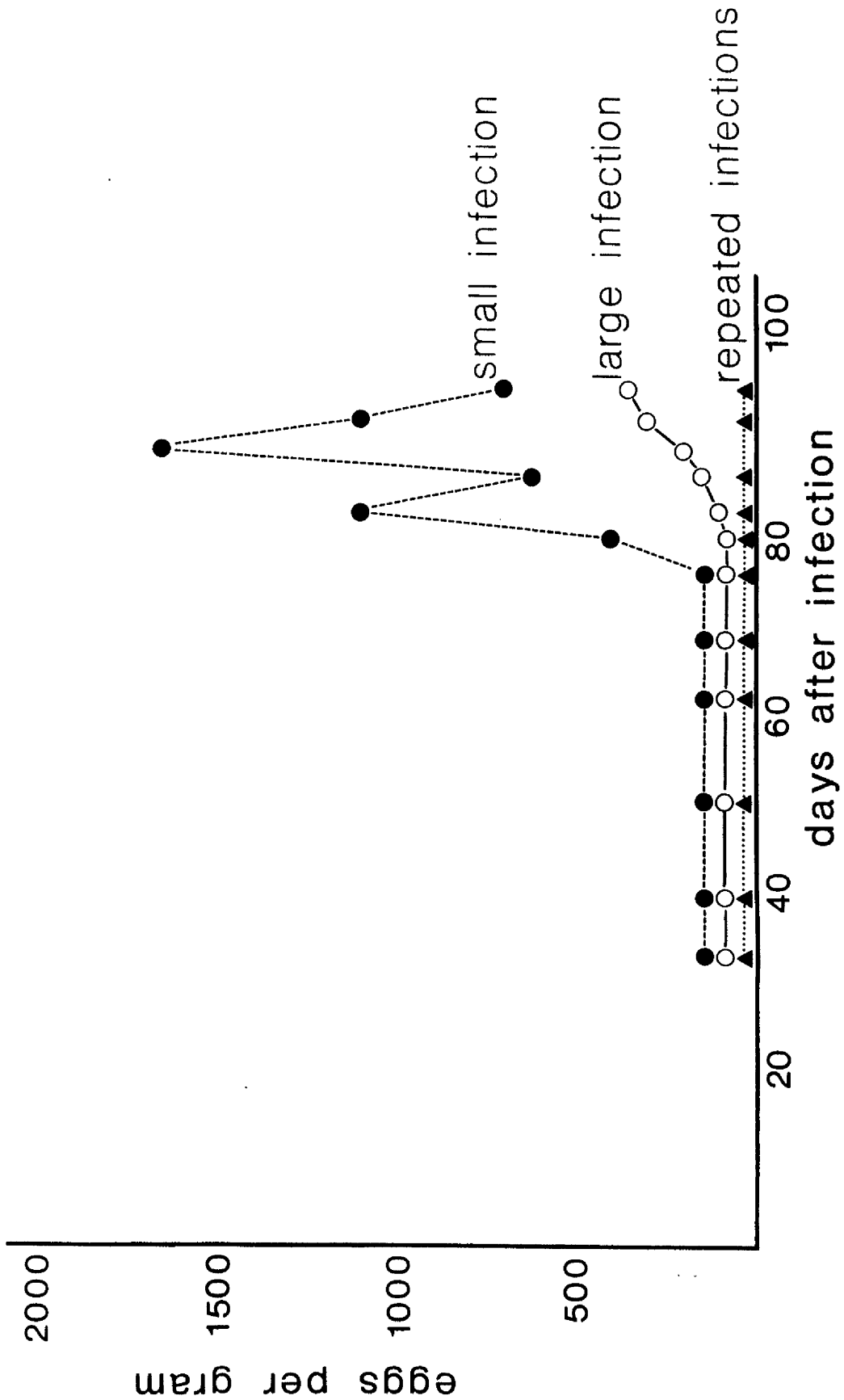


FIGURE 5: Faecal egg counts of foals after experimental *P. equorum* infection.

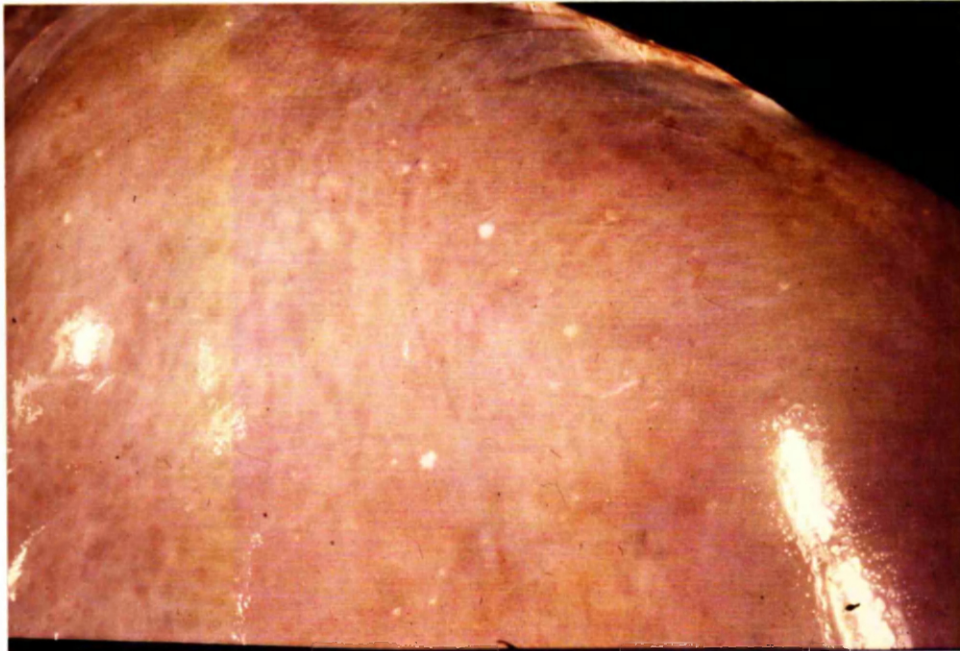

FIGURE 6: The liver of a foal killed 40 days after infection with 8,000 P. equorum eggs.

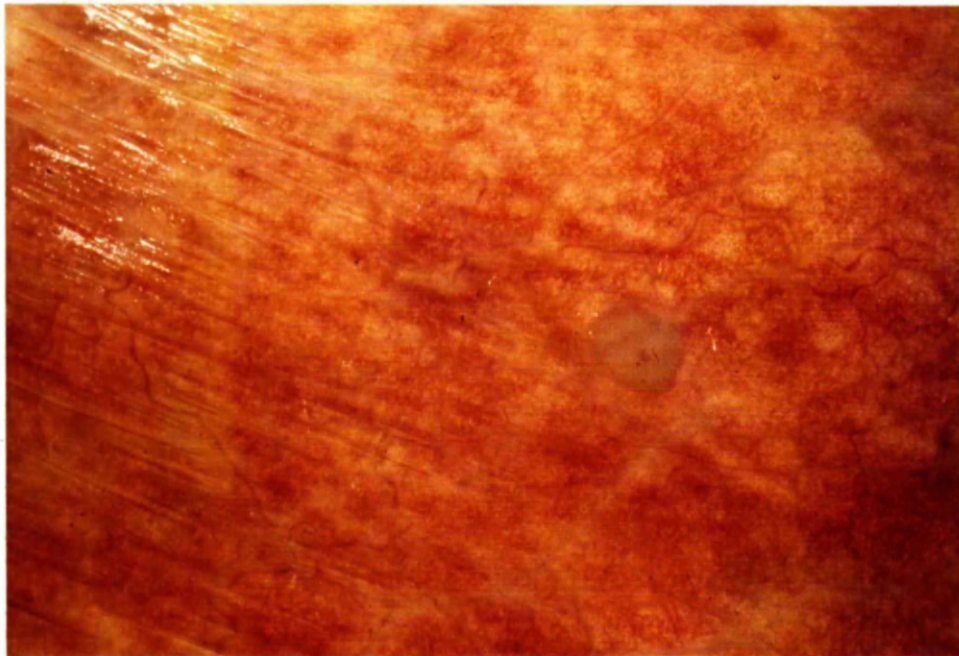


FIGURE 7: Subpleural pulmonary nodule in a foal killed 40 days after infection with 8,000 P. equorum eggs.

lungs and in the accessory lobe of the right lung. Microscopical examination showed that the pulmonary tissue in these areas was collapsed and consolidated with an associated bronchitis and bronchiolitis. Large numbers of neutrophils had accumulated in the airways and interstitium.

Multiple, subpleural nodules, up to 5 mm in diameter, were seen scattered over the surface (Figure 7). Grossly these were translucent, grey or greenish, slightly raised above the surrounding lung tissue and in the 95 and 100 day infections an appreciable number were calcified. Microscopically the nodules consisted of a mass of lymphocytes and a few eosinophils, surrounded by a lightly defined, fibrous capsule.

(c) Small Intestine - Pathological changes of the intestinal tract were not a feature and although the small intestine of the "small dose" foal killed on day 40 seemed to be thickened on palpation, microscopical examination showed that this was probably due to contraction of the muscle layers.

DISCUSSION

The clinical reactions of the foals in this experiment varied with the dose of P. equorum eggs administered. Frequent coughing occurred between days 12 and 17 in the younger "large dose" foal and in both "repeated small dose" foals. In an early report of experimental P. equorum infection in a 3 month-old, worm-free donkey foal (Wetzel and Enigk, 1938) coughing was recorded from day 10 to day 18. Hadwen (1925) and Antipin and Stepanova (1948) have also described the presence of a cough at this time in foals from 12 days to 10 months old, which were reared naturally and then challenged with large doses of P. equorum eggs. Although, under field conditions, both Russell (1948) and Wiltshire (1954) suggested that P. equorum

infection may cause coughing and a sticky nasal discharge, none of the animals in this experiment developed an abnormal nasal discharge.

Loss of bodily condition was apparent on clinical examination of the 2 animals which received a single small infection and, as a result of this observation, body weights of all foals were recorded in subsequent experiments. Unfortunately, weight gains were not measured in this preliminary study, so unthriftiness was gauged by a subjective comparison between infected animals and controls. Other authors have described parascariasis as a debilitating disease causing increasing weakness and emaciation, (Antipin and Stepanova, 1948; Chebotar'ov, 1950; Wiltshire, 1954; Ryazantsev, 1956; and Bello et al., 1973), although none of these workers has attempted to quantify their observations regarding the weight changes.

A circulating eosinophilia is a feature of the migratory phase of many helminth diseases and in the horse has been recorded in natural and experimental strongyle infections (Archer and Poynter, 1957; Drudge, Lyons and Szanto, 1966; Duncan and Pirie, 1975), and following massive P. equorum challenge of naturally reared foals (Hadwen, 1925; Antipin and Stepanova, 1948; Chebotar'ov, 1950; Ryazantsev, 1956). Ronéus (1971) studied the inter-relationship between the number of orally administered Ascaris suum eggs, blood eosinophilia and the number of adult, intestinal ascarids in piglets. In infections of over 500 eggs he showed that the number of eosinophils in the bloodstream was directly correlated with the number of inoculated eggs but that infections of less than 500 eggs gave no significant increase. The findings in this experiment were similar, in that the "small dose" foals (160 eggs) developed only a slight increase in circulating eosinophils (up to 0.3×10^9 eosinophils/l) compared with the controls, whereas the single large infection (8,000 eggs) and repeated small infections (10 x 160 eggs)

caused a marked elevation to over 1.0×10^9 eosinophils/l. In the "large dose" foal the count began to rise 12 days after infection, whilst the "repeated small dose" foal did not show a significant increase until day 22. Presumably this delay was due to the fact that the larval invasion of the tissues built up over the period of repeated infection to a level sufficient to trigger the eosinophil response. By day 40 after infection, the eosinophil counts of all foals had fallen to within the normal range and they were below 0.2×10^9 eosinophils/l for the remainder of the experimental period.

When the younger foals were killed on day 40, the parasites recovered from both the single small and single large infections represented a very high proportion of the total infective dose i.e. "takes" of 87.5 and 79.4% respectively. This finding suggested that the majority of larvae completed their somatic migration and returned to the small intestine within 40 days after a single infection. The recovery from the "repeated small dose" foal was rather lower (50.6%), but as the last infection was only 20 days earlier, it is possible that a proportion of the larvae had not yet completed their tissue migration.

By day 95 the percentage take in the "small dose" foal had fallen slightly to 63.8%, whilst the other 2 groups showed very marked reductions from 79.4 to 0.6% ("single large dose") and from 50.6 to 3.6% ("repeated small doses"). The tentative conclusion drawn from these observations was that the presence of a large number of ascarids in the intestinal lumen had stimulated a response whereby the vast majority of the worms were expelled. A somewhat similar phenomenon has been reported in A. suum infection in the pig by Ronéus (1971). In his experiments the highest number of worms became established in the small intestine after moderate infections of 100 to 500 eggs, whereas adult ascarids seldom developed after

infections of 1,000 eggs or greater. Schwartz (1959), who also recorded an elimination of worms after experimental A. suum infections, has ascribed this to an immune reaction, the antigenic stimulus being provided by the exsheathing fluid from the fourth moult.

The specimens recovered on day 40 from the "small dose" foal were remarkable for their large size (mean length 10.8 cm) compared with those found in the foals receiving a single large or repeated small infections in which all the parasites were less than 2.5 cm in length. On days 95 and 100 however, mean worm lengths of 10.2 cm and 7.6 cm respectively were recorded from these latter 2 groups and this increase in size seemed to be associated with the loss of a large proportion of worms from the gut. Over the same period there was a relatively small increase in size to a mean length of 15.7 cm in the "single small dose" foal but in this case the percentage take remained high. Two factors which may have been significant were firstly, the magnitude of the infection and secondly, the age of the foal. These aspects are explored further in Chapter 2.

The prepatent periods of 80 days and 83 days recorded in this study were similar to those reported by other workers (Wetzel and Enigk, 1938; Bello et al., 1973; Lyons et al., 1976).

Although the pathological examination in this preliminary experiment was limited, the nature of the lesions found in the liver and the lungs suggested that these organs had been invaded during parasitic migration. In future experiments the histopathological changes were studied in greater detail and these aspects will be discussed further in Chapter 3.

CONCLUSIONS

The aims of the experiment were achieved by providing the following information:

1. High percentage takes ranging from 50.6% to 87.5% were recorded on day 40 which indicated that the methods employed for the collection, cultivation, storage and administration of infective P. equorum eggs were satisfactory.

2. The effect of 3 infection levels on the numbers of parasites which became established in the small intestine of 2 to 3 month-old and 4 to 6 month-old foals was particularly interesting. In the younger foals percentage takes in excess of 50% were recorded on day 40 regardless of the magnitude of the infection. On days 95 and 100, however, percentage takes of only 0.6% and 3.6% were recorded from the older foals which received a single large and repeated small infections, whereas the "small dose" foal again had a high take (63.8%).

3. Patent infections were established in the "large dose" and "small dose" foals on days 80 and 83 after infection respectively. Although the "repeated small dose" foal did not have a patent infection when it was killed on day 100 the parasites appeared to be mature and the infection would probably have become patent within a short period of time.

4. The predominant clinical changes were firstly, the presence of a cough during the third week after infection in the foals from the "single large" and "repeated small dose" groups, and secondly, a loss of bodily condition in the "single small dose" group. Haematologically the only significant finding was the development of a circulating eosinophilia between days 12 to 40 in the animals which received a single large or repeated small infections. Pathological changes suggestive of larval migration were seen in the liver 40 days after infection and in the lungs on days 40 and 95 to 100.

CHAPTER 2

THE LIFE CYCLE AND MIGRATION OF PARASCARIS EQUORUM

SUMMARY

Eight worm-free pony foals, aged 2 to 4 weeks received a single infection of 8,000 Parascaris equorum eggs. The foals were killed at intervals to investigate the migration and subsequent development of P. equorum. Signs of larval invasion were found in the liver within 48 hours after infection. Larvae migrated from the liver to the lungs from 7 to 14 days after infection and the majority had returned to the small intestine via the tracheo-oesophageal route by day 23.

After completion of their tissue migration, the parasites grew rapidly in size in the lumen of the small intestine, but after day 37 the number of worms present in this site decreased. Patent infections developed on days 101 and 104.

INTRODUCTION

In the preliminary study described in Chapter 1 it was shown that larval migration through the body tissues had been largely completed within 40 days after infection, since a high percentage of the total infective dose was present in the small intestine at this time. To investigate the tissue migration and subsequent development of P. equorum in greater detail, an experiment was designed in which foals were killed at intervals after a single

infection. A large number of infective eggs was administered to the foals in this study for two reasons; firstly to facilitate larval recovery from the body tissues and secondly to investigate the mechanism involved in the reduction between days 40 and 95 in the number of worms established in the foals given a high dose of infective eggs in the preliminary experiment.

Some months after completion of this experiment a small calibre fiberoscope became available, which allowed the collection of tracheal washings without general anaesthesia. A further study was then made in which tracheal washings were collected repeatedly during the period of larval return to the gastrointestinal tract in an attempt to confirm that migration was via the tracheo-oesophageal route.

MATERIALS AND METHODS

Experimental Design

The design of this experiment is shown in Table 5. Ten worm-free foals from 2 to 4 weeks of age were used. Eight foals received a single infection of 8,000 P. equorum eggs and one of these animals was killed on days 2, 7, 14, 23, 37, 73, 106 and 146 after infection in order to trace the route of larval migration and subsequent development of the infection. Two uninfected foals, which were not killed, acted as controls.

10 worm-free foals, 2-4 weeks old	
8 foals	2 foals
8,000 <u>P. equorum</u> eggs	Uninfected controls
One foal killed on day 2 (F1), day 7 (F2), day 14 (F3), day 23 (F4), day 37 (F5), day 73 (F6), day 106 (F7), and day 146 (F8), after infection	C1 and C2 not killed

TABLE 5 Experimental Design

Recovery of Parasites

Routine post-mortem examinations were carried out and after the collection of blocks of tissue for histopathology, larvae were recovered from the liver and lungs by mincing and baermannising portions of the hepatic (25% by weight) and pulmonary (33% by weight) tissue. Only one lung was used for larval recovery from the parenchyma, the other lung being floated in warm saline, after opening the airways, to recover larvae from the trachea, bronchi and bronchioles.

The contents of each part of the gastrointestinal tract were collected separately and any large parasites were picked out. The remaining contents, or aliquot samples thereof in the case of the stomach and the large intestine, were formalinised and subsequently examined microscopically. A representative sample of the parasites recovered from each foal was measured.

Faecal Examination

To investigate the possibility of a large-scale expulsion of parasites from the intestinal tract, total 24 hour faecal collections were made twice weekly beginning on day 40, from the foals killed on days 73 (F6) and 106 (F7). These samples were crumbled, then scanned with the naked eye.

Routine faecal samples from all animals were examined twice weekly from day 40 for the presence of parasite eggs.

Recovery of Larvae from the Trachea

A foal which had been reared on grass was weaned at 3 months of age, then maintained indoors under conditions which precluded any further parasitic infection for one month. A single dose of 8,000 P. equorum eggs was administered and on days 14, 15 and 17 after infection tracheal washings were collected from the standing animal

using a small calibre fiberoendoscope. The washings were examined microscopically for the presence of ascarid larvae.

RESULTS

Recovery of Parasites

The parasitic recoveries from the body organs are shown in Table 6 and the measurements of the parasites from the various sites in Table 7.

Animal Identification	F1	F2	F3	F4	F5	F6	F7	F8
Killed Day	2	7	14	23	37	73	106	146
*Liver	0	272	4	0	0	NE	NE	NE
**Lungs	0	0	288	186	0	0	NE	NE
***Airways	0	0	382	0	0	0	NE	NE
Small Intestine	0	0	40	2090	4150	3195	751	123
Large Intestine	NE	NE	NE	0	0	32	4	0

NE - not examined.

* Based on examination of 25% by weight of the total hepatic tissue.

** Based on examination of 33% by weight of the total pulmonary tissue.

*** Based on examination of the airways of one lung.

TABLE 6 Numbers of P. equorum recovered from the body organs of foals after infection with 8,000 P. equorum eggs.

Animal Identification	Killed day	Site	Mean Length (Range) mm
F1	2	No larvae recovered	
F2	7	Liver	0.727 (0.580 - 0.963)
F3	14	Liver Lungs/Airways Small intestine	0.756 2.070 (1.653 - 2.436) 2.218 (2.088 - 2.494)
F4	23	Lungs Small intestine	0.867 (0.754 - 1.009) 4.490 (4.205 - 5.075)
F5	37	Small intestine	19.9 (14 - 27)
F6	73	Small intestine	74.3 (65 - 88)
F7	106	Small intestine	105.4 (81 - 129)
F8	146	Small intestine	159.0 (135 - 175)

TABLE 7 Measurements of P. equorum recovered from the body organs of foals after infection with 8,000 P. equorum eggs.

(1) Liver

Day 2: No larvae were found in the liver at this time, although the presence of multiple haemorrhagic spots on the surface of the organ suggested that larval penetration may have occurred.

Day 7: On day 7, 68 larvae, ranging from 0.580 - 0.963 mm in length were recovered from 25% of the hepatic tissue. These specimens were poorly differentiated with a rather granular appearance and rounded heads (Figure 8); the lips could not be clearly defined (Figure 9). The oesophagus was bulb-shaped with a mean length of 0.180 mm or approximately one quarter of the body length. The tail was pointed with a sub-terminal anus 0.043 mm from the tip of the tail.

Day 14: Only one larva was recovered from 25% of the liver on day 14. This specimen, which measured 0.756 mm, was similar in size and structure to those found on day 7.

Day 23 and Day 37: No larvae were found in the liver on either day 23 or day 37 and larval recovery from this organ was not subsequently attempted.

(2) Lungs

Day 2 and Day 7: No parasites were detected in the lungs or airways on days 2 or 7.

Day 14: On day 14, 96 larvae were recovered from 33% of the total pulmonary parenchyma and 191 larvae from the airways of one lung. The parasites from these two sites were similar, ranging from 1.653 to 2.436 mm in length (mean length 2.070 mm). The oesophagus measured approximately one sixth of the total body length (0.348 mm) and the anus was 0.075 mm from the tip of the tail. Figures 10 and 11 show the head and tail of a larva from the lungs, 14 days after infection.

Day 23: On day 23 no parasites were found in the airways but 62 larvae, with a mean length of 0.867 mm were recovered from 33%

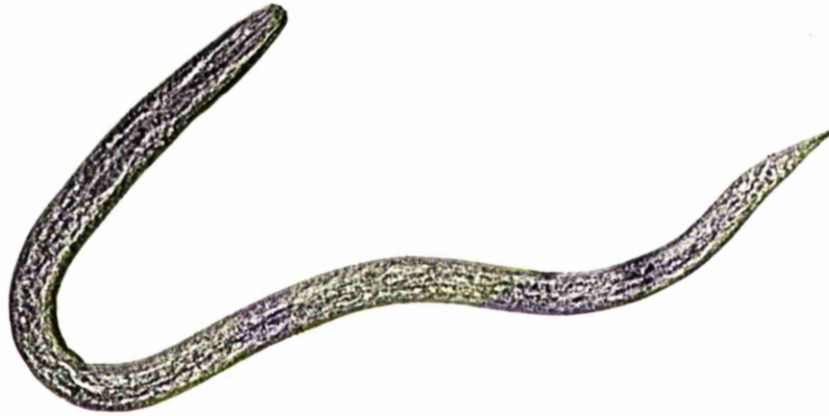


FIGURE 8: Larva recovered from the liver 7 days after infection with 8,000 P. equorum eggs. x 240

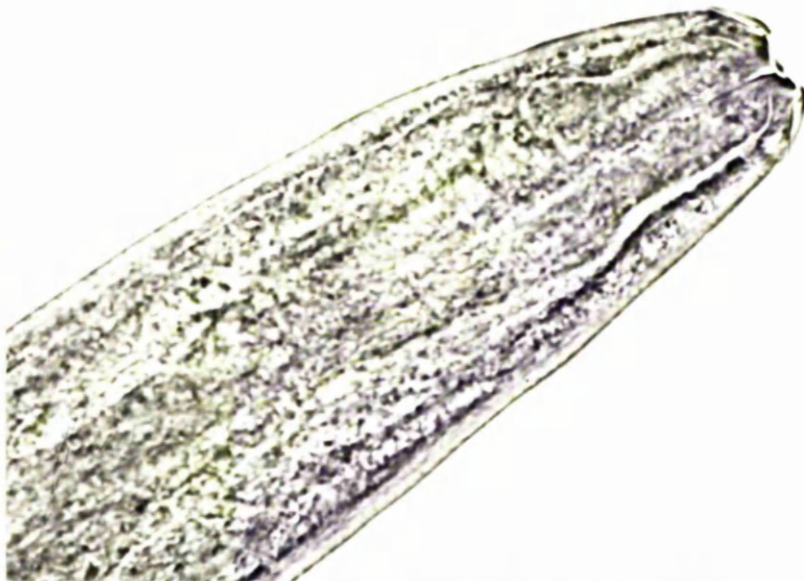

FIGURE 9: Head of larva recovered from the liver 7 days after infection with 8,000 P. equorum eggs. x 1,700




FIGURE 10: Head of larva recovered from the lungs
14 days after infection with 8,000
P. equorum eggs. x 500




FIGURE 11: Tail of larva recovered from the lungs
14 days after infection with 8,000
P. equorum eggs. x 470

of the total lung parenchyma. They were thus considerably smaller than those found in the lungs on day 14 (mean length 2.070 mm), and were indistinct morphologically.

Day 37 and Day 73: No parasites were recovered from the lungs or airways at this time, and subsequently parasitic recovery from these sites was not attempted.

(3) Small Intestine

Day 2 and Day 7: No parasites were present in the contents of the small intestine on day 2 or day 7.

Day 14: On day 14 a total of 40 larvae with a mean length of 2.218 mm were found in the small intestine. They were similar morphologically to those isolated from the lungs and airways at this time (Figure 12).

Day 23: On day 23 the small intestine contained 2,090 larvae with a mean length of 4.490 mm. Not only had the larvae doubled in size between days 14 and 23, they had also undergone a moult and the specimens recovered on day 23 could easily be distinguished from those found on day 14 by the presence of 3 distinct lips separated from the body by a marked constriction (Figures 13 and 14). The oesophagus was well-defined and bulb-shaped, measuring 0.707 mm or approximately one sixth of the total body length, and the anus was situated 0.139 mm from the tip of the tail (Figure 15).

Day 37: The highest number of P. equorum was recovered on day 37, when 4,150 worms with a mean length of 19.9 mm were present in the small intestine i.e. 51.9% of the infective dose. Even so these parasites occupied a small volume only and did not cause any obstruction of the lumen of the bowel.

Day 73: On day 73, parasites could be seen and palpated through the wall of the small intestine (Figure 16) and, on opening the intestinal wall many medium-sized ascarids spilled out

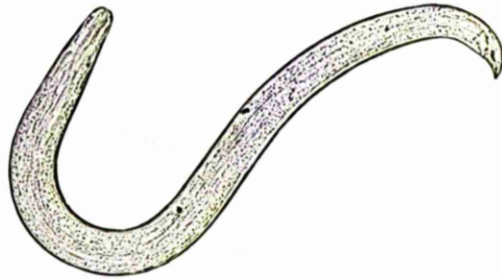


FIGURE 12: Larva recovered from the small intestine
14 days after infection with 8,000
P. equorum eggs. x 50



FIGURE 13: Larva recovered from the small intestine
23 days after infection with 8,000
P. equorum eggs. x 30




FIGURE 14: Head of larva recovered from the small intestine 23 days after infection with 8,000 P. equorum eggs. x 500

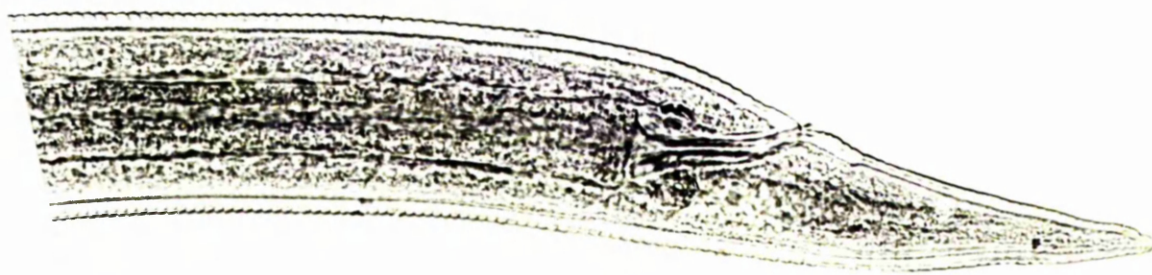


FIGURE 15: Tail of larva recovered from the small intestine 23 days after infection with 8,000 P. equorum eggs. x 300

(Figure 17). In fact 3,195 P. equorum were present, a take of 39.9%, which was slightly lower than that recorded on day 37, but the remaining worms had increased in size to a mean length of 74.28 mm.

Day 106: A further decrease in numbers to 751 (9.4% take) had occurred by day 106, with an increase in the mean parasite length to 105.38 mm. The total volume occupied by the worms recovered from the foal killed on day 106 was rather less than that of the worms recovered on day 73.

Day 146: A total of 123 ascarids, which varied in length from 135 mm to 175 mm, were present on day 146, a take of only 1.5%. The appearance of the small intestine containing these parasites before and after incision is shown in Figures 18 and 19.

The total parasitic recoveries from the small intestine on days 37, 73, 106 and 146 are shown in Figure 20. In terms of the volume occupied by the parasites in the small intestine, the largest recovery was on day 73, and subsequently there was a steady decrease in volume between days 73 and 146.

(4) Stomach

Stomach contents were examined on days 7, 14 and 23, but no parasites were found.

(5) Large Intestine

Thirty two large ascarids were present on day 73 and 4 on day 106. These worms were partially digested and therefore were not measured. Microscopical examination of the contents of the large bowel was negative on each occasion.

Recovery of Parasites from Faeces

The 2 animals from which 24 hour faecal collections were examined showed an intermittent elimination of parasites over a prolonged period. The first appearance of P. equorum in the faeces

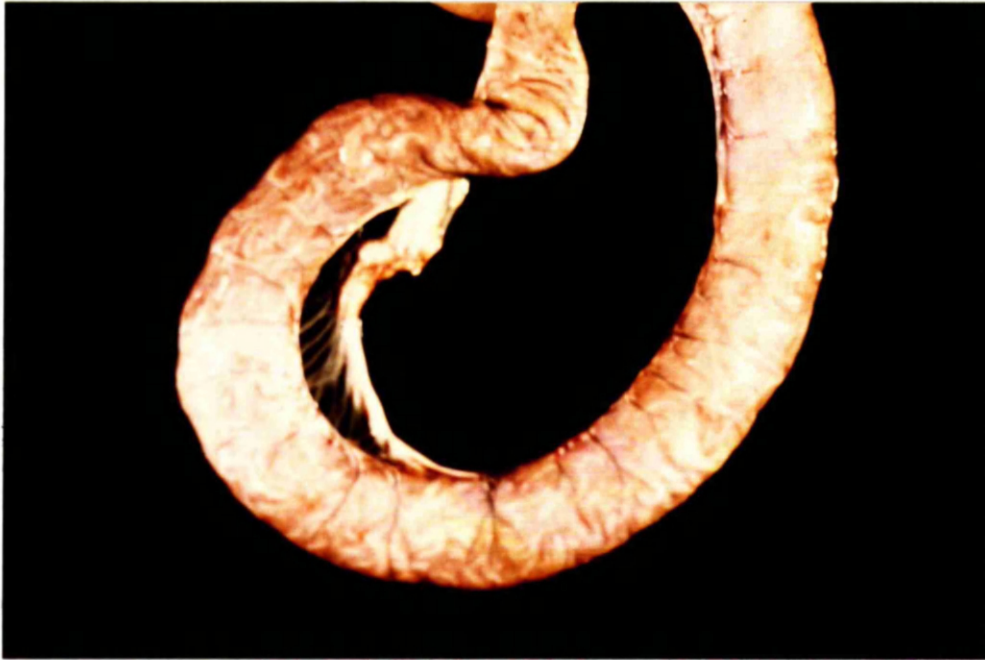

FIGURE 16: Parasites visible through the wall of the small intestine of a foal 73 days after infection with 8,000 P. equorum eggs.

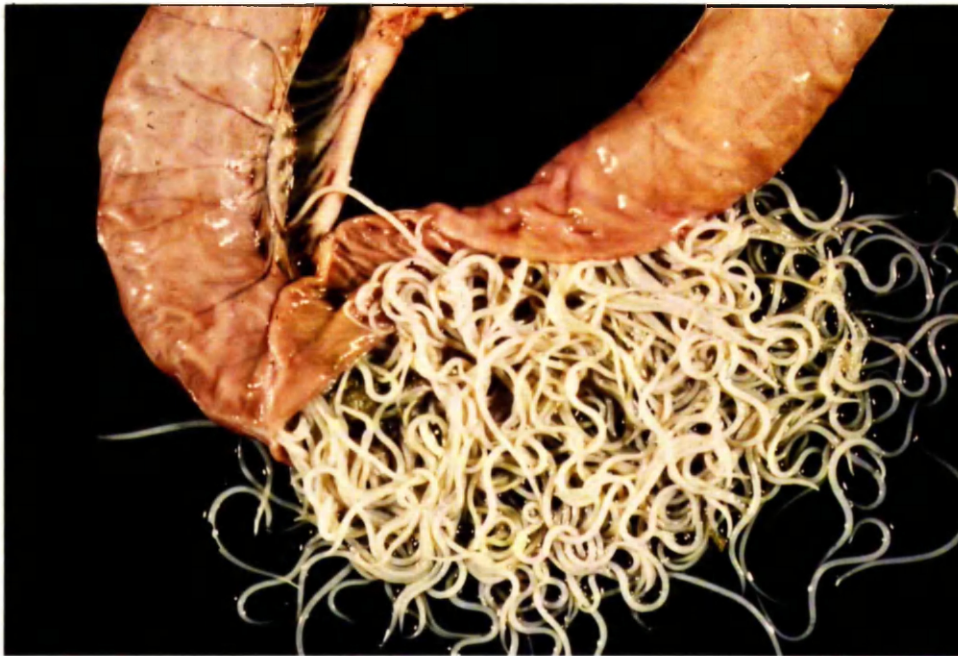

FIGURE 17: Small intestine of a foal opened to show parasites 73 days after infection with 8,000 P. equorum eggs.

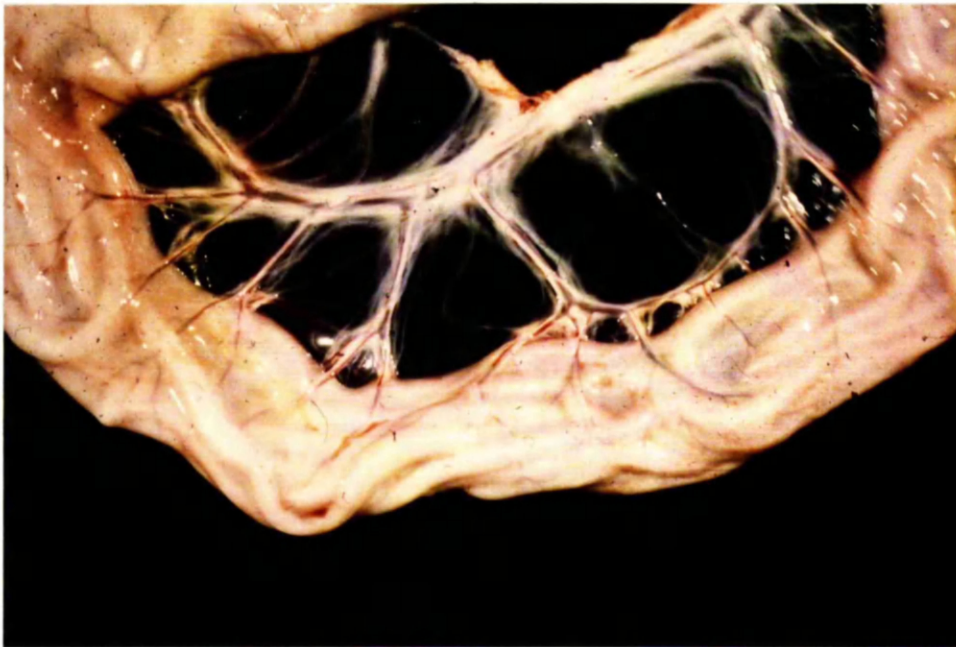


FIGURE 18: Parasites visible through the wall of the small intestine of a foal 146 days after infection with 8,000 P. equorum eggs.

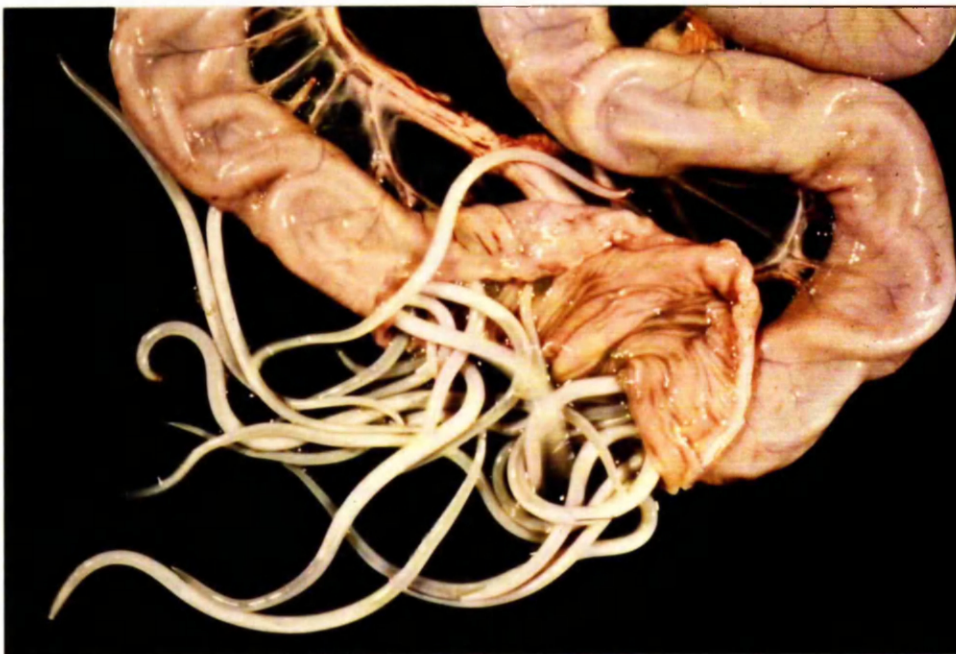

FIGURE 19: Small intestine of a foal opened to show parasites 146 days after infection with 8,000 P. equorum eggs.




FIGURE 20: Left to right, parasites recovered from the foals killed on days 37, 73, 106 and 146 after infection with 8,000 P. equorum eggs.

was recorded on day 45 in one animal (F7) and day 50 in the other (F6). Both foals were still excreting worms when they were killed on days 73 and 106. Although the worms were partially digested before elimination and could not be measured, it was obvious that, as the infection developed, the size of the worms expelled in the faeces increased.

Development of Patency

Patent infections developed in the 2 surviving foals on days 101 (F8) and 104 (F7), with counts of 150 asc. e.p.g. and 550 asc. e.p.g. respectively. One foal (F7) was killed on day 106 to determine the worm burden at this time (751 P. equorum). The pattern of the faecal egg count in the remaining foal is shown in Figure 21, which shows a marked variation in the values recorded from day to day, the highest count of 17,500 asc. e.p.g. being on day 124.

Examination of Tracheal Washings

In the foal examined endoscopically no larvae were present in the tracheal washings on days 14 or 15, but on day 16 a single P. equorum larva, 3.567 mm in length was found.

DISCUSSION

During this experiment, P. equorum larvae were recovered sequentially from the liver, lungs, airways and small intestine in sufficiently large numbers to indicate that this was the normal migratory pathway. Although the technique of mincing and baermannising a proportion of the hepatic and pulmonary tissue did not give an accurate quantitative estimation of the number of parasites present in the organ, it allowed a comparison to be made between the numbers of larvae recovered at specific times after infection.

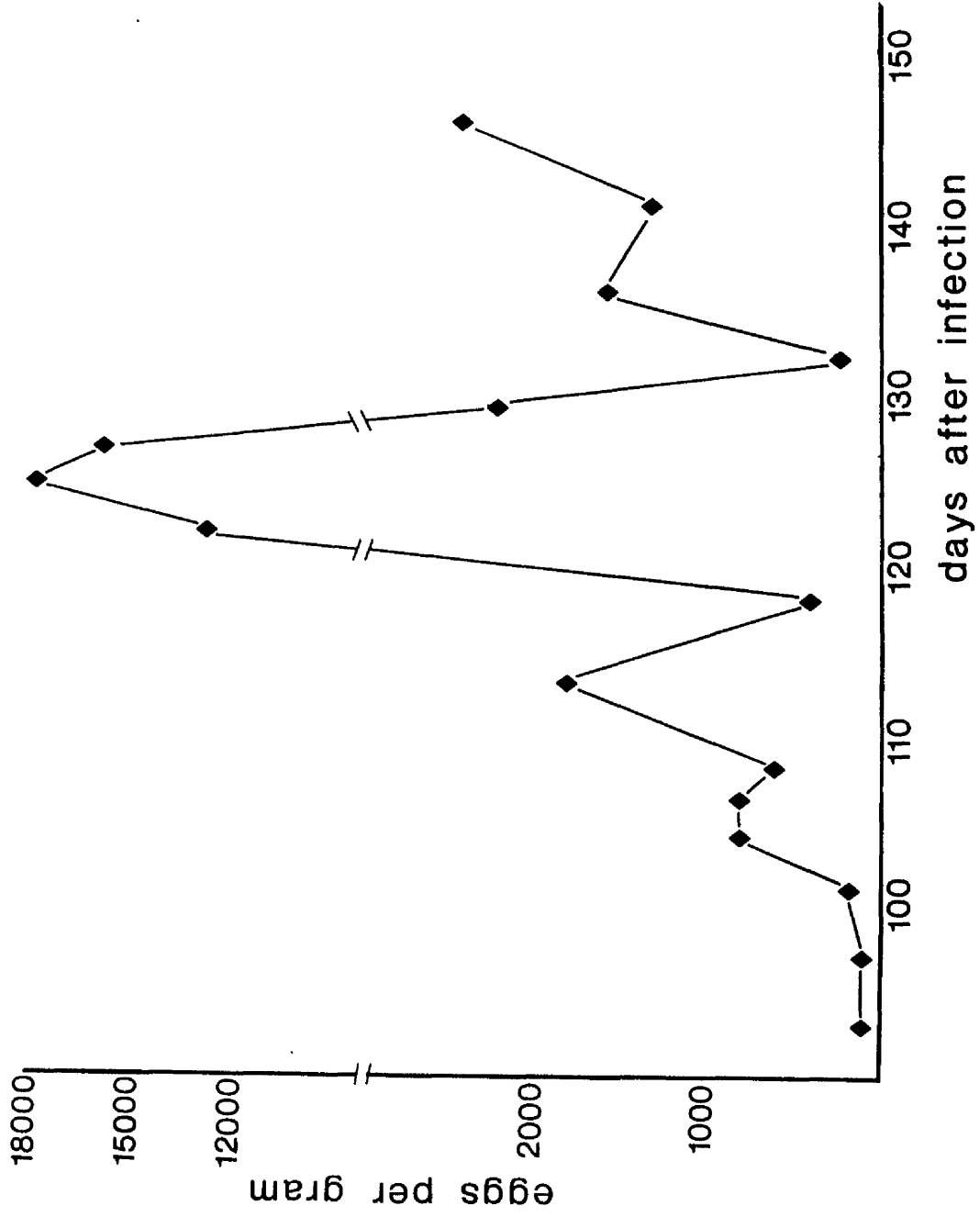


FIGURE 21: Faecal egg count of foal after infection with 8,000 *P. equorum* eggs.

Early investigations of the life cycle of Ascaris suum (Roberts, 1934) suggested that there were 2 parasitic moults in the lungs followed by one in the small intestine. However, later work by Douvres et al. (1969) on the morphogenesis and migration of A. suum, indicated that larvae reached the liver within 6 hours after ingestion of infective eggs by young pigs, and the first parasitic moult had taken place by 4 days. The larvae then migrated from the liver to the lungs between days 4 to 7, and returned to the small intestine from 8 to 10 days after infection. The same authors stated that the second parasitic moult occurred in the small intestine at 9 to 10 days, but they did not proceed to study the development beyond this stage.

Both Roberts (1934) and Douvres et al. (1969) believed that the infective stage of A. suum was the egg containing the ensheathed second stage larva and that there were 3 parasitic moults. Araujo (1972), however, examined the larvae of Ascaris lumbricoides, A. suum and Toxocara canis after incubating the eggs for 15 to 22 days in 1% aqueous formalin at 25°C. The eggs were hatched under pressure and the larvae examined using phase contrast and dark ground microscopy, when 2 distinct cuticles could be seen at the larval extremities. As a result of these findings Araujo (1972) suggested that there were 2 preparasitic moults, so the infective larvae were in the third stage. If this was the case then the moults observed in the liver and the small intestine by Douvres et al. (1969) were the third and final moults. Also the characteristics ascribed by these workers to the larvae after the intestinal moult would in fact be those of the young adult ascarid, not the fourth stage larva as had been assumed previously.

In this investigation of the migratory pathway of P. equorum no larvae were recovered from the foal killed on day 2, but the

presence of multiple haemorrhagic lesions on the surface of the liver suggested that parasitic invasion of this organ had already occurred. The failure to recover larvae at this time may have been due to the small size of the parasites in relation to the fairly large pieces of minced hepatic tissue. However, the liver was the only site in which P. equorum were found on day 7, when all the specimens were small and poorly differentiated. The stage of development was not determined and the possibility of the occurrence of a larval moult either in the intestinal submucosa or in the liver was not confirmed.

Specimens isolated from the lungs, airways and small intestine on day 14 were similar both in size and morphology and resembled those recovered from the liver at this time although the hepatic forms were considerably smaller. It was not possible to state whether a parasitic moult occurred in the lungs, but the morphological similarity between larvae found in the liver, lungs and small intestine on day 14, tended to suggest that they were all at the same stage of development.

Between days 14 and 23 the ascarids in the small intestine underwent a moult. The later larval stages were recognised by the fact that 3 prominent lips were demarcated from the head by a constriction, and the internal morphology was more distinct. The head resembled that of the larvae described by Douvres et al. (1969) as being the fourth stage, but the possibility that this description referred to the young adult has already been discussed.

Numerically, the largest recoveries from both the lungs and airways were on day 14, when the parasites had a size range of 1.653 to 2.436 mm. A small number of larvae, from 2.088 to 2.494 mm were present in the small intestine at this time. Similar results have been reported by other workers who have attempted to recover larvae following experimental P. equorum infections.

Hadwen (1925) found larvae approximately 2 mm long in the airways and duodenum of a foal which had been infected twice, 20 days and 7 days earlier, whereas Lyons et al. (1976) recovered larvae from the lungs but not the small intestine on day 14 and from both of these sites on day 17. The parasites described by Lyons et al. (1976) were in the size range of 1.4 to 2.7 mm on day 14, whereas by day 35 they ranged from 6.5 to 10.0 mm long.

At post-mortem examination the recovery of many larvae from the airways on day 14 was followed by an increase in the number of worms present in the small intestine on day 23 suggesting that parasitic migration from the lungs to the gastrointestinal tract was via the trachea. The recovery of an ascarid larva from the tracheal washings of a live foal 17 days after experimental P. equorum infection gave further support to the theory of a tracheo-oesophageal route of migration.

No larvae were found in the airways on day 23, which would seem to indicate that tracheal migration to the gastrointestinal tract had ceased. The larvae which remained in the pulmonary parenchyma at this time were remarkable for their uniformly small size (0.754 to 1.009 mm) compared with those found in the same site 9 days earlier (1.653 to 2.436 mm) and it is possible that the remaining larvae were the target of an immunological response leading to their destruction. Whatever the cause the larvae which die or are destroyed in the lungs are thought to form the basis of the lymphocytic nodules described in Chapter 1.

Following their return to the intestinal tract the ascarids increased rapidly in size. Between days 14 and 23 they doubled in length, and over the ensuing 14 days there was a fourfold increase in the mean parasite length. Even so, the worms recovered on day 37 did not cause any obstruction of the intestinal lumen. In the surviving foals the worms continued to increase in

size but decreased in number from the highest recovery of 4,150 ascarids on day 37 to only 123 ascarids on day 146. This fall in numbers was associated with the elimination of worms in the faeces from around day 45 onwards. Douvres et al. (1969) described an early elimination of ascarid larvae from the digestive tract of pigs with 10 to 15 day-old infections, which they related to the second parasitic moult, whilst Schwartz (1959) reported that, from 21 to 30 days after pigs ingested infective eggs of A. suum, larvae were eliminated on a "significant scale" and that this was associated with the final moult to the adult stage. It is possible that sensitisation to moulting fluid could lead to an expulsion of P. equorum during the final parasitic moult, the timing of which is uncertain.

Another factor which may influence the elimination of worms is overcrowding. The greatest mass of parasites was recovered from the foal killed on day 73 during the expulsive phase of the infection. In the animals killed subsequently, ascarids were not only less numerous but occupied a smaller total volume. It would seem that when large numbers of ascarids develop in the small intestine the resulting competition for space and nutrients is such that it is not possible for all the parasites to grow to maturity without causing an occlusion or indeed a rupture of the small intestine, a syndrome not frequently reported from the field.

The prepatent period of P. equorum is variable. In this experiment ascarid eggs first appeared in the faeces 101 and 104 days after infection, which is longer than the 80 days and 83 days recorded in Chapter 1. Other studies in worm-free foals have shown a similar range in the prepatent period including those of Bello et al. (1973), who found that 3 out of 10 ponies already had ascarid eggs in the faeces 84 days after infection, and the remainder became positive between days 91 and 105. Lyons et al. (1976) found prepatent periods

in the range of 72 to 110 days, and these workers described the subsequent faecal egg counts in 2 animals; a 5 month-old foal continued to excrete ascarid eggs for 119 days with counts of 50 to 430 asc. e.p.g. which was equivalent to a total daily output of 2,690 to 1,115,400 eggs, whereas in a one year-old animal the infection was patent for only 35 days with counts of 10 to 500 asc. e.p.g. In this experiment the faecal egg count of foal F8 was followed for 45 days, during which a maximum value of 17,500 asc. e.p.g. was found on day 124. This was equivalent to a total daily output of around 50 million ascarid eggs. There was, however, a marked variation in the daily faecal egg count, only 50 asc. e.p.g. being found on day 136, thus emphasising the limited value of faecal examinations as an estimate of worm burdens.

In her survey of Thoroughbred foals Russell (1948) found that every foal became infected with P. equorum and the ascarid faecal egg counts rose sharply to reach peak values at 16 to 18 weeks. The counts then declined steadily, many foals ceasing to pass eggs around 6 months of age. The average ages at which patent ascarid infections developed in foals reared naturally have been recorded as 84 to 91 days (Russell, 1948), and 77 to 98 days (Todd et al., 1949). This would seem to indicate that foals reared naturally become infected very soon after birth. In the experiment recorded here, although the foals were under one month of age at the time of infection, they had comparatively long prepatent periods of 101 and 104 days. In the preliminary experiment described in Chapter 1 foals aged 4 to 6 months developed patent infections on days 80 and 83 after infection with 160 eggs and 8,000 eggs respectively. It seems likely that the length of the prepatent period may be influenced both by the age of the foal and by the magnitude of the infection.

CONCLUSIONS

After a single infection of 8,000 P. equorum eggs larvae were found sequentially in the liver, the lungs and the small intestine in sufficient numbers to indicate that this was the normal migratory pathway. Two days after infection no larvae were recovered from the body organs, but the hepatic lesions suggested that penetration of the liver had already occurred. The only site from which parasites were recovered on day 7 was the liver but by day 14 the majority had moved on to the lungs and a small number were present in the small intestine. Between 14 and 23 days after infection most of the larvae returned to the gastrointestinal tract and the recovery of an ascarid larva from the tracheal washings of a foal 17 days after experimental infection gave support to the theory of a tracheo-oesophageal route of migration.

The larvae moulted within one week after reaching the predilection site in the cranial part of the small intestine, and were then easily recognised by the presence of 3 distinct lips at the anterior end. The young ascarids grew rapidly in size but the recoveries decreased in number after day 37 and this was associated with an expulsion of dead worms in the faeces.

Patent infections developed on days 101 and 104 with high faecal egg counts of up to 17,500 asc. e.p.g. in the surviving foal.

CHAPTER 3

THE PATHOGENESIS OF PARASCARIS EQUORUM INFECTION

SUMMARY

Eight worm-free pony foals, aged 2 to 4 weeks, received a single infection of 8,000 Parascaris equorum eggs and the clinical, haematological and biochemical changes were monitored. The foals were killed at intervals after infection to investigate the route of larval migration, which has been described in Chapter 2, and this was integrated with a study of the sequential, pathological changes.

Larval migration through the liver was associated with fibrosis and cellular infiltration around the portal triads, but clinical signs were not seen at this time and no evidence of hepatic dysfunction was found using the Normotest.

Two to 4 weeks after infection, a cough and a mucoid or purulent nasal discharge were present as the larvae migrated through the respiratory system and returned to the small intestine via the trachea. In the lungs there was a cellular infiltration around the small vessels and airways, composed initially of eosinophils but these were later replaced by lymphocytes. An additional feature on days 23 and 37 was the presence of multiple, subpleural, lymphocytic nodules, which resolved over a period of several months. A circulating eosinophilia occurred during the migratory phase of the infection and corresponded with the periods of hepatic and pulmonary eosinophilia.

During the later stages of the infection, from the third month onwards, the growth and development of a large number of ascarids in the intestinal lumen was accompanied by unthriftiness and lethargy, with a marked depression of the growth rate.

INTRODUCTION

The results of the preliminary experiment described in Chapter 1 provided some useful information on the clinical and haematological changes associated with P. equorum infections. It was considered necessary, however, to study these aspects of infection in a larger group of animals before the information could be correlated with the findings concerning the life cycle and migration of the parasite.

The experiment described in Chapter 2, which involved serial kills of a group of foals, was used in a detailed study of the clinical, haematological and sequential pathological changes following P. equorum infection. After evaluation of the data from this experiment (Experiment 1), a further study was designed in order to provide more information on the intestinal phase of the infection (Experiment 2).

EXPERIMENTAL DESIGN

(a) Experiment 1

The design of this experiment is shown in Table 8. In summary, 8 worm-free foals, aged 2 to 4 weeks, were killed at intervals of 2, 7, 14, 23, 37, 73, 106 and 146 days after a single infection of 8,000 P. equorum eggs. Two uninfected foals acted as controls for the clinical and haematological changes.

10 worm-free foals 2-4 weeks old	
8 foals	2 foals
8,000 <u>P. equorum</u> eggs	Uninfected controls
One foal killed on days 2, 7, 14, 23, 37, 73, 106 and 146 after infection	Not killed

TABLE 8 Experiment 1 - Design

(b) Experiment 2

A plan of this experiment is shown in Table 9. Six worm-free foals under one month of age were used. Four foals received a single infection of 8,000 P. equorum eggs, but the infection was allowed to develop to maturity in only 2 animals, which were killed 185 days after infection (Group A). The other 2 infected foals were treated each week with an ^{*}anthelmintic starting 4 weeks after infection (Group B). The anthelmintic chosen was known to be effective against ascarids present in the intestinal tract and it has been shown in Chapter 2 that the majority of P. equorum larvae returned to the intestine during the third and fourth weeks after infection. Therefore, in the foals in Group B, larval migration through the liver and lungs proceeded as usual, but the subsequent development in the small intestine was prohibited. The 2 remaining foals (Group C) acted as uninfected controls for the clinical and haematological changes.

The foals were weaned at 6 weeks of age.

* unmarketed ascaricidal drug

6 worm-free foals 2-4 weeks old		
2 foals	2 foals	2 foals
8,000 <u>P. equorum</u> eggs	8,000 <u>P. equorum</u> eggs	Uninfected controls
Maintained until the development of patent infections	Treated with anthelmintic at weekly intervals from 4 weeks after infection	-
Killed on day 185 after infection	Not killed	Not killed
GROUP A	GROUP B	GROUP C

TABLE 9 Experiment 2 - Design

SECTION I

CLINICAL SIGNS

MATERIALS AND METHODS

(a) Experiment 1

Clinical examinations were performed daily and when signs of respiratory disease developed special procedures were employed: thoracic radiographs were taken in the standing position 16, 24 and 31 days after infection, and endoscopic examination of the airways was performed under general anaesthesia on day 16. Also serum samples, collected during the respiratory illness and again 6 weeks later, were examined for the presence of a rising titre to the following viral pathogens of the equine respiratory tract: equine influenza (Prague strain), equine influenza (Miami strain), equine rhinovirus type 1, equine rhinopneumonitis and adenovirus.

Body weights were recorded at weekly intervals and routine faecal samples were examined twice weekly from day 40.

(b) Experiment 2

Body weights were recorded at weekly intervals from birth. Brief clinical examinations were performed daily, and faecal samples were examined twice weekly from day 40 for the presence of ascarid eggs.

RESULTS

(a) Experiment 1

Table 10 summarises the clinical changes.

Rectal Temperatures

These remained between 37.4°C and 38.9°C, which is within the normal range.

Animal Identification	Necropsy Days after infection	Patency day	Clinical Signs					
			Cough	Nasal Discharge	Anorexia	Loss of Condition	Depression	
Controls C1	-	-	-	-	-	-	-	
C2	-	-	-	-	-	-	-	
Infected Foals F1	2	-	-	-	-	-	-	
F2	7	-	-	-	-	-	-	
F3	14	-	-	-	-	-	-	
F4	23	-	13-18	17-23	-	-	-	
F5	37	-	13-15	8-22	-	-	-	
F6	73	-	15	-	-	60+	50+	
F7	106	104	14	15-24	-	60+	50+	
F8	146	101	13-41	16-41	-	60+	50+	

TABLE 10 Time (days after infection) of development of clinical signs following infection of foals with 8,000 P. equorum eggs.

Respiratory Signs

Two to 4 weeks after infection, the remaining 5 infected foals showed signs of respiratory disease. In each animal spontaneous bouts of coughing were first noted around day 13 and persisted for one to 5 days. During this time and for a few days after spontaneous coughing ceased, a cough could be induced by gently squeezing the trachea. A bilateral mucoid or purulent nasal discharge accompanied the cough and Figure 22 shows the typical white or greenish discharge which tended to become dried and crusted around the nostrils. The severity of the respiratory signs varied greatly between individuals, but in all cases the respiratory rate and character remained normal and there were no signs of systemic illness. One animal, F6, which had minimal respiratory signs coughed for one day only and did not develop a nasal discharge, while the most severely affected foal, F8, had both a cough and nasal discharge for over 3 weeks.

Serum samples taken during the respiratory illness and again 6 weeks later showed no evidence of a rising antibody titre to any of the common viral pathogens of the equine respiratory tract. The results of these investigations are shown in Table 11.

Endoscopic examination of foal F7 on day 16 revealed a copious amount of tracheo-bronchial exudate in the major airways (Figure 23), which looked glistening, white and frothy. Tracheal washings from this animal contained epithelial cells, bacteria, macrophages, masses of disintegrating neutrophils and occasional eosinophils, but parasitological examination of the washings was negative. No pus was present in the trachea of the control foal C1 and no cells were found in the tracheal washings from this animal.

No abnormalities of the pulmonary or bronchial areas were visible on thoracic radiographs of foals F7 or C1 on days 16, 24 or 31. Photographs of the X-ray plates obtained on day 16 are shown in Figures 24 and 25.



FIGURE 22: Typical muco-purulent nasal discharge 16 days after infection with 8,000 P. equorum eggs.

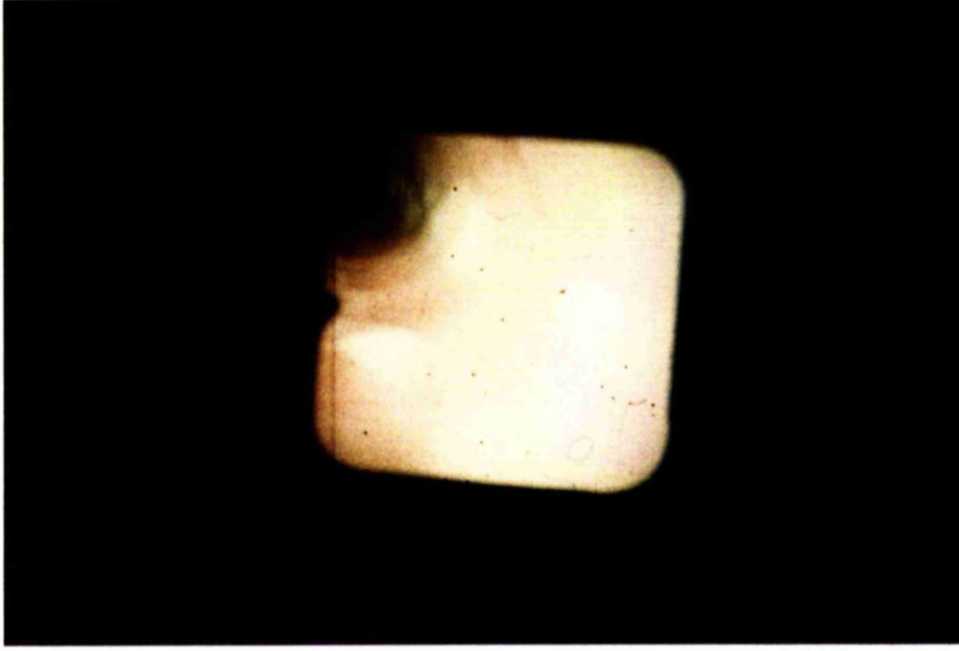


FIGURE 23: Endoscopic appearance of the trachea of a foal 16 days after infection with 8,000 P. equorum eggs showing copious tracheo-bronchial exudate.

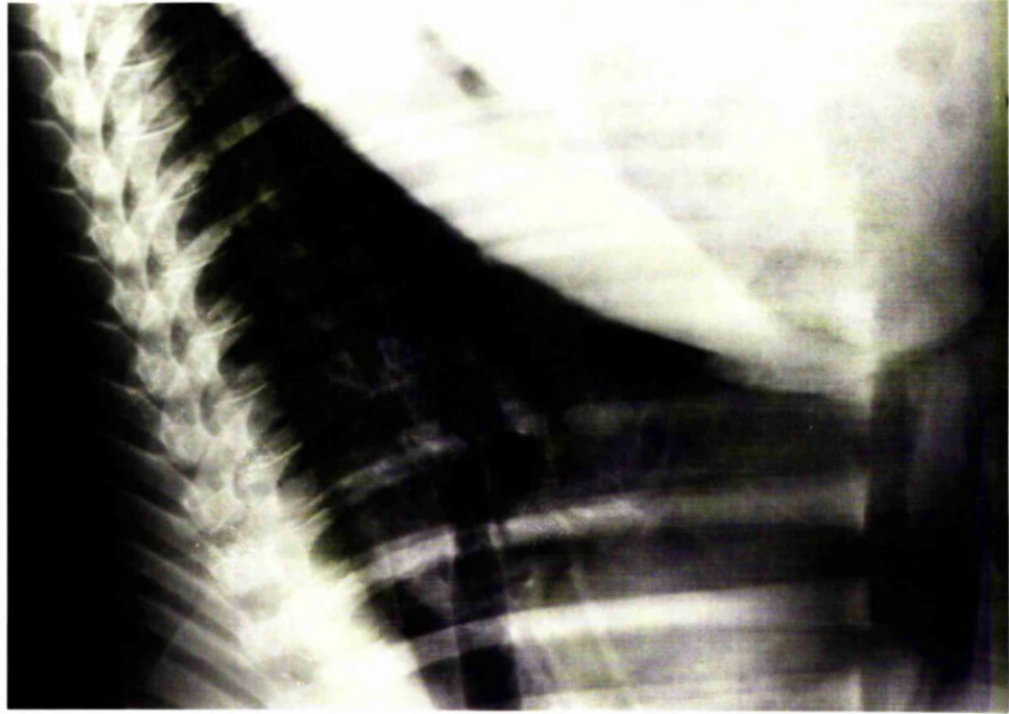


FIGURE 25: Thoracic radiograph of a foal 15 days after infection with 8,000 P. equorum eggs.

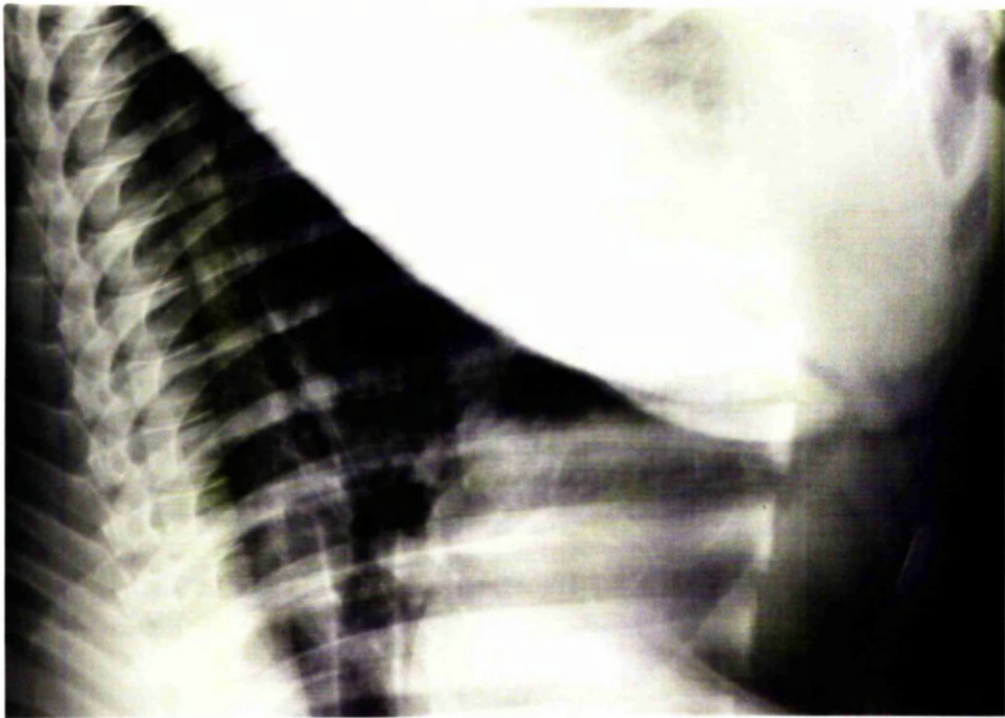


FIGURE 24: Thoracic radiograph of an uninfected foal.

	Days after Infection	Animal				
		F6	F7	F8	C1	C2
Equine influenza (Prague strain)	16	<8	<8	<8	<8	<8
	60	<8	<8	<8	<8	<8
Equine influenza (Miami strain)	16	<8	<8	<8	<8	<8
	60	<8	<8	<8	<8	<8
Equine rhinovirus Type 1	16	10	10	10	10	10
	60	10	10	10	10	10
Equine rhinopneumonitis	16	12	48	16		
	60	<8	32	<8		<8
Adenovirus	16	<8	24	<8	8	16
	60	<8	<8	<8	<8	<8

TABLE 11 Antibody titres of foals to respiratory viral pathogens following infection with 8,000 P. equorum eggs.

Body Weights

Clinically, loss of condition became obvious in the infected foals from around day 60 onwards, while the controls maintained good to fat bodily condition. Foal F6 showed a particularly rapid loss of condition before it was killed on day 73, and F7 and F8 were both very thin when killed on days 106 and 146.

The weight changes of the 2 controls and the 2 infected foals, which were maintained until the development of patency are represented graphically in Figure 26. All the foals suffered a setback after weaning, but within 30 days the controls had resumed their pre-weaning growth rates of 0.5 kg/day. During the late prepatent period, however, the mean weight gain of F7 and F8 was reduced to 0.17 kg/day. Over the entire prepatent period the increase in body

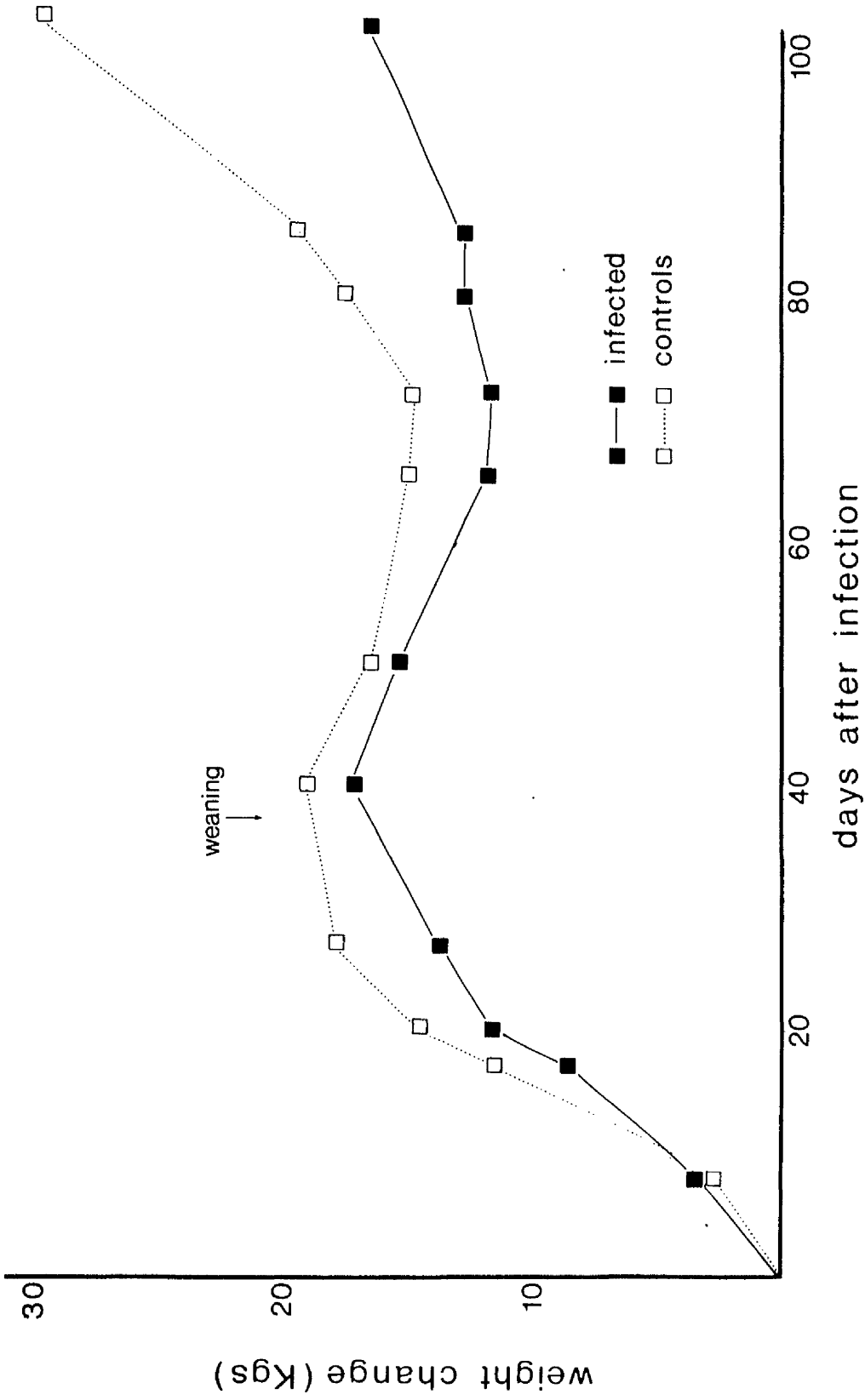


FIGURE 26: Changes in body weights of foals infected with 8,000 *P. equorum* eggs and uninfected controls (mean values).

weight of the infected foals was decreased by 50% compared with the controls. The clinical effect of these differences in growth rates are shown in Figures 27 and 28, and the complete body weight values are recorded in Appendix 6.

Other Clinical Signs

From day 50 onwards the infected foals became increasingly dull and lethargic, and spent long periods lying down. Inappetance was not a feature, however, and between periods of recumbency they ate hay or hard food. The controls, meanwhile, were bright and active.

There were no signs of intestinal disturbances such as colic or diarrhoea and nervous signs were not seen.

Development of Patency

Patent infections developed on days 101 and 104 in foals F8 and F7 respectively, and the faecal egg counts of these animals are recorded in Appendix 7 and have been discussed in Chapter 2. The faeces of the controls were consistently negative for parasite eggs.

(b) Experiment 2

The infected foals (Groups A and B) developed a spontaneous cough with a slight nasal discharge during the third week after infection; the controls were not affected.

Changes in body weights of the individual animals are shown in Figure 29 and, as in Experiment 1, all the foals showed a setback and failed to gain weight for about 30 days after weaning. The uninfected controls (Group C) gained 44 kg and 50 kg over the experimental period of 185 days, while the infected but treated foals (Group B) gained 48 kg and 54 kg. All of these animals maintained good condition and had negative faecal samples.

One of the infected, untreated foals (Group A) maintained good

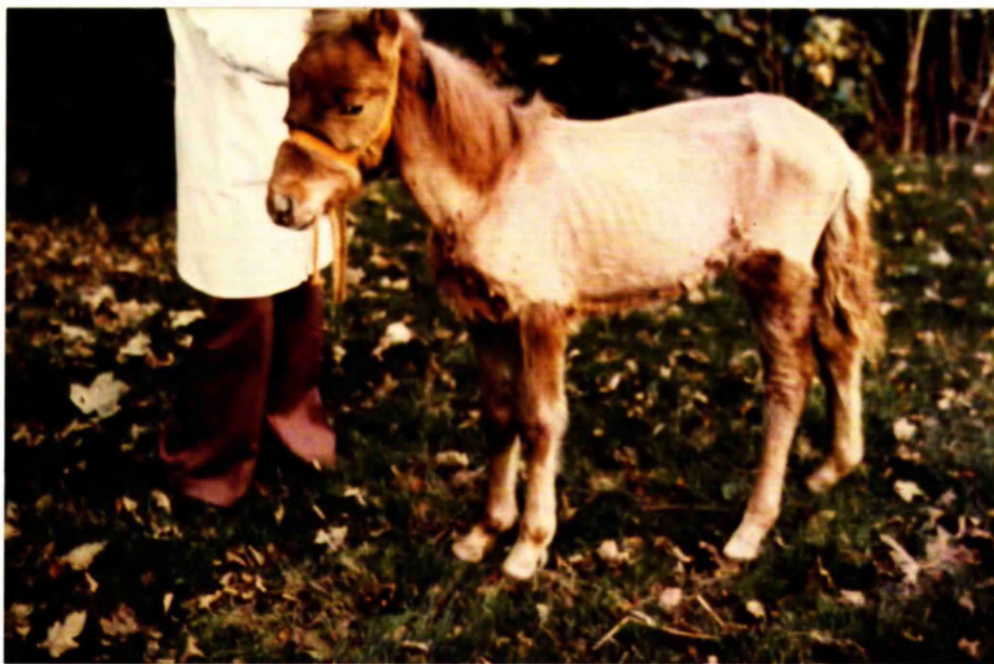

FIGURE 27: Foal clipped to show poor bodily condition 146 days after infection with 8,000 P. equorum eggs.

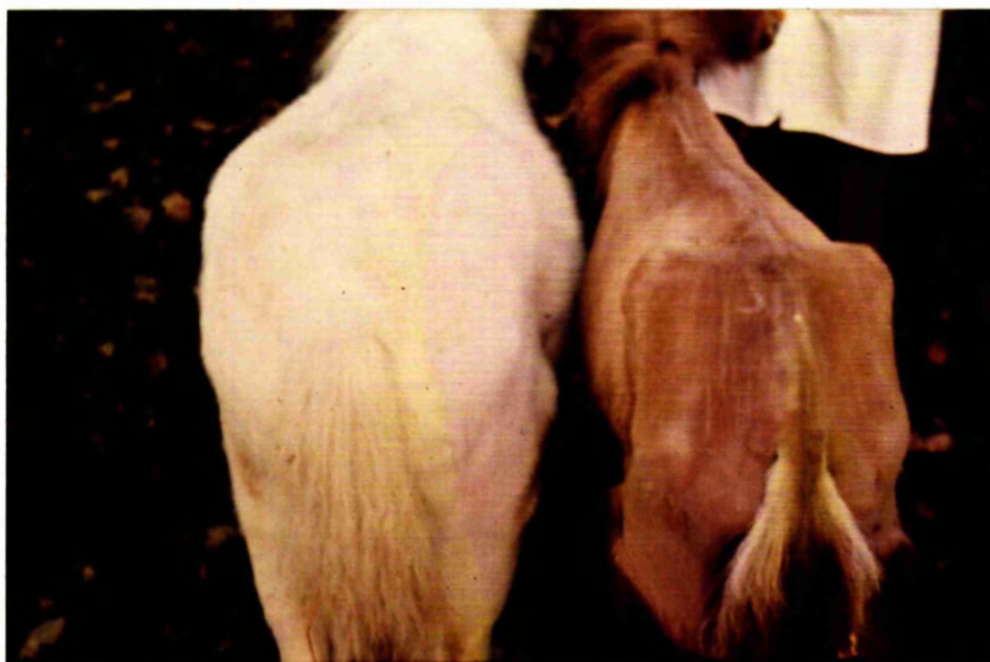

FIGURE 28: Bodily condition of a foal 146 days after infection with 8,000 P. equorum eggs (right, clipped) compared with uninfected control (left, unclipped.)

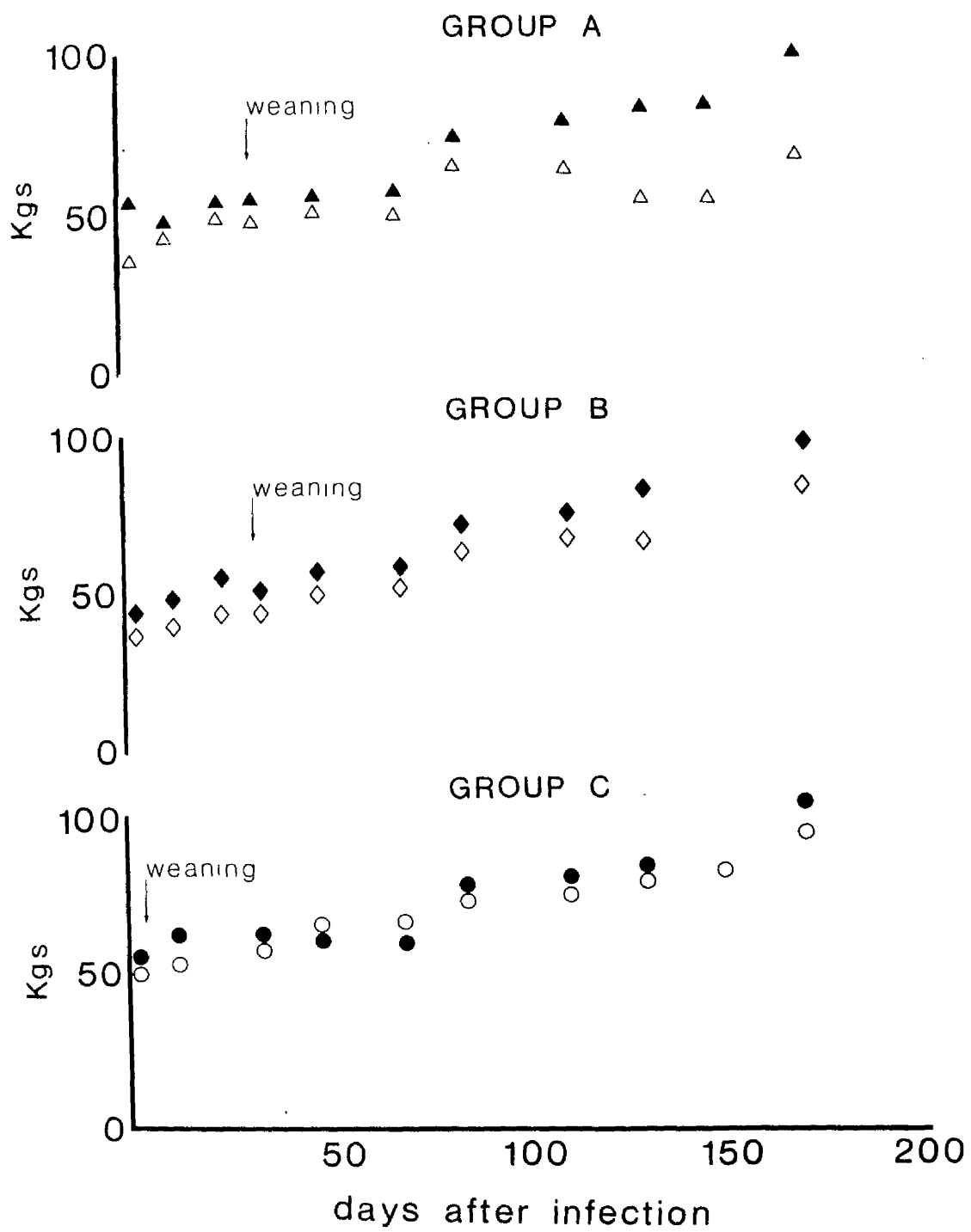


FIGURE 29 Changes in body weights of foals:
 Group A - infected with 8,000 P. equorum eggs.
 Group B - infected with 8,000 P. equorum eggs and subsequently treated weekly with an anthelmintic.
 Group C - uninfected controls.

condition putting on 52 Kg weight during the experiment. This animal had a positive faecal egg count of 50 asc. e.p.g. on day 82 only, and at post-mortem examination a single P. equorum measuring 22 mm was found. The other foal in Group A became progressively weak and emaciated, and gained only 34 kg body weight. In this case a patent infection developed on day 81 and the faecal egg count rose to a peak value of 6,350 asc. e.p.g. on day 130, then declined to around 500 asc. e.p.g. by day 160. A patent infection was maintained, however, until the foal was killed on day 185, when a total of 33 mature P. equorum with a size range of 148 mm to 233 mm were present. The timing of the increase in faecal egg count is superimposed upon the changes in body weight in Figure 30, showing that while the output of ascarid eggs was maintained at a high level the foal was actually losing weight, but as the faecal egg output declined so the body weight began to increase.

DISCUSSION

A study of the literature shows that a wide variety of clinical signs have been attributed to parascariasis, but most of these observations have been based either on field cases or on experimental P. equorum infections superimposed on a natural helminth burden. While this information from the field provides a valuable addition to the knowledge of a disease and its epidemiology, to be of real significance it should be backed up by laboratory results to confirm the diagnosis. Under field conditions the animals are exposed to a spectrum of pathogenic agents, parasitic, bacterial, viral and fungal in origin, all of which may contribute to the final disease picture.

Antipin and Stepanova (1948) studied the clinical aspects of parascariasis by giving massive infections of P. equorum to a total

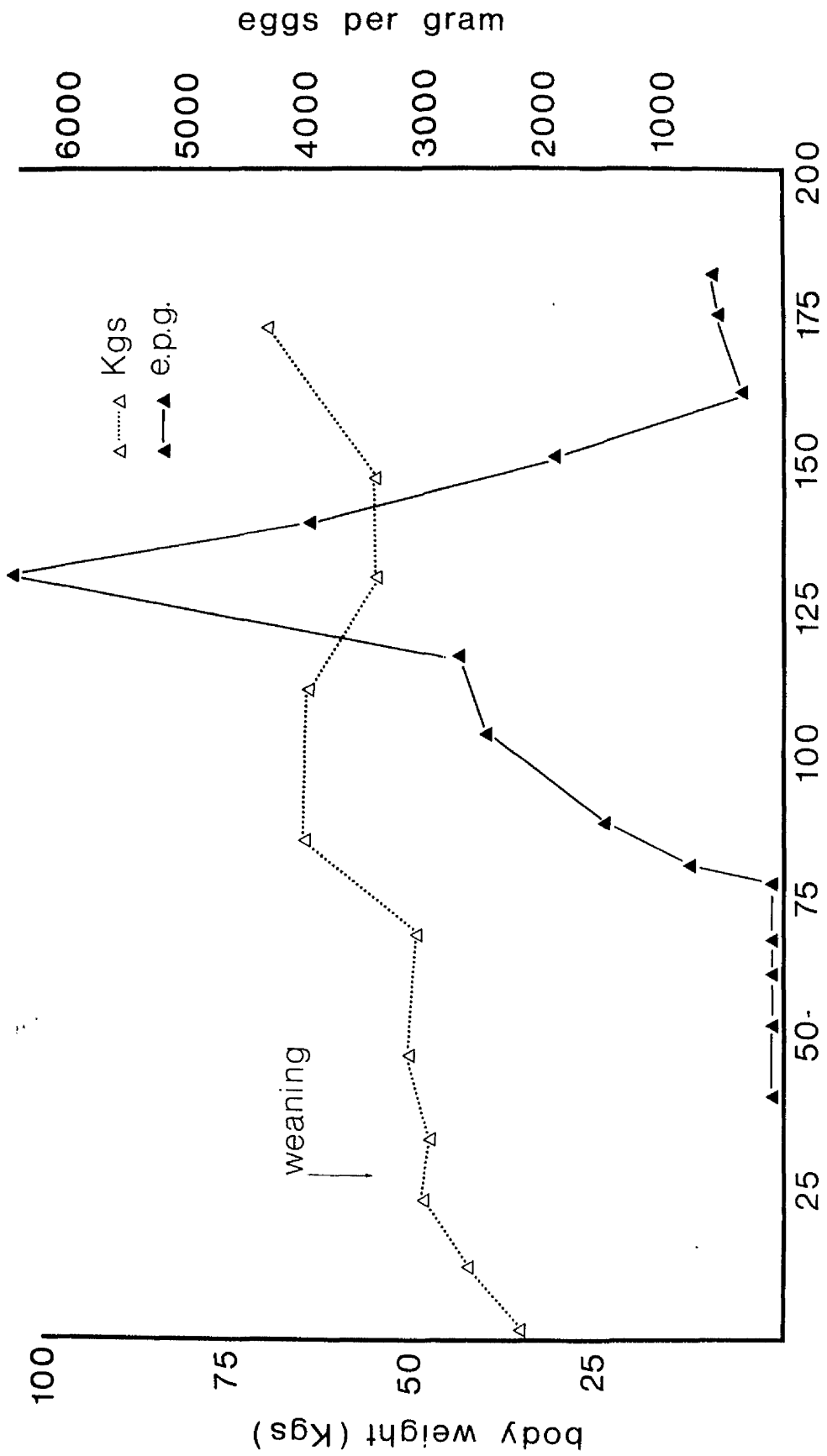


FIGURE 30 Changes in body weight and faecal egg count of a foal after infection with 8,000 P. equorum eggs.

of 7 animals which included both foals and mature horses. During the experimental period one of the infected animals had a chronic cough due to pulmonary emphysema, a second had strangles and a third developed a large abscess with systemic illness. In their control group of 4, two began to excrete ascarid eggs during the trial and a third died of unrelated causes. Thus, although Antipin and Stepanova (1948) made many pertinent observations, the value of their work was limited by the facilities available at that time. The same criticism may be applied to the studies of Hadwen (1925), who made no mention of controls and did not describe the conditions under which his 3 experimental foals were maintained.

The only large-scale studies of experimental ascarid infections of worm-free foals maintained under controlled conditions are those of Bello et al. (1973) and Lyons et al. (1976). Both of these groups of workers, however, were concerned primarily with the efficacy of various anthelmintics against P. equorum, and their descriptions of the clinical aspects of the disease were limited. A much earlier paper (Welzel and Enigk, 1938) recorded the clinical signs that followed ascarid infection of a single worm-free donkey foal.

In the series described here none of the foals died, but there are several reports in the literature of deaths due to intestinal impaction by masses of P. equorum with or without subsequent rupture and peritonitis. Drudge and Lyons (1977), in a review of the pathogenicity of the common internal parasites of the horse, stated that the primary danger in parascariasis was rupture of the small intestine resulting in fatal peritonitis. In their opinion this complication was not necessarily related to the number of worms except that "more than a few are required and a large number would be more likely to cause a rupture." These authors also noted a seasonal incidence with deaths in the autumn and early winter, which

fits in with the breeding season of the horse and the prepatent period of the parasite. Bello et al. (1937) reported that 2 out of 5 foals died of intestinal impaction following a monospecific infection of 5,000 P. equorum eggs, and at post-mortem examination, 582 and 1,118 P. equorum were found in their intestinal tracts.

Several clinicians have recorded one or more fatalities attributable to parascariasis. Wiltshire (1954) recalled at least one death each year due to intestinal obstruction, whilst Lang (1948) reported 3 cases of massive fatal ascarid infections in yearlings. Rylands (1971) and Orr (1972) each recorded a single case of rupture of the small intestine. In Ryland's (1971) report a 10 month-old colt died after an acute illness lasting less than 12 hours. At necropsy examination a hole, 1 cm in diameter and plugged with adult P. equorum, was found in the wall of the small intestine, while the lumen at this point was packed with ascarids. Orr (1972) described the case of a 4 month-old colt which died within 24 hours of the onset of clinical signs. Post-mortem examination in this case revealed a perforated duodenal ulcer, with one ascarid in the peritoneal cavity and 3 in the stomach. It was the author's opinion that the action of these worms had resulted in the perforation.

A rather unusual case of ascarid penetration through the intestinal wall was given by Lebailly and Cadillac (1957), who described the clinical and post-mortem findings in a 15 year-old horse. Animals of this age are rarely affected by parascariasis, but in this case one specimen was found encysted in the mesentery and another was attached to the parietal peritoneum. It was supposed that rupture was due to the direct action of the parasites, but it is possible that the rupture resulted from some undiagnosed and unrelated cause. In their discussion of parascariasis, Lebailly and Cadillac (1957) cited another worker Carpentier (1939) who was said to have

seen 23 cases of intestinal rupture in horses due to P. equorum probably the largest series of such cases.

Respiratory disease has often been associated with parascariasis but Drudge and Lyons (1977) made the point that experimental evidence in support of this theory was lacking and, indeed, they felt that ascarid larvae had been unjustly blamed as a cause of coughing in foals. In addition, Lyons et al. (1973) saw no evidence of pathogenic effects due to larval migration through the body tissues. However, in the 2 experiments described here the infected foals developed a cough and nasal discharge during the third week after infection, whilst controls in the same air-space were free of clinical signs. The timing of the respiratory disease corresponded to the period of larval migration from the lungs to the gastrointestinal tract and it would seem reasonable to assume that the pulmonary migration of P. equorum was at least partially responsible for the development of the respiratory signs.

The findings of other workers have suggested a relationship between ascarid infection and the development of respiratory disease. The donkey foal, which was experimentally infected by Wetzel and Enigk (1938), received 2 doses of 100 P. equorum eggs on alternate days and was seen to cough sporadically between the tenth and eighteenth days after infection. Similarly both Hadwen (1925) and Antipin and Stepanova (1948) recorded the presence of a cough during the early prepatent period following massive P. equorum challenge of foals with pre-existing natural infections. Indeed the investigations of Hadwen (1925) were prompted by an outbreak of ascariasis in young foals at the University Farm in Saskatoon, where 3 animals died and the remainder suffered from 'colds'. The diagnosis in this instance was based upon the expulsion of large numbers of ascarids following anthelmintic treatment, but this was insufficient evidence to

establish a "cause and effect" relationship, since most foals of this age would be expected to carry significant ascarid burdens.

Wiltshire (1954) noted, in retrospect, that some of the foals which died of intestinal obstruction by ascarids had shown earlier symptoms of lung damage and, according to Russell (1948), the presence of a cough and sticky nasal discharge at weaning time was often attributed to ascariasis by the owners.

Apart from the presence of a cough and nasal discharge during the early stages of infection, the most obvious clinical signs of parascariasis, in the studies described here, were progressive emaciation with increasing weakness and lethargy. Four out of 5 foals infected with 8,000 P. equorum eggs had poor growth rates and loss of condition became an obvious feature from about day 60 onwards, whereas infected foals treated with an anthelmintic after larval migration through the liver and lungs had normal growth rates. In Chapter 2 it was shown that the ascarids found in the small intestine on day 37 occupied a small volume only, but by day 73, although the number of parasites had decreased, their volume had increased enormously. Therefore, it would seem that progressive unthriftiness was associated with the presence of a large mass of P. equorum in the small intestine. Inappetance was not an obvious feature, but the unthrifty foals spent increased periods of time lying down, so that food intakes may have been reduced in these animals.

The one infected, untreated foal which had a growth rate comparable to the controls did not have a heavy intestinal burden of ascarids, only one parasite being recovered at necropsy examination. This finding supported the theory that unthriftiness depended upon the presence of a heavy ascarid burden in the intestinal lumen, although it raised another interesting question in

that the reason for the failure of parasites to become established in this animal was not known.

Bello et al. (1973) recorded increasing weakness in 8 out of 10 foals as infections of 3,000 P. equorum eggs became patent and developed. Five foals, including one which maintained normal condition, were subsequently treated with an anthelmintic, so that intestinal worm burdens were not determined in these animals. An average of 559 ascarids were recovered at necropsy from the 5 untreated foals, and it is significant that the one which was unaffected clinically had only 56 ascarids, a much smaller number than the unthrifty foals in the group. The failure of Lyons et al. (1976) to mention the physical condition of their experimental foals may have been due to the fact that none of these animals was maintained beyond 49 days, and obvious debility would not have been expected at this time.

Progressive loss of condition and a pot-bellied appearance were noted after infection of young foals by Antipin and Stepanova (1948), whereas animals which were over 5 months of age at the time of challenge were not affected in this way. Chebotar'ov (1950) was of the opinion that parascariasis was responsible for wasting and a decrease in working capacity, which presumably referred to mature horses, and finally Wiltshire (1954), from his observations of naturally reared foals, was in no doubt that ascariasis was a debilitating disease.

In the pig the development of clinical signs is usually confined to the early stages of ascarid infection and Taffs (1969) described the development of coughing, unthriftiness and loss of weight in this species, a syndrome almost identical to that described in foals. Kelley, Olsen and Hoerlein (1958) also recorded respiratory dysfunction 6 to 12 days after ascarid infection of

piglets. Nickel (1960) studied the weight gains of fattening pigs following experimental A. suum infection and found that the migratory larval stages but not the presence of mature worms caused a decrease in the daily weight gains.

Pyrexia was not a feature of the P. equorum infections presented here although rectal temperatures were taken daily during the experimental period. However, several authors, including Hadwen (1925), Antipin and Stepanova (1948) and Ryazantsev (1956), have recorded fever at intervals varying from one day to several months after P. equorum challenge. The timing of the febrile episodes showed no consistent pattern and may have been due to causes unrelated to parasitism, since all foals are exposed to a multitude of pathogenic agents, most of which can induce a mild pyrexia in the non-immune animal. The effect of P. equorum in this respect is probably less significant than early workers believed.

Other clinical signs sometimes attributed to P. equorum infection include colic (Antipin and Stepanova, 1948; Ryazantsev, 1956) and nervous disturbances or fits (McBarron, 1948), but again it is speculative whether or not these signs were in fact associated with ascariasis. For instance the description given by McBarron (1948) of a horse "simulating an epileptiform seizure" involved an acute illness with tachycardia, hyperpnoea and pain in the diaphragmatic region. The horse died the same day and at post-mortem examination was found to have peritonitis with numerous ascarids in the intestinal lumen but no mention was made of a perforation of the small intestine. When presented with another horse prone to similar "fits" and with a high ascarid faecal egg count, McBarron (1948) administered anthelmintic treatment, numerous ascarids were expelled and no further "fits" occurred in the ensuing 18 months.

In conclusion it may be stated that the early stages of P. equorum infection are often accompanied by a cough and nasal discharge, though the aetiology of the respiratory disease may be complex. When a heavy ascarid burden is present the later stages of the disease are marked by unthriftiness and lethargy, although larval migration through the liver and lungs does not appear to cause any permanent dysfunction. These were the only clinical changes observed in experimental P. equorum infections in worm-free foals.

SECTION II

(1) PATHOLOGY

MATERIALS AND METHODS

All the foals were killed using a humane killer and routine post-mortem examinations performed. In each case tissue blocks for histological examination were taken from the liver, the lungs and the small intestine. The blocks were selected both from areas which were apparently normal and from areas showing macroscopic lesions. The fixation and staining procedures have been described in an earlier section.

PATHOLOGY OF THE LIVER

RESULTS

A range of macroscopic and microscopic lesions were detected in the foals killed at varying intervals after infection.

Day 2

In the foal killed 2 days after infection the outstanding change was the presence of small (less than 1 mm diameter), focal, red spots on the surface of the liver. These lesions were scattered over all surfaces, particularly the visceral surface.

On microscopical examination irregular, narrow tracts were present throughout the liver. These were congested and infiltrated by small numbers of mononuclear cells and eosinophils, with a few neutrophils and macrophages. The tracts were most obvious beneath the capsule (Figure 31), extending into the liver along the interlobular septae and they were also numerous in the interlobular tissue between adjacent portal triads (Figure 32). Haemorrhage and



FIGURE 31: Infiltration by eosinophils beneath the capsule of the liver of a foal 14 days after infection with 8,000 P. equorum eggs. x 110.

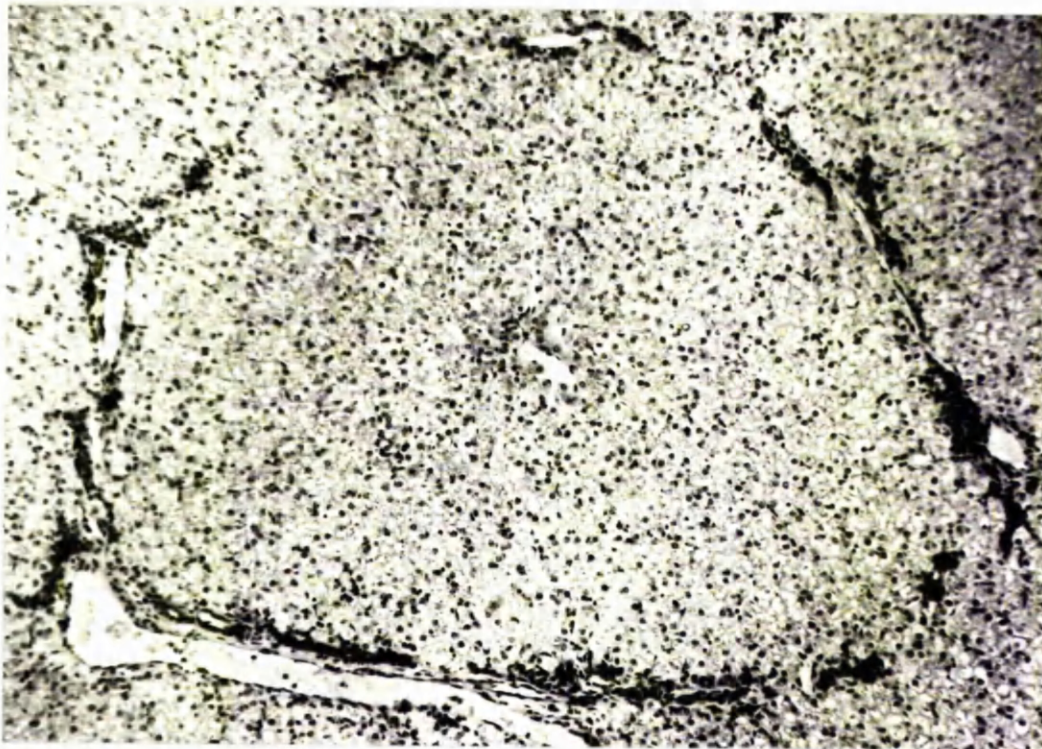


FIGURE 32: Infiltration by eosinophils in the interlobular tissue of the liver of a foal 14 days after infection with 8,000 P. equorum eggs. x 85.

necrosis of the hepatocytes was minimal, although some haemosiderin-containing macrophages were seen.

Day 7 and Day 14

The focal, red spots described above had decreased in number by day 7 and on day 14 very few remained. The most obvious feature, however, was the presence of small, white lesions, divisible morphologically into two types. Some were rather diffuse and irregular in shape, while others were more discreet and rounded (Figure 33). They were found both on the liver surface and within the parenchyma, and the rounded lesions on the surface took the form of raised, subcapsular nodules (Figure 33). Only a few of these white lesions were present on day 7, but there had been a marked increase in number by day 14.

Microscopical examination showed a cellular infiltration consisting mainly of lymphocytes and eosinophils, but the proportions of these two cells varied between different areas in a single section. When eosinophils were present in large numbers the lesions tended to be rather diffuse and irregular in outline, whereas when lymphocytes predominated the lesions were more discreet and rounded.

Days 23 and 37

The focal, red spots were no longer present but small numbers of white, rounded or irregular lesions were present in the livers of the foals killed 23 and 37 days after infection and on day 23 a few white, fibrous tracts were seen on the visceral surface. Macroscopically the fibrous reaction was less marked by day 37, but on sectioning the liver it gave the impression of being firmer than usual.

Histological examination confirmed the presence of a fibrotic reaction on days 23 and 37, when fibrous tissue was found primarily

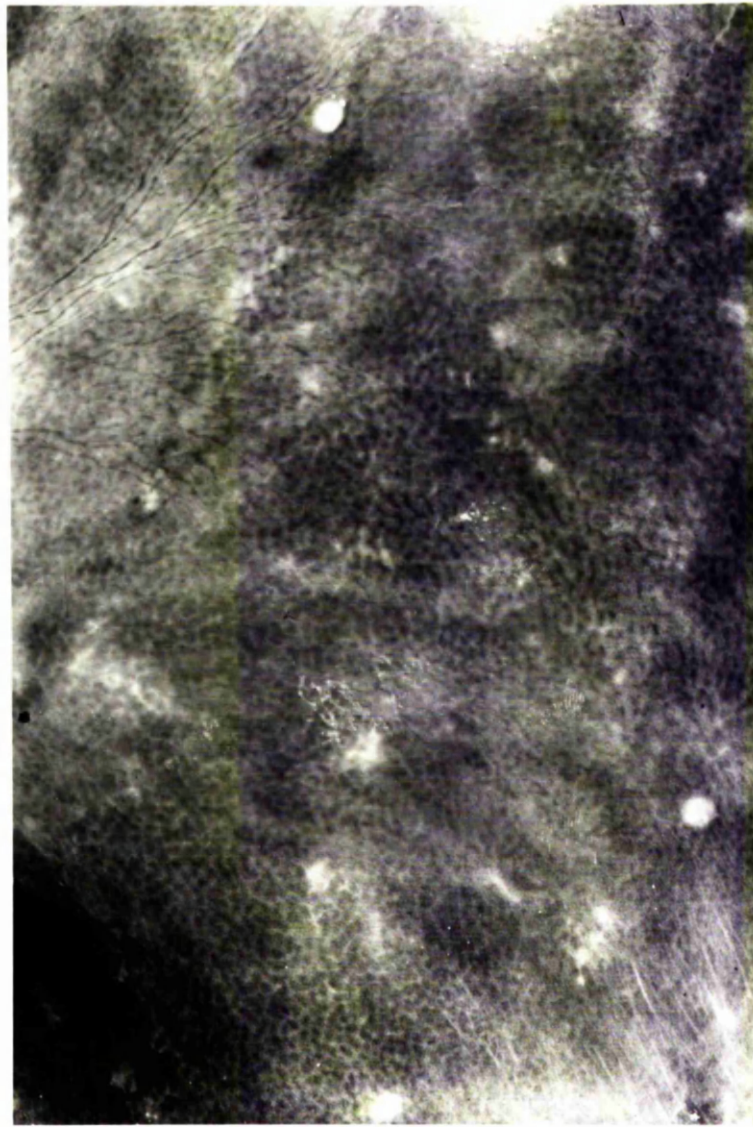


FIGURE 33 The surface of the liver of a foal 14 days after infection with 8,000 P. equorum eggs showing diffuse, irregular, white lesions and raised, subcapsular nodules.

around the portal triads and extending between the hepatic lobules. The amount of fibrosis was variable even between different areas of a single section and, although sometimes associated with cellular infiltration, quite extensive fibrosis was often present in the absence of a cellular reaction (Figure 34). The infiltration was prominent around the portal triads and again consisted mainly of lymphocytes and eosinophils together with some plasma cells and mast cells. The cellular reaction was particularly marked around interlobular branches of the portal vein and thrombosis was occasionally seen (Figure 35).

Days 73, 106 and 146

By 73 days after infection a few, white spots remained but the fibrous reaction, which had been a feature on day 37 was no longer evident on macroscopic examination. On days 106 and 146 one or two rounded nodules were still present on the liver surface.

The histological changes were essentially similar to, but less marked than those seen on day 37, with fibrosis and cellular infiltration around the portal triads.

DISCUSSION

The recovery of P. equorum larvae from the body organs has been described in Chapter 2. Using a technique of mincing and baermannising the tissue no larvae were recovered from the liver 2 days after infection but the presence of numerous haemorrhages suggested that penetration had already occurred. This was supported by the histological appearance of the organ with irregular, narrow tracts infiltrated by mononuclear cells and eosinophils. The liver was the only organ from which parasites were recovered on day 7,

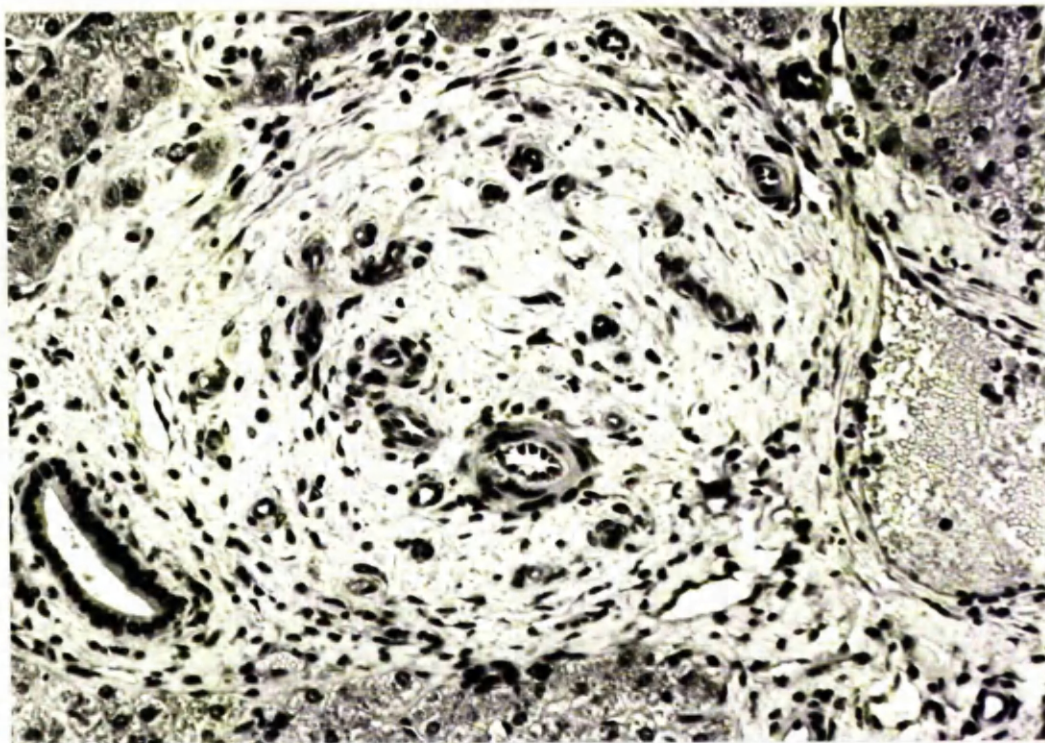


FIGURE 34: Fibrous tissue reaction in a portal triad of a foal 23 days after infection with 8,000 *P. equorum* eggs. x 250.

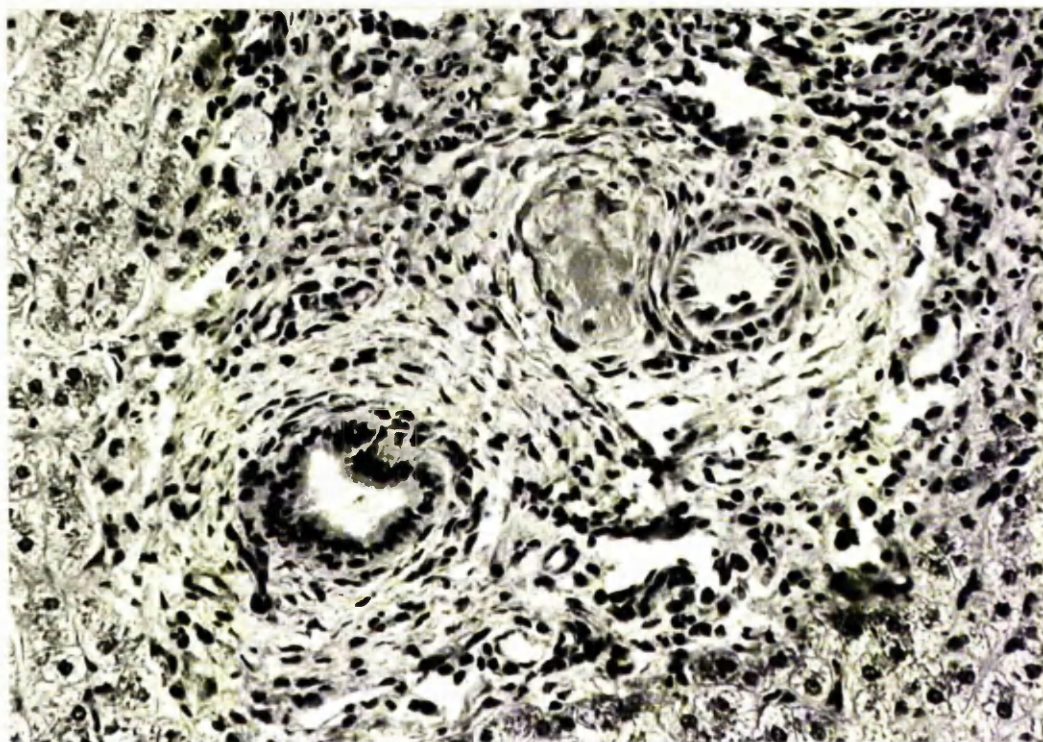


FIGURE 35: Reaction in a portal triad of a foal 23 days after infection with 8,000 *P. equorum* eggs. There is infiltration by eosinophils and thrombosis of a small branch of the portal vein. x 250.

but by day 14 the majority had moved on to the lungs. No larvae were found in the liver on subsequent occasions.

An early description of the hepatic changes following ascarid infection of foals was given by Hadwen (1925) who administered massive challenge infections of P. equorum, superimposed on an undetermined naturally acquired helminth burden. In a 4 month-old foal infected twice, 54 days and 33 days before necropsy examination, he described a granular degeneration of the hepatocytes with accumulations of eosinophils under the liver capsule and around the vessels. Hadwen (1925) believed that this distribution of eosinophils indicated that the larvae migrated in the connective tissue around the vessels.

Two other helminth parasites of the horse, which include a period of hepatic migration in their life-cycles, are the large strongyles, Strongylus equinus and Strongylus edentatus. The larvae of S. equinus migrate through the liver capsule causing a haemorrhagic, fibrinous inflammation of the capsule, then penetrate the ducts, which heal with considerable scarring (Enigk, 1970). In the case of S. edentatus the larvae reach the liver via the portal circulation and, according to McCraw and Slocombe (1974), within 2 to 4 days after infection small, white foci appear on the surface. These are similar in nature and distribution to the lesions seen in the present study during P. equorum migration, but differ slightly in the time of appearance and the extent of the cellular reaction, which was apparently more marked in S. edentatus infection. As the strongyle infection progressed McCraw and Slocombe (1974) noted that some hepatic foci had a "core" of necrotic eosinophils enclosing remnants of a larva, but lesions of this type were not seen in the present study of P. equorum infection.

Ascaris suum infection in the pig has been the subject of much research and the pathological change most commonly described in this species is the "milk spot" lesion, which was considered to be a chronic, focal, interstitial hepatitis (Oldham and White, 1944). From their studies of single and repeated A. suum infections of specific pathogen free piglets, Ferguson, Mebus and Twiehaus (1968) formed the opinion that the milk spot lesion was a hypersensitivity reaction. Copeman (1971) described 2 distinct types of hepatic lesions in experimentally infected pigs; firstly, diffuse, white areas composed of thickened capsular connective tissue, which developed after both primary and challenge infections, and secondly, discrete nodules, which were present only after reinfection. According to Nieberle and Cohrs (1967) nematode larvae may be arrested in the liver sinusoids, where the dead larva acts as a foreign body leading to the development of an inflammatory focus, visible grossly as a circumscribed, greyish-white nodule. These authors stated that it was possible to recognise parasitic material in the fresh nodules, but in older foci the larva disintegrated and was no longer visible. It would seem, therefore, that the development of discrete, circumscribed nodules in the liver is a non-specific reaction to the presence of a foreign body. In the experiment described here it is probable that the antigenic material was a dead ascarid larva, although larval remnants were not recognised in the sections examined.

(2) PATHOLOGY OF THE LUNGS

RESULTS

Lesions of several, distinct types were found, but not all of these were attributed to P. equorum invasion of the lungs. The pulmonary pathology thought to be associated with the migration of P. equorum will be described first.

Day 2 and Day 7

No lesions attributable to parasitic invasion were found.

Day 14

Petechial and ecchymotic haemorrhages were scattered over the entire lung surface (Figure 36) and throughout the parenchyma. On closer inspection the interlobular septae were seen to be more prominent than usual (Figure 37).

Microscopically the main change was a marked pulmonary eosinophilia with eosinophil accumulations around many of the blood vessels (Figure 38). The interlobular septae and subpleural areas were oedematous and infiltrated with large numbers of eosinophils (Figure 39). Focal areas of alveolar collapse and eosinophilic alveolitis together with occasional areas of alveolar haemorrhage were seen and there was widespread eosinophilic bronchitis and bronchiolitis (Figure 40) sometimes with a few eosinophils in the lumina of the airways. Small numbers of neutrophils were associated with the alveolar collapse otherwise the eosinophil was the main cell involved in the pathological changes at this time.

Cross-sections of parasitic larvae were seen in some of the smaller bronchi associated with a localised, copious, mucous exudate and small numbers of eosinophils and lymphocytes in the adjacent lamina propria (Figure 41). Occasionally a cross-section of a




FIGURE 36 The lungs of a foal 14 days after infection with 8,000 P. equorum eggs, showing petechial and ecchymotic haemorrhages.

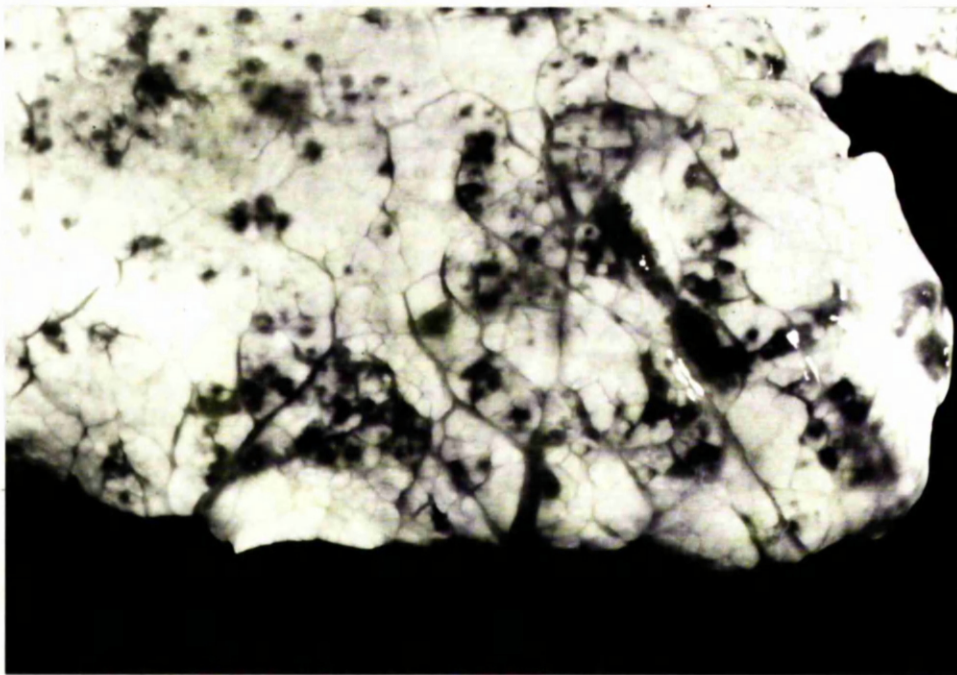


FIGURE 37 The lungs of a foal 14 days after infection with 8,000 P. equorum eggs, showing petechial and ecchymotic haemorrhages with widening of the interlobular septae.

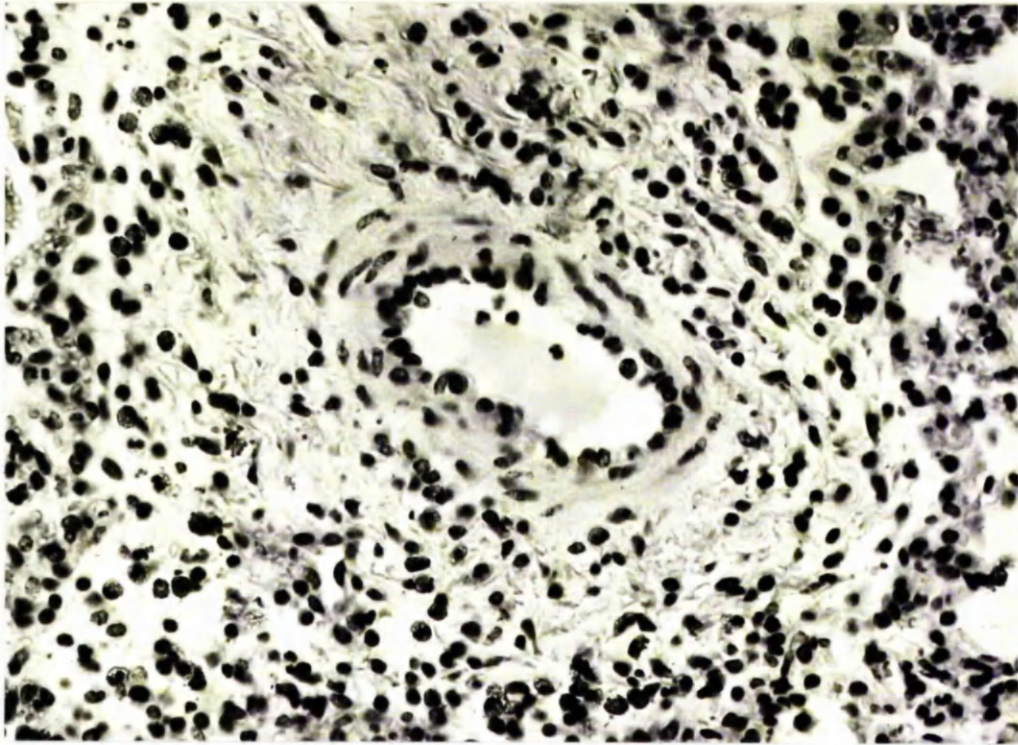


FIGURE 38 Small pulmonary blood vessel surrounded by eosinophils 14 days after infection of a foal with 8,000 P. equorum eggs. x 250.

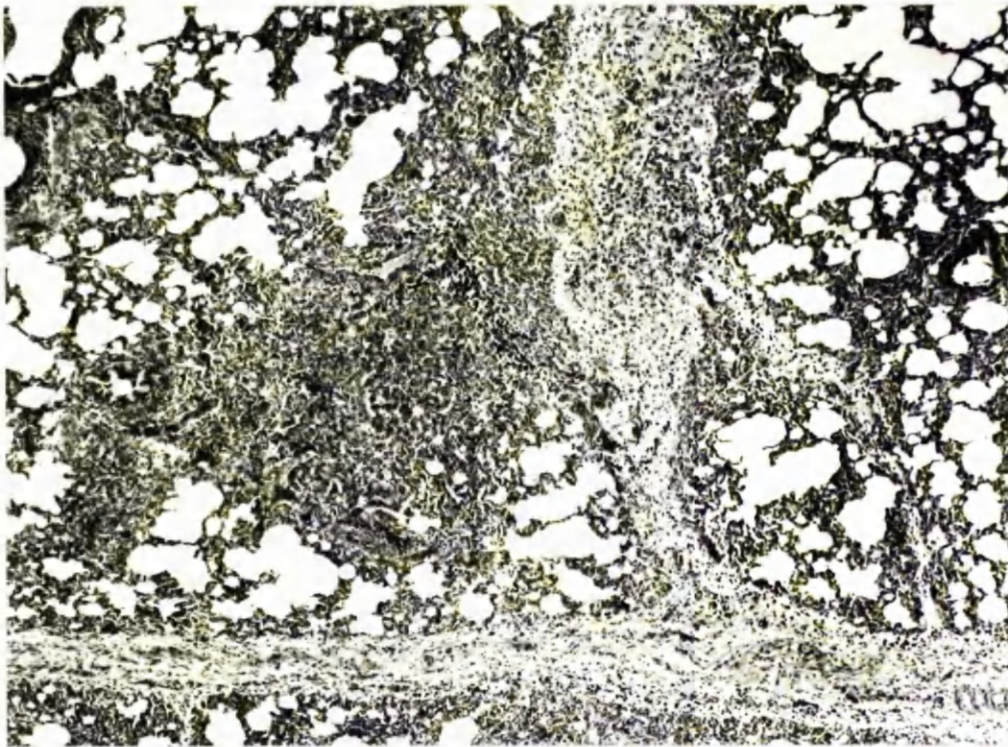


FIGURE 39 Oedematous interlobular septae infiltrated by eosinophils and a focal area of alveolar collapse 14 days after infection of a foal with 8,000 P. equorum eggs. x 35.

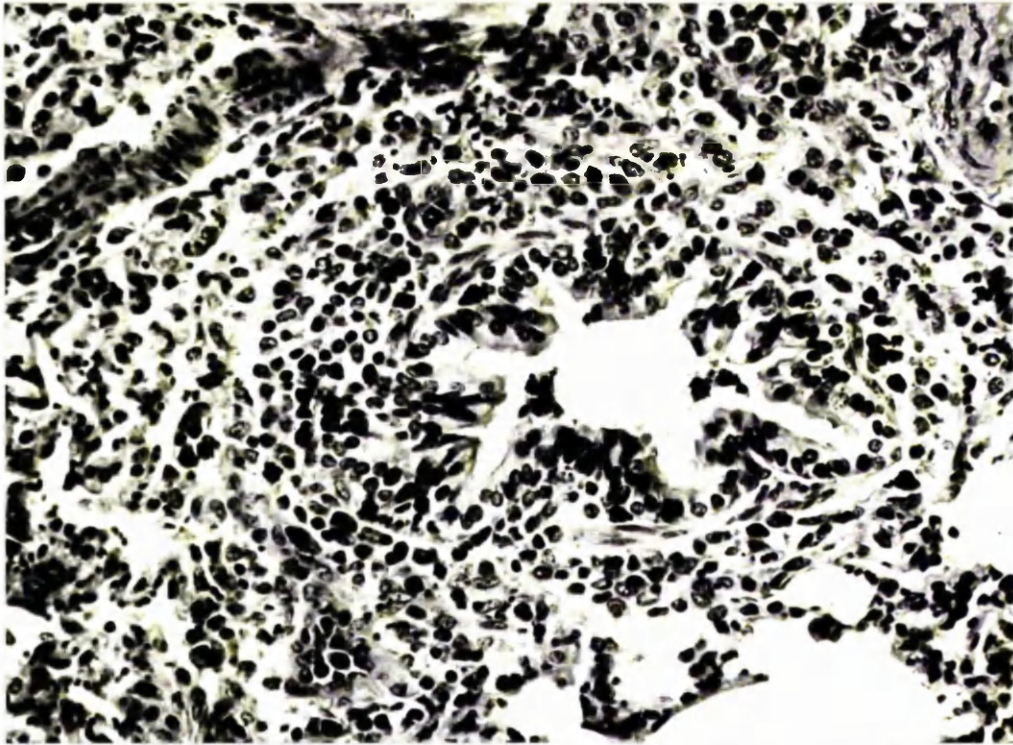


FIGURE 40 Numerous eosinophils can be seen both in the lamina propria and migrating through the hyperplastic epithelium of a bronchiole 14 days after infection of a foal with 8,000 P. equorum eggs. x 250.

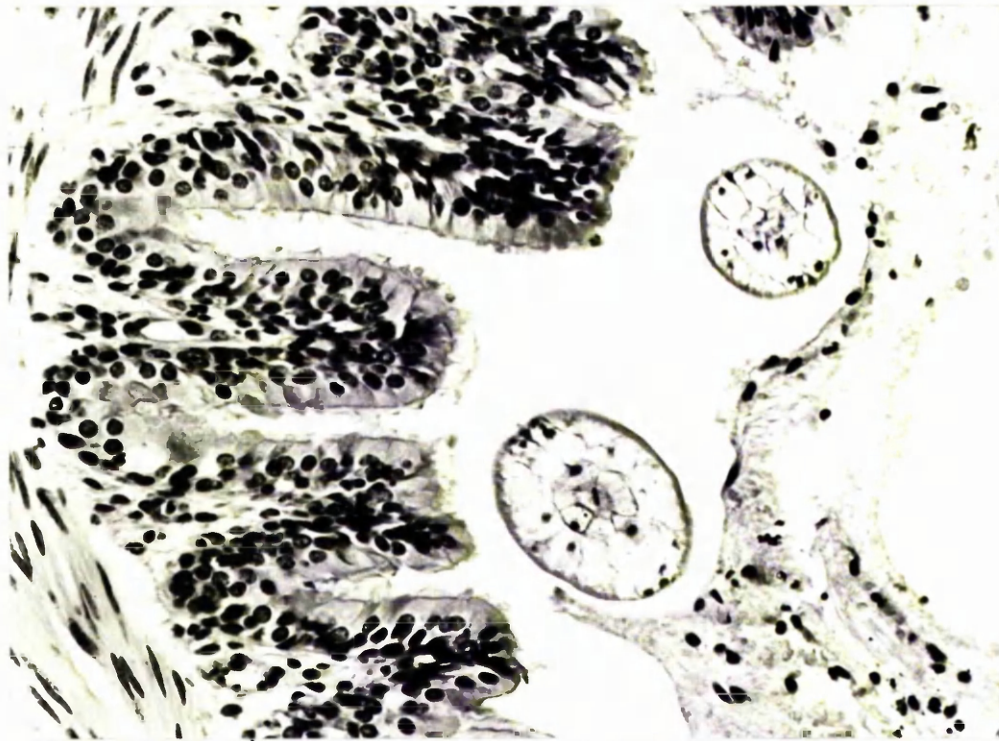


FIGURE 41 Cross-section of larvae, surrounded by mucus, in the lumen of a small bronchus 14 days after infection of a foal with 8,000 P. equorum eggs. x 250.

parasite was seen in an alveolus (Figure 42), where it did not appear to be associated with any reaction.

Day 23

Focal areas of eosinophilic alveolitis were seen as in the previous animal but more lymphocytes and macrophages were now involved in the reaction.

In addition 6 subpleural nodules, 0.3 to 1.0 cm in diameter, were found scattered over the lung surface. These were raised, spherical, translucent, grey or greenish in colour and consisted of a mass of lymphocytes surrounded by a lightly defined, fibrous capsule and a rim of eosinophils with a few eosinophils within the substance of the nodule (Figure 43). Some nodules contained a strongly eosinophilic amorphous material which was thought to represent the remnants of disintegrating parasitic larvae, whilst others had collections of large, pale-staining cells within them which were remnants of bronchial epithelium.

Day 37

Numerous subpleural nodules were scattered over the lung surface. Multiple slices were made of the lungs but no nodules could be detected in any part of the lung other than subpleurally; this was confirmed by random histological sections.

Microscopically there were narrow perivascular sleeves of lymphocytes which appeared to replace the eosinophils seen in the earlier reaction. The interstitium still contained eosinophils but accumulations of lymphocytes were now found both in the interstitium and in the bronchiolar lamina propria.

Day 73

One solitary lymphoid nodule was present in a caudal lobe.

On histological examination a few focal areas of alveolar collapse were seen, sometimes accompanied by a lymphocytic reaction

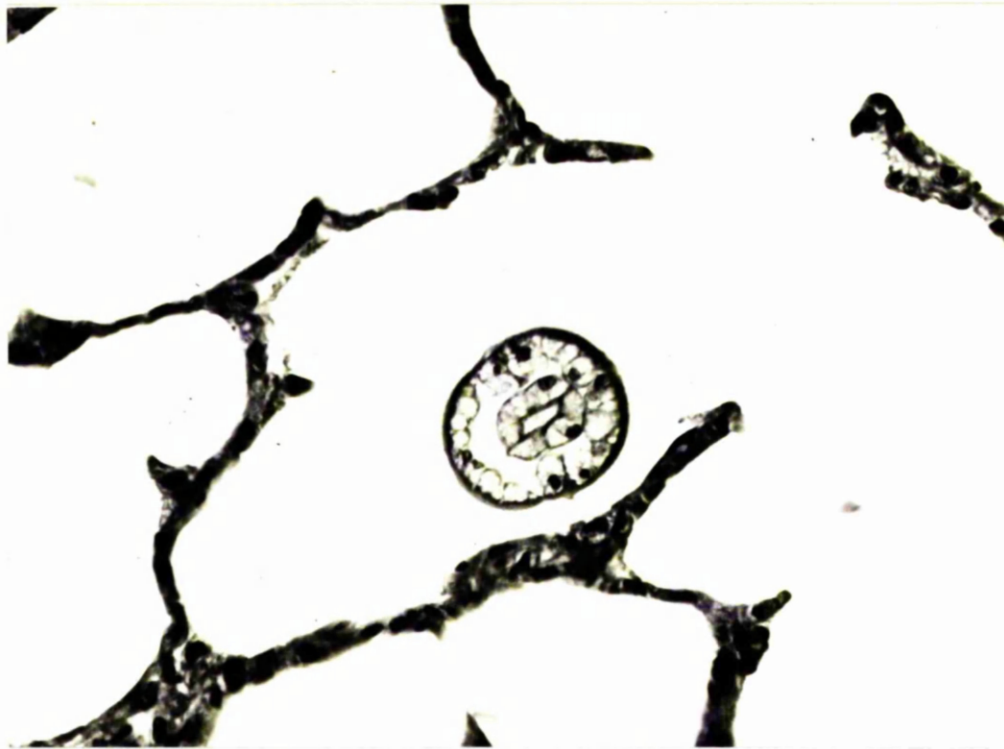

FIGURE 42 Cross-section of a larva in an alveolus with no apparent reaction of the alveolar wall 14 days after infection of a foal with 8,000 P. equorum larvae. x 400.

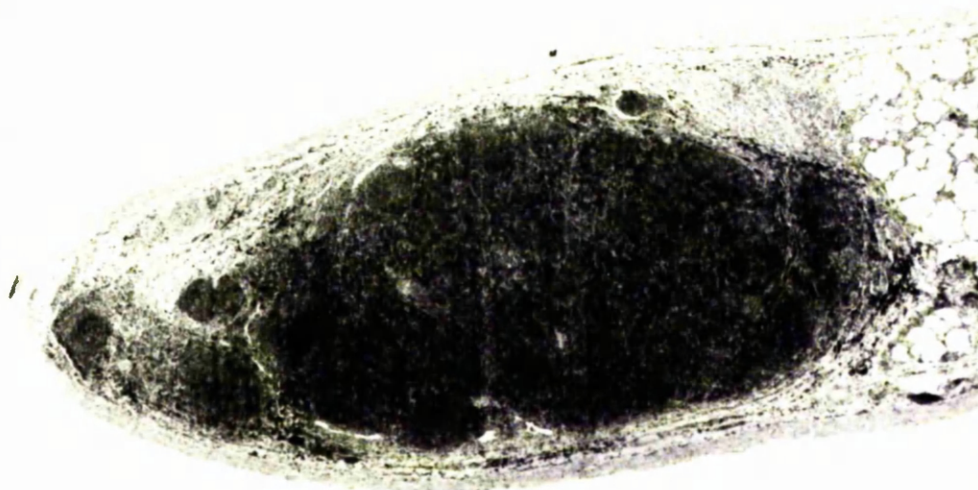

FIGURE 43 Section through a pulmonary nodule showing densely packed lymphocytes surrounded by a fibrous, eosinophilic capsule 37 days after infection of a foal with 8,000 P. equorum eggs. x 12.

and some prominent follicular lymphocytic accumulations around blood vessels and bronchioles.

Day 106

Microscopically the lungs had the same appearance as those of the foal killed on day 73. In both of these animals the lymphocytic accumulations around the blood vessels and bronchioles had developed germinal centre-like areas.

Day 146

The only macroscopic finding was the presence of 12 subpleural nodules.

Microscopically there were a few areas of a mild eosinophilic bronchitis and bronchiolitis. Very few lymphocytic accumulations were present and these were much reduced in size from those found on day 73.

The pulmonary pathology is summarised in Table 12.

In all the foals except those killed on days 7 and 146 after infection there were areas of reddened, collapsed, consolidated lung tissue in the cranial and accessory lobes, which were not attributed to P. equorum infection. These were particularly extensive in the foal killed on day 106 and Figure 44 shows the typical distribution of these lesions. The pneumonic areas consisted of collapsed, consolidated pulmonary tissue with bronchitis and bronchiolitis. The airways had a hyperplastic epithelium with neutrophils, mucus and lymphocytes in the lumina and an infiltration of neutrophils, lymphocytes and plasma cells in the interstitium (Figures 45 and 46). Eosinophils were found within these areas in all the animals except the one killed 2 days after infection but they were not particularly numerous and were confined mainly to the alveolar septae. Moderate numbers of lymphocytes accumulated in the lamina propria of some of the affected airways.

Days after Infection	Cranial lobe pneumonia	Larvae recovered from lungs	Pulmonary haemorrhage	Pulmonary eosinophilia	Pulmonary lymphocytic accumulations	Subpleural lymphocytic nodules
2	++	-	-	-	-	-
7	-	-	-	-	-	-
14	++	+++	++++	++++	-	-
23	++	+	-	++	+	+
37	++	-	-	+	++	+++
73	++	-	-	-	++	+
106	+++	-	-	-	++	+
146	-	-	-	-	-	++

+/- indicates intensity of reaction.

TABLE 12 Reactions in the lungs of foals following infection with 8,000 *P. equorum* eggs.

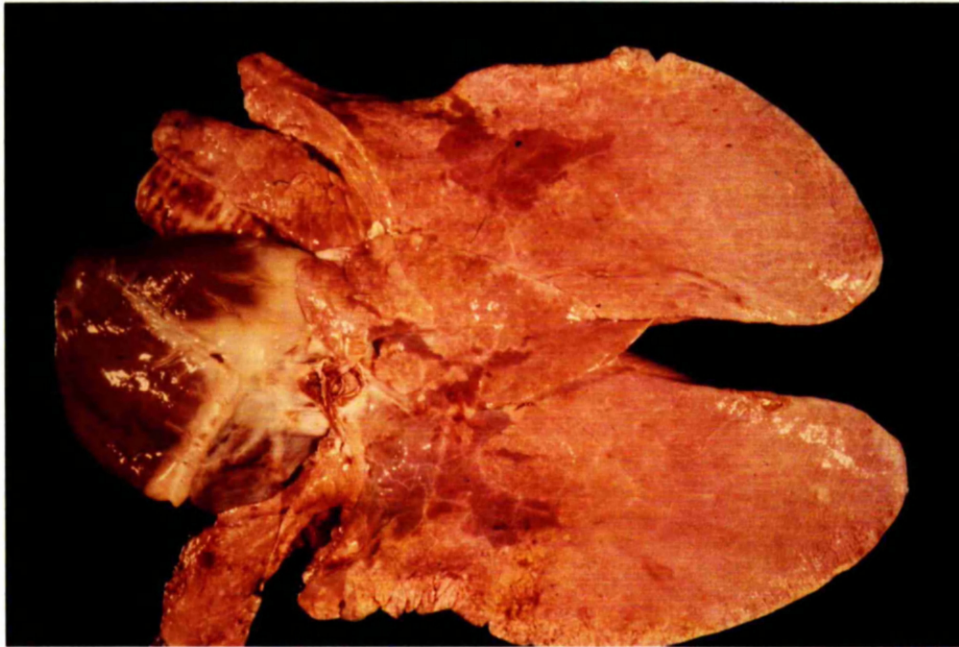


FIGURE 44 Ventral surface of the lungs of a foal 106 days after infection with 8,000 P. equorum eggs showing the distribution of the pneumonic areas.

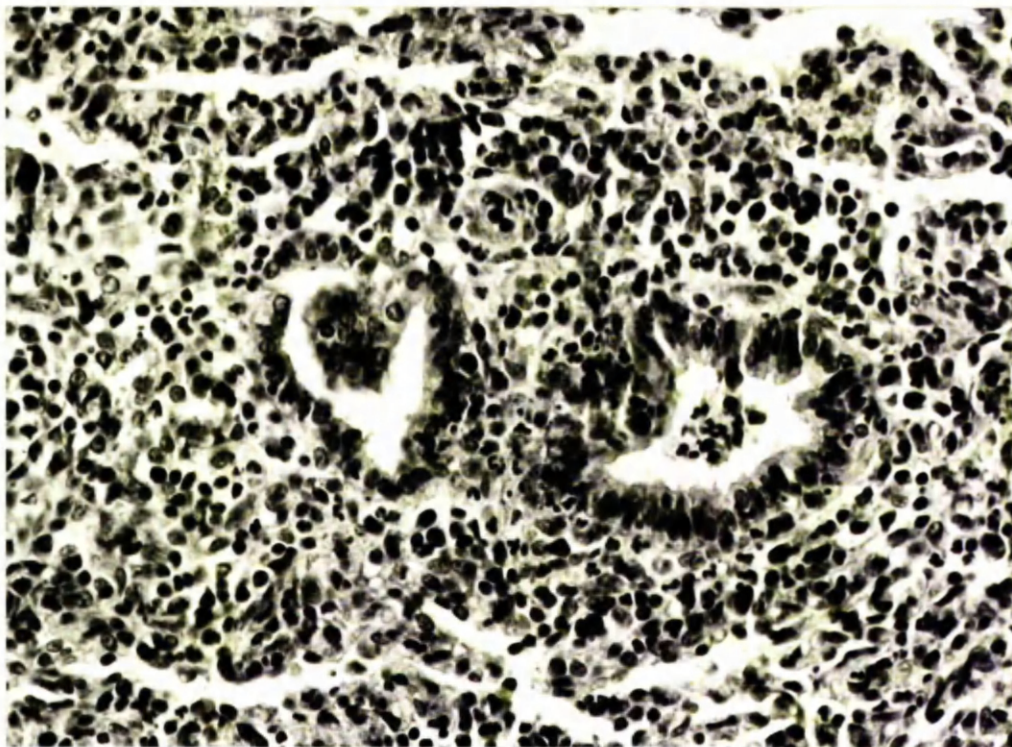


FIGURE 45 Section of a pneumonic lesion from the lungs of a foal 106 days after infection with 8,000 P. equorum eggs. The surrounding alveoli are collapsed and infiltrated by neutrophils, lymphocytes and plasma cells. x 250.

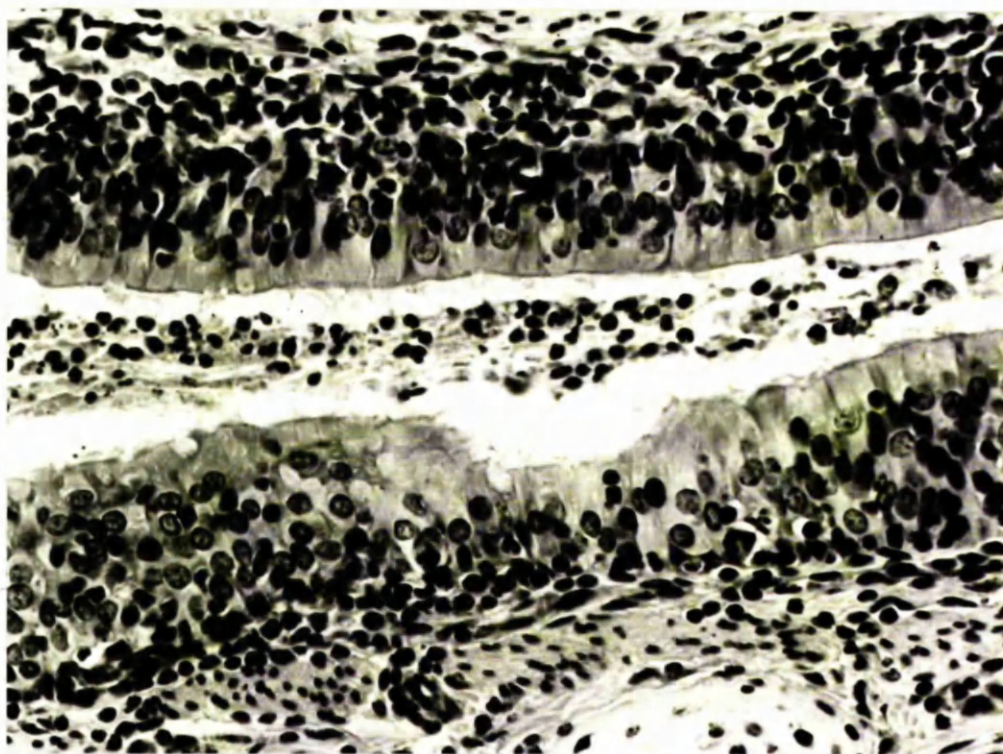


FIGURE 46 Section of a pneumonic lesion from the lungs of a foal 106 days after infection with 8,000 P. equorum eggs. The airways have a hyperplastic epithelium with neutrophils, mucus and lymphocytes in the lumina. x 300.

Mediastinal Lymph Nodes

The predominant changes in the mediastinal lymph nodes are shown in Table 13.

A few germinal centres were present on days 2 and 7. By day 14 the nodes had an enlarged, reactive appearance and contained large numbers of eosinophils especially in and around the sinuses, subcapsular area and blood vessels. Large numbers of these cells were also seen in the perinodal fat. On day 23 the nodes were still reactive with prominent germinal centres and moderate numbers of eosinophils (Figure 47). By day 37, however, the eosinophils had largely dispersed and many active germinal centres had appeared (Figure 48), which were most numerous on day 73 and had subsided by day 106.

Days after Infection	Eosinophilia	Germinal Centres
2	-	+
7	-	+
14	+++	++
23	++	++
37	+	++
73	-	+++
106	-	+
146	-	+

TABLE 13 Reactions in the mediastinal lymph nodes of foals following infection with 8,000 P. equorum eggs.

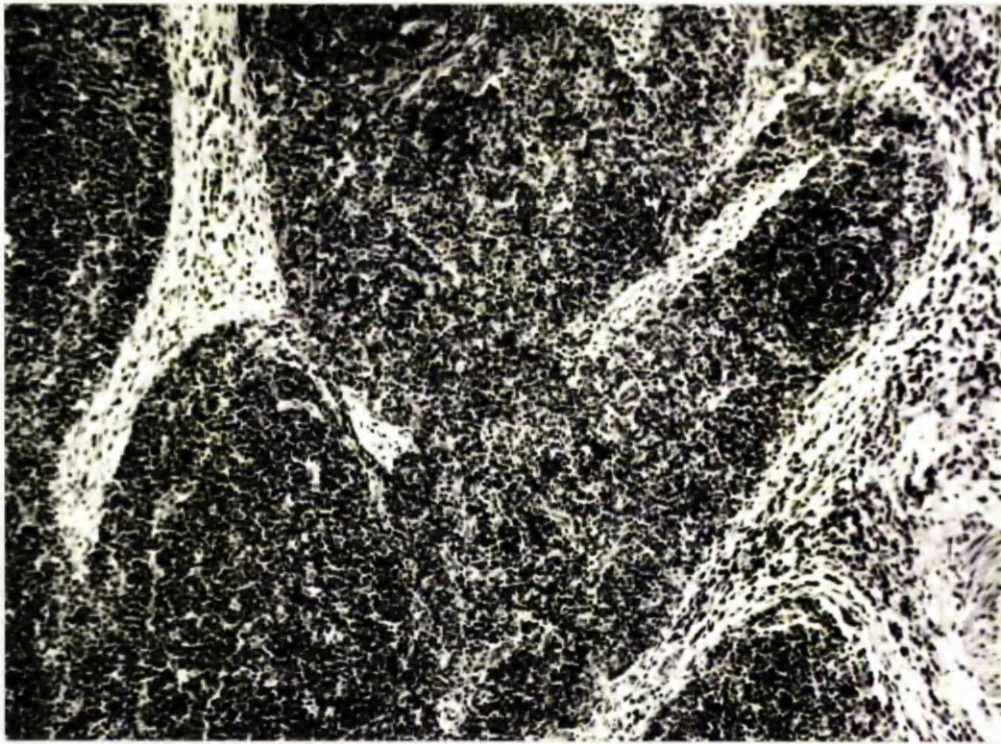


FIGURE 47 Section of the mediastinal lymph node of a foal 14 days after infection with 8,000 P. equorum eggs. The sinuses are increased in width and contain large numbers of eosinophils. x 110.



FIGURE 48 Section of the mediastinal lymph node of a foal 73 days after infection with 8,000 P. equorum eggs, showing the presence of active germinal centres. x 35.

DISCUSSION

It has been shown that the majority of P. equorum larvae reach the lungs between 7 and 14 days after infection. They apparently burst through the walls of the alveoli leaving a focal area of haemorrhage and eosinophilia, then migrate through the alveolar ducts into the bronchioles, bronchi and trachea from which they are coughed up and swallowed. The pulmonary breakthrough lesions resemble those described by Jarrett, McIntyre and Urquhart (1957) in calves infected with Dictyocaulus viviparus except that they also found foreign body giant cells in the reaction which were not seen in the lungs of the foals.

The predominant reaction provoked by the migrating parascarid larvae was an eosinophilia of the pulmonary tissue which was especially marked in the interlobular septae and subpleural areas. There was considerable oedema in these sites and this has also been mentioned by Hadwen (1925) following the migration of P. equorum through foals' lungs. Similar changes have been described in D. viviparus infections of calves (Jarret et al., 1957; Simpson, Wade, Dennis and Swanson, 1957).

The P. equorum larvae did not appear to provoke a local reaction save for the exudation of mucus around them. However, there was an eosinophilic bronchitis and bronchiolitis which affected most of the airways and inferred that there was a delayed response to the presence of larvae in the airways. The eosinophilia was transitory and by day 23 had largely been replaced by a lymphocytic reaction.

Subpleural lymphocytic nodules were first seen on day 37 and had largely disappeared by day 73. Identical nodules have often been noted in the lungs of foals and adult horses reared naturally and subsequently examined at post-mortem in the Glasgow Veterinary

School. It is noteworthy, however, that lesions of this type have not been seen in the lungs of foals reared worm-free then given a monospecific infection of S. vulgaris (Duncan, personal communication). Theiler (1918) found subpleural nodules in adult horses, whilst Hadwen (1925) commented that in one of his experimental animals many larvae had been destroyed during their migration through the lungs and small, pearly white nodules were plentiful beneath the pleura. Nieberle and Cohrs (1967) have also reported the development of subpleural, lymphocytic nodules in horses, following the death of parasitic larvae in the lungs. From the present small series of foals it was not possible to determine the significance of these nodules, but the presence of remnants of disintegrating larvae in some nodules suggested that they may give some indication of the number of parasites which had died or been destroyed in the lungs. If an immunological reaction were operating at the level of the parenchymatous organs then an increased number of nodules might be expected in an immune animal.

Identical nodules occur in certain parasitic infections in other species. In cattle they are more numerous following vaccination with X-irradiated D. viviparus larvae (Jarrett and Sharp, 1963; Michel and Mackenzie, 1965), treatment with anthelmintics (Jarrett, McIntyre and Sharp, 1962) or reinfection (Breeze, Pirie, Dawson, Selman and Wiseman, 1975). In calves the nodules persisted for at least 6 months following a double dose of X-irradiated larvae (Pirie, Doyle, McIntyre and Armour, 1971). In Metastrongylus apri infections of pigs the nodules are said to be more numerous in long-standing infections and are a feature of post-patent disease (Mackenzie, 1958).

Clinical signs of coughing and muco-purulent nasal discharge were first apparent around day 13 and persisted for about 10 days, while worm-free foals in the same air-space were not affected. This corresponds approximately to the period of larval migration through the respiratory system and their return to the gastrointestinal tract. The pathological findings at this time were severe enough to account for some clinical signs, but the possible role of the cranial lobe pneumonia cannot be ignored. As these lesions were present in the foal killed on day 2 before larvae had reached the lungs they were not thought to be related to P. equorum infection. The examination of paired serum samples failed to reveal the presence of a rising titre to any of the common viral pathogens of the equine respiratory tract. It is possible, however, that a mycoplasma may have been involved and several mycoplasmas have been isolated from the respiratory tract of horses by other workers (Allam, Powell, Andrew and Lemcke, 1973). Two seem to be specific for the horse and these have been identified as Mycoplasma equirhina (Allam and Lemcke, 1974), and the unnamed N3 (Allam and Lemcke, 1975). A large number of horse sera were examined for the presence of complement fixing antibody to these 2 organisms and 78% were found to be positive (Hooker and Butler, 1976), but their pathogenicity has not been established. Much more information is available regarding infection of pigs with mycoplasmas, as this pathogen is involved in the development of enzootic pneumonia, a respiratory disease which may cause considerable economic loss. Underdahl and Kelly (1957) found that pigs given A. suum plus an agent isolated from a case of enzootic pneumonia developed ten times as much pulmonary consolidation as pigs given the enzootic pneumonia agent alone, but pigs given A. suum alone did not develop any pulmonary consolidation.

They concluded from this that migrating ascarid larvae could enhance the lesions of a pre-existing enzootic pneumonia. This finding could explain the presence of quite considerable pulmonary consolidation in some of the foals and may be a factor in the pathogenesis of P. equorum infections.

(3) PATHOLOGY OF THE INTESTINAL TRACT

RESULTS

Very few pathological changes were evident on examination of the intestinal tract. In the foals killed on days 73, 106 and 146 reddened areas were present on the mucosa of the cranial small intestine (Figures 49 and 50), associated with the presence of many, large P. equorum.

Histological examination of sections of the small intestine taken at 1 metre intervals did not reveal any consistent abnormality. Occasionally an increased number of eosinophils was present in the intestinal wall but this could not be correlated with the stage of infection.

DISCUSSION

The infiltration of the intestinal wall by eosinophils could not be related either to the timing of the circulating eosinophilia or to the stage of the parasitic infection and the present study has also shown a virtual absence of damage to the intestinal wall. The adult P. equorum swim free in the intestinal fluids, ingesting food by means of a sucking action of the pharyngeal or oesophageal muscles (Fairbairn, 1957). Despite these apparently innocuous habits the experiments described here have shown that the presence of many ascarids feeding on the intestinal contents was associated with a loss of condition and poor weight gains in young foals, but the physiological processes responsible for this syndrome are largely unknown. Further studies are needed to investigate the mechanisms involved in the pathogenesis of the intestinal stage of P. equorum infection.




FIGURE 49 Sections of the cranial (above) and caudal (below) parts of the small intestine of a foal 73 days after infection with 8,000 P. equorum eggs.



FIGURE 50 The mucosal surface of the cranial small intestine of a foal, 106 days after infection with 8,000 P. equorum eggs.

SECTION III

CLINICAL PATHOLOGY

(1) HAEMATOLOGY

MATERIALS AND METHODS

Experiment 1

The experimental design was described earlier in this chapter (Table 8).

The haematological estimations were carried out on blood samples taken into sterile, heparinised vacutainer tubes at weekly intervals. The parameters measured were PCV, total RBC count, Hb concentration, total WBC count and differential WBC count.

RESULTS

The complete results of the PCVs, Hb concentrations, total RBC counts and total WBC counts are shown in Appendices 8 to 11 respectively.

Figure 51 illustrates the mean red cell indices of the 2 infected foals maintained until patent infections developed (F7 and F8) and of the controls (C1 and C2). It can be seen that there was some variation from sample to sample in both groups but the infected foals had lower values for each parameter throughout the experimental period. Significant changes in the red cell indices attributable to the parasitic infection were not seen.

The mean values for the total and differential WBC counts of the infected and control foals are shown in Figure 52, and although there was, again, some variation between samples in each group, significant changes were seen only in the eosinophil fraction. In

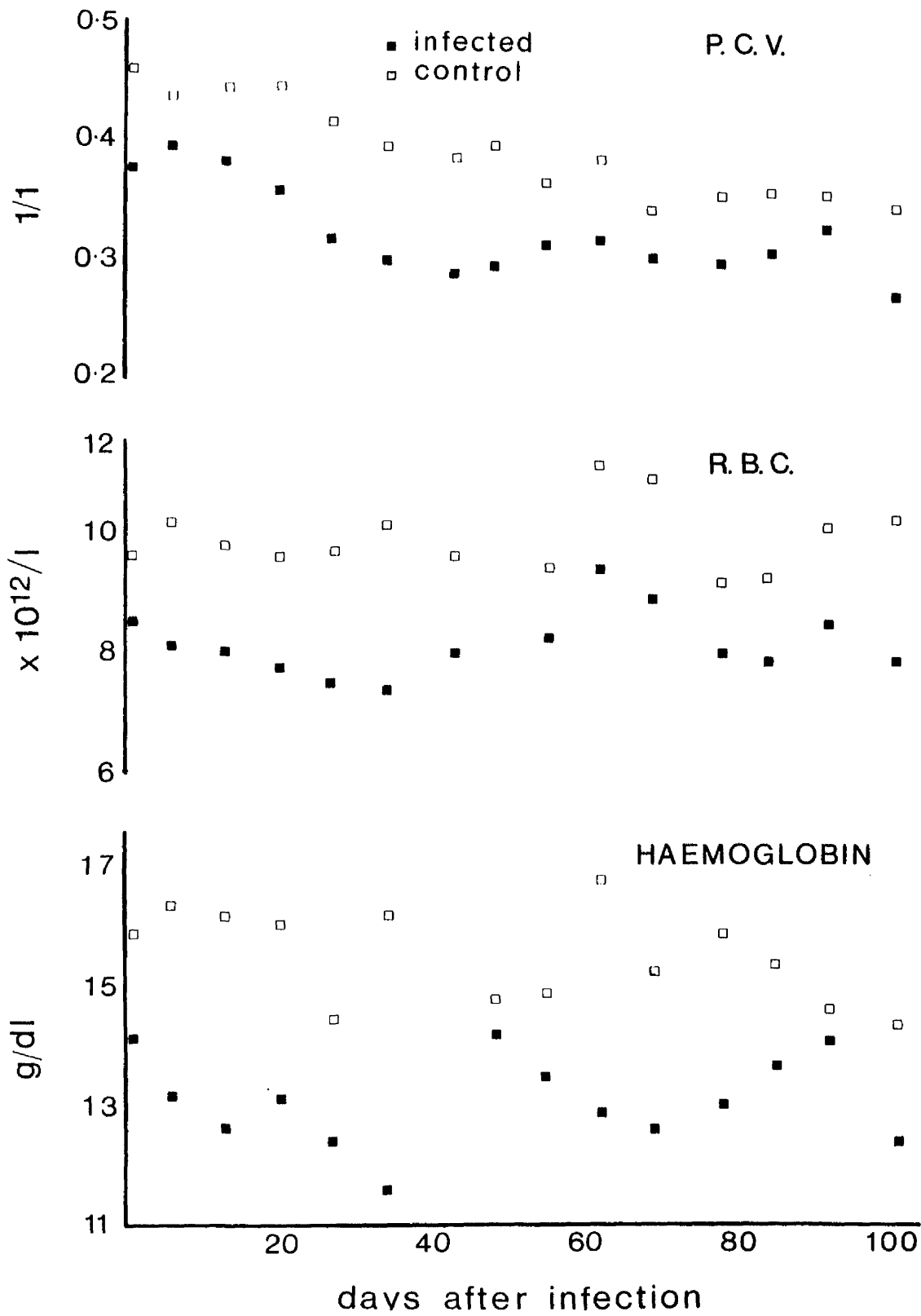


FIGURE 51

Packed cell volumes and red cell indices of foals infected with 8,000 *P. equorum* eggs and worm-free controls (mean values).

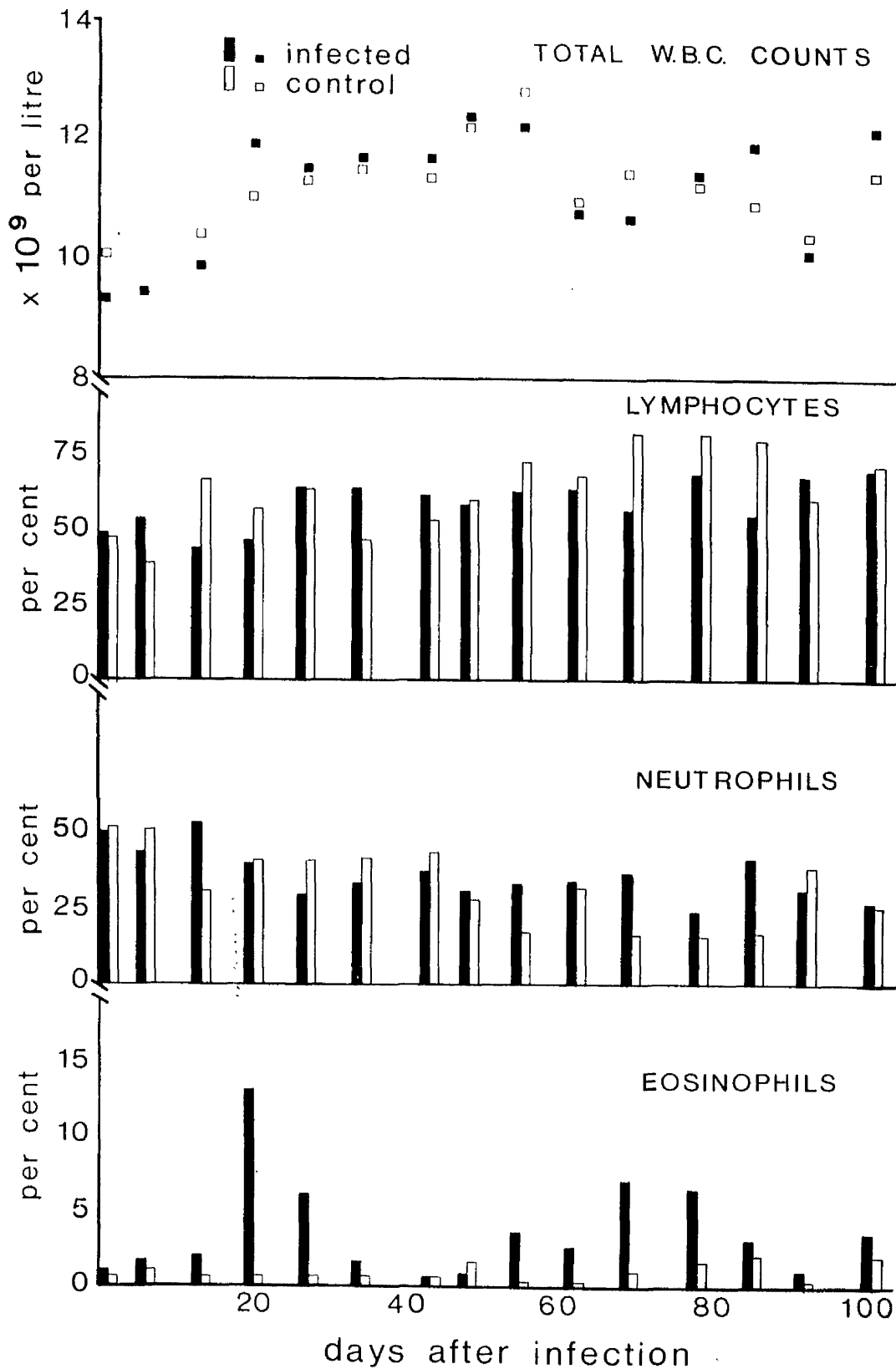


FIGURE 52

Total and differential white blood cell counts of foals infected with 8,000 *P. equorum* eggs and worm-free controls (mean values).

the infected foals which survived beyond day 14, a circulating eosinophilia was observed from the third week with a rapid rise to reach maximum counts during the fourth or fifth week after infection. In individual foals the peak values ranged from 0.98×10^9 eosinophils/l to 2.72×10^9 eosinophils/l. The number of circulating eosinophils then declined and was within the normal range by week 6, but rose again in foals F7 and F8 from week 9 onwards. In the control group the eosinophil counts remained below 0.25×10^9 eosinophils/l (i.e. 3%). The mean circulating eosinophil values of the infected foals F7 and F8 and controls C1 and C2 are represented graphically in Figure 53.

DISCUSSION

From their studies of horses reared naturally and subsequently challenged with experimental P. equorum infections Antipin and Stepanova (1948) and Ryazantsev (1956) described a fall in total red cell and haemoglobin values with a rise in the total white cell count. Chebotar'ov (1950), however, disagreed with these results in that he found no significant change in the red cell indices, whereas the total white cell count decreased during the first and second weeks after infection with an associated neutropaenia and relative lymphocytosis. The latter author also noted a circulating eosinophilia in the later stages of the infection. An increase in the eosinophil counts was also reported by Antipin and Stepanova (1948) and Ryazantsev (1956), who recorded maximum values of 8.5% and 16% respectively. Hadwen (1925) described the occurrence of a circulating eosinophilia soon after the ascarid larvae finished their tissue migration and he noted that this increase was more marked following reinfection.

Duncan and Dargie (1975) studied the haematological changes following Strongylus vulgaris infection of foals and found an early,

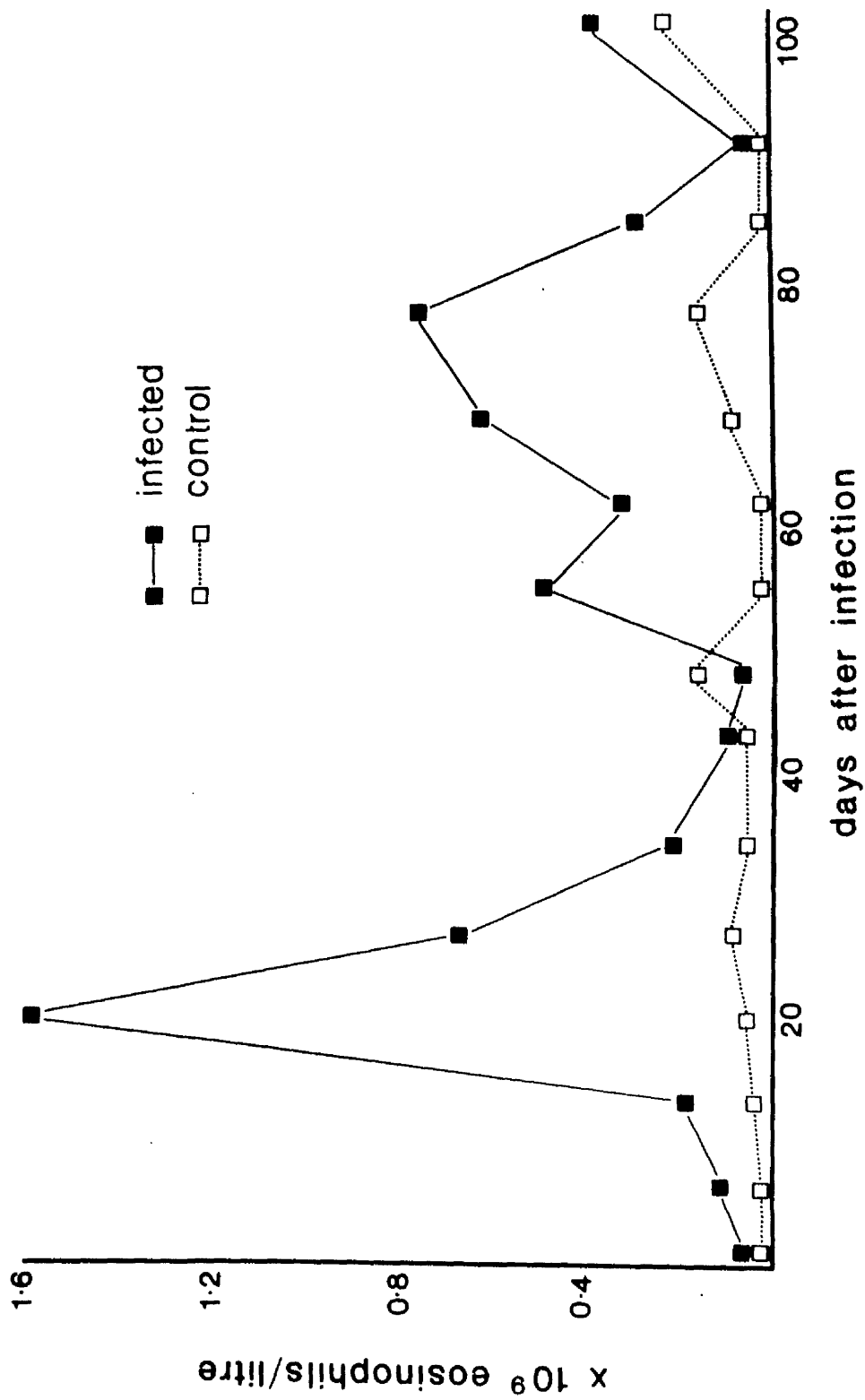


FIGURE 53 Circulating eosinophil counts of foals infected with 8,000 *P. equorum* eggs and worm-free controls (mean values).

sharp rise in the total WBC counts with an increase in the neutrophil/lymphocyte ratio and an increase in the number of circulating eosinophils. Other helminth infections of the horse in which blood eosinophilia is a feature include Dictyocaulus arnfieldi (Round, 1972) and Strongyloides westeri (Greer, Bello and Amborski, 1974).

In experimental Ascaris suum infection of calves Greenway and McCraw (1970) found that Hb and PCV values remained within normal limits, while the number of circulating eosinophils increased between 11 and 14 days after infection. These workers also recorded an eosinophilia of the bone marrow which preceded the rise in circulating eosinophils by 36 hours, and the increased number of eosinophils in the blood stream was often reflected by an increase in the total WBC count. In the experiment described here the bone marrow was not examined, but a circulating eosinophilia occurred between 15 to 35 days after infection. This corresponded to the period of pulmonary eosinophilia which was most marked in the foals killed on days 14 and 23. The second rise in blood eosinophils, from day 55 onwards, coincided with the expulsion of ascarids in the faeces, but whether there was a relationship between these two events is not known.

Eosinophilia is a feature of many helminth infections and there is evidence to suggest that the eosinophil granulocyte may be a parasite-killer cell (Mahmoud, Warren and Peters, 1975). The mature eosinophil is thought to be an end-cell, incapable of further cell division, which develops in the bone marrow, then circulates for a few hours in the blood, before migrating into extravascular sites where it dies or is shed from a mucosal surface (Basten, Boyer and Beeson, 1969). These authors also stated that eosinophils do not recirculate in the blood, and the circulatory system is thus a vehicle

for transport of the cells from their site of production to their site of action in the body tissues. It should be noted that examination of blood samples for evidence of eosinophilia measures only the number of cells which are in transit at that time and gives no indication of either the rate of production of these cells in the bone marrow or their activity in the body tissues.

(2) SERUM PROTEIN ESTIMATIONS

MATERIALS AND METHODS

Experiment 1

Blood samples were collected at two-weekly intervals for serum protein estimations. The samples were taken into sterile vacutainer tubes, and left to stand for several hours. The serum was then drawn off and stored at -5°C until the estimations were carried out.

RESULTS

The individual total protein values of the 3 infected foals, which survived more than 5 weeks after infection, and the 2 controls are shown in Table 14.

Weeks after Infection	Infected Foals			Controls	
2	51.6	45.5	54.8	48.4	52.3
4	48.6	44.5	57.2	49.6	57.0
6	48.1	46.9	57.7	no sample	no sample
8	51.0	50.4	59.2	47.5	54.6
10	51.0	57.0	63.1	50.2	53.3
12	-	48.2	60.3	49.7	58.1
14	-	45.3	54.8	50.8	56.8
16	-	38.0	57.1	48.5	53.4
18	-	-	48.1	45.0	53.2
20	-	-	53.2	46.5	51.4
22	-	-	49.5	46.1	51.8

TABLE 14 Total serum protein values (g/l) of foals infected with 8,000 P. equorum eggs and uninfected controls.

The mean values for the total protein and the albumin and globulin fractions of the infected foals, F7 and F8, and the control foals, C1 and C2, are shown in Figure 54. In the infected group there was a steady increase in the total serum proteins from 50 g/l at the time of infection to around 60 g/l in week 10, due to an increase in the globulin fraction. The values then decreased again to about 50 g/l. In the control group the globulin levels increased by a similar amount, but the albumin levels of these animals were unaccountably low in weeks 10 and 14, and this was responsible for a depression of the total protein value on these dates. The total serum protein values of the controls were maintained within the range of 48 to 55 g/l.

DISCUSSION

The normal ranges for the serum protein values of adult horses were given by Doxey (1977) as total protein 60 to 83 g/l, albumin 25 to 37 g/l and globulin 35 to 48 g/l. In the experiment presented here the serum protein values of the foals tended to be lower than the normal values quoted above, but since both the infected foals and the controls had low values the deviations were not attributed to P. equorum infection. Indeed, Duncan and Dargie (1975), who used pony foals of a similar breed and age, recorded serum protein values within the same range as those reported here.

In studies of naturally acquired helminthiasis, Round (1968) concluded that the serum protein levels gave an indication of the extent to which a horse was infected by helminth species, the pertinent change being an increase in the beta-globulin fraction. This change has been recorded in experimental infections of Strongylus vulgaris (Drudge et al., 1966; Round, 1970; Duncan and

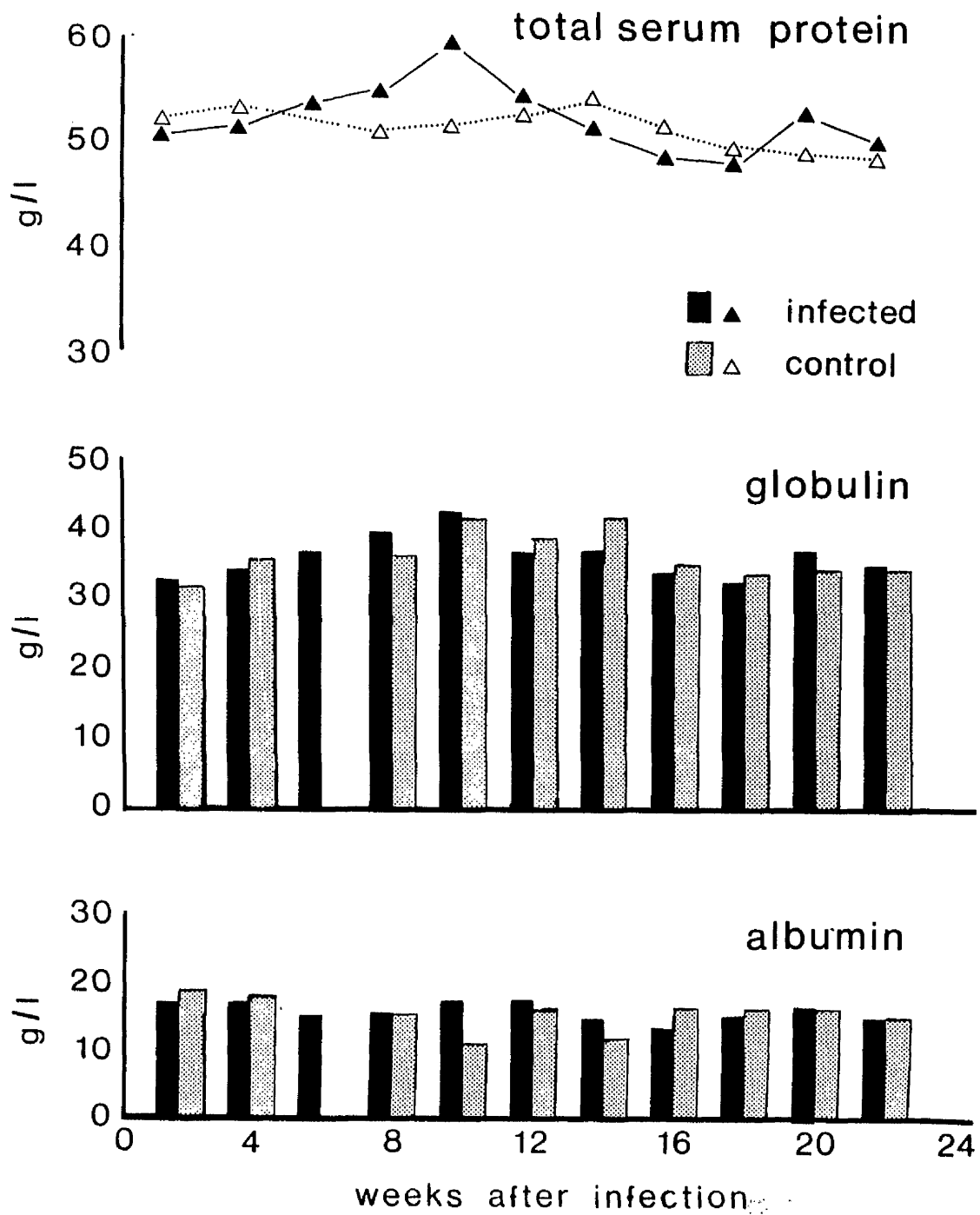


FIGURE 54 Serum protein values of foals infected with 8,000 *P. equorum* eggs and worm-free controls (mean values).

Dargie, 1975) and in small strongyle infections (Round, 1970). For example following a primary infection of 1,500 S. vulgaris in worm-free ponies, Round (1970) found an increase in the beta-globulin fraction from 12 g/l to a maximum of 30 g/l at 16 to 20 weeks after infection. This increase in the beta-globulin component was sufficient to elevate the total globulin and total protein levels. Although the serum globulin was not split into its alpha, beta and gamma components in the experiment described here, if there had been a gross increase or decrease in any of these fractions it would have been reflected in the total globulin value. No such changes were seen in the infected foals.

LIVER FUNCTION AS ESTIMATED BY THE NORMOTEST

In an earlier section it was shown that the migration of parascaris larvae through the liver gave rise to marked pathological changes in that organ. In order to investigate the interference with liver function due to larval migration the Normotest was employed.

Most of the tests used to assess dysfunction of the liver require elaborate and expensive apparatus and reagents. The Normotest, however, is a simple coagulation test requiring a minimum of laboratory equipment. It was devised by Owren for use in man, and adapted for use in the horse by Allen and Archer (1972). The liver has many diverse functions and the Normotest is based on the fact that the blood clots as a result of a series of pro-enzyme to enzyme transformations, involving a series of proteins, most of which are synthesised in the liver. When the liver is damaged these factors are diminished, with consequent alterations in the clotting characteristics.

MATERIALS AND METHODS

Experiment 2

Details of the design of Experiment 2 have already been given (Table 9). For the Normotest blood samples were taken into sterile, heparinised vacutainer tubes on days 4 and 1 before infection, on the day of infection and on days 1, 2, 5, 6, 10, 12, 15 and 19 after infection. The 4 infected foals and the 2 controls were sampled at 9 a.m. on each occasion.

RESULTS

The Normotest values of individual animals are shown in Table 15 and the mean values for the infected foals and the controls are shown in Figure 55. It can be seen from the graph that the Normotest values of the infected animals were higher than those of the controls, by up to 15% throughout the period of observation, but the values followed a similar pattern in both groups. There were no significant alterations in the Normotest which could be attributed to the parasitic infection.

Days after Infection	Infected Foals				Control Foals	
	Group A		Group B		Group C	
-4	44	89	70	73	70	67
-2	48	77	68	76	61	52
0	51	87	77	81	64	67
1	51	78	80	76	60	68
2	51	75	84	72	61	64
5	59	80	69	68	55	61
6	65	75	69	69	53	60
10	64	84	71	80	62	61
12	59	82	68	74	66	55
15	63	78	56	73	54	59
19	61	77	64	71	56	60

TABLE 15 Results of the Normotest (percentage) of foals infected with 8,000 P. equorum eggs and uninfected controls.

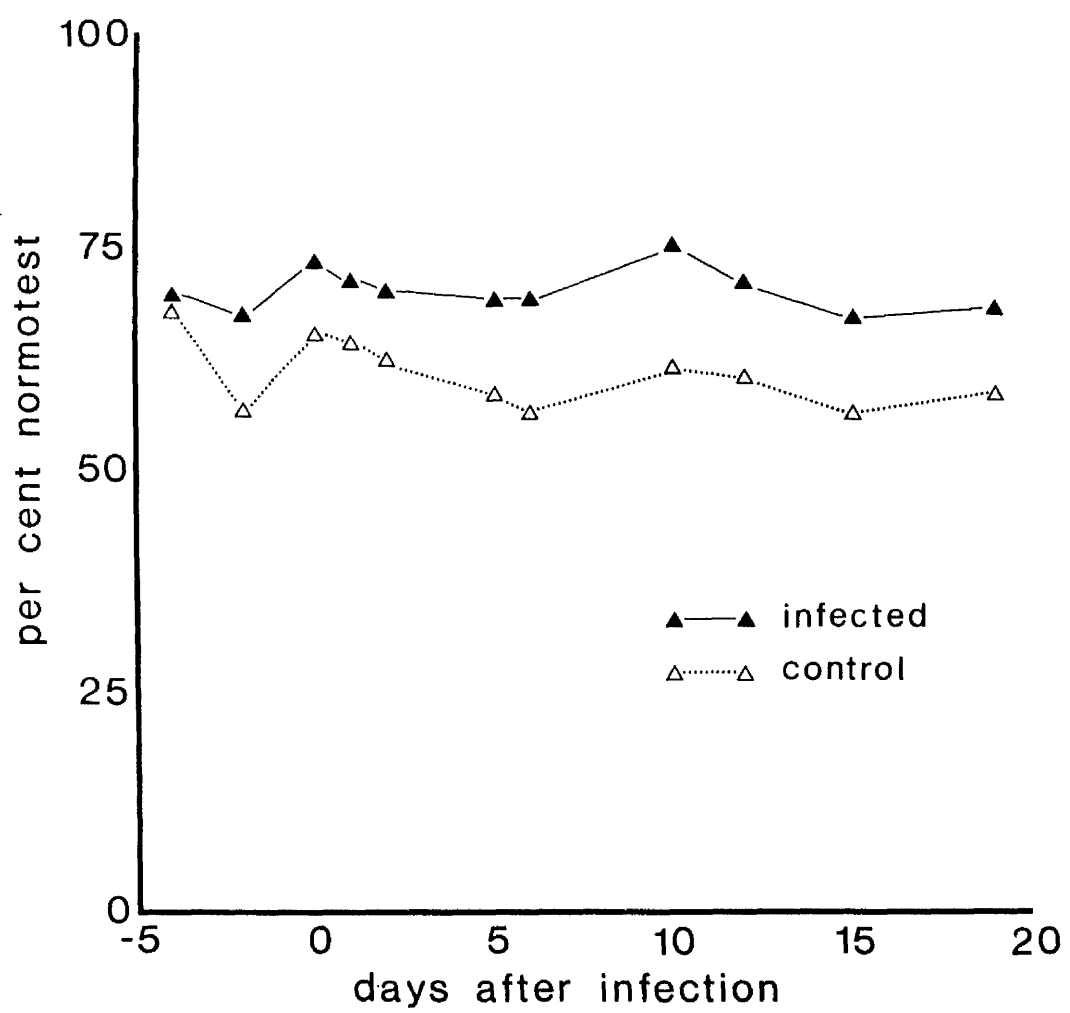


FIGURE 55 Normotest values of foals infected with 8,000 P. equorum eggs and worm-free controls (mean values).

DISCUSSION

The Normotest, expressed as a percentage has a normal range of 85 to 140 in thoroughbreds, but lower values in the range 70 to 96 are found in ponies (Allen and Archer, 1972). The test reflects the ability of the liver to synthesise particular proteins, a function which increases with age, so it is not surprising that the results are dependent upon age. Allen and Archer (1972) reported values between 40 to 60 in foals during the first few days of life. The foals in the experiment described here were under one month of age, the samples being collected at the same time each day to avoid any changes due to the diurnal rhythm. The infected foals had Normotest values which varied from 44 to 89, whereas the controls ranged from 52 to 70. None of these values was considered to be outwith the normal range for young pony foals.

CONCLUSIONS

Following a single infection of 8,000 P. equorum eggs, respiratory signs of coughing and a mucoid or purulent nasal discharge were present 2 to 4 weeks after infection. At this time the foals were bright and lively, they continued to eat well and the signs resolved without any treatment. During the later stages of infection, from the third month onwards, the presence of a large volume of ascarids in the intestinal lumen was associated with dullness and lethargy, and the weight gains were depressed by up to 50% compared with uninfected controls.

Two days after infection small, focal haemorrhages were seen on the surface of the liver and irregular narrow tracts, infiltrated by eosinophils were present throughout the organ. As the haemorrhages resolved white lesions appeared which were either discreet and rounded or diffuse and irregular in shape. The histological changes were most marked around the portal triads, and involved fibrosis and a cellular infiltration, predominantly eosinophils and lymphocytes. The results of the Normotest, however, did not indicate any impairment of hepatic function associated with these liver lesions.

Larval penetration of the lungs was marked by the development of petechial haemorrhages throughout the pulmonary tissue. In the early stages there was an infiltration of eosinophils particularly around the small blood vessels and airways, but these cells were later replaced by lymphocytes. Subpleural nodules, composed of a mass of lymphocytes, appeared in increasing numbers from day 23 to day 37, then decreased in number over a period of months.

The pathological changes in the small intestine were minimal. Localised areas of reddening were seen on the mucosal surface and an infiltration of the intestinal wall by eosinophils was sometimes present.

The only significant haematological change was a circulating eosinophilia, which was maximal between 15 to 35 days after infection, thus corresponding to the periods of hepatic and pulmonary eosinophilia. There was a second rise in circulating eosinophil levels from day 55 onwards. Changes in the serum protein values attributable to P. equorum infection were not seen.

CHAPTER 4

EXPERIMENTAL PARASCARIS EQUORUM INFECTION IN SIX TO TWELVE MONTH-OLD FOALS

SUMMARY

Eight worm-free foals, aged 6 to 12 months, received a single infection of 8,000 Parascaris equorum eggs. Only a small number of parasites returned to the intestinal tract, the majority dying or being killed in the liver and lungs presumably by the development of an age-dependent resistance to infection. The pathological changes in the liver and lungs were similar to, but more severe than those seen in younger foals. The pulmonary phase was marked clinically by the development of an interstitial pneumonia.

Similar parasitic recoveries and pathological changes were found in a group of three, 8 month-old foals, which were reared naturally then treated twice with an anthelmintic before being challenged with 8,000 P. equorum eggs.

INTRODUCTION

Both Russell (1948) and Bello et al. (1973) have noted that the ascarid faecal egg counts of foals decrease rapidly between 6 to 12 months of age, patent infections seldom being found in mature animals. It was not known whether this resistance to infection in older animals was dependent upon an acquired immunity due to previous exposure or whether age per se was an important factor.

To investigate this aspect of infection a series of experiments was designed in which experimental infections of older worm-free foals were compared with similar infections of foals reared under natural conditions.

Unfortunately the number of foals maintained under worm-free conditions for a prolonged period was restricted both by the expense involved and by the availability of accommodation. Therefore, the groups of older worm-free foals were small and infection of these animals was carried out at the same time as similar studies in younger foals, which thus acted as controls for the infectivity of the eggs and also for the clinical and haematological changes.

MATERIALS AND METHODS

Experimental Design

The design of the experiment is shown in Table 16. A total of 11 foals, 8 reared worm-free and 3 reared naturally, received a single infection of 8,000 P. equorum eggs. At the time of infection 2 of the worm-free foals were aged 12 months (A1, A2), 4 were aged 6 months (A3, A4, A5, A6) and 2 were aged 9 months (A7, A8).

The naturally infected foals were reared at grass with their dams and faecal examinations at 6 to 7 months of age showed that each animal had patent ascarid and strongyle infections. The foals were then weaned and kept indoors under a regime which precluded further helminth infection. Two anthelmintic treatments effective against the intestinal stages of P. equorum were administered at an interval of 3 weeks. One week after the second anthelmintic treatment the naturally infected foals, now aged 7 to 8 months and designated N1, N2 and N3 received a challenge infection of 8,000 P. equorum eggs.

Animal Identification	Age	Day Killed	Previous history	<u>P. equorum</u> eggs administered
N1	7-8 months	30	Naturally acquired ascarid and strongyle infections. Two anthelmintic treatments at an interval of 3 weeks	8,000
N2	7-8 months	125		
N3	7-8 months	125		
A1	12 months	14	Reared worm-free	8,000
A2	12 months	30		
A3	6 months	30		
A4	6 months	30		
A5	6 months	125		
A6	6 months	125		
A7	9 months	-		
A8	9 months	-		

TABLE 16 Experimental Design

Parasitology

Following each anthelmintic treatment of the 3 naturally infected foals, total faecal collections were made over a period of 5 days. The faeces were crumbled by hand so that any large worms could be picked out and identified. Specimens of P. equorum were then counted and measured.

At post-mortem examination the contents of each part of the gastrointestinal tract were scanned for the presence of large ascarids. The total contents of the small intestine were then preserved in 10% formaldehyde and a 20% aliquot was examined microscopically for the presence of small ascarids.

Faecal samples were taken twice weekly from day 40 for parasitological examination.

Clinical Examination

Clinical examinations were performed each day. Thoracic radiography and endoscopic examinations of the airways were undertaken in foals A2 and A8 on days 16 and 31 after infection. The body weights of foals A7 and A8 were measured at weekly intervals.

Haematology

Heparinised blood samples were collected each week for estimation of the PCVs, Hb concentrations, total RBC and WBC counts and differential WBC counts.

Pathology

All animals in this series were killed using a humane killer. Routine post-mortem examinations were performed after which the liver, lungs and gastrointestinal tract were studied in detail. Pathological changes were noted, and blocks of tissue were taken to include both visible lesions and apparently normal areas. The blocks were then prepared for histopathological examination.

RESULTS

Parasitology

Before anthelmintic treatment the naturally infected foals had patent ascarid and strongyle infections. The faecal egg counts of these animals, which were measured 10 days, 6 days and 2 days before the first anthelmintic treatment, are shown in Table 17.

Animal Identification	Faecal Egg Count		
	10 days before treatment	6 days before treatment	2 days before treatment
N1	50 asc. e.p.g.	50 asc. e.p.g.	200 asc. e.p.g.
	700 str. e.p.g.	750 str. e.p.g.	550 str. e.p.g.
N2	50 asc. e.p.g.	0 asc. e.p.g.	300 asc. e.p.g.
	0 str. e.p.g.	650 str. e.p.g.	0 str. e.p.g.
N3	0 asc. e.p.g.	100 asc. e.p.g.	0 asc. e.p.g.
	0 str. e.p.g.	950 str. e.p.g.	100 str. e.p.g.

asc. e.p.g. = ascarid eggs per gram

str. e.p.g. = strongyle eggs per gram

TABLE 17 Faecal egg counts of naturally reared foals before anthelmintic treatment.

Following anthelmintic treatment ascarids were expelled in the faeces of all 3 foals. Details of these recoveries are given in Table 18, and it can be seen that the largest number of worms was passed by foal N2, with a total of 135 P. equorum, including 2 worms recovered after the second anthelmintic treatment. Foals N1 and N3 had 25 and 3 P. equorum respectively, all of which were passed after the first treatment.

Animal Identification	1st anthelmintic treatment		2nd anthelmintic treatment	
	<u>P. equorum</u> expelled	Size range (mm)	<u>P. equorum</u> expelled	Size range (mm)
N1	25	22-124	0	-
N2	133	40-141	2	61-79
N3	3	46-105	0	-

TABLE 18 Recoveries of P. equorum from naturally reared foals following anthelmintic treatments.

Foal N1 was killed 30 days after infection when 5 P. equorum from 23 to 56 mm long were picked out of the small intestinal contents. A further 12 small specimens, 3 to 7 mm in length, were recovered by microscopical examination of a 20% aliquot. This was equivalent to a total recovery of 60 small and 5 medium-sized ascarids. The other 2 foals in this group, N2 and N3, were killed 125 days after challenge and harboured a total of 22 and 3 P. equorum respectively. The complete post-mortem recoveries from both the naturally reared and the worm-free animals are shown in Table 19.

Faecal examination was positive in one of the naturally reared foals (N2) on a single occasion only, 90 days after challenge, when a count of 50 asc. e.p.g. was recorded. All subsequent examinations of faeces from both N2 and N3 were negative.

In the group of worm-free animals, A1 (12 months old) was killed on day 14 during the migratory phase of the infection. This foal had 4 larvae in the liver, 548 in the lung parenchyma, 6 in the pulmonary airways and none in the small intestine. The remaining 12 month-old foal (A2) was killed on day 30 after infection, when 360 P. equorum were present in the small intestine, but parasites were not found in any other organ.

Animal Identification	Killed Day	Patent Day	No. <u>P. equorum</u> in the small intestine
N1 naturally	30	-	65
N2 reared	125	90	22
N3 foals	125	-	3
A1	14	-	0
A2	30	-	360
A3	30	-	10
A4 worm-free	30	-	100
A5 foals	125	NP	52
A6	125	NP	0
A7	Not killed	104	-
A8	Not killed	101	-

NP - not patent

TABLE 19 Numbers of worms recovered at post-mortem examination from 6 to 12 month-old, worm-free and naturally reared foals, following infection with 8,000 P. equorum eggs.

Two 6 month-old foals (A3 and A4), which were also killed on day 30, had totals of 10 and 100 P. equorum respectively. All of these parasites were recovered by microscopical examination of the contents of the small intestine. The 2 remaining foals in this age group (A5 and A6) were killed 125 days after infection, when A5 had 52 large P. equorum and A6 had no ascarids.

The 9 month-old foals, A7 and A8, were the only ones from the worm-free group to develop patent infections, but these animals were not killed and so their parasitic burdens were not determined. In A7 ascarid eggs first appeared in the faeces on day 104, with a count of 50 asc. e.p.g. This rose to a maximum of 350 asc. e.p.g. on day 122 and positive counts were recorded until day 130. The first recovery

of ascarid eggs from the faeces of A8 was on day 101: the count was 50 asc. e.p.g. and this rose to a maximum of 400 asc. e.p.g. on day 113. Patency persisted until day 150 in this case. The pattern of the faecal egg counts of these 2 animals is shown in Figure 56, from which it can be seen that the faecal examinations were frequently negative, positive values being recorded intermittently during the patent phase of the infection.

Clinical Findings

The clinical changes are summarised in Table 19. Rectal temperatures of all animals remained within the normal range of 37.4 to 38.9°C. The most marked clinical signs occurred in the 9 month-old foals (A7 and A8) which developed symptoms of both respiratory and systemic illness during the third week after infection. By day 15 frequent coughing, a serous or sero-mucoid nasal discharge and hyperpnoea were accompanied by depression, inappetence and loss of condition. The foals spent long periods of time lying down, but, in the absence of any treatment, their appetites began to improve on day 18. Over the next few days A7 and A8 became more alert and active until by day 24 they were clinically normal, except for the persistence of a cough in A8 until day 30.

Endoscopic examination of A8 on day 16 revealed the presence of an increased amount of tracheo-bronchial exudate. Bronchial washings, which were examined cytologically, contained many disintegrating eosinophils and macrophages, together with a few bacteria, mononuclear cells and neutrophils. Thoracic radiographs at this time demonstrated diffuse mottling and increased density of the lungs with accentuation of the bronchi, particularly in the

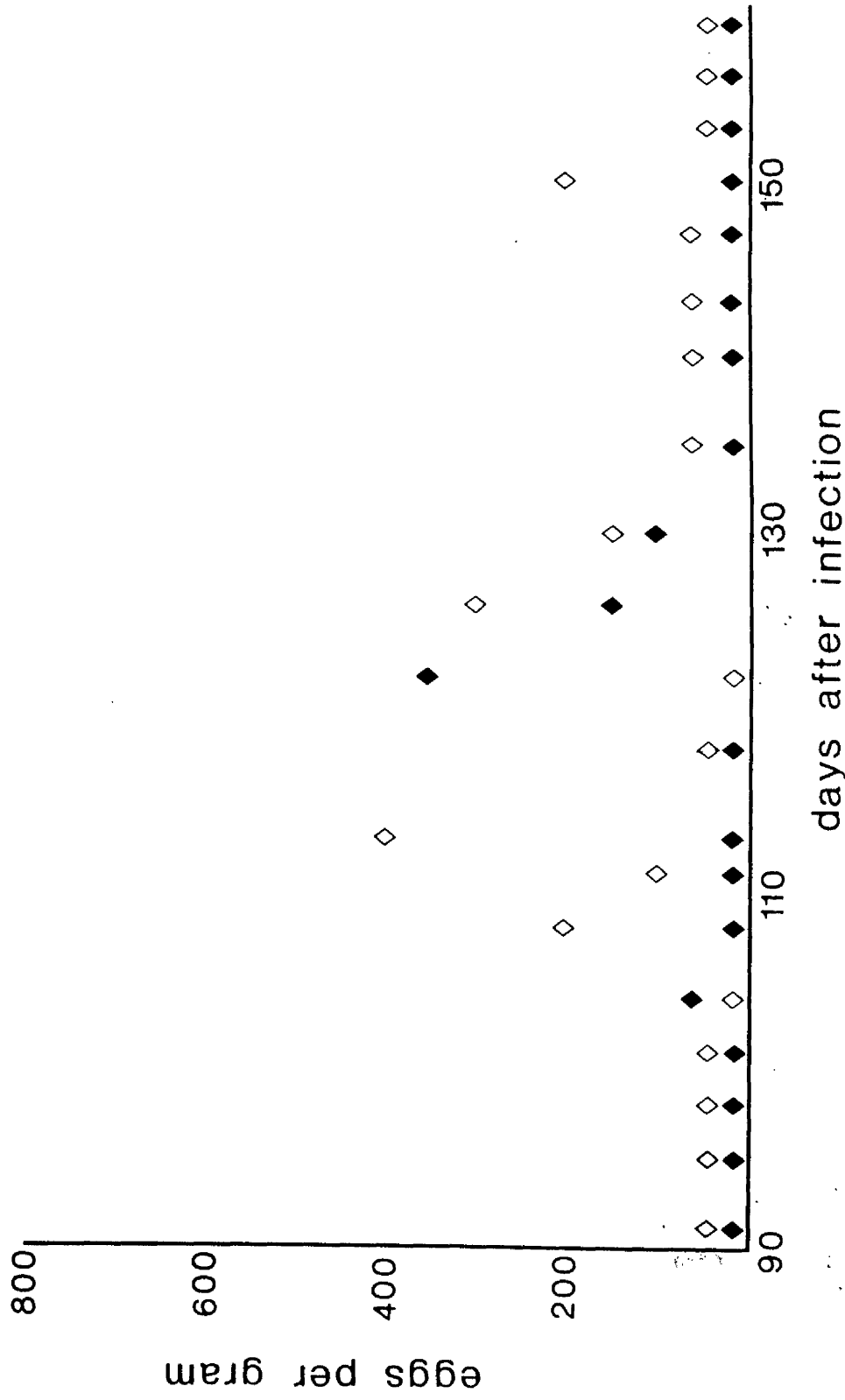


FIGURE 56 Faecal egg counts of 9 month-old foals after infection with 8,000 P. equorum eggs.

Animal Identification	Day Killed	Cough	Nasal Discharge	Dullness	Anorexia	Loss of Condition
N1 naturally	30	14	15	-	-	-
N2 reared	125	9-19	12-23	-	-	-
N3 foals	125	15-23	19	-	-	-
A1	14	12-13	12-13	14	14	-
A2	30	5-16	14-15	14	14	-
A3	30	20	16-21	-	-	-
A4 worm-free	30	13-20	9-23	-	-	-
A5 foals	125	5-27	5-20	-	-	-
A6	125	19	20-21	-	-	-
A7	-	15-20	14-16	16-23	16-23	16-23
A8	-	15-30	15	16-19	16-19	16-19

TABLE 19 Time of development (days after infection) of clinical signs in 6 to 12 month-old, worm-free and naturally reared foals, following infection with 8,000 *P. equorum* eggs.

caudal lobes (Figure 57). A follow-up radiograph on day 31 appeared to be normal (Figure 58).

The respiratory syndrome described above was associated with a temporary loss of body weight, but after A7 and A8 regained their appetites they maintained good bodily condition throughout the experimental period with weight gains of approximately 0.22 kg per day (Figure 59).

A similar, but milder, clinical syndrome was seen in foals A1 and A2 (12 months old). In these animals a cough was present during the third week after infection, accompanied by an increased amount of serous nasal discharge, mild depression and a decreased appetite. On day 17, radiographic examination of A2 showed mottling and opacity of the lungs with accentuation of the bronchi, but these changes had resolved by day 31 when a follow-up radiograph was taken. The endoscopic appearance of the airways of A2 on day 17 was apparently normal, but bronchial washing resulted in the appearance of some mucous exudate. The body weights of foals A1 and A2 were not recorded, but both animals maintained good to fat condition on clinical examination.

In the 6 month-old, worm-free foals and the naturally reared foals coughing was noted in all cases during the third week after infection, with a mucoid or purulent nasal discharge, but neither depression nor anorexia was a feature. Those animals which survived beyond day 30 (A5, A6, N2, N3) maintained good bodily condition.

Pathology

(a) Liver

Compared with the younger foals the hepatic lesions were both more numerous and more severe in the older animals. In the 12 month-old foal killed 14 days after infection all surfaces of the

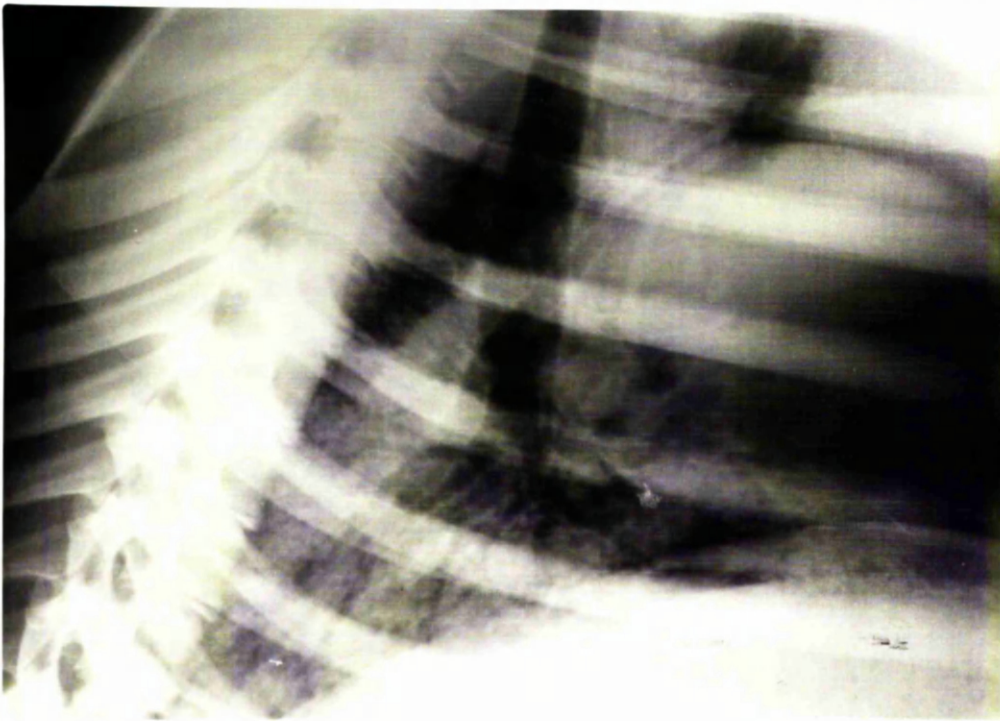


FIGURE 57 Thoracic radiograph of a 9 month-old foal 16 days after infection with 8,000 P. equorum eggs.

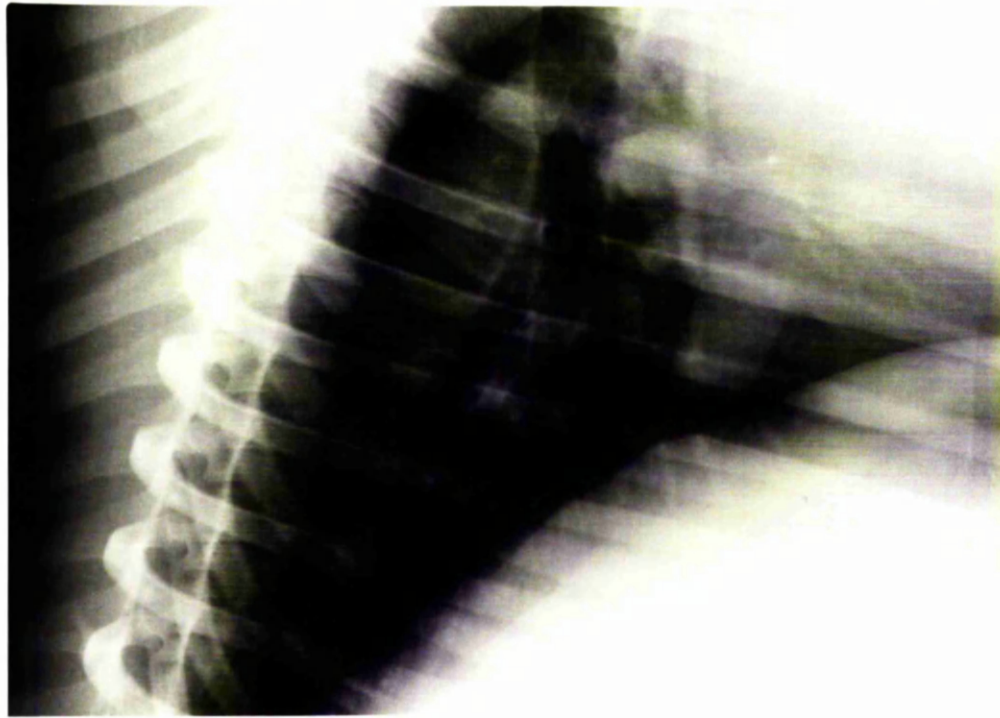


FIGURE 58 Thoracic radiograph of a 9 month-old foal 31 days after infection with 8,000 P. equorum eggs.

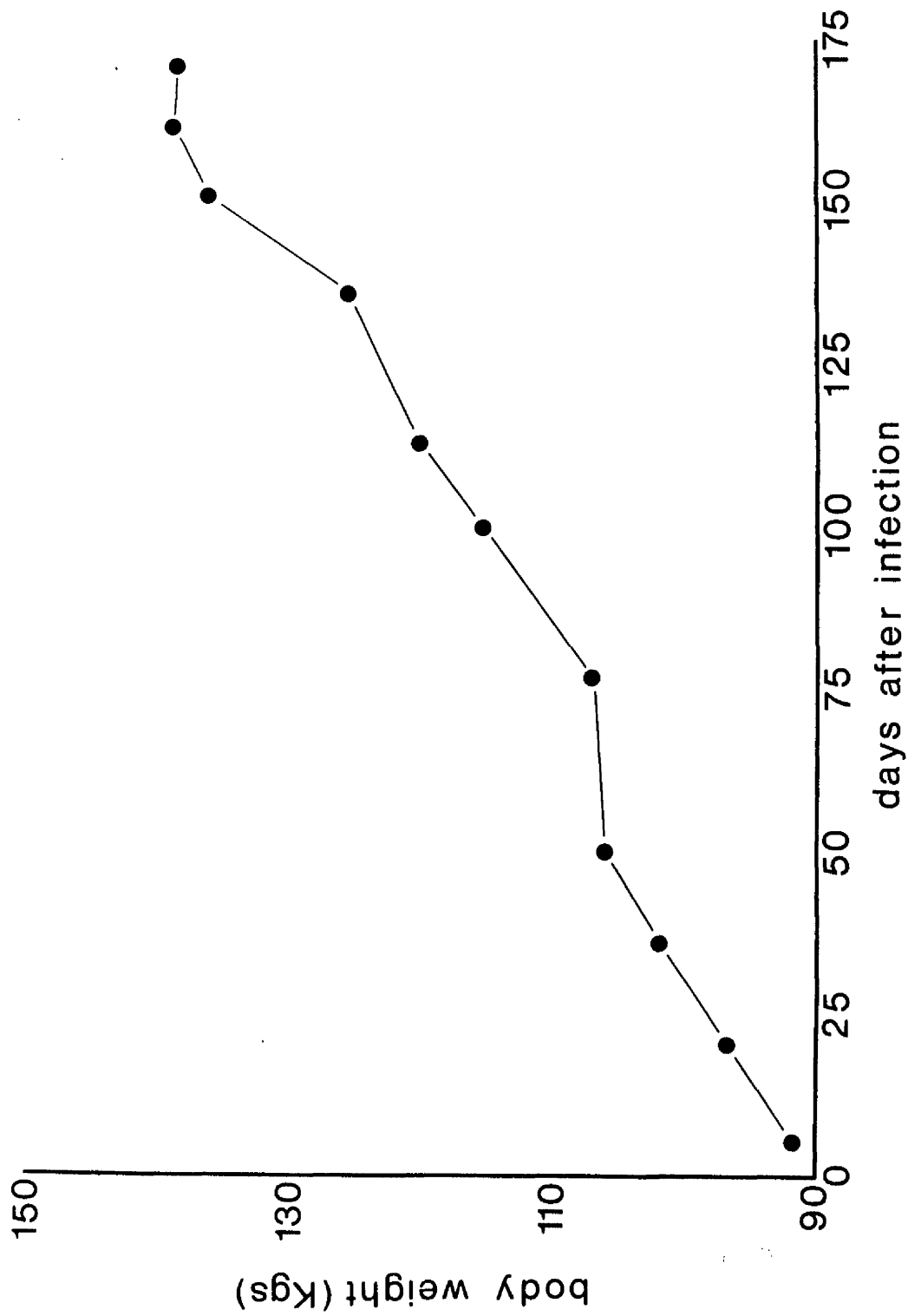


FIGURE 59 Changes in body weights of 9 month-old foals after infection with 8,000 *P. equorum* eggs.

liver were covered with rather diffuse, white areas (Figure 60). Many of these had the appearance of irregular tracts, together with a few discreet, rounded, subcapsular nodules, 1 to 3 mm in diameter. These lesions were also present in the substance of the liver tissue. On day 30 the changes were similar but less severe and by day 125 only a few discreet nodules remained beneath the capsule and within the parenchyma.

The microscopical changes resembled those described in the younger foals with fibrosis and cellular infiltration particularly around the portal triads. On day 30 large lymphoid accumulations were present often with a well-defined follicular structure (Figure 61). An additional feature seen 14 days after infection was the presence of granulomata with giant cells and macrophages around a central core of necrotic debris surrounded by some lymphocytes and eosinophils (Figure 62). These lesions were thought to have developed around dead ascarid larvae.

(b) Lungs

The pulmonary changes resembled those seen in the younger animals. In foal A1, killed 14 days after infection, petechial haemorrhages were numerous both on the surface and within the substance of the lungs. No subpleural nodules were present on day 14 but by day 23 these lesions were a prominent feature, especially in the caudal parts of the lungs. They were more numerous in the older animals than in the younger ones and were particularly marked in the naturally reared foal N1 at this time. On day 125 many lymphoid nodules were seen in the worm-free foals, whereas only a small number remained in the naturally reared animals.

In the early stages microscopical examination of the lungs revealed an eosinophilic infiltration particularly around the bronchioles and blood vessels. The eosinophils were replaced later

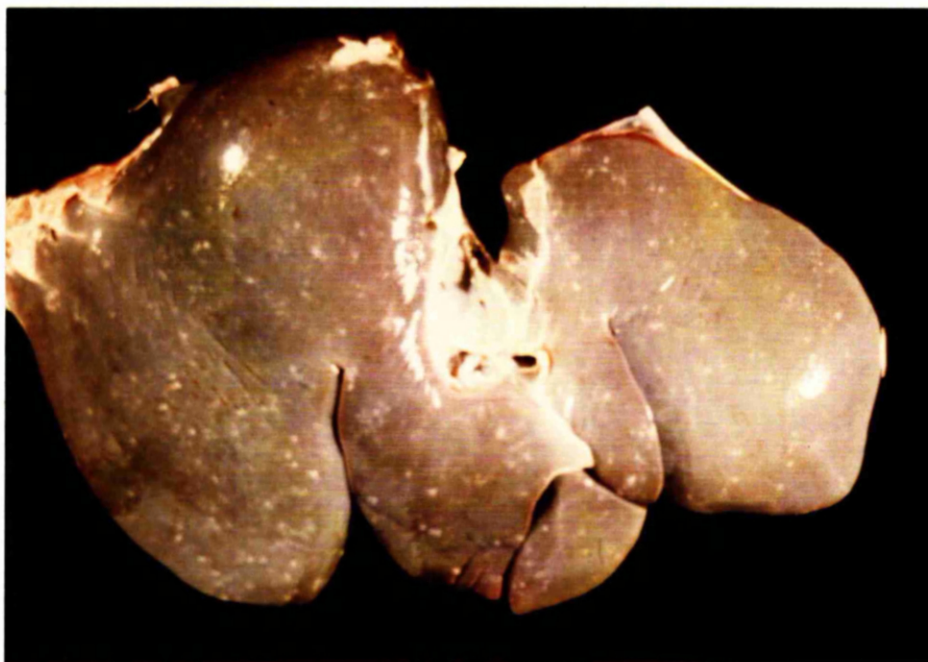


FIGURE 60 The liver of a 12 month-old foal
14 days after infection with 8,000
P. equorum eggs.




FIGURE 61: Lymphoid accumulation with follicular structure in the liver of a 7 month-old naturally reared foal 30 days after infection with 8,000 P. equorum eggs. x 110.

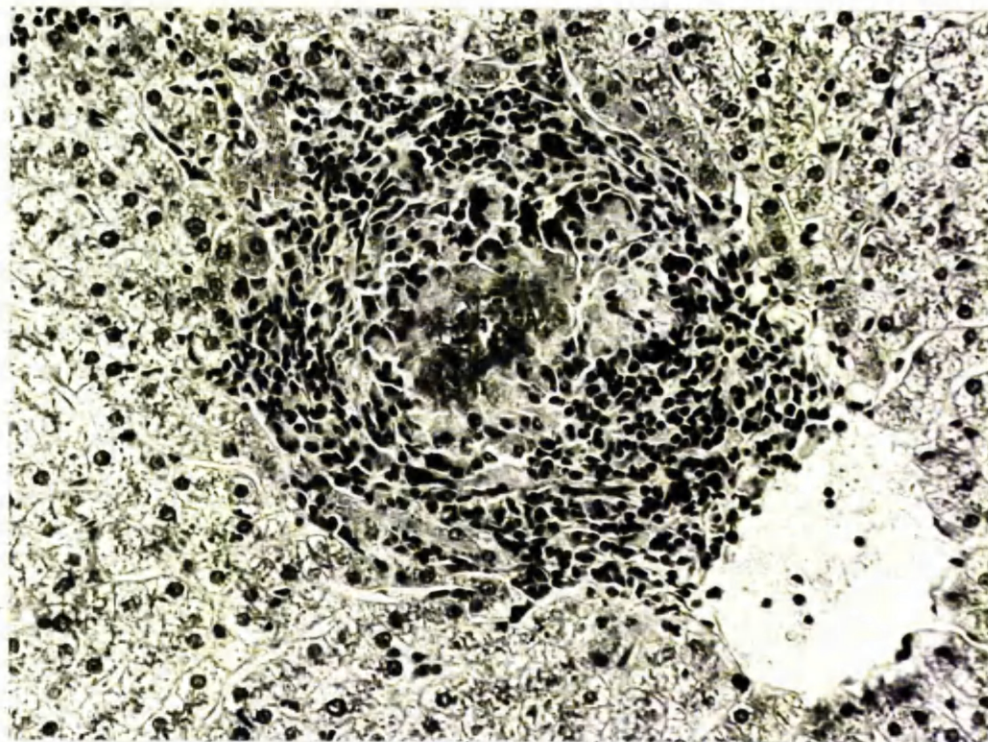


FIGURE 62: Granuloma in the liver of a 12 month-old foal 14 days after infection with 8,000 P. equorum eggs. x 250.

by lymphocytes which formed cuffs around the vessels and airways. Many of the subpleural lymphoid nodules had a follicular structure with germinal-centre like areas.

Haematology

The mean red cell indices of the 9 month-old, worm-free foals, the 6 month-old, worm-free foals, and the naturally-reared foals are shown in Figure 63. The PCVs, RBC count and Hb concentrations of the naturally reared group were slightly higher than those of the worm-free groups throughout the experimental period, but no changes attributable to P. equorum infection were seen.

The total and differential WBC counts of the 3 groups are shown in Figure 64. It can be seen that the 9 month-old, worm-free animals had higher total WBC counts and a higher neutrophil/lymphocyte ratio than the other 2 groups. After P. equorum infection there was an increase in the number of circulating eosinophils between 2 to 5 weeks after infection (Figure 65).

DISCUSSION

The results of the studies described here have shown that the changes in the older worm-free foals were similar to those in the naturally infected animals, indicating that age per se was an important factor in the development of immunity to parascariasis. There were marked differences, however, in the effects of P. equorum infection in foals aged 6 to 12 months compared with those seen in foals under one month of age, which were described previously.

Firstly, there were striking differences between the 2 groups in the number of larvae returning to the gastrointestinal tract. For instance, in the older animals killed 30 days after infection with 8,000 P. equorum eggs, the 3 worm-free and one naturally infected foal had only 10,100, 360 and 65 intestinal worms respectively,

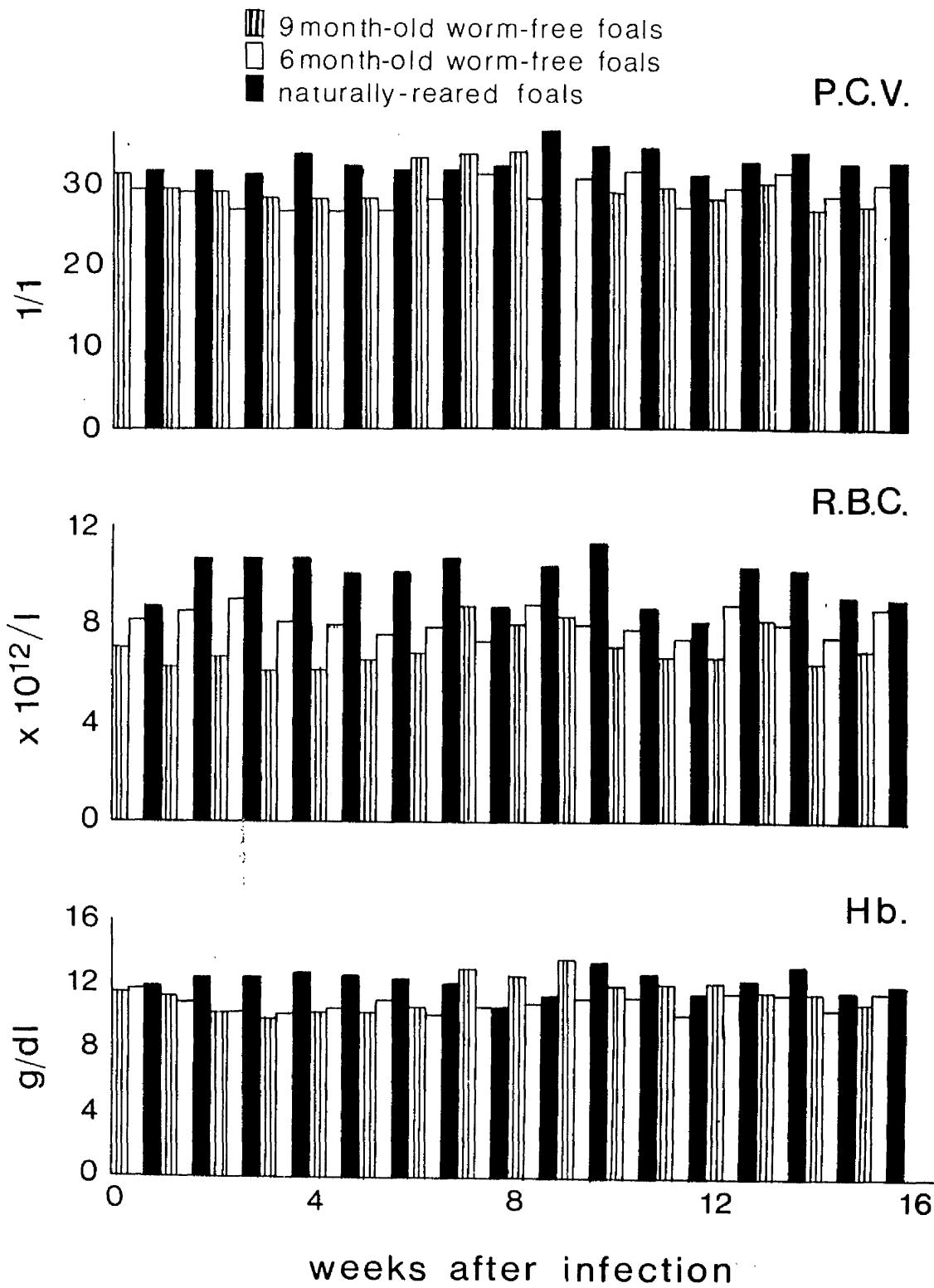


FIGURE 63

Packed cell volumes and red cell indices of foals after infection with 8,000 *P. equorum* eggs.

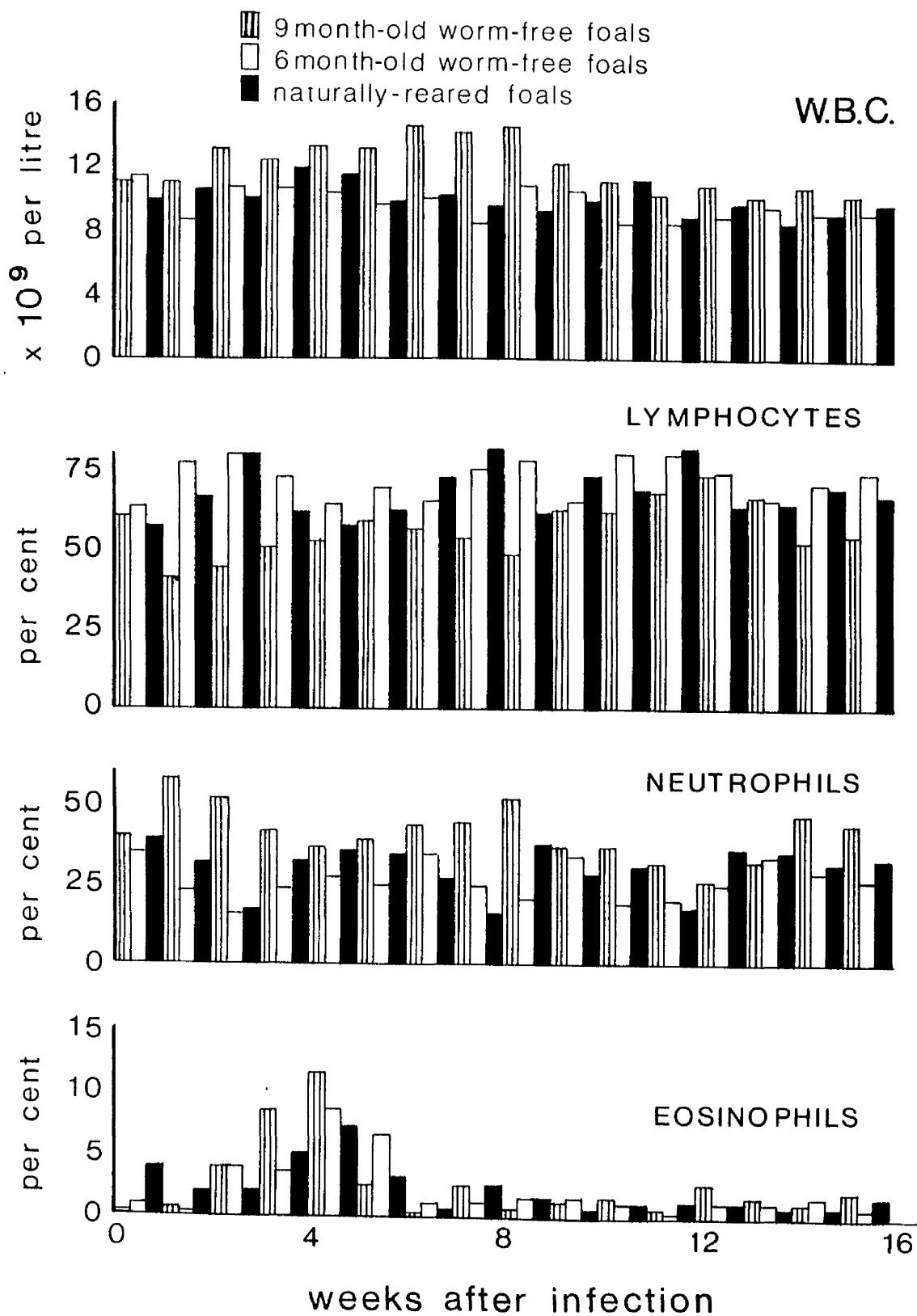


FIGURE 64

Total and differential white blood cell counts of foals after infection with 8,000 *P. equorum* eggs.

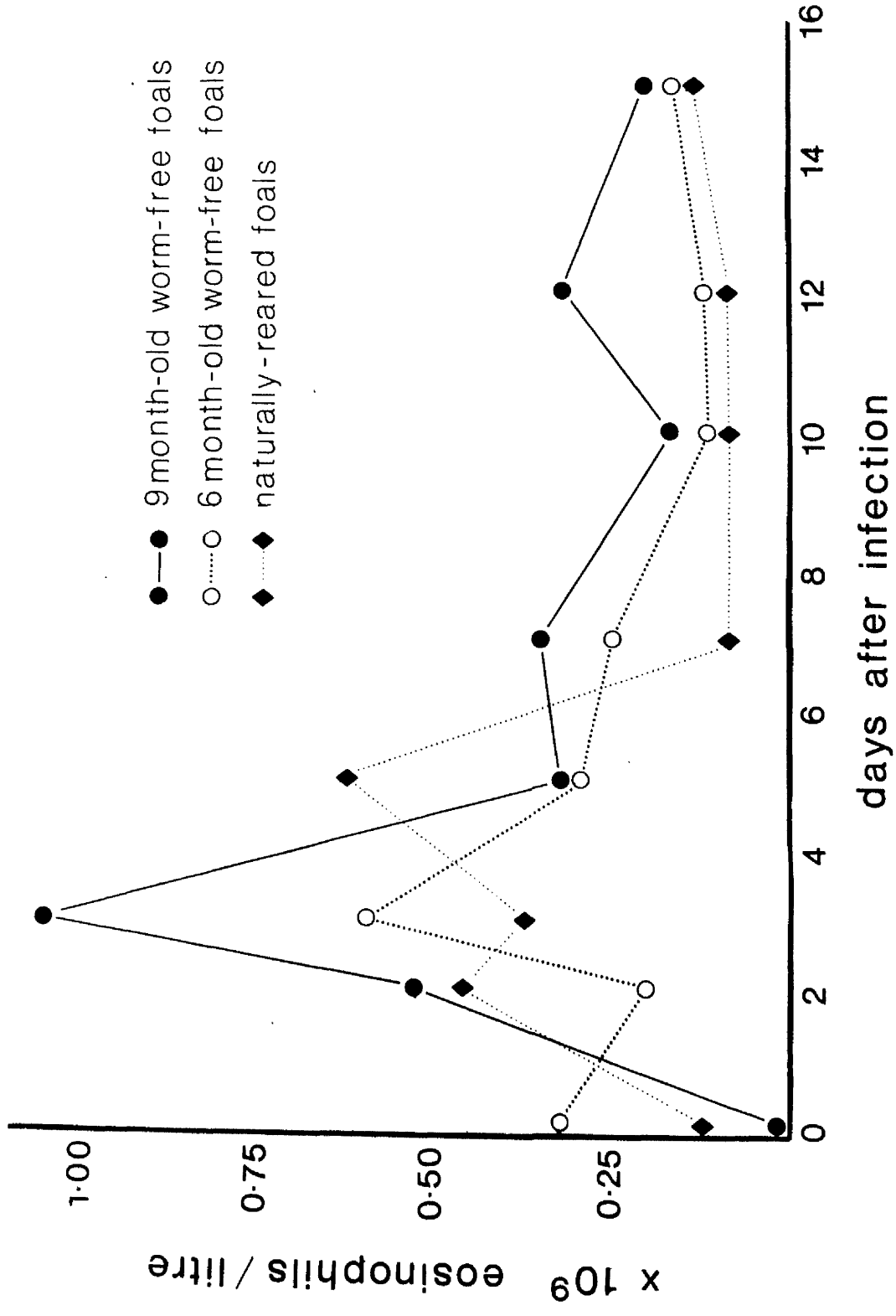


FIGURE 65 Circulating eosinophil counts of foals after infection with 8,000 *P. equorum* eggs.

whereas 23 and 37 days after a similar infection the younger animals had small intestinal burdens of 2,090 and 4,150 P. equorum respectively. In addition, the pathological changes in the liver and the lungs were both more numerous and more severe in the older animals possibly indicating that the majority of infective larvae died or were destroyed in these organs before reaching the intestinal tract. The 5 larger parasites recovered from the naturally reared foal killed on day 30 were probably acquired at grass and may not have completed their tissue migration at the time of anthelmintic treatment.

In the 12 month-old foal killed 14 days after infection the majority of larvae were present in the lung parenchyma, very few being found in the airways and none in the small intestine. In contrast, a young foal killed at this time had many parasites in the airways and a small number had already returned to the small intestine. Another young foal killed on day 23 had larvae in the parenchyma but not in the airways, suggesting that migration in the trachea had been completed. As a result of these findings in the younger animals it was postulated that those parasites which remained in the pulmonary parenchyma on day 23 were the target of an immunological response and would be destroyed in the lungs to form the basis of the lymphocytic pulmonary nodules. A similar situation probably existed in the older animals in that only a small number of worms returned to the small intestine, but the hepatic and pulmonary lesions increased in number and severity.

In the liver, lymphoid accumulations and granulomata with a central core of necrotic debris were present in the older animals, and the latter lesions were identical to the inflammatory reaction which has been described in association with dead parasitic larvae

of many species (Nieberle and Cohrs, 1967). Similarly, the subpleural lymphocytic nodules in the lungs, which were thought to represent the reaction around dead larvae (Nieberle and Cohrs, 1967), were increased in number. In the present study, the number and type of pathological lesions did not show any variation between the 6 to 12 month-old, worm-free foals, and the 7 to 8 month-old naturally reared foals which were experiencing a reinfection. It would seem, therefore, that both groups were reacting similarly.

Clinically, there was a fairly severe pneumonic syndrome in some of the older foals during the third week after infection. The radiographic changes of mottling and increased density with accentuation of the bronchi suggested an interstitial reaction, but this remains speculative since histopathological examination was not performed at this time. Clinically and radiographically the pulmonary changes had resolved by day 31 and this was supported by the pathological findings.

Loss of condition progressing to emaciation was a prominent feature in young foals infected with 8,000 P. equorum eggs, whereas the older animals maintained good to fat bodily condition throughout the experimental period. The weight gains of the 9 month-old animals were slower than those of the one month-old foals, but in many species the rate of increase in body weight has been shown to decrease with increasing age. The maintenance of good condition was consistent with the parasitological findings at post-mortem examination: the older animals killed on day 125 had totals of 0, 3, 22 and 52 P. equorum compared with the younger, unthrifty foals which had 3,195 ascarids on day 73, 751 on day 106 and 123 on day 146.

The two, 9 month-old foals developed patent infections, which persisted for less than 2 months. The prepatent periods were within

the range found in the younger animals, but the faecal egg counts were much lower. Peak values of 350 and 400 asc. e.p.g. were recorded in the older foals compared with 17,500 and 6,350 asc. e.p.g. in the young foals. In addition, one of the naturally reared animals had a count of 50 asc. e.p.g. on day 90 but was negative on all other occasions. Ascarid eggs were not found in the faeces of the other animals in the group, although at post-mortem examination the worms recovered were apparently mature and the reason for the failure to establish patent infections in these animals was not known. Other workers, including Baudet (1925) and Wetzel and Enigk (1938), have been unsuccessful in their attempts to establish patent P. equorum infections in mature horses. It has also been reported that foals tend to lose their patent ascarid infections from 6 months of age onwards (Russell, 1948; Bello et al., 1973) and surveys in various parts of the world have shown that the incidence of parascaris infection is inversely correlated with age (de Jesus and Uichanco, 1939; Langenegger et al., 1967; Poynter, 1970).

The eosinophilia in the older, worm-free group was similar in magnitude and duration to that recorded in the younger, worm-free foals. In the naturally reared animals the circulating eosinophilia was less marked, but these animals had a higher neutrophil/lymphocyte ratio. However, they had acquired a mixed strongyle burden at grass and since the anthelmintic used was not effective against migrating larvae, the alterations in the differential WBC count may have been due to the presence of strongyle larvae in the body tissues (Duncan and Dargie, 1975).

CONCLUSIONS

A group of 6 to 12 month-old foals, which had either been reared worm-free or reared naturally and subsequently treated with an anthelmintic, were infected with 8,000 P. equorum eggs. The clinical, pathological and haematological changes, together with the parasitic recoveries from these older animals were compared with those described in Chapters 2 and 3 in 2 to 4 week-old, worm-free foals.

The results showed the presence of a marked resistance to P. equorum infection by 6 months of age in both the worm-free and naturally reared animals. In both of these groups there was a significant decrease in the number of worms returning to the intestinal tract, while the number and severity of the lesions in the liver and lungs were increased when compared with the younger animals. It was thought that an immunological reaction was operating at the level of the parenchymatous organs with death of the larvae in these sites and a consequent reduction in the number of intestinal worms. In some cases the pulmonary reaction caused an interstitial pneumonia, but the development of a relatively small number of ascarids in the small intestine was not associated with unthriftiness or loss of condition. Patent infections developed in only 3 out of 6 older animals and the faecal egg counts tended to remain low.

GENERAL DISCUSSION AND CONCLUSIONS

The work described in this thesis was undertaken in order to assess the importance of Parascaris equorum infection in the foal, since there is a dearth of information regarding the pathogenic significance of this parasite.

It has been confirmed that the larvae of P. equorum undergo a hepatic-tracheal route of migration and prepatent periods in the range of 80 to 104 days were recorded. It was concluded that P. equorum may have a significant pathogenic effect in young foals involving a mild respiratory syndrome during larval migration through the pulmonary system, followed by unthriftiness and poor weight gains due to the presence of a large mass of developing ascarids in the intestinal lumen. The main hepatic changes consisted of an infiltration of eosinophils and lymphocytes and fibrosis, particularly around the portal triads. In the lungs there was a cellular infiltration, particularly around the small blood vessels and airways, consisting primarily of eosinophils which were later replaced by lymphocytes. In addition raised, lymphocytic nodules found on the surface of the lungs were thought to have developed around dead ascarid larvae. A circulating eosinophilia was present at the time of the hepatic and pulmonary infiltration by eosinophils.

In foals over 6 months of age, irrespective of whether they had previous experience of P. equorum infection, there was an age-dependent immunity. This apparently resulted in the death of the larvae in the liver and the lungs, only a few returning to the intestine. In these older animals the respiratory disease associated with the pulmonary reaction to the migrating larvae was not necessarily followed by unthriftiness or the development of patency.

Observations in the field have suggested that transmission of P. equorum from adult horses to foals is not an important factor in the epidemiology, and the occurrence of a periparturient rise in the ascarid faecal egg count of mares has not been described. The fecundity of the worms, together with the notorious longevity of the ascarid eggs, suggests that the foal is the major source of infection for other foals born either later in the same year or in subsequent years. Little information is available regarding the action of anthelmintics against migrating ascarid larvae but as a result of the work described in this thesis it is recommended that foals be treated from about 6 weeks of age with an anthelmintic known to be effective against intestinal ascarids. This will prevent the development of patent infections and so reduce the infection level available to other foals, and will also minimise the clinical signs of unthriftiness in individual animals.

APPENDICES

APPENDIX 1

PACKED CELL VOLUMES (1/1 RATIO)
AFTER INFECTION OF FOALS WITH P. EQUORUM EGGS

Weeks after infection	160 <u>P. equorum</u> eggs		8,000 <u>P. equorum</u> eggs		10 x 160 <u>P. equorum</u> eggs		Uninfected Controls	
0	0.32	0.33	0.37	0.39	0.36	0.36	0.33	0.33
1	0.30	0.32	0.36	0.37	0.32	0.35	0.34	0.32
2	0.26	0.28	0.40	0.35	0.31	0.32	0.34	0.27
3	0.27	0.27	0.35	0.32	0.29	0.32	0.32	0.26
4	0.23	0.29	0.32	0.36	0.27	0.31	0.30	0.28
5	0.25	0.32	0.39	0.39	0.31	0.33	0.36	0.32
6	-	0.28	-	0.35	-	0.31	0.30	0.29
7	-	0.29	-	0.36	-	0.29	0.33	0.29
8	-	0.29	-	0.37	-	0.33	0.30	0.30
9	-	0.31	-	0.37	-	0.32	0.31	0.29
10	-	0.30	-	0.40	-	0.34	0.30	0.32
11	-	0.31	-	0.37	-	0.30	0.30	0.30
12	-	0.31	-	0.36	-	0.33	0.33	0.31
13	-	0.29	-	0.35	-	0.28	0.29	0.30

APPENDIX 2

HAEMOGLOBIN VALUES (g/dl)
OF FOALS AFTER INFECTION WITH P. EQUORUM EGGS

Weeks after infection	160 <u>P. equorum</u> eggs		8,000 <u>P. equorum</u> eggs		10 x 160 <u>P. equorum</u> eggs		Uninfected Controls	
	0	12.7	12.6	14.4	14.4	14.0	14.3	12.3
1	11.4	12.6	14.3	14.0	13.5	14.0	14.0	11.7
2	7.5	11.4	13.7	12.6	12.9	12.0	13.1	10.8
3	10.3	10.6	16.8	14.3	11.4	12.3	12.9	10.0
4	9.8	12.2	12.9	12.6	11.0	11.7	12.6	10.8
5	9.1	12.8	13.5	13.2	11.4	12.0	13.7	12.3
6	-	11.6	14.8	14.8	-	11.7	12.4	10.6
7	-	11.8	-	13.5	-	12.6	13.4	12.1
8	-	11.4	-	14.9	-	12.9	11.4	11.8
9	-	12.6	-	14.6	-	12.9	12.8	12.0
10	-	12.9	-	14.7	-	14.0	11.7	12.1
11	-	12.0	-	15.5	-	11.2	12.0	11.7
12	-	11.8	-	14.3	-	12.3	12.6	11.5
13	-	10.6	-	13.8	-	10.2	10.9	11.2

APPENDIX 3

TOTAL RED BLOOD CELL COUNTS ($\times 10^{12}/1$)
OF FOALS AFTER INFECTION WITH P. EQUORUM EGGS

Weeks after infection	160 <u>P. equorum</u> eggs		8,000 <u>P. equorum</u> eggs		10 x 160 <u>P. equorum</u> eggs		Uninfected Controls	
	0	10.8	7.4	13.7	9.6	9.7	8.6	7.4
1	11.2	7.3	11.7	10.7	10.2	9.3	9.4	9.5
2	9.3	7.4	11.0	8.8	8.8	7.4	9.1	6.7
3	6.8	5.8	7.0	7.7	6.6	7.0	6.6	5.4
4	6.5	9.4	8.9	9.3	7.3	7.3	8.2	6.7
5	7.1	7.1	10.0	9.4	7.9	7.8	9.1	-
6	-	6.5	-	8.4	-	6.7	8.1	6.7
7	-	6.7	-	9.4	-	7.6	9.0	6.4
8	-	6.7	-	9.0	-	7.3	8.1	7.0
9	-	7.6	-	9.9	-	9.1	8.1	8.9
10	-	7.3	-	9.9	-	10.2	7.5	7.0
11	-	7.0	-	8.8	-	7.2	8.0	6.6
12	-	7.6	-	7.7	-	9.0	7.0	7.2
13	-	6.9	-	-	-	10.4	7.1	6.6

APPENDIX 4

TOTAL WHITE BLOOD CELL COUNTS ($\times 10^9/1$)
OF FOALS AFTER INFECTION WITH P. EQUORUM EGGS

Weeks after infection	160 <u>P. equorum</u> eggs		8,000 <u>P. equorum</u> eggs		10 x 160 <u>P. equorum</u> eggs		Uninfected Controls	
	0	14.8	10.3	10.6	16.1	14.7	12.6	9.6
1	11.7	11.1	13.4	15.4	15.2	11.9	11.2	18.4
2	9.2	14.8	9.8	13.9	13.3	9.1	7.6	13.9
3	9.2	9.9	10.4	15.6	15.3	10.6	6.9	13.7
4	9.9	11.7	9.0	17.1	12.1	9.6	7.4	13.2
5	11.0	9.4	10.8	17.3	15.7	13.8	8.3	13.3
6	-	8.8	-	12.2	-	10.5	7.5	16.1
7	-	10.8	-	18.2	-	10.9	7.3	16.2
8	-	8.9	-	16.7	-	12.4	6.5	13.4
9	-	9.6	-	19.2	-	11.2	6.7	14.6
10	-	9.2	-	17.2	-	11.4	6.8	16.9
11	-	11.4	-	20.9	-	9.3	7.8	16.7
12	-	14.1	-	18.8	-	13.3	9.3	21.0
13	-	9.1	-	14.2	-	7.8	5.8	13.7

APPENDIX 5

FAECAL EGG COUNTS (asc. e.p.g.)
OF FOALS AFTER INFECTION WITH P. EQUORUM EGGS

Days after Infection	160 <u>P. equorum</u> eggs	8,000 <u>P. equorum</u> eggs	10 x 160 <u>P. equorum</u> eggs	Uninfected Controls	
80	400	0	0	0	0
83	1,100	100	0	0	0
87	650	150	0	0	0
90	1,650	200	0	0	0
93	1,100	300	0	0	0
95	700	350	0	0	0

No parasite eggs were found in faecal samples examined before day 80.

APPENDIX 6

BODY WEIGHTS (Kgs) OF FOALS
AFTER INFECTION WITH 8,000 P. EQUORUM EGGS

Weeks after Infection	Infected Foals								Controls	
	F1	F2	F3	F4	F5	F6	F7	F8	C1	C2
-1	67	34	27	41	39	35	32	42	31	44
0	71	39	31	46	40	41	34	45	34	46
1	-	-	33	46	45	43	36	46	36	48
2	-	-	37	49	48	46	40	48	37	49
3	-	-	-	60	53	57	46	55	46	64
4	-	-	-	-	57	60	47	58	50	66
5	-	-	-	-	58	61	47	59	49	68
6	-	-	-	-	-	63	48	61	49	68
7	-	-	-	-	-	62	47	63	49	65
8	-	-	-	-	-	63	45	61	49	65
9	-	-	-	-	-	59	44	59	48	64
10	-	-	-	-	-	58	44	58	47	64
11	-	-	-	-	-	-	44	58	48	64
12	-	-	-	-	-	-	46	58	58	64
13	-	-	-	-	-	-	45	55	56	64
14	-	-	-	-	-	-	48	64	59	70
15	-	-	-	-	-	-	-	66	63	74
16	-	-	-	-	-	-	-	66	65	80
17	-	-	-	-	-	-	-	69	64	80
18	-	-	-	-	-	-	-	66	69	84
19	-	-	-	-	-	-	-	59	67	83

APPENDIX 7

FAECAL EGG COUNTS (asc. e.p.g.)
OF FOALS AFTER INFECTION WITH 8,000 P. EQUORUM EGGS

Days after Infection	Infected Foals		Controls	
	F7	F8	C1	C2
101	0	150	0	0
104	550	800	0	0
108	-	600	0	0
111	-	0	0	0
115	-	100	0	0
118	-	400	0	0
122	-	12,500	0	0
124	-	17,500	0	0
127	-	15,500	0	0
129	-	2,200	0	0
132	-	50	0	0
136	-	1,550	0	0
139	-	750	0	0
141	-	1,300	0	0
143	-	900	0	0
147	-	2,500	0	0

No parasite eggs were found in faecal samples examined before day 101.

APPENDIX 8

PACKED CELL VOLUMES (1/1 RATIO)
OF FOALS AFTER INFECTION WITH 8,000 P. EQUORUM EGGS

Weeks after Infection	Infected Foals								Controls	
	F1	F2	F3	F4	F5	F6	F7	F8	C1	C2
-1	0.37	0.45	0.34	0.48	0.43	0.39	0.35	0.40	0.45	0.47
0	0.36	0.44	0.31	0.45	0.40	0.38	0.39	0.37	0.41	0.47
1	-	0.43	0.31	0.42	0.37	0.40	0.34	0.37	0.45	0.43
2	-	-	0.31	0.42	0.37	0.40	0.34	0.37	0.43	0.40
3	-	-	-	0.42	0.40	0.38	0.37	0.35	0.39	0.42
4	-	-	-	-	0.34	0.37	0.30	0.34	0.39	0.37
5	-	-	-	-	0.37	0.32	0.29	0.31	0.41	0.38
6	-	-	-	-	-	0.41	0.27	0.31	0.39	0.38
7	-	-	-	-	-	0.42	0.30	0.29	0.38	0.41
8	-	-	-	-	-	0.40	0.33	0.30	0.37	0.36
9	-	-	-	-	-	0.40	0.31	0.33	0.36	0.41
10	-	-	-	-	-	0.39	0.28	0.33	0.35	0.34
11	-	-	-	-	-	-	0.27	0.33	0.38	0.33
12	-	-	-	-	-	-	0.28	0.34	0.33	0.39
13	-	-	-	-	-	-	0.32	0.34	0.32	0.39
14	-	-	-	-	-	-	0.28	0.27	0.32	0.37
15	-	-	-	-	-	-	-	0.31	0.29	0.37
16	-	-	-	-	-	-	-	0.29	0.28	0.35
17	-	-	-	-	-	-	-	0.31	0.31	0.35
18	-	-	-	-	-	-	-	0.32	0.27	0.28
19	-	-	-	-	-	-	-	0.29	0.30	0.33
20	-	-	-	-	-	-	-	0.29	0.34	0.33

APPENDIX 9

HAEMOGLOBIN VALUES (g/dl)
OF FOALS AFTER INFECTION WITH 8,000 P. EQUORUM EGGS

Weeks after Infection	Infected Foals								Controls	
	F1	F2	F3	F4	F5	F6	F7	F8	C1	C2
-1	14.3	15.5	13.2	17.8	15.5	14.9	13.4	13.8	16.0	16.1
0	14.0	18.2	12.9	18.5	15.4	14.5	13.8	14.4	15.7	16.0
1	-	19.1	12.1	16.8	13.7	15.4	12.5	13.8	16.3	16.3
2	-	-	12.0	15.0	14.1	14.4	12.3	12.9	16.0	16.3
3	-	-	-	17.2	15.7	15.4	12.6	13.5	16.3	15.7
4	-	-	-	-	13.2	14.1	12.0	12.9	15.2	13.8
5	-	-	-	-	14.8	15.7	11.3	11.9	17.9	14.4
6	-	-	-	-	-	-	-	-	-	-
7	-	-	-	-	-	18.5	14.1	14.2	14.9	14.6
8	-	-	-	-	-	16.1	13.8	12.2	17.3	12.5
9	-	-	-	-	-	16.6	12.6	13.2	16.3	17.2
10	-	-	-	-	-	15.7	12.0	13.2	15.0	15.5
11	-	-	-	-	-	-	11.9	14.1	16.3	15.4
12	-	-	-	-	-	-	12.9	14.4	14.1	16.6
13	-	-	-	-	-	-	13.7	14.4	13.8	15.3
14	-	-	-	-	-	-	12.2	12.6	12.4	16.3
15	-	-	-	-	-	-	-	12.0	11.7	9.7
16	-	-	-	-	-	-	-	13.5	12.0	11.1
17	-	-	-	-	-	-	-	12.0	12.9	12.9
18	-	-	-	-	-	-	-	12.0	10.0	10.0
19	-	-	-	-	-	-	-	10.6	11.4	13.5
20	-	-	-	-	-	-	-	9.4	12.6	12.6

APPENDIX 10

TOTAL RED BLOOD CELL COUNTS ($\times 10^{12}/l$)
OF FOALS AFTER INFECTION WITH 8,000 P. EQUORUM EGGS

Weeks after Infection	Infected Foals								Controls	
	F1	F2	F3	F4	F5	F6	F7	F8	C1	C2
-1	9.4	9.2	7.6	10.3	9.5	8.9	7.8	7.8	10.3	10.0
0	10.1	9.9	8.2	10.2	9.4	8.5	8.2	8.8	10.2	8.9
1	-	9.5	7.4	10.2	8.6	9.1	7.5	8.7	11.1	9.2
2	-	-	7.2	9.4	9.6	9.1	7.5	8.5	10.0	9.5
3	-	-	-	10.7	9.8	9.3	7.1	8.4	9.7	9.4
4	-	-	-	-	8.8	9.4	7.3	7.7	9.6	9.8
5	-	-	-	-	9.1	10.6	6.7	8.1	10.4	9.8
6	-	-	-	-	-	7.8	7.7	8.3	9.9	9.2
7	-	-	-	-	-	7.1	5.1	7.1	6.8	7.5
8	-	-	-	-	-	6.2	8.1	8.4	6.5	12.4
9	-	-	-	-	-	5.9	8.9	9.9	9.9	12.4
10	-	-	-	-	-	5.5	8.8	9.1	10.1	11.7
11	-	-	-	-	-	-	8.5	7.5	9.7	8.7
12	-	-	-	-	-	-	7.8	8.0	9.2	9.3
13	-	-	-	-	-	-	9.2	8.1	9.0	11.2
14	-	-	-	-	-	-	8.6	7.2	10.8	9.6
15	-	-	-	-	-	-	-	8.0	12.8	9.7
16	-	-	-	-	-	-	-	7.5	9.1	9.0
17	-	-	-	-	-	-	-	9.3	10.9	10.7
18	-	-	-	-	-	-	-	9.3	7.9	10.3
19	-	-	-	-	-	-	-	8.0	9.9	10.1
20	-	-	-	-	-	-	-	-	9.6	8.1

APPENDIX 11

TOTAL WHITE BLOOD CELL COUNTS ($\times 10^9/1$)
OF FOALS AFTER INFECTION WITH 8,000 P. EQUORUM EGGS

Weeks after Infection	Infected Foals								Controls	
	F1	F2	F3	F4	F5	F6	F7	F8	C1	C2
-1	12.6	7.9	14.4	12.1	10.3	7.0	11.0	10.5	9.1	7.7
0	11.1	10.4	9.7	10.6	14.3	6.7	11.6	7.0	8.4	10.7
1	-	6.9	10.1	10.3	13.4	10.5	10.9	8.0	--	12.6
2	-	-	10.8	7.2	13.2	9.5	10.7	9.2	11.2	9.6
3	-	-	-	15.3	16.2	9.7	13.3	10.5	12.5	9.5
4	-	-	-	-	13.2	12.2	12.1	10.8	11.6	11.0
5	-	-	-	-	16.2	10.4	13.9	9.3	14.7	8.3
6	-	-	-	-	-	7.7	14.6	8.7	10.6	12.1
7	-	-	-	-	-	14.3	14.8	9.8	14.6	10.0
8	-	-	-	-	-	11.3	14.0	10.4	13.6	12.1
9	-	-	-	-	-	7.9	13.0	8.5	10.7	11.0
10	-	-	-	-	-	7.9	13.3	8.0	12.5	10.4
11	-	-	-	-	-	-	12.2	10.5	11.4	11.2
12	-	-	-	-	-	-	13.9	9.8	11.2	10.6
13	-	-	-	-	-	-	10.5	9.6	10.5	10.3
14	-	-	-	-	-	-	8.9	15.3	11.8	10.9
15	-	-	-	-	-	-	-	11.5	9.6	10.5
16	-	-	-	-	-	-	-	8.8	12.5	18.8
17	-	-	-	-	-	-	-	9.3	15.4	11.3
18	-	-	-	-	-	-	-	9.9	11.0	10.3
19	-	-	-	-	-	-	-	8.8	17.1	11.0
20	-	-	-	-	-	-	-	14.2	11.0	8.7

REFERENCES

- Allam, N.M. and Lemcke, R.M. (1974)
 In International Congress on Mycoplasmas of Man, Animals, Plants
 and Insects. Abstracts volume. University of Bordeaux, France.
- Allam, N.M. and Lemcke, R.M. (1975)
 Journal of Hygiene, 74, 385-407.
- Allam, N.M., Powell, D.G., Andrew, B.E. and Lemcke, R.M. (1973)
 Veterinary Record, 93, 402.
- Allen, B.V. and Archer, R.K. (1972)
 Equine Veterinary Journal, 4, 217-222.
- Anschau, M. and Exner, H. (1953)
 Wiener tierärztliche Monatsschrift, 40, 612-619.
- Antipin, D.N. (1940)
 Vestnik sel'skokhozyaistvennoĭ nauki Veterinariya, 17, 46-64.
- Antipin, D.N. and Stepanova, E.V. (1948)
 Sbornik rabot po Gel'mint. Ed K.I. Abuladze, Moscow, pp. 25-43.
- Araujo, P. (1972)
 Rivista do Instituto de Medicina Tropical de Sao Paulo, 14, 83-90.
- Archer, R.K. and Poynter, D. (1957)
 Journal of Comparative Pathology and Therapeutics, 67, 196-207.
- Basten, A., Boyer, M.H. and Beeson, P.B. (1970)
 Journal of Experimental Medicine, 131, 1271-1287.
- Baudet, E.A.R.F. (1925)
 Tijdschrift voor diergeneeskunde, 52, 407-416.
- Bello T.R., Amborski, G.F., Torbert, B.J. and Greer, G.J. (1973)
 American Journal of Veterinary Research, 34, 771-777.
- Breeze, R.G., Pirie, H.M., Dawson, C.O., Selman, I.E. and
 Wiseman, A. (1975)
 Folia Veterinaria Latina, 5, 95-128.
- Burrows, R. (1968)
 Proceedings of the 1st international Conference on Equine Infectious
 Diseases, Stresa 1966, pp. 122-130. Grayson Foundation, Inc.
 Lexington, KY.

- Burrows, R. (1968)
Equine Veterinary Journal, 1, 32-44.
- Chebotar'ov, R.S. (1950)
Trudy Instituta zoologii. Academiya nauk Ukrainскої SSR, 4, 100-107.
- Copeman, D.B. (1971)
Dissertation Abstracts International, 32b, 1045.
- Dacie, J.V. and Lewis, S.M. (1966)
In Practical Haematology 3rd Edition. J. & A. Churchill Ltd., London.
- Darbyshire, J.H. and Pereira, H.G. (1964)
Nature, 201, 895-897.
- de Jesus, Z. and Uichanco, J.B. (1939)
The Philippine Journal of Animal Industry, 6, 435-446.
- Douvres, F.W., Tromba, F.G. and Malakatis, G.M. (1969)
Journal of Parasitology, 55, 689-712.
- Doxey, D.L. (1977)
Veterinary Record, 100, 555-556.
- Drudge, J.H. and Lyons, E.T. (1977)
The Blue Book, 27, 267-275.
- Drudge, J.H., Lyons, E.T. and Szanto, J. (1966)
In Biology of Parasites. Ed. E.J.L. Soulsby. Academic Press, New York.
- Duncan, J.L. and Dargie, J.D. (1975)
Journal of the South African Veterinary Association, 46, 81-85.
- Duncan, J.L. and Pirie, H.M. (1975)
Research in Veterinary Science, 18, 82-93.
- Eckert, J. (1973)
In Helminth Diseases of Cattle, Sheep and Horses in Europe.
Ed. G.M. Urquhart and J. Armour. The University Press, Glasgow.
- Egyed, M. and Hollo, F. (1956)
Acta veterinaria hungarica, 6, 419-427.
- Enigk, K. (1951)
Zeitschrift für Tropenmedizin und Parasitologie, 2, 523-535.

- Enigk, K. (1970)
Proceedings of the 2nd International Conference on Equine Infectious Diseases, Paris 1969, pp. 259-268. Karger, Basel/München/New York.
- Enigk, K., Doy-Hazra, A. and Batke, J. (1974)
Deutsche Tierärztliche Wochenschrift, 81, 605-607.
- Fairbairn, D. (1957)
Experimental Parasitology, 6, 491-554.
- Francis-Smith, K. and Wood-Gush, D.G.M. (1977)
Equine Veterinary Journal, 9, 155-157.
- Ferguson, D.L., Mebus, C.A. and Twiehaus, M.J. (1968)
American Journal of Veterinary Research, 29, 233-243.
- Gordon, H.McL. and Whitlock, H.V. (1939)
Journal of the Council of Scientific and Industrial Research, 12, 50.
- Greenway, J.A. and McCraw, B.M. (1970)
Canadian Journal of Comparative Medicine, 34, 238-246.
- Greer, G.J., Bello, T.R. and Amborski, G.F. (1974)
Journal of Parasitology, 60, 466-472.
- Hadley, F.B. (1943)
Veterinary Medicine, 38, 88-90.
- Hadwen, S. (1925)
Journal of Parasitology, 12, 1-11.
- Hooker, J.M. and Butler, M. (1976)
Journal of Comparative Pathology, 86, 87-92.
- Jarrett, W.F.H., McIntyre, W.I.M. and Sharp, N.C.C. (1962)
American Journal of Veterinary Research, 23, 1183-1191.
- Jarrett, W.F.H., McIntyre W.I.M. and Urquhart, G.M. (1957)
Journal of Pathology and Bacteriology, 73, 183-193.
- Jarrett, W.F.H. and Sharp, N.C.C. (1963)
Journal of Parasitology, 49, 177-189.
- Kelley, G.W., Olsen, L.S. and Hoerlein, A.B. (1958)
American Journal of Veterinary Research, 19, 401-404.

- Kondak, M. (1964)
Acta Parasitologica Polonica, 12, 93-95.
- Lang, L. (1948)
Tierärztliche Umschau, 3, 181.
- Langenegger, J., Matamoros, M.A.J. and Urbina, J.R.A. (1967)
Veterinaria, Rio de Janeiro, 20, 115-120.
- Lebailly, J. and Cadillac, G. (1957)
Revue du Corps Vétérinaire de L'Armée, Paris, 12, 12-13.
- Lyons, E.T., Drudge, J.H. and Tolliver, S.C. (1976)
Journal of Parasitology, 62, 453-459.
- McBarron, E.J. (1948)
Yearbook, Institute of Inspectors of Stock of New South Wales,
83, 85.
- McCraw, B.M. and Slocombe, J.O.D. (1974)
Canadian Journal of Comparative Medicine, 38, 124-138.
- Mackenzie, A. (1958)
Veterinary Record, 80, 843-906.
- Mahmoud, A.A.F., Warren, K.S. and Peters, P.A. (1975)
Journal of Experimental Medicine, 142, 805-813.
- Matoušek, J. (1937)
Spisy Vysoké školy zvěrolékařské, Brno, 14, 153-156.
- Michel, J.F. and Mackenzie, A. (1965)
Research in Veterinary Science, 6, 344-395.
- Neill, D.W. (1973)
In Joyce-Loebl Review, Team Valley, Gateshead. Spring Number.
- Nevenić, V. (1952)
Acta veterinaria, Belgrade, 2, 205-208.
- Nickel, E.A. (1960)
Berliner und Münchener tierärztliche Wochenschrift, 73, 265-270.

- Nieberle, K. and Cohrs, P. (1967)
In Textbook of the Special Pathological Anatomy of Domestic
Animals. Translated by R. Crawford. Pergamon Press, New York.
- Ogbourne, C.P. and Duncan, J.L. (1977)
Commonwealth Institute of Helminthology Miscellaneous Publication
No. 4.
- Oldham, J.N. and White, E.G. (1944)
Journal of Comparative Pathology and Therapeutics, 54, 1-15.
- O'Nuallain, T. (1973)
In Helminth Diseases of Cattle, Sheep and Horses in Europe.
Ed. G.M. Urquhart and J. Armour. The University Press, Glasgow.
- Orr, J.P. (1972)
Veterinary Record, 90, 571.
- Pick, E. and Turk, J.L. (1972)
Clinical and Experimental Immunology, 10, 1-23.
- Pirie, H.M., Doyle, J.M., McIntyre, W.I.M. and Armour, J. (1971)
In Pathology of Parasitic Diseases. Purdue University Press,
Indiana.
- Poynter, D. (1970)
Proceedings of the 2nd International Conference on Equine Infectious
Diseases, Paris 1969, pp. 269-289. Karger, Basel/München/New York.
- Rashek, V.A. (1964)
Byulleten' Moskovskogo obshchestva ispytatelei prirody, 69, 128-129.
- Roberts, F.S.H. (1934)
Queensland Department of Agriculture and Stock Animal Health Station,
Yeerongpilly, Bulletin No. 1, pp. 1-81.
- Ronéus, O. (1971)
In Pathology of Parasitic Diseases. Purdue University Studies,
Indiana.
- Round, M.C. (1968)
Research in Veterinary Science, 2, 583-590.

- Round, M.C. (1970)
Proceedings of the 2nd International Conference on Equine
Infectious Diseases, Paris 1969, pp. 290-303. Karger,
Basel/München/New York.
- Round, M.C. (1972)
Ph.D. Thesis. University of Cambridge.
- Russell, A.F. (1948)
Journal of Comparative Pathology, 58, 107-127.
- Ryazantsev, V.F. (1956)
Veterinariya, 33, 47.
- Rylands, J.M. (1971)
Veterinary Record, 88, 587.
- Salisbury G.W., Baker, D.W. and Britton, J.W. (1940)
Cornell Veterinarian, 30, 367-375.
- Schwartz, B. (1959)
American Journal of Veterinary Research, 20, 7-13.
- Simpson, C.F., Wade, A.E., Dennis, W.R. and Swanson, L.E. (1957)
American Journal of Veterinary Research, 18, 747-755.
- Swerczek, T.W., Nielsen, S.W. and Helmboldt, C.F. (1971)
American Journal of Veterinary Research, 32, 89-92.
- Taffs, L.F. (1969)
British Veterinary Journal, 125, 304-310
- Theiler, A. (1918)
In The seventh and eighth reports of the Director of Veterinary
Research Union of South Africa. Cape Town Government Printers.
- Todd, J.D. (1969)
Journal of the American Veterinary Medical Association, 155, 387-390.
- Todd, A.C., Hanson, M.F., Kelley, G.W., Wyant, Z.N. and Hull, F.E.
(1949)
Bulletin of the Kentucky Experimental Station, No. 536, p. 16

Tolobaev, M. (1975)
Veterinariya, 2, 76-79.

Underdahl, N.R. and Kelley, G.W. (1957)
Journal of the American Veterinary Medical Association, 130,
173-176.

Varga, I. (1973)
In Helminth Diseases of Cattle, Sheep and Horses in Europe.
Ed. G.M. Urquhart and J. Armour. The University Press, Glasgow.

Warren, E.G. (1971)
International Journal of Parasitology, 1, 85-99.

Weichselbaum, T.E. (1946)
American Journal of Clinical Pathology, Technical Section, 10,
40-49.

Wetzel, R. and Enigk, K. (1938)
Deutsche tierärztliche Wochenschrift, 46, 806-807.

Wiltshire, F.H. (1954)
Australian Veterinary Journal, 30, 22-24.

Yutuc, L.M. (1954)
Journal of Parasitology, 40, Supplement, 18-19.