



Clark, Mairi (2018) *A new experimental rodent model of cerebral palsy and foregut dysmotility*. MD thesis.

<https://theses.gla.ac.uk/30649/>

Copyright and moral rights for this work are retained by the author

A copy can be downloaded for personal non-commercial research or study, without prior permission or charge

This work cannot be reproduced or quoted extensively from without first obtaining permission in writing from the author

The content must not be changed in any way or sold commercially in any format or medium without the formal permission of the author

When referring to this work, full bibliographic details including the author, title, awarding institution and date of the thesis must be given

Enlighten: Theses

<https://theses.gla.ac.uk/>
research-enlighten@glasgow.ac.uk

A New Experimental Rodent Model
of Cerebral Palsy and Foregut Dysmotility

Mairi Clark (née Steven)

MBChB BSc (Med Sci) Hons FRCS (Paed Surg)

Submitted for the degree of MD,
University of Glasgow

Research conducted at the Central Research Facility,
University of Glasgow

Submitted June 2018

©Mairi J Steven

Abstract

Background: Children with cerebral palsy often suffer from inability to tolerate enteral feeds. This may manifest as retching, vomiting, abdominal pain and faltering weight (previously referred to as failure to thrive). This study has three stages the aim of the first stage was to develop and establish an animal model of cerebral palsy (CP) and foregut dysmotility so as to better understand the clinical association seen in paediatric practice and to develop new therapies for this condition in the future. The second stage involved performing an experimental technique of splanchnectomy to assess whether this could be used as a surgical tool for such patients who fail to respond to conventional therapy. The third and final stage involved an examination of human biopsies from children with CP and known foregut dysmotility.

Methods: Ethical approval was obtained in accordance with the Animals (Scientific Procedures) Act 1986 (PPL 60/4262). In phase one neonatal Sprague-Dawley rat pups aged postnatal days 5-6 (P5-6) underwent midline craniotomies under anaesthesia to allow either unilateral or bilateral brain injections of the neurotoxin, ibotenic acid (IBA), in the medial prefrontal (MPFC) or insular cortex (IC) using a digital stereotaxic frame. P5-6 was chosen as this has been shown to correspond to the stage of white matter vulnerability and that neurotoxin injections at this stage can mimic lesions that appear histologically similar to human peri-ventricular white matter injury as seen in cerebral palsy. A further group underwent sham injections with normal saline. All animals were monitored with a modified APGAR score post-operatively. Gastric emptying studies were then performed between 7 and 21 days postoperatively to look for any delay in gastric emptying times (GET) and animals were weighed regularly. GET was recorded by gavaging water soluble contrast and performing time lapsed x-rays. The pups were perfused on day 28 of life and their brains and foregut were examined. Phase two then involved repeating the creation of our CP model and performing unilateral splanchnectomy via a midline laparotomy to investigate whether we could improve the GET in our model. In both phase 1 and phase 2 immunohistochemistry was performed looking at several antibodies to compounds implicated in the pathogenesis of dysmotility. In phase three, a retrospective analysis of archived human biopsies from children with CP and dysmotility was performed.

Main results: In Phase 1 forty-five pups were injected in total (28 male and 17 female). The median weight at time of operation was 13.5 grams (range 7.5-21 grams). Four pups

died at the start of the study two intra-operatively from haemorrhage and two in the immediate post-operative period presumably from anaesthetic complications. GET was significantly prolonged in each IBA group compared to shams, and interestingly 5 out of 6 of those with bilateral MPFC lesions demonstrated reflux during their contrast studies. In Phase 2, twenty-six rat pups were injected (14 female and 12 male). 13 pups underwent IBA injection and 13 sham injections. One pup died post brain injection from postoperative apnoea, the remainder progressed to splachnectomy. Two pups, one from each group, died post laparotomy from intraoperative bleeding. The median GET was significantly longer in the CP model 58 minutes compared to 45 minutes ($p=0.0024$). Splachnectomy reduced the GET in the CP group to 40.5 minutes ($p<0.0001$) Our results from phase 3 revealed that we were unable to compare our animal specimens to our cohort of archived human biopsies. The reasons for this are discussed in detail.

Conclusion: In conclusion, we have developed a new and reproducible animal model of cerebral palsy and foregut dysmotility. We have shown that lesions in the brain cortex can lead to structural changes in villous and crypt architecture in the gut and that splachnectomy improves gastric emptying in our model. Further work needed is needed to explore the mechanistic pathways and provide insight into the pathogenesis of impaired gastrointestinal motility in cerebral palsy and may lead to much needed development of new treatments.

Dedication

I would like to dedicate this thesis to my husband, Ross, without whom nothing in my life would be possible. Also to my amazing boys, Lewis and Rory, who without a doubt are my greatest achievement. To my sister, Annie whose thesis inspired me to finally write this. To my brother, Paul whose bravery and courage set me on a career in medicine in the first place and lastly to my parents for giving me the best possible to start in the world and supporting me tirelessly.

Table of Contents

Abstract	2
Dedication	4
List of Tables.....	6
List of Figures	7
Acknowledgements	9
Author's Declaration.....	10
Abbreviations	11
Chapter 1 Introduction	13
Chapter 2 Materials and Methods	52
Chapter 3 Results – Phase 1	78
Chapter 4 Results – Phase 2	111
Chapter 5 Results – Phase 3	133
Chapter 6 Perspective and Limitations	141
References	146

List of Tables

Table 1.	Humoral factors that are involved in gastric emptying	23
Table 2.	Demeester scoring system for diagnosis of GORD using 24 pH probe testing	28
Table 3.	The effect of CB on gastric losses in patients in a neurosurgical intensive care unit.	40
Table 4.	The modified APGAR score.	58
Table 5.	Modified pathological scoring system for assessing intestinal specimens.	71
Table 6.	Mean weight gain of neonatal rat pups throughout Phase 1.....	80
Table 7.	Gastric emptying times comparing different brain lesions to those who underwent sham injections.	82
Table 8.	Table of microphotographs of HE Slides comparing foregut biopsies between unilateral and bilateral IBA MPFC lesioned animals and shams.	91
Table 9.	Comparative histological scoring of duodenal specimens only between the three groups: shams, unilateral MPFC injection and bilateral MPFC injection i.e. CP model	92
Table 10.	Table of microphotographs showing anti – CD117 IHC.	95
Table 11.	Results of IHC analysis comparing levels of staining for anti-iNOS antibody.	97
Table 12.	Results of IHC analysis comparing levels of staining for anti-ChAT antibody.	99
Table 13.	Results of IHC analysis comparing levels of staining for anti-Jagged1 antibody between the two groups.	101
Table 14.	Comparative histological scoring of duodenal specimens in phase 2.	119
Table 15.	Anti-iNOS antibody staining in phase 2.....	124
Table 16.	Results of IHC analysis for anti-ChAT antibody in phase 2.	126
Table 17.	Results of IHC analysis comparing levels of staining for anti-Jagged1 antibody between the two groups: our CP model (animals that had undergone bilateral MPFC IBA injections from phase 1 and the CP model that undergone splanchnectomy i.e. Phase 2.....	128

List of Figures

Figure 1.	A schematic diagram of some of the many factors that control normal gastric emptying and antroduodenal motility.	16
Figure 2.	Difference in gastric emptying rate depending on solid or liquid meal.	18
Figure 3.	Schematic diagram of the hierarchy of neural control on foregut motility from higher cerebral centres down to vagal centres and the intestinal wall and lumen.	22
Figure 4.	An upper GI study	27
Figure 5.	A typical trace from a pH/impedance study.	29
Figure 6.	High resolution manometry.	30
Figure 7.	Gastric emptying study using scintigraphy.	31
Figure 8.	Endoscopy.	32
Figure 9.	An illustration showing a 360 degree Nissen fundoplication.	37
Figure 10.	Technique of coeliac plexus block.	41
Figure 11.	Thoracoscopic splachnectomy	42
Figure 12.	Treatment algorithm.	43
Figure 13.	A schematic diagram illustrating the crux of our hypothesis	50
Figure 14.	Images from rodent gastric emptying studies	54
Figure 15.	Post-operative rat pup having undergone craniotomy and brain injection.	57
Figure 16.	Rat brain atlas figure of the medial prefrontal cortex.	62
Figure 17.	Rat brain atlas figure of the insular cortex.	64
Figure 18.	A neonatal rat pup in the stereotaxic frame.	65
Figure 19.	A timeline of phase 2 of the study.	66
Figure 20.	Intraoperative photograph showing midline laparotomy.	67
Figure 21.	Intraoperative view of the splanchnic nerves.	68
Figure 22.	Schematic diagram of the foregut specimens.	69
Figure 23.	Weight velocity of neonatal rat pups throughout Phase 1	79
Figure 24.	Images from gastric emptying studies of two pups.	81
Figure 25.	Forest plot comparing different sites of brain lesions and GET.	82
Figure 26.	Microphotograph of IC IBA lesion.	84
Figure 27.	Microphotograph showing cavitation in IC.	85
Figure 28.	Coronal section showing the MPFC in (A) a pup that had undergone a sham injection and (B) a pup that undergone a Left MPFC IBA injection.	86

Figure 29.	Another example of a left sided MPFC lesion again with the left side of the brain projected to the right of the page.....	86
Figure 30.	Microphotograph of left MPFC lesion.	87
Figure 31.	Increased glial cells in the MPFC following IBA injections.....	88
Figure 32.	Attempted Right sided MPFC lesion.....	89
Figure 33.	Comparison of duodenal specimens staining for the anti-iNOS antibody.	96
Figure 34.	Comparison of duodenal specimens stained with anti-ChAT.	98
Figure 35.	Comparison of duodenal specimens stained with anti-Jagged1.....	100
Figure 36.	Phase 2 Flow diagram	112
Figure 37.	Scatter XY graph showing weight velocity in phase 2.....	113
Figure 38.	Graph confirming our CP model in phase 2.....	115
Figure 39.	Graph showing splanchnectomy improves GET in our CP model.	115
Figure 40.	Splanchnectomy on shams and effect on GET.....	116
Figure 41.	Redressing the balance: GET of our CP model pre- and post-splanchnectomy.	116
Figure 42.	H&E of duodenal specimens in phase 2.....	118
Figure 43.	Anti-Human CD117 pre- and post splanchnectomy.	122
Figure 44.	Comparison of duodenal specimens pre- and post splanchnectomy.	123
Figure 45.	Comparison of duodenal specimens stained for anti-ChAT in phase 2.	125
Figure 46.	Comparison of duodenal specimens showing the typical staining for the anti-Jagged1 antibody in the specimens from our CP model post splanchnectomy compared to the phase 1 model that did not undergo splanchnectomy.	127
Figure 47.	Microphotographs showing duodenal endoscopic biopsies from patients with known CP, delayed gastric emptying and foregut dysmotility. FOV = field of view	138

Acknowledgements

I owe a huge debt of gratitude to the following people, for their help, advice and constant support.

- **Professor Robert Carachi MBE**, academic supervisor and retired Professor of Surgical Paediatrics, University of Glasgow, for his inspiration and supervision during my research and incredible mentorship throughout my surgical training.
- **Dr Simon Milling**, academic supervisor and Reader in immunology at the University of Glasgow, for all his guidance, encouragement and advice during my research.
- **Mr Colin Hughes**, Manager of the Central Research Facility, University of Glasgow and all his staff and technicians, for all their help and guidance in looking after the animals.
- **Mrs Jean Wilson**, assistant veterinary surgeon, Biological services, Veterinary Research Facility, for all her help and guidance and training in anaesthetic/surgical techniques for the rodent model.
- **Dr Gavin Clowry**, Senior Lecturer, Institute of Neuroscience, University of Newcastle, for all his help teaching me the technique of brain injections.
- **Dr Joshua Leach and Dr Francesco Marchesi**, Department of Veterinary Pathology, University of Glasgow, for their help analysing brain and foregut specimens.
- **Mrs Lynn Stevenson**, Senior Technician, Diagnostic Services, MVLS, School of Veterinary Medicine, University of Glasgow, for all her help and for conducting all immunohistochemistry of foregut specimens.
- **Dr Alex McConnachie**, Department of Biostatistics, University of Glasgow, for his help and advice with the statistical analysis.
- **Dr Dawn Penman**, Consultant Paediatric Pathologist, Royal hospital for Children, Glasgow, for her help and expertise analysing human biopsies.
- The Royal College of Physicians and Surgeons Glasgow as this work was kindly funded by the **Ritchie Trust Fellowship 2011/12**.

Author's Declaration

The experiments and writings within this thesis are my own and relate to research carried out by myself at the Central Research Facility, University of Glasgow. Other members of the research group who contributed to the laboratory and surgical work embodied in this thesis are specifically acknowledged above. The work has not been submitted for any other degree or other professional qualification.

Mairi Jane Clark (née Steven), June 2018

Abbreviations

ACC =	anterior cingulate cortex
ACh =	acetylcholine
AID =	agranular insular cortex dorsal
AIV =	agranular insular cortex ventral
AP =	anteroposterior
CB =	coeliac axis block
CCK =	cholecystokinin
Cg1 =	cingulate cortex
ChAT =	acetylcholinesterase
CNS =	central venous system
CP =	cerebral palsy
CV =	cresyl violet
DAB =	diaminobenzidine
DI =	dysgranular insular cortex
DV =	dorsal ventral
DVC =	dorsal vagal complex
ELISA =	enzyme-linked immunosorbent assay
ENS =	enteric nervous system
FOV =	field of view
GBA =	gut brain axis
GE =	gastric emptying
gEMB =	gastric endoscopic muscle biopsy
GET =	gastric emptying time
GIC =	granular insular cortex
GORD =	gastro-oesophageal reflux disease
HCl =	hydrochloric acid

Introduction

HE=	haematoxylin and eosin
HIER =	heat induced epitope retrieval
HMP =	human microbiome project
HRM =	high resolution manometry
HRP =	horse radish peroxidase
IBA =	ibotenic acid
IC =	insular cortex
ICC =	interstitial cells of Cajal
ICP =	intracranial pressure
IHC =	immunohistochemistry
IL =	infralimbic cortex
iNOS =	inducible nitric oxide synthase
LOS =	lower oesophageal sphincter
LP =	lamina propria
ML =	medial lateral
MMC =	Migrating myoelectric complex
MPFC =	medial prefrontal cortex
NBF =	neutral buffered formalin
NO =	nitric oxide
NTS =	nucleus tractus solitarius
NVS =	named veterinary surgeon
PFA =	paraformaldehyde
PPI =	proton pump inhibitor
PrL =	prelimbic cortex
PVL =	periventricular leukomalacia
TS =	thoracic splanchnectomy
VIP =	vasoactive intestinal peptide

Chapter 1

Introduction

1.1 The clinical problem

The role of a paediatric surgeon is demanding yet extremely rewarding. There are, however, certain groups of patients that present an enormous challenge not just to paediatric surgeons, but to paediatricians and indeed nursing staff and their carers alike; none more so, perhaps, than those children who are neurologically impaired with complex enteric feeding difficulties. Many of these patients suffer from cerebral palsy often as a result of extreme prematurity increasing the risk of white cerebral matter injury and/or intraventricular haemorrhage. In recent years with advancements in antenatal and neonatal care more and more children with cerebral palsy are surviving. (Babcock et al., 2009) Paediatricians have long recognized that many children with cerebral palsy have a poor quality of life because of severe retching, vomiting, and inability to tolerate feeds. (Reyes, Cash, Green, & Booth, 1993) We now live in an age of individualised health care which ought to be patient centred and evidence based, however, these children have very few options open to them. Those treatment options that do exist for such patients, whether it be medical or surgical, are often aimed at alleviating gastro-oesophageal reflux rather than improving motility and may in fact make some elements of intestinal dysmotility worse. In addition, as a group, these patients are difficult to study, let alone be entered into any form of randomised controlled trial. In fact, a recent Cochrane review concluded that no randomised control trial could be found in the existing worldwide literature with regards to the best way to manage enteral feeding issues in children with cerebral palsy and the need for such a study was highlighted. (Gantasala, Sullivan, & Thomas, 2013) Indeed, a similar Cochrane review in 2004 (Sleigh, Sullivan, & Thomas, 2004) found exactly the same almost ten years earlier and hence our impetus for developing a much needed animal model.

1.1.1 What is cerebral palsy?

Cerebral palsy was first described over 150 years ago by Little (Little 1862) and then clinically by Freud (Freud, 1897). Despite it now being over a century since its recognition there is no curative treatment or method of prevention and management strategies are limited. Cerebral palsy can be defined as “a group of disorders of the development of movement and posture causing activity limitations that are attributed to non-progressive disturbances that occurred in the developing foetal or infant brain” (Rosenbaum et al., 2007). As suggested by this commonly used definition and by the classification of cerebral palsy into hemiplegic, diplegic and quadriplegic cerebral palsy there is often much focus on the effect on movement (Kuban et al., 2008), however, it is widely recognised that many of these patients have problems with food intolerance, abdominal pain, vomiting and retching. These are the symptoms of foregut dysmotility and by this term we include a group of disorders that involve failure of the normal peristalsis of the gastro-intestinal tract. (V. V. Smith, 2001) Gastro-intestinal dysmotility remains a major problem in paediatric clinical practice especially in the treatment of neurologically impaired children. (Ravelli & Milla, 1998; Staiano, Cucchiara, Del Giudice, Andreotti, & Minella, 1991)

1.1.2 What causes cerebral palsy?

The cause of cerebral palsy is most likely multifactorial. There may be a history of anoxic brain injury either ante- or perinatally and this can lead to subsequent periventricular leukomalacia (PVL). PVL is commonly regarded as the heralding sign of a child being diagnosed with cerebral palsy. There are many theories as to why white matter injury or PVL occurs in preterm infants including maternal infection and high levels of glutamine (Follett et al., 2004) and raised interleukins in umbilical cord blood. (Minagawa et al., 2002) (Thomas & Speer, 2011) Other contributing factors may include low levels of thyroid hormone or glucocorticoids. The study of such contributing factors may prove helpful in identifying babies at risk and help to devise preventative strategies. (O'Shea, 2002) Indeed the recently conducted ELGAN (Extremely Low Gestational Age Newborns) study was a prospective study looking at inflammatory markers in the blood in the first two weeks of life in infants born before 28 weeks gestation and who were then diagnosed with cerebral palsy and who were clinically re-examined at 2 years of age. (Kuban et al., 2014) This study found that not only were raised levels of inflammatory markers on two separate days more than a week apart predictive of cerebral palsy, but also elevated protein levels corresponded to particular types of cerebral palsy.

More recently there has been increased focus on what is now referred to as the gut brain axis or GBA. The GBA is now believed to potentially play a pivotal role in the development of CP. Much of this work has followed on from new techniques using magnetic resonance imaging (MR) known as diffusion tensor tractography. Tractography is a 3D modelling technique which can identify neural tracts using data collected by diffusion weighted images. Not only can long tracts from the brain to the rest of the body be mapped but also the shorter connections between different cortical regions in the brain. It has been shown by tractography that in CP these networks are disrupted. (Englander et al., 2013) This concept is critical to the development of our animal model. Indeed there is evidence in the literature that changes in the medial prefrontal cortex can lead to functional disorders of the bowel such as IBS. (Seminowicz et al., 2010) (Tillisch & Labus, 2011) It is now also hoped that with advances in MRI technology that our understanding of the human connectome, the map of white matter containing the complex neural connections in the premature infant's brain, may become more detailed and accurate and help define further the cause of CP and predict clinical outcome. (Panigrahy et al., 2012)

It is not just the neural connections that have been investigated in CP but also there has been a vast project known as the Human Microbiome Project (HMP) which was a government funded project in the United States which involved the National Institutes of Health. This project aimed to identify the microorganisms which are found in association with healthy subjects and those suffering from different diseases, hence the term "the human microbiome". As part of the work done by the HMP, one study focused on analysing the faeces from preterm and term infants. The findings of this study called for further work into the bidirectional signalling along the GBA and that certain microbes in the gut are essential for a healthy symbiotic relationship between a healthy gut and a healthy developing brain. It therefore, implicated changes in the microbes in the gut of premature neonate with the development of CP and other neurodevelopmental disorders and raised the possibility that targeting certain bacteria may lead to new preventive measures for conditions such as CP. (Borre et al., 2014) The two concepts of the GBA and the human microbiome therefore go together and there is now the belief that potential gut-microbiome-brain communication may be pivotal in the aetiology of CP. It has been suggested that the sympathetic nervous system may in fact alter gut flora by means of adrenergic stimulation of enterocytes and this may in turn lead to increased gut permeability and possible damage to the developing brain. (Forsythe & Kunze, 2013)

1.2 What controls normal foregut motility?

In order to understand what may be causing dysmotility of the foregut in children with CP we must first have a detailed understanding of what controls normal foregut motility in healthy children. There are many factors that are involved in normal human foregut motility such as dietary, postural, humoral and neural including pathways from higher centres. We can break down foregut motility into gastric emptying and antroduodenal motility i.e. the coordination between the pylorus and duodenum during the process of emptying.

1.2.1 Control of Gastric Emptying

The human stomach is basically a bag-like reservoir that breaks down food both mechanically and chemically and passes it on to the duodenum, the first part of the small bowel. This needs to be in a controlled and measured fashion making sure that it goes in one direction i.e. does not reflux back. This may sound straightforward but the control of gastric motility and gastric emptying is complicated as illustrated in the Figure 1 below.

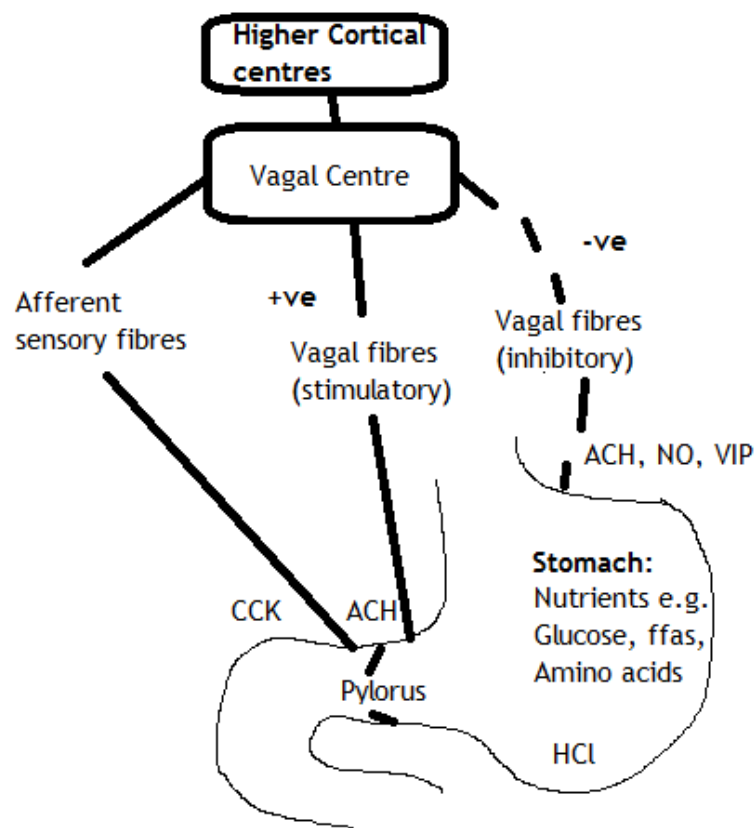


Figure 1. A schematic diagram of some of the many factors that control normal gastric emptying and antroduodenal motility. +ve = positive and -ve = negative, ACH

= acetylcholine, NO = nitric oxide, VIP = vasoactive intestinal peptide, CCK = cholecystokinin, ffas = free fatty acids and HCl = hydrochloric acid. Modified from Ehrlein, H. J., & Schemann, M. (2005). *Gastrointestinal motility. Technische Universität München: Munich.*

It is not only affected by what the patient consumes in terms of solids, liquids, calorific and protein content, but also whether the child is in a fed or fasting state. This has been eloquently shown in studies combining fibre-optic recordings and MRI and showed that the effect of calorific load on gastric emptying varies depending on whether the patient was postprandial or not. (Kwiatek et al., 2009) Liquids are known to pass through the pylorus easily, but solids need to be broken down to pass through and this is done by a churning movement. These gastric contractions are in fact quite sophisticated. When solids are consumed the process of gastric emptying occurs in two phases the first being the lag phase. This lag time is typically 20 to 30 minutes as shown in the graph below, compared to liquids which exit promptly. (Ziessman et al., 1996) Presumably this is a reflection of the fact that peristaltic waves are continuing to breakdown the solids to a small enough size before they are allowed to progress through the pylorus and onward into the small bowel. It is important to note that this does not hold true for all liquids and that gastric emptying does vary according to what is commonly referred to as the nutrient load and therefore if the liquid is rich in fat content then it follows that this will empty from the stomach much more slowly. A higher calorie load has also been shown in children and adults to prolong gastric emptying times (GET) probably as a result of secretion of Cholecystokinin (CCK) as discussed below. (Cornwell & Killenberg, 1965; Franco, Collares, & Troncon, 1985; Kwiatek et al., 2009) Posture has been shown to affect the rate of gastric emptying by groups including Moore et al. They demonstrated that gastric emptying, as perhaps expected, is significantly slower in the supine position as opposed to sitting or standing position. (Moore, Datz, Christian, Greenberg, & Alazraki, 1988; Steingoetter et al., 2006)

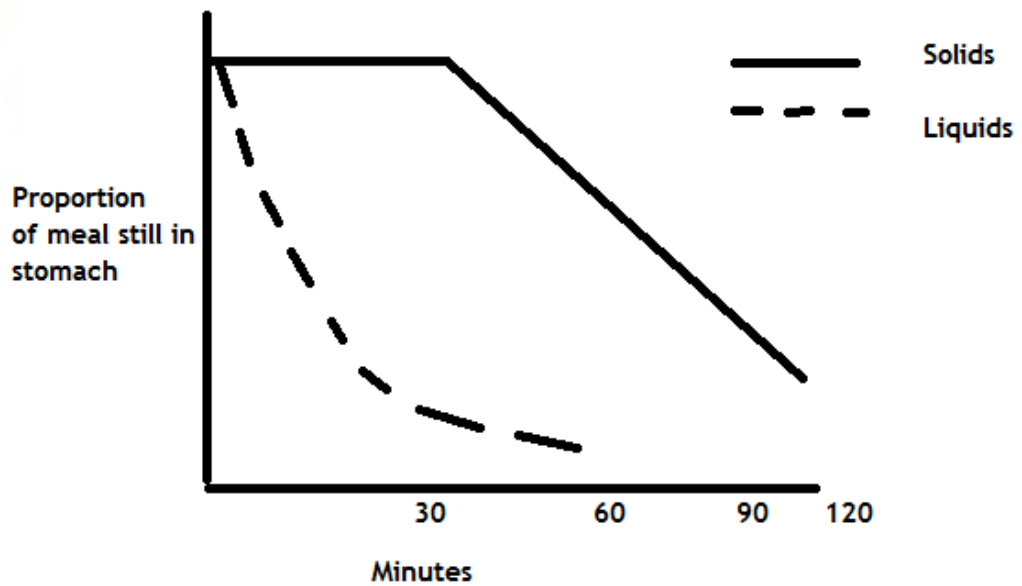


Figure 2. Difference in gastric emptying rate depending on solid or liquid meal.

Modified from Ehrlein, H. J., & Schemann, M. (2005). *Gastrointestinal motility*.

Technische Universität München: Munich.

There is in addition what is known as a physiological divide or band separating the stomach into two when it deals with solids, something which is poorly understood, but which has also historically been noted in cadaveric studies. (Moore, Dubois, Christian, Elgin, & Alazraki, 1986) The apex of the greater curvature of the stomach has been known for some time to house the gastric pacemaker where contraction starts and where their rate is thought to be controlled. (Hinder & Kelly, 1977) Interestingly, Hinder et al found that vagotomy made no difference to the potentials coming from the gastric pacemaker. Since this sentinel paper there has been much work undertaken on what exactly the gastric pacemaker cells are and where their site varies in different animal species.

1.2.2 Interstitial Cells of Cajal

We now know that the pacemaker cells of the stomach and the rest of the bowel are the interstitial cells of Cajal (ICC). These cells were first described by the Nobel laureate Santiago Ramón Y Cajal who was a Spanish pathologist over one hundred years ago (Cajal 1911) He discovered this new type of “nerve-like cell” that was intricately woven along the ends of motor neurons especially in the enteric smooth muscle cells. It wasn’t until well after the invention of the electron microscope in the 1930s that in 1989 Langton et al

beautifully demonstrated that the ICC had electrical rhythm. (Langton, Ward, Carl, Norell, & Sanders, 1989).

The next big step in our understanding of the role of the ICC was by a group of scientists in Japan who were investigating the role of the proto oncogene product “Kit”. Nishikawa et al developed an antibody to block Kit, now commonly referred to as the “anti- ckit antibody” (Nishikawa et al., 1991). The same group then went onto give neonatal animals the antibody which led to huge gastric and intestinal distension soon after birth (Maeda et al., 1992). The majority of the cKit positive cells in the GI tract were ICC and blocking the Kit pathway in mice greatly reduced the population of ICC, potentially altering the course of the cell’s development in the GI tract and destroyed the previously described pacemaker activity (Torihashi et al., 1995). Murine Kit mutant offspring were then developed and further studies confirmed that there are at least two populations of ICC in the GI tract. One group, found at the periphery of the muscle layers and generate and propagate electrical slow wave activity and the other group which is found within the muscle alongside the enteric neurons. It appears again from mutant work with W/WV mice that the subpopulation within the muscle is needed to generate pacemaker activity (Huizinga et al., 1995; Ward, Burns, Torihashi, Harney, & Sanders, 1995). Several studies have implied a ‘division of labour’ between the two types of ICC (Sanders, 1996). Intramuscular ICC are now thought to also act as stretch receptors that can influence and regulate the frequency of pacemaker activity (Won, Sanders, & Ward, 2005).

Gastroparesis is a term now broadly used in adult practice to describe delayed gastric emptying without a specific cause or any sign of obstruction. Indeed, there are many different causes of delayed gastric emptying aside from cerebral palsy. These include infections and diabetes mellitus and so called idiopathic gastroparesis. Two groups from the United States have analysed full-thickness biopsies from the antrum and pylorus of gastroparesis patients and found reduced numbers of myenteric ICCs, increased myenteric inflammation and increased evidence of fibrosis. (Harberson, Thomas, Harbison, & Parkman, 2010; Moraveji et al., 2016). More recently such findings have led to the use of the term “Cajalopathy”. Indeed, Bashshati et al have described both reduced numbers of ICC in addition to structural changes within the cell architecture. They have also demonstrated changes in the gastric slow waves in gastroparesis patients. (Bashshati & McCallum, 2015a, 2015b) The presence and number of ICC cells in the foregut is

therefore, one of the main types of cells we will be examining when it comes to analysing our animal model.

1.2.3 What is the Migrating Myoelectric Complex?

The Migrating Myoelectric Complex (MMC) can be defined as a rhythmic pattern of electric response activity (ERA) or more simply rhythmic cycles of motor activity which is initiated by the gastric pacemakers cells or ICC we have discussed above. The interdigestive motor cycle typically occurs every 90-120 minutes and each MMC is thought to have four distinct phases. Phase I consists of little or no ERA; phase II consists of intermittent ERA phase III consists of periodic ERA on every control wave cycle and phase IV has intermittent ERA, is shorter than phase II but may not always occur. (Carlson, Bedi, & Code, 1972) Despite the experiments by Carlson et al in the 1970s there was little progress into what controlled the MMC until almost ten years later when a Canadian group undertook innovative experiments on dogs where different drugs were used to block different aspects of the enteric nervous system and the effect on the propagation or progress of the MMC was then studied. These drugs included atropine, hexamethonium and tetrodotoxin and all three were found to impede MMC propagation. (Sarna, Stoddard, Belbeck, & McWade, 1981) We know now, therefore, that the MMC starts in the stomach and its progress is under the control of the enteric nervous system. That is not to say that the extrinsic nervous system cannot have an effect as can humoral factors on the MMC's progress, but these pathways are not essential. (Bueno, Praddaude, & Ruckebusch, 1979) (Sarna et al., 1981)

1.2.4 Control from higher cortical centres

Next let us consider the neural mechanisms that have a role to play in a cranio-caudal fashion i.e. starting with the cortical centres first. Despite the renewed focus into the gut brain axis or GBA it is not a new concept that higher cortical centres influence gastrointestinal autonomic function. It was first described as early as 1902 when Pavlov famously described Pavlov's dog, beautifully illustrating that at the sight of food the dog produced more saliva and that higher cortical centres must be involved. Since then with the advances in neurotracer techniques, such as using horseradish peroxidase, it has been possible for scientists to trace connections from the dorsal vagus complex (DVC) to areas in the cerebral cortex and then stimulate these and measure the effect on gastric pressures. The insular cortex and the medial prefrontal cortex are two areas in the cortex of the brain

that have been identified and shown to have an effect on gastric motility. Work from the Pavlov Institute in Russia has shown that the insular cortex communicates directly with the gastric part of the DVC and effects gastric motility. (Bagaev & Aleksandrov, 2006) This work also confirmed that the insular cortex is arranged in a viscerotopic manner similar to the homunculus of the motor cortex and that just beside the gastrointestinal part of the insular cortex are areas that effect cardiovascular and respiratory autonomic centres.

The second centre identified is the medial prefrontal cortex (MPFC). Previously similar experiments by a group from Illinois, USA found that the MPFC may also have a viscerotopic organisation and communicates directly with the nucleus tractus solitarius and subsequently the vagus nerve and that electrical stimulation of medial frontal prelimbic and infralimbic cortex (distinct areas within the MPFC) dramatically reduces ongoing gastric motility (Hurley-Guis KM 1986). The role of the vagus nerve is complicated as it has been demonstrated that there are at least two types of neurons within the nerve one excitatory and the other inhibitory and so its ultimate effect on the gastrointestinal tract is not straightforward or completely understood. (Aihara, Nakamura, Sato, & Simpson, 1978) The hierarchy of neural control would appear to be complicated but involve cortical centres such as the insular cortex and the MPFC, the DVC and the hypothalamus followed by vagal pathways. This hierarchy is summarised in the schematic diagram (Figure 3) on the next page. In addition, Aihara et al in the same set of experiments demonstrated that stimulation of the splanchnic nerves inhibited gastric motility. Some years later another Japanese group showed that by injecting capsaicin into lower thoracic interspinous tissues in rats again that they could increase gastric sympathetic nerve activity and subsequently inhibit gastric motility mainly by fibres passing through the coeliac ganglion. (Budgell & Suzuki, 2000) The input and balance of the autonomic fibres i.e. parasympathetic and sympathetic and the efferent and afferent fibres from the enteric nervous system also respond to what is happening in the lumen of the bowel for example levels of fatty acids, bile salts and CCK. (McMenamin, Travagli, & Browning, 2016)

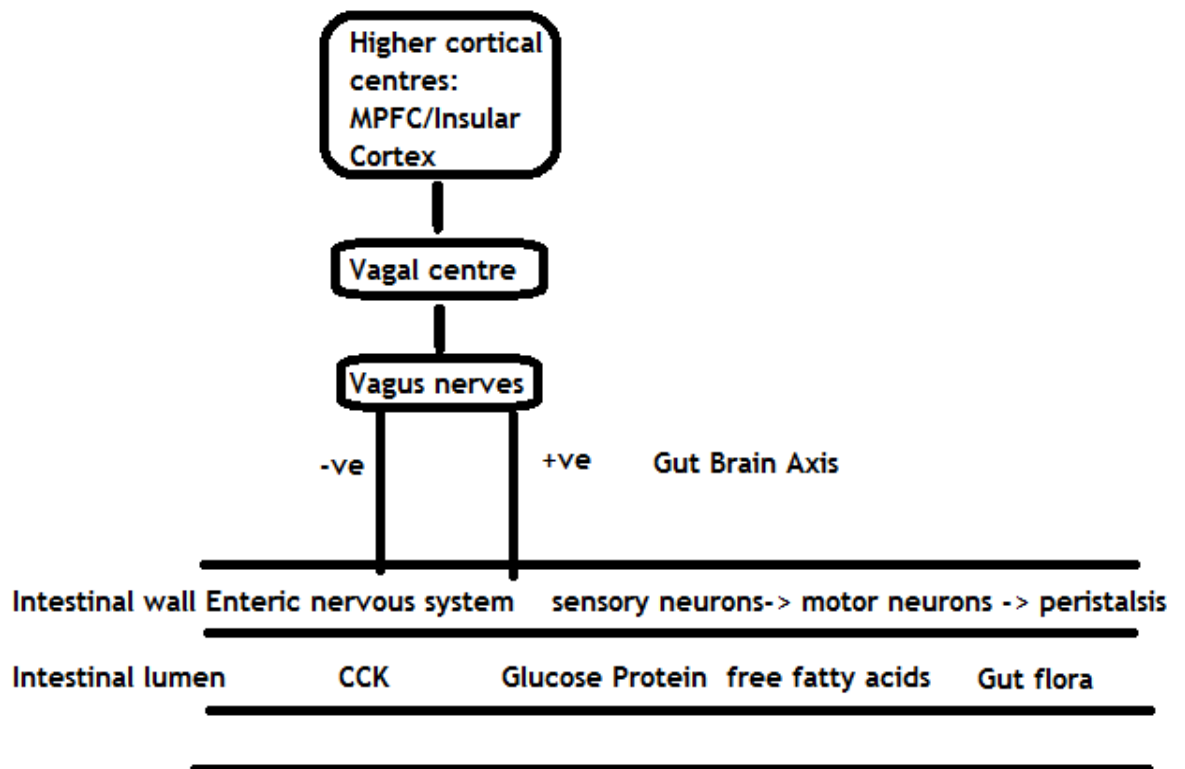


Figure 3. Schematic diagram of the hierarchy of neural control on foregut motility from higher cerebral centres down to vagal centres and the intestinal wall and lumen. The intraluminal content such as protein load, hormones and resident gut flora or microbiota all have the potential to stimulate vago-vagal reflexes. The enteric nervous system and extrinsic nervous system are akin to a complex circuit board further complicated by effects of humoral factors and the intestinal microbiome. Adapted from Ehrlein, H. J., & Schemann, M. (2005). *Gastrointestinal motility. Technische Universität München: Munich.*

1.2.5 Humoral factors involved in gastric emptying

There is a long list of humoral factors involved. Table 1 briefly outlines some of the main stakeholders. The list in this table is by no means exhaustive but focuses on the main players and also serves to illustrate the intimate relationship between neural and humoral mechanisms involved in the control of gastric emptying. It could pose much like the microbiota's influence on neural mechanisms another pathway that could be modulated and could reveal a new part of the axis that could be targeted in terms of developing new treatments for poor gastric emptying. This has been tried for example with the administration of ghrelin. In both animal and human studies ghrelin has been shown to increase appetite and food consumption. (Fujitsuka, Asakawa, Amitani, Fujimiya, & Inui,

2012; Peeters, 2013; Wren, 2008; Wren et al., 2001; Yang, Liao, Qiu, Yan, & Wang, 2014; Yang et al., 2013) This is thought to be a result of stimulation of neurons in the hypothalamic arcuate nucleus. Animal studies have shown increased gastric emptying after ghrelin administration (Fujitsuka et al., 2012), which is why the use of ghrelin for treatment of postoperative ileus has been proposed. In human studies published so far, (Sanger & Furness, 2016) (Wren et al., 2001), no effect was seen on gastric emptying. Another interesting finding is the high ghrelin levels seen in obese patients with the Prader–Willi syndrome. (Solomou & Korbonits, 2014) Ghrelin, therefore, may prove to be an important link in the chain of the brain–microbiome-gut axis. (Shin & Wo, 2015) As well as ghrelin there is another compound that is now known to have an extremely important role and that is nitric oxide (NO). NO, despite being one of the smallest substances in the body, it has been dubbed “the molecule of the millennium”. It is produced from many sources including the gut either by enzymatic from nitrate in the diet, non-enzymatic from the reaction of arginine with hydrogen peroxide or by anaerobic bacterial production. (Kochar et al 2011) It functions as an inhibitory neurotransmitter and not only influences secretion and absorption in the gastrointestinal tract and has an essential role in the control of relaxation and contraction of the smooth muscle of the gut. (Groneberg et al., 2013; Groneberg, Voussen, & Friebe, 2016)

Table 1. Humoral factors that are involved in gastric emptying.

Hormone	Action
Gastrin	Stimulates secretion of hydrochloric acid by parietal cells of the stomach and aids in gastric motility by relaxing the proximal stomach and promoting contractions in the distal stomach
Cholecystokinin (CCK)	Stimulates digestion of fat and protein
Insulin	Produced by beta cells in the pancreas and promotes absorption of glucose. Glucose levels themselves affect gastric emptying.
Motilin	Stimulates the MMC and promotes gastric emptying
Ghrelin	Produced by the fundus of the stomach. Activates growth hormone, prolactin, cortisol and ACTH. Signals hunger and increases gastric motility
GLIP 1	Produced by the ‘L cells’ in the intestinal mucosa stimulated by nutrients in the gut; stimulates insulin, inhibits glucagon release. Inhibits on gastric emptying and initiates the ‘ileal brake’ via the vagus nerve. Also reduces gastric acid and pancreatic exocrine secretion via the vagus and signals satiety.
PYY	PYY also produced by L cells in the intestine; inhibits foregut motility, inhibits gastric acid secretion.

The exact mechanistic pathway is still not understood but the development of knockout mice that lack the enzymes needed in the signalling of NO has greatly improved our understanding and reinforced the idea that NO is at the centre of gut motility. Groneberg et al demonstrated that in their knockout mouse model (SM/ICC-GCKO) by blocking nitrergic signals these mice had increased gut transit time compared with controls. NO, therefore, plays a crucial role in the function of the gut and in its development. The smooth muscle cells of the gut and the interstitial cells of Cajal are both involved and need to respond to NO signalling in order for the bowel to relax. (Groneberg et al., 2013)

Arab et al found in their series of chick embryo experiments that depriving embryos of NO lead to impaired development of the enteric nervous system. (Arab, Muhammadnejad, Faghihi, Hassanpour, & Muhammadnejad, 2014) Other authors have focused on developing animal models showed decreased NO function and increased inflammation in the stomach as well as abnormal motor function of the fundus suggesting that depleted NO may lead to poor gastric function. (Vanormelingen et al., 2016; Vanuytsel et al., 2014) A French group have shown that by inhibiting NO with the nitric oxide synthase inhibitor L-NAME (N(G)-nitro-L-arginine methyl ester) they could delay gastric emptying significantly in pigs, again reiterating the importance of NO in controlling gastric emptying. (Lefebvre, Dick, Guerin, & Malbert, 2005) There is a renewed interest in pharmacological research as new drugs are sought that could enhance NO production to help various gastrointestinal disorders including those affecting motility. (Savidge, 2014) NO is not the only substance at play and both vasoactive intestinal peptide (VIP) and acetylcholinesterase (ChAT) have been shown to also be important. The vagus nerve is imperative in the neural control of the bowel and more recently has been thought to have a role in immunity. This remains somewhat controversial, but what is clear is that the vagus may not interact directly with macrophages but it does interact with all three: nNOS, VIP and ChAT enteric neurons indirectly influencing nearby intestinal macrophages. (Cailotto et al., 2014) In addition to examining the ICC as discussed above we aim to perform immunohistochemistry on biopsies of the foregut from the animal model we aim to create, looking at NO production and levels of ChAT compared to controls or shams.

1.2.6 Antroduodenal motility

Normal antroduodenal motility consists of the pattern known as the triphasic interdigestive MMC (IDMMC) and a separate pattern in the fed state. The IDMMC has three stages,

phase one has no contractile activity, phase 2 is irregular activity and phase consistent activity both in the antrum and in the duodenum. During phase 2 there are secretions into the intestine from both the pancreas and the biliary tree and then by phase 3 these secretions are cleared and this is what is referred to as the “intestinal housekeeper” of the small bowel. (Code & Pickard, 1973) The duodenal contractile activity also influences gastric emptying. This was classically demonstrated by Ormsbee et al in 1976 in which dogs underwent pyloroplasty or were given various medications and a citrate-fat test meal. The greater rate of emptying occurs when there is relatively high antral and low duodenal activity; conversely, the slowest emptying occurs when there is relatively low antral and high duodenal activity. (Ormsbee & Bass, 1976) Gastrin secretion in the stomach leads to a lowering of the pH in the lumen of the antrum and the duodenum and this in turn suppressed the second and third phases of the MMC. (Verkijk, Gielkens, Lamers, & Masclee, 1998) Whatever the mechanisms involved it is clear that the processes that govern antroduodenal motility are complex as are affected by humoral and neural factors including signalling and pathways from higher centres.

1.3 Why do children with CP have foregut dysmotility?

Despite many advances in the understanding of how the enteric nervous system develops, such as the role of the interstitial cell of Cajal and the involvement of humoral factors.(Young, 2008) (Burns & Pachnis, 2009; Burns, Roberts, Bornstein, & Young, 2009; Burns & Thapar, 2014; Goldstein, Hofstra, & Burns, 2013; Sasselli, Pachnis, & Burns, 2012) the pathogenesis of foregut dysmotility in children with cerebral palsy is poorly understood. It was traditionally thought that the enteric nervous system (ENS) could be conceived as a “second brain” i.e. an independent nervous system out with the influence of the central nervous system (CNS). It is now clear, however, that there are many complex connections between the central, autonomic and enteric nervous systems and that the CNS can affect the function of the ENS by way of the vagus nerves amongst others. Children with cerebral palsy have, by definition, damage to higher cortical centres and it has also now been suggested that the ENS in these children may also be inherently abnormal. (Ravelli & Milla, 1998) More recently with developments in neuroimaging techniques such as diffusion tensor tractography the brain of the child with cerebral palsy can be studied in more detail. This is technique involved magnetic resonance imaging and computer analysis whereby data is collected from diffusion weighted images and computer analysis then builds 3D picture which represent neural tracts both from the cortex of the

brain to the rest of the body but also between different cortical and subcortical areas of the brain. In 2013 Englander et al performed the first known study of CP patients using this technique and showed that not only was there evidence of global white matter loss throughout the brain not simply limited to sensorimotor areas. This study found that there was a statistically significant difference in the number of long-range connections in the brains of patients with severe CP compared to those classed as moderate CP. (Englander et al., 2013) This important work gives further credence to the concept that children with CP have abnormal long fibre pathways from cortical centres and that this may well explain some of the changes we see clinically e.g. poor gastric emptying, reflux and a poorly coordinated antroduodenal motility pattern.

1.4 Current investigations

As with any clinical investigation the assessment begins with a comprehensive history and examination of the child prior to moving on to investigations such as imaging. In recent years there have been advances in how motility of the oesophagus stomach and duodenum can be measured with new tools such as the use of breath tests to measure gastric emptying (Pandolfino, Fox, Bredenoord, & Kahrilas, 2009) and the use of combined pH and multichannel intraluminal impedance studies and high resolution manometry (Roman, Pandolfino, & Mion, 2009). It is now increasingly recognised that dysmotility may be underdiagnosed and that with more specific and sensitive investigative modalities surgical management in the future needs to be and potentially could be more individualised and tailored to the patient's particular needs. In 2001, the North American Society for Pediatric Gastroenterology and Nutrition published their official recommendations of the investigation of children with gastroesophageal reflux disease (GORD). This is the condition whereby gastric contents reflux retrogradely back up the oesophagus. Such reflux is common in babies but when present and causing symptoms, is referred to as GORD. The guideline considers the pros and cons of each investigation depending on the age of the child and their symptom.(Rudolph et al., 2001) The focus of this guideline is looking for GORD rather than gastric emptying or foregut motility and is not particular to children who are neurologically impaired. It is still how we would begin our assessment of such patients and it would be useful to briefly consider each investigation in turn.

1.4.1 Upper gastrointestinal studies

Upper gastrointestinal studies involve using radiopaque dye to outline the foregut i.e. oesophagus, stomach and duodenum. Traditionally, barium was used by more commonly now is water soluble contrast such as Iohexol (Omnipaque). This type of study may show gross reflux but is more useful in looking at whether the anatomy of the foregut is normal, whether the stomach empties, the shape of the stomach and whether or not there is any cause of gastric outlet obstruction or rotational anomaly such as that shown in the figure below.

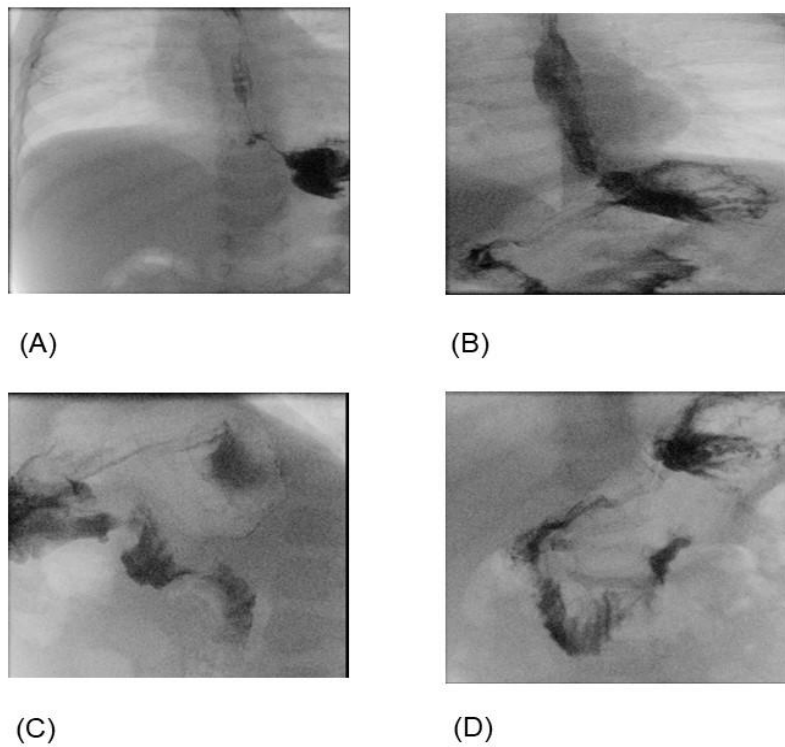


Figure 4. An upper GI study using the contrast agent Barium. (A) outlines the child's distal oesophagus and the fundus of the stomach. (B) shows some reflux into the oesophagus and contrast exiting the stomach and outlining the duodenum. (C) shows a lateral image of the stomach and duodenum and finally (D) confirms the child has normal rotation with the duodenal/jejunal flexure lying to the left of the midline at the level of L1.

1.4.2 pH studies

For many years a 24 hour pH probe study was regarded as the gold standard for investigating and diagnosing gastroesophageal reflux disease (GORD) It involves passing a tube with two channels usually down the patients nose, occasionally the mouth, with one channel and probe in the stomach and the other in the distal oesophagus. It was first described by Johnson and Demeester who designed the electrode used to monitor the patients oesophageal pH over 24 hours and they defined six parameters that once measured resulted in the Demeester score for diagnosing GORD. (Johnson & Demeester, 1974) The parameters are shown in the table below. In the 1990s working groups from both sides of the Atlantic described how such studies should be performed and interpreted in children. (Colletti, Christie, & Orenstein, 1995; Vandenplas et al., 1993) Various groups have employed pH studies in children with cerebral palsy and have found that around 70% of children with CP suffer from GORD. (Reyes et al., 1993)

Table 2. Demeester scoring system for diagnosis of GORD using 24 pH probe testing

Components of 24-h Oesophageal pH Monitoring
Percent total time pH < 4
Percent Upright time pH < 4
Percent Supine time pH < 4
Number of reflux episodes
Number of reflux episodes \geq 5 min
Longest reflux episode (minutes)

The downside of this type of test is that by definition it is only assessing GORD and not gastric emptying or antroduodenal motility. It has also been shown that in some children, especially in neonates and infants, to be notoriously unreliable (Vandenplas et al., 1993) (Grant, 2001). In neurologically impaired children such as those with CP then it is now recommended that a combination of 24-hour multichannel intraluminal impedance-pH monitoring is used and has been shown to be much a more accurate and reliable method. Impedance can be defined as the opposition to current flow or the inverse measurement of the electrical conductivity of an organ's wall and its contents. These studies mean that a food bolus or reflux can be measured. No bolus in the lumen of the foregut means there are fewer ions and so this equates to high impedance. In contrast a food bolus present in the lumen of the oesophagus means that there are many ions present and so there is low

impedance. These studies are very useful as they can detect acid and non-acid reflux in children who characteristically are not able to give a history of their symptoms. A study from London found that more than half of the reflux events in neurologically impaired children are nonacidic and would therefore go undetected by conventional pH probe studies. They concluded that children who are nasogastrically fed rather than orally fed are more likely suffer from reflux. (Del Buono, Wenzl, Rawat, & Thomson, 2006)

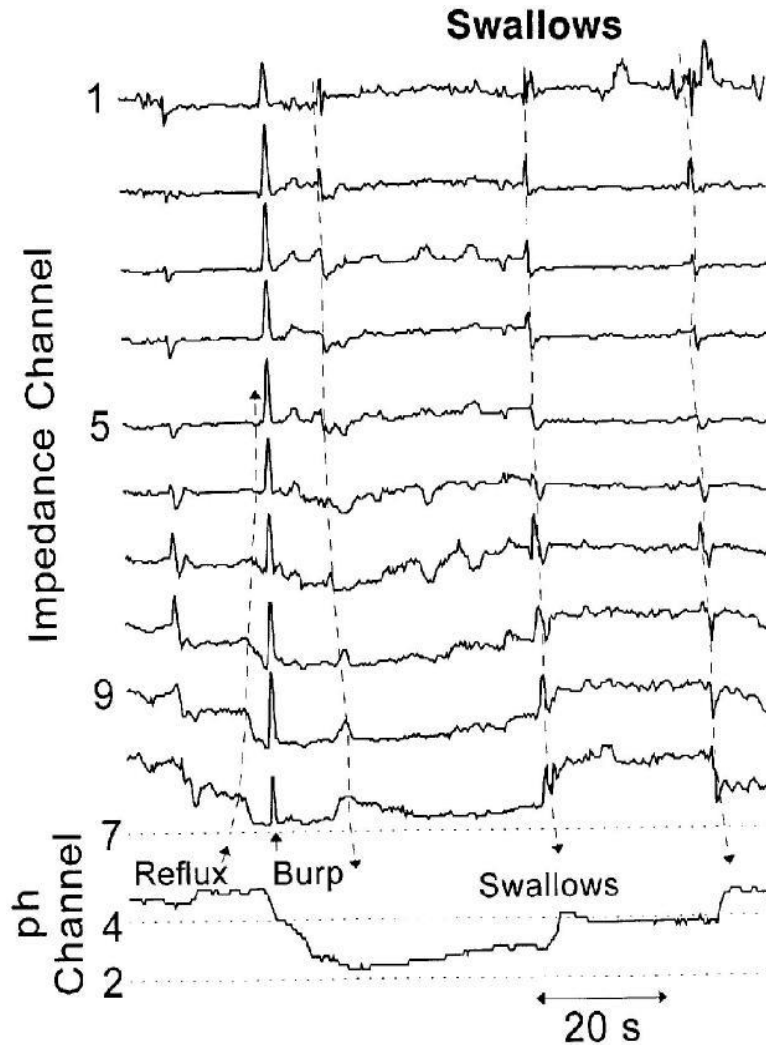


Figure 5. A typical trace from a pH/impedance study.

1.4.3 High Resolution Manometry and impedance

In the 1990s the beginnings of high resolution manometry (HRM) began and with the ongoing development in technology these techniques have greatly improved since their infancy. HRM is measures intraluminal pressure changes using a series of pressure sensors no more than 1 cm apart. HRM can be used to investigate many different types of motility

disorders and was heralded as the new gold standard tool for investigation of motility disorders. (Roman et al., 2009) The first challenge was to understand what normal was. (Herbella, Aprile, & Patti, 2014) This led to studies of normal subjects and many different patients and led to initial Chicago classification. (Bredenoord et al., 2012) This has since been recently been updated and revised. (Pandolfino et al., 2009; Pandolfino et al., 2008)

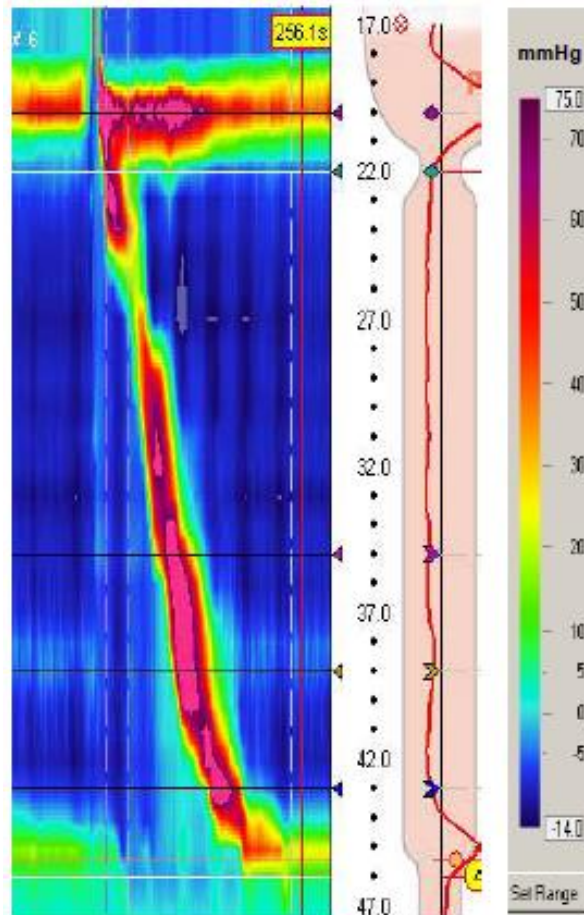


Figure 6. High resolution manometry. An example of the topographic display from the multiple sensors placed down a patient’s oesophagus.

The use of HRM and this classification is purely dealing with the proximal and distal oesophagus and the oesophago-gastric junction. It has been proposed as the investigation of choice pre- and post- operatively in those who undergo fundoplication as discussed later. (Fukahori et al., 2013) It does not assess gastric emptying or antroduodenal motility. (Kahrilas et al., 2015) More recently, techniques of high resolution mapping of gastric slow waves using electrodes have been designed to look at gastric motility and gastric dysrhythmias. In a similar way to HRM this type of mapping has been found to be possible

if electrodes are placed less than 10mm apart. Further work is needed into designing reliable gastric motility high resolution mapping. (Putney et al., 2015)

1.4.4 Scintigraphy

Nuclear medicine is a branch of radiology that involves administering radioactive isotopes and measuring their uptake and excretion from the body. In the 1980s studies showed that such tests were relatively easy to perform and could be used to investigate gastric emptying of radiolabelled meals, both solid and liquids. (Malmud, Fisher, Knight, & Rock, 1982) More recently its role as the gold standard for assessing gastric emptying has been cemented and the need to quantify what normal values are for children rather than using adult data has been highlighted. (Malik et al., 2016) In their study Malik et al studied a group of thirty healthy children and measure their gastric emptying by means of a (99m) Tc-labelled vegetarian meal. They found that the median the percent gastric retention at 30 min, 1, 2, 3 and 4 h were 90%, 77%, 33%,16% and 7% and the median lag phase was 18 minutes, but this had no correlation with gastric retention at 4 hours. It has also now been suggested that scintigraphy may have a role in investigating oesophageal transit time. (Maurer, 2016)

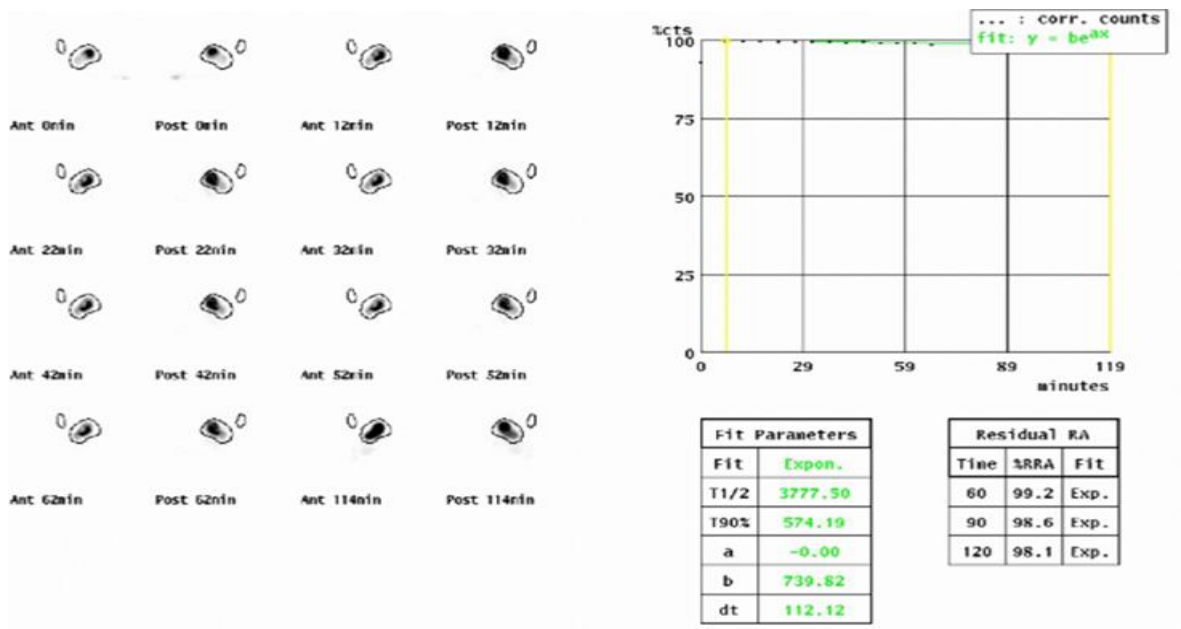


Figure 7. Gastric emptying study using scintigraphy. An example of a gastric emptying study that shows significant delay in gastric emptying in a patient with cerebral palsy.

More recently another investigation that again may be of benefit in paediatric children is a new breath test as it is non-invasive. A group from Italy compared the ^{13}C -acetate breath test (ABT) which has been used and ratified in adults in 60 children (30 normal controls and 30 children with known delayed gastric emptying). They found that the ABT breath test was reliable, cheaper and easier to perform in the paediatric population. (Gatti 2000)

1.4.5 Endoscopy

Endoscopy of the upper gastrointestinal tract allows direct visualisation of the oesophagus, stomach, first, second, third and even fourth part of the duodenum. In children, it requires a general anaesthetic and generally a flexible endoscope is used with the ability to take endoscopic biopsies. A series of typical views down the endoscope is shown below in Figure 8. It may be useful in the investigation of a patient with possible dysmotility as it can show whether there is any pathological changes of the oesophagus, stomach or duodenum. It can also be used to rule out any other causes for the patient's symptoms such as eosinophilic oesophagitis or *Helicobacter pylori*.

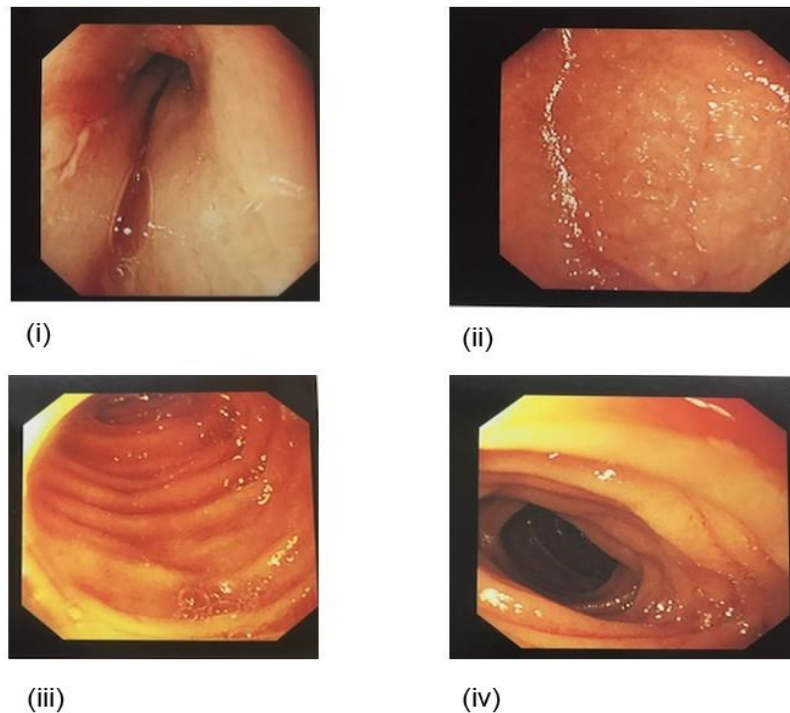


Figure 8. Endoscopy. The typical view down the endoscope of a normal (i) distal oesophagus, (ii) stomach, and (iii) and (iv) show the duodenum.

Traditionally biopsies have been limited to the mucosa and submucosa. More recently a new endoscopic muscle biopsy technique has been described by Rajan et al. They describe a series of three patients in adult practice with idiopathic gastroparesis and a “double resection clip assist technique” by dissected down endoscopically to the muscularis propria and then creating a “pseudopolyp” and then clipping the base of this and retrieving the biopsy. In the biopsies examined both inner circular and outer longitudinal muscle was identified and the specimens were examined for the presence of ganglia and interstitial cells of Cajal. (Rajan, Gostout et al. 2016) This is a novel technique which may become more commonly used and be adopted in paediatric practice, especially in patients with foregut dysmotility who may have already had multiple procedures including laparotomy or fundoplication and gastrostomy which can make laparoscopic biopsies difficult. The use of capsule endoscopy has also become increasingly popular in the last decade or so. A further variation on this is the modified magnetic capsule endoscope which allows the capsule to become attached to lumen of the stomach and, therefore, allows for ambulatory monitoring of gastric motility. This technique is in its infancy and its feasibility has only recently been demonstrated. (Kim, Choi, & Cho, 2014) Other studies have confirmed that wireless motility capsules can be useful in quantifying real time dysmotility, not just in the foregut but also in the lower gastrointestinal tract. (Rao, Mysore, Attaluri, & Valestin, 2011) In practice, it may be that capsule endoscopy or wireless motility capsule may help complement information gained from the other many investigations described above.

1.5 Current management

1.5.1 Medications

There are various medications that can be applied when it comes to trying to alleviate the symptoms that many patients with foregut dysmotility may have. The focus is on combatting any possible gastro-oesophageal reflux (GOR) that may be contributing to symptoms. Medication for GOR often starts with sodium alginate compound (gaviscon), ranitidine or a proton-pump inhibitor such as omeprazole. Several studies in the 1980s showed that gaviscon was helpful in alleviating reflux in children compared to placebo. (Buts, Barudi, & Otte, 1987; Buts & Leclercq, 1987) The efficacy of proton pump inhibitors (PPIs) has been the subject of much debate in recent years. A systematic review by Van der Pol found one study that showed a beneficial effect, 2 that showed no difference and 2 that showed no effect at all and therefore overall concluded that PPI

although well tolerated are not effective in infant and that there is little evidence for them in older children. (van der Pol et al., 2011) There also has been concerns raised that PPIs in infants and younger children may have immunosuppressive side effects. (Cohen, Bueno de Mesquita, & Mimouni, 2015) Rodent studies have also revealed a possible increased risk in oesophageal and pancreatic cancer risk with long-term use of PPIs (Dall'Olmo, L., et al. 2014)). The risk in humans is not clear but has been described as extremely low especially if there the organism *Helicobacter pylori* is eradicated. (Graham, D. Y. and R. M. Genta 2008) Another systematic review, however, stated that ranitidine and omeprazole are not only safe but can be effective in infants, but more so in older children. It did however, concede that there was less evidence for the use of domperidone or metoclopramide. (Tighe, Afzal, Bevan, & Beattie, 2009)

If symptoms persist then domperidone may be tried. This is a peripherally selective dopamine D2 receptor antagonist and is essentially a prokinetic which has been used to enhance gastric emptying and relieve nausea and vomiting. Recently the therapeutic range of domperidone has, however, been significantly narrowed because of concerns regarding effects on patients that may have a prolonged QT. The arrhythmia inducing effects of domperidone have been described in animal models such as guinea pig hearts. (Drolet, Rousseau, Daleau, Cardinal, & Turgeon, 2000) It has been shown in some infants to prolong QTc time on ECG. (Rocha & Barbosa, 2005) All patients must now have an ECG prior to commencing domperidone and afterwards. (Djeddi, Kongolo, Lefaix, Mounard, & Leke, 2008) The need for this, however, has been questioned by some authors.(Ngoenmak, Treepongkaruna, Buddharaksa, & Khositseth, 2016) It has also been suggested that for some patients the reduced dose that is now deemed safe is in fact sub therapeutic. This is reminiscent in some ways of the medication cisapride which for many years helped children with poor gastric emptying but was removed from clinical practice due to concerns over studies linking it to serious cardiac arrhythmias. (McCallum, 1991, 1996) (Mt-Isa et al., 2015) (Maclennan, Augood, Cash-Gibson, Logan, & Gilbert, 2010) (Hegar, Alatas, Advani, Firmansyah, & Vandenplas, 2009)

Many patients with neurological problems suffer from tonic posture and the medication baclofen is often used as a muscle relaxant. Baclofen is of course a GABA type B receptor agonist and is also known to reduce transient lower oesophageal sphincter relaxation and reflux. Indeed Kawai et al reported that administration of baclofen reduced the frequency of vomiting and acid reflux in neurologically impaired children. (Kawai, Kawahara,

Hirayama, Yoshimura, & Ida, 2004) Whilst baclofen's use against GORD has been questioned to be effective especially in neurologically impaired children Omari et al conducted a randomised control trial of 30 children in which they compared baclofen to placebo and performed pH and manometric studies before and afterwards. They found that baclofen did reduce reflux and improved gastric emptying times. (Omari et al., 2006) More work is needed into the efficacy of baclofen for GORD rather than just relieving spasticity in children with cerebral palsy.

Following the withdrawal of cisapride and the concerns regarding domperidone another two drugs came to the fore namely; metoclopramide and erythromycin. Metoclopramide is a dopamine D2 receptor antagonist and also a mixed 5-HT₃ receptor antagonist/5-HT₄ receptor agonist. Erythromycin is a macrolide antibiotic but its prokinetic action is thought to be a result of agonism at motilin receptors. Neither of these is without controversy either. Some studies have linked increased side effects with metoclopramide such as hyperkalaemia and other studies suggested an increase in incidence of pyloric stenosis in those infants treated with erythromycin although this was not statistically significant. Other studies have suggested that at low doses erythromycin can be beneficial for children with motility disorders. (Cucchiara et al., 1997) There have subsequently been calls for more studies looking at the safety and effectiveness of both drugs. (Chicella, Batres, Heesters, & Dice, 2005; Ericson et al., 2015) (Curry, Lander, & Stringer, 2001) The repertoire of medications is, therefore, somewhat limited and has led to much work in the pharmaceutical industry to develop novel treatments. These include drugs pharmacologically related to cisapride such as mosapride which has been suggested as an alternative for treatment of GORD in neurologically impaired children. (Komura et al., 2016) Furthermore, the next generation of 5-HT₄ receptor agonists, namely YKP10811, has shown some promise on improving gastric emptying in dogs and is yet to be trialled in humans. (Yin et al., 2016) There has been work looking at neural stem cells as a possible treatment for a variety of conditions related to the enteric nervous system. Some of the initial results from animal studies are encouraging. (Burns & Thapar, 2014) The common theme that is most striking in terms of reviewing the concern over existing medication and the lack of effective treatments for foregut dysmotility in neurologically impaired children is that more research is urgently needed and this really adds to the case for the need for a robust animal model to study any potential new therapy whether it be medical or surgical.

1.5.2 Gastrostomy

The suffix “-stomy” comes from the greek “stomata” meaning mouth or opening and so the word “gastrostomy” literally can be translated as an opening into the stomach i.e. the wall of the stomach brought up to the anterior abdominal wall and a tube inserted. There are various methods of surgically creating a gastrostomy. These include creating an open or Stamm gastrostomy, a technique often reserved for neonates. A “PEG” or percutaneous endoscopic gastrostomy can be fashioned by using an endoscope only and using a “pull technique” or it can be laparoscopically assisted either using the same technique or a “push technique”. The “push technique” is often reserved for when the patient is also undergoing a laparoscopic fundoplication (discussed below). Primary gastrostomy buttons are another low-profile device that can be used rather than a long tube coming out from the patient’s abdominal wall. All of these various techniques have their pros and cons and the paediatric surgeon should have them all in his or her armamentarium so that the best technique can be chosen on its merit on a patient by patient basis. Regardless of the technique used many patients who are neurologically impaired may be assessed by the speech and language team and found to have an unsafe swallow. This then means that the baby or child is fed initially by nasogastric tube and then after a period of time if the patient is tolerating gastric feeds then they are referred for insertion of gastrostomy. There is also evidence that children with cerebral palsy do not just have an unsafe swallow but are commonly malnourished. (Sullivan, 1997) There is also evidence that survival rates of children with cerebral palsy are increasing and that there is an increased survival rate in those who have a gastrostomy placed. (Plioplys, 2003; Plioplys, Kasnicka, Lewis, & Moller, 1998)

The creation of a gastrostomy in neurologically impaired children such as those with cerebral palsy is common place but the evidence base is lacking. Two recent Cochrane reviews, both failed to identify any randomised control trials that were conducted to look at what is the best method to feed neurologically impaired children. Gantasala et al concluded that the effects of gastrostomy or jejunal feeding on children with cerebral palsy has not been studied and remains very much in doubt and also recognised that such interventions have a possible under recognised emotional impact on the family or patient’s carers. This Cochrane review called for a randomised controlled trial to be undertaken to address this issue and resolve the dubiety of how best to feed these children. (Gantasala et al., 2013) This echoed the results of the first Cochrane review almost a decade earlier. (Sleigh & Brocklehurst, 2004) A similar systematic review was conducted by the American Academy

for Cerebral Palsy and Developmental Medicine (AACPDm) and again found a lack of evidence but found ten studies that they examined. They again found that not all families were of the opinion that a gastrostomy had had a positive impact on the care of their child or overall family life. They also found a high rate of complications and called for further well-designed studies on the effect of placing a gastrostomy in children with CP. (Samson-Fang, Butler, O'Donnell, & Aacpdm, 2003)

1.5.3 Fundoplication and its controversy

Fundoplication is a surgical procedure whereby the top of the stomach, known as the fundus, is wrapped round on itself at the oesophagogastric junction so as to treat reflux. There are many different types of fundoplications, but the most common type is a Nissen fundoplication which involves a 360 degree wrap as shown in Figure 9.

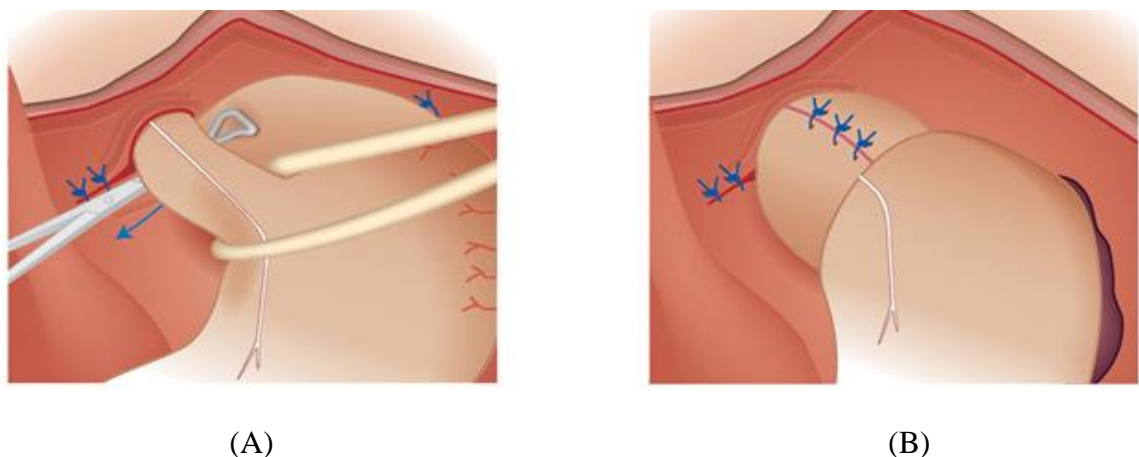


Figure 9. An illustration showing a 360 degree Nissen fundoplication. (A) shows the fundus of the stomach being grasped and pulled behind the oesophagus and then sutured into place to create what is referred to as a “long loose wrap”. Of note the white upside down “Y” structure is the vagus nerve. Care is taken not to damage this structure but it can be seen to be incorporated into the wrap itself. Modified with permission from *Basic Techniques in Pediatric Surgery: An Operative Manual* edited by Robert Carachi, Sandeep Agarwala, Tim J. Bradnock (Carachi et al., Springer 2013)

Often these patients undergo laparoscopic fundoplication at the same time as gastrostomy insertion to overcome the gastroesophageal reflux (GOR) part of their symptoms, or undergo laparotomy. Fundoplication itself especially in neurologically impaired children can result in the development or even progression of gastric dysrhythmia leading to

retching, vomiting, and food intolerance. Richards et al from London in fact showed in a very elegant study that two-thirds of neurologically impaired children compared to one in five normal children have evidence of gastric dysrhythmia on surface electrogastronomy. They also demonstrated that post fundoplication those who retched beforehand were more likely to continue to retch, but also that one in four post fundoplication would have problematic retching that they did not have before. (Richards et. al, 1998) This phenomenon was further investigated by Richards et al using a ferret fundoplication model where they found that post fundoplication there was more serosal fibrosis of the stomach and oesophagus and this was more prominent in those with disrupted wraps in which they also found histological evidence of damage to the vagus nerve. These authors proposed or hypothesised that this damage may then “sensitize the emetic reflex” resulting in an increased incidence of post-operative retching. (Richards et al, 2003)

Studies have shown that fundoplication may well alleviate reflux (Fukahori et al., 2013) and whilst some reviews quote more than 90% success rates (Di Lorenzo & Orenstein, 2002) others question whether those children that undergo fundoplication need surgery at all. (Hassall, 2005) It remains debatable, therefore, whether fundoplication is the treatment of choice for children with CP as it is simply addressing GORD rather than antral or more widespread foregut dysmotility they are now thought to have. In Europe, there are some centres who suggest that the type of wrap needs to be more patient specific and that HRM and impedance studies (as discussed earlier) can determine who may benefit from a full 360 degree Nissen type fundoplication and who may be more suited to an anterior wrap such as a Thal fundoplication or another type of procedure such as a Toupet type wrap. Esposito et al studied all three types of fundoplication and found them all to be effective and that surgeon’s experience dictated what type of wrap was used and that parents overall were happy with the surgical outcome for their child. (Esposito et al., 2006) An earlier study by the same centre concluded that laparoscopic fundoplication was safe in neurologically impaired children and whilst mortality rates were high these deaths were felt to be unrelated to the operation itself. (Esposito et al., 2003) It is recognised that post-operative problems after fundoplication are more common in neurologically impaired children and in those with motility problems. (Di Lorenzo & Orenstein, 2002) Some centres have acknowledged that re-do fundoplication is difficult in these children and now advocate oesophagogastric dissociation as a last resort in children who have had a “failed fundoplication.” (Goyal, Khalil, Choo, Mohammed, & Jones, 2005)

1.5.4 Jejunal feeding methods

Due to the controversy surrounding the effectiveness of fundoplication in children with CP, many centres have increasingly turned to trying jejunal feeding instead. This means feeding the child directly into the distal small bowel i.e. bypassing the stomach, and therefore reflux, but also the entire foregut and so may help bypass motility issues also. This can be done by means of a nasojejunal tube or gastro-jejunal tube often an extension placed onto an existing gastrostomy or by a surgically fashioned jejunostomy either by an open procedure or more recently a laparoscopic-assisted procedure. The latter has been described and reported to be safe and effective in neurologically impaired children. (C. Esposito, 2005) (Esposito, Alicchio, Escolino, Ascione, & Settimi, 2013) Other studies have described a modification of this technique percutaneous laparoscopic-endoscopic jejunostomy and again although successful in cases of foregut dysmotility had rare but the life-threatening complication of small bowel volvulus around the jejunostomy. (Belsha, Thomson, Dass, Lindley, & Marven, 2016) Surgical placement of such tubes has been shown to improve feed tolerance reduce the incidence of pneumonia presumably as a result of aspiration in neurologically impaired children. (Egnell, Eksborg, & Grahnquist, 2014) Wales et al retrospectively compared fundoplication and gastrostomy to radiologically placed jejunal tubes often without the need for general anaesthesia and although an alternative the majority of children (85%) with jejunal tubes rather than a surgical jejunostomy had complications of the tube either breaking, blocking or becoming dislodged. (Wales et al., 2002) Such problems and associated with jejunal tubes are widely reported in the literature and these tubes are known to have significant morbidity. (Godbole et al., 2002) Although this complication is less likely to occur in those with surgically placement or roux en y jejunostomy the tubes can still block or dislodge. (Gilchrist, Luks, DeLuca, & Wesselhoeft, 1997) Major complications such as small bowel volvulus may occur in up to 1 in 5 patients especially in the first six months following the procedure and there is a 5% mortality risk associated with the surgical procedure itself. All of these risks need to be explained during the consent process with the parents. (D. Smith & Soucy, 1996)

1.5.5 Coeliac plexus blockade, splanchnectomy and gastric emptying

The coeliac plexus is a group of post ganglionic nerve fibres formed from the splanchnic nerves. The splanchnic nerves arise from the lower eight thoracic sympathetic ganglia. These sympathetic fibres are vasomotor and inhibitory to peristalsis and are known to carry


sensory fibres to the abdominal viscera. It follows, therefore, that interrupting this network can not only interrupt nociceptive or pain pathways but can also affect foregut motility. Coeliac plexus blocks (CB) and thoracoscopic splanchnectomy (SP) have been employed and widely reported in adult practice to benefit patients with severe pain from pancreatitis and pancreatic cancer. (Baghdadi, Abbas, Albouz, & Ammori, 2008; Buscher, 2002; Cuschieri, Shimi, Crosthwaite, & Joypaul, 1994; Ihse, Zoucas, Gyllstedt, Lillo-Gil, & Andren-Sandberg, 1999; Kang et al., 2007; Lebovits & Lefkowitz, 1989) Another study in adult practice has shown that CB reduced gastro-intestinal dysfunction in neurosurgical intensive care patients. (Weinstabl. et al, 1993) As shown in the table below, in this study these patients underwent CB on day 3 of the study and by day 5 and 6 their gastric losses had all but gone.

Table 3. The effect of CB on gastric losses in patients in a neurosurgical intensive care unit. Modified table from Weinstabl et al, 1993. This illustrates that CB can hugely and quickly improve gastric emptying in patients with severe brain injury.

Gastric reflux volume (ml)

Days

CB



Patient no	1	2	3	4	5	6
1	690	830	670	50	0	0
2	650	680	600	20	20	50
3	550	780	800	0	90	0
4	590	700	840	0	0	0
5	610	700	800	150	0	0
6	1050	1200	1150	900	0	0
7	940	610	838	120	0	0
8	720	740	600	20	0	0

The technique of coeliac plexus blockade is shown in the figure 10. The coeliac plexus is accessed through a posterior approach at the level of the first lumbar vertebrae and the

needle is advanced under fluoroscopic guidance with radiopaque dye and then the plexus is ablated by injecting it with local anaesthetic such as levobupivacaine.

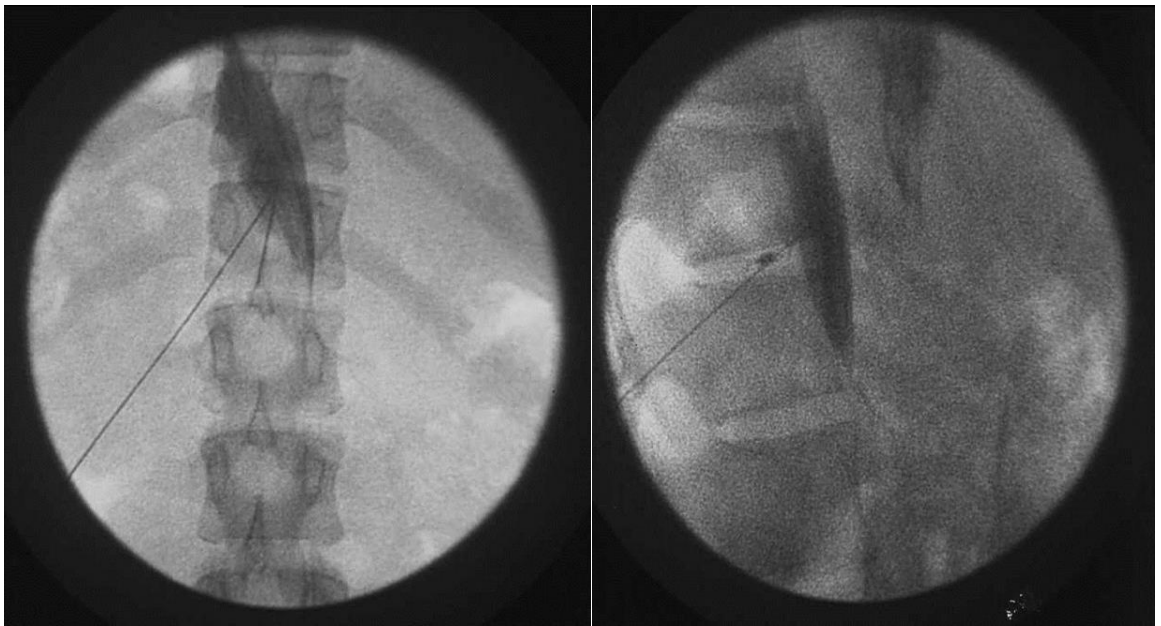
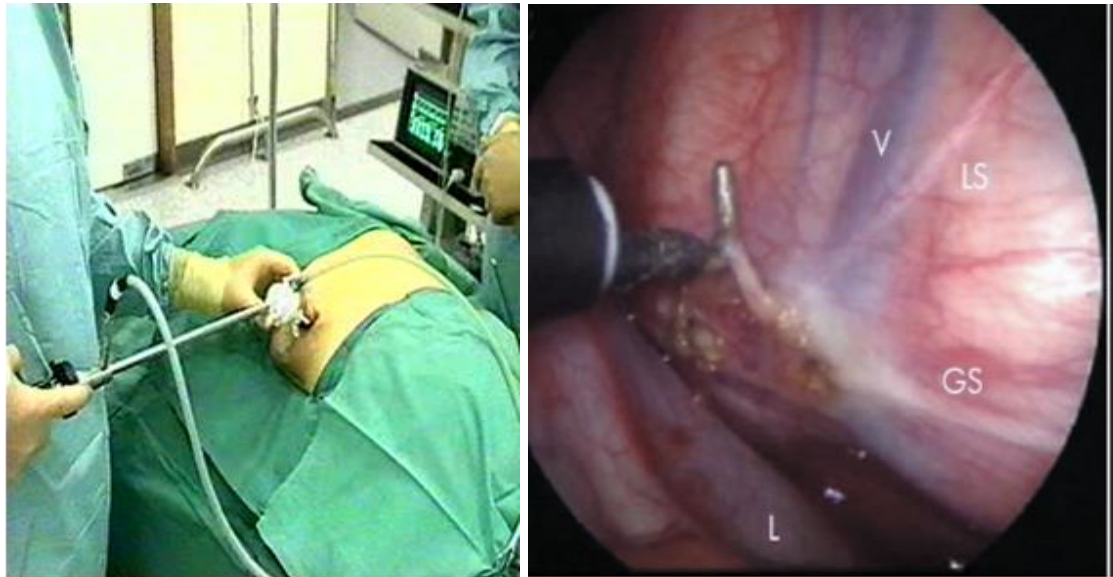


Figure 10. Technique of coeliac plexus block. Anteroposterior (left) and lateral (right) views on fluoroscopy of a coeliac plexus block. The needle can be seen and the radiopaque dye inserted to check position prior to injecting local anaesthetic such as levobupivacaine.

The effect of coeliac plexus blockade is, however, often temporary and hence why patients proceed to splanchnectomy at which the splanchnic nerves are found by means of thoracoscopy i.e. placing a telescope into the chest and identifying the nerves and dividing them with diathermy. This is shown in the figure 11.



(A)

(B)

Figure 11. Thoracoscopic splachnectomy (A) This shows a patient prepped and draped and undergoing thoracoscopy and (B) shows the view on the inside of the thoracic cavity and the splanchnic nerves are labelled GS (greater splanchnic nerve), LS (lesser splanchnic nerve) and L (the least splanchnic nerve). V is a vein.

1.5.6 Our patient series

Successful bilateral thoracoscopic splachnectomy was first reported in two children with chronic intestinal pseudo-obstruction (CIPO) ten years ago.(Khelif, Scaillon, Govaerts, Vanderwinden, & De Laet, 2006) In our centre we have a series of patients that were identified prospectively between 2000 and 2008 as having symptoms of foregut dysmotility that had failed conventional management. Patients were treated with a varied combination of low dose metoclopramide, CB and/or thoracoscopic splachnectomy (TS) as shown in the treatment algorithm below (Figure 12). Patients were followed-up routinely at clinic to review any improvement in their symptoms. The outcome measures were: pain relief and improvement in feeding difficulties. 11 patients (7 boys and 4 girls) were identified with a median age of 11 yrs. (3-21 years). Symptoms included constant retching, vomiting, severe abdominal pain and feeding difficulties. 7 had severe neurological abnormalities, 6 had had a fundoplication and 3 had a gastrostomy and others had had numerous laparotomies. Of the 11 patients 7 patients went on to have a celiac plexus blockade. This was often repeated multiple times and its effect on symptoms averaged at a median of 28 days. 5 of these 7 patients progressed to splachnectomy.

(Carachi, Currie, & Steven, 2009) Almost all patients have shown complete relief of their symptoms following splanchnectomy and the procedure has been well tolerated.

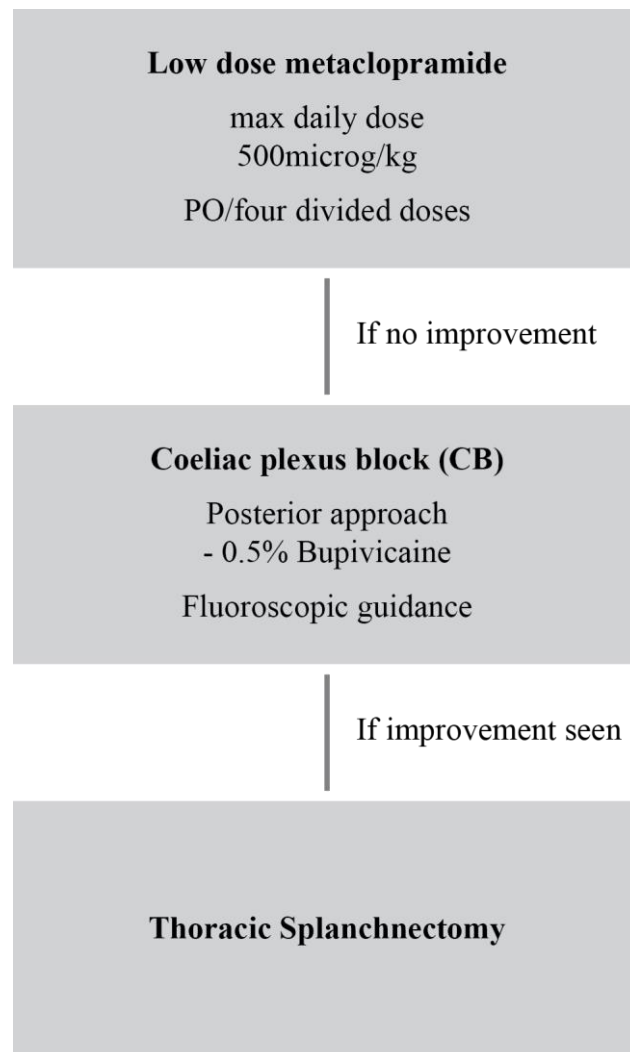


Figure 12. Treatment algorithm. This was used in our series of patients who had failed conventional treatment for symptoms of foregut dysmotility. Patients were first trialled on metoclopramide which as mentioned above has since been deemed no longer recommended for use in children. If no improvement was seen the patients progressed to CB and again after repeated response to this, patients progressed to TS.

We have not performed these procedures recently as the evidence for such procedures was lacking and there was no longer a paediatric anaesthetist able to perform CB in children in our centre. This then led to our need to develop an animal model because as shown in the various systematic reviews we have discussed including Cochrane reviews there is a real difficulty in trying to conduct randomised controlled trials in neurologically impaired children and in those with CP. It is hoped that by developing a robust animal model and

then performing splachnectomy on this model then there would be more impetus to conduct a randomised control trial in children.

1.6 Developing the Animal model

There are many different animal models of cerebral palsy. (Johnston, Ferriero, Vannucci, & Hagberg, 2005) The distribution of brain lesions is often diffuse and can include multiple cystic lesions in the white matter and diffuse cortical atrophy such as that seen in PVL in humans. As mentioned above there is no existing animal model of cerebral palsy and foregut dysmotility reported in the literature, although one paper from the Indiana group (Vane et al., 1982) did link surgically induced brain damage in cats to decreased lower oesophageal sphincter pressure and possible gastro-oesophageal reflux.

1.6.1 Historical models i.e. what has been tried before?

Historically there have been many different animal models of cerebral palsy using techniques which largely fall into four groups those that (i) induce antenatal or postnatal ischaemia by techniques such as endovascular balloon occlusion of blood supply to the placenta or ligation of the carotid artery (Jensen, Follett, Uehara, Mallard, Johnston) or (ii) maternal or foetal antenatal hypoxia (Baud et al., 2004; Mallard, Welin, Peebles, Hagberg, & Kjellmer, 2003) or (iii) a combination of carotid ligation and hypoxia (Sheldon, Chuai, & Ferriero, 1996) (McQuillen, Sheldon, Shatz, & Ferriero, 2003) or (iv) chemical lesions to the brain (Tahraoui et al., 2001). Rodent models resulting from either maternal or neonatal ischaemia often resulted in early death of offspring or rejection by the mother. Rodent brains are anatomically different and have less white matter than larger animals have also been tried including ovine models and baboons although these models are much more expensive. Baburamani et al developed a rabbit model by injecting lipopolysaccharide (LPS) into the uterus of pregnant rabbits and showed that these rabbits had brain damage on positron emission tomography imaging and had functional motor deficits. (Baburamani, Supramaniam, Hagberg, & Mallard, 2014) Ovine models have also been tried by injecting intravenous LPS into midgestation foetal sheep, an age which is similar in brain development to the preterm humans. These injections resulted in white matter injury and in higher doses showed evidence of inflammation of the neonatal brain. (Duncan et al., 2002; Nitsos, Newnham, Rees, Harding, & Moss, 2014). Asphyxia of foetal sheep has also been shown to result in white and grey matter injury.(Mallard et al., 2003) None of these models examined the effect of white matter injury on the gastrointestinal

tract. As mentioned above there is no existing animal model of cerebral palsy and foregut dysmotility reported in the literature. The only related paper is from the Indiana group (Vane et al., 1982) that did link surgically induced brain damage in cats to decreased lower oesophageal sphincter pressure and possible gastro-oesophageal reflux. This paper did not, however, focus on creating brain damage akin to that seen in cerebral palsy instead it was brain injury caused by raising intracranial pressure (ICP) by means of a burr hole and a inserting and inflating a balloon catheter. At the same time lower oesophageal sphincter pressure was measured and these authors found that by increasing the cat's ICP they lowered the LES both acutely and it remained low 2 and 6 weeks post procedure. There was, however, no measurement of effect on gastric emptying or foregut motility per se and the animal's brains were not examined at the end of the study to confirm what if any brain damage had been created. To the author's knowledge, our model will be the first of its kind focusing on cerebral palsy and foregut dysmotility.

A common theme in all of these animal models in terms of the effect on function is that most have tended to focus on damage to the motor cortex. This is well-recognised and is understood that not only is there loss of voluntary control of movement, but a disordered development of reflexes. A group in Newcastle (A. Chen, Dimambro, & Clowry, 2008) also focused on motor function and found that chemically induced lesions created by injecting the neurotoxin ibotenic acid into the motor cortex at on postnatal day 5 to 7 (P5-7) in the rat were functionally and histologically similar to PVL. Although the technique only targeted the motor cortex and not areas which would affect gut motility it was reproducible and reported as a well-tolerated by the neonatal rat pups.

In addition to animal models, there have been some interesting in vitro studies involving culturing and growing oligodendroglia and examining its response to various toxins to help understand the pathogenesis at play in the development of PVL. Oka et al found that such cells were particularly susceptible to glutamate and that glutamate receptors may be a potential new target for new pharmacological treatments. (Oka, Belliveau, Rosenberg, & Volpe, 1993) Indeed the drug topiramate may be one such option and has subsequently been tried on a hypoxic rodent model with some effect. (Follett et al., 2004)

1.6.2 Theory behind our proposed cerebral palsy model

Scientists have long known that the cerebral cortex is integrally involved in influencing autonomic function. In 1902 Pavlov famously described what is now known as “Pavlov’s dog” and this is an example of the phenomenon of “psychic” secretion of gastric juice and introduced the concept of cortico-visceral relationships. More recent work from the Pavlov institute on Wistar rats has found that autonomic representation in the rat insular cortex is organised in a viscerotopic manner similar to that of the well-known homunculus of the motor cortex (Aleksandrov, Bagaev, Nozdrachev, & Panteleev, 1996; Bagaev & Aleksandrov, 2006). It is thought that the gastrointestinal control area lies in the middle part of the insular cortex. Hurley-Guis et al in 1986 described the association of the medial frontal cortex with control of visceral function and prompted them to term this region the ‘visceral motor cortex’ (Hurley-Guis KM 1986). Their experiments, again in rats, demonstrated that by electrically stimulating areas of the medial frontal cortex they could influence and measure changes in gastric motility. Bilateral intracortical microstimulation of medial frontal infralimbic and prelimbic cortical areas produced consistent reductions in gastric motility. The majority of responses consisted of reductions in gastric tone or in the amplitude of gastric contractions, or both.

Based on the above, our hypothesis is that damage to the medial prefrontal cortex and/ or insular cortex may affect autonomic control including control of gastric motility and this forms the basis of our model of this particular aspect of cerebral palsy. We have, therefore, designed our proposed model based on creating lesions in these two cortical regions using the same method as Chen et al i.e. stereotactically targeting these areas with the neurotoxin ibotenic acid. We expect to see as Chen et al did that such lesions lead to disorder reflexes and pathways that may well apply to reflexes of the enteric nervous system, which might develop aberrantly in the absence of cortically controlled inputs from the vagus nerve and sympathetic fibres. Lesions in these areas of the brain may affect the control of gastric emptying and in turn gastric motility and will give us the animal model we need of this one aspect of cerebral palsy i.e. a CP model with associated gastrointestinal foregut dysmotility. This will be a new model that has not been studied or reported elsewhere.

This does, however, logically lead to the question do we know that children with cerebral palsy have damage to these areas in the cerebral cortex? It has in the past been assumed that in most cerebral palsy patients the cerebral cortex is widely if not globally affected.

Neuroimaging of cerebral palsy patients is really still in its infancy and although more children are undergoing MRI scans many studies of such investigations do not provide detailed or consistent anatomical descriptions of the individual patient's brains or cortex. Atrophy is often commented on but limited to whether it involves grey or white matter or ventricles rather than specific areas of the cortex. (Korzeniewski SJ & Mark C. DeLano) The field of neuroimaging is, however, rapidly expanding and with the developments in functional MRI scanning and diffusion tensor topography may provide more detailed imaging of the brains of children with cerebral palsy. Englander et al recently published a study of CP patients using this relatively new technique of diffusion tensor tractography in 17 children with severe CP. Whilst they did not specifically look at the insular or MPFC they confirmed the concept of diffuse and significant reduction in white matter connections both long and short and involving the sensorimotor cortex. This also for the first time reported that in CP there are structural disruptions between networks of connections within the white matter of the brain. (Englander et al., 2013) As stated at the start of this chapter this concept is critical to the development of our animal model. There is evidence in the literature that changes in the medial prefrontal cortex can lead to functional disorders of the bowel such as irritable bowel syndrome (IBS). (Seminowicz et al., 2010) (Tillisch & Labus, 2011) The other issue is at the moment these children often need to be sedated or anaesthetized for such scan so as to reduce the amount of movement artefact. This is not without significant risk in such patients and therefore the use of routine brain scans of children with CP has not been widely adopted. As scanners improve this may negate the need for sedation or anaesthetic and the scans themselves may also improve in the detail that can be sought and help not only to explain the patient's symptoms but also may help target patient specific treatment.

1.6.3 Pros and cons of our CP model

The main "pros" of this model is that the technique described by Chen et al is easily adaptable to instead targeting different areas of the cerebral cortex. Ibotenic acid injection has already been shown to cause histologically similar lesions to PVL as we see in babies who go onto develop CP. (A. Chen et al., 2008) A possible advantage is that this model is expected to have excellent rates of animal survival on study compared to other induced maternal ischaemic models. This is important as we would like to study these animals for a prolonged period of time to allow us to measure their gastric emptying before and after splanchnectomy. There is also evidence from previous work using a rodent model, to

support and possibly explain the improvements we have seen clinically with CP and TS as it has been demonstrated in a “stress model” in the rat, using corticotrophin releasing factor (CRF) that the over activity of the sympathetic nervous system delays gastric emptying and that this can be counteracted by celiac plexus ablation.(Lenz, Burlage, Raedler, & Greten, 1988) In terms of performing splanchnectomy in rats the procedure is a more straightforward than in humans. As discussed earlier splanchnectomy is often performed in adult surgical practice thoracoscopically, as we have done in some children, i.e. through the chest, however in the rat the splanchnic nerves are found below the diaphragm making it easier and safer in our cerebral palsy model to divide these via laparotomy with diathermy. We plan to then investigate what effect this has on gastric emptying and foregut motility this may provide further evidence for splanchnectomy as another surgical tool in these difficult cases.(Aihara et al., 1978; Sapru, 1982)

The main downside of this model is that although the technique of injecting neonatal brains with ibotenic acid is proven to create brain lesions similar to that of PVL we are not mimicking or creating a physiological similar model to that which is thought to occur ante- or perinatally in humans. This model has been chosen in part to improve animal survival in our study and also to reduce cost as a rodent model is significantly less expensive than trying to create a larger animal model or a model that involves performing procedures on a pregnant animal.

1.6.4 How to assess gastric emptying (GE) in our CP model?

In the literature there are many different methods of assessing gastric emptying in rodents. The majority, however, involve the use of chemical markers such as phenol red, performing surgery or sacrificing the animal to assess gastric emptying or involve the use of scintigraphy with a chemically specified meal after a long period of fasting. (Ito, Isobe, Tsuchida, & Higuchi, 1996; Shoji et al., 1997; van der Velde, Koslowsky, & Koopmans, 1999) Each of these methods was considered in turn but those that involved sacrificing animals were deemed not suitable as the animals in our study design need to go on to have repeated gastric emptying studies i.e. before and after brain injection and before and after splanchnectomy for a prolonged period of study. We accept that scintigraphy would be the gold standard for our study much like in clinical practice, however, this was not readily available in our research centre and would have involved huge expense and training in this technique. There was a readily available X-ray machine and water soluble contrast and so

the decision was made at least for this study to perform simple water soluble contrast swallows and meals. There are few non-invasive techniques reported in freely-feeding animals. It has previously been shown that gastric emptying increases toward the end of the lactation period in rat pups. We decided to modify the barium grain method (Sakurai et al., 1996) and use water soluble contrast rather than barium grains, as done in clinical practice in children and babies. Gastric emptying time would therefore be the time from when the stomach was full to completely empty on time lapsed X-rays in animals placed in X-ray compatible plastic tubes. This would allow a non-invasive method of a water-soluble contrast meal in a conscious and prior to the study freely suckling pup and therefore a more reliable and “real” and useful method of assessing gastric emptying in pre-weaned rats.

1.7 Rationale

In summary, cerebral palsy is a condition which is on the increase because more and more children born prematurely are surviving. There is a real spectrum of children with CP in terms of how they are affected from a developmental point of view and a motor function point of view. The effects of CP on bowel functional especially the foregut is still under recognised, but it is now widely believed that children with CP commonly suffer not just from GORD but from foregut dysmotility leading to symptoms such as vomiting, retching and abdominal pain and feed intolerance commonly previously attributed solely to GORD. It has also become apparent over the last decade that evidence is absent in terms of how best to manage these patients and the options open to clinicians and surgeons are limited and of those that are available many have serious complications.

This has led us to conclude that there is a much needed animal model of cerebral palsy and foregut dysmotility, to allow us to study why CP leads to such symptoms and problems with feeds, and to investigate whether new treatments whether it be surgical or medical may show promise.

We have noted from previous clinical experience that thoracic splachnectomy (TS) can help with improving gastric emptying and associated symptoms as described above when all else fails. This is a procedure commonly performed in adult patients as a day case and hence why we wish to perform the technique on our animal model to see if we can further cement the usefulness of this procedure for this specific group of challenging parents.

1.8 Hypothesis

It is our hypothesis that foregut dysmotility in children with cerebral palsy is a result of over activity of the sympathetic nervous system and that this leads to an imbalance in the autonomic nerve supply to the bowel as depicted in the Figure 13 below. Modification of a previous cerebral palsy animal model by targeting ibotenic acid at the MPFC and/or insular cortex will therefore lead us to develop a model of cerebral palsy with proven foregut dysmotility including delayed gastric emptying.

Secondly, we hypothesise that by performing splanchnectomy on our model we may demonstrate a “re-balancing” of the neural control and so improve gastric emptying, again as depicted in the figure below. We hope by developing such a model and its further study will aid in the development of much needed treatment options for children with cerebral palsy and indeed other children who are neurologically impaired who have symptoms of dysmotility and delayed gastric emptying.




Figure 13. A schematic diagram illustrating the crux of our hypothesis i.e. that dysmotility (A) is the result of an imbalance between the autonomic nervous supply to the foregut and that by performing splanchnectomy the balance can be redressed as shown in (B).

1.9 Specific Aims

1. We aim to investigate whether targeting certain areas in the cerebral cortex of neonatal rat pups i.e. the medial prefrontal cortex (MPFC) and/or the insular cortex will lead to lesions in the brain similar to PVL and to evidence of delayed gastric emptying that is proven and reproducible. We aim to develop such an animal model to try to provide the scientific basis for the improvements we have seen clinically.
2. We aim to perform histological examination including immunohistochemistry on our CP model and compare this to controls so as to potentially reveal any difference in the foregut between the two groups.
3. We aim to perform splachnectomy on our established animal model to investigate if this will improve gastric emptying and enteric motility. This will attempt to explain the clinical improvements we have seen by examining the animals functionally after splachnectomy and histologically.
4. We aim to examine archived foregut specimens of children with cerebral palsy and known foregut dysmotility to see if there are any similarities between such biopsies and those take from our newly developed animal model.

Chapter 2

Materials and Methods

2.1 The animal model

2.1.1 The choice of the rodent model

The choice of a rodent model was based on several factors. These included easy availability of Sprague Dawley rats and the robustness of this species for repeated use i.e. being used on more than one protocol. The main advantage was that our model was based on a previous rodent model of cerebral palsy using a technique that was easy to learn and was reproducible. (A. Chen et al., 2008) Rodents have often been selected particularly, for mammalian neuroscientific research, because not only are they relatively cheap to look after and easy to acquire, but they are fairly resistant to infection and are big enough to place in a stereotaxic frame. Following on from this there is a very detailed atlas of the rat brain by Paxinos et al that provides stereotaxic coordinates for the areas of interest. (Paxinos and Watson 1996) Neonatal Sprague-Dawley rat pups were bred in house at the University of Glasgow Central Research Facility

The average litter size of the Sprague Dawley rat is 10-11 pups. The pup's birthweight differs depending on the litter size but ranges between 5.9-6.4 grams. The adult body weight is 250–300g for females, and 450–520g for males. The typical life span is 2.5–3.5 years. Our study is split into two stages initially. Stage one is developing our animal model and stage two is performing splachnectomys on this model. Finally, there is then a third stage analysing a historical cohort of human biopsies. This chapter describes the methods involved in each of these three stages.

We performed brain injections as described below on postnatal day 5-7 as this was found by Chen et al to be the ideal time to create lesions similar to PVL and to essentially correspond to the window of time of white matter vulnerability. (A. Chen et al., 2008) The median weight at time of operation in stage one i.e. creating brain lesions was 13.5 grams (range 7.5-21 grams). They are commonly weaned at 3 weeks of age and were then on a

full adult diet. The median age at time of splachnectomy was day 21 and the median weight at splachnectomy was 64 grams (range 43.8-108gram).

2.2 Animal management and care

Animals were housed in the in Central Research Facility, University of Glasgow and were kept in a dedicated rodent room which was maintained at temperatures between 70 and 72°F with a photoperiod of 12 hours light and 12 hours dark (7am-7pm and 7pm-7am). Humidity was controlled between 45-55%. As neonates, the pups were housed with their mother or dam and allowed to feed normally and kept in standard bedding until they were weaned around 21 days of age. They were then they were housed with their littermates depending on the stage of the study. All cages had environmental enrichment with wood shavings, cardboard tubes and sizzle nest. Their diet post weaning was BK Expanded diet provided by Special Diet Services and they were cared for in a free feeding environment. Cage changes were performed once weekly and rats were examined daily by a senior member of the technical staff familiar with the study. All animals were weighed regularly whilst on study. All procedures and surgery were conducted in accordance with the Animals (Scientific Procedures) Act 1986, under licenses issued by the UK Home Office (PPL 60/4262), by appropriately-qualified individuals.

2.3 Gastric Emptying (GE) study technique

There are many different techniques used in clinical practice to assess gastric emptying in humans and many techniques have been employed in animals in biomedical research such as the barium grain technique. (Sakurai et al., 1996) In this study gastric emptying time (GET) was recorded by gavaging 0.2mls of water soluble contrast Omnipaque 300 (Iohexol 647mg equivalent to 300mg of organic iodine per mL) and placing animals awake in a x-ray compatible red rat restrainers (AH200AR supplied by Vet Tech Congleton Cheshire) similar to a Perspex 'VetMouse Trap' (Oliveira et al., 2011). Digital time lapsed x-rays were then performed using the Kodak FX Pro imaging system. Typical images from a GE study are shown below. The GET was measured as the time of gavaging the rat to the time the stomach was completely empty on imaging. This technique avoided the need for an anaesthetic which would have affected GET and also meant that animals were able to be freely feeding both as neonates and post weaning.

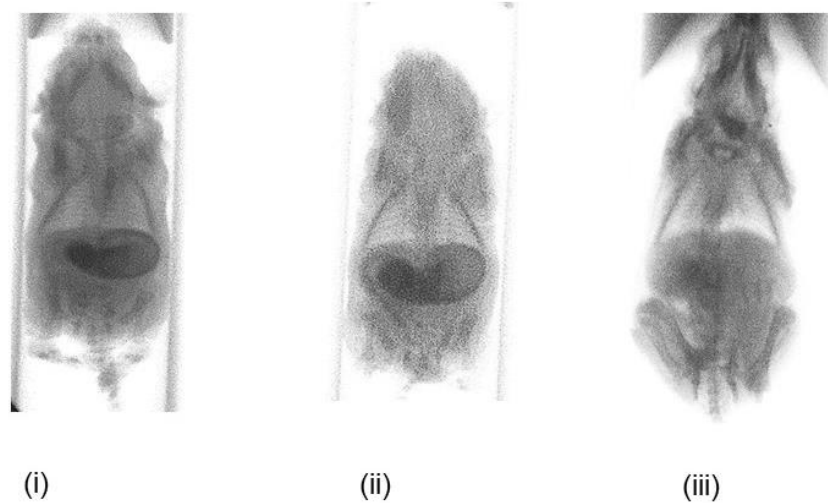


Figure 14. Images from rodent gastric emptying studies. This pup has undergone a bilateral MPFC injection with ibotenic acid. (i) shows contrast in the stomach (ii) shows contrast leaving the stomach and entering the small bowel (iii) shows an empty stomach with some contrast in the small bowel and contrast also refluxing back into the oropharynx.

2.4 Anaesthesia – Phase 1

2.4.1 Induction

On the day of surgery neonatal rat pups (postnatal days 5-6) that were freely feeding from their mother were anaesthetised by injecting 0.3 $\mu\text{g}/\text{kg}$ bodyweight fentanyl citrate and 10 $\mu\text{g}/\text{kg}$ fluanisine (Hypnorm®, Janssen) subcutaneously according to published guidance from Clowry and Flecknell. (Clowry, 2000) This technique was specifically investigated by Clowry and Flecknell because although there are various types of inhalational anaesthesia such as isoflurane and halothane, these agents can be difficult to use specifically when anaesthetising neonatal rat pups. This is because inhalational anaesthesia requires placing the very small pup's nose in a face mask which can be challenging given the animal's size. In addition, such apparatus can make it difficult to perform midline craniotomies and brain injections via a stereotaxic frame as shown below in the surgical protocols. This specific type of surgery on small neonatal animals also makes it difficult to scavenge excess inhalational gas and therefore limits the ability to reduce exposure to the person performing the procedure. For all these reasons, subcutaneous Hypnorm® was chosen. Induction with Hypnorm® usually occurs within 5-10 minutes. Adequate induction of anaesthesia was assessed by carefully pinching the toes of the pup's hind limb

with a toothed forceps and observing for any pain or withdrawal reflex. Careful observation for movement of the animal was important prior to skin incision, not only to assess adequate induction of anaesthesia, but was also essential prior to positioning of the needle on the stereotaxic frame.

2.4.2 Maintenance

Hypnorm®, in addition to being used as an induction agent, can also be used to provide maintenance anaesthesia, but it is important to continuously observe for jerking movements as discussed by Clowry and Flecknell. Their paper (Clowry, 2000) demonstrated not only good depth of anaesthesia for neurosurgical procedures but also excellent survival rates, something which can be difficult to achieve when operating on such small neonates. These authors also stressed that whilst this drug is highly successful when given subcutaneously a high animal loss rate was noted when given intraperitoneally and this is not recommended and therefore this route was avoided in this study.

2.4.3 Recovery

The pups were then transferred to recovery where they were kept warm on a warming blanket, given oxygen and constantly stimulated by gentle prodding with cotton buds to prevent apnoea. All animals were monitored with a modified APGAR score post-operatively as described by Zani et al (Zani et al., 2008) and shown in the table below. This is similar to the APGAR tool also used by Veronesi et al (Veronesi, Panzani, Faustini, & Rota, 2009) when monitoring neonatal canine puppies. This tool was used immediately post op and then when neonates were deemed fit they were returned to their mother. If analgesia was required Buprenorphine 0.01-0.005 mg (0.005-0.015ml/100g body weight) was administered subcutaneously (Buprecare® 0.3mg/ml, Animal care Ltd supplied by Henry Schein Ltd Dumfries). The animals were then inspected daily for infection or suture removal and weighed regularly. Post-operative infection has not previously occurred in similar models but if this occurred this was treated by systemic administration of antibiotic or termination of the experiment by killing by a schedule 1 method. Suture removal can also sometimes occur and should this happen wounds would be re-sutured under anaesthesia on one occasion only. This did happen on one occasion. In addition, any animal displaying abnormal behaviour (lack of inquisitiveness, hunched appearance, boarding of the abdomen) would be discussed with our named veterinary surgeon (NVS). Similarly, animals were closely observed for potential effects of the lesion, created by long

needle and delivery of neurotoxin to the cortex of the brain. Previous procedures in a similar model (A. Chen et al., 2008) has been well tolerated. However, effects of the specific lesions we were attempting to generate is as yet unknown. If the condition of the animal were to cause concern advice would be sought from the NVS and if necessary animals would be killed by a Schedule 1 method.

2.4.4 Endpoints

In phase 1 animals were humanely killed on day 28 of life to allow histological examination of the brain to assess the extent of the brain injection and any evidence of white matter injury or features in keeping with PVL. Animals were euthanized by first administering an overdose of sodium pentobarbital, 1 ml (200mg in 1ml) per 1.4kg body weight (Euthatal®, Merial supplied by Henry Schein Ltd Dumfries) subcutaneously and then placing the rat in a chamber with a rising concentration of CO₂ (CO₂ flow rate: 0.2Lmin rising to 1L per min). Once animals were deeply anesthetised all four limbs were fixed with 23G needles (BD Microlance, UK). The thorax was opened with dissecting scissors and the heart and the great vessels were exposed. An 18G needle (BD Microlance, UK) was inserted into the right atrium of heart and the rat was perfused transcordially with 0.9% saline, followed by buffered fixative (1 l/kg body weight) consisting of 4% paraformaldehyde (PFA®, Sigma-Aldrich, Poole, UK). A window was then made in the right ventricle with scissors to let returning blood. Complete fixation was determined when then tail and all four limbs of the animals were rigid. Following successful perfusion, the entire head with the animal's brain were stored in 4%PFA. Once transferred to the histopathology laboratory samples were transferred to 10% neutral buffered formalin (NBF) for 72-96 hours. The brains were then dissected from the skull and were trimmed into 1mm thick slices at multiple levels. Similarly, all the bowel from the oesophagus to rectum was harvested and stored in 4%PFA prior to histological examination. The remainder of the carcasses were bagged and placed in a refrigerated locker until collection for incineration.

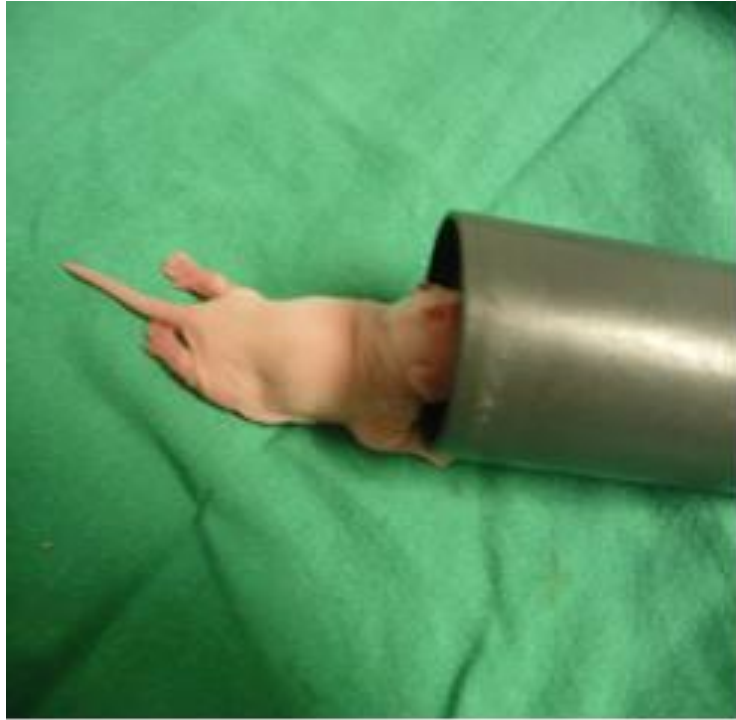

Figure 15. Post-operative rat pup having undergone craniotomy and brain injection.

The pup is shown in recovery on a heat mat and is receiving oxygen and regular stimulation and monitored as per the modified APGAR score.

Table 4. The modified APGAR score. This is an easy and reliable scoring system modified from human clinical practice and validated in animal practice by Zani et al

Appearance	
0	The pup rat is tonic and well hydrated
1	The pup rat is slimmer but still tonic and hydrated
2	The pup rat is skinny, floppy, and dehydrated
3	The pup rat is gasping and in agony
Response to touch	
0	The pup rat is alert (without stimulation)
1	The pup rat responds to mild stimulation
2	The pup rat responds to vigorous stimulation
3	The pup rat is unresponsive notwithstanding a vigorous stimulation
Natural activity	
0	The pup rat moves normally in the cage
1	The pup rat, if put supine, is able to wriggle
2	The pup rat, if put supine, is not able to wriggle
3	The pup rat does not move its limbs and lays still
Colour	
0	The pup rat skin colour is pink
1	The pup rat skin colour is pale (just at the extremities)
2	The pup rat skin colour is pale (whole body)
3	The pup rat skin colour is grey

2.5 Anaesthesia - Phase 2

2.5.1 Induction

The induction agent in phase 2 of the study was the inhalational agent, Isoflurane, instead of Hypnorm® as the licence for Hypnorm® ran out during the study and so this could no longer be supplied to our research facility. It was felt; however, now that the technique had been learnt in phase 1, the stereotactic frame could be modified to ensure that the rat pups were able to receive inhalational anaesthesia. Induction was, therefore, carried out as per current guidelines (Flecknell (2015) Laboratory Animal Anaesthesia, 4th edition, Elsevier). The animal was placed in an induction chamber and isoflurane or Isoflo® (100% weight/weight Inhalation vapour liquid, Abbott labs supplied by Henry Schein Ltd

Dumfries) was given at a flow rate of between 500-1000 ml/min until the animal was recumbent and not responding to painful stimuli to the hind limb.

2.5.2 Maintenance anaesthesia

The supply of isoflurane was then switched to the nosecone and the animal was positioned in the nosecone supplied with 1l/min of oxygen and 300-200ml/min of Isoflurane (Isoflo® 100% weight/weight Inhalation vapour liquid, Abbott labs supplied by Henry Schein Ltd Dumfries). The animal was monitored throughout the procedure in terms of colour, respiratory rate and movement or reaction to painful stimuli.

2.5.3 Recovery

Animals in phase 2, undergoing laparotomy and splachnectomy, were recovered in a similar manner to stage 1 i.e. oxygen, warming blanket and observed with the use of the Modified Apgar score and when deemed fit, returned to their cages with their cohort. If analgesia was required Buprenorphine 0.01-.005 mg (0.005-0.015ml/100g body weight) was administered subcutaneously (Buprecare® 0.3mg/ml, Animal care Ltd supplied by Henry Schein Ltd Dumfries). Again, animals were monitored for wound infection and suture removal as described above.

2.5.4 Endpoints

In phase 2 animals were kept on study for much longer than phase 1 to enable recovery from initial brain injection and subsequent gastric emptying studies both pre- and post-splachnectomy. Animals were, therefore, euthanized at 16 weeks of age following the completion of the surgical protocols. This was again performed in a similar method to phase 1 with an overdose of subcutaneous sodium pentobarbital, 1 ml (200mg in 1ml) per 1.4kg body weight (Euthatal®, Merial supplied by Henry Schein Ltd Dumfries) and placed in a chamber of rising concentration of CO₂. Once animals were deeply anesthetised all four limbs were fixed with 23G needles (BD Microlance, UK). The thorax was opened with dissecting scissors and the heart and the great vessels were exposed. An 18G needle (BD Microlance, UK) was inserted into the right atrium of heart and the rat was perfused transcardially with 0.9% saline, followed by buffered fixative (1 l/kg body weight) consisting of 4% paraformaldehyde (PFA®, Sigma-Aldrich, Poole, UK). A window was then made with scissors to open the right ventricle to let returning

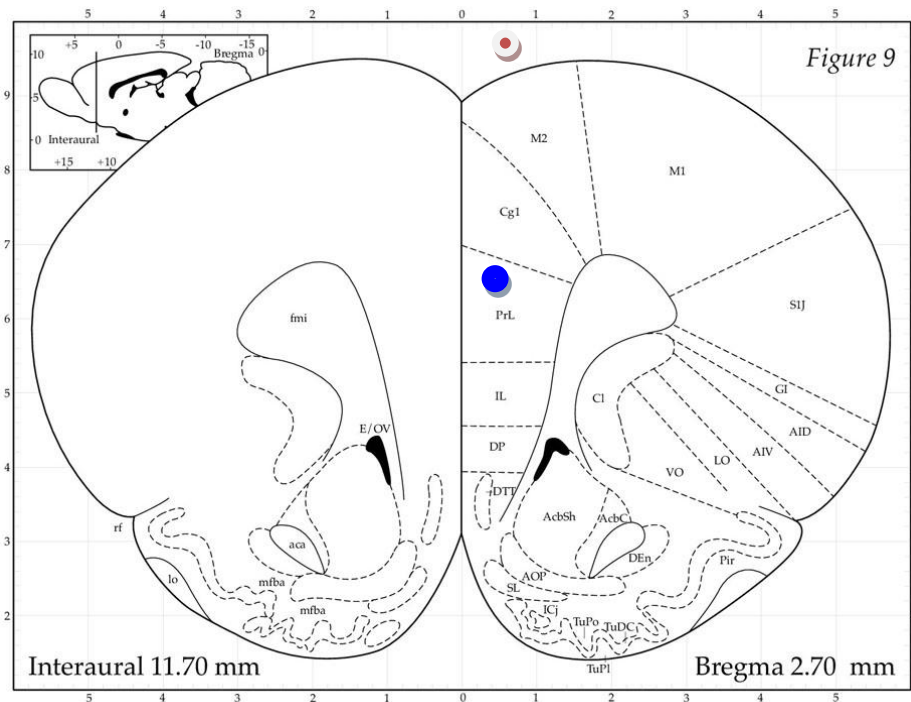
blood. Following successful perfusion, as described above, as in phase 1 the animal's brains were dissected from the skull and all the bowel from oesophagus down to rectum was harvested and stored in 10% buffered formalin. Again, the remainder of the carcasses were bagged and placed in a refrigerated locker until collection for incineration.

2.6 Surgical Protocols

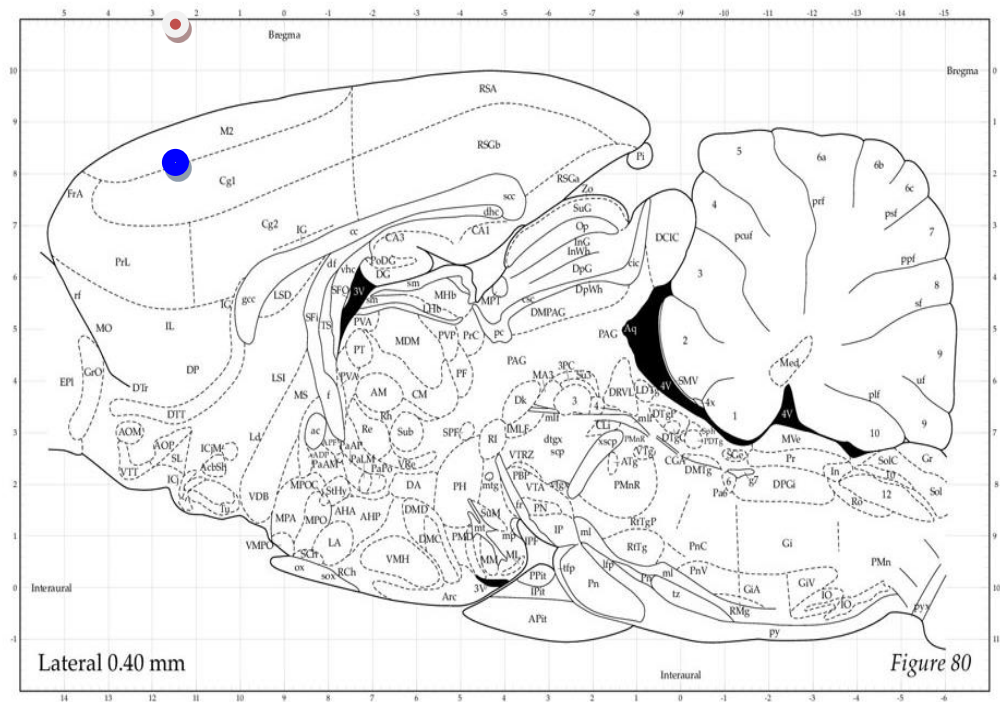
2.6.1 Midline Craniotomy and brain injections

Neonatal Sprague-Dawley rat pups aged postnatal days 5-6 (P5-6) underwent midline craniotomies under anaesthesia to allow either unilateral or bilateral brain injections of the neurotoxin, ibotenic acid (IBA) (Tocris, Cat. No. 0285), in the medial prefrontal (MPFC) or insular cortex, using a digital stereotaxic frame. P5-6 was chosen as this has been shown to correspond to the stage of white matter vulnerability and that neurotoxin injections at this stage can mimic lesions that appear histologically similar to human periventricular white matter injury as seen in cerebral palsy. The anaesthetised animal was placed prone in a digital stereotaxic frame (Harvard Apparatus limited) and fitted with an elite nanomite stereotaxic syringe pump (Harvard Apparatus Limited) and underwent midline craniotomy (Figure 18). An injection was then made of a 2.5 μ l solution containing either 2.5 μ g of IBA in 2.5 μ l sterile saline or 2.5 μ l sterile saline solution only. This was administered with a 25 μ l Hamilton syringe over 1 minute and the needle was left to rest for 5 minutes and then carefully removed. The digital stereotaxic frame was used to target either the insular cortex (IC) or medial prefrontal cortex (MPFC) using coordinates from the Paxinos rat brain atlas and using Bregma and the interaural line as landmarks (see the figures below). The IC is made up of four parts craniocaudally: the granular insular cortex (GI), the dysgranular insular cortex (DI) and the dorsal and ventral agranular insular cortex (AID and AIV respectively). The MPFC along with the anterior cingulate cortex (ACC) makes up the medial frontal cortex (MFC). The MPFC consists of three regions the cingulate cortex (Cg1), the prelimbic cortex (PrL) and the infralimbic cortex (IL). The standard nomenclature for the coordinates are similar to the more commonly used "xyz" coordinates used in mathematics, but instead are anteroposterior (AP) from Bregma, medial lateral (ML) and dorsal ventral (DV). The coordinates for the MPFC and IC used were ML 0.3mm, AP 2.7mm, DV3.2mm and ML 5.5mm, AP 1.0mm, DV 5.2mm respectively (Paxinos and Watson, 2006). The two figures below show these

two areas targeted in both coronal and sagittal views. Although these measurements are commonly used for adult rats rather than neonates, the coordinates were used as a guide for all neonates regardless of sex or weight. This was because this is the only guide available and so in particularly small animals the coordinates were adjusted slightly on a case by case basis.





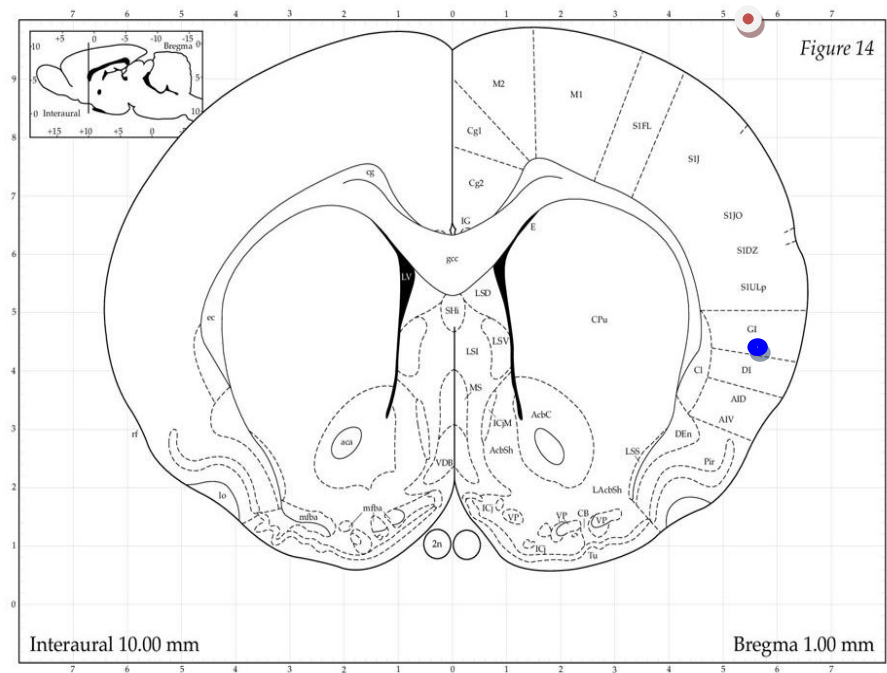
(A) Coronal view: aca = anterior commissure, ant; AcbC = accumbens nu, core; AcbSh = accumbens nu, shell; AID = agranular insular cortex, dorsal; AIV agranular insular cortex, ventral; AOP = anterior olfactory area, posterior part; Cg1 = cingulate cortex, area 1; Cl = claustrum; DEn = dorsal endopiriform nu; DP = dorsal peduncular cortex; DTT = dorsal tenia tecta; fmi = forceps minor corpus callosum; GI = granular insular cortex; ICj = islands of Calleja; IL = infralimbic cortex; lo = lateral olfactory tract; LO = lateral orbital cortex M1 = primary motor cortex; M2 = secondary motor cortex; mfba = medial forebrain bundle “a” component; Pir = piriform cortex; PrL = prelimbic cortex; SIJ = primary somatosensory cortex, jaw region SL = stratum lucidum; Tu = olfactory tubercle.



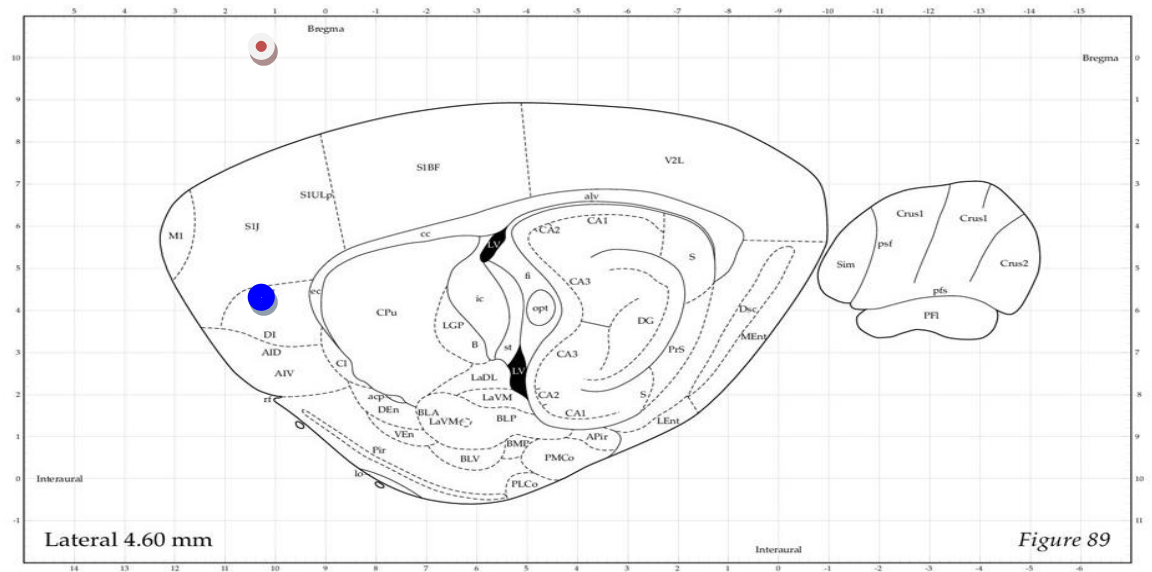
(B) Sagittal view of the MPFC - for relevant abbreviations see Fig 15 (A)

Figure 16. Rat brain atlas figure of the medial prefrontal cortex.

(A) Coronal and (B) Sagittal views of “Bregma 2.7mm (Paxinos and Watson, 1996).” Figure reproduced kindly with permission sought from “Paxinos, George, and Charles Watson. The rat brain in stereotaxic coordinates: hard cover edition. Access Online via Elsevier, 2006”. The path between  and  shows the entry point and targeted region of the brain respectively.





(A) Coronal view of the IC: 2n = optic nerve; aca = anterior commissure, ant; AcbC = accumbens nu, core; AcbSh = accumbens nu, shell; AID = agranular insular cortex, dorsal; AIV agranular insular cortex, ventral; CB cell bridges ventral striatum; cg = cingulum; Cg1 = cingulate cortex, area 1; Cg2 = cingulate cortex, area 2; Cl = claustrum; CPu = caudate putamen (striatum); claustrum; DEn = dorsal endopiriform nu; ec = external capsule; gcc = genu of corpus callosum; GI = granular insular cortex; ICj = islands of Calleja; ICjM = islands of Calleja, major island; IG = indusium griseum; LAcSh = lateral accumbens shell; lo = lateral olfactory tract; LSD = lateral septal nu, dorsal part; LSI = lateral septal nu, intermediate; LSS = lateral stripe of the striatum; LSV lateral septal nu, ventral part; LV = lateral ventricle; M1 = primary motor cortex; M2 = secondary motor cortex; mfba = medial forebrain bundle “a” component; Pir = piriform cortex; Shi = septohippocampal nucleus; S1J = primary somatosensory cortex, jaw region; SDZ = primary somatosensory cortex, dysgranular zone; S1ULP = primary somatosensory cortex, upper lip region; Tu = olfactory tubercle; VDB = nucleus of the vertical limb of the diagonal band; VP = ventral pallidum.



(B) Sagittal view of the IC – for relevant abbreviations see Fig 16 (B)

Figure 17. Rat brain atlas figure of the insular cortex.

(A) Coronal and (B) Sagittal views of “Bregma 2.7mm (Paxinos and Watson, 1996).” Figure reproduced kindly with permission sought from “Paxinos, George, and Charles Watson. The rat brain in stereotaxic coordinates: hard cover edition. Access Online via Elsevier, 2006”. The path between  and  shows the entry point and targeted region of the brain respectively.

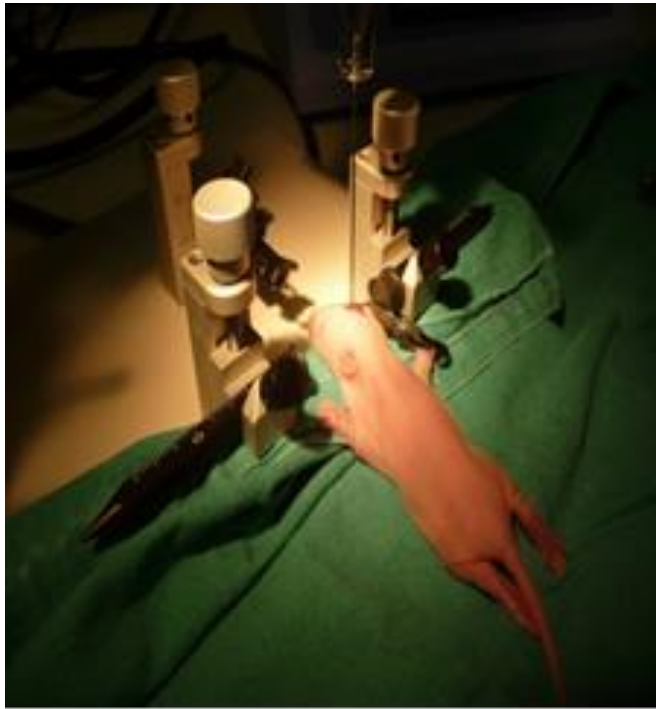


Figure 18. A neonatal rat pup in the stereotaxic frame. The pup is shown having been anaesthetised by subcutaneous Hypnorm® on a sterile drape positioned within the stereotaxic frame and undergoing brain injection through a midline craniotomy wound.

Pups underwent either unilateral or bilateral injections in each of the two regions (MPFC or IC) or sham injections of normal saline. The craniotomy wound was then closed with 6/0 vicryl interrupted sutures. All animals were monitored with a modified APGAR score post-operatively. Gastric emptying studies were then performed (as described above) between 7 and 21 days postoperatively to look for any delay in gastric emptying times (GET) and animals were weighed regularly. GET was recorded by gavaging 0.2mls of water soluble contrast and performing time lapsed x-rays as described above. The pups were then perfused on day 28 of life and their brains examined with Haematoxylin and Eosin and Cresyl Violet staining to assess the extent of the brain lesion created. (see below)

2.6.2 Splanchnectomy

In rodents the splanchnic nerves are positioned just below the diaphragm and so can be approached by midline laparotomy. (Sapru, 1982) This has the advantage of not having to go through the chest, which would most likely result in a higher animal loss. Prior to operating on live animals that were on study laparotomy was performed on rodent cadavers

and not only was the technique practiced but the splanchnic nerves were resected and analysed histologically to further confirm that what we were targeting was correct. We then progressed to operating on live animals. Once under adequate depth of anaesthesia the rat was prepped, shaved and draped and a midline laparotomy wound was made. The linea alba was then easily identified and the peritoneal cavity opened safely. A unilateral left-sided splanchnectomy was then performed by first delivering the bowel and then the stomach and spleen were reflected out the way taking care not to damage the spleen or liver. Unilateral splanchnectomy was performed for two reasons; the first being that to attempt right sided splanchnectomy in such a small animal would have meant retracting and dissecting in close proximity to the liver which would have vastly increased the risk of bleeding and the subsequent rate of animal loss. Secondly and more importantly, in the human literature, it has been widely reported that unilateral splanchnectomy is not only successful, but also less risky. For example, several papers have shown that left sided splanchnectomy alone is effective for controlling pain in patients with inoperable pancreatic cancer. (Lica, Jinescu et al. 2014) (Leksowski 2001, Masuda, Kuramoto et al. 2014) The splanchnic nerves were then divided with bipolar diathermy and the animal closed with two-layer closure using 2/0 vicryl ® and 5/0 vicryl ® interrupted buried subcuticular stitches for skin. The animal was recovered as described above. All animals underwent splanchnectomy whether they had a sham brain injection with normal saline or a bilateral MPFC with IBA. No sham splanchnectomys were performed.

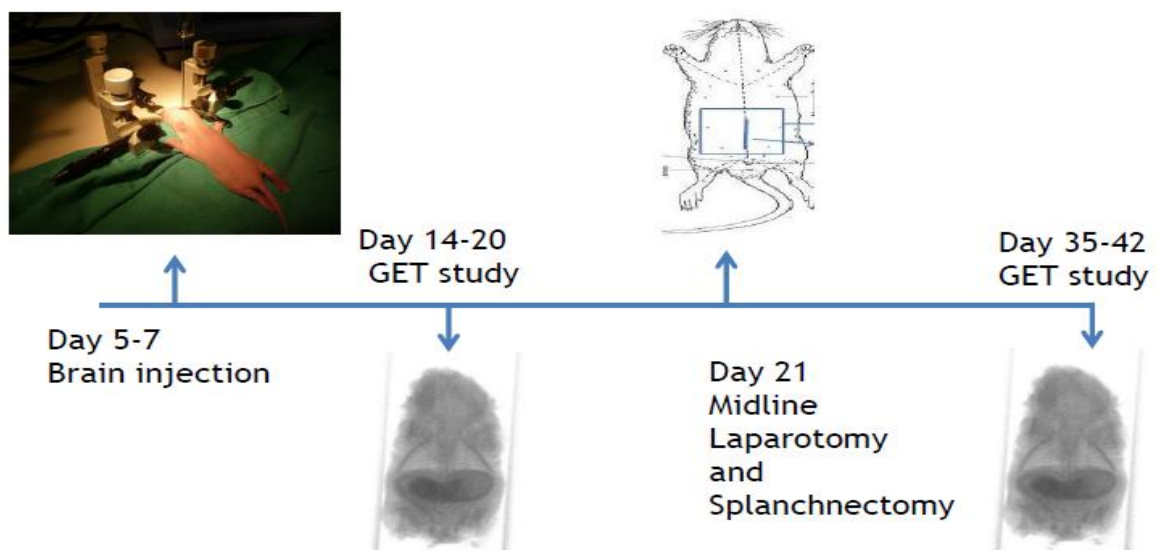


Figure 19. A timeline of phase 2 of the study.

Materials and Methods

The craniotomy and brain injection were performed on day 5 to 7 of life followed by the first GE study pre splanchnectomy, then laparotomy and splanchnectomy and then a second GE study.

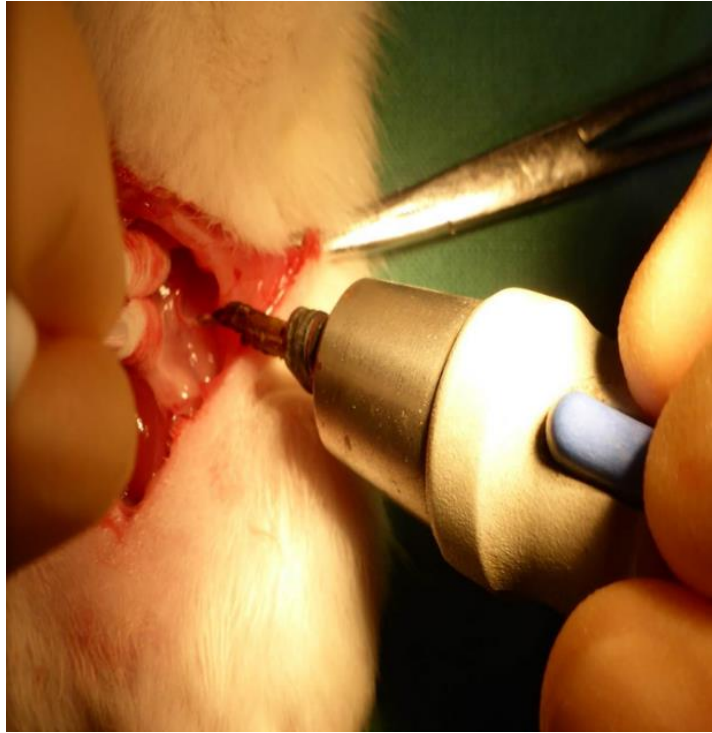

Figure 20. Intraoperative photograph showing midline laparotomy.

Cotton buds are holding stomach and spleen medially and handheld bipolar diathermy to divide the branches of the splanchnic nerves.

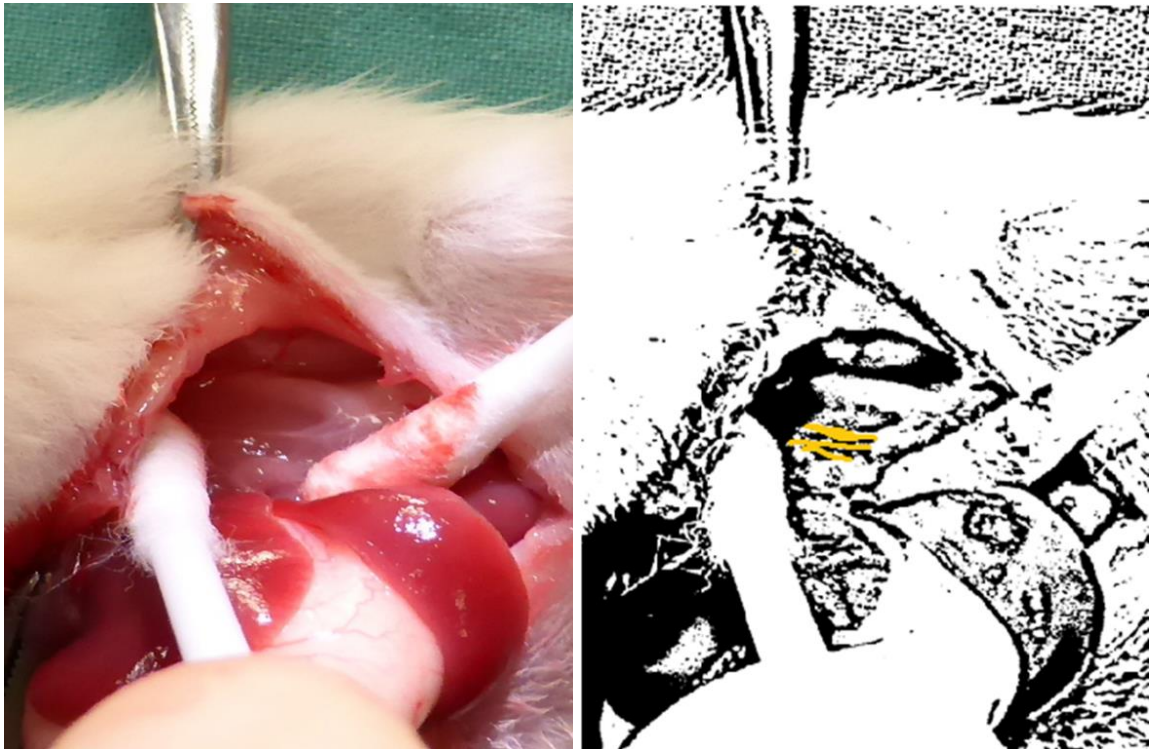


Figure 21. Intraoperative view of the splanchnic nerves.

This photo and accompanying illustration show the three branches of the splanchnic nerves highlighted having reflected the stomach and spleen out the way. The nerves are then divided with bipolar and then animal closed and recovered.

2.7 Laboratory Analysis

The laboratory analysis undertaken differed between phase 1 and phase 2 of our study. In phase one, we were developing our CP model and so all brains of the rats were analysed to assess the extent of the unilateral or bilateral lesion created either in the IC or MPFC, regardless of whether IBA was used or normal saline (i.e. a sham operation). In phase 2 brains were stored but lesion analysis was not repeated. Also in both phase 1 and phase 2 foregut biopsies were examined following perfusion of the animals. Perfusion and biopsy retrieval was performed by the author. Sectioning, embedding and immunohistochemistry techniques were performed by Mrs Lynn Stevenson and her team at Veterinary Biosciences, University of Glasgow. Histological and pathological advice was sought from Dr Francesco Marchesi and Dr Joshua Leach when interpreting slides.

2.7.1 Brain lesion analysis

In phase 1 following the sacrifice and perfusion of animals on day 28 of study, as described earlier in this chapter, brains were dissected from the skull and transferred into 10% neutral buffered formalin. Two coronal sections were collected from each specimen and processed to paraffin blocks. The two samples were embedded in the same block. Two consecutive sections from each block were then stained with Haematoxylin and Eosin (HE) and Cresyl Violet (CV). The approximate level of sectioning into 4 μ m slices was estimated on the basis of the anatomical structures identified and in the histological sections. The sections were then examined to assess the extent and site of the brain lesion created. This involved assessing for loss of cortical neurons and/or ventricular dilatation i.e. features in keeping with the development of PVL.

2.7.2 Collection of foregut specimens

Collection of foregut specimens occurred after perfusion for all the animals i.e. in phase 1 and 2. This involved taking four 1x1cm biopsies as shown in the diagram below. The specimens were taken from consistent sites in the foregut, as shown in the diagram below, namely (1) the distal oesophagus, (2) the midpoint of the greater curvature of the stomach, (3) the antrum of the stomach and (4) the second part of the duodenum. Samples were stored in 10% neutral buffered formalin.

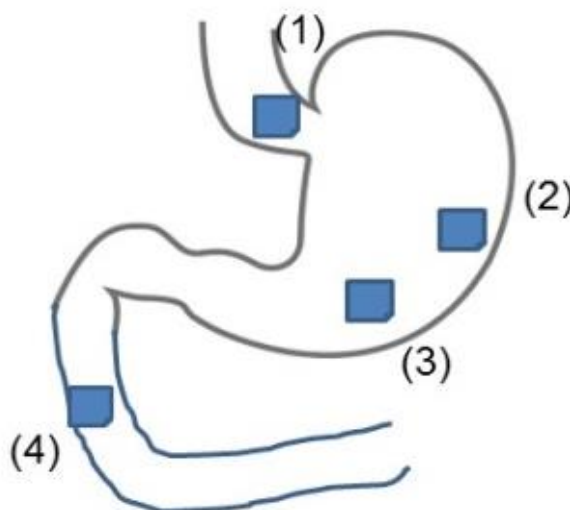


Figure 22. Schematic diagram of the foregut specimens.

Four points were chosen at which samples were taken i.e. distal oesophagus, midpoint of greater curvature, antrum and second part of duodenum.

All reagents are made in house at Veterinary Biosciences, University of Glasgow. The samples were then washed with water and stained in Gills Haematoxylin for 5 minutes. The sections were again washed in water and allowed to differentiate in 1% acid alcohol. They are then washed in water again and underwent bluing before being counterstained with Putts Eosin for 5 minutes and then again washed in water. The sections were then dehydrated, cleared, and mounted. This protocol allows all nuclei to be stained blue and all other tissue components various shades of red or pink.

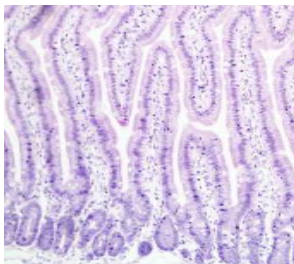

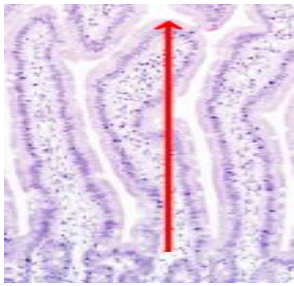
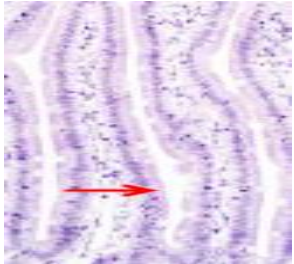
2.7.3 Histological assessment of foregut samples

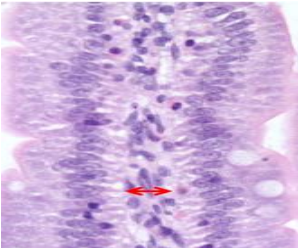
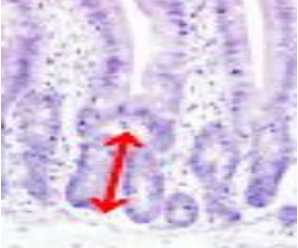

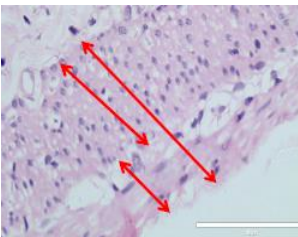
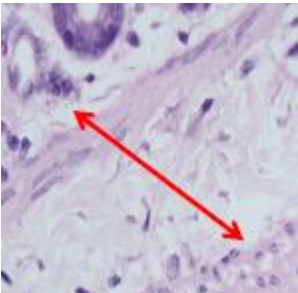
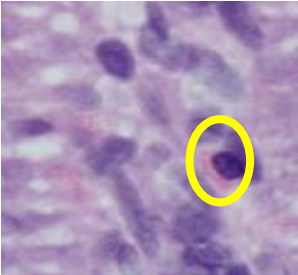
In phase 1 the histological assessment of foregut samples was split into three stages. The first stage consisted of an initial “spot the difference” analysis by the author comparing known sham animals to known animals with different brain lesions i.e. bilateral or unilateral IC or MPFC lesions. Following this two veterinary pathologists were asked to perform a blinded analysis of duodenal samples and to allocate these specimens into three groups: “no change”, “mild change” and “significant change”. The third stage then involved further examination of samples identified as showing a difference in stage 1 and 2. This third stage involved using a modified pathology scoring system. This scoring system was based on concepts described by Day et al which set standards for analysing bowel samples in different species i.e. quantifying villi height and width “per x40 stretch” or the number of a particular cell type “per 100 enterocytes” etc. (Day et al., 2008) The scoring system used in our study is summarised in the table below and allowed more accurate comparison between specimens from sham animals and those animals that underwent injection with IBA in different sites of the brain. In terms of how such variables were measured e.g. the length and width of villi and the thickness of the muscularis and submucosa then slides were digitalised by using the EVOS™ FL Auto Cell Imaging System (Thermo Fischer Scientific, Loughborough, UK) and then images were analysed using ImageJ software (Schneider, Rasband, & Eliceiri, 2012) allowing accurate measurement of structures in μm . This third stage in the analysis of specimens was performed by the author and further corroborated by a senior veterinary pathologist.

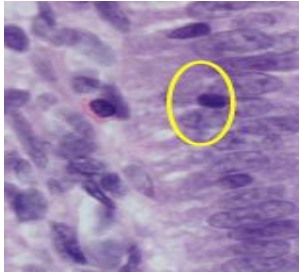
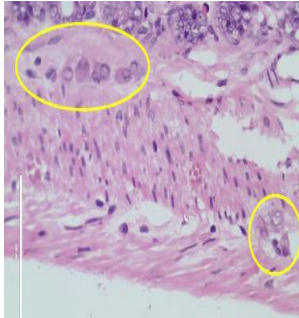
In phase 2 a similar spot the difference analysis was made this time between not only shams and our CP model but of the two groups post laparotomy and splanchnectomy. Again, once the spot the difference analysis was undertaken the scoring tool described above was employed for biopsies to streamline a more detailed comparison between the CP model and shams.

Table 5. Modified pathological scoring system for assessing intestinal specimens.

This comprises 14 pathological features and how they are assessed on a slide in a standard fashion to aid statistical comparison (based on concepts from Day et al (Day et al., 2008).

Pathological feature	Image	Measured by:
1. Villous number		Counting all villi in the FOV* x40 and then multiplying by number of FOVx40 per slide
2. Number of bifid villi		Counting number of bifid villi at x40 along length of biopsy and then dividing by the total of number of villi
3. Villous height		Measuring the height (μm) of each villus in the FOVx40 for each FOVx40 along the length of the slide. The median was then calculated.
4. Villi width		Measuring the width of each villus (μm) at the same level per FOVx40 for each FOVx40 along the length of the slide. The median was then calculated.

Pathological feature	Image	Measured by:
5. Lamina propria (LP) width		<p>Measuring the width of each LP(μm) in each villus in the FOVx40 for each FOVx40 along the length of the slide. The median was then calculated.</p>
6. Crypt height		<p>Measuring the height (μm) of each crypt in the FOVx40 for each FOVx40 along the length of the slide. The median was then calculated.</p>
7. Inter-crypt distance		<p>Measuring the inter-crypt distance (μm) in the FOVx40 for each FOVx40 along the length of the slide. The median was then calculated.</p>
8. Thickness of muscularis		<p>Measuring the thickness of the muscularis (μm) (inner and outer layers and total thickness) in each FOVx40 and for each FOVx40 along the length of the slide. The median was then calculated.</p>
9. Thickness of submucosa		<p>Measuring the thickness of the submucosa (μm) in each FOVx40 and for each FOVx40 along the length of the slide. The median was then calculated.</p>
10. Number of eosinophils		<p>Number of eosinophils per 50 enterocytes at x40 both epithelial and within the lamina propria</p>

Pathological feature	Image	Measured by:
11. Number of lymphocytes		Number of lymphocytes per 50 enterocytes at x40 both epithelial and within the lamina propria
12. Number of myenteric neurons 13. Number of submucosal neurons 14. Total number of neurons		Counting the number of submucosal/myenteric neurons at x40 along the length of slide and then dividing by the number of FOVs at x40 per slide.

*FOV = field of view, usually at x40 magnification

2.7.4 Immunohistochemistry

Immunohistochemistry was employed to some samples in phase 1 and phase 2 of the study to try to elucidate any possible reasons for changes seen, and to help point to pathways that may be involved in such differences between the CP model and shams. All immunohistochemistry (IHC) was kindly performed by Mrs Lynn Stevenson (Veterinary Pathology, Public Health & Disease Investigation, University of Glasgow). A generic IHC protocol was followed using a DAKO Autostainer. Four antibodies were investigated in total namely Anti- Human CD117, Anti -iNOS, Anti -ChAT, and Anti-Jagged 1. A negative control antibody was used for each to check specificity.

2.7.4.1 *Anti-Human CD117*

The interstitial cells of Cajal (ICC) are now known to be the pacemaker cells of the foregut, hence they are top of our list in terms of investigating whether these cells show any difference in expression in our CP model with possible altered foregut motility. The formalin-fixed foregut samples were processed and embedded in paraffin wax. 2.5µm sections were cut using a Thermo Shandon Finesse microtome and put on charged slides and incubated at 57degrees Celsius for 1 hour. Sections were then dewaxed and rehydrated through graded alcohols to water then rinsed with buffer (Trisaminomethane buffer pH7.5 and Tween) for five minutes. Heat-Induced Epitope Retrieval (HIER) was undertaken in

Sodium Citrate buffer pH6 using a Menarini Access Retrieval Unit. All subsequent steps were at room temperature. After a buffer rinse the sections were then loaded on to the Dako Autostainer. Endogenous peroxidase was blocked using Dako Real™ Peroxidase blocking (Dako Ref S2023) solution for five minutes followed by a 5 minute rinse with buffer. The sections were then incubated with the primary antibody (DAKO Ref A4502) Polyclonal Rabbit Anti-Human CD117(c-kit) for 30 minutes at room temperature. This primary antibody was diluted in Dako universal diluent (1:800 for the 1st batch and 1:400 for the repeats). The sections were then rinsed again twice with buffer for five minutes to wash off the primary antibody. Sections were then incubated with the secondary antibody Dako Envisin+ System horse radish peroxidase (HRP) labelled Polymer Anti-Rabbit ready to use (RTU)(Dako Ref K4003) for thirty minutes. The sections were then rinsed twice with buffer for five minutes and then twice for five minutes with Dako K5007 diaminobenzidine (DAB) followed by three 5 minute water rinses. They were counterstained with Gills Haematoxylin for 27 seconds then washed in water. Finally, the sections are dehydrated, cleared and mounted with coverslips using synthetic resin. The stained sections were then analysed using the EVOS cell imaging system and digitalised prior to analysis with ImageJ software to count the number of ICC in the biopsies of shams compared to IBA lesioned animals in phase 1 and to compare shams and CP model in phase2 post splachnectomy.

2.7.4.2 *Anti-iNOS*

In chapter one, we discussed the pivotal role that nitric oxide (NO) plays in the normal motility of the foregut. Nitric oxide synthases are a group of enzymes that come in different forms and act as catalysts for the production of NO. iNOS or inducible NOS is found throughout the body and is thought to have a role in immunity and the level of iNOS is directly linked to the production of NO hence the reason for examining this antibody in our samples of the foregut. A similar generic IHC protocol to that described above was followed i.e. formalin-fixed foregut samples were processed and embedded in paraffin wax. 2.5µm sections were cut using a Thermo Shandon Finesse microtome and put on charged slides and incubated at 57 degrees Celsius for 1 hour. Sections were then dewaxed and rehydrated through graded alcohols to water then rinsed with buffer (Trisaminomethane buffer pH7.5 and Tween) for five minutes. Heat-Induced Epitope Retrieval (HIER) was undertaken in Sodium Citrate buffer pH6 using a Menarini Access Retrieval Unit. All subsequent steps were at room temperature. After a buffer rinse the sections were then loaded on to the Dako Autostainer. Endogenous peroxidase was blocked using Dako Real

TM Peroxidase blocking (Dako Ref S2023) solution for five minutes followed by a 5 minute rinse with buffer. The sections were then incubated with the primary antibody (Abcam ab15323) Polyclonal Rabbit Anti-iNOS for 30 minutes at room temperature. This primary antibody was diluted in Dako universal diluent 1:50. The sections were then rinsed again twice with buffer for five minutes to wash out any excess primary antibodies. Sections were then incubated with the secondary antibody Dako Envisin+ System horse radish peroxidase (HRP) labelled Polymer Anti-Rabbit ready to use (RTU)(Dako Ref K4003) for thirty minutes. The sections were then rinsed twice with buffer for five minutes and then twice for five minutes with Dako K5007 diaminobenzidine (DAB) followed by three 5 minute water rinses. They were counterstained with Gills Haematoxylin for 27 seconds then washed in water. Finally, the sections are dehydrated, cleared and mounted with coverslips using synthetic resin. The stained sections were then analysed using the EVOS cell imaging system and digitalised prior to analysis with ImageJ software to assess the level of iNOS in biopsies of shams compared to IBA lesioned animals in phase 1 and to compare shams and the CP model in phase2 post splanchnectomy.

2.7.4.3 *Anti-ChAT*

As described in chapter 1 anti- ChAT acetylcholinesterase (ChAT) has been shown to be important in the control of foregut motility as we know that cholinergic neurons not only interact with the vagus nerve, but also may have a role in immunity by interacting with nearby intestinal macrophages. (Cailotto et al., 2014) The anti-ChAT antibody is designed to stain cell bodies and nerve terminals in both the central and peripheral central nervous system. In order to compare the levels of ChAT in foregut samples from our CP model compared to controls we used the same generic IHC protocol described above but the sections were incubated with the primary antibody (Abcam ab6168) Polyclonal Rabbit Anti-ChAT for 30 minutes at room temperature. The same secondary antibody was used as above and the IHC protocol completed and the stained sections were then analysed using the EVOS cell imaging system and digitalised prior to analysis with ImageJ software to assess the level of ChAT in biopsies of shams compared to IBA lesioned animals in phase 1 and to compare shams and the CP model in phase2 post splanchnectomy.

2.7.4.4 *Anti- Jagged 1*

A fourth antibody was added following analysis of H&E slides because this analysis showed changes in villous architecture in duodenal biopsies in our CP model. Jagged 1 is a

cell surface protein or ligand involved in the notch signalling pathway which is a pathway crucial in making decisions on the fate of cells in many different organs throughout the body. Jagged 1 was examined because the Jagged-1/Notch-1/Hes-1 pathway has been shown to be involved in intestinal adaptation post small bowel resection (G. Chen et al., 2013) and in the development and maintenance of normal villous architecture. (Sander, Brookes, & Powell, 2003; Sander & Powell, 2004) we only performed Jagged 1 analysis in our duodenal samples as we were specifically looking to see if we could marry the changes seen in villous architecture to the level of expression of Jagged 1. To assess this we compared IHC for anti-Jagged 1 in duodenal biopsies from our CP model compared to shams. Again, as described above, the generic IHC protocol was used and the sections were then incubated with the primary antibody (Abcam ab7771) Polyclonal rabbit Anti – jagged 1 for 30 minutes at room temperature. The same secondary antibody was used as above and the IHC protocol completed and the stained sections were then analysed using the EVOS cell imaging system and digitalised prior to analysis with ImageJ software to assess the level of Jagged 1 in duodenal biopsies of our CP model and shams.

2.8 Retro-analysis of human foregut biopsies

Patients were identified from the paediatric gastroenterology databases that were known to have a diagnosis of cerebral palsy and dysmotility. The online hospital patient records were then analysed to see which of these patients had had biopsies of their foregut including their duodenum. An application was then made to the hospital biorepository to examine these historical biopsies retrospectively. The H&E slides of these biopsies were then analysed jointly with a consultant paediatric pathologist using the same histological scoring tool as described and illustrated in table 4 above. (Day et al., 2008)

2.9 Statistical analysis

All values are expressed as medians or means +/- Standard Error of the Mean (SEM) unless otherwise stated. Statistical significance was set at $P < 0.05$ for all tests. All statistical analyses were performed using the biostatistics software package Graph Pad Prism 3.0 (La Jolla, CA 92037, USA). Statistical analysis in phase 1 comparing IBA injection groups to shams was undertaken by means of a Mann-Whitney test and a z-test was used to compare proportions or standard student's t test. In phase 2 paired t tests were used when comparing pairs of data e.g. measurements of gastric emptying of the same animal before and after

Materials and Methods

splanchnectomy and two sample t tests when comparing two different groups of animals e.g. shams Vs CP model. Appropriateness of statistical analysis was checked kindly by Dr Alex McConnachie, Department of Biostatistics, University of Glasgow.

Chapter 3

Results – Phase 1

Establishing a CP model with foregut dysmotility

The specific aims of Phase 1 of the study were two-fold: the first to show that by targeting certain areas in the cerebral cortex of neonatal rat pups i.e. the medial prefrontal cortex (MPFC) and or the insular cortex (IC) we can produce lesions in the brain similar to periventricular leukomalacia (PVL) and show that this leads to evidence of delayed gastric emptying. We need to develop a CP model that is reproducible and by developing such a model this will help provide the scientific basis for the improvements we have seen in clinical patients. The second aim in phase 1 was to undertake a thorough histological examination of the foregut of different brain lesioned animals compared to shams. This analysis will include immunohistochemistry and we hope to identify any possible changes in the foregut of our CP model compared to controls.

3.1 Animals

45 (postnatal day 5-7) pups were injected in total (28 male and 17 female). The median weight at time of operation was 13.5 grams (range 7.5-21 grams). Four pups died at the start of the study: two intra-operatively from haemorrhage (one L MPFC and one R MPFC) and two in the immediate post-operative period from anaesthetic complications or apnoea (both R MPFC). This is a recognised complication when anaesthetising and operating on such small neonatal animals.

3.2 Difference in weight velocity

Animals were weighed regularly throughout phase 1 of the study. Weight velocity means the rate at which the animal gained weight. Figure 23 shows a graph of the weight velocity of the different groups i.e. the shams compared to the various IBA injections, unilateral or bilateral IC or MPFC. It would appear from the spread of this graph that there is a difference between the weight velocities of shams compared to certain types of IBA injections namely right-sided MPFC and IC and bilateral IC. Standard t tests were used to

quantify the difference in mean weight gain between the shams and the various IBA brain lesions. These results are shown in Figure 23 and tabulated in Table 6 on the next page. This showed that weight gain or weight velocity was significantly reduced in four groups, the R MPFC and all insular cortex lesioned animals. It was also approaching significance in the bilateral MPFC group. It is still difficult, however, to be sure of the significance of this as the initial birthweight of the animal has a bearing on their ultimate weight gain and this is undoubtedly affected not only by the sex of the animal but also the initial litter size that the particular group of pups came from i.e. the larger the litter size the smaller the pups.

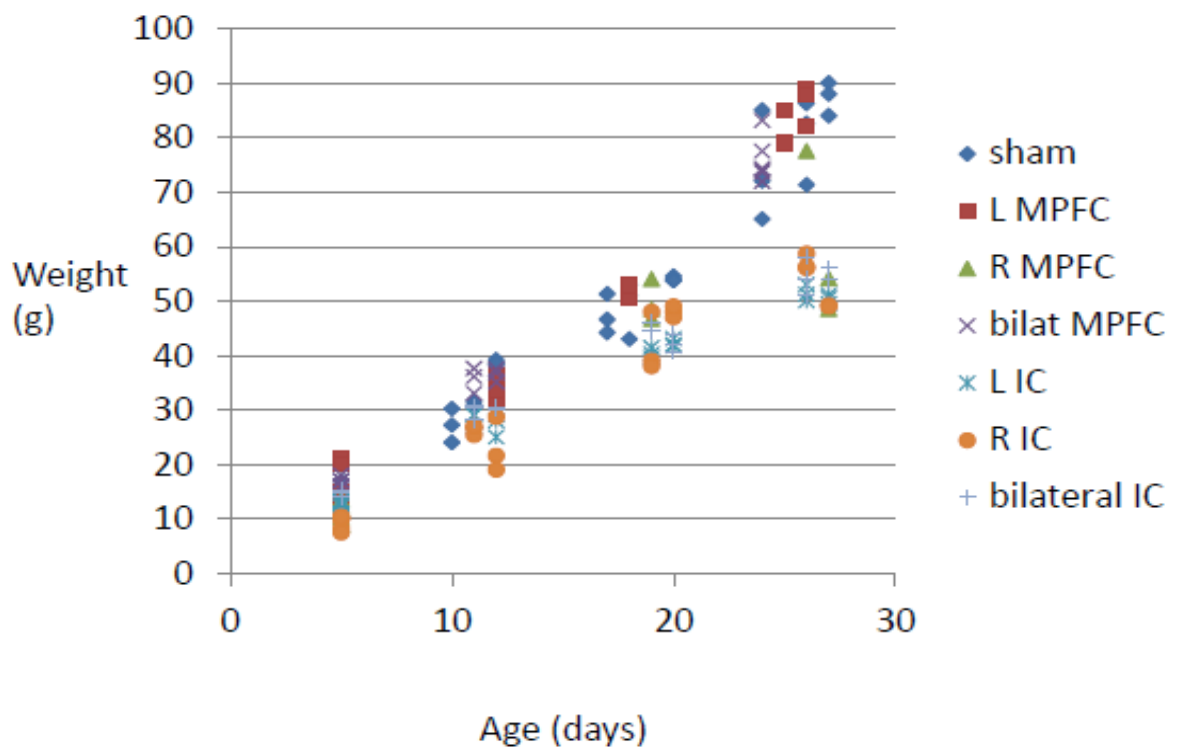


Figure 23. Weight velocity of neonatal rat pups throughout Phase 1

A scatter XY graph showing the weight gain of neonatal rat pups according to which group they belonged to i.e. which brain lesion they underwent: sham, unilateral or bilateral MPFC (medial prefrontal cortex), unilateral or bilateral IC (insular cortex). It can be seen that the weight gain or weight velocity was poorest in the RMPFC and insular cortex groups. The mean values are shown in table 6.

Table 6 shows a comparison of mean weight gain between the different brain lesions and shams up until day 28 of life i.e. the end of Phase 1 of the study. MPFC = medial

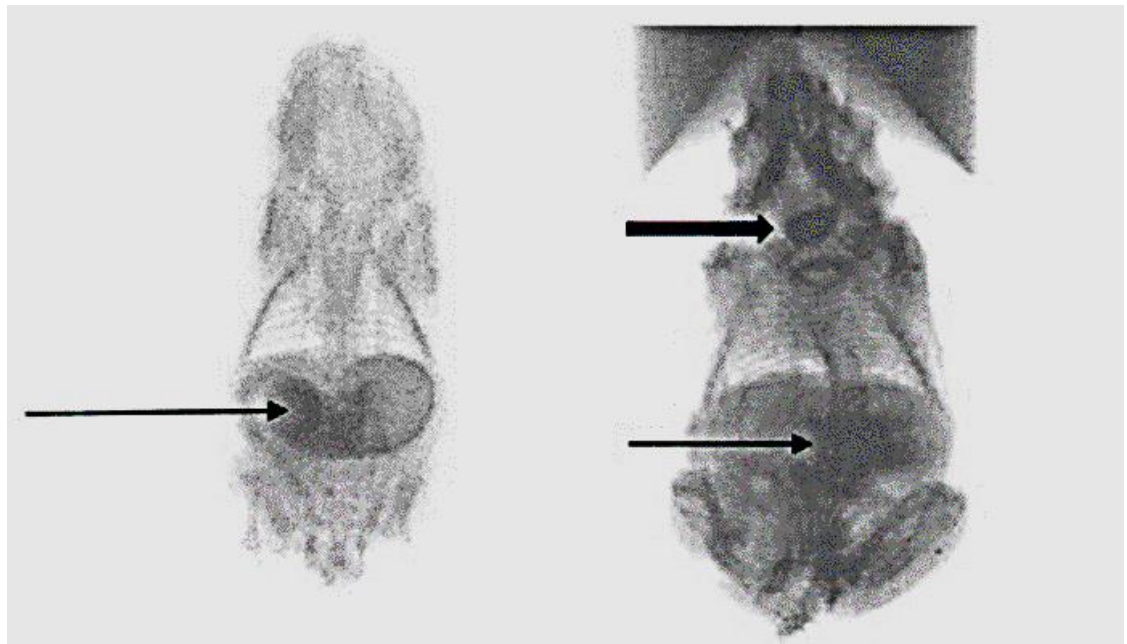
prefrontal cortex and IC = insular cortex. Brain lesioned animals were compared to shams by means of a standard unpaired student's t test.

Table 6. Mean weight gain of neonatal rat pups throughout Phase 1

Lesion	Sham (n=9)	L MPFC (n=5)	R MPFC (n=3)	BILATERAL			BILATERAL IC (n=6)
				MPFC (n=6)	L IC (n=6)	R IC (n=6)	
Mean weight gain (g)	67	66.5	32.9	59.1	38.3	44.2	39.7
P-value		0.92	0.0001	0.07	0.0001	0.0002	0.0001

3.3 Gastric Emptying Studies

The various sites of neurotoxin injections and shams are shown in Table 7 with their corresponding median gastric emptying time (GET) in those that survived the craniotomy procedure and brain injection. Figure 25 shows the same data in a different format, by means of a Forest plot. GET was significantly prolonged in each IBA group compared to shams, but most interestingly 5 out of 6 of those with bilateral MPFC lesions demonstrated reflux during their contrast studies (Figure24). This was not seen in any of the other groups. There was also a difference seen between laterality of the brain lesion created and degree of prolonged GET.



(A)

(B)

Figure 24. Images from gastric emptying studies of two pups.

Both pups had undergone IBA MPFC injections (A) has undergone a unilateral injection and show the arrow points to contrast in the stomach and (B) has undergone bilateral MPFC injections and the thin arrow shows some contrast in the stomach and small bowel and the thick arrow shows contrast also refluxing back into the oropharynx.

Table 7. Gastric emptying times comparing different brain lesions to those who underwent sham injections. Times were compared statistically by means of a Mann-Whitney U test using GraphPad Prism.

Lesion	Sham (n=9)	L MPFC (n=5)	R MPFC (n=3)	Bilateral MPFC (n=6)	L insular (n=6)	R insular (n=6)	Bilateral insular (n=6)
Mean GET (mins)	46.8	72.6	85.2	57.8	71.9	60.8	67.1
P-value		0.0092	0.009	0.0496	0.0018	0.0028	0.0008

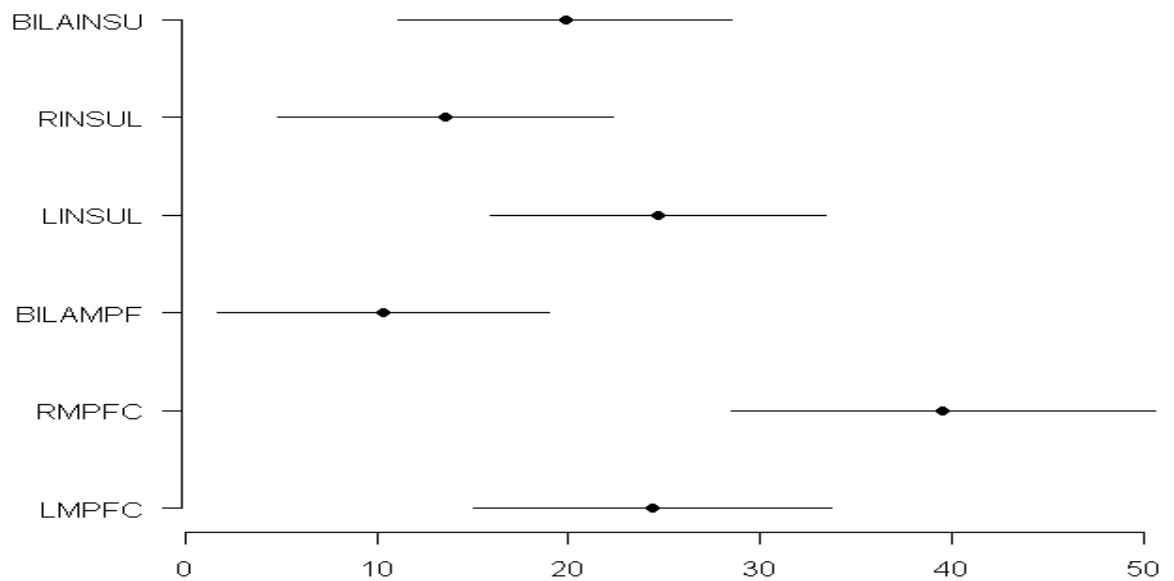


Figure 25. Forest plot comparing different sites of brain lesions and GET.

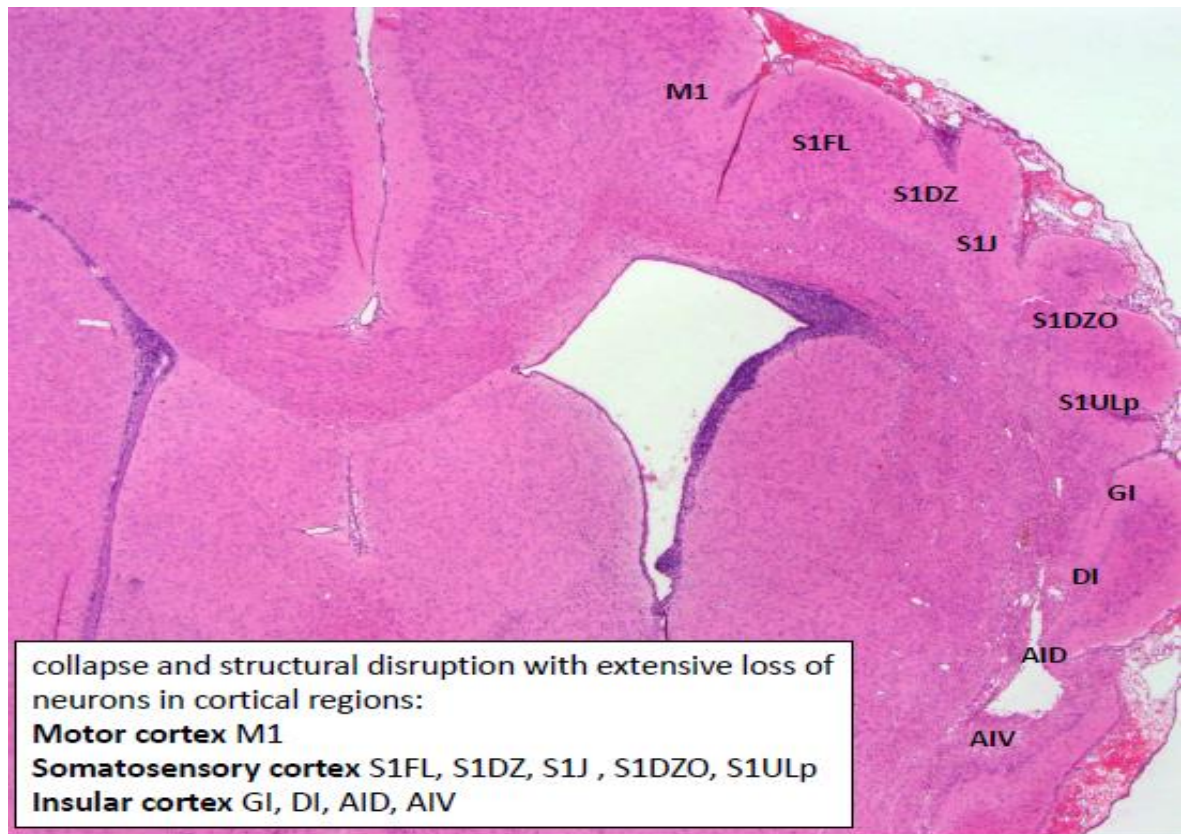The same data as displayed in table 6. RINSUL = right insular cortex, LINSUL = left insular cortex, BILAMPF = bilateral medial prefrontal cortex, RMPFC = right medial prefrontal cortex and LMPFC = left medial prefrontal cortex. The lines show the range of the GETs measure and the dot indicates the median GET in minutes.

3.4 Histological Analysis

3.4.1 Brain lesion analysis

In terms of cerebral histopathology what became immediately clear was that the MPFC lesions were easier to identify histologically compared to lesions of the insular cortex given its more lateral site in the rat brain. Out of 18 rats that underwent insular cortex lesions (12 unilateral and 6 bilateral) only in two of the brain specimens could any changes in the insular cortex be identified with confidence. In these two specimens, there was evidence of an increase in numbers of glial cells in the subcortical white matter in addition to areas of loss of substance or “cavitation” at the junction between cortical layers and subcortical white matter in the AID and AIV areas of the insular cortex (see Fig. 26 and 27). As described in earlier chapters the MPFC consists of three regions the cingulate cortex, the prelimbic cortex and the infralimbic cortex. Figure 28 demonstrates the difference between the appearance of these regions of the brain in those who had undergone sham injection and those who had a unilateral MPFC lesion with IBA. Even on H&E staining there is evidence in the IBA injected brain of both loss of cortical neurons and ventricular dilatation. This is demonstrated by the further examples shown in Figures 29 and 30. Figure 32 demonstrates an increased number of glial cells on H&E staining and by means of staining with cresyl violet. These changes were identified in 10 out of 14 animals that underwent MPFC IBA injections. In two out of the fourteen rats that underwent MPFC IBA injections the lesions were too lateral as shown in Figure 32 with lesions and changes seen in the lateral prelimbic cortex and extending into the fmi (forceps minor of the corpus callosum) rather than limited to the MPFC. This is probably a reflection of the size of the neonatal animal and using stereotactic coordinates designed for larger subjects. This was because, as discussed in chapter 2, there are no published neonatal rat brain coordinates. These two rat pups were noted retrospectively to be from a larger litter and, therefore, at the smaller end of the spectrum in terms of birthweight and hence weight at operation.

In summary, in terms of our brain lesions analysis the MPFC was much easier to consistently target than the insular cortex. 10 out of 14 (71%) rat brains showed histological evidence of lesions and 2 showed lesions that were too lateral. We have demonstrated histological changes consistent with PVL i.e. loss of cortical neurons, ventricular dilatation and increased number of glial cells.



HE 1.25x

Figure 26. Microphotograph of IC IBA lesion. This photograph shows typical appearances of the rat pup brain following IBA injection into the insular cortex.

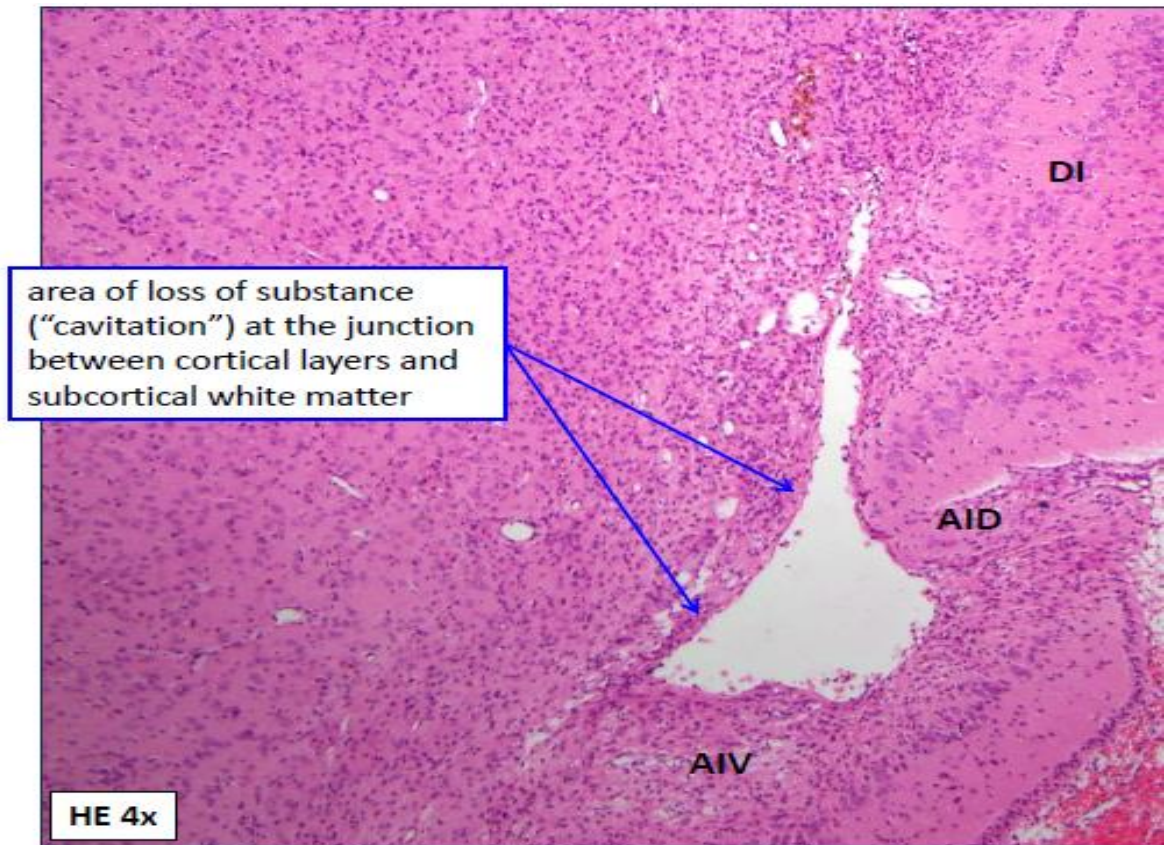


Figure 27. Microphotograph showing cavitation in IC. This photograph shows the same area of "cavitation" in the insular cortex at a higher magnification.

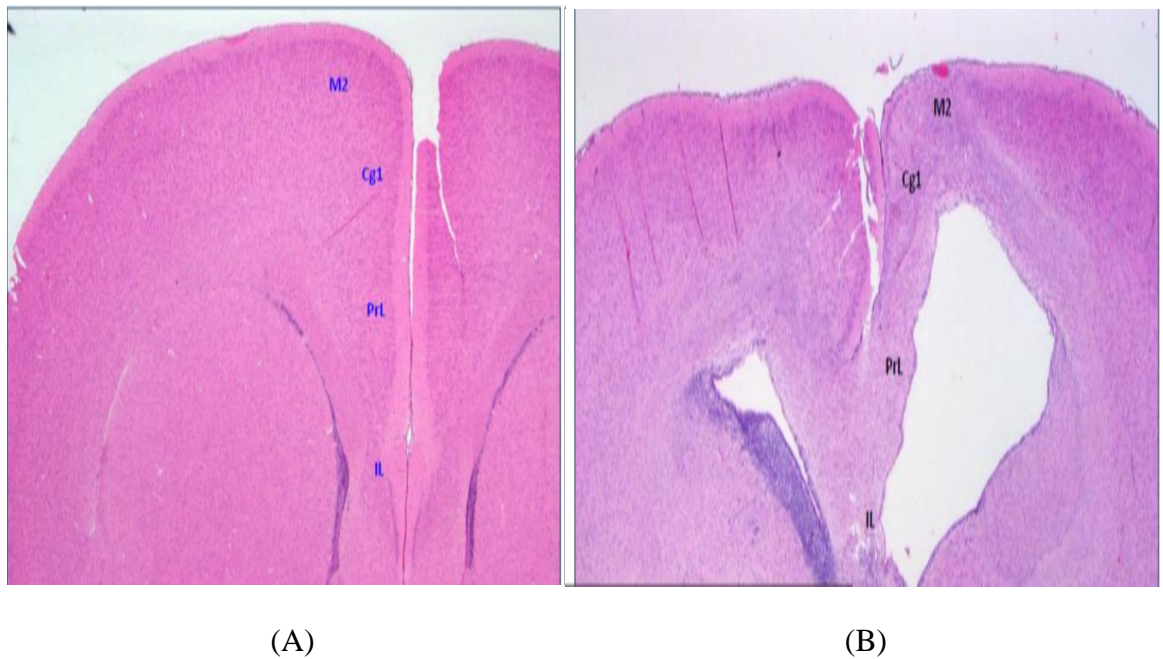


Figure 28. Coronal section showing the MPFC in (A) a pup that had undergone a sham injection and (B) a pup that undergone a Left MPFC IBA injection. Both the images are projected in an anteroposterior fashion so that the right-hand side of the picture corresponds to the left side of the animal's brain. M2 =Motor cortex, Cg1 = Cingulate cortex, PrL = Prelimbic cortex and IL = Infralimbic cortex

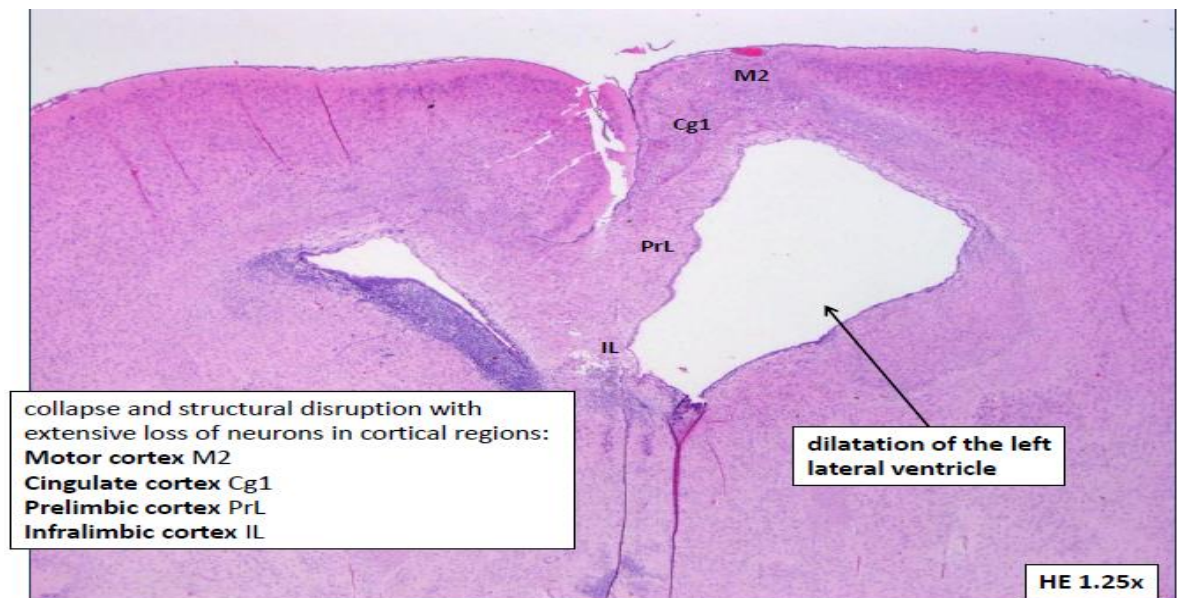


Figure 29. Another example of a left sided MPFC lesion again with the left side of the brain projected to the right of the page. There is obvious dilatation of the left ventricle compared to contralateral side

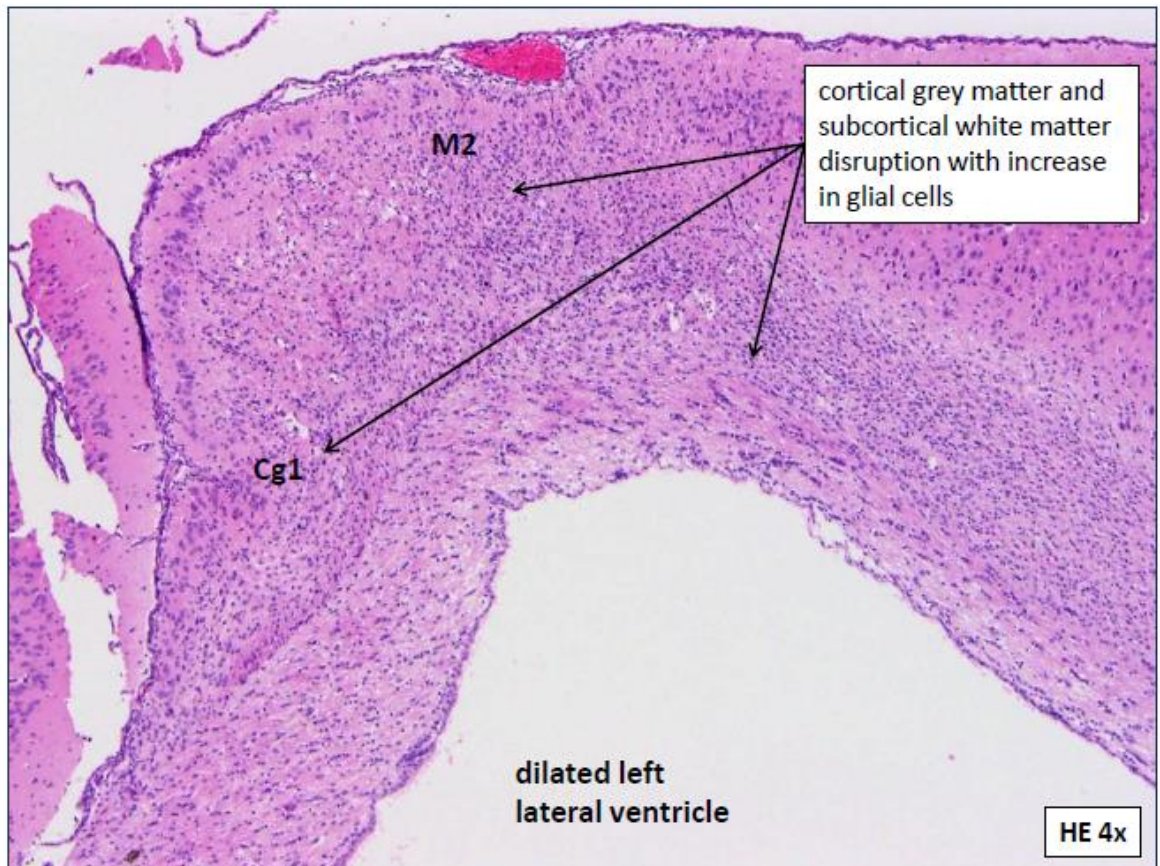


Figure 30. Microphotograph of left MPFC lesion. This is the same section as in Figure 28 but this time at a higher power showing an increase in glial cells on the side of the brain injected.

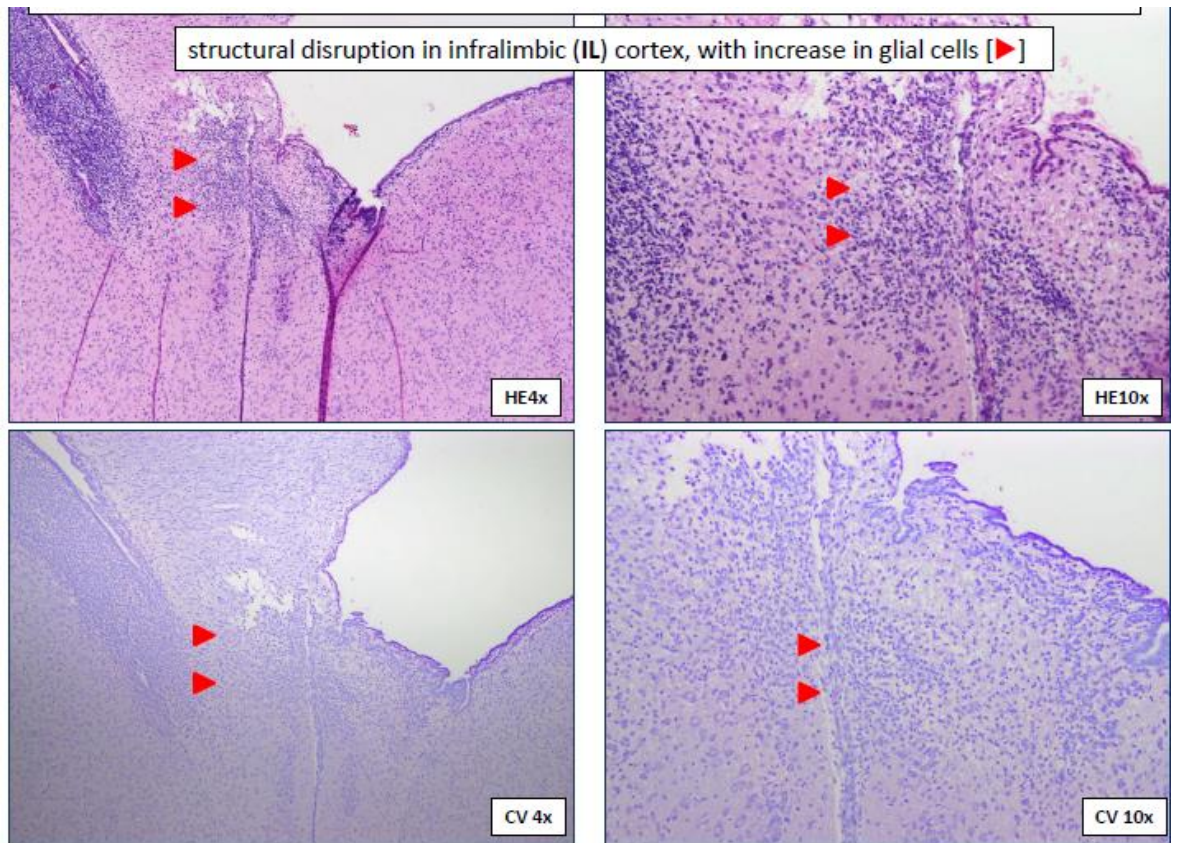


Figure 31. Increased glial cells in the MPFC following IBA injections.

The four slides above show H&E slides at x4 and x10 magnifications of the IL region of the MPFC and then below the same sections this time stained with cresyl violet (CV) to better define the increased number of glial cells.

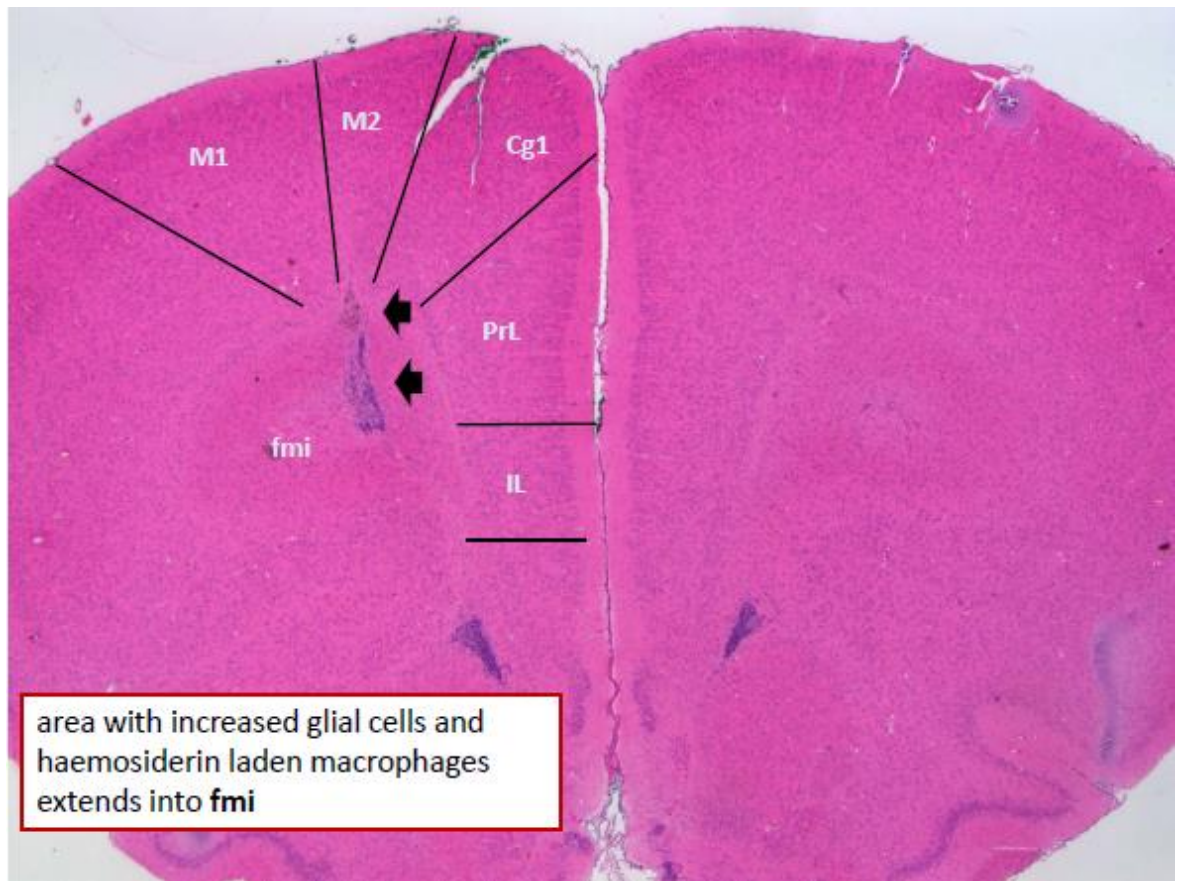


Figure 32. Attempted Right sided MPFC lesion.

The microphotograph above shows the brain of rat pup in which a R sided (to the left of the page) MPFC was attempted but the injection was too lateral and subtle changes were instead found in the lateral aspect of the prelimbic cortex (PrL) and into the forceps minor of the corpus callosum (fmi).

3.4.2 Foregut analysis

Foregut sample analysis was performed in all pups that had undergone either shams or MPFC lesions, unilateral or bilateral. Samples of the foregut of IC lesioned animals were taken but not examined. This was due to the finding above that following the GE studies and brain analysis it was clear that although animals with unilateral or bilateral IC lesions did demonstrate poor weight gain and poor gastric emptying the brain lesions were not easily identifiable; nor reproducible. The MPFC injections, however, were more reliable and this group demonstrated poor weight gain which despite small numbers was approaching statistical significance. The bilateral MPFC group were also the only group on GE studies to show evidence of possible gastro-oesophageal reflux. These results, therefore, ruled out IC

lesions as our potential CP model and we began to focus on the unilateral and bilateral MPFC lesions compared to shams. As previously described in chapter 2 the analysis of the foregut samples involved 3 stages. The first was a “spot the difference” analysis by the author of all four foregut samples i.e. the distal oesophagus, the midpoint of the greater curvature of the stomach, the antrum and the second part of the duodenum, comparing the shams to the IBA MPFC lesioned animals. This initial spot the difference showed no obvious difference between the shams and IBA lesioned animals in terms of the proximal three samples i.e. oesophagus, greater curvature or antrum. This is illustrated in table 8.

In the spot the difference analysis looking at the different gastric specimens it was difficult to appreciate any consistent differences between gastric biopsies from different groups. This was also made more difficult because in the rat the stomach may be divided into two main regions: the forestomach, a non-glandular region lined by stratified squamous epithelium, and the glandular stomach. In retrospect, the junction between the two i.e. the midpoint of the greater curvature of the stomach was not the ideal sample site, but comparison of the oesophageal and antral specimens also showed no appreciable difference between the groups. This is again illustrated by examples of such specimens in table 7. It was a different story, however, with the duodenal specimens as these looked quite different between the three groups. In stage 2 of the histological analysis i.e. the blinded analysis, the two pathologists labelled 6 samples as showing significant change and these correlated with 5 out of 6 samples that had come from the bilateral MPFC group i.e. our CP model. This was encouraging and so we decided to score the duodenal specimens from the unilateral and bilateral MPFC lesioned animals and shams using the scoring tool described in chapter 2. The villi height and width were measured as a more quantitative assessment of villous blunting and atrophy, a feature seen often particularly in any cases where there has been damage to the villous enterocytes. The number of villi was counted as a way of calculating the percentage of bifid or fused villi, a potential marker of inflammation or disordered architecture. Lamina propria width and intercrypt distance were measured as a means of quantifying any difference in the presence of oedema. Crypt height was measured in an attempt to identify any proliferative response occurring in these animals. We hypothesised that the thickness of the muscularis may be different owing to the fact that we’ve shown these same animals have delayed GET and so we measured this and similarly we counted the number of neurons in the myenteric and submucosal plexus. We also counted the number of eosinophils and the number of lymphocytes in the epithelium and in the lamina propria per 50 enterocytes. Table 9 shows the results of the analysis in descending order of significance starting with the most significant finding first. From these results, it can be seen that villous width and height and

thickness of the submucosa were all significantly increased in our CP model i.e. bilateral MPFC injection. Other result comparisons that were approaching significance included decreased number of submucosal neurons and increased number of bifid villi. In addition, the thickness of the longitudinal muscle was raised as was the number of eosinophils but this was not significant. There was no change was seen in the total number of neurons and lastly there was no difference in total thickness of the muscularis contrary to what we had anticipated.

In summary, our foregut analysis has revealed that although there no obvious differences between our proposed CP model and shams in terms of oesophagus or stomach specimens there was a difference between the duodenal specimens. On further more in detail analysis this involved a significant difference in villous architecture as well as a decreased number of submucosal neurons and an increased number of bifid villi.

Table 8. Table of microphotographs of HE Slides comparing foregut biopsies between unilateral and bilateral IBA MPFC lesioned animals and shams.

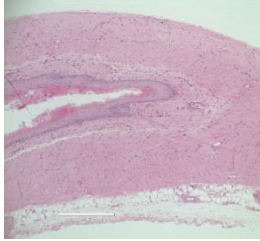
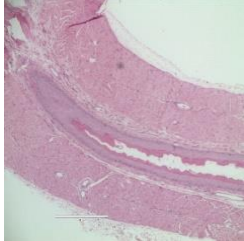
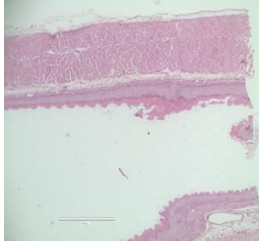
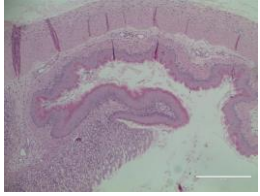
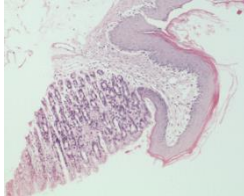
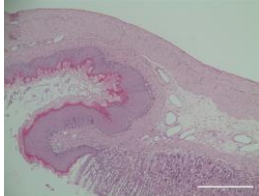
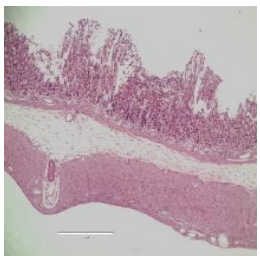
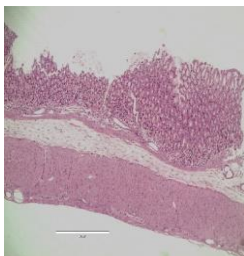
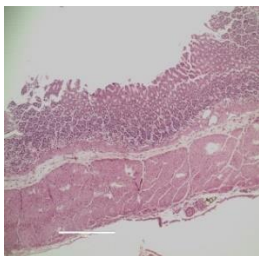
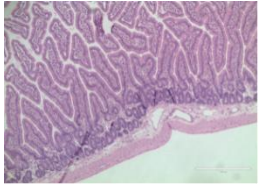
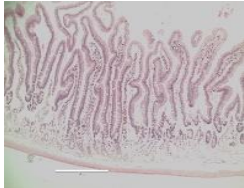
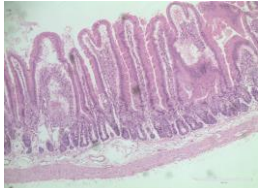
	Sham	Unilateral MPFC	Bilateral MPFC
Oesophageal specimen			
Greater Curvature specimen			
Antral specimen			
Duodenal specimen			

Table 9. Comparative histological scoring of duodenal specimens only between the three groups: shams, unilateral MPFC injection and bilateral MPFC injection i.e. CP model

Median	Sham	Unilateral MPFC Brain injection	Bilateral MPFC Brain Injection (CP model)
Villous width (µm)	109.9 (86.1-135.8)	125.5 (97.3- 158.5) p=0.24	133.1. (109.7-204.5) p=0.03
Villous height (µm)	388.9 (314.7-496.8)	551.2 (342.8-601.6) p=0.06	500.4 (429.5-576.3) p=0.04
Thickness of submucosa (µm)	49.1 (24.9-56.2)	66.1 (60.4-87.5) p=0.002	72.8 (49.7-104.1) p=0.02
No. of submucosal neurons per x40 FOV	3.1 (2.1-5.2)	3.2 (1.6-5) p=0.69	2.1 (0.9-3.5) p=0.06
No. of lymphocytes in Lamina Propria per 50 enterocytes	8.5 (5-24)	9.0 (1-12) p>0.99	6.0 (5.0-7.0) p=0.08
Intercrypt distance (µm)	52.2 (40.4-69.9)	134.4 (43.2-214.1) p==0.06	59.9 (50.3-77.8) p=0.09
Total number of lymphocytes per 50 enterocytes	19 (10-32)	14.5 (3-26) p= 0.52	8.5 (5-21) p= 0.10
% Bifid Villi	6.9	5.0 p=0.39	10.2 p=0.1
Outer longitudinal (µm)	30.0 (21.1-53.9)	23.0 (12.9-33.4) p=0.13	43.3 (22.3-48.9) p=0.13
No. of myenteric neurons per x40 FOV	2.4 (1.25-3.8)	1.3 (0.8-1.3) p=0.06	1.5 (0.6-2.6) p=0.14
Width of lamina propria (µm)	37.8 (33.5-46.5)	45.4 (28.2-108.2) p=0.24	46.2 (36.1-94.1) p=0.18

Median	Sham	Unilateral MPFC Brain injection	Bilateral MPFC Brain Injection (CP model)
Total number of eosinophils*	7.5 (4-12)	6.5 (4-10) p=0.47	11.0 (5-16) p=0.22
No. of epithelial lymphocytes*	8.0 (5-18)	6.5 (2-14) p=0.37	4.5 (1-14) p=0.22
Total no. of neurons per x40 (FOV)	5.25 (4.0-9.0)	4.25 (2.4-6.4) p=0.26	4.15 (2.9-8.74) p=0.24
No. of Epithelial eosinophils*	0.5 (0-6)	1.0 (0-6) p>0.99	2.5 (1-9) p=0.29
No. of eosinophils in Lamina propria*	7.5 (0-14)	4.5 (3-8) p=0.57	9.0 (1-10) p=0.29
Crypt height (µm)	189.2 (129.1-284.4)	187.7 (140.1-245.3) p=0.93	213.9 (141.9-283.0) p=0.59
Inner circular (µm)	65.5 (55.8-90.6)	52.2 (26.3-79.8) p=0.13	62.1 (49.1-80.9) p=0.59
Total thickness of muscularis (µm)	101.3 (85.6-142.2)	74.2 (43.4-116.1)	108.4 (60.6-133.9)
* = per 50 enterocytes		p=0.13	p=0.87

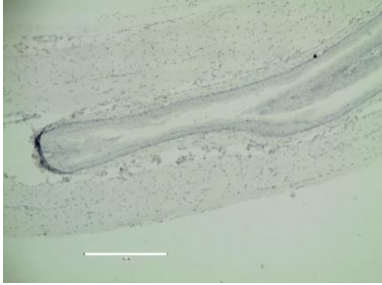
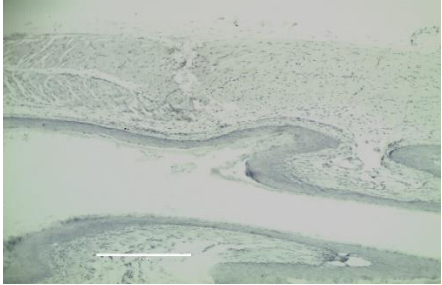
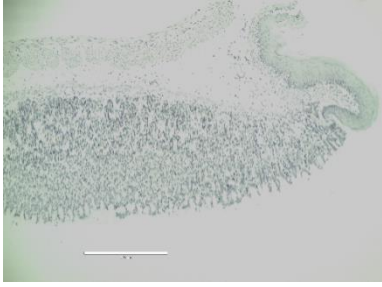

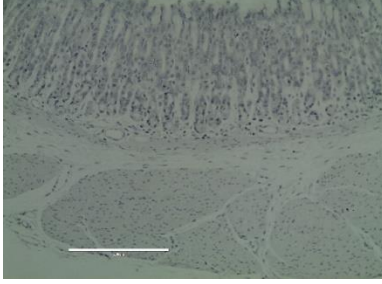
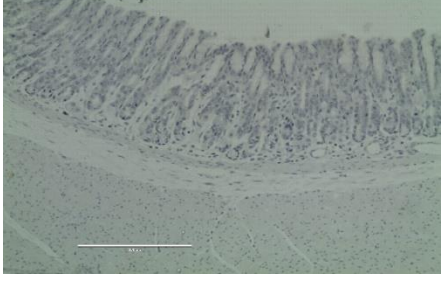
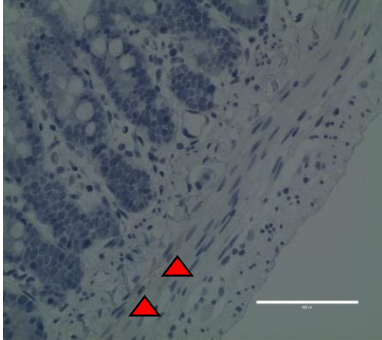
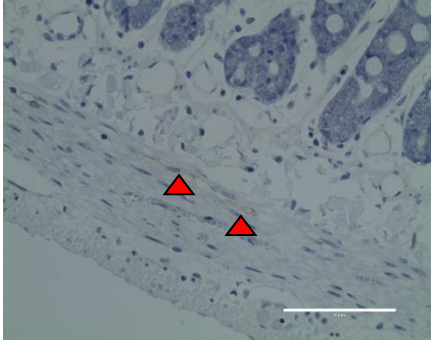
3.5 Immunohistochemistry

Following the results described above, in terms of our analysis of foregut biopsies, we elected to perform immunohistochemistry comparing specimens from our sham animals to those animals that had undergone bilateral MPFC IBA injections as it was becoming clear from our ongoing assessment that this was now the brain lesion site and technique that was becoming the focus of our proposed CP model. What also became clear during both the HE analysis and the initial IHC studies was that the most obvious differences in the foregut specimens was in the duodenum and so whilst IHC was performed on all specimens for anti-human CD117 subsequently IHC for the remaining three antibodies: anti-iNOS, anti-ChAT and anti-jagged 1 was only performed on the duodenal specimens.

3.5.1 Anti-Human CD117

The interstitial cells of Cajal (ICC) are now known to be the pacemaker cells of the foregut, hence they were top of our list in terms of investigating whether these cells show any difference in expression in our CP model which we have demonstrated to have altered foregut motility. When examining and reporting numbers of ICC it is important to use the correct nomenclature and to realise that the different subsets of ICC are expressed differently throughout the GI tract and that this can vary between species. An example of this is that it is widely recognised that expression of ICC varies throughout the different regions of the stomach e.g. the fundus is different to the pylorus, but the small bowel and colon are much more predictable. This is certainly something we confirmed when looking at our specimens as it was often particularly difficult to distinguish ICCs in the oesophagus and stomach whereas they were much easier to identify in the duodenal specimens. This is demonstrated in table 10. To clarify for the purposes of this thesis we are adopting a similar nomenclature as described by Hanani et al. (Hanani, Farrugia, & Komuro, 2005; Komuro, 2006). Therefore, ICC-SMP and ICC-SM refers to the ICC found between the submucosa and circular muscle layer in the colon and gastric pylorus, respectively and ICC-DMP equates to the deep muscular plexus located between the inner and outer circular muscle in the duodenum and ICC-CM and ICC-LM are found within the circular and longitudinal muscle layers, respectively. Lastly ICC-MPs are those found in the myenteric plexus between the circular and longitudinal muscle layers. As described in chapter 2, 1x 1cm biopsies were taken from the second part of the duodenum and the specimens were stained with anti-c-kit (CD117) to examine for the presence of interstitial cells of Cajal. As shown in table 9 the deep muscular plexus interstitial cells of Cajal (DMP-ICC) were more readily identifiable in the duodenal specimens and it is the author's interpretation that this equates to the human submucosal plexus rather than myenteric plexus. Therefore, as this was the only population of ICC that was consistently seen only this population was counted. The numbers of DMP-ICCs were counted along the length of the specimen and were recorded as the number of cells per x40 field of view seen and was compared to the numbers seen and counted in the pups that had undergone sham injections. Specimens were analysed from 12 rat pups: 6 that had undergone bilateral MPFC injections (our CP model) and 6 had undergone sham injections.

Table 10. Table of microphotographs showing anti – CD117 IHC. All four sites of foregut specimens are shown comparing the two groups. (▲ = deep muscular plexus interstitial cells of Cajal)

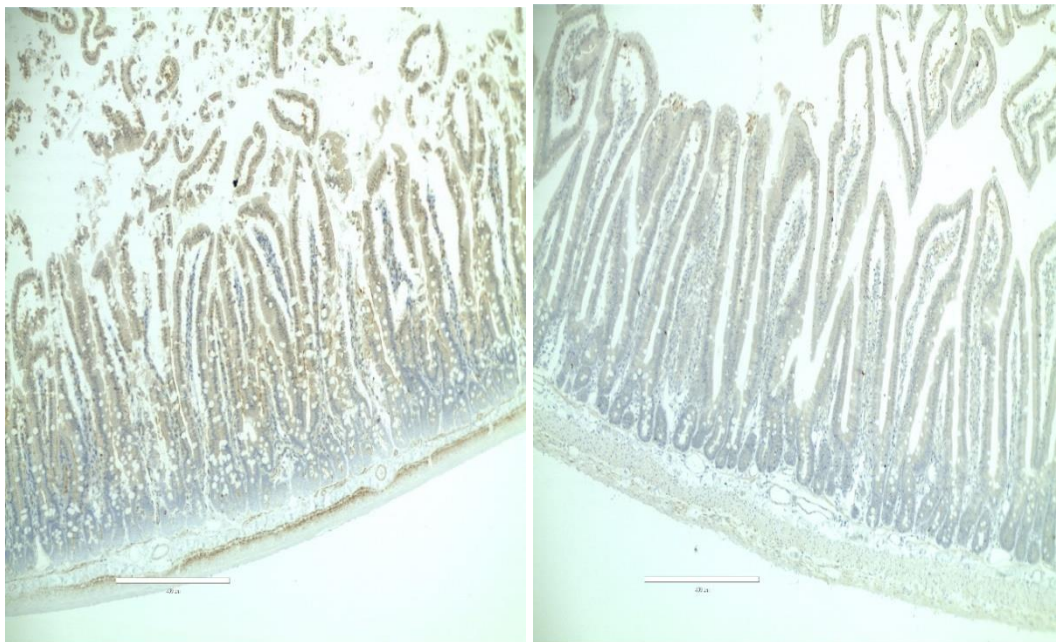
	Sham	CP model
Oesophagus		
Greater curvature		
Antrum		
Duodenum		

The median number of DMP-ICC per x40 FOV was 2.7 (1.4-4.3) in the sham animals compared to 2.0 (1.36-2.45) in the CP group ($p=0.04$). This, therefore, indicates a reduction in the number and organisation of the DMP-ICC. This is an important finding as we have shown that our CP model shows significantly reduced numbers of a subpopulation of interstitial cells of Cajal compared to shams.

3.5.2 Anti-iNOS antibody staining

Nitric oxide (NO) is essential for normal foregut motility, interacting with both the smooth muscle of the foregut and the ICC network described above. It is present in different forms including inducible nitric oxide and this is produced through a pathway involving the enzyme inducible nitric oxide synthase or iNOS. This antibody therefore targets this enzyme and therefore, highlights the presence of NO in the tissues, in this case the duodenum. Six specimens of duodenum from each of the two groups were analysed for the presence of iNOS. It was not possible to blind the author to which specimens were from which cohort and so the digitalised slides were analysed using ImageJ's IHC tool to quantify objectively the area fraction stained with the antibody. This is a standard method of calculating the percentage pixel stained with the antibody i.e. brown staining in a standard x10 field of view allowing statistical comparison between slides. The results are shown in Table 11.

On comparing these values by means of an unpaired t test there was a significant difference in the level of staining between the two groups. The mean percentage pixels stained was 5.360 ± 0.8480 N=6 in the sham group compared to 0.5867 ± 0.2052 N=6 in the CP model group ($p=0.0003$). Therefore, there was a significantly reduced expression of iNOS in the CP model group.



Sham

CP model

Figure 33. Comparison of duodenal specimens staining for the anti-iNOS antibody.

These examples show a typical reduced expression in the specimens from the bilateral IBA injections group i.e. our CP model compared to shams.

This a comparison between the two groups: those that had undergone sham brain injections with normal saline and those that undergone bilateral MPFC IBA injections i.e. our CP model. The “%pixels” is the percentage of pixels stained in a standard x10 FOV (field of view).

Table 11. Results of IHC analysis comparing levels of staining for anti-iNOS antibody.

Sham		CP model	
Area fraction stained (μm)	%pixels	Area fraction stained (μm)	% pixels
158536	5.04	5244	0.17
92464	2.94	1049	0.03
173051	5.5	41135	1.31
270209	8.59	32813	1.04
109106	3.47	16531	0.53
208232	6.62	14706	0.47

3.5.3 Anti– ChAT antibody staining

As described in chapter 1 NO is not the only substance at play and acetylcholinesterase (ChAT) has also been shown to be important in foregut motility in a number of ways. ChAT interacts with both the vagus nerve and enteric neurons as well as intestinal macrophages. (Cailotto et al., 2014) Immunohistochemistry was therefore performed using the antibody anti-ChAT on duodenal specimens from the bilateral MPFC IBA group compared to shams. Six duodenal specimens were compared from each group. As stated previously it was not possible to blind the author to which specimens were from which cohort and so the digitalised slides were analysed using ImageJ’s IHC tool to quantify objectively the area fraction stained with the antibody. Figure 34 shows an example of a comparison between a sham duodenal specimen and a specimen from our proposed CP model. In this example, there appeared to be a subjective increase in the staining for anti-ChAT in the submucosal plexus, however, on reviewing all 12 specimens it was evident that the staining for anti-ChAT antibody was not consistent throughout the length of the

specimen in some specimens compared to others. It is unclear why this was the case and different concentrations of the antibody were tried with no real change in outcome. The ImageJ DAB analysis was undertaken nonetheless in exactly the same manner as for anti-iNOS. The results are shown in Table 12. On comparing these values by means of an unpaired t test there was no significant difference in the level of staining between the two groups. The mean percentage pixels stained was $3.272\% \pm 0.8129\%$ in the sham group compared to $4.04\% \pm 0.9391\%$ in the CP model group ($p=0.55$). Therefore, there was no significant difference between the expression of ChAT in either group.

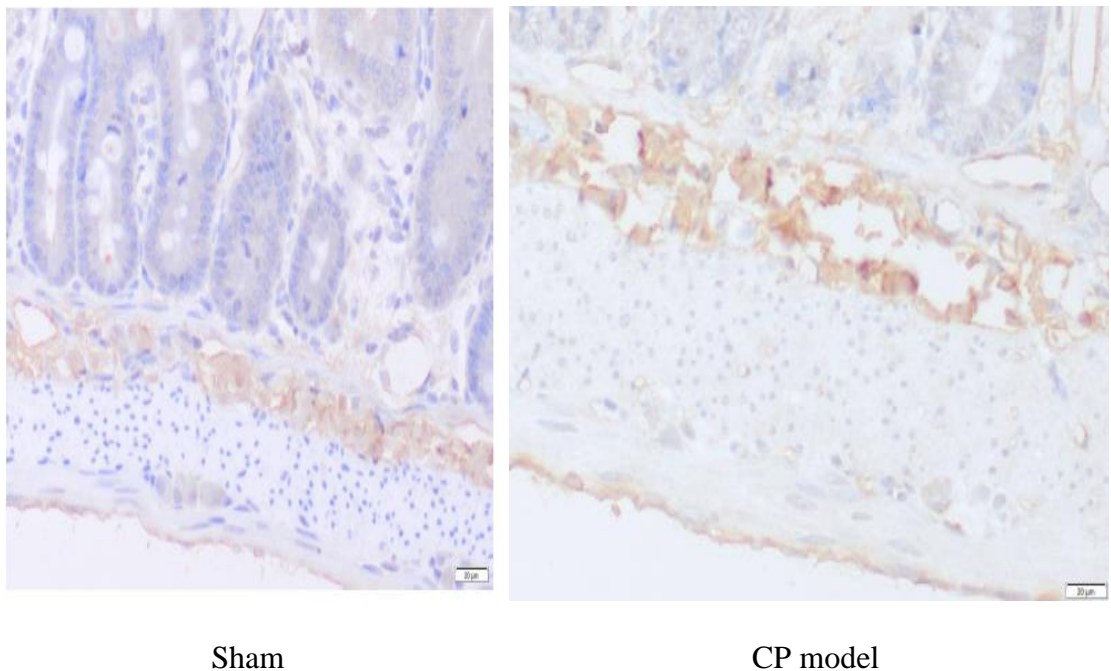


Figure 34. Comparison of duodenal specimens stained with anti-ChAT.

This shows an apparent increased staining in the submucosal plexus of the CP model compared to that of the Sham.

This is a comparison between the two groups: those that had undergone sham brain injections with normal saline and those that undergone bilateral MPFC IBA injections i.e. our CP model. The “%pixels” is the percentage of pixels stained in a standard x10 FOV (field of view).

Table 12. Results of IHC analysis comparing levels of staining for anti-ChAT antibody.

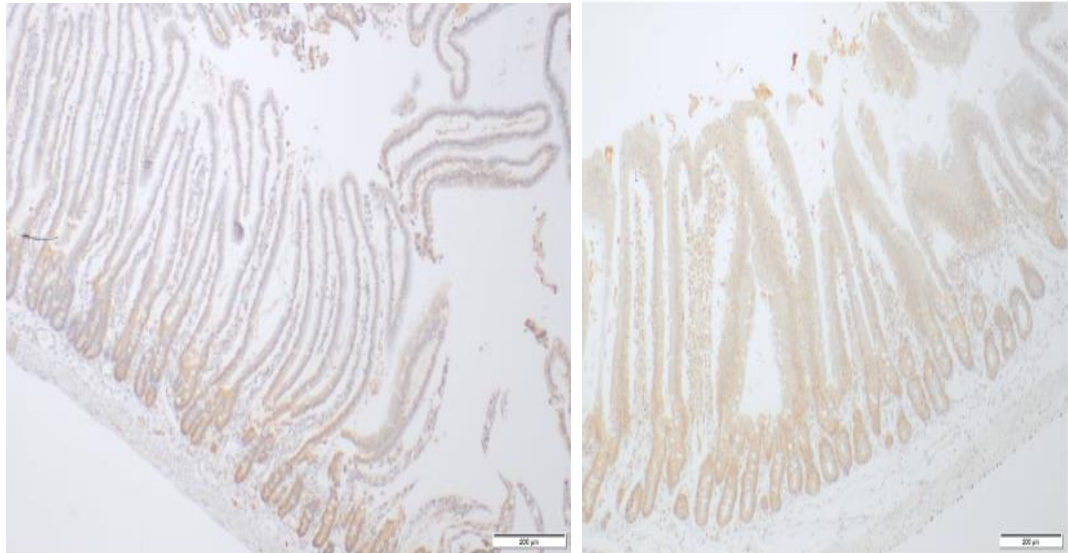
Sham		CP model	
Area fraction stained (μm)	%pixels	Area fraction stained (μm)	% pixels
106750	3.39	25008	0.8
220838	7.02	95899	3.05
97515	3.1	219191	6.97
81067	2.57	82957	2.63
75029	2.39	150549	4.79
36520	1.16	188850	6

3.5.4 Anti- Jagged 1 antibody staining

The final antibody examined was anti-jagged1. The reason for looking at this particular antibody was in response to the changes in villous architecture noted between the sham group and the CP model. Jagged 1 is a cell surface protein or ligand involved in the notch signalling pathway which is a pathway crucial in making decisions on the fate of cells in many different organs throughout the body. Jagged 1 was examined because the Jagged-1/Notch-1/Hes-1 pathway has been shown to be involved in intestinal adaptation post small bowel resection (G. Chen et al., 2013) and in the development and maintenance of normal villous architecture. (Sander et al., 2003; Sander & Powell, 2004) we only performed Jagged 1 analysis in our duodenal biopsies as we were specifically looking to see if we could relate the changes seen in villous architecture to the level of expression of Jagged 1. To assess this, we compared IHC for anti-Jagged 1 in duodenal biopsies from our CP model compared to shams.

Unlike the anti-ChAT IHC the anti-Jagged 1 results were similar to the anti-iNOS in that even before the ImageJ DAB analysis was undertaken it was clear that there was a difference in expression between the two groups and as expected the expression of Jagged1 was clearly increased in the CP model group compared to the sham group. This is illustrated in Figure 35. The ImageJ DAB analysis was undertaken and the results are shown in Table 13. On comparing these values by means of an unpaired t test there was a significant difference in the level of staining between the two groups. The mean percentage pixels stained was $13.40\% \pm 1.652\%$ in the sham group compared to $5.442\% \pm 2.260\%$ in

the CP model group ($p=0.0174$). This is an important finding as we have demonstrated a significant increase in Jagged1 expression in the CP model group compared to shams possibly pointing to a mechanistic pathway for the changes in villous architecture we have seen.



Sham

CP model

Figure 35. Comparison of duodenal specimens stained with anti-Jagged1.

This is an example showing increased staining of the CP model specimen compared to that of the sham specimen.

The two groups were those that had undergone sham brain injections with normal saline and those that undergone bilateral MPFC IBA injections i.e. our CP model. The “%pixels” is the percentage of pixels stained in a standard x10 FOV (field of view).

Table 13. Results of IHC analysis comparing levels of staining for anti-Jagged1 antibody between the two groups.

Sham		CP model	
Area fraction stained (μm)	%pixels	Area fraction stained (μm)	% pixels
261031	8.3	27609	0.88
321851	10.23	11234	0.36
488851	15.54	434027	13.8
589083	18.73	303193	9.64
355703	11.31	210640	6.71
513042	16.31	39661	1.26

3.6 Discussion

3.6.1 Choice of animal model

Sprague-Dawley rats were chosen for our animal model as they are easy to source and care for and we were endeavouring to create a new model based on a previous rodent model which created similar lesions in the motor cortex. (A. Chen et al., 2008) This work showed that the model was well-tolerated by the neonatal rat pups and reproducible, it also illustrated that chemically induced lesions created by injecting the neurotoxin ibotenic acid into the motor cortex on postnatal day 5 to 7 (P5-7) in the rat were functionally and histologically similar to PVL. This model did not target any other cortical regions other than the motor cortex but could easily be adapted to target areas in the brain now known to be responsible for autonomic gastrointestinal control i.e. MPFC and IC. Rodents have been used as experimental models in anatomical research for many years especially in research focusing on the brain because so much is now known with regards to the rat brain as outlined by the Paxinos Rat Brain Atlas. (Paxinos, G., and Watson, C. (1996). *The Rat Brain in Stereotaxic Coordinates*, Compact 3rd Edition CD Rom, Academic Press, San Diego.) It provides a stereotactic map as to how to target different regions in the brain and also show similarities between the brain of a rodent and that of a human. It could be argued, however, that although the Sprague Dawley rats provided a resilient animal model the neonatal pups were very small and can vary greatly in size depending on litter size. The small size of the neonatal rat pups (typically 15g at craniotomy) did make performing craniotomy and brain injections a challenge despite this the Paxinos coordinates were very

helpful especially when trying to target the MPFC. The atlas is, however, for adult rat pups not neonates and so the more lateral IC area was in retrospect always going to be more difficult to inject successfully. We did consider using a larger model such as a pig; however, it was felt on advice from our NVS that creating a piglet with cerebral palsy may result in a large aggressive animal that was difficult to care for.

Other animal models of cerebral palsy have been studied in the past including those that induce antenatal or postnatal ischaemia by techniques such as endovascular balloon occlusion of blood supply to the placenta or ligation of the carotid artery (Jensen, Follett, Uehara, Mallard, Johnston) or maternal or foetal antenatal hypoxia (Baud et al., 2004; Mallard et al., 2003) or a combination of carotid ligation and hypoxia (Sheldon et al., 1996) (McQuillen et al., 2003) or chemical lesions to the brain (Tahraoui et al., 2001). Rodent models resulting from either maternal or neonatal ischaemia often resulted in early death of offspring or rejection by the mother. In addition, because rodent brains are anatomically different and have less white matter larger animals have also been tried including sheep and baboons although these models are much more expensive. Most models have also tended to focus on the resulting motor deficit and there is to the author's knowledge no pre-existing model of cerebral palsy and foregut dysmotility. The only paper that has linked brain damage to foregut dysfunction was from the Indiana group (Vane et al., 1982) which did link surgically induced brain damage in cats to decreased lower oesophageal sphincter pressure and possible gastro-oesophageal reflux. This paper did not, however, focus on creating brain damage akin to that seen in cerebral palsy instead it was brain injury caused by raising intracranial pressure (ICP) by means of a burr hole and inserting and inflating a balloon catheter. At the same time lower oesophageal sphincter pressure was measured and these authors found that by increasing the cat's ICP they lowered the LES both acutely and it remained low 2 and 6 weeks post procedure. There was, however, no measurement of effect on gastric emptying or foregut motility per se and the animal's brains were not examined at the end of the study to confirm what if any brain damage had been created. To the author's knowledge, our chosen model is the first of its kind focusing on cerebral palsy and foregut dysmotility.

3.6.2 Method of investigation of gastric emptying

The gold standard for measuring gastric emptying is scintigraphy. This was not an option in our study as we did not have access to nuclear medicine equipment such as isotopes and

a gamma camera that would be suitable to study such small animals. Manometry and impedance would also have been interesting to study in our model, but again we did not have such equipment for such small animals available to try and to purchase would have been expensive. These are both investigations that perhaps in the future could be considered. The water soluble upper gastrointestinal (GI) contrast series can provide a crude and relatively easy way of measuring gastric emptying time (GET). There are many different methods of assessing gastric emptying in rodents. The majority, however, involve sacrificing the animal to assess gastric emptying. (Ito et al., 1996; Shoji et al., 1997; van der Velde et al., 1999) Such methods were not suitable for our purpose as the animals in our study needed to go on to have repeated gastric emptying studies i.e. before and after brain injection and before and after splanchnectomy for a prolonged period of study. There are, in fact few non-invasive techniques reported in freely-feeding animals. It has previously been shown that gastric emptying increases toward the end of the lactation period in rat pups. We decided to modify the barium grain method (Sakurai et al., 1996) and use water soluble contrast rather than barium grains, as done in routine clinical practice in children and babies. Gastric emptying time would therefore be the time when the stomach was full to completely empty on time lapsed X-rays in animals placed in X-ray compatible plastic tubes. This would allow a non-invasive method of a water-soluble contrast meal in a conscious and prior to the study freely suckling pup and therefore a more reliable and “real” and useful method of assessing gastric emptying in pre-weaned rats.

3.6.3 Histological brain lesions

Identifying brain lesions that targeted the insular cortex (IC) proved difficult. This was most likely because there are no available stereotactic coordinates for neonatal rat pups and because the IC is more lateral in the rat brain. It is, therefore, possible that we did not manage to inject the correct area. Or it may be that due to its laterality the lesions were difficult to find histologically but were there. The latter is a possibility as it can be seen from our results that the rat pups that underwent unilateral or bilateral IC injections did show a difference in both their weight velocity and a delay in their gastric emptying on contrast studies. The other difference between the histological changes seen between MPFC and IC lesions is that not only were MPFC more consistently found on histological examination, but also MPFC lesions rather than showing just areas of cavitation seen in the IC lesions also showed decreased number of neurons and increased numbers of glial cells. This is a significant finding as there has been much focus recently in the literature in

relation to glial cells rather than neurons. Glial cells have now been referred to as the “the fulcrum of brain disease” (Giaume, Kirchhoff, Matute, Reichenbach, & Verkhratsky, 2007). These cells appear to function in two ways but essentially act as fierce guardians of brain tissue in that they not only protect the brain tissue but they also act like natural killer cells endeavouring to wall off damaged areas essentially “to save the whole at the expense of the part”. This split personality of glial cells seems to be specifically seen when there has been an ischaemic brain injury like in preterm and perinatal ischaemia that can cause periventricular leukomalacia (PVL). PVL is thought to be the precursor of cerebral palsy and is typically characterised by diffuse injury of white matter surrounding the lateral ventricles often resulting in apparent ventricular dilatation as seen in those rats in our study that underwent MPFC injections. (Back & Rivkees, 2004) (Li et al., 2003; Li, Wang, & Rosenberg, 2009) These three features of PVL i.e. ventricular dilatation, white matter and neuronal loss and increased glial cells are not only seen in our MPFC lesioned group but were similar to the changes seen in the work by Chen et al. (A. Chen et al., 2008) Chen et al, unlike in our study, also immunostained for myelin basic protein (MBP) and non-phosphorylated neurofilaments (NPNF) and showed that both of these were significantly reduced in the IBA lesioned group compared to controls. This is again perhaps something we could look at analysing in our brain lesions in the future. The Chen et al model, as stated previously, was focused on the motor cortex and was the CP model we were modifying in order to create a CP model with foregut dysmotility. These similar brain lesions in the MPFC were therefore encouraging and began to focus our efforts on the MPFC group as being our sought-after CP model.

3.6.4 Gastric emptying studies after brain lesions

Delayed gastric emptying was found in all animals with brain lesions with IBA regardless of whether lesions were later confirmed to be in the targeted cortical area or not. The difference in GET in each IBA group was statistically significant compared to shams as illustrated in table 7 and figure 25. Our proposed model of bilateral MPFC was only just statistically significant with a mean GET of 57.8 minutes compared to a mean of 46.8 minutes in the sham group ($p= 0.0496$). The most significantly delayed GET was in the bilateral insular cortex group with a mean time of 67.1 minutes ($p=0.0008$). This result is difficult to interpret as numbers are small. An explanation could be that the IC injections were in the right place but that we were unable to locate them consistently on pathology. Our results have also shown a difference on the effect on GET depending on the side of the

brain injected. This raises the questions as to whether laterality is important or not, however, this may be particular to the rodent species as there are recognised differences between gender in some aspects of brain morphology (Paxinos, G., and Watson, C. (1996). *The Rat Brain in Stereotaxic Coordinates*, Compact 3rd Edition CDROM, Academic Press, San Diego.) It could be the case that this is due to bias as the numbers in this study are small and the difference may not be true if a further larger study were undertaken. It is, therefore, difficult to comment further on this.

Another important finding that singled out the bilateral MPFC group as the forerunner for our CP model was that eighty-three percent of the pups with bilateral MPFC lesions showed reflux on the GET study. There has always been debate as to whether rodents are capable of reflux or not. It is well recognised that they do not vomit, but there is evidence in the literature rats are capable of demonstrating some degree of reflux. This relates to gavage induced reflux which is recognised phenomenon and is often encountered in the pharmaceutical industry (Damsch et al 2011, Damsch et al 2011) The reflux seen in the bilateral MPFC IBA group is not gavage related as all animals were gavaged with the same amount of contrast and using the same technique including the shams and the other types of IBA brain lesions. It was only those, although not all, who underwent bilateral MPFC IBA injections that demonstrated evidence of reflux on their contrast study. It should, however, also be borne in mind that, as in humans, contrast studies are not the best imaging modality to diagnose reflux. The same papers cited above by Damsch et al highlight examining nasal histology of rats as a further means of quantifying the presence of reflux. This is akin to examination of airways in children looking for lipid laden macrophages and other inflammatory changes as a way of diagnosing reflux. In the rat study they found evidence of inflammation and areas of necrosis. They also found food material within the inflammatory exudate indicating reflux and/or aspiration of stomach contents. We did not examine the nasal passages of our rats but certainly nasal histology is again something we could consider for future work on our model.

3.6.5 Histological differences in duodenal specimens

The differences seen in the duodenal specimens between the shams and unilateral and bilateral MPFC are interesting but probably raise more questions than answers in terms of their aetiology. It is difficult to know whether the histological changes contribute to or are a result of delayed gastric emptying. For example, the fact that the villi are larger and

wider in the bilateral MPFC IBA group is this part of the aetiology of delayed GET? Or maybe it is biologically significant due to increase absorptive ability due to the reduced motility? Other results that were approaching significance included decreased number of submucosal neurons and increased number of bifid villi. These comparisons would have become significant if we had had larger numbers in our study. The author concedes that counting neurons on HE slides is a fairly crude tool to look for neuronal changes and hence is why we went onto stain for anti-ChAT and anti- iNOS. The increased number of bifid villi is sometimes seen in an inflammatory process but one would expect that if this was purely an inflammatory response that the villi would be shorter and flattened and atrophic looking as seen in coeliac disease. Another finding that goes against the changes seen as being purely an inflammatory response is that the number of total number of lymphocytes per 50 enterocytes was in fact reduced 8.5 in the bilateral MPFC (CP model) group compared to 19 in the shams ($p=0.10$). Interestingly the total number of eosinophils per 50 enterocytes was raised 11.0 in the CP model compared to 7.5 in the shams ($p=0.22$). This was not, however, a significant increase and is therefore difficult to comment further on.

3.6.6 Reduction in number of duodenal Interstitial cells of Cajal

Prior to discussing the duodenal ICC, it is worth mentioning that these cells were looked for in the rest of the foregut but could not be reliably identified in either the distal oesophagus or the stomach. Initially the author was concerned that what was identified in these specimens was faint and almost sporadic but on further examination of the literature it would appear that this is not uncommon. (Komuro, 2006). Perhaps in retrospect electron microscopy of such samples would have been more rewarding when searching for the ICC in these locations. When analysing the number of DMP-ICC cells found in the duodenum of our CP model compared to shams there appeared to be a reduction in the number and organisation of the DMP-ICC. The counting technique using ImageJ was checked by one of the veterinary pathologists and although appears real and statistically significant, it is important to point out that there were only 6 specimens of duodenum examined in the two groups and therefore numbers were small. It may be that a reduction in ICC is involved in the pathogenesis of impaired motility in patients with cerebral palsy or it may be in response to delayed gastric emptying. There is also some work in the literature supporting the idea that ICC can apparently reduce in number because of damage to their networks in response to inflammation. Bettolli et al showed this very elegantly in their paper that in patients with appendicitis compared to controls the networks of ICC are damaged and

difficult to see, but are still present when examined by means of electron microscopy. (Bettolli et al., 2012) They also showed that this damage is temporary as they also examined appendices from those patients undergoing interval appendicectomy i.e. appendicectomy following a prolonged course of antibiotics and such damage was not seen. It may be that the apparent reduction we have seen was in response to gastric emptying rather than the cause and it difficult to comment on this when ICC cells could not be reliably identified in the antral specimens. In addition to perhaps in the future conducting electron microscopy it would also be worth examining specimens from animals allowed to survive even longer post operatively. In phase 1 rats were sacrificed on day 28 of study and it would be worth seeing if the animals were allowed to live for longer following their brain injection whether indeed the gastric emptying time might return to nearer normal but also whether the duodenal changes we have seen including numbers of ICC also return to normal or show some signs of recovery.

3.7 Further immunohistochemistry analysis

There is currently much controversy amongst researchers as to what is the best way to quantify differences in staining of specimens and immunohistochemistry (IHC) in a meaningful and consistent way. Even the experienced and blinded research pathologists can differ in the opinion of intensity of staining and inter-observer variability can be a difficult hurdle to overcome. Hence, in recent years, technology has been used to try to combat this with the advent and popularity of programmes such as ImageJ. (Jensen et al., 1994; Varghese, Bukhari, Malhotra, & De, 2014) (Rizzardi et al., 2012) Whilst some papers endorse this type of analysis there are authors who are of the opinion that such analysis is not recommended as antigen-antibody reactions are not what is referred to as stoichiometric i.e. the “brownness of the stain” does not necessarily reflect the level of reaction between the tissue and the antibody. Given that the author is not a pathologist and there was not time for blinding of a pathologist to examine IHC by a traditional scoring method, it was felt that using the ImageJ IHC toolbox was the most reliable method to aid comparison between specimens from the two groups.

3.7.1 Anti- iNOS staining

The gut is a major source of NO and is made by the conversion of L-arginine to L-citrulline and NO. This conversion by oxidation is catalysed by on three forms of the enzyme nitric oxide synthase (NOS). It is felt that levels of different types of NOS reflects

the amount of NO in the tissues. The predominant form in the enteric nervous system is nNOS (neuronal nitric oxide synthase) and studies have shown a reduction in nNOS in mice can lead to increased relaxation of the lower oesophageal sphincter (LOS) and gastroparesis. (Mashimo & Goyal, 1999). Several studies have shown a relationship between gut dysfunction and inhibition or low levels of NO for example in conditions such as pyloric stenosis (Vanderwinden, Mailleux, Schiffmann, Vanderhaeghen, & De Laet, 1992), Hirschsprungs disease (Larsson et al., 1995) and achalasia (Mearin et al., 1993). We did not examine nNOS, which perhaps in retrospect we should have, but we have shown a clear reduction in the iNOS expression in the duodenum of our proposed CP model. The reason we chose to examine iNOS was that it is known to be found in epithelial cells and neurons and also it is known to remain activated for longer and result in more NO production than perhaps the other isoforms making it possibly easier to identify in our specimens. The reduction we have seen in our CP model may be explained by impaired motility, but it is also known that iNOS is produced in disease states often as a response to inflammation and its production is affected by bacterial pathogens, inflammatory cytokines and macrophages. (Han, Fink, Yang, & Delude, 2004) Indeed, there is much work ongoing to attempt to pharmacologically reduce iNOS so as to create a further anti-inflammatory agent. (Chiou, Chen, & Lin, 2000) Therefore, it could be argued, that the significant reduction in iNOS in our model compared to the sham specimens further supports the theory that the microscopic changes we have seen in villous architecture are not related to an inflammatory process but to the pathogenesis of impaired gastric emptying and dysmotility. It would be prudent therefore, that further study of our model would include assessment of nNOS levels rather than just iNOS. The results of this particular antibody whilst interesting and clearly different between the two groups may raise more questions than answers as to why we are seeing the changes we have seen in our CP duodenal specimens.

3.7.2 Anti- ChAT staining

Despite some specimens that appeared to have increased staining or expression of ChAT in the submucosal plexus the overall quantitative comparison revealed no appreciable difference between the two groups. There also appeared to asymmetrical and inconsistent staining at times in the anti-ChAT specimens which is difficult to explain as all IHC protocols were standardised and followed as such. It maybe that there was a problem with poor fixation of the tissue at the time of the specimen retrieval, but either way it is

disappointing that no real conclusions could be made despite trying different concentrations. We had expected that the level of ChAT may be raised in our CP model bowel specimens, as we commonly see in Hirschsprungs disease, but perhaps further study of this antibody and our CP model may be more productive in the future.

3.7.3 Anti-jagged 1

Finally, anti-jagged 1 was our last antibody examined as it was singled out due to the observation of deranged villous architecture in the duodenum of our CP model. Previous studies have highlighted the importance of the notch pathway and Jagged1 in the general homeostasis of the adult gut. (Sander et al., 2003; Sander & Powell, 2004) Immunohistochemistry and subsequent analysis of our duodenal specimens clearly showed an increased expression in our CP model. The possible reasons for this include a response to poor gastric emptying and the need for widened and taller villi to try to maximise absorptive capacity. On the other-hand it could be as a result of a failure in the notch/jagged1 pathway or possible derangement of a negative feedback mechanism and hence uncontrolled expression leading to poor maintenance of villi structure and function therefore leading to poor motility. There is also relatively recent evidence in the literature relating intestinal motility to the Notch pathway. Indeed, Jia et al showed for the first time that the pathway is involved in the enteric nervous system. They showed, however, the opposite finding to what we have seen in our CP model. Instead of increased jagged 1 expression they found that in Hirschsprungs disease there was downregulation of Notch-1 and Jagged-2 mRNA. (Jia, Zhang, Chen, Gao, & Wang, 2012) The Notch pathway has also been implicated along with other pathways such as Wnt and bone morphogenic protein/TGF- beta in the pathogenesis of irritable bowel syndrome. (Ratanasirinrawoot & Israsena, 2016) Many studies have described the Notch pathways important role in the development in the enteric nervous system and the differentiation of epithelial stem cells and normal gastric formation. (Le Guen, Marchal, Faure, & de Santa Barbara, 2015) (Faure, McKey, Sagnol, & de Santa Barbara, 2015; Okamura & Saga, 2008; Takashima et al., 2011; Theocharatos et al., 2013) The Notch pathway is closely linked with Hedgehog signalling and both are needed for normal enteric nervous development. (Liu & Ngan, 2014) Perhaps the increased jagged1 expression we have found in the duodenal specimens of our CP model reflects an interruption and subsequent disorganisation of this signalling pathway which may be a factor in the impaired gastric emptying we have demonstrated.

3.7.4 Phase 1 summary

In conclusion, at the end of phase 1 we have succeeded in achieving our first aim of creating a new model of cerebral palsy that demonstrates evidence of poor gastric emptying and foregut dysmotility. This CP model is created by injecting ibotenic acid bilaterally into the MPFC via midline craniotomy on postnatal day 5 to 7. We have demonstrated that we can create lesions in the brain similar to PVL with evidence of ventricular dilatation, neuronal loss and increased number of glial cells. We have also shown that when such lesions are created in the brain this results in delayed gastric emptying and an increased risk of gastro-oesophageal reflux. Lastly and importantly we have linked these lesions in the cortex of the brain to structural changes in the villous and crypt architecture in the foregut. Therefore, for the remainder of this thesis when referring to the CP model this will be synonymous with bilateral MPFC IBA injections.

Chapter 4

Results – Phase 2

As stated in chapter 1 the aim of phase 2 of the study was to perform splanchnectomys on our established CP model and find out if this improves gastric emptying and enteric motility. This will attempt to explain the clinical improvements we have seen in our small series of patients. It will also help confirm whether our thesis of an imbalance of the sympathetic and parasympathetic nerve supply to the bowel can be rectified by this simple procedure. We then plan to examine the animals functionally by means of further gastric emptying (GE) studies after splanchnectomy and also histologically by means of further foregut specimens similar to that discussed in chapter 3. As also mentioned in chapter 2, prior to splanchnectomy on live animals, cadaveric laparotomies on rodents were performed to not only practice the technique but to ensure that what we identified as the three branches of the splanchnic nerves was accurate. In these cadaveric laparotomies therefore the splanchnic nerves were resected and analysed histologically. The histological analysis, which was corroborated by our veterinary pathologist, showed three bundles of myelinated nerve fibres, supported by a fibrillary stroma (endoneurium) with scattered small blood vessels and surrounded by connective tissue sheath consistent with perineurium. It, therefore, importantly confirmed that what we were targeting was indeed the three branches of splanchnic nerves.

4.1 Animals

In phase 2 twenty-six pups were used in total, 14 female and 12 male. The median weight at the time of operation was 64grams (range 43-108.1 grams). As can be seen in the flow diagram (Fig.36) there were 13 pups in each group i.e. the CP model and the sham group. One animal died from a sham injection from post-operative apnoea and two animals, one from each group, died from bleeding from the suprarenal artery. This problem of bleeding from the suprarenal artery was encountered within the first few splanchnectomys and again much like the procedures in phase 1 of our study there was a learning curve and once we knew that the suprarenal artery lay so close to our dissection field then we subsequently

managed to avoid injuring it in future laparotomies. Of note it is important to point out that in both cases the bleeding was controlled but due to the small size of the animal and therefore its small circulating blood volume subsequent resuscitation attempts were futile. This, therefore, left us with 12 in the CP group and 11 in the sham group.

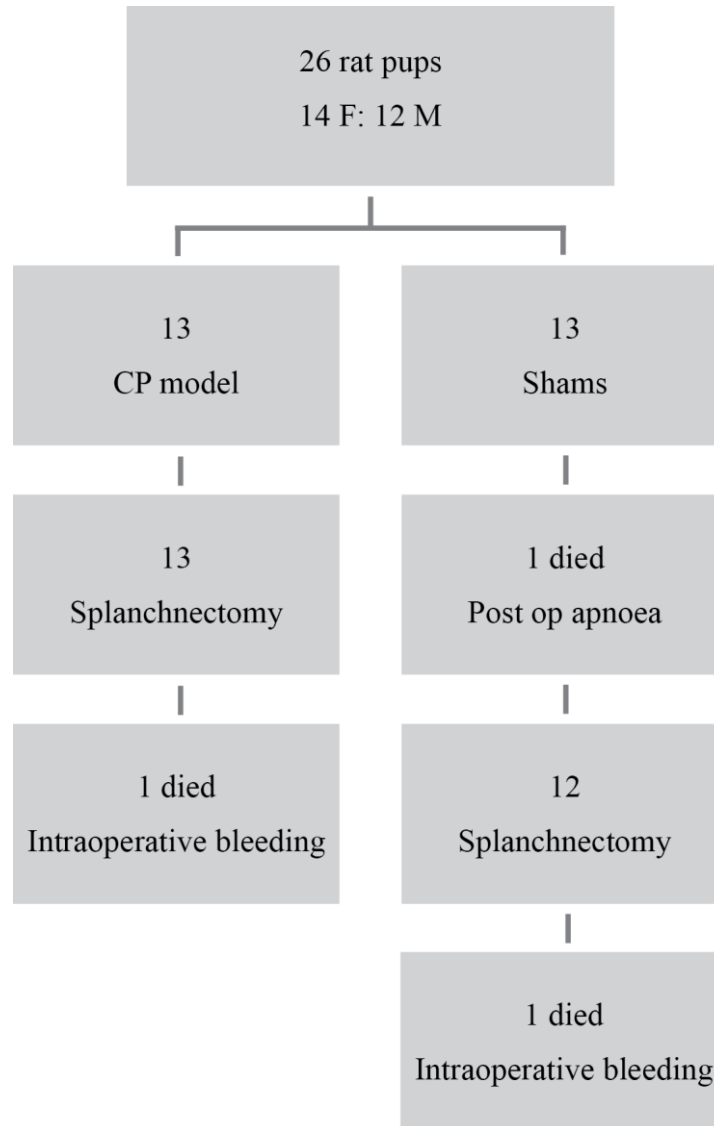


Figure 36. Phase 2 Flow diagram

Flow diagram showing the numbers of animals in each group and the animals lost both pre- and post splanchnectomy.

4.2 Difference in weight velocity

As stated in chapter 2 the pups in phase 2 of the study went through a timeline of GE study pre- and post splanchnectomy and were weighed regularly and their relative weight gain or

“weight velocity” was plotted. Figure 37 shows a graph comparing the weight velocity of the two groups. At first glance it would appear that there is no real difference between the two groups, however, in retrospect if we compare the two groups in terms of the mean weight at the start of the study i.e. on the day of brain injections (postnatal day 5) there is a significant difference. The sham group have a mean start weight of 12.45 grams (10.3-14.3grams) compared to a mean start weight of 16.35grams (12.2-15.2grams) in the CP model group ($p=0.013$). This was not noticed at the time of the study but in retrospect was most likely due to a difference in random litter size and selection i.e. a small litter size in the CP model group resulting in larger offspring as opposed to the sham group. When comparing overall weight velocity over the course of phase 2 between the two groups then there is no appreciable difference. The mean weight velocity in the shams was 126.8 grams (106.2-142 grams) compared to 137.3 grams (108.1 -158.1 grams) in the CP model, $p=0.272$.

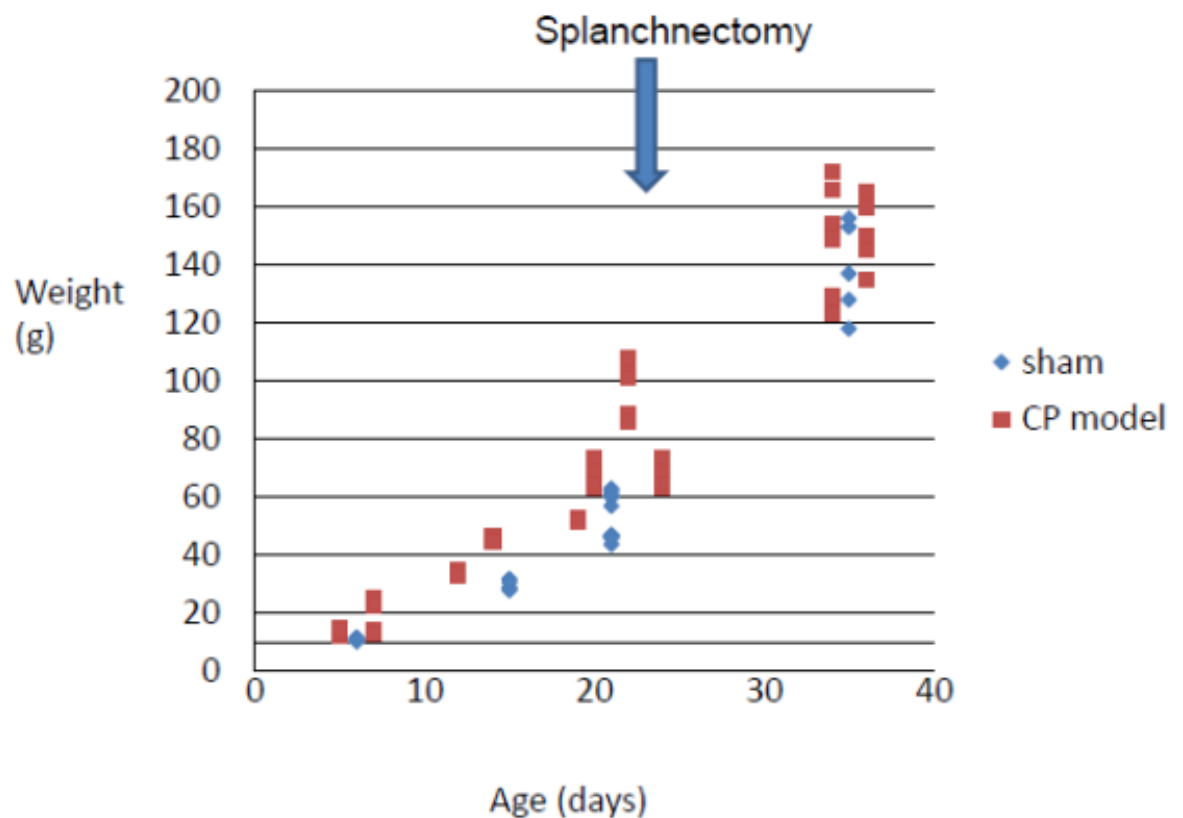


Figure 37. Scatter XY graph showing weight velocity in phase 2.

Graph showing the weight velocity of the two groups i.e. the shams and the CP model over the course of phase two of the study. There is no significant difference in overall weight velocity, but of note the shams were significantly smaller in retrospect but demonstrated

catch up growth compared to the CP group. As shown by the blue arrow splanchnectomy was performed mostly between day 20 and day 22.

4.3 Gastric Emptying Studies

As stated in chapter 2, in phase2 of our study gastric emptying (GE) studies were conducted according to a timeline. This was following brain injections and then pre- and post splanchnectomy. The purpose of repeated GE studies served to be two-fold. It was not only necessary to measure GE in the same cohort pre- and post splanchnectomy but also provided an opportunity to repeat and re-demonstrate what was shown in phase 1. This is essential so as to further corroborate our decision to adopt bilateral MPFC IBA injections as our cerebral palsy model by yet again demonstrating that a further group that have undergone this type of injection show delayed gastric emptying compared to controls. This is illustrated in Figure 38. The mean GE time in the CP model was 56.0 minutes compared to 42.18 in the controls or shams ($p=0.0024$). Both groups then underwent midline laparotomy and splanchnectomy. In the CP model group this reduced the GET from 56.9 minutes to 39.25 minutes, Figure 39 ($p= 0.0005$). Then, interestingly, there is the other group that had undergone sham brain injections also underwent splanchnectomys and their GET also reduced significantly from 42.18 to 29.18 minutes ($p=0.0045$) Figure 40.

The main message in this chapter is summed up in Figure 41. This shows our most important finding yet which is that the GET of the CP model after splanchnectomy was similar to the GET of the shams in phase 1. In other words, we have again proven that our CP model works i.e. injecting IBA into the MPFC bilaterally significantly delays GET. In addition, we have shown that splanchnectomy returns this GET to near normal values. Our hypothesis was that the delay in GET was due to an imbalanced autonomic nervous system with sympathetic overdrive. Our results go a long way towards proving this as we have shown that by performing splanchnectomy we can “redress the balance”.

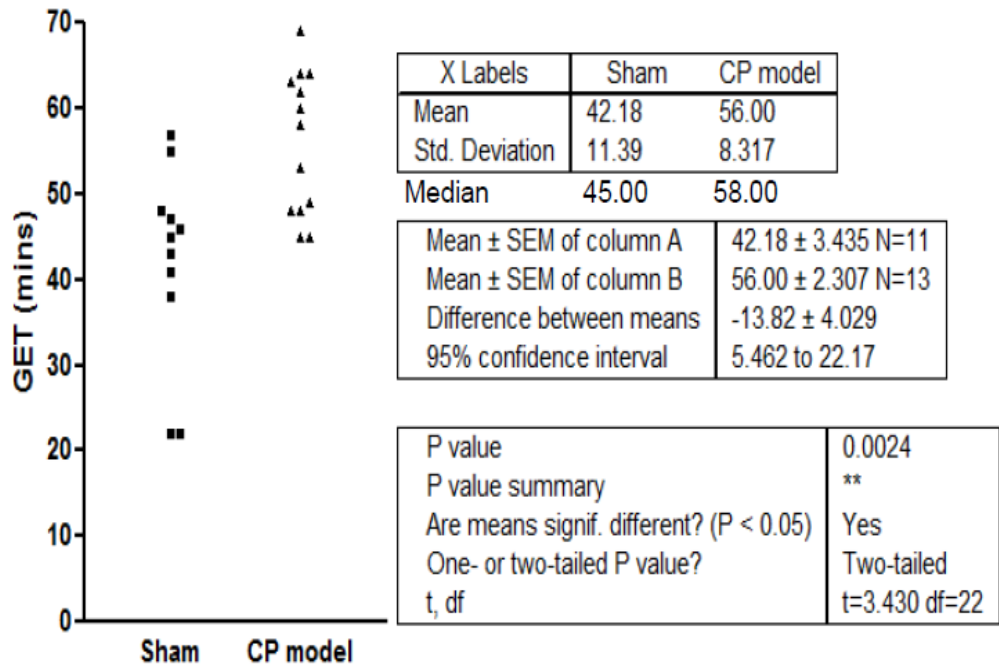


Figure 38. Graph confirming our CP model in phase 2.

This graph shows that we have evidence of delayed gastric emptying time (GET) in the CP model compared to shams in phase 2 as first shown in phase 1 (chapter 3.)

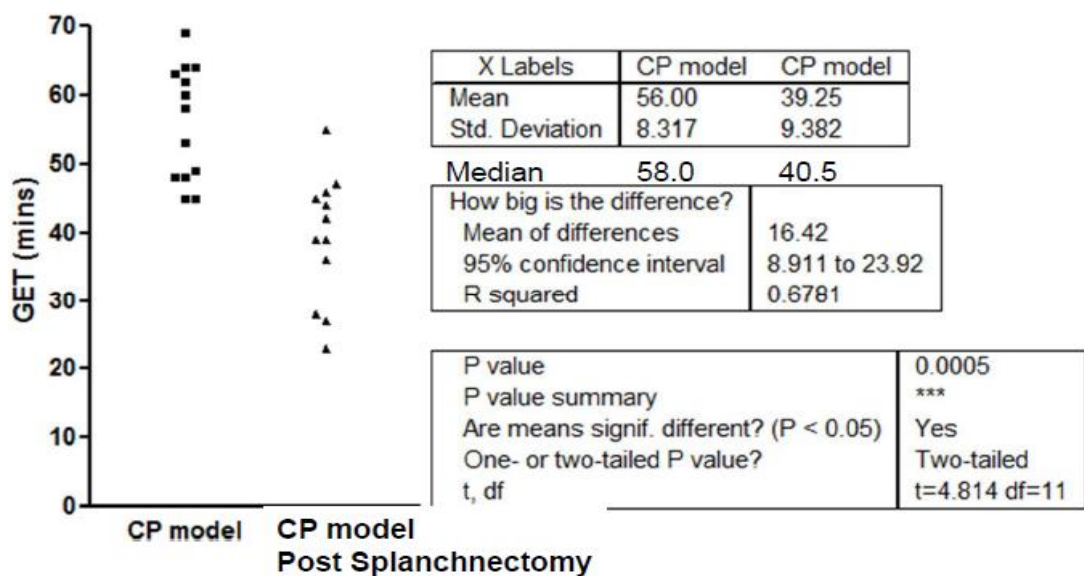


Figure 39. Graph showing splanchnectomy improves GET in our CP model.

A graph showing that our CP model has a statistically significant improvement in gastric emptying time (GET) following unilateral splanchnectomy by means of midline laparotomy and division of the splanchnic nerves with diathermy.

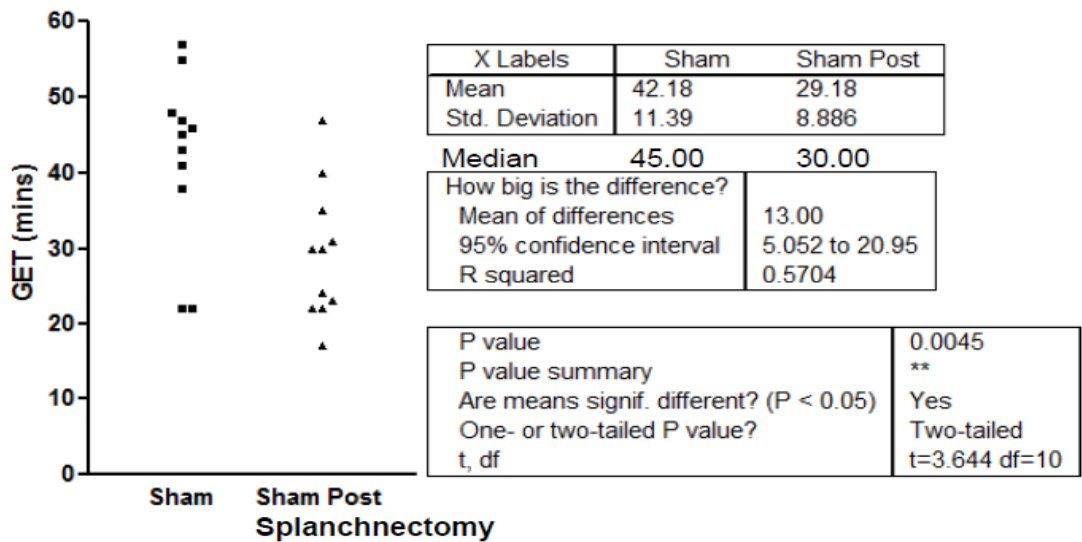


Figure 40. Splanchnectomy on shams and effect on GET.

This graph shows that not only was there a fall in the GET of the CP model but also when splanchnectomy was performed on sham animals i.e. those that had undergone a brain injection with normal saline rather than IBA, the GET fell significantly.

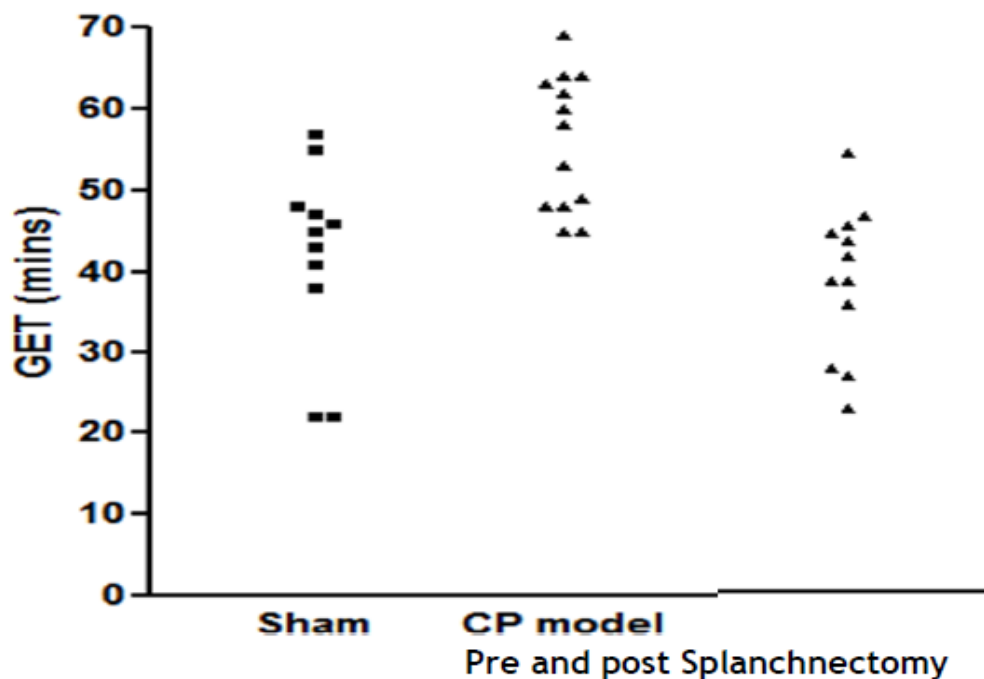


Figure 41. Redressing the balance: GET of our CP model pre- and post-splanchnectomy. Post splanchnectomy the values are comparable to the shams i.e. the GET has been brought back down to normal.

4.4 Histological analysis

As stated in chapter 2, in phase 2 of the study histological analysis was not repeated on brain specimens, although these were stored they were not later analysed for time and monetary reasons. It was also because it was felt that phase 1 had shown that this lesion could be produced consistently and therefore, it was not necessary at this stage. Instead the histological analysis of phase 2 will focus on the foregut analysis of specimens taken post splanchnectomy. Duodenal specimens were examined using the same modified scoring tool as illustrated in chapters 2 and 3, from Day et al. (Day, Bilzer et al. 2008) As before the villi height and width were measured as a more quantitative assessment of villous blunting and atrophy, a feature seen often particularly in any cases where there has been damage to the villous enterocytes. The number of villi was counted as a way of calculating the percentage of bifid or fused villi, a potential marker of inflammation or disordered architecture. Lamina propria width and intercrypt distance were measured as a means of quantifying any difference in the presence of oedema. Crypt height was measured in an attempt to identify any proliferative response occurring in these animals. We hypothesised that the thickness of the muscularis may be different again owing to the fact that we've shown these same animals that had had delayed GET now have normal GET post splanchnectomy. We also measured this and similarly we counted the number of neurons in the myenteric and submucosal plexus. We also counted the number of eosinophils and the number of lymphocytes in the epithelium and in the lamina propria per 50 enterocytes. The main question we wanted to answer from this part of the analysis was whether some of the changes we reported in the duodenum of our CP model in chapter 3 e.g. increased villous width and height and thickness of the submucosa, decreased number of submucosal neurons and increased number of bifid villi, were still present or absent post splanchnectomy. Table 14 shows the results of the analysis and compares it to our previous CP model and sham results from phase 1 of the study.

Initially, on reviewing the slides from the post splanchnectomy animals the so-called “spot the difference” analysis was interesting as it appeared that all the duodenal specimens appeared the same. There was no obvious difference between the previous shams from stage 1 and that some of changes seen in the duodenum in the CP model group appeared to have resolved. It can be seen, however, going down the table and through the different features that this was not necessarily the case. For example, at first glance the villous architecture looked like it may be more normal post splanchnectomy but then the villi

height and width measurements were more akin the to the CP model rather than the previous shams although it is important, as has already been stated, to point out that the post splanchnectomy animal was 16 weeks old at the endpoint of the study. Their bigger size may go some way to explain why the measurements and villous height and width were not similar to previous smaller sham or control animals but more like the pre-splanchnectomy CP model. We had sham animals that underwent splanchnectomy but in retrospect it would have been better for comparison if we had had a further group of our CP model that underwent a sham laparotomy without splanchnectomy. This would have made this histological analysis easier.

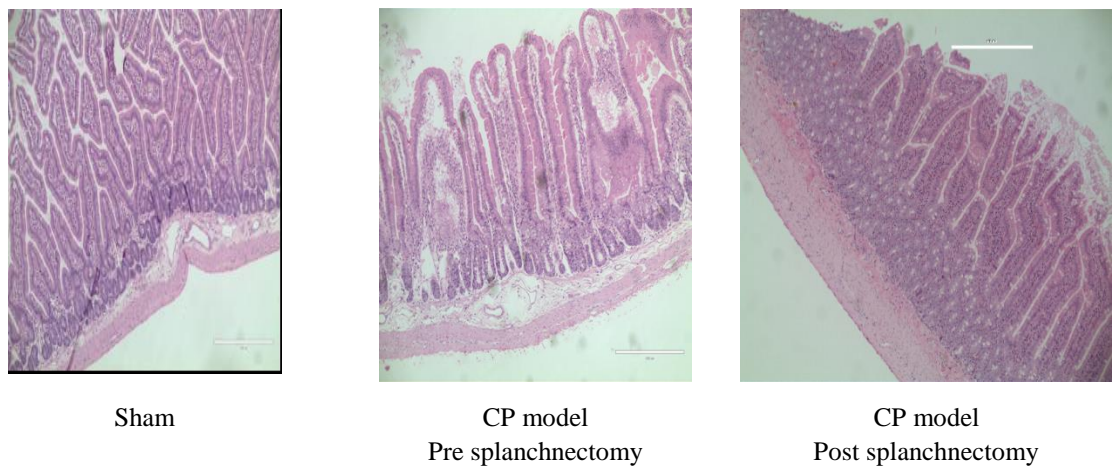


Figure 42. H&E of duodenal specimens in phase 2.

Three microphotographs comparing the typical appearance of duodenal specimens from each of the three groups, the shams, the CP model and the CP model post splanchnectomy. It can be seen the sham and post splanchnectomy appearances look similar with normal looking villi compared to the CP model that had not undergone splanchnectomy. These specimens showed broader more bifid villi with more disordered villous architecture.

Table 14. Comparative histological scoring of duodenal specimens in phase 2.

This was between the three groups: shams, CP model (bilateral MPFC IBA injections) pre- and post splanchnectomy. The results are displayed in the same order as in chapter 3 which showed the most significant differences between the shams and CP model first. It is important to point out that these are not the same animals pre- and post splanchnectomy. The sham and CP model data is take from phase 1 when the animals were 28 days of life at the time of cardiac perfusion but the post splanchnectomy animals were on study for longer and were 16 weeks of age and much bigger at the endpoint of the study. This difference in size and age will therefore make comparison difficult for some measurements.

Median	Sham	CP model	CP model post splanchnectomy
Villous width (µm)	109.9 (86.1-135.8)	133.1. (109.7-204.5) p=0.03	165.11 (117.4-204.19) p=0.0007
Villous height (µm)	388.9 (314.7-496.8)	500.4 (429.5-576.3) p=0.04	606.43 (455.69 – 820.06) p=0.0028
Thickness of submucosa (µm)	49.1 (24.9-56.2)	72.8 (49.7-104.1) p=0.02	67.30 (61.85-128.86) p=0.0028
No. of submucosal neurons per x40 FOV	3.1 (2.1-5.2)	2.1 (0.9-3.5) p=0.06	4.0 (2-6) p=0.0193
No. of lymphocytes in Lamina Propria per 50 enterocytes	8.5 (5-24)	6.0 (5.0-7.0) p=0.08	10.0 (5-28) p=0.2145
Intercrypt distance (µm)	52.2 (40.4-69.9)	59.9 (50.3-77.8) p=0.09	39.29 (14.73-91.66) p=0.0128
Total number of lymphocytes per 50 enterocytes	19 (10-32)	8.5 (5-21) p= 0.10	26.0 (14-46) p=0.0854
% Bifid Villi	6.9	10.2 p=0.1	3.1 p=0.022
Outer longitudinal muscle thickness(µm)	30.0 (21.1-53.9)	43.3 (22.3-48.9) p=0.13	44.799 (21.14-84.054) p=0.0052

Median	Sham	CP model	CP model post splachnectomy
No. of myenteric neurons per x40 FOV	2.4 (1.25-3.8)	1.5 (0.6-2.6) p=0.14	2 (1-4) p=0.579
Width of lamina propria (μm)	37.8 (33.5-46.5)	46.2 (36.1-94.1) p=0.18	54.355 (37.95-63.14) p=0.0096
Total number of eosinophils*	7.5 (4-12)	11.0 (5-16) p=0.22	6.0 (5-8) p=0.0366
No. of epithelial lymphocytes*	8.0 (5-18)	4.5 (1-14) p=0.22	7.0 (6-11) p=0.776
Total no. of neurons per x40 (FOV)	5.25 (4.0-9.0)	4.15 (2.9-8.74) p=0.24	6.5 (5-8) p=0.514
No. of Epithelial eosinophils*	0.5 (0-6)	2.5 (1-9) p=0.29	2.5 (1-7) p=0.543
No. of eosinophils in Lamina propria*	7.5 (0-14)	9.0 (1-10) p=0.29	2.0 (1-6) p=0.0847
Crypt height (μm)	189.2 (129.1-284.4)	213.9 (141.9-283.0) p=0.59	192.02 (133.66-328.33) p=0.637
Inner circular muscle thickness (μm)	65.5 (55.8-90.6)	62.1 (49.1-80.9) p=0.59	62.24 (32.31-144.03) p=0.989
Total thickness of muscularis (μm)	101.3 (85.6-142.2)	108.4 (60.6-133.9) p=0.87	105.42 (55.07-195.54) p=0.813

* = per 50 enterocytes

Although, there was some difficulty comparing measurements of structures such as villi and muscle because of difference in animal size, table 13 does show some potential differences in cell populations which may have been affected by splachnectomy. For example, rather than a reduction in the number of submucosal neurons seen in a field of view (FOV) at magnification x40 as there was when we compared the CP model to shams there was in fact a statistically significant increase in numbers post splachnectomy. The total number of lymphocytes also returned to a level similar to the shams and the total

number of eosinophils was significantly reduced. There was also a significant reduction in the number or overall percentage of bifid villi. This may suggest that the previous changes seen in our CP model may have had some inflammatory component but it is still not clear exactly what caused the changes seen previously some of which appear to be reversed post splanchnectomy. This is illustrated further in Figure 41 which shows a typical appearance of a sham duodenal specimen from phase 1, a CP model specimen and a CP model specimen post splanchnectomy. Much like in chapter 3 this histological analysis probably raised more questions than answers and hence why we elected to repeat the same immunohistochemistry post splanchnectomy to investigate and search for a reason why the appearance of the duodenum in our CP model has changed.

4.5 Immunohistochemistry

As described in chapter 3 it was difficult to appreciate histological differences between areas of the foregut other than the duodenum and as such in phase 2 immunohistochemistry studies were performed for the same four antibodies on all duodenal specimens taken post splanchnectomy. The first was anti-human CD117. As stated in chapter 3 we have already made the important discovery that the number of interstitial cells of Cajal or ICC is reduced in number in the deep muscular plexus in our CP model compared to shams. In this analysis, we wanted to investigate whether splanchnectomy affected the number of DMP-ICC and whether this was a possible explanation as to why the gastric emptying post splanchnectomy improved. Similarly, whether the expression of the remaining three antibodies: anti-iNOS, anti-ChAT and anti-jagged 1 were influenced by splanchnectomy in an attempt to further explain the mechanistic pathways which maybe at play in the improvements we have seen just clinically but also now in our animal model.

4.5.1 Anti-Human CD117

As described in chapter 2 and 3 this antibody allowed good visualisation of the interstitial cells of Cajal in the deep muscular plexus or DMP –ICC in the duodenum, which meant that the numbers of the cells could be counted along the length of the specimen and expressed per x40 FOV. Ten duodenal specimens were retrieved from rats, all of whom had undergone our CP model (bilateral MPFC IBA injections) and splanchnectomy. Figure 42 illustrates the expression of these interstitial cells of Cajal in our CP model and then in our CP model post splanchnectomy. We found that in the post splanchnectomy group the median number of DMP-ICC per x40 FOV rose to 6.5 (2-16) compared to what we found

in phase 1 of our study where the median number of DMP-ICC per x40 FOV was 2.7 (1.4-4.3) in the sham animals compared to 2.0 (1.36-2.45) in the CP group ($p=0.04$). This, therefore, indicates a substantial increase in the number and organisation of the DMP-ICC. In addition, throughout this analysis it was apparent although difficult to measure quantitatively that not only were the numbers of DMP-ICC increased, but importantly, they appeared more predictably and regularly as perhaps can be appreciated from the example in Figure 42. This may go some way to explain the significant improvement seen in our gastric emptying times in this group or again as mentioned above may be that the animals have had longer to recover from their surgery, which as mentioned in chapter 3 can be influenced by surgery and also may naturally increase in number over time in animals that are not only more mature but also bigger in size.

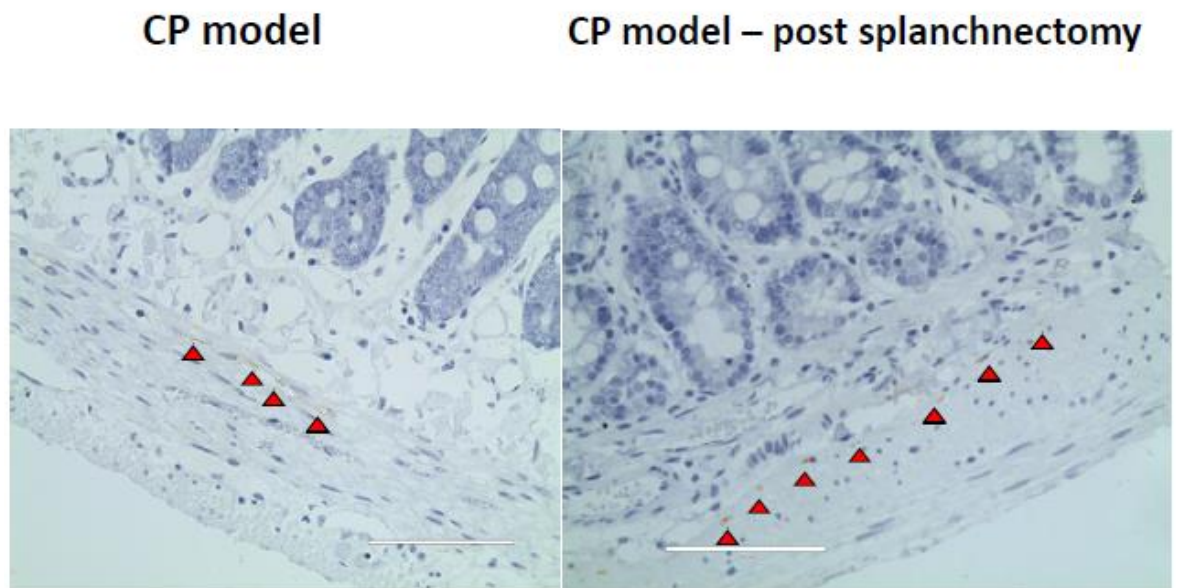
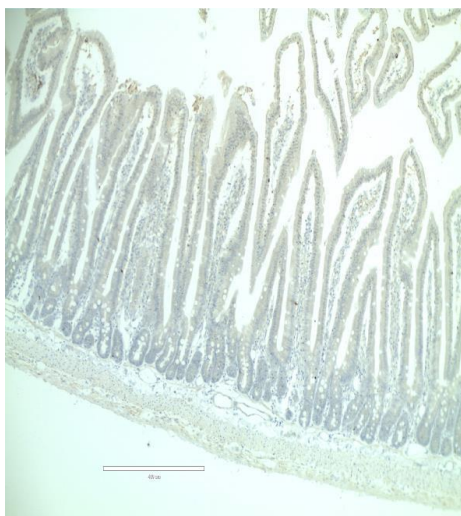


Figure 43. Anti-Human CD117 pre- and post splachnectomy.

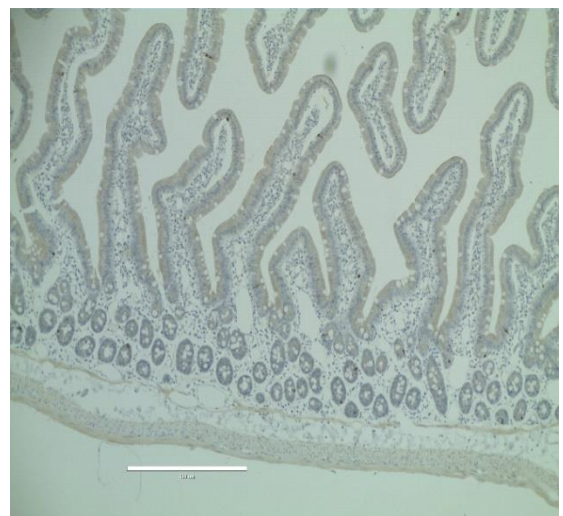The figure above shows two microphotographs taken at x40 FOV showing cells stained a bronze/brown colour sitting deep to the submucosa. They are marked with a red arrow and in the CP model were found to be reduced and at times clumped together as shown above, however, in the CP model post splachnectomy they were found more regularly and evenly spaced along this layer between the submucosa and the inner circular muscle.

4.5.2 Anti-iNOS antibody staining

As discussed in all three preceding chapters, nitric oxide is one of the single most important compounds when it comes to normal intestinal motility. It is present in different forms including inducible nitric oxide and this is produced through a pathway involving the enzyme inducible nitric oxide synthase or iNOS. This antibody therefore targets this enzyme and therefore, highlights the presence of NO in the tissues, in this case the duodenum. Therefore, as before, six specimens were taken from the second part of the duodenum from animals that had undergone bilateral MPFC IBA injections (our CP model) and then subsequent splachnectomy. These were then stained for anti-iNOS using the standard immunohistochemistry protocol discussed in chapter 2 and compared to area fraction stained of those that had undergone bilateral IBA MPFC injection only i.e. our CP model from phase 1. Figure 44 shows a typical example from each cohort. It was not possible to blind the author to which specimens were from which cohort and so the digitalised slides were analysed using ImageJ's IHC tool to quantify objectively the area fraction stained with the antibody. The results are shown in Table 15. On comparing these values by means of an unpaired t test the difference between the means was -1.157 ± 0.6579 (CI -0.3092 to 2.623), $p=0.1092$. These results would suggest that although we have shown in chapter3 that the level of iNOS was reduced in our CP model compared to shams, this level is not affected by splachnectomy and therefore the improvement in gastric emptying time post splachnectomy does not appear to be mediated by NO levels in the duodenum.



CP model from phase 1



CP model post splachnectomy

Figure 44. Comparison of duodenal specimens pre- and post splachnectomy.

The microphotographs in Figure 44 show the typical difference in staining for the anti-iNOS antibody. Equivalent expression can be seen in the specimens from the bilateral IBA injections group i.e. our CP model and the CP model post splanchnectomy.

This table shows analysis of staining for anti-iNOS between the two groups: our CP model (animals that had undergone bilateral MPFC IBA injections from phase 1) and the CP model that undergone splanchnectomy i.e. phase 2. The “%pixels” is the percentage of pixels stained in a standard x10 FOV (field of view).

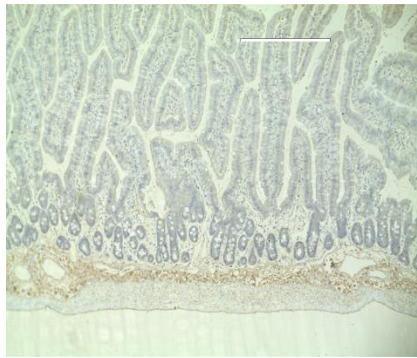
Table 15. Anti-iNOS antibody staining in phase 2.

CP model (from phase1)		CP model post splanchnectomy (phase 2)	
Area fraction stained (μm)	% pixels	Area fraction stained (μm)	% pixels
5244	0.17	53492	1.7
1049	0.03	6326	0.2
41135	1.31	384743	1.23
32813	1.04	9203	0.29
16531	0.53	92713	2.95
14706	0.47	128719	4.09

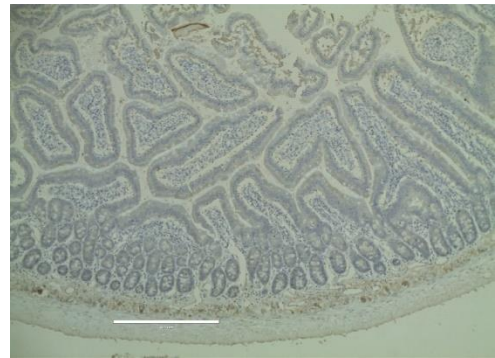
4.5.3 Anti-ChAT antibody staining

As described in chapter 3 acetylcholinesterase (ChAT) has been shown to be important in foregut motility in a number of ways. ChAT interacts with the vagus nerve and enteric neurons as well as intestinal macrophages. (Cailotto et al., 2014) When comparing sham animals compared to our CP model, no difference was found between the two groups in terms of the expression of the antibody. In phase 2 immunohistochemistry was performed using the antibody anti-ChAT on duodenal specimens from the bilateral MPFC IBA group (the CP model) post splanchnectomy from phase 1 compared to our CP model post splanchnectomy. Six duodenal specimens were compared from each group. As stated previously it was not possible to blind the author to which specimens were from which cohort and so the digitalised slides were analysed using ImageJ’s IHC tool to quantify objectively the area fraction stained with the antibody. Figure 44 shows an example of a comparison between the duodenal specimens from each group. Although there was no

difference found in ChAT expression in phase one we have shown that the animals post splanchnectomy do show a significant improvement in their gastric emptying time and therefore this stain was repeated to see if the ChAT pathway was involved in this functional improvement. The ImageJ DAB analysis was undertaken nonetheless in exactly the same manner as for anti-iNOS. The results are shown in Table 15. On comparing these values by means of an unpaired t test there was again no difference found in the level of staining between the two groups. The mean percentage pixels stained was 4.040 ± 0.9391 (N=6) in the CP model group compared to 4.803 ± 0.8553 (N=6) in the CP model post splanchnectomy group ($p=0.56$). From this we can conclude that in terms of the improvement in gastric emptying time seen post splanchnectomy this does not appear to be mediated by any difference in expression of ChAT.



CP model from phase 1



CP model post splanchnectomy

Figure 45. Comparison of duodenal specimens stained for anti-ChAT in phase 2. Microphotographs showing the typical appearances of staining for the anti-ChAT antibody showing equivalent expression in the specimens from the bilateral IBA injections group i.e. our CP model and the CP model post splanchnectomy.

Table 16 shows the anti-ChAT staining analysis for the two groups: our CP model (animals that had undergone bilateral MPFC IBA injections from phase 1) and the CP model that undergone splanchnectomy i.e. phase 2. The “%pixels” is the percentage of pixels stained in a standard x10 FOV (field of view).

Table 16. Results of IHC analysis for anti-ChAT antibody in phase 2.

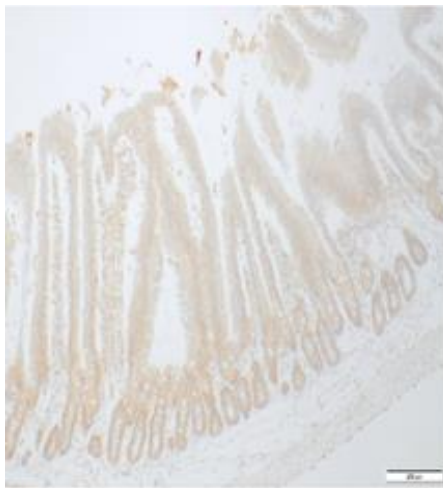
CP model (from phase 1)		CP model post splachnectomy (phase 2)	
Area fraction stained (μm)	% pixels	Area fraction stained (μm)	% pixels
25008	0.8	189420	6.02
95899	3.05	175313	5.57
219191	6.97	144683	4.60
82957	2.63	61759	1.96
150549	4.79	93511	2.97
188850	6	242027	7.70

4.5.4 Anti-Jagged 1 antibody staining

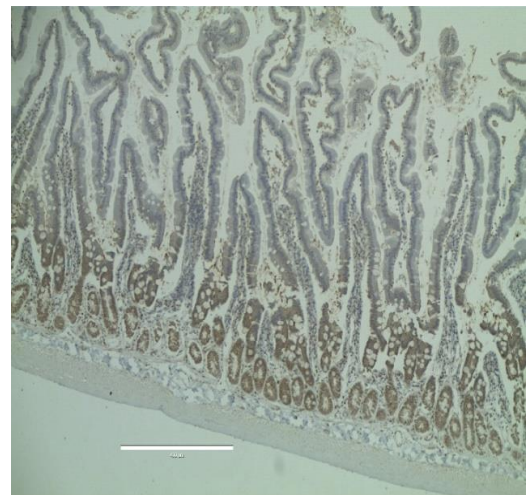
Jagged1 is a cell surface protein or ligand involved in the notch signalling pathway which is a pathway crucial in making decisions on the fate of cells in many different organs throughout the body. Jagged 1 was examined because the Jagged-1/Notch-1/Hes-1 pathway has been shown to be involved in intestinal adaptation post small bowel resection (G. Chen et al., 2013) and in the development and maintenance of normal villous architecture. (Sander et al., 2003; Sander & Powell, 2004). As in chapter 3 we only performed Jagged 1 analysis on our duodenal specimens as we were specifically looking to see if we could marry the changes seen in villous architecture to the level of expression of Jagged 1. In chapter 3 we found a significant increase in Jagged1 expression in the CP model group compared to the sham group corresponding to more deranged villous architecture compared to normal villous architecture in our control specimens taken from shams. Histologically, there appeared post splachnectomy to be some return to normal villous architecture although this was difficult to quantify as the two groups were not comparable in terms of age or size at the endpoints of phase1 versus phase2 of the study when the foregut specimens were collected. It had been hoped therefore that anti-Jagged1 antibody expression may clarify whether or not this pathway was involved in the improvements we have seen functionally and histologically post splachnectomy.

The ImageJ DAB analysis was undertaken nonetheless in exactly the same manner as for the other antibodies. The results are shown in Table 17. On comparing these values by means of an unpaired t test there was again no difference found in the level of staining

between the two groups. The mean percentage pixels stained was 5.442 ± 2.260 (N=6) in the CP model group compared to 6.892 ± 1.629 (N=6) in the CP model post splachnectomy group ($p=0.614$). From this we can conclude that in terms of the improvement in gastric emptying time seen post splachnectomy this does not appear to be related to any difference in levels of jagged 1 as these remain essentially the same in those animals sacrificed at 28 days post creation of our CP model and in those allowed to survive until 16 weeks that had underwent splachnectomy.



CP model from phase 1



CP model post splachnectomy

Figure 46. Comparison of duodenal specimens showing the typical staining for the anti-Jagged1 antibody in the specimens from our CP model post splachnectomy compared to the phase 1 model that did not undergo splachnectomy.

Table 17. Results of IHC analysis comparing levels of staining for anti-Jagged1 antibody between the two groups: our CP model (animals that had undergone bilateral MPFC IBA injections from phase 1 and the CP model that undergone splachnectomy i.e. Phase 2. The “%pixels” is the percentage of pixels stained in a standard x10 FOV (field of view).

CP model (from phase 1)		CP model post splachnectomy (phase 2)	
Area fraction stained (μm)	% pixels	Area fraction stained (μm)	% pixels
27609	0.88	270388	8.95
11234	0.36	90354	2.87
434027	13.8	156533	4.98
303193	9.64	87206	2.77
210640	6.71	285487	9.07
39661	1.26	399753	12.71

Discussion

4.6 Splachnectomy method

As mentioned previously our technique of splachnectomy had some initial issues with bleeding and subsequent animal loss. This however, was at the start of performing the technique on live animals and despite practising on cadavers and ensuring as mentioned at the start of this chapter that we were indeed dividing the correct nerves, it still had a steep learning curve. Once the author realised how to avoid dissecting too close to the suprarenal artery the problems encountered with bleeding stopped. Another important consideration was that the splachnectomy, as mentioned in chapter 2, were performed through an abdominal approach rather than through the thorax in humans. This was due to the variation in anatomy of the nerves in rodents compared to humans and was thought to be fortuitous as it was unlikely that such small animals would have tolerated and recovered so well from a thoracotomy versus laparotomy. Lastly, in terms of splachnectomy technique this was unilateral rather than bilateral and the reason for this was two-fold. The first being that to attempt right sided splachnectomy in such a small animal would have meant retracting and dissecting in close proximity to the liver which would have vastly increased the risk of bleeding and the subsequent rate of animal loss. Secondly and more importantly,

in the human literature, it has been widely reported that unilateral splanchnectomy is not only successful, but also less risky. For example, several papers have shown that left sided splanchnectomy alone is effective for controlling pain in patients with inoperable pancreatic cancer. (Lica, Jinescu, Pavelescu, & Beuran, 2014) (Leksowski, 2001; Masuda et al., 2014)

4.7 Study design

On reflection, there was one main issue with our study design. Instead of just having shams and our CP model undergo splanchnectomy it would have been more useful if we also had had a separate arm to the study with our CP model undergoing a “sham splanchnectomy”. At the time of designing the study it was felt to be appropriate so that the only difference between the two groups was the brain injection with neurotoxin, but a sham splanchnectomy would have meant that the histological evaluation would have been between two similar aged groups of animals e.g. in terms of measurements when looking at bowel specimens. This is an arm of the study which we could perhaps be included in future study of our model.

4.8 Gastric emptying studies

We had two main findings in phase 2 of our study, the first being that yet again, as in phase 1, our CP model works. We have demonstrated that a further group of day 5-7 old neonatal rat pups that undergo bilateral MPFC IBA injections have delayed gastric emptying. Secondly, we have shown that unilateral splanchnectomy reverses this delay and brings gastric emptying time back to normal. This importantly reflects what we have seen in clinical practice and proves our hypothesis that the delay in gastric emptying in our CP model is a result of sympathetic overdrive and can be corrected. We have also shown that shams i.e. those that underwent normal saline injections into their MPFC had normal gastric emptying times, but this was further reduced following splanchnectomy. This is an interesting finding as it is not something we as paediatric surgeons have come across as we have not performed splanchnectomy on children who are otherwise well. As mentioned above splanchnectomy is performed in adult practice for patients with chronic pancreatitis or pancreatic malignancy as a means of controlling pain. On reviewing the literature, however, there are no reports to the authors knowledge of enhanced or prompter gastric emptying leading to symptoms in such patients and, therefore, this may indeed occur but

may not have been studied or reported before. It may simply be a reflection of the fact that regardless of the reason why splanchnic nerves are divided it decreases emptying time even if that GET was previously normal. We do not think this affects our finding that splanchnectomy improves GET in our CP model, other than being of academic interest the only other point this result adds is that we were consistent in dividing the splanchnic nerves regardless of the group of animals operated on.

4.9 Histological changes post splanchnectomy

When first reviewing the microscopic appearances of the foregut specimens in the post splanchnectomy group the appearance of taller wider more bifid villi seen in the original phase 1 CP model specimens seemed to improve. The specimens from the post splanchnectomy group looked more like the original sham specimens from phase 1. This, however, was difficult to quantify as measurements of the villous architecture were not comparable due to the animals different age and size as discussed above and also it is difficult to rule out that some of the improvements seen were simply related to the passage of time. It may be that if the original phase 1 CP model animals had been kept on study for longer i.e. that some of the histological changes may have been temporary and have disappeared with time. Two points, that go against this are that splanchnectomy not only improved the gastric emptying time of our CP model but also of our sham group, showing that its functional effect was real. Also, whilst the appearances of the villous architecture were difficult to quantify other histological changes were noteworthy post splanchnectomy for example a statistically significant increase in the number of submucosal neurons seen in a field of view (FOV) at magnification x40 when we compared duodenal specimens from the CP model post splanchnectomy model to the original shams. It could be argued therefore that the only possible mechanism we have found that could explain the improvement in gastric emptying time is an increase in submucosal neurons and increase and improved organisation in the number of deep muscular plexus interstitial cells of Cajal (DMP-ICC). Splanchnectomy also appeared to have an anti-inflammatory effect or some effect on the immune response seen in the foregut as the total number of lymphocytes also returned to a level similar to the shams and the total number of eosinophils was significantly reduced. There was also a significant reduction in the number or overall percentage of bifid villi. This may suggest that the previous changes seen in our CP model may have had some inflammatory component but it is still not clear exactly what caused the changes seen previously some of which appear to be reversed post splanchnectomy.

4.9.1 Immunohistochemistry post splanchnectomy

As mentioned above there was no significant difference found in any of the three antibodies: iNOS, ChAT or jagged1 between the original CP model animals from phase 1 and our CP model post splanchnectomy. The anti-human CD117, however, did show an increase in numbers of DMP-ICC and apparent increase in their regularity and organisation as shown in Figure 43. As discussed in chapter one several papers have shown that in biopsies from the antrum and pylorus of gastroparesis patients the numbers of ICC are reduced and there were also increased signs of inflammatory change. (Harbersen et al., 2010) Bashashati and McCallum 2015). This reduction in ICC numbers leading to intestinal dysfunction has now become known as “Cajalopathy”. It could be concluded from our findings that foregut dysmotility in our CP rodent model could indeed be part of the spectrum of “Cajalopathy”. This also something that has been recognised in post spinal cord injury patients who have neuropathic bowel and dysmotility and it is has been suggested that new treatments may be found by targeting various ion channels that smooth muscle and ICC cells rely on to function properly. New treatments could potentially then promote normal peristalsis.(Radulovic, Anand, Korsten, & Gong, 2015) It may be that a reduction in number and organisation of ICC is involved in the pathogenesis of impaired motility in patients with cerebral palsy and that splanchnectomy can reverse this. As already mentioned in chapter 3 we know that ICC networks are damaged in the presence of inflammation and that this effect is temporary. (Bettolli et al., 2012) We have shown that splanchnectomy appears to have an anti-inflammatory effect and that this may allow the ICC network to recover and allow gastric emptying times and foregut motility to improve and return to normal.

4.9.2 Conclusions

As stated in chapter one the aim of phase 2 of the study was two-fold. Firstly, to show that splanchnectomy performed on our now established animal CP model would improve gastric emptying and enteric motility. Secondly to attempt to explain the clinical improvements we have seen by examining the animals functionally after splanchnectomy and histologically. We have succeeded in completing both of these objectives. In chapter 3 or phase 1 of the study we managed to link cortical lesions in the brain to functional and structural changes in the foregut. Whereas now we have gone one step further, and have shown that splanchnectomy can reverse the delay in gastric emptying time and also some of the histologically changes seen.

We have also shown that splachnectomy improves the number and organisation of the interstitial cells of Cajal network in the deep muscular plexus of the duodenum previously found to be reduced in our CP model. In addition, we found that splachnectomy increased the number of submucosal neurons and decreased the number of inflammatory cells in the duodenum. Further work is needed to explore the mechanistic pathways behind this. We hope further study of this model may provide greater insight into the pathogenesis of dysmotility associated with cerebral palsy and may help develop new treatments for this challenging group of patients.

Chapter 5

Results – Phase 3

As stated in chapter 1 the specific aim of this final phase of the study was to review a recent cohort of patients with CP who have known foregut dysmotility and to perform a retrograde analysis of archived human pathology specimens from these patients to see if we can identify any similarities histologically between these and our established animal CP model. As discussed in chapter 3 we found when establishing our CP model changes in the duodenum namely villous width and height and thickness of the submucosa were all significantly increased in our CP model i.e. bilateral MPFC IBA injection. Other results comparisons were approaching significance including decreased number of submucosal neurons and increased number of bifid villi. In addition, the thickness of the longitudinal muscle was raised as was the number of eosinophils but this was not significant. The question we wanted to try and answer in this chapter was: are such changes seen in clinical practice? It is important to state that duodenal biopsies are not routinely biopsied in such children, and when they are taken a prism such as the scoring tool described in chapter 2 would not be implemented in the clinical setting; such in detail comparison is only really reserved for research purposes.

5.1 Patient series

Twenty-one patients were identified from the paediatric gastroenterology database of CP patients with known foregut dysmotility, eight female and thirteen male. Of the twenty-one patients with this diagnosis only ten had previously undergone duodenal biopsies. Of these ten patients the ages ranged from 1.08 years to 18.17 years with a median age of 5.88 years. Symptoms included feed intolerance, vomiting, retching, faltering weight and intermittent abdominal distention and abdominal pain. All patients had undergone upper gastrointestinal contrasts and 8 had undergone gastric emptying studies by means of scintigraphy as described in chapter one. In terms of previous surgery, 5 had undergone fundoplication, 6 had a gastrostomy, 4 had a jejunostomy and 2 had undergone other procedures such as exploratory laparotomy. This series of patients are somewhat similar to

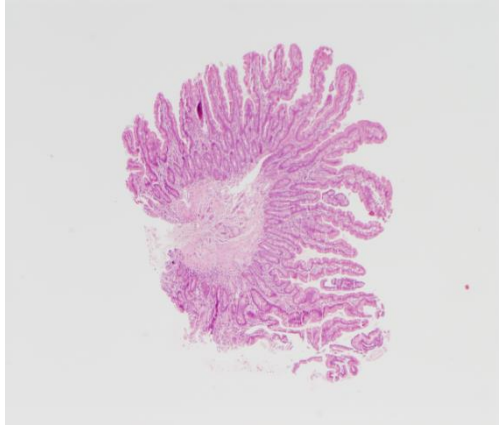
the original patient series discussed in chapter 1. None of these patients, however, had undergone celiac plexus blockade or thoracic splanchnectomy.

5.2 Retrograde histological examination of archived human biopsies

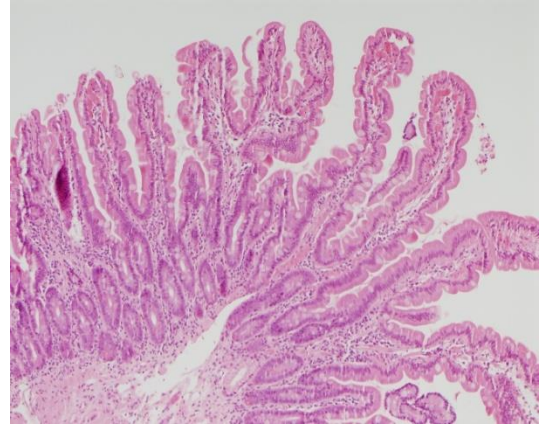
Having obtained ethical approval from our local biorepository laboratory all ten sets of HE slides were retrieved and analysed jointly with a paediatric pathologist. From the outset, it became clear the using the same scoring tool as described in chapter 2 and 3 would not be possible as the biopsies taken from paediatric patients were taken endoscopically and were not designed to be analysed for research purposes. This of course meant that the biopsies were not full thickness and were not orientated specimens. This meant that consistently counting and measuring villi was not possible and also that whilst we could often see and spot some neurons we could not always identify submucosa, let alone, any muscularis. Despite this we did manage to identify some bifid villi (see Figure 46 A-E) although it was not possible to reliably work out a percentage as not all biopsies had complete villi to calculate a denominator. We were also able to examine the width of some villi, which did in some samples seem short and thickened, but again as we could not reliably identify all villi or calculate a denominator as this was difficult to quantify. Some slides also showed evidence of inflammation with increased eosinophils and lymphocytes within the lamina propria. (Figure 47)

As discussed in chapter one there is a new endoscopic technique known as “gEMB” or gastric endoscopic muscle biopsy that allows an endoscopic biopsy that included not just submucosa but also the intermuscular layer allowing examination of muscle and neurons and importantly the interstitial cells of Cajal (ICCs). This may allow a non-invasive and safe way to look for abnormalities of the enteric nervous and so called “Cajalopathy”. (Rajan et al., 2016) It is perhaps a technique we could employ in the future in our clinical practice, but at present is not available or practised at our institution. There are a few select cases of patients with cerebral palsy and foregut dysmotility who undergo formal jejunostomy with a roux-en-Y loop which results in a small amount of full-thickness small bowel being sent routinely for histopathological examination. Unfortunately, no ethical approval was granted to examine full thickness biopsies from such patients or to perform any immunohistochemistry. If this was granted future work could examine both the number of interstitial cells of Cajal and compare specimens to a group of controls. We

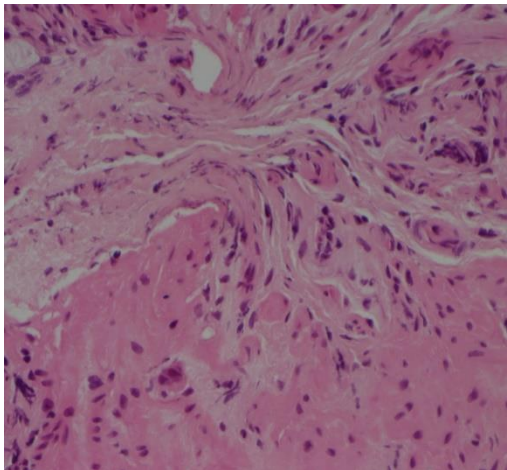
could also examine levels of iNOS and jagged1 to see if there were any other similarities between our human patients and our rodent CP model.



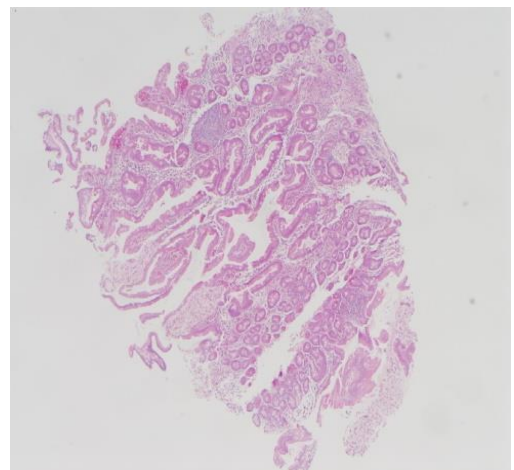
Patient 1 – x10 FOV –
showing an example of a bifid villi



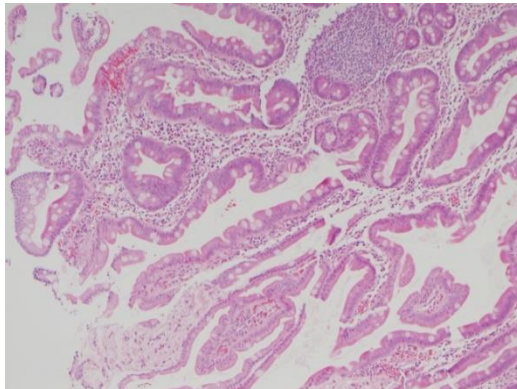
Patient 1 – x20 FOV –
showing evidence of inflammation



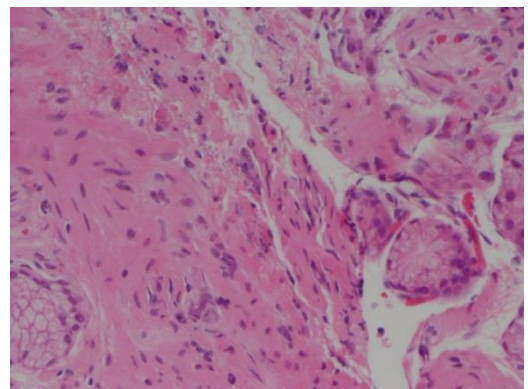
Patient 1 – x40 FOV –
3 submucosal neurons seen with evidence of
inflammatory cells.



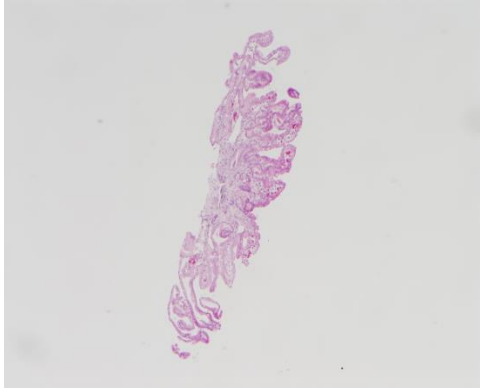
Patient 2 – x10 FOV –
superficial biopsy with few complete villi



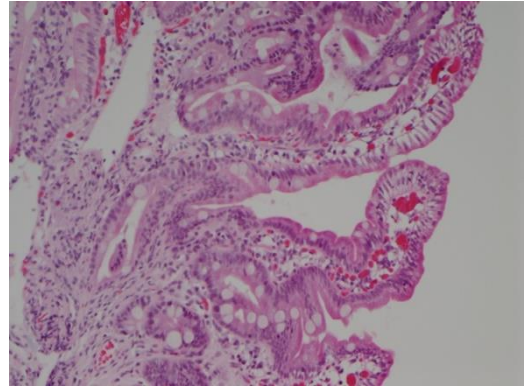
Patient 2 – x20 FOV –
some evidence of inflammation



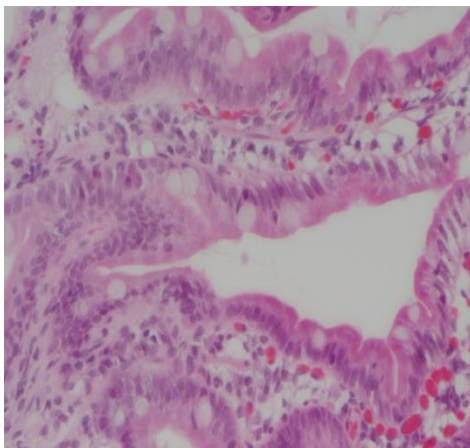
Patient 2 – x40 FOV –
again some inflammatory cells and 2 neurons



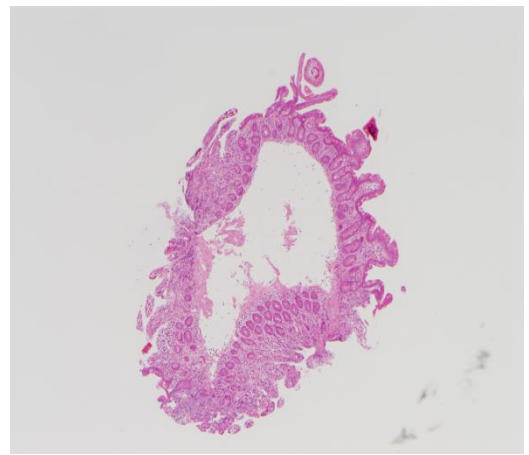
Patient 3 – x10 FOV –
superficial biopsy, some wider flatter villi



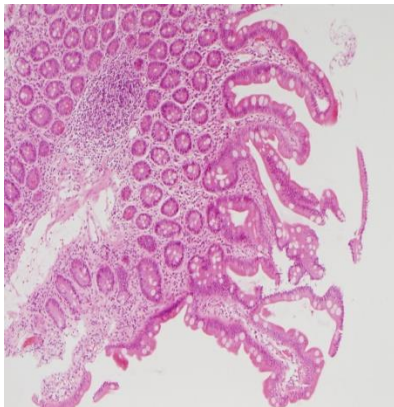Patient 3 – x20 FOV –
some evidence of inflammatory cells in the
lamina propria



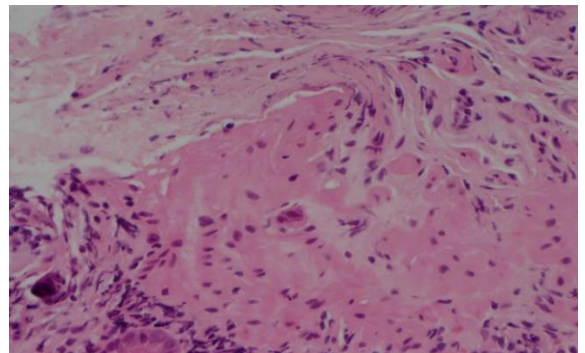
Patient 3 – x40 FOV –
inflammatory cells in the lamina propria.



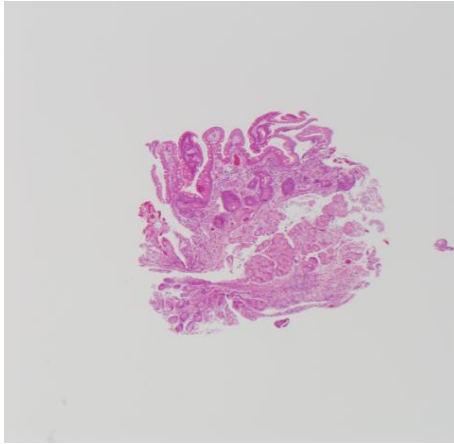
Patient 4 – x10 FOV –
superficial biopsy, but possible bifid villi



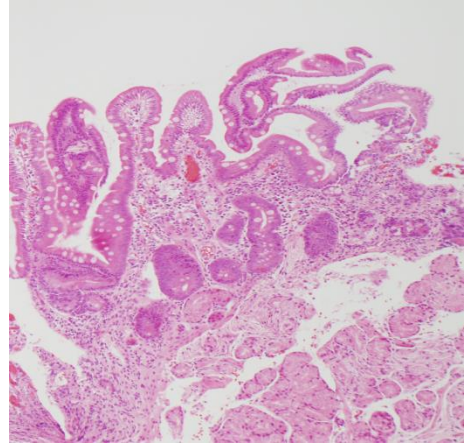
Patient 4 – x20 FOV –
possible increased crypt height



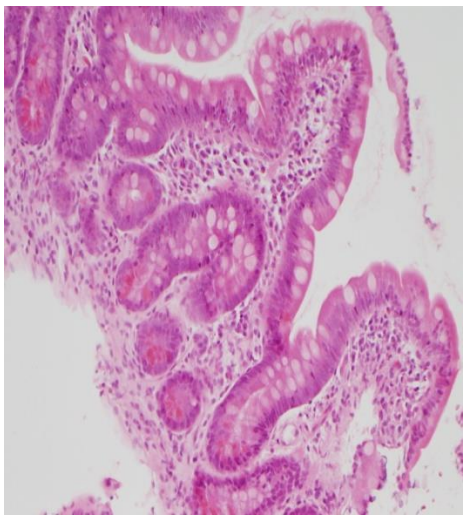
Patient 4 – x40 FOV –
inflammatory cells



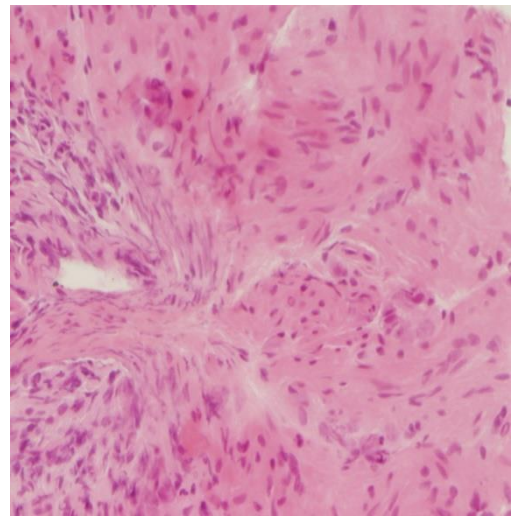
Patient 5 – x10 FOV –
very small superficial biopsy



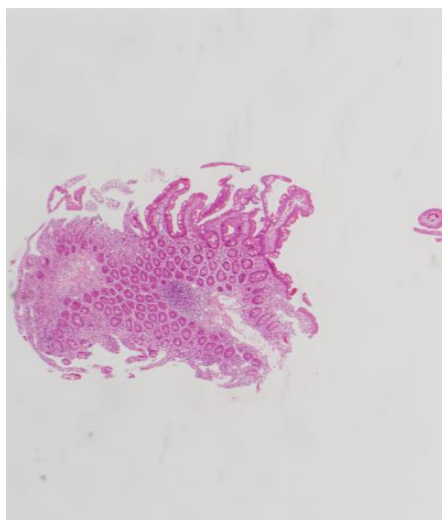
Patient 5 – x20 FOV –
possible widened bifid villi



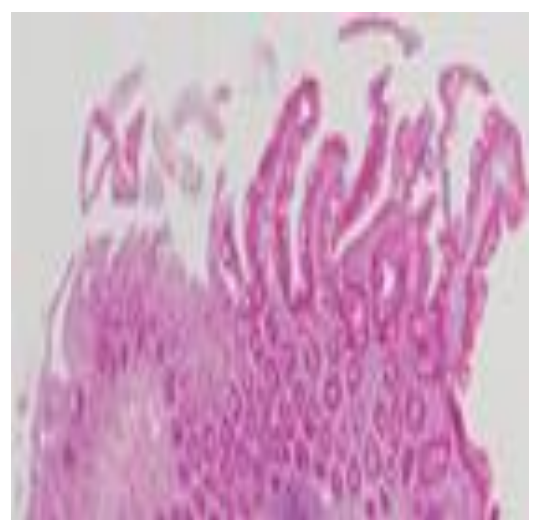
Patient 6 – x20 FOV –
widened villi with inflammatory cells
within the lamina propria



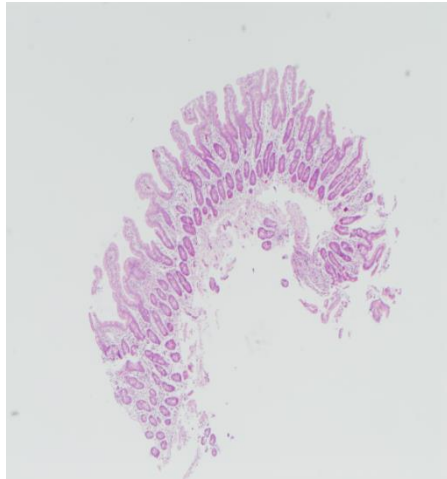
Patient 6 – x40 FOV –
9 submucosal neurons seen



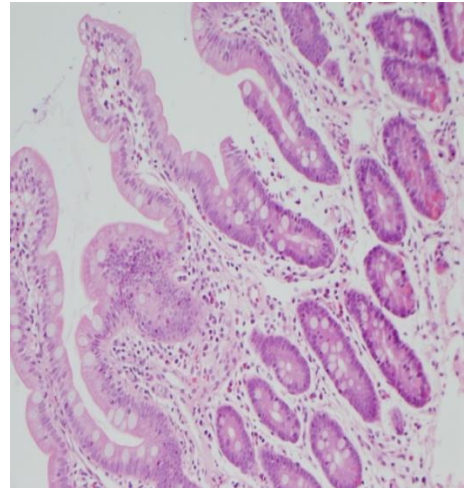
Patient 7 – x10 FOV –
irregular biopsy with only few villi



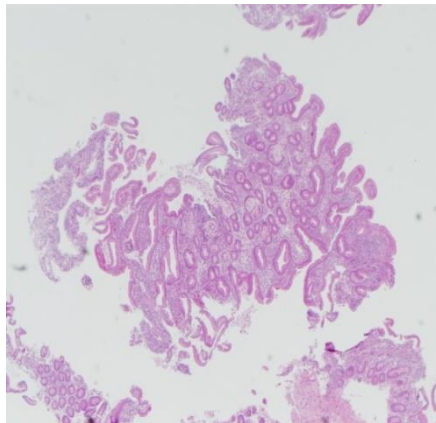
Patient 7 – x20 FOV –
possible increased crypt height



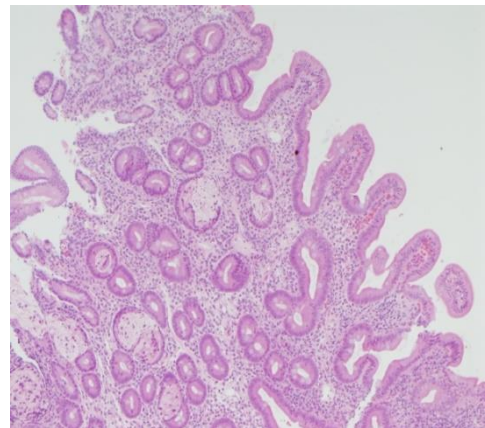
Patient 8 – x10 FOV –
more villi in this specimen some of which appear
wider and bifid in form



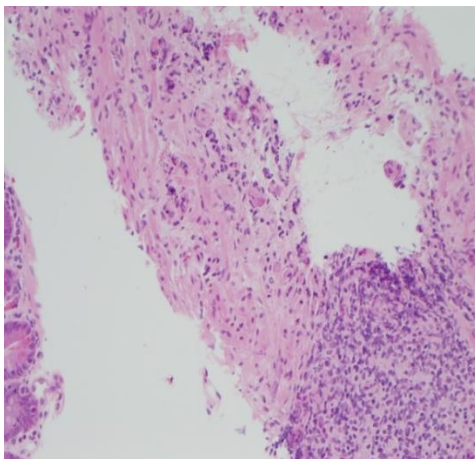
Patient 8 – x20 FOV –
evidence of inflammatory change between the crypts
and with the lamina propria



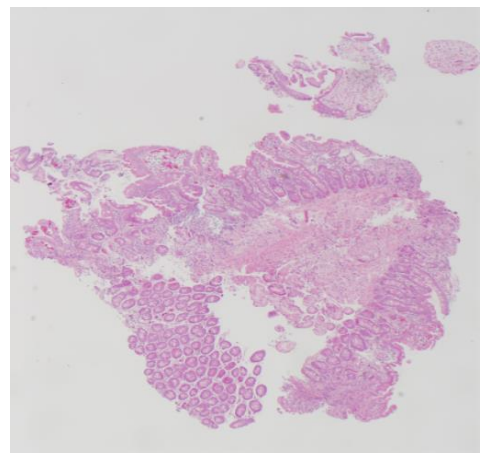
Patient 9 – x10 FOV –
very superficial biopsy



Patient 9 – x20 FOV –
some broader more bifid villi seen.



Patient 9 – x40 FOV –
inflammatory cells and submucosal neurons seen



Patient 10 – x10 FOV –
incomplete villi and some crypts with inflammatory cells.

Figure 47. Microphotographs showing duodenal endoscopic biopsies from patients with known CP, delayed gastric emptying and foregut dysmotility. FOV = field of view

5.3 Discussion

As stated at the start of this chapter the specific aim of this final phase of the study was to review a recent cohort of patients with CP who have known foregut dysmotility and to perform a retrograde analysis of archived human pathology specimens from these patients to see if we can identify any similarities histologically between these and our established animal CP model. Unfortunately, this was not successful as only endoscopic biopsies were available for review not full thickness biopsies. Even endoscopic biopsies are not routine in patients with cerebral palsy hence the small numbers we identified. As these biopsies were very small and superficial it rendered true comparison with our rodent CP model near to impossible. We looked at getting ethical approval to compare endoscopic biopsies of normal controls but this was not possible in the time frame of our study. We also did not have ethical approval to perform immunohistochemistry on these archived samples; however, it would have been difficult to make conclusions from this given the superficial nature of the biopsies available. These results are disappointing but it was important to at least try to examine human biopsies from CP patient to investigate whether a link could be made to our rodent CP model. The major difficulty is that this was a retrograde analysis of biopsies that were taken for clinical purposes not for research.

Direct comparison even if we had full thickness biopsies from this most recent cohort would also be difficult as these children are on various treatments such as the medications mentioned in chapter one including domperidone etc. Many of them have also undergone surgical procedures such as fundoplication, gastrostomy, jejunal feeding etc. Whilst many of these treatments having varying often poor success rates they may well influence the appearance of their duodenal specimens. Again, in retrospect what we ideally would have required would have been full thickness biopsies from children known to have CP and foregut dysmotility who had not had previous surgery or been on treatment that might influence the biopsies. In essence, this would not be possible or ethical as even we had access to the gEMB method of taking biopsies it is unlikely at present that such children would not have had surgery such as fundoplication or jejunal feeding or various and multiple medications. In some ways, this failure of achieving a direct comparison which we had hoped would give further credence for our animal model instead has reaffirmed the great need for an animal model as this group of children are so difficult to study.

Of note also is the fact that no child in our most recent cohort of patients has undergone coeliac plexus block or subsequent splanchnectomy. This is due to the fact the paediatric anaesthetist who previously performed the procedure of coeliac plexus block (which if successful lead on to splanchnectomy) has retired and there is a general consensus that the evidence for the procedure is lacking. This again demonstrates the need for our rodent CP model to be further studied and highlights the importance of phase 2 of our study in which we have clearly demonstrated that splanchnectomy does work.

An important aside from going through this database is that it would appear more biopsies of not just the oesophagus and stomach but also the duodenum have been taken in recent years. The reasons for this may be two-fold. Firstly, in recent years there has been the development of a much-needed multidisciplinary complex feeding clinic at our institution for children with feeding difficulties the majority of whom are neurologically impaired. Secondly, there is increasing evidence in the literature that children with cerebral palsy are at increased risk of conditions such as eosinophilic oesophagitis (Napolis et al 2015) and possibly coeliac disease or autoimmune enteropathy potentially related to an early brain insult and a damaging or inflammatory effect on the bowel, through the gut-brain axis. (Stenberg et al 2014). Importantly, these conditions may cause symptoms similar to gastro-oesophageal reflux or antro-duodenal dysmotility and therefore, should be ruled out by routine biopsy.

In conclusion, from our limited examination of superficial endoscopic duodenal biopsies from only ten patients with known CP and foregut dysmotility it is difficult to draw any definite connection between the changes in our model and our human cohort. This may have been possible if we had had access to full thickness biopsies, controls and or tissue for immunohistochemistry, but this would be extremely difficult. All that can be concluded is that in some of our biopsies there is evidence of widened and bifid villi and there was also evidence of ongoing inflammation in places. Further, more in depth study is needed to rule in or out any true similarities or differences between our paediatric patients and our rodent CP model.

Chapter 6

Perspective and Limitations

With advancements in antenatal and neonatal care more and more children with cerebral palsy are surviving. (Babcock et al., 2009) Paediatricians have long recognized that many children with cerebral palsy have a poor quality of life because of severe retching, vomiting, and inability to tolerate feeds. (Reyes et al., 1993) There is also work by Campanozzi et al suggesting that treating feeding intolerance and improving nutrition and fat free mass that this can have a positive effect on motor function. (Campanozzi et al 2007) Despite the increasing incidence of this clinical problem there are few management options available for these children. Of those options that are available in recent years there has been increasing debate as to the safety and efficacy of each of these. For instance, there has been issues with possible serious cardiac side effects of medication such as cisapride, leading to its withdrawal (McCallum, 1991, 1996) (Mt-Isa et al., 2015) (MacLennan et al., 2010) (Hegar et al., 2009), and domperidone, leading to the need for every child to undergo an electrocardiogram and a much narrower prescribing window which can be sub therapeutic for certain children. (Drolet et al., 2000) (Rocha & Barbosa, 2005) (Djeddi et al., 2008) (Ngoenmak et al., 2016) Gastrostomy and jejunostomy tubes are also not without their issues with reports of significant and life-threatening complications such as enteric fistulas and small volvulus. (C. Esposito, 2005) (Belsha et al., 2016; Godbole et al., 2002) (Mammi P et al 2011) Fundoplication has been employed frequently in neurologically-impaired children to alleviate gastro-oesophageal reflux but there have been concerns raised that this not only treats reflux rather than foregut dysmotility and indeed that fundoplication may in fact worsen antral dysrhythmia as shown by the work of Richards et al by means of animal studies examining ferrets post-fundoplication. (Richards C et al 1998) There is now a growing consensus in the literature that foregut dysmotility is underrecognized and underdiagnosed in children who are neurologically impaired. (Werlin SL et al 2004).

As stated in chapter one, two Cochrane reviews have found no randomised controlled trials looking at how best to overcome complex feeding issues in neurologically impaired

children.(Gantasala et al., 2013))(Sleigh et al., 2004). Children with cerebral palsy are a difficult population to recruit to such trials and as such we recognised the great need for an animal model. The CP model we have created is a new animal model which whilst being based on a previously reported chemically induced model damaging the motor cortex by Chen et al, (A. Chen et al., 2008) is the first of its kind to combine a cerebral palsy model which results in delayed gastric emptying and foregut dysmotility. This type of study can be tremendously useful for providing the evidence needed to illustrate possible pathways involved in this complex condition and also for trialling and investigating possible new and much needed treatments. Here, our preliminary data demonstrates not only that our CP model is robust and reproducible but also that the foregut dysmotility seen may be related to a reduced number of interstitial cells of Cajal and reduced levels of iNOS. We have also shown changes in the villous architecture of the duodenum which appears to be related to an increased expression of the cell surface protein jagged 1. The Jagged-1/Notch-1/Hes-1 pathway is a signalling pathway which is now thought to be pivotal in deciding the fate of cells in many different organs throughout the body. In addition, it has been shown to be involved in intestinal adaptation post small bowel resection (Chen, Sun et al. 2013) and in the development and maintenance of normal villous architecture. These three changes reduced ICC and iNOS and increased jagged1 require further investigation but could potentially be targets for future treatments.

We have also demonstrated in our new CP model the same effect we have shown in a few select cases in clinical practice i.e. that splanchnectomy can reverse delay in gastric emptying. This supports our original hypothesis which was that foregut dysmotility is due to an imbalance of the sympathetic and parasympathetic autonomic nerve supply to the foregut and that splanchnectomy can be employed to redress this balance. However, this work has important limitations, which are described below.

If we consider each phase of the study in turn then there are four possible limitations to consider in first phase of our study which involved the development of our CP model. The first limitation of this phase was that there were small numbers in each of the groups of neonatal rat pups undergoing each type of unilateral or bilateral brain injection either sham or with the neurotoxin ibotenic acid. Forty-five rats were used in total in this phase but this was split between seven groups as there was 9 shams and then n=5 and n=3 respectively in the unilateral MPFC group and n=6 in the bilateral MPFC and n=6 in the unilateral and bilateral insular cortex lesioned groups. These numbers were smallest in the first groups of

animals as there was a higher rate of animal loss at the start of the study due to a steep learning curve not only on the brain injection technique in such small animals but also in their anaesthesia and successful care in the initial post-operative period.

The second limitation was that although we examined that brains and foreguts of the animals in detail at the end of phase one we did not attempt to examine the spinal cord either histologically or by means of neuronal tracer techniques for example using horse radish peroxidase. This is a technique along with others that is widely reported in the literature (Wang et al 1998) (Shin et al 2009) and could potentially have provided much needed information with regards to the brain– gut axis and potential differences between shams and our CP model. Shin et al successfully traced neurons mostly from the stomach to the nucleus tractus solitaries (NTS) in the brainstem and showed that activation of such neurons is affected by hyponatraemia and certain hormones. This is a technique the author would wish to learn and explore further as one of the first steps in further examining our new CP model.

The third limitation was our method of assessing gastric emptying by means of gavaging radio-opaque contrast and taking time-lapsed X-rays was fairly basic and crude. As in clinical practice scintigraphy would have been the gold standard, but this was not available in our research facility. Other simpler, yet useful studies would have included pressure studies within the antrum and/or oesophagus similar to the paper previously described by Vane et al with their feline model. (Vane et al., 1982) Another option would be by means of a breath test such as that used by Toti et al 2014 in their rodent model of Parkinson's disease. This study used a ^{13}C -octanoic acid breath test to show delayed gastric emptying in their model. This again is something we would consider performing on our model in the future. (Toti & Travagli, 2014)

The fourth limitation in phase one of our study was that other than gastric emptying studies and regular weights no other samples such as stool or serum were taken from the animals during the study. As stated in chapter one not only has the gut-brain axis become a major focus for clinical research over recent years, so has the human microbiome project and it would have been of interest in retrospect to investigate the microbiota and flora of the bowel in our CP models compared to controls to assess any difference between the two groups. In terms of serological tests and there are several humoral factors that we could have investigated including cytokines for example vasoactive intestinal peptide or VIP. As

mentioned in chapter five there is recent evidence in the literature that there is a potential increased risk of anti TD6 antibodies and coeliac related disease in children with cerebral palsy (Stenberg R et al 2014) (Farih-Ayed, M., et al. 2006). This is something that would be relatively easy to test for in our model in terms of analysing serum for IgA/IgG class anti-TG6 antibodies by ELISA and comparing levels between our CP model and shams. This would be of interest as in retrospect some of the appearances such as the loss of normal villous architecture in the duodenum of our CP model is reminiscent of changes often associated with coeliac disease.

The main perceived limitation of phase two of the study was the lack of an arm of the study in which a group of the CP model animals underwent midline laparotomy and sham splanchnectomy perhaps by just grasping the splanchnic nerves with forceps rather than dividing them with bipolar diathermy. This approach would have allowed a more meaningful comparison in terms of assessing gastric emptying times between a matched cohort in terms of age and size and also in evaluation difference in subsequent foregut histology. Lastly, the main limitation of phase 3 of the study was that the only duodenal human biopsies we were able to examine in a group of CP patient with known foregut dysmotility were superficial endoscopic biopsies and therefore, this greatly limited our ability examine them and look for any possible changes that were akin or in any way similar to the changes we found unexpectedly in the duodenum of our CP model.

Previous work by Richards et al in London (Richards C et al 1998 and Richards C et al 2003) showed the effect of fundoplication on ferrets. Although not a limitation of this study as it was not one of our original aims it would be a potentially important study to instead perform just splanchnectomys and sham splanchnectomys to also perform fundoplication and/or gastrostomy on our model and assess its effect as this is what is commonly performed on this group of children in clinical practice despite the fact that we cannot always be sure what effect such a procedure is having on foregut motility, which may already be abnormal and pathogenic.

Despite all the limitations discussed above this is still an important and much needed piece of work which has for the first time created a rodent model of cerebral palsy which demonstrates delayed gastric emptying and makes some attempt to explain the possible mechanistic pathways behind this. Not only have we successfully linked cortical lesions in the brain, similar to periventricular leukomalacia seen in cerebral palsy, to functional and

structural changes in the foregut we have also shown that splanchnectomy can reverse the delay in gastric emptying time. This provides further evidence for the use of this procedure in clinical practice and has emphasised the lack and need for clinical trials. Further work is needed to explore the pathways behind both our new CP model and the improvements seen following splanchnectomy. It is the authors hope that further study of this model may provide greater insight into the pathogenesis of dysmotility associated with cerebral palsy and may help develop new and much needed treatments for neurologically-impaired children. In addition to the study of this model in terms of foregut dysfunction, there is also evidence in the literature that the medial prefrontal cortex, the area targeted to create our new model, is also involved in autonomic bladder control, not just bowel. (Sakakibara et al, 2014) It may also be the case, therefore, that this model could be adopted to investigate the condition of neuropathic bladder in the future. We, therefore, speculate that this model is very exciting as it could be extremely useful for future research including possible treatments whether it be medical or surgical for foregut dysmotility in cerebral palsy as well as new treatments for different types of neuropathic bowel and potentially neuropathic bladder.

References

- Aihara, Y., Nakamura, H., Sato, A., & Simpson, A. (1978). Relations between various fiber groups of vagal and splanchnic nerves and gastric motility in rats. *Neurosci Lett*, *10*(3), 281-286.
- Aleksandrov, V. G., Bagaev, V. A., Nozdrachev, A. D., & Panteleev, S. S. (1996). Identification of gastric related neurones in the rat insular cortex. *Neurosci Lett*, *216*(1), 5-8.
- Arab, H. A., Muhammadnejad, S., Faghihi, S. M., Hassanpour, H., & Muhammadnejad, A. (2014). Effects of nitric oxide modulating activities on development of enteric nervous system mediated gut motility in chick embryo model. *J Biosci*, *39*(5), 835-848.
- Babcock, M. A., Kostova, F. V., Ferriero, D. M., Johnston, M. V., Brunstrom, J. E., Hagberg, H., & Maria, B. L. (2009). Injury to the preterm brain and cerebral palsy: clinical aspects, molecular mechanisms, unanswered questions, and future research directions. *J Child Neurol*, *24*(9), 1064-1084. doi:10.1177/0883073809338957
- Baburamani, A. A., Supramaniam, V. G., Hagberg, H., & Mallard, C. (2014). Microglia toxicity in preterm brain injury. *Reprod Toxicol*, *48*, 106-112. doi:10.1016/j.reprotox.2014.04.002
- Back, S. A. and S. A. Rivkees (2004). "Emerging concepts in periventricular white matter injury." *Semin Perinatol* **28**(6): 405-414.
- Bagaev, V., & Aleksandrov, V. (2006). Visceral-related area in the rat insular cortex. *Auton Neurosci*, *125*(1-2), 16-21. doi:10.1016/j.autneu.2006.01.006
- Baghdadi, S., Abbas, M. H., Albouz, F., & Ammori, B. J. (2008). Systematic review of the role of thoracoscopic splanchnicectomy in palliating the pain of patients with chronic pancreatitis. *Surg Endosc*, *22*(3), 580-588. doi:10.1007/s00464-007-9730-x
- Bashashati, M., & McCallum, R. W. (2015a). Is Interstitial Cells of Cajalopathy Present in Gastroparesis? *J Neurogastroenterol Motil*, *21*(4), 486-493. doi:10.5056/jnm15075
- Bashashati, M., & McCallum, R. W. (2015b). Motility: Is 'ICC-opathy' present in gastroparesis-like syndrome? *Nat Rev Gastroenterol Hepatol*, *12*(7), 375-376. doi:10.1038/nrgastro.2015.96
- Baud, O., Daire, J. L., Dalmaz, Y., Fontaine, R. H., Krueger, R. C., Sebag, G., . . . Verney, C. (2004). Gestational hypoxia induces white matter damage in neonatal rats: a new model of periventricular leukomalacia. *Brain Pathol*, *14*(1), 1-10.
- Belsha, D., Thomson, M., Dass, D. R., Lindley, R., & Marven, S. (2016). Assessment of the safety and efficacy of percutaneous laparoscopic endoscopic jejunostomy (PLEJ). *J Pediatr Surg*, *51*(3), 513-518. doi:10.1016/j.jpedsurg.2015.11.023
- Bettolli, M., C. De Carli, D. Cornejo-Palma, K. Jolin-Dahel, X. Y. Wang, J. Huizinga, A. Krantis, S. Rubin and W. A. Staines (2012). "Interstitial cell of Cajal loss correlates with the degree of inflammation in the human appendix and reverses after inflammation." *J Pediatr Surg* *47*(10): 1891-1899.
- Borre, Y. E., O'Keeffe, G. W., Clarke, G., Stanton, C., Dinan, T. G., & Cryan, J. F. (2014). Microbiota and neurodevelopmental windows: implications for brain disorders. *Trends Mol Med*, *20*(9), 509-518. doi:10.1016/j.molmed.2014.05.002

References

- Bredenoord, A. J., Fox, M., Kahrilas, P. J., Pandolfino, J. E., Schwizer, W., Smout, A. J., & International High Resolution Manometry Working, G. (2012). Chicago classification criteria of esophageal motility disorders defined in high resolution esophageal pressure topography. *Neurogastroenterol Motil*, *24 Suppl 1*, 57-65. doi:10.1111/j.1365-2982.2011.01834.x
- Budgell, B., & Suzuki, A. (2000). Inhibition of gastric motility by noxious chemical stimulation of interspinous tissues in the rat. *J Auton Nerv Syst*, *80*(3), 162-168.
- Bueno, L., Praddaude, F., & Ruckebusch, Y. (1979). Propagation of electrical spiking activity along the small intestine: intrinsic versus extrinsic neural influences. *J Physiol*, *292*, 15-26.
- Burns, A. J., & Pachnis, V. (2009). Development of the enteric nervous system: bringing together cells, signals and genes. *Neurogastroenterol Motil*, *21*(2), 100-102. doi:10.1111/j.1365-2982.2008.01255.x
- Burns, A. J., Roberts, R. R., Bornstein, J. C., & Young, H. M. (2009). Development of the enteric nervous system and its role in intestinal motility during fetal and early postnatal stages. *Semin Pediatr Surg*, *18*(4), 196-205. doi:10.1053/j.sempedsurg.2009.07.001
- Burns, A. J., & Thapar, N. (2014). Neural stem cell therapies for enteric nervous system disorders. *Nat Rev Gastroenterol Hepatol*, *11*(5), 317-328. doi:10.1038/nrgastro.2013.226
- Buscher, H. C. (2002). Long-term results of bilateral thoracoscopic splanchnectomy in patients with chronic pancreatitis. *British Journal of surgery*. *89*(2):158–162
- Buts, J. P., Barudi, C., & Otte, J. B. (1987). Double-blind controlled study on the efficacy of sodium alginate (Gaviscon) in reducing gastroesophageal reflux assessed by 24 h continuous pH monitoring in infants and children. *Eur J Pediatr*, *146*(2), 156-158.
- Buts, J. P., & Leclercq, V. (1987). Gaviscon and gastroesophageal reflux in children. *J Pediatr Gastroenterol Nutr*, *6*(3), 482-483.
- Cajal SR. (1911) Histologie du Système Nerveux de L'homme et des Vertébrés. Paris: Maloine. *Histologie du Système Nerveux*. Translated by L. Azoulay. Madrid.
- Cailotto, C., Gomez-Pinilla, P. J., Costes, L. M., van der Vliet, J., Di Giovangiulio, M., Nemethova, A., . . . Boeckxstaens, G. E. (2014). Neuro-anatomical evidence indicating indirect modulation of macrophages by vagal efferents in the intestine but not in the spleen. *PLoS One*, *9*(1), e87785. doi:10.1371/journal.pone.0087785
- Campanozzi, A., et al. (2007). "Impact of malnutrition on gastrointestinal disorders and gross motor abilities in children with cerebral palsy." *Brain Dev* *29*(1): 25-29.
- Carachi, R., Agarwala, S., Bradnock, T. J., (2013) Basic Techniques in Pediatric Surgery: An Operative Manual Springer Berlin Heidelberg pages 270-272
- Carachi, R., Currie, J. M., & Steven, M. (2009). New tools in the treatment of motility disorders in children. *Semin Pediatr Surg*, *18*(4), 274-277. doi:10.1053/j.sempedsurg.2009.07.009
- Carlson, G. M., Bedi, B. S., & Code, C. F. (1972). Mechanism of propagation of intestinal interdigestive myoelectric complex. *Am J Physiol*, *222*(4), 1027-1030.
- Chen, A., Dimambro, N., & Clowry, G. J. (2008). A comparison of behavioural and histological outcomes of periventricular injection of ibotenic acid in neonatal rats at postnatal days 5 and 7. *Brain Res*, *1201*, 187-195. doi:10.1016/j.brainres.2008.01.066

References

- Chen, G., Sun, L., Yu, M., Meng, D., Wang, W., Yang, Y., & Yang, H. (2013). The Jagged-1/Notch-1/Hes-1 pathway is involved in intestinal adaptation in a massive small bowel resection rat model. *Dig Dis Sci*, 58(9), 2478-2486. doi:10.1007/s10620-013-2680-3
- Chicella, M. F., Batres, L. A., Heesters, M. S., & Dice, J. E. (2005). Prokinetic drug therapy in children: a review of current options. *Ann Pharmacother*, 39(4), 706-711. doi:10.1345/aph.1E411
- Chiou, W. F., C. F. Chen and J. J. Lin (2000). "Mechanisms of suppression of inducible nitric oxide synthase (iNOS) expression in RAW 264.7 cells by andrographolide." *Br J Pharmacol* 129(8): 1553-1560.
- Clowry, G. J. (2000). The successful use of fentanyl/fluanisone ('Hypnorm') as an anaesthetic for intracranial surgery in neonatal rats. *Laboratory Animals*, 34(3):260-4
- Code, C. F., & Pickard, D. W. (1973). The importance of the lymphatic system in the absorption of water from the intestine. *J Physiol*, 231(1), 40P-41P.
- Cohen, S., Bueno de Mesquita, M., & Mimouni, F. B. (2015). Adverse effects reported in the use of gastroesophageal reflux disease treatments in children: a 10 years literature review. *Br J Clin Pharmacol*, 80(2), 200-208. doi:10.1111/bcp.12619
- Colletti, R. B., Christie, D. L., & Orenstein, S. R. (1995). Statement of the North American Society for Pediatric Gastroenterology and Nutrition (NASPGN). Indications for pediatric esophageal pH monitoring. *J Pediatr Gastroenterol Nutr*, 21(3), 253-262.
- Cornwell, G. G., 3rd, & Killenberg, P. G. (1965). The Effects of a Low-Fat, Low-Calorie Synthetic Nutrient (Metrecal) on Gastric Secretion and Emptying in Man. *Am J Dig Dis*, 10, 22-30.
- Cucchiara, S., Minella, R., Scoppa, A., Emiliano, M., Calabrese, F., Az-Zeqeh, N., . . . Salvia, G. (1997). Antroduodenal motor effects of intravenous erythromycin in children with abnormalities of gastrointestinal motility. *J Pediatr Gastroenterol Nutr*, 24(4), 411-418.
- Curry, J. I., Lander, T. D., & Stringer, M. D. (2001). Review article: erythromycin as a prokinetic agent in infants and children. *Aliment Pharmacol Ther*, 15(5), 595-603.
- Cuschieri, A., Shimi, S. M., Crosthwaite, G., & Joypaul, V. (1994). Bilateral endoscopic splanchnicectomy through a posterior thoracoscopic approach. *J R Coll Surg Edinb*, 39(1), 44-47.
- Dall'Olmo, L., Fassin, M., Dassie, E., Scarpa, M., Realdon, S., Cavallin, F., . . . Castoro, C. (2014) Role of proton pump inhibitor on esophageal carcinogenesis and pancreatic acinar cell metaplasia development: an experimental in vivo study, *PLoS One* 9(11): e112862
- Damsch, S., et al. (2011). "Gavage-related reflux in rats: identification, pathogenesis, and toxicological implications (review)." *Toxicol Pathol* 39(2): 348-360.
- Damsch, S., et al. (2011). "Unexpected nasal changes in rats related to reflux after gavage dosing." *Toxicol Pathol* 39(2): 337-347.
- Day, M. J., Bilzer, T., Mansell, J., Wilcock, B., Hall, E. J., Jergens, A., . . . World Small Animal Veterinary Association Gastrointestinal Standardization, G. (2008). Histopathological standards for the diagnosis of gastrointestinal inflammation in endoscopic biopsy samples from the dog and cat: a report from the World Small Animal Veterinary Association Gastrointestinal Standardization Group. *J Comp Pathol*, 138 Suppl 1, S1-43. doi:10.1016/j.jcpa.2008.01.001

References

- Del Buono, R., Wenzl, T. G., Rawat, D., & Thomson, M. (2006). Acid and nonacid gastro-oesophageal reflux in neurologically impaired children: investigation with the multiple intraluminal impedance procedure. *J Pediatr Gastroenterol Nutr*, *43*(3), 331-335. doi:10.1097/01.mpg.0000232333.77805.94
- Di Lorenzo, C., & Orenstein, S. (2002). Fundoplication: friend or foe? *J Pediatr Gastroenterol Nutr*, *34*(2), 117-124.
- Djeddi, D., Kongolo, G., Lefaix, C., Mounard, J., & Leke, A. (2008). Effect of domperidone on QT interval in neonates. *J Pediatr*, *153*(5), 663-666. doi:10.1016/j.jpeds.2008.05.013
- Drolet, B., Rousseau, G., Daleau, P., Cardinal, R., & Turgeon, J. (2000). Domperidone should not be considered a no-risk alternative to cisapride in the treatment of gastrointestinal motility disorders. *Circulation*, *102*(16), 1883-1885.
- Duncan, J. R., Cock, M. L., Scheerlinck, J. P., Westcott, K. T., McLean, C., Harding, R., & Rees, S. M. (2002). White matter injury after repeated endotoxin exposure in the preterm ovine fetus. *Pediatr Res*, *52*(6), 941-949. doi:10.1203/00006450-200212000-00021
- Egnell, C., Eksborg, S., & Grahnquist, L. (2014). Jejunostomy enteral feeding in children: outcome and safety. *JPEN J Parenter Enteral Nutr*, *38*(5), 631-636. doi:10.1177/0148607113489832
- Ehrlein, H. J., & Schemann, M. (2005). Gastrointestinal motility. *Technische Universität München: Munich*.
- Englander, Z. A., Pizoli, C. E., Batrachenko, A., Sun, J., Worley, G., Mikati, M. A., . . . Song, A. W. (2013). Diffuse reduction of white matter connectivity in cerebral palsy with specific vulnerability of long range fiber tracts. *Neuroimage Clin*, *2*, 440-447. doi:10.1016/j.nicl.2013.03.006
- Ericson, J. E., Arnold, C., Cheeseman, J., Cho, J., Kaneko, S., Wilson, E., . . . Best Pharmaceuticals for Children Act-Pediatric Trials Network Administrative Core, C. (2015). Use and Safety of Erythromycin and Metoclopramide in Hospitalized Infants. *J Pediatr Gastroenterol Nutr*, *61*(3), 334-339. doi:10.1097/MPG.0000000000000792
- Esposito C, A. S., 2 A. Centonze,1 G. Capano,2 G. Ascione2. (2005). Laparoscopic-assisted jejunostomy. An effective procedure for the treatment of neurologically impaired children with feeding problems and gastroesophageal reflux. *Surg Endosc*, *19*: , 501–504.
- Esposito, C., Alicchio, F., Escolino, M., Ascione, G., & Settimi, A. (2013). [Laparoscopy-assisted jejunostomy in neurological patients with chronic malnutrition and GERD. Technical considerations and analysis of the results]. *Pediatr Med Chir*, *35*(3), 125-129. doi:10.4081/pmc.2013.45
- Esposito, C., Montupet, P., van Der Zee, D., Settimi, A., Paye-Jaouen, A., Centonze, A., & Bax, N. K. (2006). Long-term outcome of laparoscopic Nissen, Toupet, and Thal antireflux procedures for neurologically normal children with gastroesophageal reflux disease. *Surg Endosc*, *20*(6), 855-858. doi:10.1007/s00464-005-0501-2
- Esposito, C., Van Der Zee, D. C., Settimi, A., Doldo, P., Staiano, A., & Bax, N. M. (2003). Risks and benefits of surgical management of gastroesophageal reflux in neurologically impaired children. *Surg Endosc*, *17*(5), 708-710. doi:10.1007/s00464-002-9170-6
- Faure, S., J. McKey, S. Sagnol and P. de Santa Barbara (2015). "Enteric neural crest cells regulate vertebrate stomach patterning and differentiation." *Development* **142**(2): 331-342.

References

Flecknell (2015) *Laboratory Animal Anaesthesia*, 4th edition, Elsevier

- Follett, P. L., Deng, W., Dai, W., Talos, D. M., Massillon, L. J., Rosenberg, P. A., . . . Jensen, F. E. (2004). Glutamate receptor-mediated oligodendrocyte toxicity in periventricular leukomalacia: a protective role for topiramate. *J Neurosci*, 24(18), 4412-4420. doi:10.1523/JNEUROSCI.0477-04.2004
- Forsythe, P., & Kunze, W. A. (2013). Voices from within: gut microbes and the CNS. *Cell Mol Life Sci*, 70(1), 55-69. doi:10.1007/s00018-012-1028-z
- Franco, V. H., Collares, E. F., & Troncon, L. E. (1985). Gastric emptying in children. III. Study on marasmic protein-calorie malnutrition. *Arq Gastroenterol*, 22(2), 88-92.
- Freud S (1897) Die infantile Cerebrallähmung. In: Nothnagel H (ed.) *Spezielle Pathologie und Therapie*, pp. 1–327. Wien, Austria: Alfred Hölder.
- Frih-Ayed, M. Boughammoura-Bouatay, A. Fitouri, F. Chebel, S. (2006) Coeliac disease an spastic paraplegia. *Rev Neurol (Paris)* 162 (5): 648-50
- Fujitsuka, N., Asakawa, A., Amitani, H., Fujimiya, M., & Inui, A. (2012). Ghrelin and gastrointestinal movement. *Methods Enzymol*, 514, 289-301. doi:10.1016/B978-0-12-381272-8.00018-0
- Fukahori, S., Asagiri, K., Ishii, S., Tanaka, Y., Kojima, S., Saikusa, N., . . . Yagi, M. (2013). Pre and post-operative evaluation of gastroesophageal reflux and esophageal motility in neurologically impaired children using combined pH-multichannel intraluminal impedance measurements. *Pediatr Surg Int*, 29(6), 545-551. doi:10.1007/s00383-013-3295-7
- Gantasala, S., Sullivan, P. B., & Thomas, A. G. (2013). Gastrostomy feeding versus oral feeding alone for children with cerebral palsy. *Cochrane Database Syst Rev*(7), CD003943. doi:10.1002/14651858.CD003943.pub3
- Gatti, C. (2000). "Is the 13C - Acetate Breath test a valid procedure to assess gastric emptying in children." *J Pediatr Surg* 35(1): 62–65
- Giaume, C., F. Kirchhoff, C. Matute, A. Reichenbach and A. Verkhatsky (2007). "Glia: the fulcrum of brain diseases." *Cell Death Differ* 14(7): 1324-1335.
- Gilchrist, B. F., Luks, F. I., DeLuca, F. G., & Wesselhoeft, C. W., Jr. (1997). A modified feeding Roux-en-Y jejunostomy in the neurologically damaged child. *J Pediatr Surg*, 32(4), 588-589.
- Godbole, P., Margabanthu, G., Crabbe, D. C., Thomas, A., Puntis, J. W., Abel, G., . . . Stringer, M. D. (2002). Limitations and uses of gastrojejunal feeding tubes. *Arch Dis Child*, 86(2), 134-137.
- Goldstein, A. M., Hofstra, R. M., & Burns, A. J. (2013). Building a brain in the gut: development of the enteric nervous system. *Clin Genet*, 83(4), 307-316. doi:10.1111/cge.12054
- Goyal, A., Khalil, B., Choo, K., Mohammed, K., & Jones, M. (2005). Esophagogastric dissociation in the neurologically impaired: an alternative to fundoplication? *J Pediatr Surg*, 40(6), 915-918; discussion 918-919. doi:10.1016/j.jpedsurg.2005.03.004
- Graham, D. Y. Genta, R. M. (2008) Long-term proton pump inhibitor use and gastrointestinal cancer. *Curr Gastroenterol Rep* 10 (6):543-7

References

- Grant, C. (2001). Can pH monitoring reliably detect gastro-oesophageal reflux in preterm infants? *Arch Dis Child Fetal Neonatal Ed*, 85, F155–F158.
- Groneberg, D., Lies, B., Konig, P., Jager, R., Seidler, B., Klein, S., . . . Friebe, A. (2013). Cell-specific deletion of nitric oxide-sensitive guanylyl cyclase reveals a dual pathway for nitrergic neuromuscular transmission in the murine fundus. *Gastroenterology*, 145(1), 188-196. doi:10.1053/j.gastro.2013.03.042
- Groneberg, D., Voussen, B., & Friebe, A. (2016). Integrative Control of Gastrointestinal Motility by Nitric Oxide. *Curr Med Chem*, 23(24), 2715-2735.
- Han, X., M. P. Fink, R. Yang and R. L. Delude (2004). “Increased iNOS activity is essential for intestinal epithelial tight junction dysfunction in endotoxemic mice.” *Shock* 21(3): 261-270.
- Hanani, M., G. Farrugia and T. Komuro (2005). “Intercellular coupling of interstitial cells of cajal in the digestive tract.” *Int Rev Cytol* 242: 249-282.
- Harberson, J., R. M. Thomas, S. P. Harbison and H. P. Parkman (2010). “Gastric neuromuscular pathology in gastroparesis: analysis of full-thickness antral biopsies.” *Dig Dis Sci* 55(2): 359-370.
- Hassall, E. (2005). Outcomes of fundoplication: causes for concern, newer options. *Arch Dis Child*, 90(10), 1047-1052. doi:10.1136/adc.2004.069674
- Hegar, B., Alatas, S., Advani, N., Firmansyah, A., & Vandenplas, Y. (2009). Domperidone versus cisapride in the treatment of infant regurgitation and increased acid gastro-oesophageal reflux: a pilot study. *Acta Paediatr*, 98(4), 750-755. doi:10.1111/j.1651-2227.2008.01158.x
- Herbella, F. A., Aprile, L. R., & Patti, M. G. (2014). High-resolution manometry for the evaluation of gastric motility. *Updates Surg*, 66(3), 177-181. doi:10.1007/s13304-014-0261-4
- Hinder, R. A., & Kelly, K. A. (1977). Human gastric pacesetter potential. Site of origin, spread, and response to gastric transection and proximal gastric vagotomy. *Am J Surg*, 133(1), 29-33.
- Huizinga, J. D., Thuneberg, L., Kluppel, M., Malysz, J., Mikkelsen, H. B., & Bernstein, A. (1995). W/knit gene required for interstitial cells of Cajal and for intestinal pacemaker activity. *Nature*, 373(6512), 347-349. doi:10.1038/373347a0
- Hurley-Guis KM , N. E. (1986). The Medial Frontal Cortex and Gastric Motility: Microstimulation Results and Their Possible Significance for the Overall Pattern of Organization of Rat Frontal and Parietal Cortex. *Brain Research*, 365, 241-248.
- Ihse, I., Zoucas, E., Gyllstedt, E., Lillo-Gil, R., & Andren-Sandberg, A. (1999). Bilateral thoracoscopic splanchnicectomy: effects on pancreatic pain and function. *Ann Surg*, 230(6), 785-790; discussion 790-781.
- Ito, C., Isobe, Y., Tsuchida, K., & Higuchi, S. (1996). 5-Hydroxytryptamine3 receptor and regulation of gastric emptying in rats. *Arch Int Pharmacodyn Ther*, 331(2), 203-218.
- Jensen, F. E., G. J. Gardner, A. P. Williams, P. M. Gallop, E. Aizenman and P. A. Rosenberg (1994). “The putative essential nutrient pyrroloquinoline quinone is neuroprotective in a rodent model of hypoxic/ischemic brain injury.” *Neuroscience* 62(2): 399-406.

References

- Jia, H., K. Zhang, Q. Chen, H. Gao and W. Wang (2012). "Downregulation of Notch-1/Jagged-2 in human colon tissues from Hirschsprung disease patients." *Int J Colorectal Dis* **27**(1): 37-41.
- Johnson, L. F., & Demeester, T. R. (1974). Twenty-four-hour pH monitoring of the distal esophagus. A quantitative measure of gastroesophageal reflux. *Am J Gastroenterol*, *62*(4), 325-332.
- Johnston, M. V., Ferriero, D. M., Vannucci, S. J., & Hagberg, H. (2005). Models of cerebral palsy: which ones are best? *J Child Neurol*, *20*(12), 984-987.
- Kahrilas, P. J., Bredenoord, A. J., Fox, M., Gyawali, C. P., Roman, S., Smout, A. J., . . . International High Resolution Manometry Working, G. (2015). The Chicago Classification of esophageal motility disorders, v3.0. *Neurogastroenterol Motil*, *27*(2), 160-174. doi:10.1111/nmo.12477
- Kang, C. M., Lee, H. Y., Yang, H. J., Jang, H. J., Gil, Y. C., Kim, K. S., . . . Kim, B. R. (2007). Bilateral thoracoscopic splachnicectomy with sympathectomy for managing abdominal pain in cancer patients. *Am J Surg*, *194*(1), 23-29. doi:10.1016/j.amjsurg.2006.11.018
- Kawai, M., Kawahara, H., Hirayama, S., Yoshimura, N., & Ida, S. (2004). Effect of baclofen on emesis and 24-hour esophageal pH in neurologically impaired children with gastroesophageal reflux disease. *J Pediatr Gastroenterol Nutr*, *38*(3), 317-323.
- Khelif, K., Scaillon, M., Govaerts, M. J., Vanderwinden, J. M., & De Laet, M. H. (2006). Bilateral thoracoscopic splachnicectomy in chronic intestinal pseudo-obstruction: report of two paediatric cases. *Gut*, *55*(2), 293-294. doi:10.1136/gut.2005.082024
- Kim, H. M., Choi, J. S., & Cho, J. H. (2014). A pilot trial of ambulatory monitoring of gastric motility using a modified magnetic capsule endoscope. *J Neurogastroenterol Motil*, *20*(2), 261-264. doi:10.5056/jnm.2014.20.2.261
- Kochar N, Chandewal A, Bakal R and Kochar P. (2011) *Int. J. Pharm.* **7** (1):31-39
- Komura, M., Kanamori, Y., Tanaka, Y., Kodaka, T., Sugiyama, M., Terawaki, K., . . . Iwanaka, T. (2016). Mosapride for gastroesophageal reflux disease in neurologically impaired patients. *Pediatr Int*. doi:10.1111/ped.13144
- Komuro, T. (2006). "Structure and organization of interstitial cells of Cajal in the gastrointestinal tract." *J Physiol* **576**(Pt 3): 653-658.
- Korzeniewski SJ, M., MA, Gretchen Birbeck, MD, MPH., & Mark C. DeLano, M., Michael J. Potchen, MD, and Nigel Paneth, MD, MPH. A Systematic Review of Neuroimaging for Cerebral Palsy. *Journal of Child Neurology*, *23*(2), 216-227.
- Kuban, K. C., Allred, E. N., O'Shea, M., Paneth, N., Pagano, M., Leviton, A., & Group, E. S. C. P.-A. (2008). An algorithm for identifying and classifying cerebral palsy in young children. *J Pediatr*, *153*(4), 466-472. doi:10.1016/j.jpeds.2008.04.013
- Kuban, K. C., O'Shea, T. M., Allred, E. N., Paneth, N., Hirtz, D., Fichorova, R. N., . . . Investigators, E. S. (2014). Systemic inflammation and cerebral palsy risk in extremely preterm infants. *J Child Neurol*, *29*(12), 1692-1698. doi:10.1177/0883073813513335

References

- Kwiatek, M. A., Menne, D., Steingoetter, A., Goetze, O., Forras-Kaufman, Z., Kaufman, E., . . . Fox, M. R. (2009). Effect of meal volume and calorie load on postprandial gastric function and emptying: studies under physiological conditions by combined fiber-optic pressure measurement and MRI. *Am J Physiol Gastrointest Liver Physiol*, 297(5), G894-901. doi:10.1152/ajpgi.00117.2009
- Langton, P., Ward, S. M., Carl, A., Norell, M. A., & Sanders, K. M. (1989). Spontaneous electrical activity of interstitial cells of Cajal isolated from canine proximal colon. *Proc Natl Acad Sci U S A*, 86(18), 7280-7284.
- Larsson, L. T., Z. Shen, E. Ekblad, F. Sundler, P. Alm and K. E. Andersson (1995). "Lack of neuronal nitric oxide synthase in nerve fibers of aganglionic intestine: a clue to Hirschsprung's disease." *J Pediatr Gastroenterol Nutr* 20(1): 49-53.
- Lebovits, A. H., & Lefkowitz, M. (1989). Pain management of pancreatic carcinoma: a review. *Pain*, 36(1), 1-11.
- Lefebvre, R. A., Dick, J. M., Guerin, S., & Malbert, C. H. (2005). Involvement of NO in gastric emptying of semi-solid meal in conscious pigs. *Neurogastroenterol Motil*, 17(2), 229-235.
- Le Guen, L., S. Marchal, S. Faure and P. de Santa Barbara (2015). "Mesenchymal-epithelial interactions during digestive tract development and epithelial stem cell regeneration." *Cell Mol Life Sci* 72(20): 3883-3896.
- Leksowski, K. (2001). "Thoracoscopic splanchnicectomy for control of intractable pain due to advanced pancreatic cancer." *Surg Endosc* 15(2): 129-131.
- Lenz, H. J., Burlage, M., Raedler, A., & Greten, H. (1988). Central nervous system effects of corticotropin-releasing factor on gastrointestinal transit in the rat. *Gastroenterology*, 94(3), 598-602.
- Lica, I., G. Jinescu, C. Pavelescu and M. Beuran (2014). "Thoracoscopic left splanchnicectomy - role in pain control in unresectable pancreatic cancer. Initial experience." *Chirurgia (Bucur)* 109(3): 313-317.
- Li, J., J. C. Lin, H. Wang, J. W. Peterson, B. C. Furie, B. Furie, S. L. Booth, J. J. Volpe and P. A. Rosenberg (2003). "Novel role of vitamin k in preventing oxidative injury to developing oligodendrocytes and neurons." *J Neurosci* 23(13): 5816-5826.
- Li, J., H. Wang and P. A. Rosenberg (2009). "Vitamin K prevents oxidative cell death by inhibiting activation of 12-lipoxygenase in developing oligodendrocytes." *J Neurosci Res* 87(9): 1997-2005.
- Liu, J. A. and E. S. Ngan (2014). "Hedgehog and Notch signaling in enteric nervous system development." *Neurosignals* 22(1): 1-13.
- MacLennan, S., Augood, C., Cash-Gibson, L., Logan, S., & Gilbert, R. E. (2010). Cisapride treatment for gastro-oesophageal reflux in children. *Cochrane Database Syst Rev*(4), CD002300. doi:10.1002/14651858.CD002300.pub2
- Maeda, H., Yamagata, A., Nishikawa, S., Yoshinaga, K., Kobayashi, S., Nishi, K., & Nishikawa, S. (1992). Requirement of c-kit for development of intestinal pacemaker system. *Development*, 116(2), 369-375.

References

- Malik, R., Srivastava, A., Gambhir, S., Yachha, S. K., Siddegowda, M., Ponnusamy, M., & Poddar, U. (2016). Assessment of gastric emptying in children: Establishment of control values utilizing a standardized vegetarian meal. *J Gastroenterol Hepatol*, *31*(2), 319-325. doi:10.1111/jgh.13145
- Mallard, C., Welin, A. K., Peebles, D., Hagberg, H., & Kjellmer, I. (2003). White matter injury following systemic endotoxemia or asphyxia in the fetal sheep. *Neurochem Res*, *28*(2), 215-223.
- Malmud, L. S., Fisher, R. S., Knight, L. C., & Rock, E. (1982). Scintigraphic evaluation of gastric emptying. *Semin Nucl Med*, *12*(2), 116-125.
- Mammi, P., Zaccaria, B., Dazzi, F., Saccavini, M. (2011) Prolonged duodenal paralysis after PEG placement in a patient with traumatic brain injury: a case report. *Eur J Phys Rehabil Med* *47* (1): 49-51
- Maurer, A. H. (2016). Gastrointestinal Motility, Part 1: Esophageal Transit and Gastric Emptying. *J Nucl Med Technol*, *44*(1), 1-11. doi:10.2967/jnumed.112.114314
- Mashimo, H. and R. K. Goyal (1999). "Lessons from genetically engineered animal models. IV. Nitric oxide synthase gene knockout mice." *Am J Physiol* *277*(4 Pt 1): G745-750.
- Masuda, T., M. Kuramoto, S. Shimada, S. Ikeshima, K. Yamamoto, K. Nakamura and H. Baba (2014). "Splanchnicectomy for pancreatic cancer pain." *Biomed Res Int* 2014: 941726.
- McCallum, R. W. (1991). Cisapride: a new class of prokinetic agent. The ACG Committee on FDA-related matters. American College of Gastroenterology. *Am J Gastroenterol*, *86*(2), 135-149.
- McCallum, R. W. (1996). Clinical pharmacology forum: motility agents and the gastrointestinal tract. *Am J Med Sci*, *312*(1), 19-26.
- McMenamin, C. A., Travagli, R. A., & Browning, K. N. (2016). Inhibitory neurotransmission regulates vagal efferent activity and gastric motility. *Exp Biol Med (Maywood)*, *241*(12), 1343-1350. doi:10.1177/1535370216654228
- McQuillen, P. S., Sheldon, R. A., Shatz, C. J., & Ferriero, D. M. (2003). Selective vulnerability of subplate neurons after early neonatal hypoxia-ischemia. *J Neurosci*, *23*(8), 3308-3315.
- Mearin, F., M. Mourelle, F. Guarner, A. Salas, V. Riveros-Moreno, S. Moncada and J. R. Malagelada (1993). "Patients with achalasia lack nitric oxide synthase in the gastro-oesophageal junction." *Eur J Clin Invest* *23*(11): 724-728.
- Minagawa, K., Tsuji, Y., Ueda, H., Koyama, K., Tanizawa, K., Okamura, H., & Hashimoto-Tamaoki, T. (2002). Possible correlation between high levels of IL-18 in the cord blood of pre-term infants and neonatal development of periventricular leukomalacia and cerebral palsy. *Cytokine*, *17*(3), 164-170. doi:10.1006/cyto.2001.0988
- Moore, J. G., Datz, F. L., Christian, P. E., Greenberg, E., & Alazraki, N. (1988). Effect of body posture on radionuclide measurements of gastric emptying. *Dig Dis Sci*, *33*(12), 1592-1595.
- Moore, J. G., Dubois, A., Christian, P. E., Elgin, D., & Alazraki, N. (1986). Evidence for a midgastric transverse band in humans. *Gastroenterology*, *91*(3), 540-545.

References

- Moraveji, S., Bashashati, M., Elhanafi, S., Sunny, J., Sarosiek, I., Davis, B., . . . McCallum, R. W. (2016). Depleted interstitial cells of Cajal and fibrosis in the pylorus: Novel features of gastroparesis. *Neurogastroenterol Motil*, 28(7), 1048-1054. doi:10.1111/nmo.12806
- Mt-Isa, S., Tomlin, S., Sutcliffe, A., Underwood, M., Williamson, P., Croft, N. M., & Ashby, D. (2015). Prokinetics prescribing in paediatrics: evidence on cisapride, domperidone, and metoclopramide. *J Pediatr Gastroenterol Nutr*, 60(4), 508-514. doi:10.1097/MPG.0000000000000657
- Napolis, A. C. Alves, F. A. Rezende, E. R. Segundo, G. R. (2015) Esophageal eosinophilia in pediatric patients with cerebral palsy. *Einstein (Sao Paulo)* 13 (2): 232-7
- Ngoenmak, T., Treepongkaruna, S., Buddharaksa, Y., & Khositseth, A. (2016). Effects of Domperidone on QT Interval in Children with Gastroesophageal Reflux Disease. *Pediatr Neonatol*, 57(1), 60-64. doi:10.1016/j.pedneo.2015.03.015
- Nishikawa, S., Kusakabe, M., Yoshinaga, K., Ogawa, M., Hayashi, S., Kunisada, T., . . . Nishikawa, S. (1991). In utero manipulation of coat color formation by a monoclonal anti-c-kit antibody: two distinct waves of c-kit-dependency during melanocyte development. *EMBO J*, 10(8), 2111-2118.
- Nitsos, I., Newnham, J. P., Rees, S. M., Harding, R., & Moss, T. J. (2014). The impact of chronic intrauterine inflammation on the physiologic and neurodevelopmental consequences of intermittent umbilical cord occlusion in fetal sheep. *Reprod Sci*, 21(5), 658-670. doi:10.1177/1933719111399928
- O'Shea, T. M. (2002). Cerebral palsy in very preterm infants: new epidemiological insights. *Ment Retard Dev Disabil Res Rev*, 8(3), 135-145. doi:10.1002/mrdd.10032
- Oka, A., Belliveau, M. J., Rosenberg, P. A., & Volpe, J. J. (1993). Vulnerability of oligodendroglia to glutamate: pharmacology, mechanisms, and prevention. *J Neurosci*, 13(4), 1441-1453.
- Okamura, Y. and Y. Saga (2008). "Notch signaling is required for the maintenance of enteric neural crest progenitors." *Development* 135(21): 3555-3565.
- Oliveira, C. R., Ranallo, F. N., Pijanowski, G. J., Mitchell, M. A., O'Brien, M. A., McMichael, M., . . . O'Brien, R. T. (2011). The VetMousetrap: a device for computed tomographic imaging of the thorax of awake cats. *Vet Radiol Ultrasound*, 52(1), 41-52.
- Omari, T. I., Benninga, M. A., Sansom, L., Butler, R. N., Dent, J., & Davidson, G. P. (2006). Effect of baclofen on esophagogastric motility and gastroesophageal reflux in children with gastroesophageal reflux disease: a randomized controlled trial. *J Pediatr*, 149(4), 468-474. doi:10.1016/j.jpeds.2006.05.029
- Ormsbee, H. S., 3rd, & Bass, P. (1976). Gastroduodenal motor gradients in the dog after pyloroplasty. *Am J Physiol*, 230(2), 389-397.
- Pandolfino, J. E., Fox, M. R., Bredenoord, A. J., & Kahrilas, P. J. (2009). High-resolution manometry in clinical practice: utilizing pressure topography to classify oesophageal motility abnormalities. *Neurogastroenterol Motil*, 21(8), 796-806. doi:10.1111/j.1365-2982.2009.01311.x
- Pandolfino, J. E., Ghosh, S. K., Rice, J., Clarke, J. O., Kwiatek, M. A., & Kahrilas, P. J. (2008). Classifying esophageal motility by pressure topography characteristics: a study of 400 patients and 75 controls. *Am J Gastroenterol*, 103(1), 27-37. doi:10.1111/j.1572-0241.2007.01532.x

References

- Panigrahy, A., Wisnowski, J. L., Furtado, A., Lepore, N., Paquette, L., & Bluml, S. (2012). Neuroimaging biomarkers of preterm brain injury: toward developing the preterm connectome. *Pediatr Radiol*, *42 Suppl 1*, S33-61. doi:10.1007/s00247-011-2239-4
- Paxinos, G., and Watson, C. (1996). *The Rat Brain in Stereotaxic Coordinates*, Compact 3rd Edition CDROM, Academic Press, San Diego
- Peeters, T. L. (2013). Ghrelin and the gut. *Endocr Dev*, *25*, 41-48. doi:10.1159/000346051
- Plioplys, A. V. (2003). Survival rates of children with severe neurologic disabilities: a review. *Semin Pediatr Neurol*, *10*(2), 120-129.
- Plioplys, A. V., Kasnicka, I., Lewis, S., & Moller, D. (1998). Survival rates among children with severe neurologic disabilities. *South Med J*, *91*(2), 161-172.
- Putney, J., O'Grady, G., Angeli, T. R., Paskaranandavadivel, N., Cheng, L. K., Erickson, J. C., & Peng, D. (2015). Determining the efficient inter-electrode distance for high-resolution mapping using a mathematical model of human gastric dysrhythmias. *Conf Proc IEEE Eng Med Biol Soc*, *2015*, 1448-1451. doi:10.1109/EMBC.2015.7318642
- Radulovic, M., P. Anand, M. A. Korsten and B. Gong (2015). "Targeting Ion Channels: An Important Therapeutic Implication in Gastrointestinal Dysmotility in Patients With Spinal Cord Injury." *J Neurogastroenterol Motil* *21*(4): 494-502.
- Rajan, E., C. J. Gostout, L. M. Wong Kee Song, L. A. Szarka, P. C. Kashyap, T. C. Smyrk, J. Bingener, J. L. Deters, M. A. Knipschild, C. E. Bernard and G. Farrugia (2016). "Innovative gastric endoscopic muscle biopsy to identify all cell types, including myenteric neurons and interstitial cells of Cajal in patients with idiopathic gastroparesis: a feasibility study (with video)." *Gastrointest Endosc* *84*(3): 512-517.
- Rao, S. S., Mysore, K., Attaluri, A., & Valestin, J. (2011). Diagnostic utility of wireless motility capsule in gastro. *Child Care Health Dev*, *19*(2), 109-118.
- Ratanasirintrao, S. and N. Israsena (2016). "Stem Cells in the Intestine: Possible Roles in Pathogenesis of Irritable Bowel Syndrome." *J Neurogastroenterol Motil* *22*(3): 367-382.
- Ravelli, A. M., Milla, P. J. (1998) Vomiting and gastroesophageal motor activity in children with disorders of the central nervous system. *J Pediatr Gastroenterol Nutr.* *26* (10); 56-63.
- Reyes, A. L., Cash, A. J. Green, S. H. Booth, I. W. (1993) Gastroesophageal reflux in children with cerebral palsy. *Child Care Health Dev.* *19* (2): 109-18
- Richards C. et al. (1998). Nissen fundoplication may induce gastric myoelectrical disturbance in children. *J Pediatr Surg* *33* (12):1801-1805
- Richards et al (2003). The histological appearances of Nissen-type fundoplication in the ferret. *Neurogastroenterol Motil.* *15*: 121-128.
- Rizzardi, A. E., A. T. Johnson, R. I. Vogel, S. E. Pambuccian, J. Henriksen, A. P. Skubitz, G. J. Metzger and S. C. Schmechel (2012). "Quantitative comparison of immunohistochemical staining measured by digital image analysis versus pathologist visual scoring." *Diagn Pathol* *7*: 42.
- Rocha, C. M., & Barbosa, M. M. (2005). QT interval prolongation associated with the oral use of domperidone in an infant. *Pediatr Cardiol*, *26*(5), 720-723. doi:10.1007/s00246-004-0922-z

References

- Rodriguez - Membrilla et al (1995). Is nitric oxide the final mediator regulating the migrating myoelectric complex cycle? *Am J of Physiol* 268 (2): G207-G214
- Roman, S., Pandolfino, J., & Mion, F. (2009). High-resolution manometry: a new gold standard to diagnose esophageal dysmotility? *Gastroenterol Clin Biol*, 33(12), 1061-1067. doi:10.1016/j.gcb.2009.06.014
- Rosenbaum, P., Paneth, N., Leviton, A., Goldstein, M., Bax, M., Damiano, D., . . . Jacobsson, B. (2007). A report: the definition and classification of cerebral palsy April 2006. *Dev Med Child Neurol Suppl*, 109, 8-14.
- Rudolph, C. D., Mazur, L. J., Liptak, G. S., Baker, R. D., Boyle, J. T., Colletti, R. B., . . . Nutrition. (2001). Guidelines for evaluation and treatment of gastroesophageal reflux in infants and children: recommendations of the North American Society for Pediatric Gastroenterology and Nutrition. *J Pediatr Gastroenterol Nutr*, 32 Suppl 2, S1-31.
- Sakakibara, Tateno, F. Yano, M. Takahashi, O. Sugiyama, M. Ogata, T. Kishi, M. Tsuyusaki, Y. Shibata, C (2014) Tolterodine activates the prefrontal cortex during bladder filling in OAB patients: a real-time NIRS-urodynamics study *NeuroUrol Urodyn*, 33(7) 1110-5
- Sakurai, T., Torii, A., Tanaka, F., Asakawa, H., Matsuoka, M., Negishi, M., . . . Toda, G. (1996). A basic study on gastric emptying test using barium grains and effect of drugs on gastric emptying in rats. *Nihon Shokakibyo Gakkai Zasshi*, 93(2), 75-82.
- Samson-Fang, L., Butler, C., O'Donnell, M., & Aacpdm. (2003). Effects of gastrostomy feeding in children with cerebral palsy: an AACPDm evidence report. *Dev Med Child Neurol*, 45(6), 415-426.
- Sander, G. R., S. J. Brookes and B. C. Powell (2003). "Expression of Notch1 and Jagged2 in the enteric nervous system." *J Histochem Cytochem* 51(7): 969-972.
- Sander, G. R. and B. C. Powell (2004). "Expression of notch receptors and ligands in the adult gut." *J Histochem Cytochem* 52(4): 509-516.
- Sanders, K. M. (1996). A case for interstitial cells of Cajal as pacemakers and mediators of neurotransmission in the gastrointestinal tract. *Gastroenterology*, 111(2), 492-515.
- Sanger, G. J., & Furness, J. B. (2016). Ghrelin and motilin receptors as drug targets for gastrointestinal disorders. *Nat Rev Gastroenterol Hepatol*, 13(1), 38-48. doi:10.1038/nrgastro.2015.163
- Sapru, H. N. (1982). Greater Splanchnic nerve activity in the rat. *Brain Research Bulletin*.
- Sarna, S., Stoddard, C., Belbeck, L., & McWade, D. (1981). Intrinsic nervous control of migrating myoelectric complexes. *Am J Physiol*, 241(1), G16-23.
- Sasselli, V., Pachnis, V., & Burns, A. J. (2012). The enteric nervous system. *Dev Biol*, 366(1), 64-73. doi:10.1016/j.ydbio.2012.01.012
- Savidge, T. C. (2014). Importance of NO and its related compounds in enteric nervous system regulation of gut homeostasis and disease susceptibility. *Curr Opin Pharmacol*, 19, 54-60. doi:10.1016/j.coph.2014.07.009
- Schneider, C. A., Rasband, W. S., & Eliceiri, K. W. (2012). NIH Image to ImageJ: 25 years of image analysis. *Nat Methods*, 9(7), 671-675.

References

- Seminowicz, D. A., Labus, J. S., Bueller, J. A., Tillisch, K., Naliboff, B. D., Bushnell, M. C., & Mayer, E. A. (2010). Regional gray matter density changes in brains of patients with irritable bowel syndrome. *Gastroenterology*, *139*(1), 48-57 e42. doi:10.1053/j.gastro.2010.03.049
- Sheldon, R. A., Chuai, J., & Ferriero, D. M. (1996). A rat model for hypoxic-ischemic brain damage in very premature infants. *Biol Neonate*, *69*(5), 327-341.
- Shin, A., & Wo, J. M. (2015). Therapeutic applications of ghrelin agonists in the treatment of gastroparesis. *Curr Gastroenterol Rep*, *17*(2), 430. doi:10.1007/s11894-015-0430-8
- Shoji, E., Okumura, T., Onodera, S., Takahashi, N., Harada, K., & Kohgo, Y. (1997). Gastric emptying in OLETF rats not expressing CCK-A receptor gene. *Dig Dis Sci*, *42*(5), 915-919.
- Sleigh, G., & Brocklehurst, P. (2004). Gastrostomy feeding in cerebral palsy: a systematic review. *Arch Dis Child*, *89*(6), 534-539.
- Sleigh, G., Sullivan, P. B., & Thomas, A. G. (2004). Gastrostomy feeding versus oral feeding alone for children with cerebral palsy. *Cochrane Database Syst Rev*(2), CD003943. doi:10.1002/14651858.CD003943.pub2
- Smith, D., & Soucy, P. (1996). Complications of long-term jejunostomy in children. *J Pediatr Surg*, *31*(6), 787-790.
- Smith, V. V. (2001). Chronic intestinal pseudo-obstruction: the pathologist's perspective. *J Pediatr Gastroenterol Nutr*, *32* Suppl 1, S23-24.
- Solomou, S., & Korbonits, M. (2014). The role of ghrelin in weight-regulation disorders: implications in clinical practice. *Hormones (Athens)*, *13*(4), 458-475. doi:10.14310/horm.2002.1551
- Staiano, A., Cucchiara, S., Del Giudice, E., Andreotti, M. R., & Minella, R. (1991). Disorders of oesophageal motility in children with psychomotor retardation and gastro-oesophageal reflux. *Eur J Pediatr*, *150*(9), 638-641.
- Steingoetter, A., Fox, M., Treier, R., Weishaupt, D., Marincek, B., Boesiger, P., . . . Schwizer, W. (2006). Effects of posture on the physiology of gastric emptying: a magnetic resonance imaging study. *Scand J Gastroenterol*, *41*(10), 1155-1164. doi:10.1080/00365520600610451
- Stenberg, R., Hadjivassiliou, M., Aeschlimann, P., Hoggard, N., Aeschlimann, D. (2014) Anti-transglutaminase 6 antibodies in children and young adults with cerebral palsy *Autoimmune Dis*, 237107
- Sullivan, P. B. (1997). Gastrointestinal problems in the neurologically impaired child. *Baillieres Clin Gastroenterol*, *11*(3), 529-546.
- Tahraoui, S. L., Marret, S., Bodenant, C., Leroux, P., Dommergues, M. A., Evrard, P., & Gressens, P. (2001). Central role of microglia in neonatal excitotoxic lesions of the murine periventricular white matter. *Brain Pathol*, *11*(1), 56-71.
- Takashima, S., K. L. Adams, P. A. Ortiz, C. T. Ying, R. Moridzadeh, A. Younossi-Hartenstein and V. Hartenstein (2011). "Development of the Drosophila entero-endocrine lineage and its specification by the Notch signaling pathway." *Dev Biol* **353**(2): 161-172.

References

- Theocharatos, S., D. J. Wilkinson, S. Darling, B. Wilm, S. E. Kenny and D. Edgar (2013). "Regulation of progenitor cell proliferation and neuronal differentiation in enteric nervous system neurospheres." *PLoS One* **8**(1): e54809.
- Thomas, W., & Speer, C. P. (2011). Chorioamnionitis: important risk factor or innocent bystander for neonatal outcome? *Neonatology*, *99*(3), 177-187. doi:10.1159/000320170
- Tighe, M. P., Afzal, N. A., Bevan, A., & Beattie, R. M. (2009). Current pharmacological management of gastro-esophageal reflux in children: an evidence-based systematic review. *Paediatr Drugs*, *11*(3), 185-202. doi:10.2165/00148581-200911030-00004
- Tillisch, K., & Labus, J. S. (2011). Advances in imaging the brain-gut axis: functional gastrointestinal disorders. *Gastroenterology*, *140*(2), 407-411 e401. doi:10.1053/j.gastro.2010.12.014
- Torihashi, S., Ward, S. M., Nishikawa, S., Nishi, K., Kobayashi, S., & Sanders, K. M. (1995). c-kit-dependent development of interstitial cells and electrical activity in the murine gastrointestinal tract. *Cell Tissue Res*, *280*(1), 97-111.
- Toti, L. Travagli, R. A. (2014) Gastric dysregulation induced by microinjection of 6-OHDA in the substantia nigra pars compacta of rats is determined by alterations in the brain-gut axis. *Am J Physiol Gastrointest Liver Physiol*, *307* (10), G1013-23
- van der Pol, R. J., Smits, M. J., van Wijk, M. P., Omari, T. I., Tabbers, M. M., & Benninga, M. A. (2011). Efficacy of proton-pump inhibitors in children with gastroesophageal reflux disease: a systematic review. *Pediatrics*, *127*(5), 925-935. doi:10.1542/peds.2010-2719
- van der Velde, P., Koslowsky, I., & Koopmans, H. S. (1999). Measurement of gastric emptying during and between meal intake in free-feeding Lewis rats. *Am J Physiol*, *276*(2 Pt 2), R597-605.
- Vandenplas, Y., Ashkenazi, A., Belli, D., Boige, N., Bouquet, J., Cadranet, S., . . . et al. (1993). A proposition for the diagnosis and treatment of gastro-oesophageal reflux disease in children: a report from a working group on gastro-oesophageal reflux disease. Working Group of the European Society of Paediatric Gastro-enterology and Nutrition (ESPGAN). *Eur J Pediatr*, *152*(9), 704-711.
- Vanderwinden, J. M., P. Mailleux, S. N. Schiffmann, J. J. Vanderhaeghen and M. H. De Laet (1992). "Nitric oxide synthase activity in infantile hypertrophic pyloric stenosis." *N Engl J Med* *327*(8): 511-515.
- Vane, D. W., Shiffler, M., Grosfeld, J. L., Hall, P., Angelides, A., Weber, T. R., & Fitzgerald, J. F. (1982). Reduced lower esophageal sphincter (LES) pressure after acute and chronic brain injury. *J Pediatr Surg*, *17*(6), 960-964.
- Vanormelingen, C., Vanuytsel, T., Masaoka, T., De Hertogh, G., Vanheel, H., Vanden Berghe, P., . . . Tack, J. (2016). The normoglycaemic biobreeding rat: a spontaneous model for impaired gastric accommodation. *Gut*, *65*(1), 73-81. doi:10.1136/gutjnl-2014-308154
- Vanuytsel, T., Vanormelingen, C., Vanheel, H., Masaoka, T., Salim Rasool, S., Toth, J., . . . Farre, R. (2014). From intestinal permeability to dysmotility: the biobreeding rat as a model for functional gastrointestinal disorders. *PLoS One*, *9*(10), e111132. doi:10.1371/journal.pone.0111132

References

- Verkijk, M., Gielkens, H. A., Lamers, C. B., & Masclee, A. A. (1998). Effect of gastrin on antroduodenal motility: role of intraluminal acidity. *Am J Physiol*, 275(5 Pt 1), G1209-1216.
- Veronesi, M. C., Panzani, S., Faustini, M., & Rota, A. (2009). An Apgar scoring system for routine assessment of newborn puppy viability and short-term survival prognosis. *Theriogenology*, 72(3), 401-407. doi:10.1016/j.theriogenology.2009.03.010
- Wales, P. W., Diamond, I. R., Dutta, S., Muraca, S., Chait, P., Connolly, B., & Langer, J. C. (2002). Fundoplication and gastrostomy versus image-guided gastrojejunal tube for enteral feeding in neurologically impaired children with gastroesophageal reflux. *J Pediatr Surg*, 37(3), 407-412.
- Ward, S. M., Burns, A. J., Torihashi, S., Harney, S. C., & Sanders, K. M. (1995). Impaired development of interstitial cells and intestinal electrical rhythmicity in steel mutants. *Am J Physiol*, 269(6 Pt 1), C1577-1585.
- Weinstabl, et al. (1993). celiac plexus block with bupivacaine reduces gastrointestinal dysfunction in neurosurgical ICU patients. *Anaesthesia*. 48:2, 162-164
- Won, K. J., Sanders, K. M., & Ward, S. M. (2005). Interstitial cells of Cajal mediate mechanosensitive responses in the stomach. *Proc Natl Acad Sci U S A*, 102(41), 14913-14918. doi:10.1073/pnas.0503628102
- Wren, A. M. (2008). Gut and hormones and obesity. *Front Horm Res*, 36, 165-181. doi:10.1159/0000115364
- Wren, A. M., Seal, L. J., Cohen, M. A., Brynes, A. E., Frost, G. S., Murphy, K. G., . . . Bloom, S. R. (2001). Ghrelin enhances appetite and increases food intake in humans. *J Clin Endocrinol Metab*, 86(12), 5992. doi:10.1210/jcem.86.12.8111
- Yang, C. G., Liao, Z. F., Qiu, W. C., Yan, J., & Wang, Z. G. (2014). Function of ghrelin and ghrelin receptors in the network regulation of gastric motility. *Mol Med Rep*, 10(5), 2453-2458. doi:10.3892/mmr.2014.2571
- Yang, C. G., Wang, W. G., Yan, J., Fei, J., Wang, Z. G., & Zheng, Q. (2013). Gastric motility in ghrelin receptor knockout mice. *Mol Med Rep*, 7(1), 83-88. doi:10.3892/mmr.2012.1157
- Yin, J., Xu, X., Song, G., Han, H. S., Kim, H. W., & Chen, J. D. (2016). Prokinetic Effects of a New 5-HT4 Agonist, YKP10811 on Gastric Motility in Dogs. *J Gastroenterol Hepatol*. doi:10.1111/jgh.13490
- Young, H. M. (2008). Functional development of the enteric nervous system--from migration to motility. *Neurogastroenterol Motil*, 20 Suppl 1, 20-31. doi:10.1111/j.1365-2982.2008.01098.x
- Zani, A., Eaton, S., Leon, F. F., Malerba, A., Hall, N. J., De Coppi, P., . . . Pierro, A. (2008). Captopril reduces the severity of bowel damage in a neonatal rat model of necrotizing enterocolitis. *J Pediatr Surg*, 43(2), 308-314. doi:10.1016/j.jpedsurg.2007.10.022
- Ziessman, H. A., Atkins, F. B., Vemulakonda, U. S., Tall, J., Harkness, B., & Fahey, F. H. (1996). Lag phase quantification for solid gastric emptying studies. *J Nucl Med*, 37(10), 1639-1643.