



University
of Glasgow

Robertson, Elaine V. (2016) *Studies of the gastro-oesophageal junction in normal and overweight healthy volunteers*. MD thesis.

<http://theses.gla.ac.uk/7491/>

Copyright and moral rights for this thesis are retained by the author

A copy can be downloaded for personal non-commercial research or study

This thesis cannot be reproduced or quoted extensively from without first obtaining permission in writing from the Author

The content must not be changed in any way or sold commercially in any format or medium without the formal permission of the Author

When referring to this work, full bibliographic details including the author, title, awarding institution and date of the thesis must be given

UNIVERSITY OF GLASGOW

Studies of the Gastro-oesophageal Junction in Normal and Overweight Healthy Volunteers

Dr Elaine V. Robertson MBChB (Hons), MRCP (UK)

Submitted in fulfilment of the requirements for the degree of Doctor of Medicine

Institute of Cardiovascular and Medical Sciences

College of Medicine, Veterinary and Life Science

University of Glasgow

April 2016

Acknowledgements

In undertaking this thesis I have had tremendous support from the team directly involved in the project and from other colleagues, family and friends.

Firstly I wish to thank my supervisor Professor McColl for his faith, vision and encouragement and for his relentless positivity. He has been an inspiration and a source of support to me throughout this journey. Dr Mohammad Derakhshan deserves a special mention for his help with the statistics and his patient explanations as I grappled with the complexities of data analysis. He was also instrumental in the pathological analysis of specimens and led the analysis on the immunophenotyping of biopsies.

I have learned that the process of researching is a team endeavour and I was privileged to have wonderful colleagues day to day in Angela Wirz and Janice Arnott. Angela and Janice reliably provided administrative support, advice and often emotional support in the day to day running of the study as well as helping to recruit and liaise with volunteers. Similarly Dorothy Ronney has been a fantastic source of practical support.

Dr Stuart Ballantyne was an invaluable source of help in interpreting the scans and Dr James Going an incredible asset in offering his expertise with the pathology. Not only did Dr Going help with interpretation he was also key to the ongoing hypothesis building. I was also fortunate to have the considerable experience of Dr Andrew Kelman who developed the custom made programme allowing data interpretation. My work would not have been possible without the volunteers who gave up their time to help and I owe them a debt of gratitude. I am also extremely grateful to my husband Derek and my girls Emily and Sophie who have supported me and tolerated me through this process.

Lastly I dedicate this work to my mum, Violet who saw the start of this project but sadly not the end. She was my friend, my inspiration and my strength. She believed in me and I hope she would be proud.

Authors Declaration

The study was conceived and originally designed by Professor McColl and refined and finalised by myself, Dr Mohammad Derakhshan, Dr Yeong-Yeh Lee and Professor McColl.

I was responsible for the recruitment and retention of volunteers along with Sister Angela Wirz and for performing all clinical, endoscopic and physiological assessments. The MRI scans and fluoroscopic screening were performed by the radiology department staff at Gartnavel General Hospital and the MRI scans analysed by Dr Stuart Ballantyne and Dr Scott Hanvey. The pathological analysis was undertaken by Dr James J Going and Dr Mohammad H. Derakhshan.

I performed the statistical analysis in conjunction with Dr Mohammad H. Derakhshan. Data analysis and interpretation was done by me in consultation with all members of the research team and under the supervision of Professor McColl.

I declare that I am responsible for composing this thesis.

It has not previously been submitted for a higher degree.

Elaine Violet Robertson, April 2016

Contents

Acknowledgements.....	2
Authors Declaration	3
Abstract.....	16
Publications	18
Abstracts and Presentations	19
Abbreviations	20
1 An Introduction to Gastro-oesophageal Reflux Disease	23
1.1 Background	23
1.2 The Gastro-oesophageal Junction and Anti-reflux Mechanisms.....	24
1.2.1 Intrinsic and Extrinsic Components of the Lower Oesophageal Sphincter.....	26
1.2.2 The Intra-Abdominal Oesophagus.	26
1.2.3 The Gastro-oesophageal Flap Valve.....	26
1.2.4 The Location of the SCJ within the Lower Oesophageal Sphincter..	27
1.2.5 Mechanisms to Limit Oesophageal Acid Exposure.....	27
1.3 Mechanisms of Reflux	27
1.3.1 Transient Lower Oesophageal Sphincter Relaxations	27

1.3.2	Hypotensive Lower Oesophageal Sphincter	28
1.3.3	Hiatus Hernia.....	28
1.4	Impaired Oesophageal Acid Clearance	29
1.5	Factors Predisposing to GORD	30
1.6	Summary	31
2	The Luminal Environment at the Gastro-oesophageal Junction	32
2.1	Background	32
2.2	The Acid Pocket	32
2.2.1	Acid as 'Pocket', 'Film' or 'Coat'	34
2.2.2	Acid Pocket Length	36
2.2.3	Acid Pocket and Association with Hiatus Hernia	36
2.3	Short Segment Reflux	37
2.4	The Concept of Intrasphincteric Reflux	37
2.5	Summary	38
3	The Histology of the Gastro-oesophageal Junction.....	40
3.1	Epithelial Types in the Oesophagus and Proximal Stomach	40
3.1.1	Squamous Mucosa.....	41
3.1.2	Gastric Oxyntic Mucosa	41
3.1.3	Cardiac Mucosa	42

3.1.4	Oxynto-cardiac Mucosa	43
3.1.5	Intestinal Metaplastic Epithelium	44
3.2	Defining the Cardia.....	44
3.2.1	Is Cardiac Mucosa Universally Present?.....	45
3.2.2	What is the Significance of Cardiac Mucosa?	46
3.2.3	What is the Significance of Cardiac Mucosal length?	47
3.3	Summary: The Acquired Cardia Hypothesis.....	47
4	Obesity and Adenocarcinoma of the Cardia	49
4.1	Epidemiology	49
4.2	Obesity and Gastric Cardia Adenocarcinoma: Is there a link?.....	49
4.3	Is All Fat Equal?	50
4.4	Obesity and Gastric Cardia Adenocarcinoma: What is the link?	51
4.4.1	Gastro-oesophageal reflux disease.....	51
4.4.2	The Use of Acid Suppressing Medications	52
4.4.3	Diabetes mellitus	52
4.4.4	Diet	52
4.4.5	Helicobacter Pylori	52
4.5	Potential Mechanisms	53
4.5.1	Metabolic Model	53

4.5.2	Mechanistic Model	55
4.6	An integrated model of carcinogenesis of the gastro-oesophageal junction	57
5	Aims and Methods	58
5.1	Aims	58
5.2	Methods	58
5.2.1	Recruitment	58
5.2.2	Upper GI Endoscopy	59
5.2.3	Biopsy Orientation and Processing	60
5.2.4	Staining and Immunophenotyping of Biopsies	61
5.2.5	MRI Studies	63
5.2.6	pH Monitoring	64
5.2.7	Manometry Set Up and Pressure Calibration.....	64
5.2.8	Combining pH and Manometry Probes	65
5.2.9	Thermal Calibration of the Manometry Probe	65
5.2.10	Data Capture and Handling	66
5.2.11	Fluoroscopy.....	67
6	Addressing the Thermal Drift of the Manoscan System	68
6.1	Introduction:	68

6.2	Methods	69
6.2.1	High Resolution Manometry	69
6.2.2	Characterising ‘Thermal Drift’ in Vitro	69
6.2.3	Correction Processes	70
6.2.4	Probe Behaviour ‘in Vivo’	71
6.3	Results	72
6.3.1	The Immediate Effect of Temperature Change	72
6.3.2	Measurement of a Constant Pressure at 37°C	72
6.3.3	The Thermal Compensation Correction	75
6.3.4	Linear Correction	75
6.3.5	Probe Behaviour ‘In Vivo’	75
	Discussion	76
7	Central Obesity in Asymptomatic Volunteers is Associated with Expansion of the Cardia by Columnar Metaplasia	79
7.1	Introduction	79
7.2	Methods	80
7.2.1	Subjects	80
7.2.2	Study Design	81
7.2.3	Biopsy specimen processing	82

7.2.4	H&E and Immunohistochemistry Staining of Biopsies	82
7.2.5	Data Analysis	83
7.2.6	Statistical Analysis.....	84
7.2.7	Ethics	85
7.3	Results:	85
7.3.1	Obesity and Cardiac Mucosal Length.....	85
7.3.2	Inflammation and Intestinal Metaplasia at Cardia and SCJ.....	86
7.3.3	Immunohistochemistry of the GOJ	88
7.3.4	Obesity and markers of glandular differentiation	94
7.4	Discussion	97
8	Central Obesity in Asymptomatic Volunteers is associated with Intrasphincteric Acid Reflux without Traditional Reflux.....	102
8.1	Introduction	102
8.2	Methods	103
8.2.1	Study Subjects	103
8.2.2	Study Protocol	103
8.2.3	Data Analysis	105
8.2.4	Statistical Analysis.....	107
8.2.5	Ethics	107

8.3	Results	107
8.3.1	Obesity and Acid Reflux	107
8.3.2	Obesity and Manometric Measures	108
8.3.3	Obesity and Diaphragm Position by MRI	112
8.3.4	Obesity and the location of the pH transition point.....	112
8.3.5	Obesity and location of the SCJ	113
8.4	Discussion	115
9	Hiatus Hernia in Healthy Volunteers is Associated with Intrasphincteric Reflux and Cardiac Mucosal Lengthening without Traditional Reflux.....	118
9.1	Introduction	118
9.2	Methods	118
9.2.1	Study Protocol	119
9.2.2	Data Analysis	120
9.2.3	Inflammatory Scores	120
9.2.4	Acid Data.....	121
9.2.5	Prevalence of the Double Peaked Pressure Profile	121
9.2.6	Detailed Analysis of Lower Oesophageal Sphincter	122
9.2.7	Fluoroscopy.....	122
9.2.8	Statistical Analysis.....	122

9.3	Results	123
9.3.1	Group Characteristics	123
9.3.2	MRI Measures	123
9.3.3	Junctional Mucosal Characteristics	124
9.3.4	Acid Reflux	124
9.3.5	LOS Pressure and Inspiratory Augmentation Pressure	125
9.3.6	Prevalence of Double Peak on High Resolution Manometry	126
9.3.7	Intrasphincteric Characteristics of Hiatus Hernia versus Controls ..	127
9.3.8	Intrasphincteric Characteristics of Hiatus hernia Versus Controls When Both Have Similar Pressure Profile	129
9.4	Discussion	131
10	Discussion.....	137
	References.....	145
	Appendix 1: Protocol for Endoscopy	154
	Appendix 2: Protocol for Recording Manometry and pH Data.....	157
	Appendix 3: Protocol for Recording pH and Manometry	164
	Appendix 4: Protocol for Exporting pH and Manometry Data	170
	Appendix 5: Study Questionnaire	172

Index of Figures

Figure 1.1: The normal gastro-oesophageal junction and anti-reflux mechanisms	25
Figure 1.2: The pathophysiology of gastro-oesophageal reflux.....	31
Figure 2.1: Colour contour plots depicting the occurrence of the acid pocket after the meal.	33
Figure 2.2: MRI showing a secretion layer forming atop gastric contents after the meal.	34
Figure 2.3: Depiction of the ‘acid coat’	35
Figure 2.4: Significant shortening of the high pressure zone after the meal due to loss of the distal component of the lower oesophageal sphincter.	38
Figure 3.1: Stratified squamous epithelium of the oesophagus ⁸	41
Figure 3.2: Normal gastric oxyntic mucosa	42
Figure 3.3: Cardiac mucosa.....	43
Figure 3.4: Oxynto-cardiac mucosa	43
Figure 3.5: Intestinal metaplasia showing typical goblet cells.	44
Figure 5.1: Endoscopic targetting of biopsies across the squamocolumnar junction indicating optimal positioning	59
Figure 5.2: Sample biopsy obtained from squamocolumnar junction.....	60
Figure 5.3: Sample scan used for quantification of visceral and subcutaneous fat.	63

Figure 5.4: Schematic showing the spacing of the pH sensors on the custom made high resolution pH probe	64
Figure 5.5: Combined pH and manometry apparatus with manometry sensor 29 corresponding to pH sensor 7.	65
Figure 6.1: Thermal drift in a prolonged study.	68
Figure 6.2: Thermal Effect.....	72
Figure 6.3: Sample pressure-time graphs showing the change in recorded pressure with time for 36 sensors in a single two hour experiment.	73
Figure 7.1: Sample biopsy across gastro-oesophageal junction showing squamous, cardiac and cardio-oxynitic mucosal types.	86
Figure 7.2: Inflammation and mucosal stress (reactive atypia) at squamo-columnar junction compared to gastric body and antral mucosae.....	87
Figure 7.3 Histology and immunohistochemistry of samples from the gastro-oesophageal junction of healthy volunteers compared with samples taken from patients with Barrett’s oesophagus.....	92
Figure 8.1: Alterations in the gastrointestinal junction associated with increased waist circumference.	113
Figure 9.1: Intrasphincteric characteristics of hiatus hernia versus controls after a meal in the supine posture.	129

Index of Tables

Table 1.1: The clinical spectrum of gastro-oesophageal reflux disease.....	24
Table 3.1: Epithelial types that occur in the oesophagus and proximal stomach.....	40
Table 5.1: Antibodies used for immunohistochemistry.....	62
Table 6.1: Summary of six experiments examining thermal effect and baseline drift in a single high resolution manometry catheter.....	74
Table 7.1: Inflammation in squamocolumnar junction biopsies compared with other parts of gastric mucosa.....	88
Table 7.2: The extent (%) of immunostaining with different antibodies in biopsies from squamocolumnar junction compared with gastric body, antrum and Barrett's.....	90
Table 7.3: The extent (%) of Ki-67 immunoreactivity in biopsies from squamocolumnar junction compared with tissues from gastric body, antrum and Barrett's.....	94
Table 7.4: Correlation between obesity and expression of trefoil factor family 3 (TFF-3) and liver-intestine (LI)-cadherin in gastro-oesophageal junctional biopsies, squamous mucosa (partial correlation).....	95
Table 7.5: Correlation between obesity and expression of various antibodies in gastro-oesophageal junctional biopsies, cardiac mucosa.....	96
Table 8.1: Mean Acid Exposure Time in Sensors Located 5 cm Above the Upper Border of the LES, Sensors Detecting pH Transition Point, and the Sensors 1.1 cm Proximal and 1.1, 2.2, and 3.3 cm Distal to the pH Transition Point.....	110
Table 8.2 Summary of Differences Between Large and Small WC Groups for Manometric Measures.....	111
	14

Table 8.3: Relative Positions of Components of the LOS, pH Transition Point, and SCJ.....	114
Table 8.4: Correlations Between Parameters of Obesity and the Position of the pH Transition Point Relative to the Upper Border of the LOS.....	115
Table 9.1: Acid exposure time [Median % time pH<4 (IQR)] in pH sensors located at 1.1cm proximal to the SCJ and 5cm above the upper border LOS in healthy volunteers with Hiatus Hernia and Controls. (FU: fasting upright; FS: fasting supine, PPU: post-prandial upright; PPS: post-prandial supine)...	125
Table 9.2: LOS Pressure (LOSP) and Inspiratory Augmentation Pressure in Hiatus Hernia and Control Groups.....	126
Table 9.3: Percentage time spent in double peaked pressure profile for hiatus hernia and control groups.....	127
Table 9.4: Detailed analysis of LOS components in hiatus hernia versus controls showing positions of the upper border LOS, pH Transition Point, SCJ and First Pressure Peak.....	128
Table 9.5: Analysis of Single Peaked Pressure Profile in Hiatus Hernia and Controls: Positions of SCJ, pH transition point and peak LOS pressure relative to nares and to upper border LOS.....	130
Table 9.6 Analysis of double-peaked pressure profile in hiatus hernia and controls: Positions of SCJ, pH transition point and proximal pressure peak relative to nares and upper border LOS.....	131

Abstract

Introduction: Oesophageal adenocarcinoma has increased dramatically in incidence over the past three decades with a particularly high burden of disease at the gastro-oesophageal junction. Many cases occur in individuals without known gastro-oesophageal reflux disease and in the absence of Barrett's oesophagus suggesting that mechanisms other than traditional reflux may be important.

Distal squamous mucosa may be prone to acid damage even in the absence of traditional reflux by the mechanism of distal opening of the lower oesophageal sphincter. This is splaying of the distal segment of lower oesophageal sphincter allowing acid ingress without traditional reflux.

It has been suggested that the cardiac mucosa at the gastro-oesophageal junction, separating oesophageal squamous mucosa and acid secreting columnar mucosa of the stomach may be an abnormal mucosa arising as a consequence of acid damage. By this theory the cardiac mucosa is metaplastic and akin to ultra-short Barrett's oesophagus.

Obesity is a known risk factor for adenocarcinoma at the gastro-oesophageal junction and its rise has paralleled that of oesophageal cancer. Some of this excess risk undoubtedly operates through stress on the gastro-oesophageal junction and a predisposition to reflux. However we sought to explore the impact of obesity on the gastro-oesophageal junction in healthy volunteers without reflux and in particular to determine the characteristics of the cardiac mucosa and mechanisms of reflux in this group.

Methods: 61 healthy volunteers with normal and increased waist circumference were recruited. 15 were found to have a hiatus hernia during the study protocol and were analysed separately. Volunteers had comprehensive pathological, physiological and anatomical assessments of the gastro-oesophageal junction including endoscopy with biopsies, MRI scanning before and after a standardised meal, prolonged recording of pH and manometry before and after a meal and screening by fluoroscopy to identify the squamo-columnar junction.

In the course of the early manometric assessments a potential error associated with the manometry system recordings was identified. We therefore also sought to document and address this on the benchtop and in vivo.

Key Findings

- In documenting the behaviour of the manoscan we described an immediate effect of temperature change on the pressure recorded by the sensors; ‘thermal effect’ and an ongoing drift of the recorded pressure with time; ‘baseline drift’. Thermal effect was well compensated within the standard operation of the system but baseline drift not addressed. Applying a linear correction to recorded data substantially reduced the error associated with baseline drift.
- In asymptomatic healthy volunteers there was lengthening of the cardiac mucosa in association with central obesity and age. Furthermore, the cardiac mucosa in healthy volunteers demonstrated an almost identical immunophenotype to non-IM Barrett’s mucosa, which is considered to arise by metaplasia of oesophageal squamous mucosa. These findings support the hypothesis that the cardia is metaplastic in origin.
- We have demonstrated a plausible mechanism of damage to distal squamous mucosa in association with obesity. In those with a large waist circumference we observed increased ingress of acid within but not across the lower oesophageal sphincter; ‘intrasphincteric reflux’
- The 15 healthy volunteers with a hiatus hernia were compared to 15 controls matched for age, gender and waist circumference. Those with a hiatus hernia had a longer cardiac mucosa and although they did not have excess traditional reflux they had excess distal acid exposure by short segment acid reflux and intrasphincteric acid reflux.

Conclusions: These findings are likely to be relevant to adenocarcinoma of the gastro-oesophageal junction

Publications

1. Mitchell DR, Derakhshan MH, Robertson EV, et al. The Role of the Acid Pocket in Gastroesophageal Reflux Disease. *J Clin Gastroenterol* 2016;50:111-9.
2. Derakhshan MH, Robertson EV, Yeh Lee Y, et al. In healthy volunteers, immunohistochemistry supports squamous to columnar metaplasia as mechanism of expansion of cardia, aggravated by central obesity. *Gut* 2015;64:1705-14.
3. Lee YY, Wirz AA, Whiting JG, et al. Waist belt and central obesity cause partial hiatus hernia and short-segment acid reflux in asymptomatic volunteers. *Gut* 2014;63:1053-60.
4. Robertson EV, Derakhshan MH, Wirz AA, et al. Central obesity in asymptomatic volunteers is associated with increased intrasphincteric acid reflux and lengthening of the cardiac mucosa. *Gastroenterology* 2013;145:730-9.
5. Lee YY, Whiting JG, Robertson EV, et al. Measuring movement and location of the gastroesophageal junction: research and clinical implications. *Scand J Gastroenterol* 2013;48:401-11.
6. Seenan JP, Wirz AA, Robertson EV, et al. Effect of nitrite delivered in saliva on postprandial gastro-esophageal function. *Scand J Gastroenterol* 2012;47:387-96.
7. Robertson EV, Lee YY, Derakhshan MH, et al. High-resolution esophageal manometry: addressing thermal drift of the manoscan system. *Neurogastroenterol Motil* 2012;24:61-4, e11.
8. Lee YY, Whiting JG, Robertson EV, et al. Kinetics of transient hiatus hernia during transient lower esophageal sphincter relaxations and swallows in healthy subjects. *Neurogastroenterol Motil* 2012;24:990-e539.
9. Derakhshan MH, Robertson EV, Fletcher J, et al. Mechanism of association between BMI and dysfunction of the gastro-oesophageal barrier in patients with normal endoscopy. *Gut* 2012;61:337-43.

Abstracts and Presentations

1. E. V. Robertson, M. H. Derakhshan, A. A. Wirz, Y.-Y. Lee, S. A. Ballantyne, J. J. Going, K. E. L. McColl. HIATUS HERNIA IN HEALTHY VOLUNTEERS IS ASSOCIATED WITH LENGTHENING OF THE CARDIAC MUCOSA AND INTRASPINCTERIC ACID EXPOSURE WITHOUT TRADITIONAL REFLUX
 - a. Poster Presentation Digestive Diseases Federation 2015: Prize for best poster within oesophageal section.

2. E. V. Robertson, M. H. Derakhshan, Y. Y. Lee, A. A. Wirz, S.A. Ballantyne, S.S Hanvey, J. J. Going, K. E. L. McColl METAPLASIA AT THE GASTRO-OESOPHAGEAL JUNCTION IN ASSOCIATION WITH CENTRAL OBESITY: SPHINCTERIC ACID INFLUX WITHOUT TRADITIONAL REFLUX.
 - a. Poster Presentation United European Gastroenterology Week 2012: Prize for poster of distinction.
 - b. Oral presentation Scottish Society of Gastroenterology 2012: Ann Ferguson Prize for best oral presentation

3. E. V. Robertson, M, H. Derakhshan, A. A. Wirz, Y.Y Lee, J.J Going, S. Hanvey, S. A. Ballantyne, K.E.L McColl, CENTRAL OBESITY AND AGE PREDICT CARDIA MUCOSAL LENGTH IN HEALTHY VOLUNTEERS: EVIDENCE FOR AN ACQUIRED ENTITY
 - a. Poster presentation Digestive Diseases Week 2012
 - b. Poster Presentation Digestive Diseases Federation 2012: Poster of Distinction

4. E. V. Robertson , Y. Y. Lee , M. H. Derakhshan , J. R. H. Whiting , A. Wirz , K. E. L. McColl. High Resolution Oesophageal Manometry: Addressing Thermal Drift.
 - a. Oral Presentation British Society Gastroenterology 2011
 - b. Oral Presentation Digestive Diseases Week 2011

Abbreviations

BMI: body mass index

CC: correlation coefficient

CDX2: caudal type homeobox 2

DAB: diaminobenzamine

FS: fasting supine

FU: fasting upright

GI: gastro-intestinal

GOJ: gastro-oesophageal junction

GORD: gastro-oesophageal reflux disease

H&E haematoxylin and eosin

HH: hiatus hernia

IAF: Intra-abdominal fat

IGF 1: Insulin-like growth factor 1

IGFBP3: Insulin-like growth factor binding protein 3

IGP: Intra-gastric Pressure

IL-1: Interleukin 1

IL-6: Interleukin 6

IL-8: Interleukin 8

IM: Intestinal metaplasia

IQR: Interquartile range

LB: lower border

LI-(cadherin): liver intestine

LOS: lower oesophageal sphincter

MCP-1: monocyte chemoattractant protein 1

MN: mononuclear

MRI: magnetic resonance imaging

MUC1: mucin 1

MUC2: mucin 2

MUC5AC: mucin 5AC

PACS: picture archiving and communication system

PBS: Phosphate buffered saline

PIP: pressure inversion point

PMN: polymorphonuclear

PPI: proton pump inhibitor

PPS: post-prandial supine

PPU: post prandial upright

RA: reactive atypia

SCF: subcutaneous fat

SCJ: squamo-columnar junction

SD: standard deviation

TFF-3: trefoil factor family 3

TLOSRS: transient lower oesophageal sphincter relaxations

TNF- α : tumour necrosis factor alpha

WC: waist circumference

1 An Introduction to Gastro-oesophageal Reflux Disease

1.1 Background

Gastro-oesophageal reflux disease (GORD) occurs when reflux of gastric contents causes troublesome symptoms and or complications (Montreal definition)¹. The cardinal associated symptoms are heartburn and regurgitation. It is one of the commonest chronic diseases in Western world affecting up to 28% of the population in North America and up to 26% in Europe and the prevalence continues to increase.²

The importance of GORD lies in its associated complications. Complications arise as a result of mucosal damage and encompass erosive oesophagitis with or without associated strictures, Barrett's oesophagus and oesophageal adenocarcinoma (Table 1.1)

TABLE 1.1: THE CLINICAL SPECTRUM OF GASTRO-OESOPHAGEAL REFLUX DISEASE

Clinical Entity	Definition
Non-Erosive Reflux Disease	Reflux of gastric contents causing troublesome symptoms in the absence of endoscopically visible mucosal damage
Erosive Oesophagitis	<p>Oesophageal mucosal damage caused by the reflux of gastric contents and graded by severity according to the Los Angeles classification.³</p> <p>Grade A: One (or more) mucosal break no longer than 5mm, that does not extend between the tops of two mucosal folds</p> <p>Grade B: One (or more) mucosal break more than 5mm long that does not extend between the tops of two mucosal folds</p> <p>Grade C: One (or more) mucosal break that is continuous between the tops of two or more mucosal folds, but which involves less than 75% of the circumference</p> <p>Grade D: One (or more) mucosal break that involves more than 75% of the oesophageal circumference.</p>
Barrett's Oesophagus	The presence of columnar lined oesophagus with or without intestinal metaplasia.

In 1952 the occurrence of oesophageal adenocarcinoma in Barrett's oesophagus merited a case report⁴. Over the last three decades incidence has increased markedly. In the UK the cumulative risk between the ages of 15 and 74 increased tenfold in men and fivefold in women in little more than a single generation.⁵ Oesophageal adenocarcinoma is now the 5th leading cause of cancer related death in the world in men⁶ and Scotland has the highest incidence worldwide.⁷

1.2 The Gastro-oesophageal Junction and Anti-reflux Mechanisms

The environment of the gastro-oesophageal junction is unique in that acid producing parietal cells of the proximal stomach are in close proximity to the squamous mucosa of the distal oesophagus. Indeed the mucosal subtypes may be

separated by only a few mm⁸. The columnar mucosa of the stomach is adapted to withstand the challenge of a highly acidic environment whilst the stratified squamous mucosa of the distal oesophagus is vulnerable.

The gastro-oesophageal junction incorporates a number of protective mechanisms acting in concert to prevent retrograde flow of acid and pepsin and protect vulnerable squamous mucosa (Figure 1.1)⁹

1. Intrinsic and extrinsic components of the lower oesophageal sphincter.
2. The intra-abdominal oesophagus.
3. The mucosal flap valve.
4. The location of the SCJ within the LOS
5. Mechanisms to limit oesophageal acid exposure

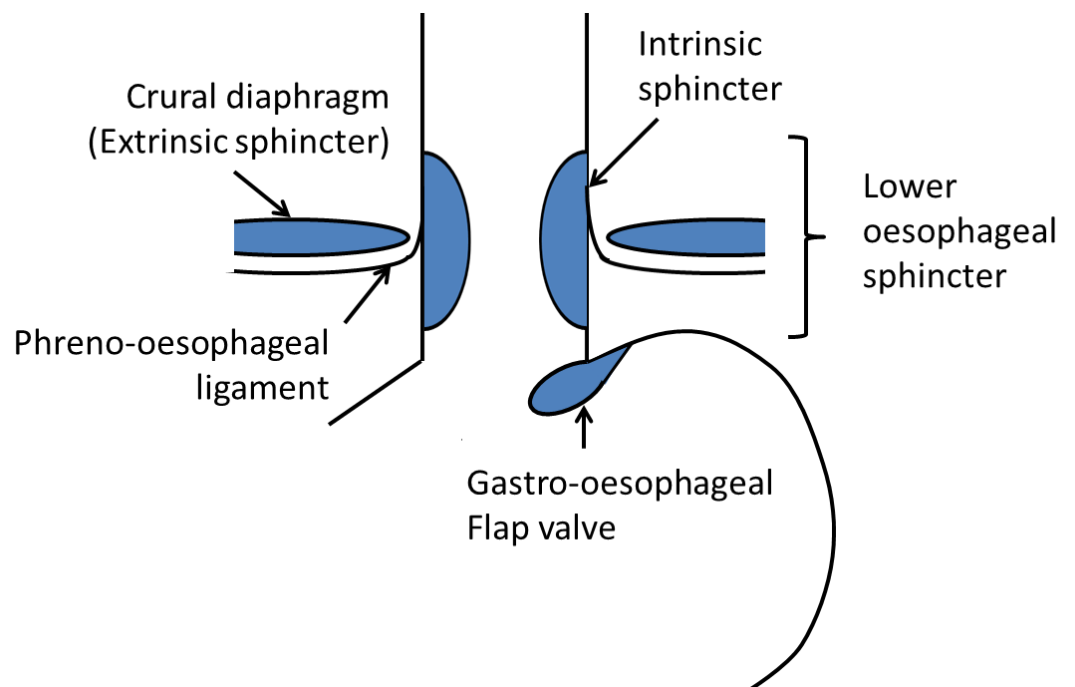


FIGURE 1.1: THE NORMAL GASTRO-OESOPHAGEAL JUNCTION AND ANTI-REFLUX MECHANISMS

1.2.1 Intrinsic and Extrinsic Components of the Lower Oesophageal Sphincter

The LOS comprises both intrinsic and extrinsic components. The intrinsic sphincter is formed as a length of circular smooth muscle measuring 3-4 cm in length. It maintains a tone of 10-15mmHg above intra-gastric pressure to prevent reflux of intra-gastric contents⁹. The extrinsic sphincter is formed by the crural diaphragm which overlaps and reinforces the intrinsic component. The relationship between the sphincter components is maintained by the integrity of the phreno-oesophageal ligament which is formed by the fused endothoracic and endoabdominal fascia of the diaphragm and inserts circumferentially into the oesophageal musculature close to the squamo-columnar junction.

This overlapping arrangement of sphincter components provides additional protection against an array of pressure challenges for the GOJ. For example during inspiration when the gastro-oesophageal pressure gradient increases, the contraction of the crural diaphragm increases the pressure exerted by the extrinsic sphincter. There is also reflex contraction of the diaphragm with sudden increases in intra-abdominal pressure.

1.2.2 The Intra-Abdominal Oesophagus.

The normal location of the GOJ in the intra-abdominal compartment is a further protective mechanism against reflux. Increased intra-abdominal pressure can act to provoke reflux by increasing intragastric pressure and the gradient between stomach and oesophagus (gastro-oesophageal pressure gradient). However a rise in intra-abdominal pressure and therefore intra-gastric pressure is offset by an equal rise in the pressure in the intra-abdominal oesophagus.

1.2.3 The Gastro-oesophageal Flap Valve

The gastro-oesophageal flap valve is a mucosal fold in the proximal stomach formed by gastric sling fibres. It is passively closed when intragastric pressure increases preventing retrograde acid flow.

1.2.4 The Location of the SCJ within the Lower Oesophageal Sphincter

In healthy individuals the SCJ is distally located within the high pressure zone of the lower oesophageal sphincter with the peak sphincter pressure more proximally. The local pressure gradient therefore acts to promote flow towards stomach rather than oesophagus.

1.2.5 Mechanisms to Limit Oesophageal Acid Exposure

Following a reflux episode oesophageal acid clearance begins by emptying the refluxed fluid by peristalsis. Residual acidic refluxate is neutralized by swallowed salivary bicarbonate.¹⁰

1.3 Mechanisms of Reflux

The anti-reflux barrier is structurally and functionally complex and therefore vulnerable to dysfunction. The three dominant mechanisms of reflux are:

1. Transient lower oesophageal sphincter relaxations (TLOSRS)
2. A hypotensive lower oesophageal sphincter
3. Disruption of sphincter integrity most commonly associated with a hiatus hernia.

The relative importance of each is debated but is likely that the dominant mechanism varies with disease severity¹¹. In mild reflux disease, acid reflux during transient lower oesophageal sphincter relaxation predominates¹². At the more severe end of the spectrum hiatus hernia and a hypotensive LOS become more important.¹²⁻¹⁴

1.3.1 Transient Lower Oesophageal Sphincter Relaxations

During a transient lower oesophageal sphincter relaxation there is complete vagally-mediated relaxation of both intrinsic and extrinsic sphincter components¹⁵. This differs from swallow induced relaxation of the lower oesophageal sphincter in duration (>10secs) and by the absence of oesophageal peristalsis or a preceding pharyngeal contraction¹⁶. Oesophageal shortening

occurs resulting in the formation of a temporary hiatus hernia and effacement of the gastro-oesophageal flap valve¹⁷.

TLOSRS occur in both healthy individuals and those with reflux disease and are thought to allow venting of air by belching. It is therefore not the occurrence of TLOSRS per se that causes reflux disease but rather a dysregulation of this complex process with an increased proportion of TLOSRS associated with acid reflux in those with GORD¹⁸. The reason for this progression is incompletely understood although one hypothesis is an increased compliance of the gastro-oesophageal junction associated with enlargement of the diaphragmatic hiatus in those with reflux disease.¹⁹ The associated increase in the cross sectional area of the GOJ during opening may limit the ability of the system to protect against reflux and to discriminate between air and liquid refluxate.

1.3.2 Hypotensive Lower Oesophageal Sphincter

Only a minority of patients with gastro-oesophageal reflux disease have a grossly hypotensive lower oesophageal sphincter (<10mmHg) during fasting conditions.²⁰ However many have periods of sphincter hypotension associated with factors that further reduce LOS tone such as gastric distension, certain foods, drugs or smoking. There are two main mechanism by which reflux can occur in association with a hypotensive sphincter.

1. Strain induced reflux: the hypotensive sphincter is overcome by an increase in the gastro-oesophageal pressure gradient. Experimental data suggests a prerequisite basal LOS pressure of below 4mmHg.²¹
2. Free reflux: reflux occurs without an increase in gastro-oesophageal pressure gradient in the context of significant sphincter hypotension (<4mmHg)

1.3.3 Hiatus Hernia

Hiatus hernia is characterised by the proximal displacement of the gastro-oesophageal junction relative to the diaphragmatic hiatus. This is associated with mechanical disruption to the anti-reflux barrier and is a well-recognised risk factor for GORD. Almost all patients with severe GORD have an associated

hiatus hernia and hiatal hernia is seen in up to 77% of patients with Barrett's oesophagus.^{22, 23}

Hiatus hernia causes gastro-oesophageal reflux by a number of different mechanisms^{9 19, 24-27}

- Loss of the gastro-oesophageal flap valve
- Reduced LOS pressure
- Excess acid reflux during transient lower oesophageal sphincter relaxations
- Increased diameter of the diaphragmatic hiatus promoting retrograde flow
- Impaired oesophageal acid clearance.
- Acid trapping within hiatal sac forming a reservoir for refluxate.
- Re-reflux following a peristaltic wave.

In combination these abnormalities render the lower oesophageal sphincter a less effective barrier to reflux of acid and gastric contents.

A hiatus hernia has historically been considered an 'all or none' phenomenon but it is more likely that there is a spectrum of severity with progressive mechanical degradation of the GOJ. At one end of the continuum subtle functional alterations may dominate with increased GOJ compliance¹⁹, loss of LOS-CD synergy²⁸ and weakening of the phreno-oesophageal ligament and at the other frank separation of the sphincter components as overt hiatus hernia. In keeping with this concept several investigators have now demonstrated the intermittent nature of small hiatus hernias in longitudinal and interventional studies.^{29, 30} Developing this further Bredenoord et al demonstrated that the double peaked profile was associated with acidic and weakly acidic reflux suggesting that intermittent hiatus hernia may be an important mechanism of mild reflux³⁰.

1.4 Impaired Oesophageal Acid Clearance

When the reflux barrier is breached, an important determinant of damage to squamous mucosa is the acid exposure time, defined as the length of time the oesophageal pH is below 4. Impaired oesophageal acid clearance occurs by two

broad mechanisms; Defective peristalsis, such as occurs with connective tissue disorders, oesophageal fibrosis or in association with a hiatus hernia and reduced salivation eg in cigarette smokers. The latter also helps to explain the damaging effect of nocturnal reflux since salivation is reduced during sleep and acid contact time in this situation is prolonged.

1.5 Factors Predisposing to GORD

Many factors have been described which promote or aggravate GORD acting through one or more of the mechanisms described above. Obesity for example is thought to contribute to GORD by progressive mechanical disruption leading to hiatus hernia. The rate of TLOSRS is also increased in obesity and an elevated gastro-oesophageal pressure gradient will exploit any impairment of barrier function.

Another well recognised association is pregnancy which acts both via a hormonally mediated reduction in smooth muscle sphincter tone and an increase in mechanical stress on the sphincter. Further associations include increasing age, trauma, oesophageal dysmotility and cigarette smoking. The interplay of these factors is summarised in figure 2. It is likely that *Helicobacter Pylori* confers a protective effect through impaired gastric acid production.

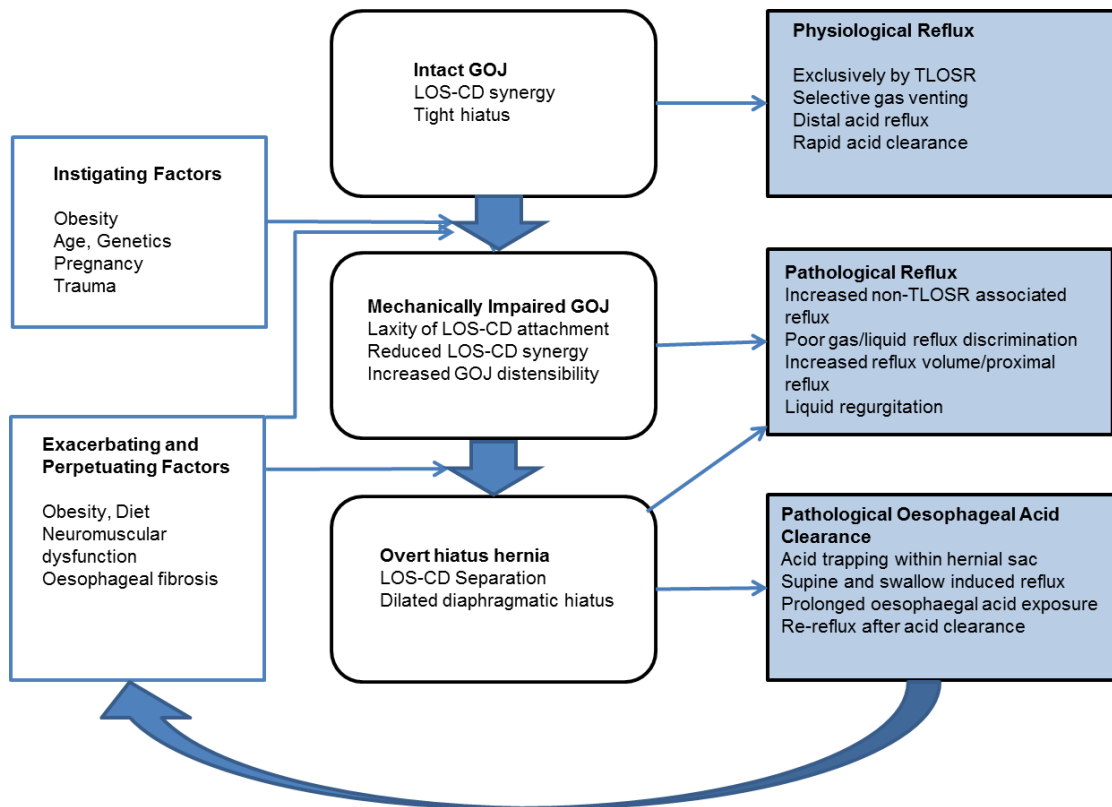


FIGURE 1.2: THE PATHOPHYSIOLOGY OF GASTRO-OESOPHAGEAL REFLUX

1.6 Summary

Gastro-oesophageal reflux disease is a common clinical problem, important both in terms of significant associated morbidity but also due to the devastating complication of oesophageal adenocarcinoma. The pathogenesis is complex and it is likely that the dominant mechanism varies with progressively more severe disease. At the mild end of the spectrum, reflux during transient lower oesophageal sphincter relaxations predominates. With progressive failure of barrier function there is more significant reflux during TLOSRs and increasing non-TLOSR associated reflux. At the severe end of the spectrum lies the overt hiatus hernia with its myriad mechanical failings.

2 The Luminal Environment at the Gastro-oesophageal Junction

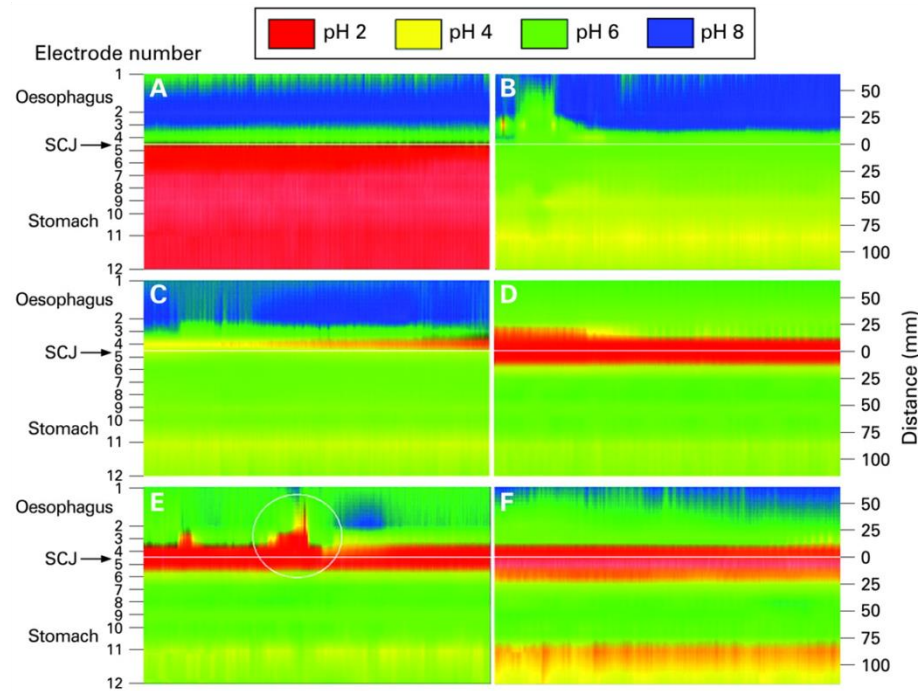
2.1 Background

The gastro-oesophageal junction is disproportionately affected by pathology and whilst we have seen an increase in oesophageal adenocarcinoma we have seen a much greater increase in the incidence of junctional adenocarcinoma³¹⁻³³. Adenocarcinoma is recognised to be a consequence of chronic acid damage and columnar metaplasia of distal squamous mucosa. Over time increasing genetic mutations predispose to neoplasia. However the association between gastro-oesophageal reflux disease and junctional adenocarcinoma is weak. Only 28% have a history of frequent reflux symptoms³⁴ and in one study Barrett's oesophagus was found in only 12% at the time of cancer diagnosis.³⁵ These observations suggest that mechanisms other than traditional reflux may be important.

2.2 The Acid Pocket

A paradox in the pathophysiology of reflux disease is the occurrence of reflux episodes predominantly after a meal when the buffering effect of a meal acts to reduce gastric acidity. This was resolved in 2001 by the description of the acid pocket.³⁶ Using the technique of gastric pull-through, withdrawing a pH catheter in small increments, Fletcher et al demonstrated a region of acidity persisting at the gastro-oesophageal junction after a meal with a pH of 1.6 compared with the intra-gastric pH of 4.7. Oesophageal refluxate after the meal was more acidic than the pH in the body of the stomach establishing this 'acid pocket' as a potential source of post-prandial acidic refluxate. Differences in regional acidity have since been confirmed by numerous investigators using a variety of techniques.^{25, 27, 36-42} Figure 2.1 shows the changes in regional acidity after a meal measured using high resolution pHmetry. Immediately after the meal buffering of intragastric contents is demonstrated, depicted by a neutral pH. With increasing time from the meal a region of acidity emerges close to the squamocolumar junction.

Surface contour plots (each 120 s duration) of high definition 12-electrode pHmetry.



A T Clarke et al. Gut 2009;58:904-909

GUT

FIGURE 2.1: COLOUR CONTOUR PLOTS DEPICTING THE OCCURRENCE OF THE ACID POCKET AFTER THE MEAL. (A) THE FASTING STATE WITH MARKED INTRAGASTRIC ACIDITY. (B) AT 3 MIN AFTER COMPLETION OF THE MEAL, INTRAGASTRIC BUFFERING BY THE INGESTED MEAL IS SEEN. (C) AT 17 MIN AFTER THE MEAL THE EMERGENCE OF THE ACID POCKET AT THE GASTRO-OESOPHAGEAL JUNCTION IS SEEN. (D) AT 43.5 MIN AFTER THE MEAL THE ENLARGING ACID POCKET IS DEMONSTRATED. (E) AT 47.5 MIN AFTER THE MEAL AN ACIDIC REFLUX EPISODE (CIRCLED) FROM THE ACID POCKET IS SEEN WITH SIMULTANEOUS DISTAL INTRAGASTRIC BUFFERING. (F) AT 73.5 MIN AFTER THE MEAL BOTH THE PROXIMAL ACID POCKET AND DISTAL ACIDITY ARE RECORDED SIMULTANEOUSLY. SCJ: SQUAMOCOLUMNAR JUNCTION. (REPRODUCED WITH PERMISSION, BMJ PUBLISHING GROUP, LICENSE NUMBER 3742681210338)

Although this has advanced our current concept of reflux disease as Mitchell et al state in a recent review it is more likely a rediscovery of an old concept.⁴³ In a paper published in 1898, Cannon states: *“In the fundus food near the periphery was acid; food 2cm from the gastric wall showed the original alkalinity”*. Another paper published in the UK by Hurst in 1911 observes *“As no peristalsis and consequently no churning of the contents occurs high in the fundus, the outer layer of chyme remains constantly very acidic”*

2.2.1 Acid as 'Pocket', 'Film' or 'Coat'

In the original description by Fletcher et al the concept was of a pocket or pool of acid in the proximal stomach with in vitro studies confirming the formation of a layer of acid atop gastric contents which will disperse by mixing.³⁶ In vivo the fundus of the stomach relaxes after a meal and there is relatively little motility and mixing allowing persistence of acid in this region.⁴⁴ Studies using MRI have shown the formation of a secretion layer accumulating after a meal at the meal-air interface (Figure 2.2).⁴¹

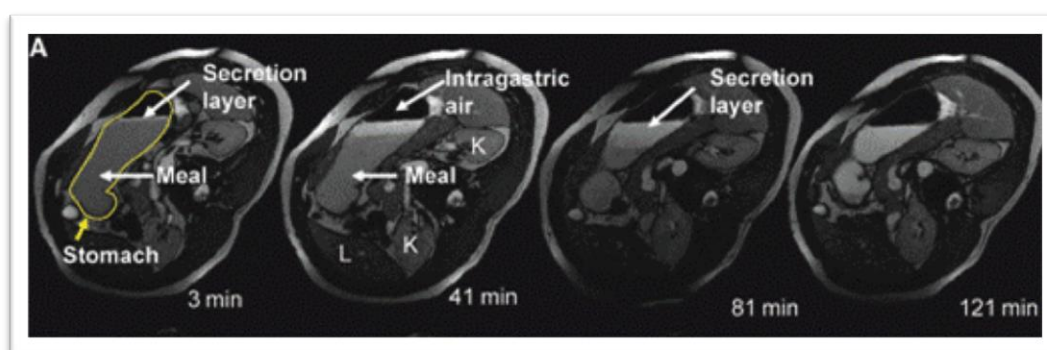


FIGURE 2.2: MRI SHOWING A SECRETION LAYER FORMING ATOP GASTRIC CONTENTS AFTER THE MEAL. THIS LAYER ENLARGES AND ULTIMATELY DISPERSES BY MIXING WITH GASTRIC CONTENTS FROM PROXIMAL TO DISTAL. (REPRODUCED WITH PERMISSION FROM JOHN WILEY AND SONS, LICENSE NUMBER: 374269138312)

Studies using scintigraphy have also been able to locate a pocket of fluid persisting in the proximal stomach after the meal. By aspirating the fluid identified by scintigraphy the authors confirmed that the finding represented an actual volume of fluid with an acidic pH of 1.8.²⁵

An alternative explanation for differences in regional acidity is the 'acid coat'. Acid is secreted from the gastric wall in response to a meal. Post-prandially this region will be most acidic since the lumen is buffered by the presence of food. When the acid pocket was first described and investigated it was by stationary pH pull-through giving a one dimensional view of regional acidity. Interestingly as well as a proximal drop in pH, an acid environment has also been demonstrated in the distal stomach which likely corresponds to where the probe contacts the wall of the greater curvature (Figure 2.3).^{37, 38} In this description

therefore the peripheries of the stomach including the cardia region remain acidic after a meal with a progressive increase in pH towards the middle due to mixing of gastric contents.

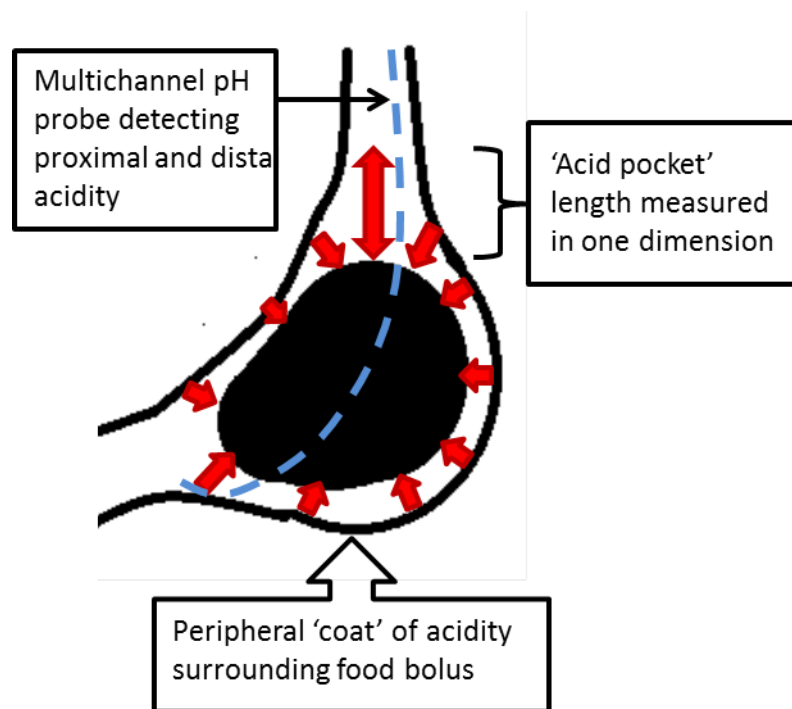


FIGURE 2.3: DEPICTION OF THE 'ACID COAT', A PERIPHERAL ZONE OF ACIDITY SURROUNDING THE CENTRAL FOOD BOLUS AND RELATIVELY UNBUFFERED COMPARED WITH THE GASTRIC LUMEN.

The final model of regional variation in acidity is the 'acid film'. Pandolfino et al described proximal displacement of acid within a closed sphincter in patients with GORD after a meal⁴⁰. The acid was seen to traverse the squamo-columnar junction. They argued that a volume of acid would not traverse a closed LOS but proposed that a 'film' of acid may be the explanation.

Regardless of the terminology, differences in regional acidity after a meal have now been confirmed by numerous investigators and by various modalities. It is likely that these theories are not mutually exclusive but rather overlap with variability attributable to different predispositions to reflux in the populations studied.

2.2.2 Acid Pocket Length

In healthy volunteers the length of the acid pocket has been measured as between 1cm and 3.3cm.^{25, 36, 40} The variability may stem from differences in the techniques employed or the populations studied. There is likely also some variation with time after the meal with Beaumont et al demonstrating a maximum length of 3.3 cm at sixty minutes after the meal with multiple measurements.²⁵

In patients with known gastro-oesophageal reflux disease the acid pocket is lengthened, ranging from 3.0 to 6.5cm in length.^{25, 27, 40} This lengthening represents proximal extension of acid toward or even across the squamo-columnar junction.

2.2.3 Acid Pocket and Association with Hiatus Hernia

Hiatus hernia is a key mediator in the pathogenesis of gastroesophageal reflux through impaired function of the barrier mechanism of the gastro-oesophageal junction and delayed oesophageal acid clearance. Studies suggest hiatus hernia may also contribute to reflux disease through effects on the size and position of the acid pocket.

Two principal studies have described the characteristics of the acid pocket in association with hiatus hernia. Clarke et al demonstrated lengthening of the acid pocket in reflux patients compared with healthy volunteers attributable to the presence of a hiatus hernia²⁷. Beaumont *et al* studied the acid pocket in those with small and large hiatus hernias and controls²⁵. Consistent with the observations of Clarke et al they demonstrated lengthening of the acid pocket in association with hiatus hernia but they argued it was the position of the acid pocket relative to the diaphragm that was the important determinant of reflux. In 40% of those with a large hiatus hernia, the acid pocket was consistently located above the diaphragm whereas in controls and those with a small hiatus hernia it was consistently below the diaphragm. The location of the acid pocket above the diaphragm was a risk factor for acid reflux during transient lower oesophageal sphincter relaxations.

There are likely a number of mechanisms at play causing lengthening of the acid pocket in sliding hiatus hernia. The presence of a hernial sac above the diaphragm will act as a reservoir for acid secreted by the gastric mucosa within the sac. Thus contained, the acid may be protected from the buffering effect of intragastric food and from the dispersing and mixing effect of the proximal stomach. The intrinsic sphincter, deprived of reinforcement from the crural diaphragm, will be more easily breached allowing proximal extension of acid into the distal oesophagus

2.3 Short Segment Reflux

Reflux episodes are conventionally measured 5 cm above the lower oesophageal sphincter. Acid exposure adjacent to the SCJ is less likely than conventionally measured reflux to be symptomatic; ⁴⁵⁻⁴⁷ however, it is potentially of great pathophysiological significance. Recent interest has therefore focussed on acid exposure in this important region.

Oesophageal acid exposure is significantly more frequent close to the squamo-columnar junction. Fletcher et al. first described this concept of 'short segment reflux' noting that oesophageal acid exposure was significantly greater at 0.5cm above the squamo-columnar junction compared with 5.5cm (11.7 vs. 1.8%; $P < 0.001$). ⁴⁸ This difference was even more pronounced for the post-prandial period. In 2008 Merkapti et al extended this observation with a pH profile across the sphincter detailing increased acid exposure for sensors located 1.5 cm above the sphincter compared to 5cm above and progressively increasing acid exposure for sensors traversing the sphincter. ⁴⁹ This finding of distal oesophageal acid exposure or 'short segment reflux' has been widely replicated and also implicated in distal oesophageal pathology ⁵⁰⁻⁵².

2.4 The Concept of Intrasphincteric Reflux

Retrograde flow of acid into the oesophagus requires complete breach of the integrity of the protective gastro-oesophageal junction. However it is plausible that distal squamous mucosa be exposed to acid without complete failure of the lower oesophageal sphincter.

This mechanism was first proposed by and developed by Chandrasoma and deMeester based on post mortem studies⁵³. Our own group in living human subjects has demonstrated shortening of the lower oesophageal sphincter after a meal due to loss of the distal component (Figure 2.4).^{37, 54}

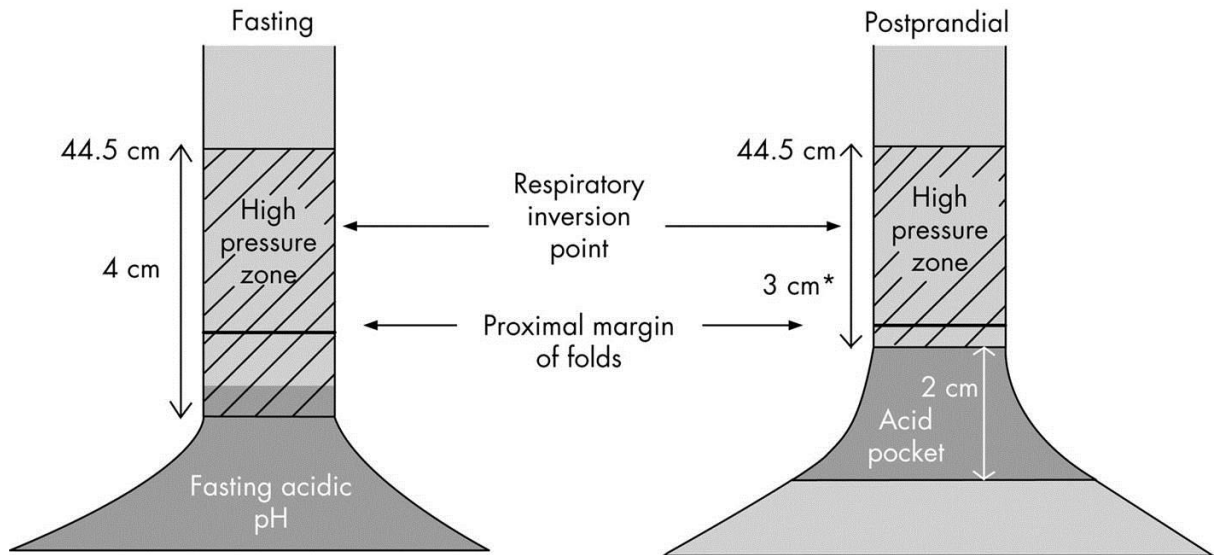


FIGURE 2.4: SIGNIFICANT SHORTENING OF THE HIGH PRESSURE ZONE AFTER THE MEAL DUE TO LOSS OF THE DISTAL COMPONENT OF THE LOWER OESOPHAGEAL SPHINCTER. THE POST-PRANDIAL ACID POCKET HAS MOVED PROXIMALLY TO OCCUPY THE FASTING LOCATION OF THE DISTAL HIGH PRESSURE ZONE THAT OPENED DURING THE MEAL. (REPRODUCED WITH PERMISSION, BMJ LICENSING GROUP, LICENSE: 3742701398297)

This 'distal opening' was associated with acid ingress within the sphincter in the absence of detectable acid measured at the traditional site 5cm above the lower oesophageal sphincter. This mechanism is distinct from transsphincteric reflux in that the proximal sphincter remains closed and only the most distal squamous mucosa is exposed to acid. Acid exposure by the mechanism may be more prolonged in the absence of secondary protective mechanisms such as oesophageal clearance.

2.5 Summary

There is a rising incidence of adenocarcinoma at the gastro-oesophageal junction. The relationship with reflux disease is weak suggesting mechanisms other than traditional reflux may be important. After a meal a region of acidity termed the 'acid pocket' persists at the cardia escaping the buffering effect of

food. There is also loss of the distal component of the lower oesophageal sphincter allowing acid ingress within the sphincter, 'intrasphincteric acid'.

This distal acid exposure may explain how metaplasia of the distal oesophagus is most prevalent at, and immediately proximal to, the SCJ and can occur in subjects without conventional evidence of reflux disease.

3 The Histology of the Gastro-oesophageal Junction

3.1 Epithelial Types in the Oesophagus and Proximal Stomach

There are five epithelial subtypes found to varying degrees at the gastro-oesophageal junction (Table 3.1)

TABLE 3.1: EPITHELIAL TYPES THAT OCCUR IN THE OESOPHAGUS AND PROXIMAL STOMACH

Epithelial Type	Location	Description
Squamous	Only oesophagus	Stratified squamous epithelium
Oxyntic	Only stomach	Columnar epithelium glands composed only of parietal and chief cells
Cardiac	Oesophagus and within 3cm distal to the endoscopically defined gastro-oesophageal junction	Columnar epithelium composed only of mucous cells
Oxyntocardiac	Oesophagus and within 3cm distal to the endoscopically defined gastro-oesophageal junction	Columnar epithelium with glands composed of a mixture of mucous and parietal cells
Intestinal Metaplasia		
Oesophageal Type	Oesophagus and within 3cm distal to the endoscopically defined gastro-oesophageal junction	Goblet cells in cardiac mucosa
Gastric Type	Only stomach	Goblet cells in oxyntic (usually atrophic) mucosa

3.1.1 Squamous Mucosa

The tubular oesophagus is lined by stratified squamous non-keratinised epithelium. (Figure 3.1) Since the principal function of the oesophagus is as a conduit for foodstuff the epithelium is highly adapted, with a capacity to resist shear stress. The multi-layered epithelium gradually changes from the basal cuboidal cells that divide and replenish superficial layers to the flattened surface layers that eventually slough off.

Beneath the epithelium there is a thin layer of connective tissue, the lamina propria containing small lymphatics and blood vessels and scattered mucous glands, and a smooth muscle layer, the muscularis mucosae, a thin layer of longitudinal irregularly arranged muscle fibres.

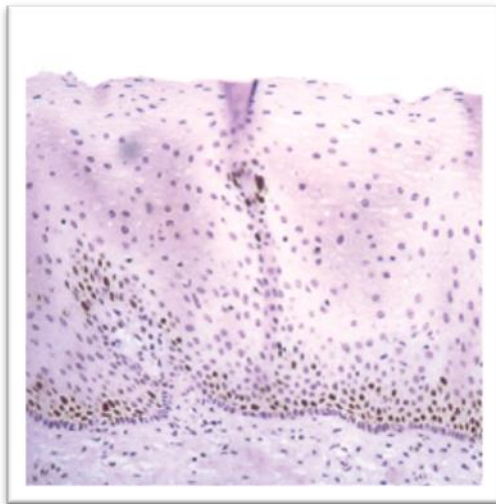


FIGURE 3.1: STRATIFIED SQUAMOUS EPITHELIUM OF THE OESOPHAGUS (REPRODUCED WITH PERMISSION LICENSE NUMBER 3767650624116)⁸

3.1.2 Gastric Oxyntic Mucosa

This is the normal lining of the body and fundus of the stomach (Figure 3.2). Oxyntic gastric mucosa is characterised by:

- A surface layer of mucous cells with small basally located nuclei and uniform apical cytoplasm producing a thick protective coating of mucous
- A foveolar region that extends vertically down from the surface as a pit which is usually very short and lined with mucous cells

- A straight tubular gland that is lined by parietal and chief cells and scattered neuroendocrine cells. There are a few mucous cells in the neck region of the gland but the deeper part is normally devoid of mucous cells.

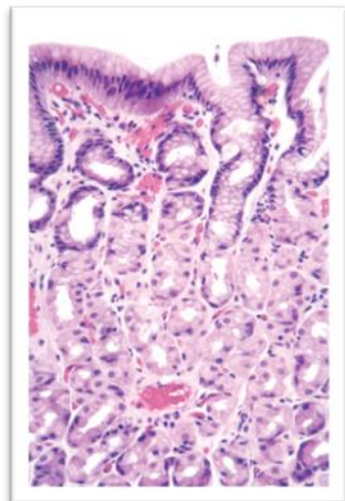


FIGURE 3.2: NORMAL GASTRIC OXYNTIC MUCOSA SHOWING A SHORT FOVEOLAR PIT FROM WHICH ARISES A STRAIGHT TUBULAR GLAND CONTAINING PARIETAL AND CHIEF CELLS WITHOUT MUCOUS CELLS (REPRODUCED WITH PERMISSION. LICENSE NUMBER 3767651282535)

The parietal cell or oxyntic cell is responsible for acid production whilst the chief cells secrete pepsinogen. The glands are tightly packed so there is minimal lamina propria. Normal gastric mucosa is a dynamic epithelium continually renewing from progenitor cells in the deep region of the foveolar pit and isthmus of the gastric gland.

3.1.3 Cardiac Mucosa

Cardiac mucosa is defined as a mucosa composed entirely of mucous cells and devoid of parietal or goblet cells. (Figure 3.3) Cardiac mucosa can have Paneth cells, pancreatic cells and neuroendocrine cells but never parietal or goblet cells.

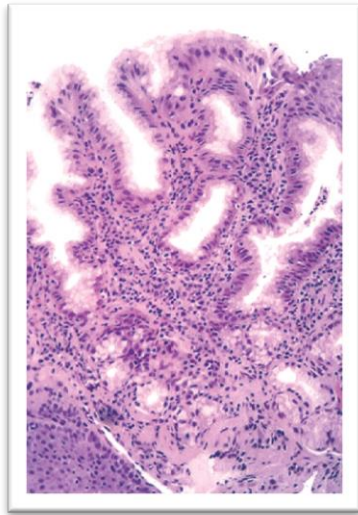


FIGURE 3.3: CARDIAC MUCOSA AT THE SQUAMO-COLUMNAR JUNCTION (LICENSE 3767641501944)8

3.1.4 Oxynto-cardiac Mucosa

Oxynto-cardiac mucosa is defined by the presence of glands that are composed of a mixture of mucous cells and parietal cells. The presence of even a single parietal cell in a single glandular unit excludes cardiac mucosa. Paneth cells, pancreatic cells and neuroendocrine cells may be present in oxynto-cardiac mucosa.

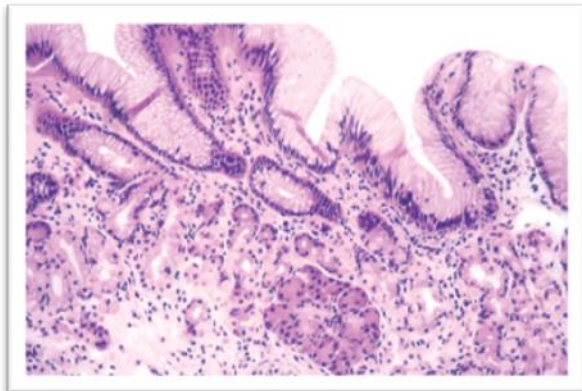


FIGURE 3.4: OXYNTO-CARDIAC MUCOSA SHOWING MILD CHRONIC INFLAMMATION AND SHORT, SLIGHTLY DISTORTED GLANDS CONTAINING A MIXTURE OF MUCOUS AND PARIETAL CELLS (REPRODUCED WITH PERMISSION: 3767670067402)

3.1.5 Intestinal Metaplastic Epithelium

The hallmark of intestinal metaplasia is the presence of well-formed goblet cells, which may be present in the surface epithelium or the foveolar region.

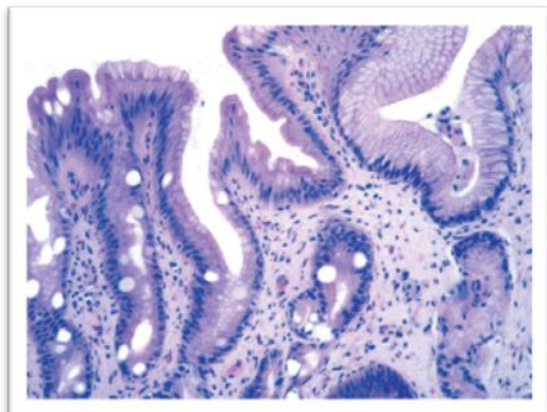


FIGURE 3.5: INTESTINAL METAPLASIA SHOWING TYPICAL GOBLET CELLS. (REPRODUCED WITH PERMISSION 3767670410775)

Intestinal metaplasia may occur in the oesophagus or the stomach. Histologically intestinal metaplasia of the oesophagus is defined by the presence of goblet cells in cardiac type mucosa and is the result of the effect of gastro-oesophageal reflux on the mucosa. Gastric intestinal metaplasia occurs on a background of gastric oxyntic mucosa and is mainly seen with atrophic gastritis due to *Helicobacter pylori*, autoimmune gastritis and in the healing phase of erosive lesions.

3.2 Defining the Cardia

Whilst the histological description of epithelial subtypes is clear what constitutes a normal gastro-oesophageal junction is controversial even amongst experienced pathologists. Until recently it was commonly believed that the distal 1-2 cm of the oesophagus was lined with a transitional zone of columnar epithelium extending for a variable extent into the stomach as the gastric cardia⁵⁵. This concept persisted until 1994 when Spechler et al demonstrated the presence of intestinal metaplasia in the distal 2cm of columnar lined oesophagus redefining this mucosa as short segment Barrett's oesophagus.⁵⁶

The accepted endoscopic criterion for the transition from oesophagus to stomach is the proximal limit of the gastric folds.⁵⁷⁻⁵⁹ In normal individuals this coincides with the squamo-columnar junction, 'Z line', and histological transition from squamous to columnar type mucosa. Many investigators therefore define the cardia as the most proximal region of the stomach. Thus any biopsy from this region would be 'cardiac mucosa' and accordingly a mix of phenotypes and characteristics have been reported.^{60, 61}

Chandrasoma proposed stricter definitions based purely on the histological classification as outlined above and therefore easily reproducible.^{8, 53} Defined in this way cardiac mucosa is simply columnar mucosa devoid of parietal cells.

3.2.1 Is Cardiac Mucosa Universally Present?

As the definition of the cardia has evolved so too has a debate over its origins. The original description of 'normal' columnar epithelium in the distal oesophagus, although now disproven, introduced the concept of a transitional zone of columnar tissue devoid of acid producing cells. Such a zone would have a protective function separating vulnerable squamous mucosa from the gastric body mucosa densely packed with parietal cells. This idea of an innate transitional zone measuring 2-3cm has been perpetuated in medical teaching.

In an autopsy study published in 2000, Chandrasoma examined the entire circumference of the gastro-oesophageal junction including the vertical extent of the various epithelial types.⁶² The cardiac mucosa was completely absent in 10 of 18 subjects with direct transition from squamous to parietal cell-containing mucosa, either oxyntic or oxynto-cardiac. The maximum cardiac mucosal length ranged between 0 and 2.75mm.

Studies in children and adults are now numerous^{61, 63-67} and yet disagreement persists over whether the cardia is an innate or abnormal epithelium. In a study of a paediatric population, Glickman et al reported the presence of cardiac mucosa in 81% of 74 patients and oxynto-cardiac in the remainder with no patients in this study group transitioning directly from squamous to oxyntic mucosa⁶⁴. The authors concluded that their findings supported a congenital origin for the cardia. Similarly Zhou and colleagues and Kilgore and colleagues

support the concept of the gastric cardia as an innate structure describing its universal presence in paediatric populations.^{67, 68} These studies have been criticized for imprecise definitions and in fact when the strict definition of cardiac mucosa is applied to the former study by Zhou et al its presence was demonstrated in only 22 of the 45 post-natal patients.

In endoscopy samples in adult populations the cardiac mucosa has been deemed to be absent in 26 to 39% with direct transition from squamous to oxynto-cardiac or pure oxyntic mucosa.^{63, 65, 66} Autopsy studies allow for more detailed mapping and in one study of 36 patients, cardiac mucosa was present in the entire circumference of the squamo-columnar junction in 20, in part of the circumference in 15 and entirely absent in one case.⁶⁹

Variations in estimates may arise through populations studied, methodology and definitions. However when these studies are taken together it is reasonable to conclude that cardiac mucosa is not universally present.

3.2.2 What is the Significance of Cardiac Mucosa?

Cardiac mucosa where present is minimal in paediatric populations and increases in length with age⁶². Characteristics of the cardia are also influenced by measures of gastro-oesophageal reflux disease. Oberg et al associated the presence of cardiac mucosa and carditis with several indicators of reflux disease including an abnormal 24 hour pH score and the presence of hiatal hernia or erosive oesophagitis.⁶⁶ Glickman and colleagues described lengthening of the cardiac mucosa in association with active oesophagitis.⁶⁴

In a study of the characteristics of the cardia in 141 patients, Der and colleagues demonstrated that the cardia was universally chronically inflamed whilst most patients had no inflammation in body or antral biopsies⁷⁰. Furthermore the extent of inflammation was correlated with higher acid exposure by 24 hour pH monitoring.

In contrast studies on subjects with a lower propensity towards reflux for example normal autopsy populations⁶² and biopsies obtained from patients more

likely to have a normal gastro-oesophageal junction at endoscopy (REF Jain) demonstrate a lower prevalence of cardiac mucosa.

Thus where present the characteristics of the cardia are influenced by the clinical characteristics of the subjects studied.

3.2.3 What is the Significance of Cardiac Mucosal length?

There is a relationship between cardiac mucosa length and measures of reflux in those without endoscopic evidence of columnar lined oesophagus. In the study by Glickman et al the presence of more than 1mm of cardiac mucosa had a significantly greater association with reflux than those with less than 1mm of cardiac mucosa.⁶⁴ Oberg and colleagues, as well as demonstrating inflammation in the cardiac mucosa demonstrated a progressive increase in acid exposure as the length of cardiac plus oxyntocardiac mucosa increased.⁶⁶ In a more recent study in an Eastern population the presence of cardiac mucosa at the gastro-oesophageal junction was associated with endoscopically apparent oesophagitis.

71

Barrett's oesophagus arises from columnar metaplasia of oesophageal squamous mucosa. Histologically there are three main epithelial components; cardiac mucosa, oxyntocardiac mucosa, and intestinal metaplasia (cardiac mucosa with goblet cells). There is a well described relationship between the length of Barrett's oesophagus and severity of reflux⁷² which continues as the length of columnar lined oesophagus increases.⁷³

These parallel observations have led some to propose that cardiac mucosa is an abnormal epithelium arising from squamous to columnar metaplasia in the same way as Barrett's oesophagus.⁷⁴

3.3 Summary: The Acquired Cardia Hypothesis

Cardiac mucosa, defined as columnar epithelium devoid of parietal cells is not universally present. Where present it increases in length with age and with markers of gastro-oesophageal reflux disease. Histologically it is

indistinguishable from endoscopically apparent columnar lined oesophagus and may represent an early stage of squamous to columnar metaplasia.

4 Obesity and Adenocarcinoma of the Cardia

4.1 Epidemiology

Whilst the incidence of many solid tumours has been in decline over the past thirty years, there has been a dramatic and continued rise in the incidence of oesophageal adenocarcinoma and adenocarcinoma of the gastro-oesophageal junction⁷⁵. Data from the USA has shown that the overall incidence of adenocarcinoma of the oesophagus and gastric cardia increased from 13.4 per million in 1973 to 51.4 per million in 2009 and continues to rise⁷⁶. For gastric cardia adenocarcinoma incidence has risen from ten cases per million population in 1973 to over 20 cases per million population in 2010. Data from other Western countries has shown similar trends.

The rise in oesophageal adenocarcinoma and adenocarcinoma of the gastric cardia has been paralleled by a worldwide obesity epidemic leading to speculation of a causative relationship. Recent data from the USA show that 68% of the population over twenty years old are defined as overweight and 32% as obese⁷⁷. In Scotland in 2014 figures were remarkably similar with 65% of adults aged 16 and over defined as overweight, including 28% who were obese.⁷⁸ These trends are echoed throughout the Western world.⁷⁹

4.2 Obesity and Gastric Cardia Adenocarcinoma: Is there a link?

Obesity comes with a myriad of health consequences including an association with cancers of the colon and rectum, renal cell carcinoma, malignant melanoma and liver cancer⁸⁰. One of the most strongly associated cancers is oesophageal adenocarcinoma with a recent meta-analysis giving an odds ratio of 2.73 for a BMI of 30kg/m² or more⁸¹.

There is also an accumulating literature on the relationship between obesity and adenocarcinoma of the gastric cardia with most studies demonstrating a positive association between increasing BMI and cancer risk and many showing evidence of a dose response relationship.⁷⁵ The earliest report of a positive relationship was a case control study in a Chinese population by Ji et al in 1997 where men in

the fourth quartile (highest) BMI group were found to have an odds ratio of 3.0 for gastric cardia cancer compared with those in the first quartile.⁸² Similarly Chow et al the following year, this time in a Western population demonstrated an increasing risk of gastric cardia cancer with increasing body mass index.⁸³ Several studies have since confirmed this trend in populations from the USA and Europe with odds ratios ranging from 1.46 to 4.3⁸⁴⁻⁹⁰

There have been two negative studies published. The first by Tran and colleagues in a Chinese population was a large prospective cohort study of 1089 cases.⁹¹ The study was in a population at generally lower risk of oesophageal and gastric adenocarcinoma but has also been criticised for a complex design including dietary intervention.⁷⁵ In another large study examining the influence of obesity on multiple cancer types Semanic and colleagues found an elevated risk for oesophageal adenocarcinoma but did not demonstrate a relationship for the 229 cases of cardia cancer⁸⁰.

Studies are heterogeneous in design and plagued by inconsistencies in definitions but nonetheless 9 of 11 studies summarised in a recent review demonstrated a positive association between obesity and gastric cardia adenocarcinoma.⁷⁵ This was confirmed in a meta-analysis where obesity was associated with gastric cardia adenocarcinoma with a relative risk of 1.93 (95 % CI 1.52-2.45).⁸¹

4.3 Is All Fat Equal?

There is increasing recognition of the importance of body fat distribution in cancer risk and central or visceral obesity has attracted particular interest. Rates of obesity have been rising in men and women and across ethnic groups. However the incidence of oesophageal adenocarcinoma and gastric cardia adenocarcinoma varies by race and gender.^{92, 93}

This apparent discord may be explained by variations in the distribution of body fat by race and gender. For example body fat is characteristically more visceral than truncal in men and Caucasians, two groups at higher risk of adenocarcinoma of the oesophagus. Several studies have now documented an excess risk of

oesophageal adenocarcinoma in association with measures of central obesity.^{85, 94, 95}

For adenocarcinoma of the gastric cardia three recent studies have examined the risk associated with the central pattern of fat distribution.^{85, 94, 95} O'Doherty and colleagues found an association for both waist circumference and BMI with gastric cardia adenocarcinoma⁹⁵ whilst Corley et al failed to demonstrate an association using abdominal diameter as an index of central obesity.⁸⁵ Most recently, using data from almost 400,000 individuals from the European Prospective Investigation into Cancer and Nutrition (EPIC) study, investigators demonstrated an association between gastric cardia adenocarcinoma and waist circumference only after adjustment for BMI.⁹⁴

4.4 Obesity and Gastric Cardia Adenocarcinoma: What is the link?

4.4.1 Gastro-oesophageal reflux disease

Obesity is a recognised risk factor for gastro-oesophageal reflux disease and there is, in turn, a well-documented relationship between gastro-oesophageal reflux disease and oesophageal adenocarcinoma.^{60, 96} However the data linking reflux symptoms with adenocarcinoma at the cardia are either more modest or conflicting. Derakhshan and colleagues reported on 53 cases of adenocarcinoma of the gastric cardia finding an odds ratio of 10.0 (95% CI 2.29-44.36) for frequent symptoms of gastro-oesophageal reflux disease compared with age matched controls.⁹⁷ However a larger case-control study including 261 cases of adenocarcinoma of the cardia failed to find a link with symptoms of gastro-oesophageal reflux.⁹⁸ Lagergren and colleagues in 1999 reported a relatively weak association between symptoms of reflux and cardia cancer with an odds ratio of 2.0 (95% CI 1.4-2.9) but a much higher odds ratio of 7.7 (95% CI 5.3-11.4) for oesophageal adenocarcinoma and in 2003 Wu et al reported similar findings.⁹⁶

Therefore despite the epidemiological evidence indicating that adenocarcinoma of the gastro-oesophageal junction in the Western world is the result of acid reflux, there is only a weak association between these cancers and reflux symptoms. This raises the question as to whether the most distal oesophagus

may be subject to damage by gastric acid in the absence of reflux symptoms or traditional reflux disease.

4.4.2 The Use of Acid Suppressing Medications

There is a theory linking the use of acid suppressing medications to the rising incidence of oesophageal cancer and therefore also potentially to gastric cardia adenocarcinoma. The use of these medications became widespread in the 1970s coincident with the start of the rise of oesophageal and gastric cardia adenocarcinoma. Although there are some supportive data^{99, 100} and a plausible mechanism in elevated gastrin levels, this theory has not gained general support.

4.4.3 Diabetes mellitus

There is a slight excess risk of gastric cancer associated with a diagnosis of diabetes mellitus with an odds ratio of the order of 1.1 to 1.2.¹⁰¹ Whether this extends to adenocarcinoma of the gastric cardia is less clear. This has been specifically examined in three studies, two of which failed to demonstrate an independent relationship between diabetes mellitus and gastric cardia adenocarcinoma.^{102, 103} In the third an association was seen between obesity and gastric cardia adenocarcinoma but not with oesophageal adenocarcinoma, directly contradicting the findings of the other studies.¹⁰⁴ This suggests that the observed relationship between gastric cardia adenocarcinoma and obesity is unlikely to operate entirely through a comorbid diagnosis of diabetes mellitus.

4.4.4 Diet

Diet is an important potential confounder in a relationship between obesity and gastric cardia adenocarcinoma. Although there are some conflicting studies the literature is generally supportive of a beneficial effect of fruit and vegetable intake and a deleterious effect of starchy foods, meat and fats.¹⁰⁵ Studies of diet are difficult to interpret due to recall and reporting bias.

4.4.5 Helicobacter Pylori

There is a well-established positive association between distal gastric cancer and infection with *Helicobacter pylori*. On the other hand gastric cardia

adenocarcinoma, like oesophageal adenocarcinoma has been negatively associated with H. Pylori with an odds ratio of 0.5-1.0, thought due to increased acid production by a healthy (non-atrophic) stomach.^{97, 106, 107} Is it possible that the association between obesity and gastric cardia adenocarcinoma is operating through the influence of H. pylori on both variables?

There are some data suggesting that H. pylori infection impacts on appetite through effects on gastric atrophy and grehlin production, a hormone involved in appetite stimulation.¹⁰⁸ In support of this, one study showed significant weight gain after successful eradication of H. pylori in dyspeptic patients.¹⁰⁹ The authors attributed this finding to the improvement in dyspeptic symptoms but others have speculated that eradicating H. pylori may impact appetite regulation.⁷⁵ Other studies have failed to show an association between BMI and H. Pylori status.¹¹⁰ There is therefore weak but inconclusive evidence that eradicating H. pylori may promote obesity and this area requires further study.

4.5 Potential Mechanisms

For oesophageal adenocarcinoma there are two competing models of carcinogenesis associated with obesity; the humoral model and the mechanistic model and it is likely that the same principles apply to gastric cardia adenocarcinoma.

4.5.1 Metabolic Model

Adipose tissue is metabolically active secreting various biologically active products that promote inflammation and insulin resistance. The proposed mechanisms linking obesity to cancer include hyperinsulinaemia and altered insulin growth factor 1 (IGF 1) signalling, growth factors produced by adipocytes (adipokines) and the pro-inflammatory effects of obesity.¹¹¹

Insulin and IGF-1 Signalling

Obesity is associated with insulin resistance and increased circulating levels of insulin and IGF 1.¹¹² This is at least partly driven by secretions from metabolically active visceral fat. Both insulin and IGF-1 can bind to the IGF

receptor complex, stimulating pathways that promote cellular proliferation.¹¹² Insulin resistance has been associated with an increased risk of progression to adenocarcinoma in patients with Barrett's oesophagus.¹¹³ In resection specimens from patients with oesophageal adenocarcinoma IGF-1 receptor expression was increased in viscerally obese patients and associated with higher circulating levels IGF-1.¹¹⁴ However in a longitudinal study of patients with Barrett's oesophagus no association was seen between levels of IGF-1 or of the principal binding protein (IGFBP3) and risk of oesophageal adenocarcinoma.¹¹⁵

Adipokines

Adipose tissues synthesise and secrete polypeptide growth factors and cytokines known as adipokines. Of these, adiponectin and leptin are the best studied in relation to carcinogenesis in the GI tract. Adiponectin normally opposes proliferation and angiogenesis and has anti-inflammatory properties. Its level is reduced in association with obesity and also with oesophageal adenocarcinoma and gastric cardia adenocarcinoma.^{111, 116} Leptin on the other hand, which stimulates cell growth and proliferation and angiogenesis, has been associated with the risk of progression from Barrett's oesophagus to oesophageal adenocarcinoma.¹¹³ Its level is elevated in gastric cardia adenocarcinoma and levels have been shown to correlate with histological stage and outcome¹¹¹.

Meta-inflammation

Obesity is associated with chronic low grade inflammation, also called meta-inflammation.¹¹¹ This is related to the secretion of a variety of pro-inflammatory mediators by the adipose tissue including tumour necrosis factor- α (TNF- α), IL-1, IL-6, IL-8, interferon- β and monocyte chemoattractant protein 1 (MCP-1). It is not completely understood how the associated systemic inflammatory response promotes cancer but simplistically many of these mediators promote cell proliferation, inhibit apoptosis and stimulate angiogenesis¹¹². How this systemic inflammatory process might translate into an increased risk of cancer in the oesophagus or gastric cardia is not clear but faecal calprotectin is also elevated in association with obesity indicating chronic low grade inflammation in the gastrointestinal tract.¹¹⁷

4.5.2 Mechanistic Model

Although the humoral model is attractive it does not explain why the effects of obesity should be so marked in the distal oesophagus and gastro-oesophageal junction. Obesity is associated with an array of assaults on the gastro-oesophageal junction and consequent mechanical stress.

Obesity, particularly visceral obesity has been associated with increased intra-gastric pressure.¹¹⁸⁻¹²⁰ Although there is a concomitant rise in intra-oesophageal pressure this does not offset the rise in intra-gastric pressure and there is an overall increase in the gastro-oesophageal pressure gradient. This enhances the likelihood of reflux of gastric contents in the setting where the barrier function of the lower oesophageal sphincter is compromised.

Obesity simultaneously impacts on gastro-oesophageal junction integrity in a more complex manner than simple pressure changes¹²¹. Where the intra-abdominal pressure is artificially elevated for example by extrinsic compression or straight leg raising the pressure of the intrinsic lower oesophageal sphincter is either preserved or increased.^{122, 123} This is thought due either to reflex crural contraction and reinforcement¹²³ or passive external compression of the intra-abdominal segment of the distal oesophagus¹²². In the setting of chronic obesity however the pressure of the intrinsic lower oesophageal sphincter is reduced.^{119, 120} What is the explanation for this discrepancy? This may represent a process of adaptation to chronically elevated intra-abdominal pressure associated with obesity as distinct from an acute pressure challenge. Alternatively it could be an early manifestation of a hiatus hernia¹²¹.

Obesity is associated with the presence of hiatus hernia which in turn is a well-recognised determinant of reflux disease. In a recent meta-analysis involving 3597 patients increased BMI was associated with a hiatus hernia with a pooled odds ratio of 1.93.¹²⁴ Smaller hiatus hernias are likely to be more common but less readily detected. Pandolfino and colleagues have demonstrated an increased likelihood of separation of intrinsic and extrinsic components of the lower oesophageal sphincter in association with obesity.¹¹⁹ Integrating these observations De Vries et al suggested that elevated intra-abdominal pressure

acting through chronic stress on the gastro-oesophageal junction predisposes to hiatus hernia formation, a well-documented determinant of reflux¹¹⁸.

Furthering this observation work from Lee and colleagues has shown a proximally positioned squamo-columnar junction within the diaphragmatic hiatus in obese versus non-obese asymptomatic subjects.¹²⁵ In obese subjects the squamo-columnar junction was consistently 2-3 cm above the crural diaphragm but not beyond the upper border of the GOJ. This was observed without obvious evidence of separation of gastro-oesophageal junction pressure components manometrically, considered the hallmark of overt hiatus hernia. The authors interpreted these findings as the presence of 'partial hiatus hernia', an early, minimal but discernible hiatus herniation that occurs in asymptomatic subjects with obesity.¹²⁵

Another potential mechanism by which obesity could predispose to gastro-oesophageal reflux is through transient lower oesophageal sphincter relaxations. In one study, obese subjects had increased frequency of transient lower oesophageal sphincter relaxations and an increased proportion associated with acid reflux¹²⁶. Although further studies have failed to confirm the former observation there is more consistent evidence of the latter.^{121, 125} This may relate to the presence of an elevated gastro-oesophageal pressure gradient in the obese exploiting deficiencies of the anti-reflux barrier or indeed the presence of a partial hiatus hernia with earlier opening of the lower oesophageal sphincter.¹²¹

The effects of obesity on the acid pocket are unknown. However obesity is associated with hiatus hernia which in turn is associated with lengthening of the acid pocket.²⁷ It is likely that this will also hold true for obesity.

These mechanistic analyses assume that the lower oesophageal sphincter has to fail completely for acid reflux and damage to occur. However as discussed in Chapter 2 there is accumulating evidence that distal squamous mucosa can be exposed to acid in the absence of complete breach of the lower oesophageal sphincter termed 'intrasphincteric reflux'. This mechanism may help reconcile the poor correlation between symptoms of reflux and gastric cardia

adenocarcinoma. How obesity may contribute to this process has not been well studied. Conceivably obesity, through increasing the intra-gastric pressure could contribute to opening of the distal sphincter promoting acid influx.

4.6 An integrated model of carcinogenesis of the gastro-oesophageal junction

Given the wealth of accumulating literature and associated controversies how can we integrate these observations into a model of obesity related carcinogenesis at the gastro-oesophageal junction? Central to the pathway is the progression from normal squamous mucosa to columnar metaplasia and eventually adenocarcinoma. It is likely that the mechanism of acid exposure varies. At one end of the spectrum lies the mechanically dysfunctional gastro-oesophageal junction with a myriad of impairments the result of chronic stress caused and perpetuated by obesity. At the other end more subtle and presumably more common abnormalities allowing distal acid damage through distal opening of the sphincter and intrasphincteric reflux, likely with a contribution from a partial hiatus hernia.

By either pathway damage to squamous mucosa could over time cause progression to columnar metaplasia with the attendant risk of adenocarcinoma promoted perhaps by the metabolic disturbances associated with obesity.

5 Aims and Methods

5.1 Aims

The aim of these studies was to investigate the anatomy, physiology and histology of the gastro-oesophageal junction in healthy volunteers without known gastro-oesophageal reflux disease. In particular:

1. To determine the influence of obesity on the cardiac mucosal length
2. To examine acid exposure at the gastro-oesophageal junction in relation to measures of obesity
3. To investigate the barrier function of the gastro-oesophageal junction in obese and non-obese volunteers
4. To study the pathophysiology of acid reflux in those healthy volunteers found incidentally to have a hiatus hernia but without known reflux disease.

In the course of the study it was observed that there was a progressive alteration in the pressure recordings taken using the high resolution manometry system. Thus a secondary aim was to investigate and document this potential error and to develop and assess a correction method.

5.2 Methods

5.2.1 Recruitment

Volunteers were recruited by word of mouth and by advertisement in the local newspaper. Potential volunteers were invited to attend for a urea breath test for *Helicobacter pylori* and were screened for eligibility. Those found positive for *H. Pylori* were excluded from participation in the study. Others were asked to complete a brief questionnaire to determine any history of reflux symptoms and current or past use of acid suppressing medications. Past medical history and drug history was documented as was history of smoking and alcohol use and past history of obesity. The symptom assessment was adapted from the Leeds dyspepsia questionnaire.^{127, 128} A sample questionnaire is shown in appendix 2.

Those found to have a hiatus hernia during the study protocol were analysed separately

5.2.2 Upper GI Endoscopy

Subjects attended after an overnight fast. The procedure was undertaken with local anaesthetic throat spray (xylocaine 1%) or conscious sedation (intravenous midazolam 1-4mg) according to volunteer preference. The anatomy of the upper GI tract was examined and any abnormalities documented.

- Hiatus hernia was defined as present where the indentation made by the crural diaphragm was separated by 2cm or more from the top of the gastric folds, recognised as the endoscopic landmark of the gastro-oesophageal junction.
- Barrett's oesophagus was diagnosed where columnar mucosa was seen endoscopically proximal to the top of the gastric folds.

Biopsies were taken across the squamo-columnar junction using large capacity radial jaw forceps 4 (Boston Scientific, Hemel Hempstead, Herts, UK). Biopsies were taken perpendicular to the Z line and targeted to include just enough squamous mucosa to confirm positioning with an emphasis on capturing a full span of cardiac mucosa (Figure 5.1).

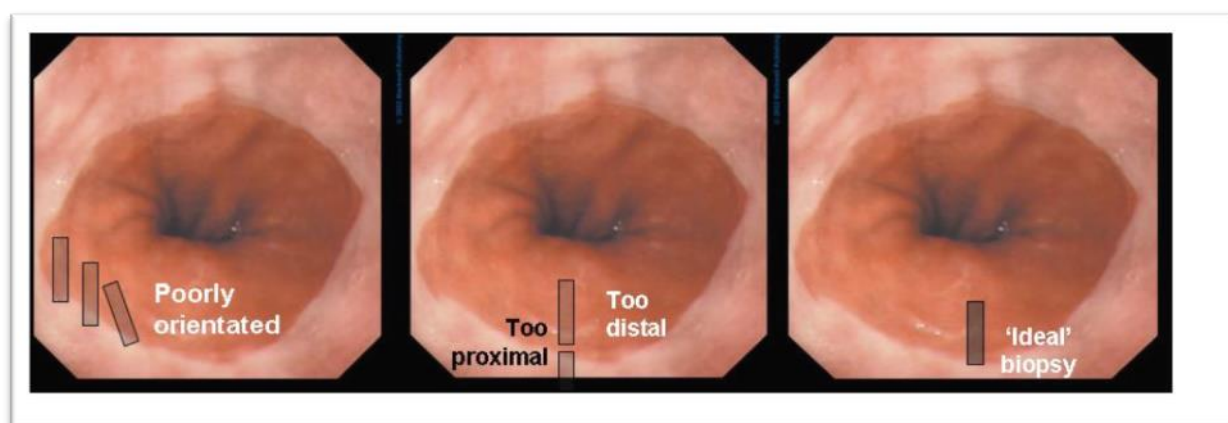


FIGURE 5.1: ENDOSCOPIC TARGETTING OF BIOPSIES ACROSS THE SQUAMOCOLUMNAR JUNCTION INDICATING OPTIMAL POSITIONING

To maximise the chances of successfully capturing the cardia intra-procedure pathological feedback was available. Biopsies obtained were immediately examined by simple light microscopy to determine that squamous mucosa and glandular mucosa were present within the same biopsy and in continuity. Up to three biopsies were taken to maximise the chances of obtaining a full span of cardiac mucosa within at least one biopsy allowing accurate length measurement.

Further biopsies were taken from the antrum and body of the stomach for comparison. Finally two endoclips were applied to the squamo-columnar junction as markers for subsequent fluoroscopic visualisation ((HX-610-135; Olympus, Southend-on-Sea, UK). See also appendix 1.

5.2.3 Biopsy Orientation and Processing

Biopsy specimens were placed immediately on dental wax, which has a non-adherent surface, and oriented flat. An isotonic solution of Hyoscine N butyl bromide (1 mg/mL) was applied to minimize sample contraction and preserve the length. Biopsy specimens were transferred to filter paper using a non-touch technique and re-oriented where necessary (Figure 5.2). Samples were transported in formalin and embedded in agar on the filter paper without further manipulation.

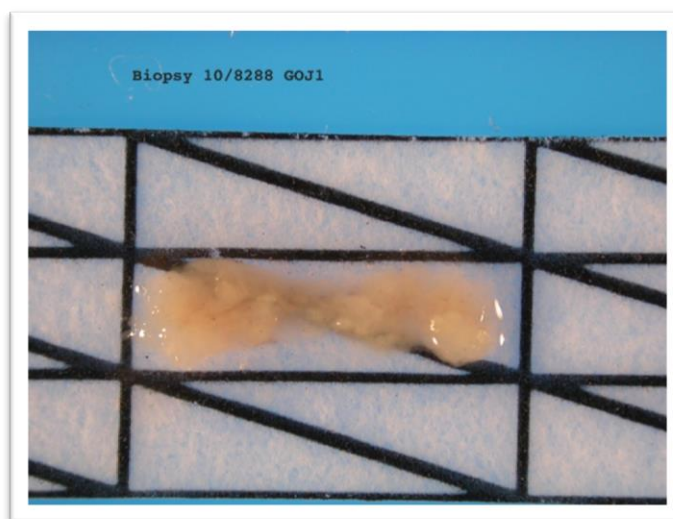

FIGURE 5.2: SAMPLE BIOPSY OBTAINED FROM SQUAMOCOLUMNAR JUNCTION AND CAREFULLY ORIENTATED ON FILTER PAPER.

5.2.4 Staining and Immunophenotyping of Biopsies

All biopsies were stained with H&E for initial assessment. Further staining was carried out using a panel of antibodies selected to evaluate the immunohistochemical staining pattern of the gastro-oesophageal junction:

- CDX-2 (caudal type homeobox 2) –a marker of epithelial intestinal differentiation;¹²⁹
- Villin—essential for brush border formation in normal intestinal epithelial cells¹³⁰ and with differential expression in cardiac type mucosa versus Barrett's mucosa with intestinal metaplasia;¹³¹
- Liver-intestine (LI)-cadherin—a sensitive marker of intestinal metaplasia in the upper GI tract;¹³²
- Trefoil factor family 3 (TFF-3)—a marker of intestinal differentiation, strongly expressed in Barrett's mucosa with intestinal metaplasia¹³³
- MUC1, a membrane—associated mucin apoprotein
- MUC2; a marker of mucin cell differentiation associated with intestinal type mucosa
- MUC5AC—a marker of mucin cell differentiation associated with normal gastric mucosa

To assess the extent of cell replication, we used MIB-1 antibodies against Ki-67 antigens.^{134 97}

TABLE 5.1: ANTIBODIES USED FOR IMMUNOHISTOCHEMISTRY

Antibody	Manufacturer	Product	Type	Specificity	Dilution
CDX-2	Leica Biosystems	NCL-CDX2	Mouse monoclonal	Human	1:100
Villin	Abcam	ab133510	Rabbit Monoclonal	Human	1:1000
TFF-3	Abcam	ab109104	Rabbit monoclonal	Human	1:1000
LI-cadherin	Abcam	ab109220	Rabbit monoclonal	Human	1:1000
Ki-67 (MIB-1)	DAKO	IR62661	Mouse monoclonal	Human	1:500
MUC-1	Leica Biosystems	NCL-MUC-1core	Mouse monoclonal	Human	1:500
MUC-2	Leica Biosystems	NCL-MUC-2	Mouse monoclonal	Human	1:1000
MUC-5ac	Leica Biosystems	NCL-MUC-5ac	Mouse monoclonal	Human	1:1000

CDX-2, caudal type homeobox 2; LI, liver-intestine; MUC, mucin; TFF-3, trefoil factor family 3.

Formalin-fixed paraffin-embedded (FFPE) sections cut at 3 µm floated out on a water bath at 56°C were collected on silane-coated glass slides, put in a metal rack and dried at 60°C in a fan-assisted oven for 1 h. Slides were then transferred to plastic slide racks for use with the DAKO autostainer with reagents from the DAKO EnVision FLEX+ Mouse High pH kit (DAKO K8002). Deparaffinisation and rehydration were followed by heat-induced epitope retrieval with DAKO High pH EnVision FLEX Target Retrieval Solution (1:50 in deionised water). The slides were placed in a retrieval bath heated to 85°C, then 100°C for 20 min, then 70°C for 15 min before transfer to phosphate-buffered saline (PBS) at room temperature for 5 min. All staining was carried out in the DAKO autostainer. Endogenous peroxidase was blocked using DAKO EnVision FLEX peroxidase blocking reagent for 5 min. The sections were then washed in PBS for 5 min. After titration and optimisation, the primary monoclonal antibodies were diluted in DAKO diluent. Antibodies were incubated for 30 min then washed in PBS for 5 min. A negative control was diluent alone

for each run. A polymer-based detection system was used: EnVision FLEX/HRP. Sections were incubated for 30 min then washed for 5 min in PBS.

Visualisation used diaminobenzidine (DAB) (20 drops concentrate/20 mL of DAB substrate buffer) applied twice×5 min. After washing in PBS (5 min), DAB staining was enhanced in 0.5% copper sulfate/0.9% saline solution for 5 min. Sections were counterstained with haematoxylin, then coverslipped.

5.2.5 MRI Studies

Scans were performed before and after a standardised meal consisting of battered fish and chips using the Phillips T1.5 scanner. For fat quantification, images were taken in three axial planes at the levels of the third, fourth and fifth lumbar vertebrae and examined independently by two GI radiologists. Fat quantification was performed using commercially available software (Tomovision Slice-o-matic, Magog, Quebec, Canada). This software allows segmentation of different tissue types, in this case visceral and subcutaneous fat and accurate volume measurement. An example axial scan is shown in Figure 5.3 with the subcutaneous and visceral fat compartments highlighted in green and blue respectively.

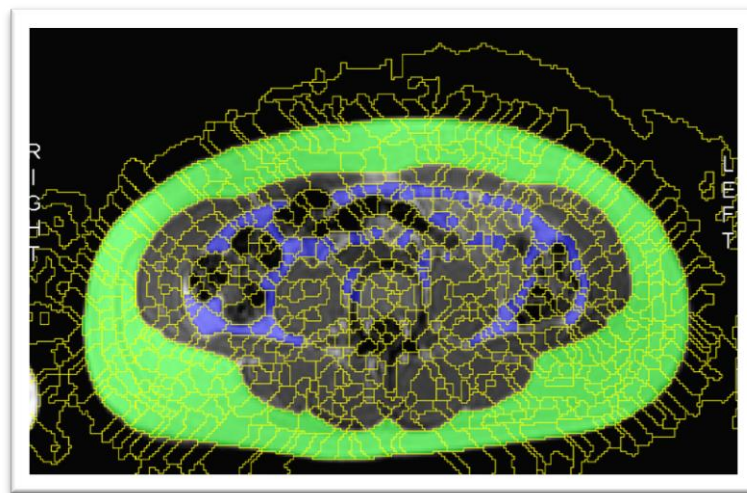


FIGURE 5.3: SAMPLE SCAN USED FOR QUANTIFICATION OF VISCERAL AND SUBCUTANEOUS FAT, COMMERCIALY AVAILABLE SOFTWARE ALLOWS SEGMENTATION OF THE FAT COMPARTMENTS WITH VISCERAL SHOWN IN BLUE AND SUBCUTANEOUS IN GREEN. THE VOLUME OF FAT PRESENT CAN THEN BE ACCURATELY DETERMINED.

Note was made of the presence or absence of a hiatus hernia defined as the gastro-oesophageal junction visible above the diaphragmatic hiatus.

5.2.6 pH Monitoring

pH data were captured using a custom made high resolution pH probe (Synectics Medical Ltd, Ensfeld, UK) with 12 antimony pH sensors designed to maximise resolution at the gastro-oesophageal junction. The flexible catheter was 2.1 mm in diameter. The most distal sensor was located at the tip of the catheter with the other 11 sensors positioned 30, 50, 61, 72, 83, 94, 105, 116, 127, 138 and 172 mm proximally (Figure 5.4). Prior to each study the probe was calibrated by immersion in buffer solutions at pH 1.07 and 7.01.

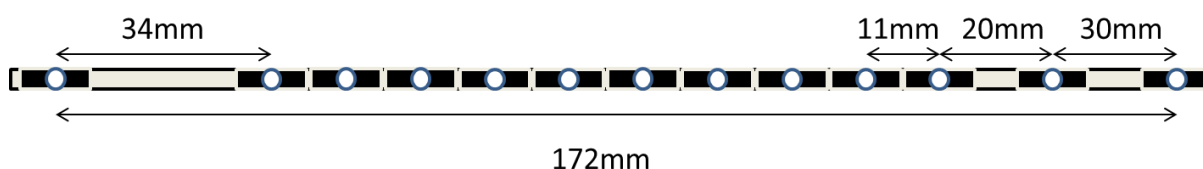


FIGURE 5.4: SCHEMATIC SHOWING THE SPACING OF THE PH SENSORS ON THE CUSTOM MADE HIGH RESOLUTION PH PROBE

Data was recorded using Polygram Net software (Medtronic Inc., Fridley, Minnesota, USA). Raw data were exported for detailed analysis our own custom-designed software.

5.2.7 Manometry Set Up and Pressure Calibration

Manometry data were captured using the commercially available Manoscan 360 system model A100. (Sierra Scientific Instruments) The probe was 4.2mm in diameter and had 36 circumferential solid state manometry sensors spaced 10mm apart. Each sensor in turns comprised 12 radially orientated sensors (TactArray™) such that the pressure reading represented an average of the circumferentially recorded pressures.

Before each study the probe was calibrated for pressure according to manufacturer's recommendations. This process involves application of known externally applied pressure from 0-300mmHg within a pressure chamber. All

experiments were performed with a protective sheath (Manoshield, Sierra Scientific).

Manoview acquisition software was used to display recorded pressures and capture data. After each study the raw data was exported as a text file. pH and manometry text files were combined and analysed using our own custom made software.

5.2.8 Combining pH and Manometry Probes

Once calibrated, pH and manometry probes were attached with adhesive tape placed to avoid interference with sensors. Probes were consistently combined so that pH sensor 7 corresponded to manometry sensor 29 (Figure 5.5). This allowed correlation of pH and pressure data. (Appendix 1)

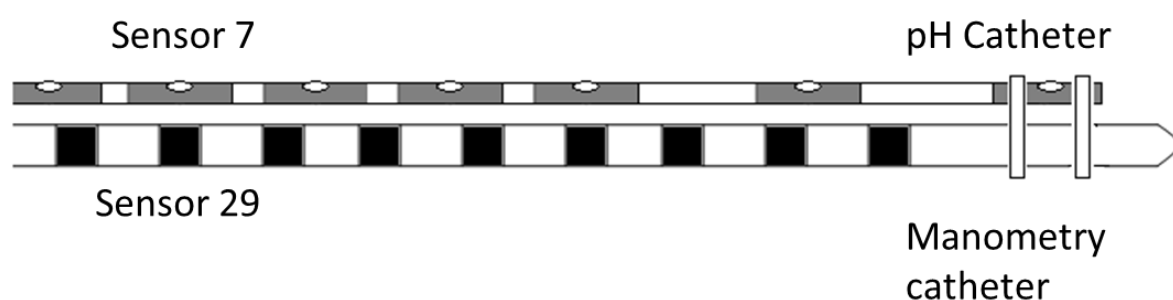


FIGURE 5.5: COMBINED PH AND MANOMETRY APPARATUS WITH MANOMETRY SENSOR 29 CORRESPONDING TO PH SENSOR 7.

5.2.9 Thermal Calibration of the Manometry Probe

To address the thermal drift of the manoscan system two calibration processes were applied. It is widely recognised that there is an immediate response of the manoview system to temperature change. We have also gone on to describe an ongoing linear drift of the recorded pressures with time and have employed and tested a corrective process to minimise the error associated with the drift. These were developed and validated as part of developing the methods of the study and this process is detailed in the results chapters.

At the beginning of a recording the combined pH and manometry apparatus was placed in a water bath at 2cm depth and 37°C and left for three minutes to reach a steady state. At the end of this period the probe was removed from the water bath and held aloft. At this point the probe was considered to be at body temperature but without external pressure influence and the pressure readings were zeroed.

At the end of each study the probes were removed from the volunteer and held aloft. Again the probes were considered to be recording conditions of zero pressure and to be at body temperature. A linear interpolation process was used to correct the pressures assuming a linear drift of the pressure recorded by each sensor.

The manufacturer also recommends an additional weekly 'in vivo' calibration of the system for temperature. For this process the catheter is placed in water at thirty-seven degrees Celsius (37°C) and 2cm depth. The software records the change in detected pressure for each sensor with the change in temperature. The pressure effect of the water is assumed to be negligible. These recorded values are then subtracted from the pressures collected in the in vivo environment to reset the baseline.

5.2.10 Data Capture and Handling

Recordings were synchronised electronically by starting both recordings simultaneously. At the end of the recording period the recordings were also stopped simultaneously. The raw data were exported separately as text files from each programme of origin; Polygram Net for pH data and Manoview analysis software for manometry data. A custom made programme was used to combine the files for further analysis. The pH sampling rate was 8Hz whilst the manometry was 40Hz. To allow correlation of the data the manometry data was compressed into 8 readings per second by calculating the mean of the manometry recordings taken over each 0.125s from the raw data.

Since characteristics of the lower oesophageal sphincter vary by respiration, analysis was performed by inspiration and by expiration separately. To assist this process a programme was designed to allow manual selection of data points for

detailed analysis. First the manoview analysis software was used to identify the index time of recording for detailed analysis for example a period with concurrent fluoroscopy. This time was entered into the custom designed software 'ManpH' which also allowed the user to select from 1-36 manometry channels to display pressure output as line tracings. Inspiration and expiration could be clearly identified. The user could then select six consecutive inspirations and six consecutive expirations. The raw data from these manually selected time points were output into an excel file for further analysis.

5.2.11 Fluoroscopy

During the recording of pH and manometry fluoroscopic images were obtained using the portable Phillips BV Pulsera C arm. Volunteers were asked to breathe normally and minimise swallowing to allow capture of a period of stable lower oesophageal sphincter tone. Recordings were taken over thirty seconds and were synchronised with the pH and manometry recording using an event marker simultaneously on both traces to mark the start and end of recording. Fluoroscopy was carried out before and after the meal and in upright and supine postures.

Images were uploaded onto the picture archiving and communication system (PACS) used by the National Health Service for viewing and reporting images. The endoscopically placed clip previously placed to mark the position of the squamo-columnar junction was identified and its position from the nares calculated using the manometer as reference and internal scale. Thus data were available for the position of the squamo-columnar junction relative to the nares and to the pH and manometry data.

6 Addressing the Thermal Drift of the Manoscan System

6.1 Introduction:

The solid state high resolution manometry (HRM) system (Manoscan, Sierra Scientific Instruments, CA) is a sophisticated and widely used technology allowing detailed examination of oesophageal function. A recognised limitation of the system is a propensity to ‘thermal drift’ where the pressure recorded by the manometry catheter is affected by temperature. In our own practice we have observed marked increases in pressure at the end of prolonged studies, in the range 40-60mmHg for some sensors. (Figure 6.1)

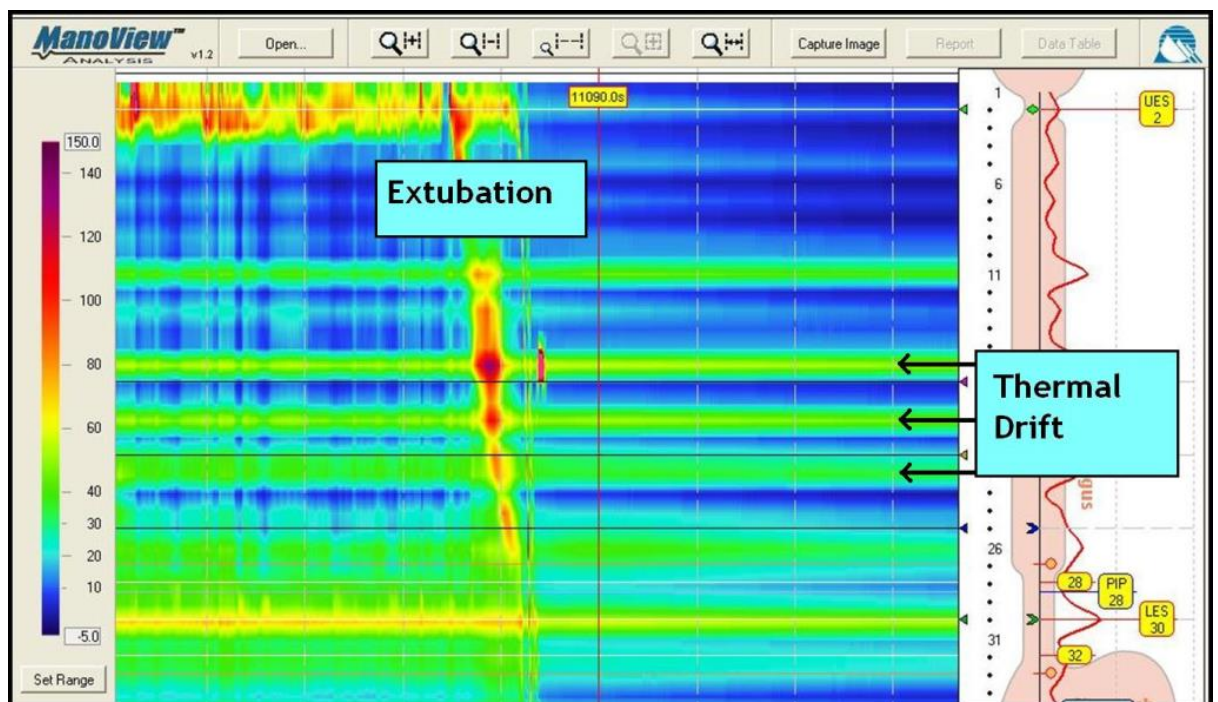


FIGURE 6.1: THE HRM CATHETER HAS BEEN REMOVED FROM THE PATIENT AND HELD ALOFT. AT THIS STAGE PRESSURES SHOULD BE EQUAL TO ATMOSPHERIC PRESSURE REPRESENTED BY THE BLUE COLOUR IN THE COLOUR CONTOUR SCALE. IN SOME SENSORS THE PRESSURE IS IN THE RANGE OF 40 TO 60MMHG REPRESENTED BY THE GREEN/YELLOW COLOUR IN THE PRESSURE SCALE. THESE VALUES REPRESENT THE MAGNITUDE OF BASELINE OR THERMAL DRIFT IN A PROLONGED STUDY.

This effect is less striking with shorter studies, suggesting an ongoing pressure change with time rather than a simple temperature effect. The standard thermal correction does not appear to adequately correct the elevated pressures in prolonged studies. There has been a lack of clarity on the availability and application of alternative corrections.

Given the potential impact of this pressure change on measured physiological values, the aims of this study were:

1. To characterise the behaviour of the manoscan system with temperature and time
2. To test the currently available corrections.

6.2 Methods

6.2.1 High Resolution Manometry

The manoscan A100 system was used for all experiments (Sierra Scientific Instruments, Los Angeles, CA) Equipment was calibrated for pressure and temperature according to manufacturers' instructions.

The in vitro studies were performed using a catheter with only one prior clinical use (EAN 00119). For the in vivo studies results were available from two additional probes used within the unit (EAN 00762 and EAS 0010). Experiments were performed with a sheath. (Manoshield, Sierra Scientific, CA)

6.2.2 Characterising 'Thermal Drift' in Vitro

6.2.2.1 Immediate Effect of Temperature Change

A water bath was prepared with water at 37°C and 2cm depth. Atmospheric pressure was recorded at room temperature by holding the catheter in mid-air and at body temperature by immersing the catheter in the water bath. The calculated pressure of 2cm water (1.47mmHg) was subtracted from readings taken in the water bath.

Difference in recorded pressure between the two temperatures tested was calculated. This process was repeated six times. Results were summarised as median and inter-quartile range. Comparison was made between sensors using the Kruskal-Wallis test.

6.2.2.2 Measurement of a Constant Pressure at 37°C

Six further experiments were performed with the HRM catheter placed in a water bath at a constant depth of 10cm and temperature of 37°C. Pressure readings for the 36 sensors were plotted against time at 5 minute intervals for 2 hours. Pressure change for each sensor was calculated as the difference between the last recorded pressure and the pressure recorded at 60 seconds into the study, expressed as median and interquartile range. Kruskal-Wallis test was used to assess variability between sensors.

6.2.3 Correction Processes

6.2.3.1 Thermal Compensation Method

In the standard correction for thermal drift, the pressure in each sensor is measured immediately after extubation with the catheter still at body temperature. These values are used to correct recorded pressures. To replicate this, measured pressures at the end of each two hour study were subtracted from the pressure readings taken at five minute intervals. Difference from zero was considered an error.

6.2.3.2 Interpolated Correction

For prolonged studies a separate correction process ‘interpolated thermal compensation’ can be enabled. This assumes a linear drift of measured pressures and corrects the data accordingly. To replicate this, the equation for the best-fit line was calculated for each of 216 pressure-time lines produced. Each measured pressure was corrected by subtracting the drift predicted by the best fit line. Difference from zero in either direction was considered the magnitude of the error.

6.2.4 Probe Behaviour 'in Vivo'

For each of the three probes used within our unit six 'in vivo' studies were selected at random. For each study the time point immediately after extubation was selected such that the probe was free of external pressure but still at body temperature. Actual pressure values were documented for each sensor. As part of our protocol for prolonged studies we record pressures at conditions of 37°C and no applied pressure at the start of each study prior to intubation. These values were used to calculate a line gradient for each sensor within each study. Using line gradient corrects for study duration and allows comparison between studies of different length and with the bench top data.

Comparison was made between the probe tested on the bench top, 'probe A' and the same probe tested in vivo. Probe 'A' was also compared to each of the other two probes 'B' and 'C'. Results were summarised as median and inter quartile range and compared using Mann-Whitney U test

6.3 Results

6.3.1 The Immediate Effect of Temperature Change

The median immediate pressure change for all 36 sensors was 7.0mmHg (IQR 3.8mmHg). Considerable variability was observed between sensors ($P < 0.0001$). Some sensors demonstrated a drop in detected pressure associated with change in temperature whilst most demonstrated a rise with a range of -3.3 to +9.9mmHg. (Figure 6.2) We termed this immediate pressure response to temperature ‘thermal effect’

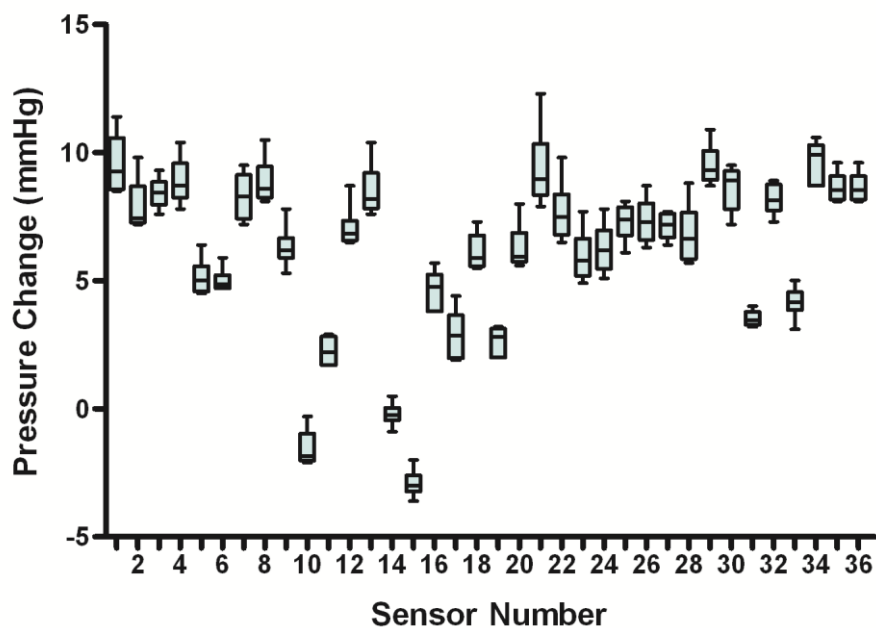


FIGURE 6.2: THE IMMEDIATE EFFECT OF TEMPERATURE ON PRESSURE RECORDED BY THE MANOMETRY CATHETER. SENSORS 1 TO 36 ARE SHOWN ON THE X AXIS AND FOR EACH SENSOR THE BOX PLOT DEPICTS THE MEDIAN, RANGE AND INTERQUARTILE RANGE OF SIX EXPERIMENTS. CONSIDERABLE VARIATION IN RECORDED PRESSURES WAS OBSERVED BETWEEN SENSORS. ($P < 0.001$)

6.3.2 Measurement of a Constant Pressure at 37°C

For a 2 hour study at 37°C the median pressure change was 11.1mmHg (IQR 9.9mmHg). The magnitude of the effect varied between sensors with a range of 3.0mmHg to 33.2mmHg. ($P < 0.0001$)

For a given sensor within a given experiment, change in measured pressure with time was linear with R^2 values above 0.85 in all cases. Thirty-six example

pressure time graphs are shown (Figure 6.3). Median line gradient for all sensors was 0.1mmHg/minute equating to a pressure change of 1.5mmHg in 15 minutes, 3mmHg in 30 minutes and 6mmHg in 60 minutes. Maximum line gradient was 0.39mmHg/min which corresponds to a pressure change of 5.85mmHg in 15 minutes. We termed this ongoing linear drift of the measured pressure with time ‘baseline drift’.

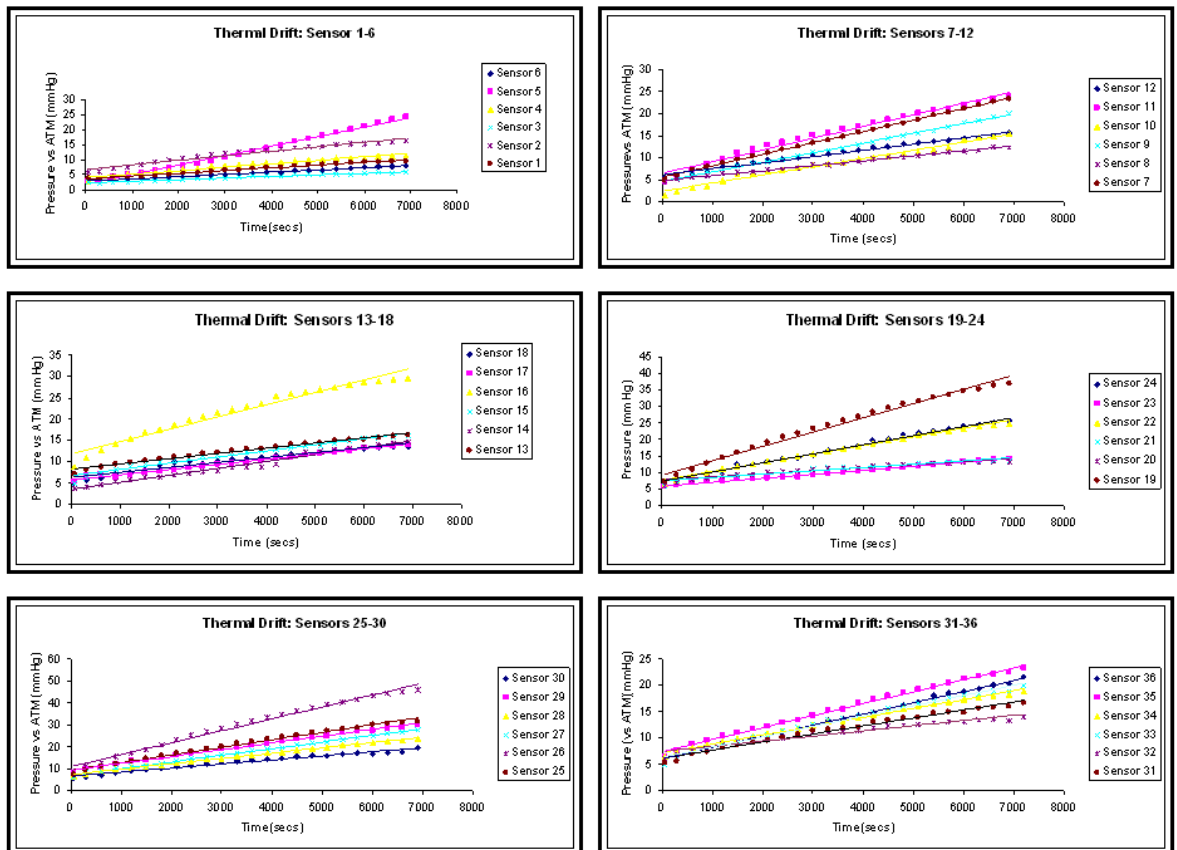


FIGURE 6.3: SAMPLE PRESSURE-TIME GRAPHS SHOWING THE CHANGE IN RECORDED PRESSURE WITH TIME FOR 36 SENSORS IN A SINGLE TWO HOUR EXPERIMENT. FOR A SINGLE SENSOR WITHIN A GIVEN STUDY THE MEASURED DRIFT WAS LINEAR.

The results from six experiments on each sensor are presented in Table 1.

TABLE 6.1: SUMMARY OF SIX EXPERIMENTS EXAMINING THERMAL EFFECT AND BASELINE DRIFT IN A SINGLE HIGH RESOLUTION MANOMETRY CATHETER.

Sensor Number	Thermal Effect			Baseline Drift		
	Median	Maximum	Minimum	Median	Maximum	Minimum
1	8.5	9.6	8.1	12.4	14.8	6.5
2	8.5	9.6	9.1	13.1	15.9	9.8
3	9.9	10.6	8.7	9.0	11.7	6.8
4	4.1	5.0	3.1	12.6	13.8	8.6
5	8.1	8.9	7.3	5.1	13.0	2.6
6	3.4	4.0	3.2	11.2	12.2	5.0
7	8.9	9.5	7.2	12.4	40.9	4.1
8	9.3	10.9	8.7	18.8	23.5	14.5
9	6.7	8.8	5.7	16.0	17.3	11.8
10	7.2	7.7	6.4	19.9	23.3	14.0
11	7.3	8.7	6.3	33.2	40.4	20.6
12	7.4	8.1	6.1	18.7	25.2	11.1
13	6.2	7.8	5.1	16.4	20.4	8.5
14	5.8	7.7	4.9	8.7	12.3	4.8
15	7.5	9.8	6.5	16.7	26.0	11.1
16	9.0	12.3	7.9	5.8	20.0	3
17	5.9	8.0	5.6	5.6	10.1	2.8
18	2.8	3.2	2.0	26.3	41.8	16.5
19	5.9	7.3	5.5	6.9	11.8	3.9
20	2.9	4.4	1.9	9.3	10.6	7.6
21	4.7	5.7	3.8	18.2	44.7	7.9
22	-3.0	-2.0	-3.6	8.3	19.2	3.1
23	-0.3	0.5	-0.9	9.2	10.8	8.7
24	8.2	10.4	7.6	8.0	17.8	5.3
25	6.8	8.7	6.5	8.8	9.8	4.9
26	2.2	2.9	1.7	17.9	35	12.5
27	-1.8	-0.3	-2.1	12.8	15.7	8.1
28	6.2	7.8	5.3	16.1	19.2	10.3
29	8.6	10.5	8.1	6.6	7.8	5.3
30	8.3	9.5	7.2	18.9	27.3	14.8
31	4.9	5.9	4.7	5.4	6.2	2.8
32	5	6.4	4.5	25.7	38.7	13.9
33	8.7	10.4	7.8	6.7	10.9	3.2
34	8.5	9.3	7.6	2.9	6.5	1.9
35	7.5	9.8	7.2	8	13.5	2.7
36	9.2	11.4	8.5	4.8	6.8	3.1

6.3.3 The Thermal Compensation Correction

For data corrected by the thermal compensation method the error was least for data collected at the end of the study and greatest for early data. For data collected 15 minutes before study end the median error for all 36 sensors was 1.2mmHg (IQR 1.2mmHg). Corresponding values for 30 and 60 minutes were 2.9mmHg (IQR 2.5mmHg) and 5.4mmHg (IQR 5.2mmHg) respectively.

6.3.4 Linear Correction

After application of a linear correction, the median error was independent of study duration at 0.3mmHg (IQR 0.2mmHg) overall.

6.3.5 Probe Behaviour 'In Vivo'

The median line gradient for probe A in vivo was 0.10mmHg/min (IQR 0.08) which would equate to a baseline drift of 12.0mmHg in two hours. For probes B and C gradients were 0.05mmHg/min (IQR 0.05) and 0.10mmHg/min (IQR 0.06) respectively. The median line gradient for probe A on the bench top was 0.10mmHg/min (IQR 0.09) which was not significantly different from the in vivo gradient. ($p=0.91$)

For individual sensors in vivo there was considerable variability in the extent of baseline drift indicated by variation in line gradients. ($P<0.0001$) This did not appear exaggerated in sensors exposed to the high pressures of upper and lower oesophageal sphincters.

In vivo probe behaviour was similar between probe A and probe C. ($P=0.71$) Probe B showed significantly less drift than either of the other two probes. ($P=0.0001$)

Discussion

The problem of thermal drift has long been recognised but we believe this represents the first attempt to characterise the phenomenon and assess the potential associated error.¹³⁵ Rather than a ‘once and for all’ type phenomenon, we have demonstrated two components to thermal drift, an initial change in pressure associated with change in temperature and an ongoing pressure drift with time. We have employed the terms thermal effect and baseline drift respectively to differentiate these concepts.

Thermal effect therefore is the discrepancy between measurements of the same pressure taken at two different temperatures. From body temperature to room temperature there was a median pressure step up of 7mmHg. The magnitude of the thermal effect varied between sensors but the important clinical implication is the ability of the system to compensate.

In vivo calibration is a process carried out weekly in the normal operation of the manoscan system. The catheter is placed in a shallow water bath at 37°C. The software records the change in pressure for each sensor with change in temperature, assuming negligible pressure effect of water and uses these values to reset the baseline. In essence the system is measuring the thermal effect for each sensor and correcting recorded pressures accordingly.

Baseline drift is best understood as a progressive upward change of the zero pressure with time. This effect varies markedly between sensors but for a given sensor within an experiment the effect is linear. The potential impact of this effect depends on study duration. For prolonged studies a pressure change of up to 33.2mmHg as demonstrated on the bench top would render interpretation of the data impossible. For short clinical studies, lasting less than fifteen minutes baseline drift will have less impact but may still affect sensitive measurements such as sphincter length.

‘Thermal compensation’ subtracts measured pressures from the end of a clinical study after extubation from the in vivo pressures. Correcting the data in this way simply shifts the maximum error from the end to the start of the study

underestimating early pressures. Since it does not address the gradient of the line, the magnitude of the error is unchanged.

We have tested a linear correction on our bench top data with an overall error of 0.3mmHg independent of study duration. This mirrors the interpolated compensation process recommended by the manufacturer for prolonged studies and extrapolating from our bench top data will dramatically reduce the error associated with baseline drift. Whilst a linear correction can be applied within current software, it has to be enabled discretely in the program files in conjunction with the manufacturer and as it is not referenced in the standard operating instructions it requires awareness of the problem on the part of the user.

Of course it is not possible to entirely replicate the complex and dynamic in vivo environment on the bench top. To address this we examined six in vivo studies from each of three probes used within our unit. The magnitude of the baseline drift was comparable for the probe tested on the bench-top and used for extended in vivo studies. There was also no clear exaggeration of the baseline drift in sensors exposed to the upper and lower oesophageal sphincters. This suggests that the baseline drift is predominantly a temperature rather than a pressure phenomenon.

Comparison between the three probes from the in vivo data suggests a variation in propensity to baseline drift. From both the bench top and in vivo data it is clear that there is marked variability in the extent of baseline drift between sensors. Since a probe is a collection of thirty-six sensors with independent baseline drift characteristics it follows that the baseline drift profile will vary from probe to probe. This poses a quality control issue for manufacturers.

Based on these results we would suggest that the current correction process be replaced by a linear correction already within the capability of current software. This could be done by interpolating between stored in vivo compensation values collected weekly and the set thermal compensation values specific to each study. This would markedly improve the accuracy of the system, would allow its

use for prolonged studies without additional modification and would not impact on ease of use.

In conclusion we have described the behaviour of the HRM system with temperature and time. There is an immediate thermal effect which is well compensated and an ongoing baseline drift which is not well recognised or addressed. The error associated with this phenomenon could be reduced by applying a linear correction. Ultimately this would be best incorporated into standard software so that ease of use is maintained. This observation represents a quality control issue for the manufacturer as well as setting a challenge to all manufacturers of similar technologies. Thermal effect and baseline drift must be considered, documented and addressed.

7 Central Obesity in Asymptomatic Volunteers is Associated with Expansion of the Cardia by Columnar Metaplasia

7.1 Introduction

The gastro-oesophageal junction carries a high burden of disease and adenocarcinoma at this site has shown an alarming increase in incidence over the past thirty years.^{75, 76} This cancer shared epidemiological features with oesophageal adenocarcinoma.^{97, 136} However, its association with traditional reflux is particularly weak, with only 29% having a history of reflux symptoms⁶⁰ and Barrett's mucosa being detected in only 12% at the time of cancer diagnosis.³⁵

An observation that may provide a clue to the aetiology of adenocarcinoma of the gastric cardia and gastro-oesophageal junction (GOJ) in subjects with no reflux history is the frequent finding of pathologic changes at the cardia and GOJ in asymptomatic volunteers. Inflammation of the gastric cardia has been reported in a high proportion of asymptomatic subjects.^{56, 66, 70} This 'carditis' has been attributed to either *Helicobacter pylori* infection or acid reflux^{66, 137} but is also present in most people without *H. pylori* infection or symptoms or signs of reflux¹³⁸. Intestinal metaplasia at the cardia has also been described in the absence of *H. pylori* infection or GORD.¹³⁹ In one study, intestinal metaplasia at the cardia was observed in 16% of Caucasians having screening colonoscopy.¹³⁹

Cardiac mucosa is non-acid-secreting columnar mucosa lying between the squamous mucosa of the oesophagus and the acid-secreting mucosa of the stomach. The origin and even universal existence of cardiac mucosa has been hotly debated. In neonates, the cardiac mucosa is less than 1mm in length⁶⁴ but increases in length with age.⁶² Previous investigators have also shown lengthening of the cardiac mucosa in association with acid reflux.^{64, 66} These observations have led some to suggest that the cardiac mucosa is a pathologic

phenomenon arising through a process of metaplasia of the most distal oesophageal squamous mucosa akin to the development of Barrett's oesophagus.

8

Obesity is a risk factor for both oesophageal adenocarcinoma and adenocarcinoma of the gastro-oesophageal junction.^{75, 81} There is a documented association between obesity and Barrett's oesophagus.¹⁴⁰ The influence of obesity on the development of cardiac mucosa or on pathological changes at the gastro-oesophageal junction is not known.

The aims of this study therefore were:

1. To examine the association between measures of obesity and cardiac mucosa length
2. To test the hypothesis that the cardiac mucosa arises from columnar metaplasia of distal squamous mucosa

To avoid confusion related to H pylori-induced histologic changes in the proximal stomach we limited our study to subjects without the infection. In addition, because we were interested in subjects without traditional reflux, we also excluded subjects with hiatus hernia.

7.2 Methods

7.2.1 Subjects

7.2.1.1 Healthy Volunteers

Healthy volunteers were recruited by word of mouth and newspaper advertisement. Those who had ever taken proton pump inhibitors or ever attended primary or secondary care with reflux symptoms were excluded. All subjects were screened for H pylori by urea breath test and those testing positive or who had a past history of the infection were excluded. Subjects who were found to have hiatus hernia during the study protocol were excluded from the current analysis.

Subjects were recruited to the study to achieve 2 groups defined by small or large waist circumference (WC) and matched with respect to age and sex. Large WC was defined on entry as greater than 102 cm in males and greater than 88 cm in females. Small WC was defined as less than 94 cm in males and less than 80 cm in females. Waist circumference has been validated as a non-invasive assessment of visceral fat mass.¹⁴¹

7.2.1.2 Barrett's oesophagus patients

Archived endoscopic biopsies from 15 patients with long-segment Barrett's oesophagus were included in the analysis to compare immunophenotypes with GOJ, gastric body and antral biopsies taken from healthy volunteers. All Barrett's specimens had columnar metaplasia, with or without intestinal metaplasia, but no dysplastic changes. Biopsies were confirmed to be of oesophageal origin by endoscopic and histological indicators consistent with guidelines of the British Society of Gastroenterology.¹⁴²

7.2.2 Study Design

7.2.2.1 Study day 1: Clinical and magnetic resonance imaging assessment of fat distribution

Demographic details and waist circumference were recorded and magnetic resonance imaging (MRI) scans of the abdomen were performed using the Philips T1.5 MRI scanner (Philips Healthcare, Surrey, UK) before and 45 minutes after a standardized meal.

7.2.2.2 Study day 2: Upper gastrointestinal endoscopy with biopsies

An upper gastrointestinal (GI) endoscopy was performed after a 12-hour fast. Biopsy specimens were taken across the squamo-columnar junction using a large-capacity radial jaw 4 forceps (Boston Scientific, Hemel Hempstead, Herts, UK) with a jaw span of 8 mm. Junctional biopsy specimens were taken perpendicular to the squamo-columnar junction and targeted to include just enough squamous mucosa at the proximal end to confirm positioning. Biopsy specimens were examined during the endoscopy procedure for the presence of glandular and

squamous mucosa and intra-procedure feedback was given for biopsy accuracy. Up to 3 junctional biopsy specimens were taken to optimize the chances of capturing the full span of the cardiac mucosa in a single biopsy sample, allowing accurate length measurement. Biopsy specimens also were taken of the body and antrum of the stomach.

7.2.3 Biopsy specimen processing

Biopsy specimens were placed immediately on dental wax, which has a nonadherent surface, and oriented flat. An isotonic solution of Hyoscine N butyl bromide (1 mg/mL) was applied to minimize sample contraction and preserve the length. Biopsy specimens were transferred to filter paper using a no touch technique and re-oriented where necessary. Samples were transported in conventional formalin and embedded in agar on the filter paper without further manipulation.

7.2.4 H&E and Immunohistochemistry Staining of Biopsies

All biopsies were stained with H&E for initial assessment. Further staining was carried out using a panel of antibodies selected to evaluate the immunohistochemical staining pattern of the gastro-oesophageal junction:

- CDX-2 (caudal type homeobox 2) –a marker of epithelial intestinal differentiation;¹²⁹
- Villin—essential for brush border formation in normal intestinal epithelial cells¹³⁰ and with differential expression in cardiac type mucosa versus Barrett's mucosa with intestinal metaplasia;¹³¹
- Liver-intestine (LI)-cadherin—a sensitive marker of intestinal metaplasia in the upper GI tract;¹³²
- Trefoil factor family 3 (TFF-3)—a marker of intestinal differentiation, strongly expressed in Barrett's mucosa with intestinal metaplasia¹³³
- MUC1, a membrane—associated mucin apoprotein
- MUC2; a marker of mucin cell differentiation associated with intestinal type mucosa
- MUC5AC—a marker of mucin cell differentiation associated with normal gastric mucosa

To assess the extent of cell replication, we used MIB-1 antibodies against Ki-67 antigens.^{134 97}

7.2.5 Data Analysis

7.2.5.1 MRI scans.

Images were taken in 3 axial planes at the level of the second, third, and fourth lumbar vertebrae and assessed by 2 independent GI radiologists. Fat quantification was performed with commercially available software (Tomovision Slice-o-matic, Magog, Quebec, Canada). The presence or absence of a hiatus hernia on MRI was defined as the identification of the gastro-oesophageal junction proximal to the diaphragmatic hiatus.

7.2.5.2 Cardiac mucosal length.

The cardiac mucosa was considered fully measurable when consecutive squamous, cardiac, and cardio-oxync mucosal types were present in the same biopsy specimen. The cardiac mucosa was defined as epithelium devoid of parietal cells and consisting of mucous-secreting cells. The demarcation between squamous and cardiac epithelium was clear and the distal limit of cardiac mucosa was taken as the appearance of parietal cells. Biopsy specimens were assessed by 2 independent gastrointestinal pathology experts blinded to the clinical characteristics of the volunteers. Length was assessed by ocular micrometre. Inter-observer agreement of length measurement was examined (kappa test, 0.78) ($P < 0.01$).

7.2.5.3 Inflammatory Scoring of Biopsy specimens.

Biopsy specimens were scored quantitatively for the presence and degree of inflammation. Scores of 0-3 were given for inflammation, as follows: 0, none; 1, mild; 2, moderate; and 3, marked inflammation. This was performed for acute inflammation, chronic inflammation, and reactive atypia, and for each different mucosal type. This was performed by 2 independent GI pathologists blinded to the details. Inter-observer agreements were examined using kappa tests, which

ranged between 0.74 and 0.89 (P values for each < .01) for different parameters in the 3 parts of squamous, cardiac, and oxyntocardiac mucosae.

7.2.5.4 Assessment of Immunohistochemical Pattern

In sections of gastric antrum, body and gastro-oesophageal junction (cardiac, oxyntocardiac mucosa and Barrett's), the percentage of glandular cells having positive immunostaining was estimated by eye, with all mucosal epithelial cells (surface, foveolar and glandular) being the relevant denominator. In oesophageal squamous epithelium, the only positive differentiation markers were TFF-3 and LI-cadherin. As their expression was entirely restricted to the basal and suprabasal layers, these cells (i.e., those cells not yet showing obvious squamous differentiation) were taken as the relevant denominator. Positive immunostaining was represented by unequivocal brown DAB signal. In any one biopsy, all the mucosae of a particular phenotype were assessed using medium ($\times 10$, $\times 20$) and high-power ($\times 40$) objectives. In the case of Ki-67, where there was >2 mm of squamous mucosa, separate scores were assigned for proximal and squamous epithelium.

7.2.6 Statistical Analysis

Results are presented as either mean (+SD) or median (+IQR), based on symmetry of data distribution. Comparisons between groups were made using Mann-Whitney U test or independent groups T test, if appropriate. To compare two paired groups, we used related samples T test or related samples Wilcoxon signed-rank test, where appropriate. For correlations between continuous variables, Spearman's rho bivariate correlations were used with significance taken at $p < 0.05$.

If any correlations had to be adjusted to other variables, partial correlations were used with a condition of normal distribution of variables to be correlated.

For the determinants of cardiac mucosal length, multivariable analysis was performed using stepwise linear regression. The variables incorporated in the model were age, WC, and MRI total fat.

7.2.7 Ethics

The study protocol was approved by the West of Scotland ethics committee and all volunteers provided written informed consent.

7.3 Results:

Sixty-one volunteers completed the study protocol. However, 10 were found to have a hiatus hernia on MRI scanning and were excluded from this analysis. Thus, the study groups had 24 volunteers (12 females) in the small WC group and 27 volunteers (13 females) in the large WC group.

The median age in the group with the small WC was 45 years (21y-73 y) and in the large WC group the median age was 46 years (21y-71 y) ($P= 0.610$). The median BMI was 23.6 kg/m² in the small WC group (16.7-26.7 kg/m²) and 30.5 kg/m² in the large WC group (25.3-43.3 kg/m²) ($P < 0.001$).

The Barrett's oesophagus comparison patients (12 men, 3 women) had a mean (SD) age of 58 (14) years.

7.3.1 Obesity and Cardiac Mucosal Length

Thirty-five volunteers without hiatus hernia had at least one biopsy of the gastro-oesophageal junction incorporating squamous, cardiac, and oxyntic mucosa (median length, 6.5 mm) (17 in the large WC group and 18 in the small WC group). Results presented for cardiac mucosal length refer to these 35 volunteers with a fully measurable cardiac mucosa whereas associations with physiological parameters refer to the whole group.

In the group with a large WC, the cardiac mucosal length was 2.5 mm (IQR 0.8 mm) compared with 1.75mm (IQR 1.1 mm) in the small WC group ($p= 0.008$). In both groups the transition from cardiac to cardio-oxyntic mucosa was identified easily by the abrupt appearance of parietal cells. (Figure 7.1)

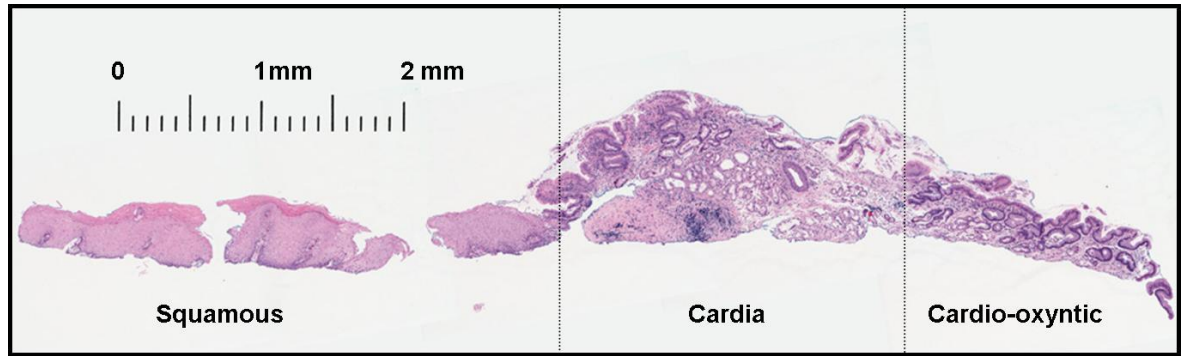


FIGURE 7.1: SAMPLE BIOPSY ACROSS GASTRO-OESOPHAGEAL JUNCTION SHOWING SQUAMOUS, CARDIAC AND CARDIO-OXYNTIC MUCOSAL TYPES.

By bivariate analysis, cardiac mucosal length was correlated positively with age ($R = 0.455$; $p=0.006$), with intra-abdominal fat ($R = 0.351$; $p =0.045$), and with total fat ($R =0.369$; $p =0.034$). No significant associations were seen for BMI ($p=0.125$) or for subcutaneous fat ($p=0.133$).

No difference was seen in cardiac mucosal length by sex ($p =0.722$) or by height ($p=0.434$). On correcting for age, the association for intra-abdominal fat was lost ($R = 0.276$; $p=0.126$). The association with total fat remained significant ($R= 0.357$; $p=0.045$).

On regression analysis the independent predictors of cardiac mucosal length were WC (standardized coefficient, 0.342 ; $p=0.035$) and age (standardized coefficient, 0.322 ; $p=0.046$).

7.3.2 Inflammation and Intestinal Metaplasia at Cardia and SCJ

In this group of healthy volunteers, the cardiac mucosa was universally inflamed. As shown in Figure 7.2 inflammation defined by the density of neutrophils was significantly higher in cardiac mucosa than in the adjacent oxyntocardiac or distant gastric body and antral mucosa (all p values < 0.001). Again, inflammation measured by the density of mononuclear cells was evident in all 3 mucosal subtypes and was in its maximum density in cardiac mucosa (all p values < 0.001 for cardia vs others). Reactive atypia, an indicator of mucosa stress, was seen in all 3 types of SCJ mucosa, but the maximum activity was evident in the most distal squamous mucosa followed by cardiac mucosa (Figure 7.2). All biopsy specimens from the gastric body and antral mucosa were virtually normal.

Intestinal metaplasia at the cardia defined by the presence of goblet cells was seen in only 1 volunteer.

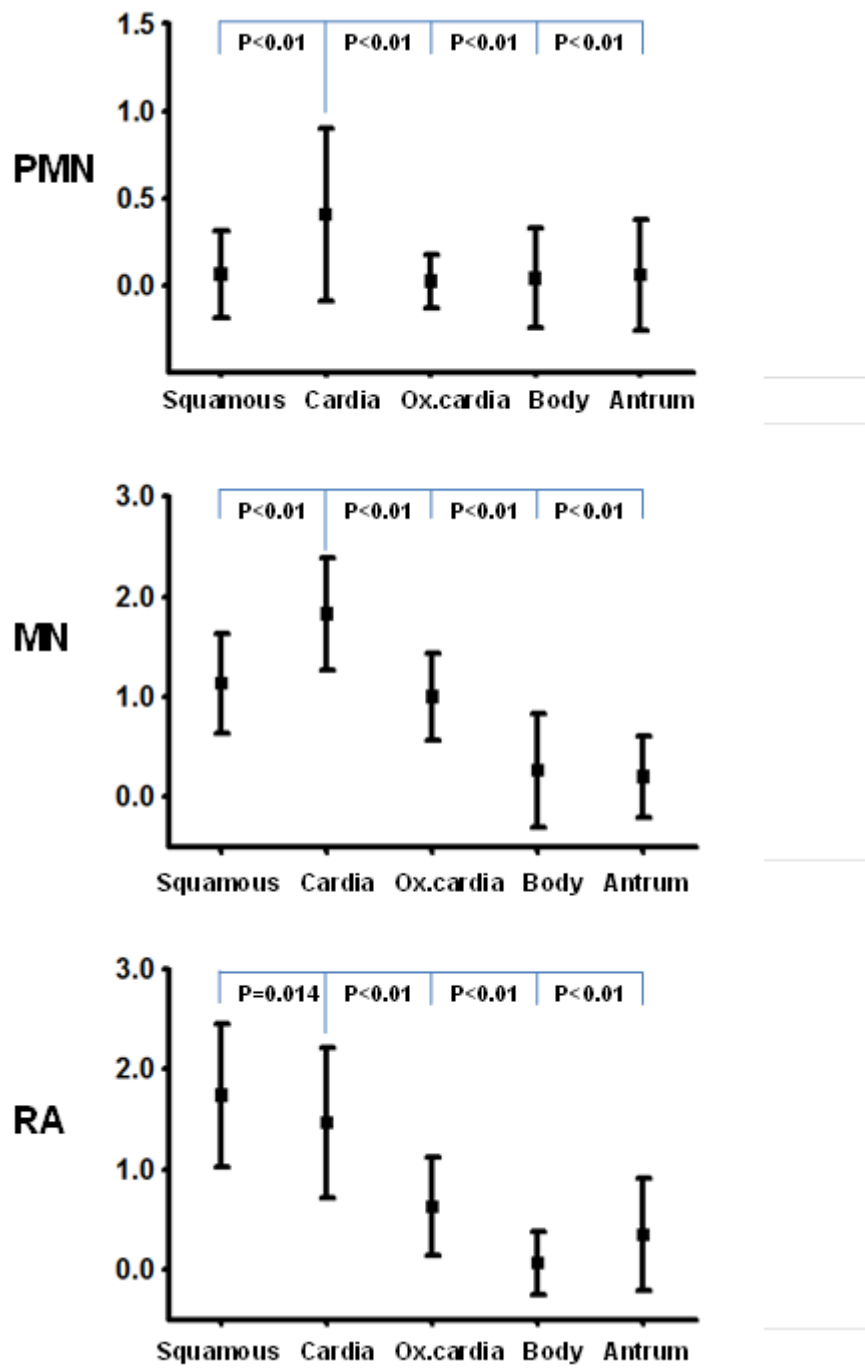


FIGURE 7.2: INFLAMMATION AND MUCOSAL STRESS (REACTIVE ATYPIA) AT SQUAMO-COLUMNAR JUNCTION COMPARED TO GASTRIC BODY AND ANTRAL MUCOSAE. PMN: POLYMORPHONUCLEAR CELLS, MN: MONONUCLEAR CELLS, RA: REACTIVE ATYPIA. ALL COMPARISONS ARE BETWEEN SCORES OF CARDIA AND OTHER LOCATIONS, AND TESTED BY WILCOXON SIGNED RANK TEST.

When biopsies from the gastro-oesophageal junction in healthy volunteers were compared with the biopsies from patients with Barrett's oesophagus, Inflammation in the cardiac mucosa was equivalent to that in Barrett's mucosa with or without intestinal metaplasia (Table 7.1). Reactive atypia was also similar to that in Barrett's with or without intestinal metaplasia (Table 7.1)

TABLE 7.1: INFLAMMATION IN SQUAMOCOLUMNAR JUNCTION BIOPSIES COMPARED WITH OTHER PARTS OF GASTRIC MUCOSA

	Squamous	Cardiac	Oxynto-cardiac	Body	Antrum	Barrett's (IM)	Barrett's (Non-IM)
PMN Infiltration							
Mean	0.06	0.48	0.04	0.04	0.05	0.61	0.46
SD	0.24	0.58	0.21	0.27	0.30	0.61	0.66
p Value (cardia vs other)	<0.001		<0.001	<0.001	<0.001	0.405	0.807
MN Infiltration							
Mean	1.17	1.88	1.02	0.27	0.22	2.06	2.15
SD	0.55	0.58	0.45	0.56	0.42	0.54	0.69
p Value (cardia vs other)	<0.001		<0.001	<0.001	<0.001	0.270	0.163
Reactive Atypia							
Mean	1.79	1.50	0.65	0.07	0.36	1.78	1.77
SD	0.70	0.73	0.48	0.33	0.59	0.65	0.83
p Value (cardia vs other)	0.014		<0.001	<0.001	<0.001	0.184	0.388
p Value (squamous vs other)		<0.001	<0.001	<0.001	<0.001	n/a	n/a

IM, intestinal metaplasia; MN, mononuclear cells; PMN, polymorphonuclear cells.

7.3.3 Immunohistochemistry of the GOJ

7.3.3.1 CDX-2

There was no CDX-2 immunostaining of oesophageal squamous mucosa, gastric oxyntic or oxyntocardiac mucosa. A small number of glandular cells (1%, IQR 0-3%) showed positive staining in cardiac and antral mucosa. In biopsies from Barrett's mucosa, CDX-2 was strongly expressed (90%, IQR 50-90%) in glandular

areas with intestinal metaplasia but was much less evident in the absence of intestinal metaplasia. (5%, IQR 1-5%, $p=0.022$) (Table 7.2)

7.3.3.2 Villin

There was no immunostaining for villin in squamous mucosa. There was substantial expression in cardiac mucosa (30%, IQR 10-70%) with a sharp decrease in oxyntocardiac (5%, IQR 0-10%) and oxyntic (1%, IQR 0-1%) mucosae. Antral mucosa (90%, IQR 81-90%) and Barrett's mucosa with intestinal metaplasia (90%, IQR 86-95%) both expressed villin even more strongly than cardia ($p<0.001$ for both). Villin expression in Barrett's mucosa without intestinal metaplasia was lower at 25% (IQR 10-40%), similar to cardiac mucosa ($p=0.425$). (Table 7.2)

7.3.3.3 TFF-3

In oesophageal squamous mucosa, a minority, mean 4% (SD 6%), of basal layer cells were distinctly positive for TFF-3 (Figure 7.3) This was significantly lower than its expression in cardiac mucosa (54%, SD 37%, $p<0.001$). TFF-3 expression decreased to 26% (SD 20%, $p<0.001$ vs cardia) in oxyntocardiac and to 12% (SD 19%, $p=0.003$ vs cardia) in oxyntic mucosae. Again in antral mucosa, a high proportion (47%, SD 25%) of cells expressed TFF-3 and similar to cardia ($p=0.489$).

In Barrett's mucosa, TFF-3 expression was maximal in IM (89%, SD 3%), which was significantly higher than cardia ($p=0.001$). Non-IM Barrett's mucosa expresses TFF-3 at levels similar to cardia (69%, SD 9, $p=0.352$).

TABLE 7.2: THE EXTENT (%) OF IMMUNOSTAINING WITH DIFFERENT ANTIBODIES IN BIOPSIES FROM SQUAMOCOLUMNAR JUNCTION COMPARED WITH GASTRIC BODY, ANTRUM AND BARRETT'S

Antibody	Squamous	Cardiac	Oxynto-cardiac	Body	Antrum	Barrett's (IM)	Barrett's (Non-IM)
CDX2							
Median	0	1	0	0	1	90	5
IQR	0-0	0-3	0-0	0-0	0-1.0	50-90	1-5
P Value (cardia vs other)	<0.001		<0.001	<0.001	0.384	<0.001	0.022
Villin							
Median	0	30	5	1	90	90	25
IQR	0-0	10-70	0-10	0-1	81-90	86-95	10-40
P Value (cardia vs other)	<0.001		<0.001	0.069	0.001	<0.001	0.425
TFF-3							
Mean	4	54	26	12	47	89	69
SD	6	(37)	20	(19)	(25)	(3)	(9)
P Value (Cardia vs other)	<0.001		<0.001	0.003	0.489	0.001	0.352
LI-Cadherin							
Mean	7	14	10	5	18	65	13
SD	(6)	(11)	(7)	(4)	(7)	(37)	(10)
P Value (cardia vs other)	<0.001		<0.001	<0.001	0.594	<0.001	0.465
MUC1							
Median	1	5	15	40	10	0	3
IQR	0-1	1-8	9-22	8-65	5-50	0-0	0-5
P Value (cardia vs other)	<0.001		<0.001	0.028	0.035	<0.001	0.063
MUC2							
Median	0	0	0	0	0	90	0
IQR	0-0	0-1	0-0	0-0	0-0	80-90	0-1
P Value (cardia vs other)	0.0014		0.011	0.317	0.157	<0.001	0.074
MUC5ac							
Median	0	50	40	30	55	90	60
IQR	0-0	50-70	30-40	25-60	40-70	90-90	50-70
P Value (cardia vs other)	<0.001		<0.001	0.013	0.270	<0.001	0.927

Marker expression is given as the percentage of positive cells for all mucosal epithelial cells, except for TFF-3 and LI-cadherin, which were only expressed by basal cells (and suprabasal cells for LI-cadherin) and are expressed as the percentage of the cells in that specific compartment. CDX-2, caudal type homeobox 2; IM, intestinal metaplasia; LI, liver-intestine; MUC, mucin; TFF-3, trefoil factor family 3.

7.3.3.4 LI-cadherin

The distal oesophageal squamous mucosa showed strong LI-cadherin immunostaining in 7% (SD 6%) of basal and suprabasal layer cells (Figure 7.3). There was greater staining in cardiac mucosa (14%, SD 11%), which gradually decreased to 10% (SD 7%) ($p < 0.001$ vs cardia) in oxyntocardiac and then to 5% (SD 4%) ($p < 0.001$ vs cardia) in oxyntic mucosa. Expression of LI-cadherin in antral mucosa was 18% (SD 7%), similar to cardia ($p = 0.594$). (Table 7.2)

In Barrett's biopsies, while sections with IM expressed LI-cadherin strongly (65%, SD 37%) ($p < 0.001$ vs cardia) non-IM sections expressed lower levels (13%, SD 10%) similar to cardia ($p = 0.465$).

7.3.3.5 MUC-1, MUC-2 and MUC-5ac

Except weak and superficial expression of MUC1, extending to a median of 1% (IQR 0-1%), none of the other antibodies were detectably expressed in squamous mucosa of the SCJ. MUC1 was expressed in 5% (IQR 1-8%) of cells in cardiac mucosa, and the expression increased distally to 15% (IQR 9-22%) in oxyntocardiac ($p = 0.001$) and 40% (IQR 8-65%) ($p = 0.028$ vs cardia) in oxyntic mucosae. Antral mucosa showed 10% (IQR 5-50%) expression, slightly higher than cardia ($p = 0.035$). There was no reactivity in Barrett's mucosa with IM, but non-IM Barrett's showed 3% (IQR 0-5%) expression, similar to cardia ($p = 0.063$). (Table 7.2)

MUC-2 was strongly expressed only in Barrett's mucosa with IM (90%, IQR 80-90), which was significantly higher than that of cardiac mucosa ($p < 0.001$). MUC-5ac-positive cells were present in 50% (IQR 50-70%) of cardia and decreased in oxyntocardiac to 40% (IQR 30-40%) ($p < 0.001$) and in oxyntic mucosae to 30% (IQR 25-60%) ($p < 0.001$ vs cardia). In antrum, MUC-5ac was expressed in 55% (IQR 40-70%), which was similar to cardia. MUC-5ac was highly expressed in Barrett's with IM (90%, IQR 90-90%, $p < 0.001$), but its expression in non-IM Barrett's was similar to cardia (60%, IQR 50-70%, $p = 0.927$) (Table 7.2)

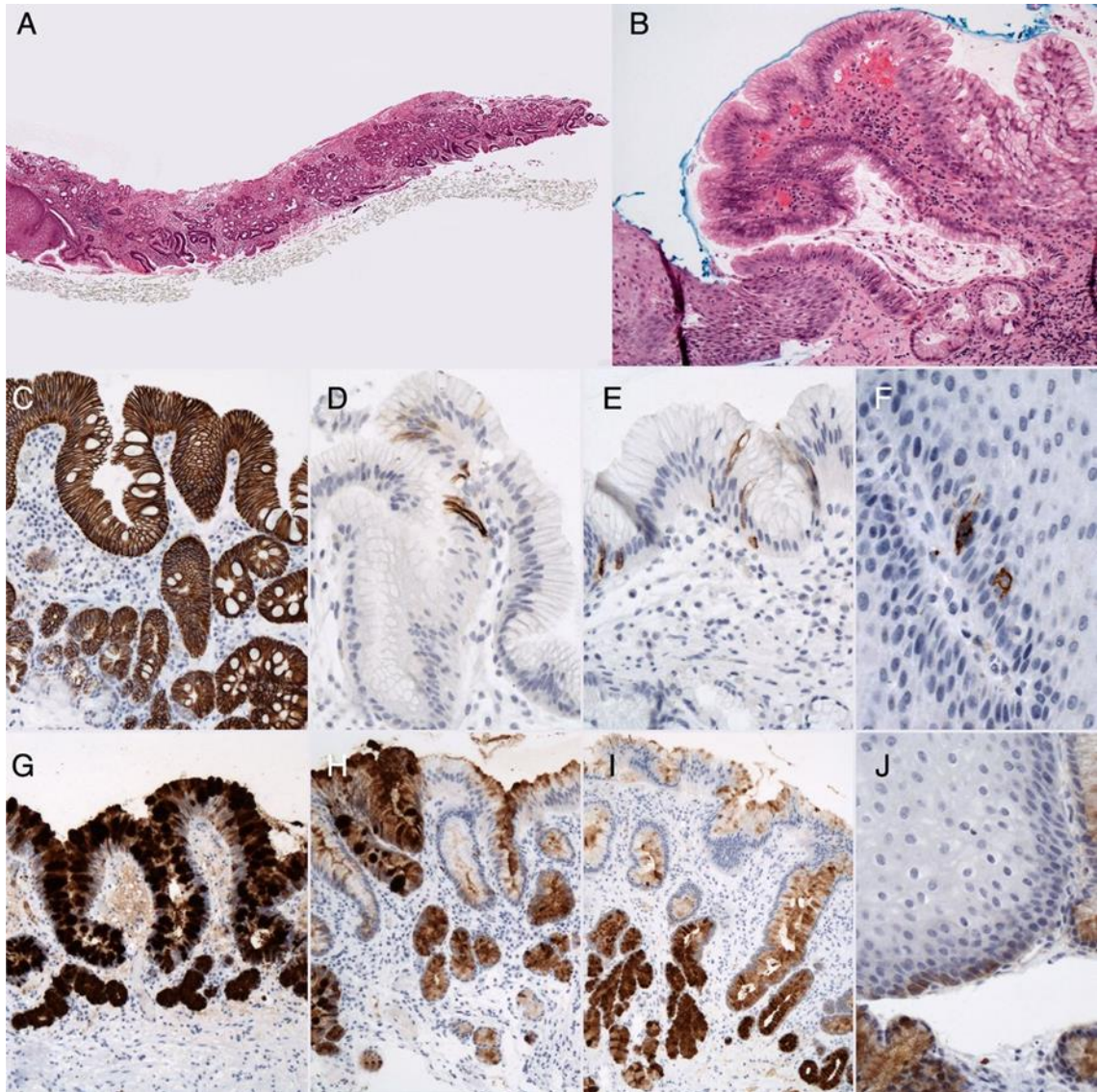


FIGURE 7.3: SAMPLE BIOPSIES OF SQUAMOCOLUMNAR JUNCTION SHOWING INFLAMMATION AND IMMUNOHISTOCHEMICAL STAINING.

TOP ROW: (A) LOW-POWER VIEW OF A BIOPSY FROM THE SQUAMOCOLUMNAR JUNCTION OF A VOLUNTEER SHOWING BIOPSY LENGTH AND ORIENTATION. (B) HIGHER-POWER VIEW OF SQUAMOCOLUMNAR JUNCTION OF ANOTHER VOLUNTEER SHOWING INFLAMMATION AND REACTIVE CHANGES TO SQUAMOUS AND GLANDULAR MUCOSA.

MIDDLE ROW: LIVER-INTESTINE (LI)-CADHERIN, IMMUNOHISTOCHEMISTRY. (C) STRONG EXPRESSION BY BARRETT'S MUCOSA WITH INTESTINAL METAPLASIA (IM). (D) OCCASIONAL POSITIVE CELLS IN NON-IM BARRETT'S MUCOSA. (E) OCCASIONAL POSITIVE CELLS IN CARDIA MUCOSA IN A VOLUNTEER. (F) BASAL LI-CADHERIN-POSITIVE CELLS IN SQUAMOUS MUCOSA IN A VOLUNTEER.

BOTTOM ROW: TREFOIL FACTOR FAMILY (TFF)-3. (G) STRONG EXPRESSION BY BARRETT'S MUCOSA WITH IM. (H) INTERFACE BETWEEN BARRETT'S MUCOSA WITH IM AND NON-IM BARRETT'S MUCOSA. (I) CARDIAC MUCOSA FROM A VOLUNTEER. (J) BASAL TFF-3 POSITIVITY IN SQUAMOUS EPITHELIUM NEXT TO CARDIA IN A VOLUNTEER.

7.3.3.6 Immunostaining of cardiac versus other mucosae

Cardiac mucosa immunostaining was statistically indistinguishable from that of non-IM Barrett's mucosa with respect to six of the seven antibodies employed. CDX-2 was expressed by a slightly but significantly higher number of cells in non-IM Barrett's mucosa (1%, 0-3 vs 5%, 1-5). Cardiac mucosa differed from all the other upper GI epithelia by showing different characteristics with respect to at least two of the immunostains.

7.3.3.7 Proliferation marker Ki-67 and inflammation

As expression of Ki-67 appeared to vary across squamous mucosa of GOJ biopsies, we measured the variation of expression in 20 biopsies with >2 mm of squamous mucosa. In SCJ biopsies, expression of Ki-67 was maximum at the most distal squamous epithelium (39%), and decreased moving proximally (25%) and distally (20% in cardia) (p for trend <0.01) (Table 7.3)

Decreasing Ki-67 expression in the small distance between distal to proximal squamous epithelium within single biopsies was parallel to a decreasing median inflammatory score (mononuclear cells + polymorphonuclear cells) over the same distance (4.0 (IQR 3.5-5.0) vs 2.5 (IQR 2.0-3.0), p value <0.01). Correlation between proliferation (indicated by Ki-67) and inflammation at the SCJ was positive (Spearman's coefficient 0.510) and statistically significant (p=0.022) in the 20 samples with sufficient length of squamous mucosa in specimen.

Ki-67 expression was highest in Barrett's mucosa with IM (75%, IQR 70-80) and lower in non-IM Barrett's at 40% (IQR 35-45) (p<0.01 for cardia vs Barrett's with IM and p<0.05 for cardia vs non-IM Barrett's).

TABLE 7.3: THE EXTENT (%) OF KI-67 IMMUNOREACTIVITY IN BIOPSIES FROM SQUAMOCOLUMNAR JUNCTION COMPARED WITH TISSUES FROM GASTRIC BODY, ANTRUM AND BARRETT'S

	Squamo-columnar Junction				Body	Antrum	Barrett's (IM)	Barrett's (Non-IM)
	Squamous (proximal)	Squamous (distal)	Cardiac	Oxynto-cardiac				
N	20	20	39	18	11	10	15	15
Median	25.0	39.0	20.0	10.00	10.00	30.00	75.00	40
Centiles								
25	15.00	31.50	20.00	10.00	5.00	25.00	70.00	35
75	30.75	47.00	30.00	15.00	10.00	30.00	80.00	45

IM, intestinal metaplasia

7.3.4 Obesity and markers of glandular differentiation

In squamous mucosa of the distal oesophagus, expression of TFF-3 and LI-cadherin was correlated with obesity (Table 7.4). The TFF-3 expression was correlated strongly to WC (correlation coefficient (CC) =0.54, p=0.001), BMI (CC=0.58, p=0.001), subcutaneous fat thickness at lower abdomen (CC=0.39, p=0.020), average subcutaneous fat (CC=0.44, p=0.005) and intra-abdominal fat at a similar area (CC=0.48, p=0.002). These correlations remained significant or became stronger when adjusted for age and gender or age, gender and cardiac mucosa length (Table 7.4).

Expression of LI-cadherin also was correlated to WC (CC=0.51, p=0.001), BMI (CC=0.37, p=0.015) and subcutaneous fat thickness at lower abdomen (CC=0.34, p=0.039), and these correlations also became stronger when correcting for age, gender and cardia length.

Expression of CDX-2, villin and Ki-67 in distal squamous mucosa was not correlated with obesity. None of the tested antibodies in cardiac mucosa correlated with obesity parameters (Table 7.5).

TABLE 7.4: CORRELATION BETWEEN OBESITY AND EXPRESSION OF TREFOIL FACTOR FAMILY 3 (TFF-3) AND LIVER-INTESTINE (LI)-CADHERIN IN GASTRO-OESOPHAGEAL JUNCTIONAL BIOPSIES, SQUAMOUS MUCOSA (PARTIAL CORRELATION)

Adjustment	TFF-3			LI-Cadherin		
	None	Age and Gender	Age, gender and cardia length	None	Age and Gender	Age, gender and cardia length
WC						
CC	0.540	0.542	0.604	0.512	0.462	0.462
P Value	0.001	0.001	0.001	0.001	0.002	0.002
N	41	37	30	43	39	39
BMI						
CC	0.582	0.573	0.617	0.369	0.366	0.366
P Value	0.001	0.001	0.001	0.015	0.019	0.019
N	41	37	30	43	39	39
SCF Thickness, upper abdomen						
CC	0.238	0.210	0.239	0.355	0.372	0.372
P Value	0.156	0.226	0.188	0.188	0.023	0.023
N	37	33	30	39	35	35
SCF Thickness, lower abdomen						
CC	0.391	0.518	0.536	0.341	0.447	0.447
P Value	0.020	0.002	0.002	0.039	0.007	0.007
N	35	31	30	37	33	33
SCF (L2, L3, L4 average)						
CC	0.445	0.441	0.505	0.243	0.325	0.325
P Value	0.005	0.007	0.003	0.130	0.047	0.047
N	38	34	30	40	36	36
IAF (L2, L3, L4 average)						
CC	0.482	0.602	0.638	0.302	0.060	0.060
P Value	0.002	0.001	0.001	0.058	0.721	0.721
N	38	34	30	40	36	36
Total Fat (L2, L3, L4 average)						
CC	0.586	0.593	0.668	0.307	0.249	0.249
P Value	0.001	0.001	0.001	0.054	0.132	0.132
N	38	34	30	40	36	36

BMI, body mass index; CC, correlation coefficient; IAF, intra-abdominal fat; SCF, subcutaneous fat; WC, waist circumference

TABLE 7.5: CORRELATION BETWEEN OBESITY AND EXPRESSION OF VARIOUS ANTIBODIES IN GASTRO-OESOPHAGEAL JUNCTIONAL BIOPSIES, CARDIAC MUCOSA

	CDX-2	Villin	TFF-3	LI-cadherin	Ki-67
WC					
CC	-0.066	-0.055	0.097	0.284	0.176
P Value	0.676	0.733	0.523	0.058	0.272
N	43	41	46	45	41
BMI					
CC	-0.163	0.064	0.060	0.262	0.154
P Value	0.295	0.692	0.692	0.082	0.336
N	43	41	46	45	41
SCF Thickness, upper abdomen					
CC	0.120	0.004	0.098	0.017	0.283
P Value	0.462	0.982	0.531	0.918	0.085
N	40	38	43	41	38
SCF Thickness, lower abdomen					
CC	0.164	-0.035	0.141	0.144	0.265
P Value	0.332	0.842	0.386	0.381	0.123
N	37	35	40	39	35
SCF (L2, L3, L4 average)					
CC	0.003	-0.073	0.221	0.026	0.206
P Value	0.985	0.657	0.149	0.870	0.209
N	41	39	44	42	39
IAF (L2, L3, L4 average)					
CC	0.094	-0.043	0.104	0.069	0.263
P Value	0.561	0.794	0.502	0.664	0.106
N	41	39	44	42	39
Total Fat (L2, L3, L4 average)					
CC	0.077	-0.062	0.221	0.114	0.290
P Value	0.630	0.707	0.150	0.470	0.073
N	41	39	44	42	39

BMI, body mass index; CC, correlation coefficient; CDX-2, caudal type homeobox 2; IAF, intra-abdominal fat; LI, liver-intestine; SCF, subcutaneous fat; TFF-3, trefoil factor family 3; WC, waist circumference.

7.4 Discussion

The main finding of this study was that in asymptomatic volunteers without a hiatus hernia, the length of cardiac mucosa lying between oesophageal squamous mucosa and gastric oxyntic mucosa increases with waist circumference and age. There is debate regarding the origin of cardiac mucosa in apparently normal individuals, and whether its expansion with age may be a result of columnar (glandular) metaplasia of distal oesophageal squamous mucosa. The findings of our current study support the cardia arising in this way as it shows an almost identical immunophenotype to non-IM Barrett's mucosa, which is considered to arise by metaplasia of the oesophageal squamous mucosa, induced by gastro-oesophageal acid reflux.

To accurately measure the length of the cardiac mucosa we used biopsy forceps with an 8-mm jaw span and took a biopsy specimen perpendicular to the squamo-columnar junction, carefully oriented the sample, and then cut on edge. In some cases, the mucosa included the distal squamous mucosa but did not include oxyntic mucosa, and therefore we may have underestimated the mean length of non-oxyntic cardia mucosa. However, this should not affect the association with waist circumference, which we limited to those with accurately measured full-length non-oxyntic cardia mucosa.

In our group of asymptomatic volunteers, we found that the cardiac mucosa was inflamed, showing infiltration with both acute and chronic inflammatory cells. In contrast, the oxyntic mucosa distal to the cardiac mucosa was not inflamed. Reactive atypia, an indicator of epithelial damage and repair, was most marked in squamous mucosa. Only 1 subject had evidence of intestinal metaplasia. Previous studies have reported inflammation of cardiac mucosa and attributed it to H pylori infection or gastro-oesophageal reflux disease¹³⁸. However our subjects were H pylori negative and had no symptoms of reflux. We are not aware of either the length or inflammatory status of the cardiac mucosa having been studied in this subject group previously.

We were able to assess the correlation of the cardiac mucosa length with a range of parameters of body size and fat distribution. There was no correlation

with body height, indicating it was not merely a reflection of skeletal size. There was a significant correlation with intra-abdominal fat, but not with subcutaneous fat, and after correcting for age only total abdominal fat remained significant. We recognize that intra-abdominal fat on its own explains only a relatively small part of the variance in cardiac mucosa length.

The increasing length of the cardiac mucosa with age and waist circumference suggests that some or all of this mucosa is acquired throughout life. This possibility was suggested originally by Chandrasoma,⁸ who proposed that cardiac mucosa developed by gastro-oesophageal reflux, inducing squamo-columnar metaplasia of the distal oesophagus. Two features of the histologic appearance of the gastroesophageal junction in our current study are consistent with the lengthening of the cardiac mucosa being caused by changes affecting its proximal end where it abuts the oesophageal squamous mucosa. First, the subjects did not have H pylori infection, which might cause atrophy of adjacent oxyntic mucosa with loss of parietal cells. This atrophic mucosa, with loss of specialized parietal cells, would resemble cardiac mucosa producing apparent distal lengthening. Second, the inflammation was focused at the squamo-columnar junction, suggesting local damage, which could result in proximal extension as a result of replacement of squamous mucosa by columnar mucosa.

The mucosal changes we have observed at the gastro-oesophageal junction in our asymptomatic subjects with central obesity may be relevant to the aetiology of adenocarcinoma of the cardia and gastro-oesophageal junction. As mentioned earlier in the text, these cancers are associated with obesity and frequently present in subjects without evidence of traditional reflux. We found that cardiac mucosa showed identical staining to non-IM Barrett's mucosa for six of the seven immunohistological markers of differentiation of GI epithelium. The only marker showing a slight difference was CDX-2, which had a slightly lower median value for cardia versus non-IM Barrett's. In contrast, in IM Barrett's CDX-2 expression was much higher than either with a median of 90% (IQR 50-90). The slightly higher value in the non-IM Barrett's mucosa versus cardia might indicate some of the former starting to show evidence of progression to IM-type Barrett's. Vallbohmer et al¹⁴³ have previously reported that Cdx-2 gene expression in cardiac mucosa lies between that of squamous mucosa and Barrett's mucosa.

Unlike cardiac mucosa, the other gastric epithelia, that is, phenotypes, oxyntocardiac, oxyntic and antral, all differed from non-IM or IM Barrett's with respect to at least three of the immunostains. Both non-IM Barrett's and cardiac epithelium are known to develop and/or expand with increasing age, and the close similarity of cardiac and non-IM Barrett's with respect to markers of differentiation is consistent with them being acquired by a similar process.

In long-segment Barrett's oesophagus, the mucosa is a patchwork of regions with intestinal and non-intestinal columnar metaplasia.¹⁴⁴ Proximally, IM is most prevalent, whereas at the distal end, non-IM is more prevalent.¹⁴⁴ Cardiac mucosa is at the most distal end of the oesophagus and therefore columnar metaplasia in this region would most typically be similar to non-IM rather than IM metaplasia. Glandular metaplasia of the oesophagus is regarded as an adaptation to the changing environment of the adjacent lumen. Predominance of IM at the proximal end of long-segment Barrett's oesophagus is consistent with this region being exposed to less acidic reflux and thus developing mucosa more typical of the small or large intestine where the environment is much less acidic than that of the stomach. In contrast, the distal end of the oesophagus in patients with Barrett's mucosa is exposed to levels of acidity similar to the stomach and therefore metaplasia similar to the antrum of the stomach may have an adaptive advantage.

Only one of our subjects had evidence of intestinal metaplasia of the cardia, which traditionally has been regarded as a marker of malignant potential in patients with columnar-lined oesophagus. The carcinogenic potential of intestinal metaplasia vs non-goblet cell columnar (cardiac-type) metaplasia recently was challenged. A recent study of 141 patients who had endoscopic resection of early carcinoma at the gastro-oesophageal junction reported that 70% had cardiac-type epithelium rather than intestinal metaplasia adjacent to the cancer.¹⁴⁵ In addition, a retrospective study of 712 patients who had undergone previous biopsy studies of their distal oesophagus found a similar rate of adenocarcinoma over the subsequent 12 years in those with (45%) vs those without (36%) goblet cells in their oesophageal columnar epithelium.¹⁴⁶ The changes we have observed in the cardia are occurring in the asymptomatic population and thus are many times more prevalent than traditional Barrett's.

Even a small risk of malignant transformation therefore could result in a high burden of cancer cases.

Previous studies have reported similarity between cardiac mucosa and non-IM Barrett's mucosa. However, our current study differs from those studies in two respects. First, our study included healthy volunteers without gastro-oesophageal acid reflux, whereas previous studies have involved patients with typical reflux symptoms,¹⁴⁷ reflux oesophagitis,¹⁴⁸ Barrett's oesophagus¹⁴⁹ or oesophageal adenocarcinoma.¹⁵⁰ Second, our current study has employed a more comprehensive panel of immunostains than the previous studies. Pereira et al used a panel of four immunostains (villin, sucrose isomaltase CK7 and CK20) and only the villin showed similarity of both mucosae.¹⁴⁸ Chaves and colleagues used only antibodies against mucins (Muc-2, Muc-5ac and Muc-6).¹⁴⁹ Lord et al used CK7, CK20 and DAS-1 as markers of Barrett's plus other antibodies to assess dysplasia, which was not our interest.¹⁵⁰ Theisen et al¹⁵¹ used only Alcian blue to assess the presence of goblet cells in both mucosae. We believe our comprehensive panel of immunostains covered full ranges of cellular and histological changes in the cardiac and Barrett's mucosae and also in other types of interest in the upper GI tract.

Cardiac mucosa also resembled Barrett's mucosa with respect to pattern and severity of inflammatory infiltrate. Acute and chronic inflammatory cell infiltrates in cardiac mucosa, IM and non-IM Barrett's mucosa were similar and substantially greater than in any other upper GI mucosae in our H. pylori-negative healthy volunteers. Likewise, reactive atypia, a marker of stress, was similar in cardiac mucosa, IM and non-IM Barrett's mucosa and greater than in any other upper GI columnar mucosae. The similarity with respect to inflammation, reactive atypia and markers of differentiation all support the two mucosae being acquired by a similar mechanism.

If the expansion of the cardia is arising by gastric acid damaging the most distal oesophageal squamous mucosa and resulting in metaplastic change, then one would expect to see evidence of damage and possibly early metaplasia of the oesophageal squamous mucosa at the SCJ. We found that the inflammatory cell infiltrate and rate of epithelial proliferation were most marked near to the SCJ.

We also observed evidence of expression of TFF-3 and LI-cadherin within the distal oesophageal squamous mucosa consistent with early columnar metaplasia or at least a wavering commitment to glandular differentiation. TFF-3 and LI-cadherin especially were expressed by a small number of basal and immediately suprabasal cells. This could indicate transient expression by stem cells or early daughter cells, not maintained in later generations of transit-amplifying cells. If such glandular differentiation was maintained, rather than being switched off, it would represent a possible pathway to glandular metaplasia potentiated by obesity.

In addition to the association seen between obesity and cardiac mucosal length we also observed associations between central obesity and the immunohistology of the GOJ. In the distal oesophageal squamous mucosa, the expression of the markers of glandular columnar differentiation (TFF-3 and LI-cadherin) correlated with WC and this was strongest when corrected for age, gender and cardiac length. This is consistent with central obesity promoting squamo-columnar metaplasia close to the SCJ by mechanically inducing acid reflux within the region of the LOS and possibly also aggravated by humeral factors related to central obesity.

In conclusion, we have shown that in the asymptomatic, moderately overweight population there is evidence of lengthening of the gastric cardiac mucosa. The immunohistological changes observed at the GOJ provide further support for gastric acid causing damage and columnar metaplasia of the distal oesophageal mucosa. This inflammation and metaplasia occurring at the SCJ in apparently healthy volunteers may be relevant to the high proportion of junctional adenocarcinoma that present in subjects without a history of reflux disease.

8 Central Obesity in Asymptomatic Volunteers is associated with Intrasphincteric Acid Reflux without Traditional Reflux

8.1 Introduction

Oesophageal adenocarcinoma is believed to develop from columnar metaplasia of oesophageal squamous epithelium (Barrett's oesophagus), resulting from gastro-oesophageal reflux of acid and possibly bile. Reflux occurs when there is complete loss of lower oesophageal sphincter (LOS) tone, allowing gastric juice to flow up into the body of the oesophagus. This transsphincteric reflux occurs most commonly during transient lower oesophageal sphincter relaxations (TLOSRS).

There is a strong association between oesophageal adenocarcinoma and both body mass index (BMI) and waist circumference.^{81, 84} This may be explained partly by these morphometric characteristics being associated with impaired function of the lower oesophageal sphincter.¹¹⁸⁻¹²⁰ In addition, increased visceral fat might promote the carcinogenic pathway by humoral mechanisms.¹¹²

Most cases of adenocarcinoma at the gastro-oesophageal junction are in individuals without a prior history of gastro-oesophageal reflux disease or Barrett's oesophagus^{34, 35, 60} suggesting that mechanisms other than traditional reflux may be important. We previously suggested that pathology occurring at the gastro-oesophageal junction might be related to opening of the distal segment of the lower oesophageal sphincter, allowing ingress of gastric juice, while the more proximal segment of the sphincter retains tone, preventing transsphincteric reflux.^{27, 152}

We have described lengthening of the cardiac mucosa at the gastro-oesophageal junction in healthy volunteers in association with age and obesity.¹⁵³ We have also demonstrated similarities between cardiac mucosa and non-IM Barrett's oesophagus suggesting that the cardiac mucosa may be a pathological phenomenon acquired over time by a process of metaplasia of distal squamous

mucosa.¹⁵⁴ The short length of cardiac mucosa and its circumferential pattern also would fit with it arising from the opening of the most distal segment of the lower oesophageal sphincter rather than by conventional reflux.

The aim of this current study was therefore to determine whether central obesity disrupts the structure and functioning of the distal segment of the lower oesophageal sphincter, allowing acid ingress without transsphincteric reflux. To avoid confusion related to H pylori-induced histologic changes in the proximal stomach, we limited our study to subjects without the infection. In addition, because we were interested in subjects without traditional reflux, we also excluded subjects with hiatus hernia.

8.2 Methods

8.2.1 Study Subjects

The study volunteers were recruited and allocated to 2 groups defined by normal or increased waist circumference as previously outlined. (7.2.1.1)

8.2.2 Study Protocol

8.2.2.1 Study Days 1 and 2

As part of the full study protocol study volunteers attended on two initial study days as outlined in chapter 7. On the first visit anthropometric assessment was carried out and MRI scans performed for assessment of fat volume and distribution. On the second, upper GI endoscopy with biopsies was performed. At the time of endoscopy the squamo-columnar junction was marked by 2 endoclips (HX-610-135; Olympus, Southend-on-Sea, UK) to allow subsequent fluoroscopic visualisation.

8.2.2.2 Study Day 3: combined recording of pH and manometry.

After a 12-hour fast, a combined high-resolution manometry catheter and high-resolution pH catheter was passed nasally. Recordings were taken for 15 minutes fasting with subjects seated in an upright position and for a further 15 minutes supine. Subjects then consumed a standardized meal over a 20-minute period

and were asked to eat until full. The meal consisted of battered fish and chips with 150 mL of water. After the meal, combined recording of pH and pressure was continued for 45 minutes with patients in an upright position and for 30 minutes supine. In each of the 4 periods of recording (fasting upright, fasting supine, post-prandial upright, and postprandial supine), fluoroscopic screening was performed for 30 seconds to visualize the endoscopically placed clips.

8.2.2.3 Equipment

High-resolution pH-metry: pH recordings were taken using a high-resolution custom-made pH probe, composed of 12 antimony pH electrodes (Synectics Medical, Ltd, Enfield, UK). The most distal pH electrode was placed at the tip of the catheter and the other 11 electrodes were 30, 50, 61, 72, 83, 94, 105, 116, 127, 138, and 172 mm proximal to it. Recordings were captured using polygram net software (Synectics Medical).

High-resolution manometry: Manometry was performed using a solid-state high-resolution manometry system with 36 circumferential sensors spaced at 10-mm intervals (Manoscan A100; Sierra Scientific Instruments, Los Angeles, CA). To compensate for thermal drift, calibration was performed weekly and an additional tailored linear correction was applied to collected data.¹³⁵

The Combined Probe and its Positioning: The manometry and pH probes were combined so that pH sensor 7 corresponded to manometer sensor 29. The combined probe was positioned so that the 9 closely spaced (11-mm apart) pH sensors straddled the lower oesophageal sphincter and the most proximal pH sensor was 5 cm proximal to the upper border of the lower oesophageal sphincter.

Fluoroscopy: Fluoroscopic images were obtained using the Siemens portable C arm (Siemens, Surrey, UK). Images were uploaded onto our in-house picture archiving and communication system (PACS) for further analysis.

8.2.3 Data Analysis

8.2.3.1 MRI Scans:

Images were taken in 3 axial planes at the level of the second, third, and fourth lumbar vertebrae and assessed by 2 independent GI radiologists. Fat quantification was performed with commercially available software (Tomovision Slice-o-matic, Magog, Quebec, Canada). The presence or absence of a hiatus hernia on MRI was defined as the identification of the gastro-oesophageal junction proximal to the diaphragmatic hiatus.

The positions of the diaphragmatic hiatus and the dome of the left hemidiaphragm were measured relative to the lumbar vertebrae.

8.2.3.2 Acid exposure

The mean pH was calculated for each of the 12 pH sensors for each phase of the study. For the postprandial data the recording period from 30 to 45 minutes was used to represent the post-prandial upright position and the period from 45 to 60 minutes was used to represent the post-prandial supine position. The pH transition point within the gastro-oesophageal junction was defined by the index sensor recording a decrease in mean pH of at least 1 unit from proximal to distal and corrected for 1.1-cm spacing between sensors.

Acid exposure was examined at the pH transition point as the mean percentage of time the pH was less than 4. The location of the pH transition point was determined relative to the upper border of the LOS. Acid exposure also was determined at the following points:

1. The traditional site 5 cm above the upper border of the LOS,
2. The sensor 1.1 cm proximal to the pH transition point, and
3. The sensors distal to the pH transition point.

Traditional acid reflux was considered present where the sensor 5 cm proximal to the LOS recorded a mean percentage of time the pH was less than 4 of at least 4%. Short-segment acid reflux was considered present if the sensor 1.1 cm

proximal to the pH transition point recorded a mean percentage of time the pH was less than 4 of at least 4%.

8.2.3.3 Manometry

For each of the 4 phases of the study the period during fluoroscopic recording was analysed in detail. Six inspiratory and 6 end-expiratory points were selected using a custom-made computer program.

- The lower border of the LOS was defined as the first sensor moving proximally from the stomach where the pressure increased to more than 2mmHg above gastric baseline.
- The upper border of the LOS was defined by a decrease in pressure to within 2 mm Hg of intra-gastric pressure.
- Intra-gastric pressure (IGP) (mm Hg) was calculated on expiration and defined as the median pressure of the first 3 sensors immediately distal to the lower oesophageal sphincter.
- The pressure inversion point (PIP) was defined as the first sensor moving from the lower oesophageal sphincter proximally toward the oesophageal sensors showing a pressure fall with inspiration.
- Proximal and distal LOS lengths were determined using the PIP as reference point.
- Transient Lower Oesophageal Relaxations (TLOSRs) were identified by visual inspection of the manometry trace and defined by Holloways criteria¹⁶:
 - absence of swallowing for 4 seconds before to 2 seconds after the onset of LOS relaxation
 - relaxation rate of at least 1mmHg/s
 - Time from onset to complete relaxation of at least 10 seconds
 - Nadir pressure of less than or equal to 2mmHg

For distances measured from the nares, the midpoint between inspiration and expiration was used and 0.5 cm was added to correct for the error associated with the 1-cm spacing of the sensors.

8.2.3.4 Fluoroscopy.

The position of the squamo-columnar junction (SCJ) was derived from fluoroscopic images using the manometric sensors as reference and internal scale. This was calculated for the midpoint between inspiration and expiration and was expressed both relative to the nares and to the upper border of the LOS.

8.2.4 Statistical Analysis

Results are presented as mean and standard error or median and interquartile range according to normal or non-normal distribution respectively. Comparison of variables between groups was made using the Mann-Whitney U test. For all correlations between 2 continuous variables, the Spearman Rho bivariate correlations were used.

8.2.5 Ethics

The study protocol was approved by the West of Scotland ethics committee and all volunteers provided written informed consent.

8.3 Results

Fifty one volunteers without hiatus hernia completed the study protocol: 24 volunteers (12 females) in the small WC group and 27 volunteers (13 females) in the large WC group.

The median age in the group with the small WC was 45 years (21y-73 y) and in the large WC group the median age was 46 years (21y-71 y) ($P=0.610$). The median BMI was 23.6 kg/m² in the small WC group (16.7-26.7 kg/m²) and 30.5 kg/m² in the large WC group (25.3-43.3 kg/m²) ($P < 0.001$).

8.3.1 Obesity and Acid Reflux

The percentage of time the pH was less than 4 at 5 cm proximal to the LOS was 0.1% (SE, 0.04) for fasting upright, 1.0% (SE, 0.06) for fasting supine, 1.3% (SE, 0.44) for post-prandial upright, and 0.8% (SE, 0.63) for postprandial supine.

There was no significant excess of transsphincteric traditional reflux seen in the large WC group (Table 8.1, all $P > 0.05$). When the relationship between cardiac mucosal length measured in these volunteers previously and transsphincteric reflux was assessed, no significant association was seen (fasting upright, $P = 0.386$; fasting supine, $P = 0.109$; postprandial upright, $P=0.464$; post-prandial supine, $P = 0.702$).

The pH transition point was determined by the position of the most proximal of the 12 pH sensors showing a mean pH decrease of 1 unit. As shown in Table 8.1, this sensor was the first showing an abrupt change from oesophageal to gastric pH. At the sensor located 1.1 cm proximal to the pH transition point there was some evidence of short-segment reflux in the post-prandial phase in the group as a whole (the percentage of time the $\text{pH} < 4$ was 4.2% [SE, 0.7] for postprandial upright, the percentage of time the $\text{pH} < 4$ was 5.6% [1.6] for post-prandial supine) (Table 8.1). Short segment reflux was similar in both groups (all $P > 0.05$).

8.3.2 Obesity and Manometric Measures

8.3.2.1 IGP.

IGP was significantly greater in the large WC group in the fasting state and post-prandial supine (Table 8.2)

8.3.2.2 LOS Length.

The total LOS length was shortened in the large WC group for fasting upright and post-prandial supine postures (Table 8.2). There was no difference between the groups in the length of the intra-abdominal LOS or intrathoracic LOS measured with reference to the pressure inversion point (PIP). By using the position of peak pressure as a reference point, significant shortening of the distal LOS was seen in the post-prandial phase in the large WC group with a strong trend for distal shortening in the fasting upright phase (Table 8.2)

8.3.2.3 LOS Pressure.

No differences were shown between the groups in LOS pressure measured relative to the IGP (Table 8.2).

8.3.2.4 PIP position.

The distance from the nares to the PIP was similar between the small and large WC groups (Table 8.2)

8.3.2.5 TLOSRS.

TLOSRS were infrequent in the fasting state with a median of 1 (IQR, 1) seen in the upright posture and 0 (IQR, 0) supine. In the first 45 minutes after the meal a median of 7 TLOSRS were observed (IQR, 4) and a further 1 (IQR, 1) in the supine posture. No significant differences were seen between the groups in frequency of TLOSRS (Table 8.2)

TABLE 8.1: MEAN ACID EXPOSURE TIME IN SENSORS LOCATED 5 CM ABOVE THE UPPER BORDER OF THE LES, SENSORS DETECTING PH TRANSITION POINT, AND THE SENSORS 1.1 CM PROXIMAL AND 1.1, 2.2, AND 3.3 CM DISTAL TO THE PH TRANSITION POINT

Sensor Location		Total				Large WC				Small WC			
		FU	FS	PPU	PPS	FU	FS	PPU	PPS	FU	FS	PPU	PPS
Proximal	5cm	0.1 (0.04)	0.1 (0.06)	1.4 (0.50)	0.9 (0.73)	0.1 (0.04)	0.1 (0.04)	0.9 (0.79)	0 (0)	0.2 (0.08)	0.1 (0.12)	1.7 (0.65)	1.6 (1.27)
	1.1cm	3.9 (0.8)	4.0 (0.9)	4.7 (0.7)	6.1 (1.8)	4.2 (1.4)	4.4 (1.3)	4.5 (1.4)	6.7 (3.3)	3.6 (0.9)	3.5 (1.1)	4.8 (0.9)	5.6 (1.8)
pH Transition Point	0	37.9 (3.7)	42.9 (4.2)	58.5 (5.3)	50.6 (4.8)	35.4 (4.9)	47.8 (6.0)	55.0 (8.2)	51.0 (7.2)	40.7 (5.7)	37.6 (5.6)	61.2 (7.0)	50.2 (6.5)
	1.1cm	71.0 (4.2)	70.3 (4.5)	71.2 (5.3)	76.3 (5.0)	73.2 (5.7)	72.1 (5.8)	72.2 (8.1)	81.7 (7.4)	68.6 (6.2)	68.3 (7.0)	70.3 (7.3)	72.0 (6.8)
Distal	2.2cm	81.1 (4.0)	87.5 (3.0)	65.3 (6.1)	76.4 (5.2)	79.9 (5.7)	92.2 (2.3)	65.5 (9.5)	75.2 (7.5)	83.4 (5.6)	82.6 (5.6)	65.2 (8.0)	77.3 (7.3)
	3.3cm	85.1 (3.9)	97.8 (0.7)	49.0 (7.1)	64.9 (6.4)	87.5 (5.3)	98.1 (0.7)	56.8(10.7)	73.7 (8.1)	82.3 (5.9)	97.4 (1.3)	42.2 (9.3)	57.6 (9.6)

NOTE. The mean acid exposure time is calculated as follows: percentage of time the pH value is less than 4. The SE is shown in parentheses. FS, fasting supine; FU, fasting upright; PPU, postprandial upright; and PPS, postprandial supine.

TABLE 8.2 SUMMARY OF DIFFERENCES BETWEEN LARGE AND SMALL WC GROUPS FOR MANOMETRIC MEASURES

		Small WC	Large WC	Sig.
IGP (mmHg)	FU	9.0 (IQR 4.6)	11.1 (IQR 5.1)	p=0.020
	FS	8.7(IQR 4.9)	10.3 (IQR 3.4)	p=0.017
	PPU	10.7 (IQR 3.2)	11.6 (IQR 4.4)	p=0.083
	PPS	8.9 (IQR 4.4)	11.1 (IQR 3.9)	p=0.001
LOS Length (cm)	FU	6 (IQR 2)	4 (IQR 2)	p=0.016
	FS	5 (IQR 2)	5 (IQR 1)	p=0.254
	PPU	4 (IQR 3)	3 (IQR 2)	P=0.298
	PPS	4.5 (IQR)	3 (IQR 3)	p=0.043
Length Distal Component LOS (cm)	FU	2.82 (2.27-3.38)	2.12 (1.63-2.61)	p=0.066
	FS	2.72 (2.20-3.23)	2.34 (1.87-2.81)	p=0.327
	PPU	2.36 (1.91-2.81)	1.69 (1.25-2.13)	p=0.026
	PPS	2.17 (1.78-2.57)	1.52 (1.06-1.98)	P=0.039
LOS Pressure (mmHg vs IGP)	FU	21.9 (IQR 15.9)	18.1 (IQR 16.6)	p=0.165
	FS	24.4 (IQR 14.9)	17.9 (IQR 6.0)	p=0.163
	PPU	9.1 (IQR 9.3)	11.2 (IQR 11.7)	p=0.985
	PPS	16.5 (IQR 13.9)	15.7 (IQR 8.1)	p=0.657
Nares to PIP (cm)	FU	45.5 (4.5)	44.5 (2.0)	p=0.118
	FS	46.5 (4.25)	45.5 (3.5)	p=0.319
	PPU	44.5 (4.25)	43.5 (3.0)	p=0.382
	PPS	45.5 (4.25)	44.5 (4.0)	P=0.333
TLOSrs (Number)	FU	1 (IQR 1)	0 (IQR 1)	p=0.146
	FS	0 (IQR 0)	0 (IQR 0)	p=0.279
	PPU	7 (IQR 3)	6 (IQR 4)	p=0.157
	PPS	1 (IQR 1)	1 (IQR 1)	p=0.901

8.3.3 Obesity and Diaphragm Position by MRI

8.3.3.1 Obesity and the Position of the Dome of the Left Hemidiaphragm.

In the fasting state, the median diaphragm position in the large WC group was close to the upper margin of T9 (9.125; IQR, 1.19) whereas in the small WC group it was close to the upper margin of T10 (10.2; IQR, 0.75) ($P = 0.001$), representing a difference of 26 mm¹⁵⁵. A similar difference of 24 mm was observed postprandially.

8.3.3.2 Obesity and the position of the diaphragmatic hiatus.

The position of the diaphragmatic hiatus was similar between groups, being at the level of the 10th thoracic vertebrae for fasting and post-prandial states.

8.3.4 Obesity and the location of the pH transition point

The pH transition point was more proximal within the LOS in the group with a large WC compared with the small WC group (Table 8.3, Figure 8.1). In addition, gastric acid extended further up with respect to the location of the peak LOS pressure being distal to it in the small WC group, but at or above it in those with a large WC (Table 8.3, Figure 8.1). The positions of the upper border of the LOS and the peak LOS pressure relative to the nares were similar in large vs small WC groups (Table 8.3).

Intra-abdominal fat and total fat were correlated strongly with a more proximal pH transition point (Table 8.4). BMI was associated with a shorter distance between the upper border of the LOS and acid in the postprandial setting. For subcutaneous fat this association was significant for the fasting upright phase only (Table 8.4). In the fasting supine state a negative correlation was seen between age and the position of the pH transition point, indicating more proximal acid ingress with increasing age ($R = -0.286$; $P = 0.044$). No significant variation was seen by sex.

8.3.5 Obesity and location of the SCJ

The SCJ was significantly closer to the upper border of the LOS and to the PIP in the large vs small WC subjects (Table 8.3, Figure 8.1). In addition, the SCJ was closer to the peak LOS pressure in the large WC subjects (Table 8.3, Figure 8.1). There was no difference between the groups with respect to the relative positions of the SCJ and pH transition point.

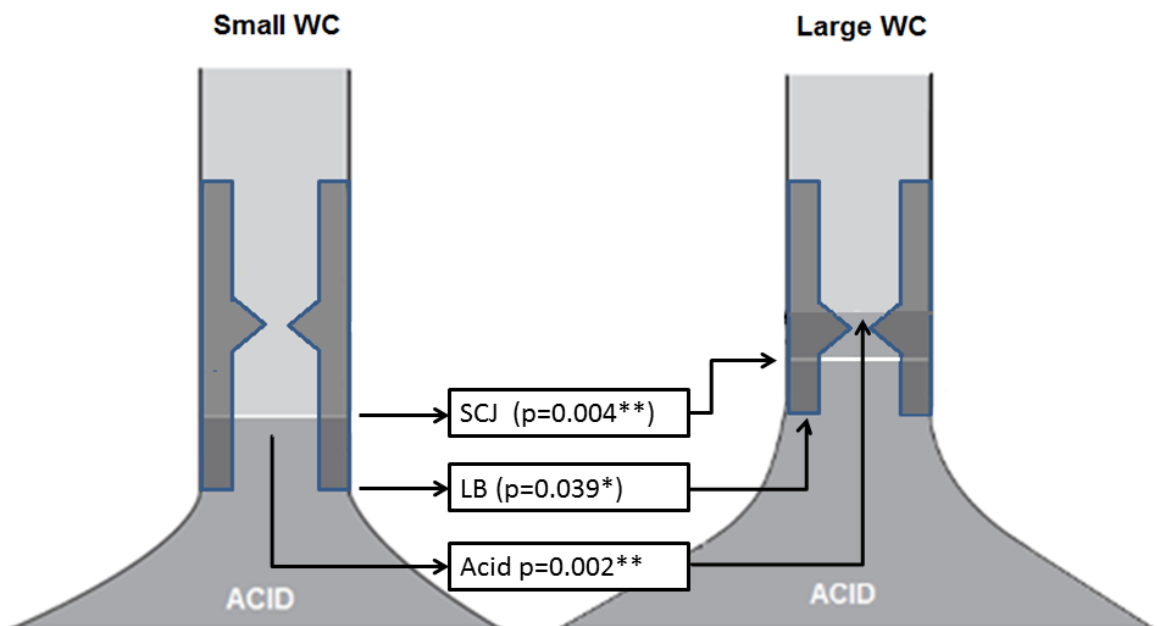


FIGURE 8.1: ALTERATIONS IN THE GASTROINTESTINAL JUNCTION ASSOCIATED WITH INCREASED WAIST CIRCUMFERENCE. THE POSITION OF THE SCJ IS INDICATED BY A WHITE LINE. THE HIGH-PRESSURE ZONE OF THE LOS IS REPRESENTED BY THE 2 VERTICAL SHADED COLUMNS AND THE POSITION OF THE PEAK LOS PRESSURE BY THE FACING APICES OF THE SHADED TRIANGLES. ACID, GASTRIC ACIDITY IS REPRESENTED BY THE SHADED AREA. THE SIGNIFICANCE VALUES FOR THE POSITION OF THE SCJ AND PH TRANSITION POINT ARE RELATIVE TO UPPER-BORDER LOS. DATA ARE BASED ON MEDIAN POSTPRANDIAL SUPINE VALUES.

TABLE 8.3: RELATIVE POSITIONS OF COMPONENTS OF THE LOS, PH TRANSITION POINT, AND SCJ

		Small WC	Large WC	Sig.
Nares to Upper Border LOS (cm)	FU	44.0 (IQR 4.3)	44.0 (IQR 2.5)	p=0.639
	FS	45.0 (IQR 4.8)	44.0 (IQR 3.0)	p=0.699
	PPU	43.5 (IQR 4.0)	42.3 (IQR 3.9)	p=0.063
	PPS	44.5 (IQR 4.0)	43.5 (IQR 3.5)	p=0.311
Nares to Peak LOS Pressure (cm)	FU	46.5 (IQR 4.5)	45.5 (IQR 2.5)	p=0.373
	FS	47.0 (IQR 4.0)	46.0 (IQR 3.5)	p=0.469
	PPU	45.5 (IQR 4.8)	44.0 (IQR 4.3)	p=0.051
	PPS	46.5 (IQR 4.5)	45.5(IQR 4.0)	p=0.226
Upper Border LOS to Peak LOSP (cm)	FU	2.00 (IQR 0.50)	2.00 (IQR 1.00)	p=0.435
	FS	2.00 (IQR 1.00)	2.00 (IQR 1.00)	p=0.771
	PPU	2.00 (IQR 1.00)	1.50 (IQR 0.88)	p=0.350
	PPS	2.00 (IQR 0.50)	1.50 (IQR 0.50)	p=0.133
pH Transition Point from Upper Border LOS(cm)	FU	4.1 (IQR 2.3)	2.65 (IQR 2.8)	p=0.027
	FS	3.0 (IQR 3.3)	2.3 (IQR 2)	p=0.051
	PPU	2.9 (IQR 1.4)	1.6 (IQR 2.3)	p=0.011
	PPS	3.2 (IQR 1.9)	1.8 (IQR 1.5)	p=0.002
pH Transition Point from Peak LOSP (cm)	FU	2.0 (IQR 2.30)	0.55 (IQR 2.83)	p=0.058
	FS	1.4 (IQR 4.10)	0.4 (IQR 2.10)	p=0.047
	PPU	0.9 (IQR 1.65)	-0.1(IQR 2.30)	p=0.042
	PPS	1.2 (IQR 1.90)	-0.1 (IQR 1.62)	p=0.007
SCJ from Upper Border LOS (cm)	FU	3.54 (IQR 1.49)	2.77 (IQR 1.04)	p=0.023
	FS	3.42 (IQR 1.77)	2.89 (IQR 1.80)	p=0.017
	PPU	3.02 (IQR 1.58)	2.85 (IQR 1.01),	p=NS
	PPS	3.34 (IQR 1.73)	2.20 (IQR 1.40),	p=0.004
SCJ from PIP(cm)	FU	2.87 (1.15)	1.94 (0.88)	p=0.003
	FS	2.31 (2.49)	1.47 (1.22)	p=0.025
	PPU	2.59 (1.98)	2.20 (0.95)	p=0.041
	PPS	3.1 (1.66)	1.62 (1.51)	p=0.005
SCJ from peak LOSP(cm)	FU	1.3 (1.5)	0.7(IQR 1.1)	p=0.05
	FS	1.42 (1.8)	0.59 (IQR 1.46)	p=0.011
	PPU	1.15 (1.90)	1.06 (0.76)	p=0.395
	PPS	1.23 (1.58)	0.58(1.24)	P=0.017
pH Transition Point from SCJ (cm)	FU	0.56 (IQR 2.66)	-0.36 (IQR 2.58)	p=0.202
	FS	0.28 (IQR 2.32)	0.05 (IQR 2.80)	p=0.297
	PPU	-0.20 (IQR 2.25)	-1.03 (IQR 2.29)	p=0.250
	PPS	-0.18 (IQR 1.46)	-0.81 (IQR 2.11)	p=0.276

TABLE 8.4: CORRELATIONS BETWEEN PARAMETERS OF OBESITY AND THE POSITION OF THE PH TRANSITION POINT RELATIVE TO THE UPPER BORDER OF THE LOS

			Parameters of Obesity			
			BMI	SCF	IAF	Total Fat
Position of pH Transition Point	FU	R	-0.243	-0.304	-0.271	-0.328
		P	0.086	0.034	0.059	0.021
	FS	R	-0.196	-0.180	-0.378	-0.294
		P	0.173	0.220	0.008	0.042
	PPU	R	-0.327	-0.212	-0.371	-0.325
		P	0.019	0.413	0.009	0.023
	PPS	R	-0.345	-0.281	-0.473	-0.433
		P	0.013	0.051	0.001	0.002

FS, fasting supine; FU, fasting upright; PPS, postprandial supine; PPU, post-prandial upright; SCF, subcutaneous fat. IAF, intra-abdominal fat;

8.4 Discussion

This study demonstrates a novel mechanism for acid damage at the gastro-oesophageal junction associated with obesity in otherwise healthy asymptomatic volunteers. In those with a large waist circumference, there was acid influx within the lower oesophageal sphincter (intrasphincteric reflux) without the complete loss of sphincter tone characteristic of traditional (transsphincteric) reflux. This mechanism may underlie the mucosal changes at the junction previously demonstrated in association with obesity in this group.

Traditional reflux measured at 5cm above the gastro-oesophageal junction was not a feature in either group. However our subjects with a large waist circumference did have a number of abnormalities of the gastro-oesophageal junction and intrasphincteric acidity, which could explain the previously described lengthening of the cardiac mucosa. The LOS was shorter in those with a large WC and our data indicated that this was from loss of the distal component of the LOS, especially after a meal. In addition, in these subjects, gastric acid extended more proximally within the LOS relative to both the upper border of the LOS and peak LOS pressure. In the small WC subjects, the leading

edge of gastric acidity only came to within 1-2 cm distal to the point of peak LOS pressure, whereas in those with a large WC it reached this point. This leading edge of gastric acidity represented a pH value of less than 4 for 40%-52% of recorded time. The association with intrasphincteric acid extension was strongest for MRI measurement of intra-abdominal fat and total abdominal fat.

The SCJ also was positioned more proximally within the LOS with respect to the upper border of the LOS and peak LOS pressure in obese subjects. This more proximal positioning of the SCJ within the LOS could be due to 2 separate mechanisms, or more likely a combination of both. The first is proximal displacement of the gastro-oesophageal junction within the diaphragmatic hiatus similar to a very early or partial hiatus hernia. The second is proximal migration of the SCJ relative to the gastro-oesophageal junction as a result of proximal lengthening of the cardiac mucosa.

The abnormalities observed at the gastro-oesophageal junction in the large WC group are likely to be explained by the increase in intra-abdominal pressure associated with central obesity and documented in our subjects by their increased intra-gastric pressure. Evidence of the effect of the increased intra-abdominal pressure was the marked proximal displacement of the dome of the costal diaphragm being 2.6 cm higher in the obese group. In contrast, the position of the diaphragmatic hiatus was not displaced proximally, presumably because of the tethering of the crura to the nearby spinal column. It thus appears that the increased intra-abdominal pressure is compressing the GOJ into the undisplaced diaphragmatic hiatus, causing distortion and dysfunction.

The mechanism of the proximal extension of gastric acid within the LOS is unclear but there are several possibilities. First, it could be due to increased intra-abdominal pressure prying open the distal segment of the LOS while the proximal segment remains closed, thus preventing full transsphincteric reflux. This is supported by the shortening of the LOS seen in those with large WC and caused by shortening of the distal component. Second, some of the intrasphincteric acid could be due to a proximal displacement of the GOJ within the diaphragmatic hiatus and thus the leading edge of acid-secreting gastric mucosa lying more proximally within the high-pressure zone. Finally, it is

possible that the deformity of the GOJ impairs the normal distal flow of acid secreted by mucosa within the sphincter and permits it to flow back up into the sphincter and toward the oesophageal squamous mucosa. This is supported by the altered juxtaposition of the intrasphincteric acid and peak LOS pressure seen in the group with large WC, with their pH transition point being at or above their peak sphincter pressure.

The proximal extension of gastric acid within the LOS provides a plausible explanation for the lengthening of the cardiac mucosa¹⁵³. Exposure of the most distal oesophageal squamous mucosa to gastric acid will damage it and with time cause it to be replaced with columnar mucosa suited to an acidic environment. Unlike Barrett's oesophagus, the proximal extension of columnar mucosa associated with central obesity is confined to the intrasphincteric region of the distal oesophagus. Likewise, the proximal extension of acid in our asymptomatic subjects with central obesity is occurring within the LOS and is not traversing it as occurs with traditional reflux disease. This proximal extension of acidity within the LOS might be referred to as intrasphincteric reflux, as opposed to traditional (transsphincteric) reflux.

The lack of heartburn in our healthy volunteers despite the intrasphincteric acidification is interesting. It has been shown previously that the severity of symptoms correlated positively with the extent that the reflux extends up the oesophagus⁴⁶. This very short segment intrasphincteric reflux therefore may not activate sufficient nerve endings to reach consciousness. In addition, or alternatively, the extension of the cardiac mucosa with replacement of squamous mucosa by columnar mucosa may in itself provide some protection from symptom generation with short-segment acid reflux.

In conclusion, we have shown that in the asymptomatic, moderately overweight population without evidence of traditional reflux there is proximal extension of gastric acid within the lower oesophageal sphincter without traditional acid reflux. This mechanism may underlie the observed lengthening of the cardiac mucosa in this group. These findings may be relevant to adenocarcinoma at the gastro-oesophageal junction which is associated with obesity and frequently presents in subjects without a history of reflux disease.

9 Hiatus Hernia in Healthy Volunteers is Associated with Intrasphincteric Reflux and Cardiac Mucosal Lengthening without Traditional Reflux

9.1 Introduction

Hiatus hernia is a key mediator of acid reflux. Although there is an extensive literature on the effect of hiatus hernia on lower oesophageal sphincter function in subjects presenting with reflux symptoms,^{9, 24, 26} there is little on the effects of hiatus hernia detected in healthy volunteers.

In our previous studies, 10 volunteers had a hiatus hernia on MRI scanning and were excluded from analysis¹⁵³. If proximal extension of cardiac columnar mucosa and intrasphincteric acid exposure is indeed due to dysfunction of the lower oesophageal sphincter caused by age and/or central obesity, then similar changes may occur in subjects with lower oesophageal sphincter dysfunction due to hiatus hernia.

In this current study we have examined the anatomy and physiology of the gastro-oesophageal junction in our healthy volunteers with hiatus hernia and compared them with healthy volunteers without hiatus hernia, matched for age, sex and central obesity.

9.2 Methods

As part of the previous study we recruited 61 healthy volunteers negative for *Helicobacter Pylori* and without known gastroesophageal reflux. Fifteen volunteers who completed the full study protocol were found to have a hiatus hernia; ten diagnosed by MRI, 12 by endoscopy and 7 by both modalities. The subgroup diagnosed by MRI was excluded from the original analysis. In this study we compared these volunteers who had a hiatus hernia with age and sex matched controls from the original study cohort.

9.2.1 Study Protocol

9.2.1.1 Study Day 1: Clinical and MRI Assessment

Clinical details were recorded including demographics and anthropometric measures. Volunteers completed a validated survey reporting reflux symptoms¹²⁷. MRI scans of the abdomen were performed (Philips 1.5T MRI scanner, Surrey, UK) before and forty-five minutes after a standardised meal consisting of fried battered fish and chips. A hiatus hernia was identified when the gastro-oesophageal junction was proximal to the diaphragmatic hiatus. Where present on MRI, the length of the hiatus hernia was documented. In addition, the diameter of the gastro-oesophageal junction at the diaphragmatic hiatus was measured in all participants.

9.2.1.2 Study Day 2: Endoscopy with Biopsies and Placement of Radio-opaque Clip

Volunteers attended after an overnight fast. Upper GI endoscopy was carried out using standard equipment with throat spray or intravenous sedation according to volunteer preference. Anatomy of the upper GI tract was examined and hiatus hernia defined endoscopically as separation of the diaphragmatic indentation and the top of the gastric folds by at least 2cm. Where hiatus hernia was identified its length was measured and recorded. Biopsies were taken across the squamo-columnar junction (SCJ) in a cranio-caudal direction to include both squamous mucosa and glandular mucosa in the same sample. Intra-procedure pathology feedback of biopsy accuracy was available and up to three biopsies were taken to achieve an optimal sample allowing measurement of cardiac mucosal length. Finally the SCJ was marked by two endoclips (HX-610-135; Olympus, Southend-on-Sea, UK). Biopsies were carefully orientated for histological processing as previously described (5.2.3)

9.2.1.3 Study Day 3: Combined pH and Manometry with Fluoroscopy

Volunteers attended after an overnight fast. A combined high resolution manometry and pH probe was passed through the anaesthetised nostril. The pH probe used was customised for purpose and made up of 12 pH sensors (Synectics

Medical, Enfield, UK). Manometry recordings were taken using a high resolution probe comprising 36 solid state sensors. The probes were combined in a standardised way to allow correlation of pressure and pH findings. Recordings were taken for 15 minutes with volunteers seated in the upright posture and 15 minutes supine. Volunteers then consumed the same standardised meal as on study day 1 and were asked to eat until full. After the meal, recordings were continued for 45 minutes seated upright and a further 30 minutes supine. Fluoroscopy was performed for thirty seconds during each phase to allow visualisation of the endoscopically placed clip.

9.2.2 Data Analysis

9.2.2.1 Cardiac Mucosal Length

The cardiac mucosa was considered ‘fully measurable’ where consecutive squamous, cardiac and glandular mucosal types were present in continuity in the same biopsy. Specimens were considered ‘measurable’ if squamous mucosa and cardiac mucosa were present in continuity within the same biopsy. A third category of ‘not analysable’ was allowed where none of the samples taken had at least two mucosal subtypes in continuity within the same biopsy. Samples defined as ‘not analysable’ were not included in the measurement of cardiac mucosal length.

The cardiac mucosa was defined as columnar epithelium devoid of parietal cells. The proximal demarcation of cardiac mucosa at the SCJ was clear and the distal limit was taken as the appearance of parietal cells. The cardiac mucosal length was measured using an ocular micrometer by two independent GI pathologists (JJG, MHD) blinded to clinical characteristic of the volunteer.

9.2.3 Inflammatory Scores

Biopsies were semi-quantitatively scored for acute and chronic inflammation and for reactive atypia, a measure of cell turnover and repair, using scores of 0-3 as follows; 0=absent, 1=mild, 2=moderate, 3=severe. Acute inflammation was defined by the presence of polymorphs and chronic by a monocytic infiltrate.

9.2.4 Acid Data

To measure intrasphincteric acid position, the mean pH was calculated for each of the twelve sensors for each phase of the study. The first pH sensor recording a mean pH drop of 1 unit was identified. This was termed the pH transition point. We have previously shown that this point represents the abrupt transition from oesophageal to gastric pH. The position of this sensor relative to the upper border of LOS, the SCJ and the peak LOS pressure was measured. Distances were corrected for 1.1cm spacing of pH sensors.

Acid exposure also was determined at the following points:

- (1) The traditional site 5 cm above the upper border of the LOS
- (2) The sensor 1.1cm proximal to the sensor detecting the pH transition point

These sites were defined as detecting traditional and short segment reflux respectively. Traditional acid reflux was considered present where the pH was below 4 at least 4% of the time at the sensor 5cm proximal to the upper border LOS and short segment reflux where the pH was less than 4 at least 4% of the time in the sensor 1.1cm proximal to the pH transition point.

9.2.5 Prevalence of the Double Peaked Pressure Profile

For each phase of the study the manometric recording was split into 60 second intervals. For each of these segments the pressure profile of the LES was examined using the Manoview analysis software and based on both the colour contour plot and the pressure profile. The profile was classified as 'single' where one pressure peak was identified and 'double' where the LOS comprised two pressure peaks. A third observation of 'not analysable' was allowed where there was insufficient stable sphincter tone to enable classification such as occurred with the presence of transient lower oesophageal sphincter relaxations or frequent swallows. For each group the total time spent in double and single pressure profiles was recorded.

9.2.6 Detailed Analysis of Lower Oesophageal Sphincter

For each of the four periods where fluoroscopic screening was available the LOS was analysed in detail. Data from six consecutive inspirations and six consecutive expirations were selected using a custom-made computer programme. The pressure profile was classified as 'single or double' where one or two peaks were seen respectively.

The position of the upper border LOS was calculated on inspiration as a decrease in pressure to within 2mmHg of intra-gastric pressure moving proximally from the sensors within the LOS to the sensors within the oesophagus. The upper border LOS was used as a local reference point for the positions of the SCJ and pH transition point. Peak LOS pressure was calculated on both inspiration and expiration as the peak pressure within the LOS irrespective of pressure profile. The inspiratory augmentation pressure was calculated by subtracting the expiratory LOS pressure from the inspiratory LOS pressure.

9.2.7 Fluoroscopy

The position of the SCJ was derived from the fluoroscopic images for a median of 6 inspirations and using the manometer and pH sensors as reference and internal scale. This was calculated relative to the upper border LOS.

9.2.8 Statistical Analysis

All results are presented as median and interquartile range unless otherwise stated. The Mann Whitney U Test was used for comparison between groups and differences were considered significant at a p value of less than 0.05.

9.3 Results

9.3.1 Group Characteristics

Of the original study group 15 volunteers (11 male, aged 38-74 years) were found to have hiatus hernia. Age range in the control group was 28-73years ($p=0.206$) and 11 were male. Median BMI in the hiatus hernia group was 25.9kg/m² (Range 21.0-35.6, IQR 5.8) and waist circumference 91.0cm (Range 77-119, IQR 24). Corresponding values for those without hiatus hernia were 28.7 (16.7-34.5, IQR 7.8) ($p=0.650$) and 99cm (70-118cm, IQR 23) ($p=0.820$), respectively.

Twelve of the 15 hiatus hernias were diagnosed by endoscopy, 10 by MRI and 7 by both modalities. For those diagnosed by MRI the median length of the hiatus hernia was 2.3cm (IQR 0.79) and by endoscopy the median length 3 cm (IQR 0).

9.3.2 MRI Measures

The diameter of the diaphragmatic hiatus, measured by MRI was significantly larger in the hiatus hernia group. This was true for both fasting [13.3mm (IQR 5.1) vs. 10.0mm (IQR 2.75), $p=0.001$] and for after the meal [14.9mm (IQR 6.5) vs 9.7mm (IQR 3.45), $p=0.006$].

This widened hiatus was seen irrespective of the method by which the hiatus hernia was originally detected. For those diagnosed with hiatus hernia on the basis of endoscopy the diameter of the hiatus in fasting was 13.6mm (IQR 5.8) compared with 10.6mm (IQR 3.2mm) in those without hiatus hernia on endoscopy ($p=0.003$). For those diagnosed by MRI the diameter of the diaphragmatic hiatus was 15.7mm (IQR 5.2) compared with 10.25mm (IQR 3.1) for those negative for hiatus hernia by MRI ($p<0.001$). For those with hiatus hernia confirmed on two modalities the diameter of the hiatus was widened compared to those with hiatus hernia diagnosed on one modality [17mm (IQR 3.8) versus 12.4mm (IQR 2.6), $p=0.009$ for fasting, and 17.4mm (IQR 4.9) versus 11.1mm (IQR 5.9), $p=0.006$ after the meal].

9.3.3 Junctional Mucosal Characteristics

Three volunteers had Barrett's oesophagus identified endoscopically and were excluded from the analysis of cardiac mucosal length and junctional mucosal characteristics. All three had an associated hiatus hernia. Of the remaining 12 in the hiatus hernia group 9 had cardiac mucosa that was either 'measurable' or 'fully measurable' compared with 13 out of 15 in the control group.

Cardiac mucosa was significantly longer in the group with hiatus hernia compared to controls [3.5mm (IQR 1.0) vs 2.5mm (IQR 1.0), $p=0.014$]. In only 5 of the hiatus hernia group was a full span of the cardiac mucosa obtained in a single biopsy (fully measurable) whilst 11 out of 15 in the control group had a fully measurable cardia ($p=0.038$).

Moderate chronic inflammation of the cardiac mucosa did not differ significantly between groups [median score for mononuclear infiltrate in hiatus hernia group 2.0 (IQR 1.0) vs 2.0 (IQR 1.0) in controls, $p=0.248$]. Reactive atypia, a marker of cell turnover and repair, was also similar between the two groups [median score 2.0 (IQR 1.0) in hiatus hernia group vs 2.0 (IQR 1.0) in controls, $p=0.748$]. Acute inflammation was not a prominent feature in either group and did not differ between groups [median score, based on polymorphonuclear infiltrate, 1.0 (IQR 2) for hiatus hernia group and 0 (IQR 1.0) for controls, $p=0.116$].

9.3.4 Acid Reflux

There was no significant excess of reflux symptoms in those with hiatus hernia compared to those without (Median reflux scores in hiatus hernia group 7 (IQR 3) versus 5 in controls (IQR 3) $p=0.065$). Acid exposure measured in the traditional manner (percentage of time pH was below 4 at 5cm above the LOS) was not a feature in either group and did not differ significantly between groups either before or after the meal. (Table 9.1) Short segment reflux (percentage of time pH was less than 4 at 1.1cm above the pH transition point) was greater in the hiatus hernia group versus controls in the supine posture after a meal. ($p=0.011$, Table 9.1)

TABLE 9.1: ACID EXPOSURE TIME [MEDIAN % TIME PH<4 (IQR)] IN PH SENSORS LOCATED AT 1.1CM PROXIMAL TO THE SCJ AND 5CM ABOVE THE UPPER BORDER LOS IN HEALTHY VOLUNTEERS WITH HIATUS HERNIA AND CONTROLS. (FU: FASTING UPRIGHT; FS: FASTING SUPINE, PPU: POST-PRANDIAL UPRIGHT; PPS: POST-PRANDIAL SUPINE)

		Hiatus Hernia	Controls	P value
Acid Exposure 5cm above LOS	FU	0.0 (0.5)	0.0 (0.0)	0.345
	FS	0.0 (0.0)	0.0 (0.0)	0.285
	PPU	1.8 (6.9)	0.2 (1.2)	0.401
	PPS	0.0 (0.0)	0.0 (0.0)	0.686
Acid Exposure 1.1cm above pH Transition Point	FU	1.2 (26.9)	0.20 (9.40)	0.424
	FS	0.45 (6.7)	0.10 (13.2)	0.314
	PPU	4.25 (45)	4.0 (17.3)	0.330
	PPS	5.45 (25.4)	0.30 (3.20)	0.011

9.3.5 LOS Pressure and Inspiratory Augmentation Pressure

There was no significant difference in the hiatus hernia group compared with controls in peak LOS pressure either on inspiration or on expiration. However inspiratory augmentation pressure was diminished in the hiatus hernia group after the meal in the supine posture. (Table 9.2)

TABLE 9.2: LOS PRESSURE (LOSP) AND INSPIRATORY AUGMENTATION PRESSURE IN HIATUS HERNIA AND CONTROL GROUPS (FU: FASTING UPRIGHT; FS: FASTING SUPINE, PPU: POST-PRANDIAL UPRIGHT; PPS: POST-PRANDIAL SUPINE)

		Hiatus Hernia	Controls	P Value
Peak LOSP on Inspiration (mmHg)(IQR)	FU	36.9 (20.78)	32.2 (21.41)	0.870
	FS	30.7 (13.21)	35.6 (10.24)	0.345
	PPU	29.4 (12.74)	30.1 (16.48)	0.838
	PPS	27.4 (10.63)	34.2 (9.09)	0.137
Peak LOSP on Expiration (mmHg)(IQR)	FU	27.8 (22.04)	21.6 (14.25)	0.683
	FS	26.0 (16.52)	24.2 (7.10)	0.461
	PPU	22.9 (11.74)	18.2 (7.04)	0.074
	PPS	24.8 (13.92)	24.9 (8.57)	0.775
Inspiratory Augmentation Pressure (mmHg)	FU	6.97 (7.76)	10.4 (11.15)	0.624
	FS	5.12 (7.98)	6.12 (12.2)	0.137
	PPU	6.59 (9.07)	12.18 (14.8)	0.217
	PPS	3.82 (9.08)	8.52 (4.61)	0.037

9.3.6 Prevalence of Double Peak on High Resolution Manometry

In those with hiatus hernia the double peaked pressure profile was intermittent rather than fixed being seen on manometry a total of 36.6% of the time across all phases of the study (Table 9.3). Only one volunteer demonstrated a double peaked profile persistently throughout the recording. In the control group, negative for hiatus hernia by both endoscopy and MRI, the double peaked pressure profile was also seen intermittently and for 25.4% of total recorded time. Although the double peak was seen in both groups, there was a strong trend to increased prevalence of the double peak in those with hiatus hernia ($p=0.053$). The prevalence of the double peak for each group across the phases of the study is shown in Table 9.3)

TABLE 9.3: PERCENTAGE TIME SPENT IN DOUBLE PEAKED PRESSURE PROFILE FOR HIATUS HERNIA AND CONTROL GROUPS. FIGURES ARE SHOWN FOR EACH STUDY PHASE AND FOR THE TOTAL RECORDED TIME. (FU: FASTING UPRIGHT; FS: FASTING SUPINE; PPU: POST-PRANDIAL UPRIGHT; PPS: POST-PRANDIAL SUPINE)

	Hiatus Hernia	Controls	P value
FU	40.4%	38.6%	0.826
FS	52%	23.1%	0.077
PPU	32.9%	22.7%	0.285
PPS	28.9%	24%	0.431
Total	36.6%	25.4%	0.054

9.3.7 Intrasphincteric Characteristics of Hiatus Hernia versus Controls

9.3.7.1 Relative Positions of pH Transition Point, SCJ and Upper Border LOS

The pH transition point was determined by the position of the most proximal of the 12 pH sensors showing a mean pH fall of 1 unit. We have previously shown that this sensor represents the abrupt change from oesophageal to gastric pH¹⁵³. In those with hiatus hernia the pH transition point was closer to the upper border LOS in all phases of the study aside from fasting upright (Figure 9.1). In the hiatus hernia group, the SCJ was also more proximally sited within the LOS in FU, PPU and PPS with a trend to significance in FS. There were no differences between the groups in the relative positions of the pH transition point and SCJ except after the meal in the supine posture in which the pH transition point was measured 0.31cm proximal to the SCJ in the hiatus hernia group versus 0.55cm distal to it in controls. (p=0.033). The upper border LOS was located a similar distance from the nares in both groups.

9.3.7.2 Relative Positions of pH Transition Point, SCJ and LOS Peak Pressures

To allow comparison between groups, each having both types of pressure profile, the pH transition point was measured relative to either the proximal pressure peak of a double profile or the isolated peak of a single profile. In the

hiatus hernia group the pH transition point was proximal to this pressure peak after the meal in both upright and supine positions but remained distal throughout in controls (Table 9.4). The differences between the hiatus hernia subjects and controls were most pronounced in the supine posture after the meal and these are illustrated in Figure 9.1.

TABLE 9.4: DETAILED ANALYSIS OF LOS COMPONENTS IN HIATUS HERNIA VERSUS CONTROLS SHOWING POSITIONS OF THE UPPER BORDER LOS, PH TRANSITION POINT, SCJ AND FIRST PRESSURE PEAK. (FU: FASTING UPRIGHT; FS: FASTING SUPINE, PPU: POST-PRANDIAL UPRIGHT; PPS: POST-PRANDIAL SUPINE)

		Hiatus Hernia	Controls	P Value
Nares to upper border LOS (cm)(IQR)	FU	44.5 (2.0)	44.5 (5.0)	P=0.92
	FS	44.5 (3.0)	45.5 (4.0)	P=0.138
	PPU	43.0 (3.5)	43.25 (5.63)	P=0.783
	PPS	44.0 (3.5)	44.0 (3.0)	P=0.365
Upper border LOS to pH Transition Point (cm)(IQR)	FU	2.4 (4.0)	3.15 (1.42)	P=0.245
	FS	0.50 (4.2)	2.35 (3.08)	P=0.048
	PPU	1.1 (3.0)	2.55 (4.73)	P=0.022
	PPS	-0.5 (4.2)	2.30 (4.18)	P=0.008
Upper border LOS to SCJ (cm)(IQR)	FU	2.46 (2.33)	2.94 (1.31)	P=0.046
	FS	2.13 (1.89)	3.22 (1.69)	P=0.055
	PPU	2.21 (2.24)	3.10 (1.26)	P=0.033
	PPS	1.23 (2.07)	2.53(1.57)	P=0.019
SCJ to pH Transition point (cm)(IQR)	FU	0.54 (2.13)	-0.18 (2.47)	P=0.530
	FS	0.22 (3.24)	0.15 (1.90)	P=0.638
	PPU	-0.56 (2.77)	-0.64 (5.44)	P=0.249
	PPS	-0.31 (3.47)	0.54 (4.28)	P=0.033
Proximal Pressure Peak to pH Transition Point (cm)(IQR)	FU	0.40 (3.70)	0.90 (2.53)	P=0.217
	FS	-1.3 (5.18)	0.20 (3.15)	P=0.134
	PPU	-0.60 (2.72)	0.55 (4.48)	P=0.039
	PPS	-2.4 (4.03)	0.7 (4.35)	P=0.002

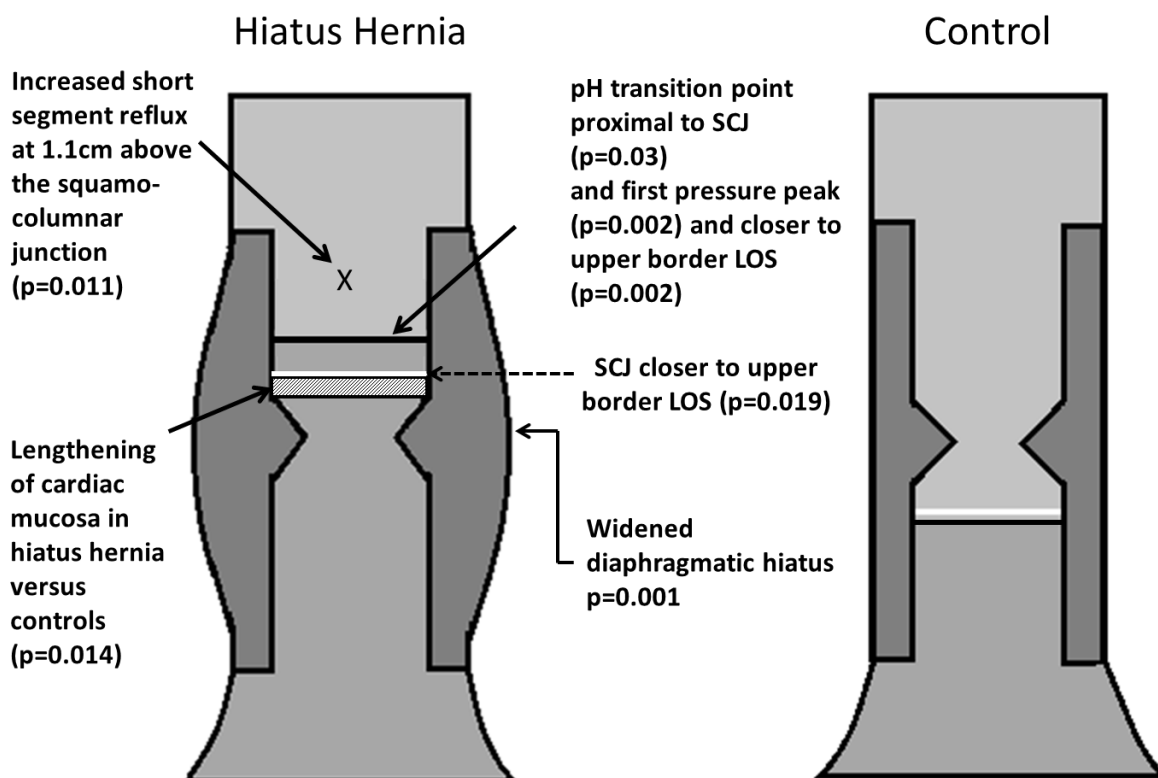


FIGURE 9.1: INTRASPHINCTERIC CHARACTERISTICS OF HIATUS HERNIA VERSUS CONTROLS AFTER A MEAL IN THE SUPINE POSTURE.

9.3.8 Intrasphincteric Characteristics of Hiatus hernia Versus Controls When Both Have Similar Pressure Profile

Both the hiatus hernia subjects and controls showed a double peak pressure profile for a similar proportion of the recording period. We compared the intrasphincteric characteristics of the hiatus hernia versus controls when both showed a single peak profile during fluoroscopy and again when both showed double peak profile. As this reduced the recording period available for analysis, we combined the fasting, postprandial, supine and erect data.

9.3.8.1 Comparison of the Single Peaked Pressure Profile in Hiatus Hernia and Controls

A total of 32 single pressure profiles were detailed during fluoroscopy for the hiatus hernia group and 43 for controls. In the single peaked pressure profile there was no difference between the groups in the position of the upper border LOS from the nares. However the SCJ and pH transition point were more

proximally sited relative to the nares in the group defined as having a hiatus hernia in the original study protocol (Table 9.5)

The pH transition point was closer to the upper border LOS in the hiatus hernia group versus controls. Furthermore the pH transition point was sited proximal to the peak LOS pressure in those with hiatus hernia but distal to it in controls.

TABLE 9.5: ANALYSIS OF SINGLE PEAKED PRESSURE PROFILE IN HIATUS HERNIA AND CONTROLS: POSITIONS OF SCJ, PH TRANSITION POINT AND PEAK LOS PRESSURE RELATIVE TO NARES AND TO UPPER BORDER LOS. RESULTS PRESENTED AS MEDIAN (IQR)

	Hiatus Hernia	Controls	P value
Nares to Upper Border LOS (cm)	44.5 (4.13)	44.5 (3.5)	0.184
Nares to SCJ (cm)	46.1 (4.76)	47.2 (3.99)	0.010
Nares to pH Transition Point (cm)	45.6 (7.10)	48.5 (6.33)	0.004
Upper Border LOS to pH Transition Point (cm)	2.2 (4.28)	2.5 (2.85)	0.011
Upper Border LOS to SCJ (cm)	1.99 (2.63)	2.34 (1.65)	0.081
Peak LES Pressure to pH transition point (cm)	-0.5 (4.60)	0.8 (2.95)	0.003

9.3.8.2 Comparison of the Double-Peaked Pressure Profile in Hiatus Hernia and Controls

A total of 28 double peaked pressure profiles were analysable for the hiatus hernia group verses 16 in controls.

In the double peaked pressure profile the distance from the nares to the upper border LOS was similar between the groups (Table 9.6). The SCJ and the pH transition point were however proximally displaced in those with hiatus hernia

with respect to controls when measured relative to the nares. Both the SCJ and the pH transition point were also more proximally located with respect to the upper border LOS. When the position of the pH transition point was measured with respect to the proximal pressure peak of the double peak it was located proximal to it in those with hiatus hernia and distally in controls.

TABLE 9.6 ANALYSIS OF DOUBLE-PEAKED PRESSURE PROFILE IN HIATUS HERNIA AND CONTROLS: POSITIONS OF SCJ, PH TRANSITION POINT AND PROXIMAL PRESSURE PEAK RELATIVE TO NARES AND UPPER BORDER LOS. RESULTS PRESENTED AS MEDIAN (IQR)

	Hiatus Hernia	Controls	P value
Nares to Upper Border LOS (cm)	43.5 (1.88)	44.5 (4.75)	0.294
Nares to SCJ (cm)	44.9 (4.25)	46.9 (3.94)	0.003
Nares to pH Transition Point (cm)	44.4 (3.90)	47.4 (4.80)	0.002
Upper Border LOS to pH Transition Point (cm)	0.8 (2.55)	2.3 (2.50)	0.003
Upper Border to SCJ (cm)	1.5 (1.68)	3.2 (2.44)	0.008
Proximal Pressure Peak to pH transition point(cm)	-1.2 (3.10)	0.3 (2.70)	0.012

9.4 Discussion

The hiatus hernias that were detected in 25% of our healthy volunteers were not associated with increased traditional transsphincteric acid reflux or reflux symptoms. However, these subjects with hiatus hernia did have proximal extension of their cardiac mucosa. In addition, the hiatus hernia subjects had short segment acid reflux and their pH transition point located proximal to their SCJ following a meal in the supine position. The proximal extension of the cardiac mucosa is likely to be due to squamo-columnar metaplasia of the distal oesophagus induced by the increased intrasphincteric acid exposure.

Of our fifteen healthy volunteers with hiatus hernia, 12 were diagnosed at endoscopy, 10 with MRI scan and 7 by both. The variation in findings by these two tests performed at different times is in keeping with the intermittent nature of hiatus hernia^{29, 30}. The diameter of the diaphragmatic hiatus assessed by MRI was increased in the hiatus hernia subjects consistent with the disorder being associated with a weakness of the diaphragmatic crura. This widened hiatus detected by MRI was the case irrespective of the method by which the hiatus hernia was originally detected although in those confirmed to have a hiatus hernia by both modalities the widening was most apparent. This may reflect those with a more substantial crural defect spending more time in the hiatus hernia state.

High resolution manometry has been claimed to be useful in diagnosing hiatus hernia on the basis of demonstration of a double-peak pressure profile due to the separation of the intrinsic and extrinsic sphincter.¹⁵⁶ In our subjects with hiatus hernia, the double peaked pattern was observed intermittently and for less than the 50% of the recording time and this was similar to the subjects who were negative for hiatus hernia by both MRI scan and endoscopy. Scheffer et al reported that a double-peak was observed 53.2% of the time in patients with reflux disease compared to only 14.5% of the time in controls¹⁵⁷. The same group in a further study reported that a double-peak was present for a similar period in reflux patients with a small hiatus hernia and controls but was present for a greater proportion of time in reflux patients with a large hiatus hernia²⁹. The similar prevalence of double-peak in our subjects with hiatus hernia versus controls is consistent with them having small hiatus hernias. The explanation for the double peak present in our healthy controls and also those studied by Bredenoord et al is unclear. However, Miller et al¹⁵⁸ described three pressure contributions to the LOS in healthy subjects; one from the crural diaphragm, one attributable to the intrinsic LOS and a third which the authors hypothesised represented the sling and clasp fibres of the proximal stomach i.e. the gastro-oesophageal flap valve. The third pressure contribution was absent in the patients with reflux symptoms. It may be therefore that rather than representing an intermittent hiatus hernia, the double peak in our healthy volunteers represents the manometric signature of a healthy gastro-oesophageal flap valve.

There was no evidence of increased acid exposure in our hiatus hernia subjects versus controls when measured at the traditional location 5cm above the lower oesophageal sphincter. In addition, our subjects with hiatus hernia did not have increased reflux symptoms. Hiatus hernia is associated with reflux disease⁹ and the absence of traditional reflux in our healthy volunteers with hiatus hernia might be explained by their well-maintained intrinsic LOS pressure. They had evidence of impaired extrinsic sphincter function as seen in their widened hiatus on MRI and their impaired respiratory augmentation. The lack of reduction of peak LOS pressure in our hiatus hernia subjects despite this clear evidence of impaired extrinsic sphincter function indicates well maintained intrinsic sphincter function and the latter may be protecting them from transsphincteric reflux. The hiatus hernias in our present study must represent the majority of hiatus hernias in the general population as we detected them in 25% of healthy volunteers and the fact that they were not associated with transsphincteric reflux may explain the controversies which have existed about the relevance of hiatus hernia to reflux disease.¹⁵⁹

Though our healthy volunteers with hiatus hernia did not have traditional transsphincteric reflux, they did have evidence of short segment acid reflux detected within the sphincter region at 1.1cm proximal to the pH transition point but only following the meal and in the supine position. The occurrence following a meal may be explained by the increased stress on the lower oesophageal sphincter known to occur following a meal²⁷ and the occurrence only in the supine position due to the fact that hiatus hernias tend to reduce after a meal when the subject is in the erect position.¹⁵⁷

Our healthy volunteers with hiatus hernia had abnormalities of their mucosa within the region of the lower oesophageal sphincter. The length of their columnar cardiac mucosa was greater compared to those without hiatus hernia and this was after full correction for age and central obesity. In addition, the number of volunteers whose mucosa was longer than could be measured by our technique was significantly greater in those with versus without hiatus hernia indicating that the observed difference may be an underestimate. Three volunteers with hiatus hernia had endoscopic evidence of Barrett's oesophagus

and were excluded from analysis. In all subjects, the cardiac mucosa was inflamed.

More detailed analysis of the gastro-oesophageal junction was possible during the periods of fluoroscopy when we had accurate information on the relative positions of the squamo-columnar junction, pH transition point and sphincter manometric landmarks. The distance from the nares to the upper border of the LOS was not significantly different but in the hiatus hernia group the squamo-columnar junction and pH transition point were closer to the nares and also closer to the upper border of the LOS. After the meal the pH transition point was also proximal to the first pressure peak in the group with hiatus hernia but distal throughout in controls. These differences were also apparent when the hiatus hernia and controls were compared when showing similar pressure profiles (i.e. single or double peak).

How can we explain the observed proximal displacement of the pH step-up point and squamo-columnar junction relative to the upper border of the LOS and nares without the proximal displacement of the upper border of the LOS relative to the nares? Perhaps this represents the alteration in the relationship between extrinsic and intrinsic sphincters in those with a small or intermittent hiatus hernia. In the absence of a hiatus hernia where the anatomy at the gastro-oesophageal junction is preserved the extrinsic sphincter overlaps and reinforces the intrinsic sphincter and the pressure inversion point is proximal to the peak sphincter pressure. The upper border of the LOS would be detected as a pressure increase from oesophageal pressure but the pressure contribution could come from the extrinsic sphincter, the intrinsic sphincter or both. Our observations could be consistent with the upper border LOS in normal subjects being formed by the extrinsic sphincter with the intrinsic sphincter positioned just distally. Thus in our subjects with early hiatus hernia there could be proximal movement of the GOJ including the intrinsic sphincter, SCJ and pH transition point within and even across the extrinsic sphincter. This would only be detectable from the nares once it was persistently proximally displaced with respect to the extrinsic sphincter. Some of the proximal displacement of the SCJ may also be explained by the proximal extension of cardia mucosa and proximal displacement of the pH transition point by intrasphincteric ingress of gastric acid. Finally, the lack of

proximal displacement might be partly artefactual due to difficulty in detecting a small change over a relatively long distance.

The lengthening of the cardiac mucosa is likely to be due to the observed acid ingress within the sphincteric region and consequent columnar metaplasia of the distal oesophageal squamous mucosa. Several of the abnormalities observed in our healthy volunteers with hiatus hernia are likely to contribute to the intrasphincteric reflux. The squamo-columnar junction normally lies within the region of the intrinsic sphincter and closure of the latter prevents gastric juice from refluxing onto oesophageal squamous mucosa. However, maintaining closure of the LOS also depends upon its reinforcement by the extrinsic sphincter and in our hiatus hernia subjects there was weakness of the extrinsic sphincter and intermittent loss of its superimposition relative to the intrinsic sphincter. This impairment of extrinsic sphincter function will predispose to distal opening of the intrinsic sphincter and acid ingress. The observation that the pH transition point in our hiatus hernia subjects was positioned proximal to the peak pressure point within the sphincter is also likely to be important. This will mean that acid secreted by the most proximal gastric mucosa lying above this peak pressure point will tend to flow proximally on to the most distal squamous mucosa rather than distally into the stomach.

These changes observed in subjects with hiatus hernia are similar to those which we observed in subjects without hiatus hernia and associated either with central obesity or increased age. Together, they suggest that stress or ageing or damage to the supporting structures of the gastro-oesophageal junction allow acid to ingress within the sphincteric region encroaching on the most distal oesophageal mucosa without increased reflux across the sphincter.

This dysfunction of the gastroesophageal barrier and associated metaplasia of the distal oesophageal mucosa appears to be common in our population. It occurs in the 25% of healthy volunteers who have this type of hiatus hernia and is also observed in healthy volunteers without hiatus hernia but with central obesity or with increasing age. Though the metaplastic change arising at the gastro-oesophageal junction might not carry the high risk of adenocarcinoma associated with transsphincteric reflux and full Barrett's oesophagus, the high

prevalence of the condition may contribute to the significant number of cancers occurring at the cardia and gastro-oesophageal junction in subjects without a reflux history.

10 Discussion

This work brings together studies of the pathology and physiology of the gastro-oesophageal junction in healthy volunteers. The gastro-oesophageal junction is disproportionately affected by pathology and recent years have seen a marked increase in the incidence of adenocarcinoma at this site.⁷⁵ Barrett's oesophagus and reflux disease are documented risk factors for adenocarcinoma but many cases arise in those without a history of reflux disease or known Barrett's oesophagus suggesting a role for mechanisms other than traditional reflux.^{35, 60}

To study the gastro-oesophageal junction in detail we employed novel techniques including high resolution measurements of pH and manometry. During our prolonged recordings the manometry readings appeared unstable. Given the accuracy required for detailed manometric assessment of the lower oesophageal sphincter this observed error posed a potential problem. Examining this further on the benchtop we were able to characterise two components of the error identified on the manometry trace; an initial step up in the recorded pressure attributable to the temperature change from room temperature to body temperature; and an ongoing pressure drift with time. We termed these errors thermal effect and baseline drift respectively.¹³⁵

Whilst documenting the error is important, arguably more important is addressing the error and optimising the accuracy of recordings. In communication with the manufacturer we learned of a linear correction process already within the capabilities of the current recording system but not well recognised or routinely applied. Indeed employing this corrective process at all requires both knowledge of the potential error and direct communication with the manufacturer. For this process the user must record conditions of body temperature and zero applied pressure at the start and end of a study. The software then extrapolates between these points assuming a linear drift and re-zeroes the baseline accordingly. For our studies we incorporated a linear correction to address both thermal effect and baseline drift into our custom designed software. Testing this process on the benchtop data we found a minimal residual error of 0.3mmHg overall independent of study duration.

One of the main themes of this work was to study the pathological changes at the gastro-oesophageal junction in a healthy population. In particular to explore the hypothesis first proposed by Chandrasoma⁸ that the cardiac mucosa at the gastro-oesophageal junction is not an innate but rather an acquired structure reflecting squamous to columnar metaplasia. To study the cardia in detail in healthy volunteers presented several challenges, not least developing a method for accurate length measurement of this mucosa in healthy volunteers. The characteristics of the cardia have been previously studied both in resection specimens⁶² and in patients in whom a protocol for mapping biopsies of the gastro-oesophageal junction was developed to systematically characterise the area.⁶³ We were concerned that discontinuous sampling of the mucosa could introduce inconsistencies in length measurement particularly given the movement of the gastro-oesophageal junction with respiration and the poor resolution of distance measurement on a conventional endoscope. Thus we sought to sample the mucosa in its entirety in a single biopsy. To do this we used large capacity forceps with a jaw span of 8mm being the largest forceps that would fit down a standard biopsy channel of the endoscope. We developed a protocol for taking the biopsies to maximise the chances of successfully capturing a span of the biopsy in a single sample including intra-procedure pathological feedback.

Despite this there were a proportion of volunteers whose cardia could not be fully captured in a single biopsy. In some volunteers this was sampling error but in most cases squamous and cardiac mucosae were present and in continuity and despite an average biopsy length of 6.5mm the cardia was incompletely measured. To minimise the impact of this on the results of our main study (Chapter 7) we confined the results relating to cardiac mucosal length and any correlations with cardiac mucosal length to those with a fully measurable cardia defined by the presence of three mucosal subtypes in continuity. For the study examining mucosal characteristics in those found to have hiatus hernia only 5 of 12 volunteers without Barrett's oesophagus had a fully measurable cardia compared with 11 out of 15 in the control group. For this study we allowed a less strict definition of cardiac mucosal length 'measureable' rather than fully measureable where we were able to quantify the length of cardiac mucosa present but not to obtain a full span. This does represent a limitation of our

methodology but we considered that any effect of this on our results would be to underestimate the impact of a hiatus hernia on cardiac mucosa length and therefore there may be an even greater difference between the groups than we were able to measure.

We were able to demonstrate significant lengthening of the cardiac mucosa in association with waist circumference and age and we propose that this lengthening represents metaplastic transformation of distal squamous mucosa as a result of acid damage. This supports the original hypothesis proposed by Chandrasoma which has admittedly not garnered universal support. Those who argue against the acquired cardia hypothesis have cited its presence in children and its universal presence in adults as evidence of an innate rather than an acquired structure.^{68, 160} Many studies in this area have been plagued by inconsistencies in definition and we deliberately chose the strict histological definition of the cardia to avoid confusion. In our population cardiac mucosa was universally present although length varied with the clinical characteristics of the volunteer. In no individual did we observe direct transition from squamous to oxyntic mucosa or even to oxynto-cardiac mucosa. There are at least two possible explanations for this. One is that acid damage to distal squamous mucosa is prevalent in our population under study such that by adulthood all have some evidence, albeit only mm, of columnar metaplasia. The second may be a reflection of our method of sampling. We were not able to sample the entire circumference of the squamo-columnar junction in the way that is possible with resection specimens and may have missed areas of direct transition from squamous to oxyntic mucosa.

To develop the hypothesis that the cardia is acquired rather than innate we studied the inflammatory characteristics of the mucosal subtypes present at the gastro-oesophageal junction. We also employed immunohistochemistry to compare the cardiac mucosa in our healthy volunteers to a cohort of patients with Barrett's oesophagus. We found that the cardiac mucosa was universally chronically inflamed and markedly more so than the adjacent oxyntic mucosa. In squamous mucosa the inflammation was most marked distally with reactive atypia most pronounced immediately adjacent to cardiac mucosa indicating a mucosa under stress. On immunostaining cardiac mucosa resembled non-IM

Barrett's in six of the seven immunohistological markers of differentiation of GI epithelium whereas the other mucosal subtypes studies (oxynto-cardiac, oxyntic and antral) differed from Barrett's mucosa with respect to at least three of the immunostains. Long segment Barrett's oesophagus is typically a patchwork of intestinal and non-intestinal columnar metaplasia with a greater proportion of the latter distally. Cardiac mucosa is at the most distal end of the oesophagus where columnar metaplasia would typically be most similar to non-IM rather than IM metaplasia. Taken together, the observations that the cardia mucosa lengthens with age and with measures of central obesity and the staining demonstrating that cardiac mucosa is histologically indistinguishable from non-IM Barrett's oesophagus indicates that the cardiac mucosa is acquired by acid damage to distal squamous mucosa.

Although Barrett's oesophagus and gastro-oesophageal reflux disease are well documented risk factors for oesophageal adenocarcinoma a significant proportion of cases occur in their absence. We have hypothesised and demonstrated a mechanism of acid exposure at the gastro-oesophageal junction that may reconcile this apparent paradox^{27, 152, 153}. Our volunteers had no known reflux disease and were selected from the healthy population. Current or previous PPI use excluded participation in the study as did previous attendance at primary or secondary care for symptoms of acid reflux. The lack of significant acid exposure 5cm above the upper border of the lower oesophageal sphincter was confirmed on pHmetry with no subjects demonstrating a pH below 4 more than 4% of recorded time at this level. Whilst the recordings were prolonged lasting more than 105 minutes in total and including the effect of posture and a meal, they do not parallel the clinical approach to diagnosing significant acid reflux. Nonetheless, in combination with the lack of symptoms and previous and current anti-secretory therapy we have reasonable evidence for lack of significant traditional reflux in our study population.

Although our subjects did not have significant transsphincteric reflux those with obesity did demonstrate dysfunction of the gastro-oesophageal barrier allowing acid influx within the lower oesophageal sphincter. We termed this mode of acid exposure intrasphincteric reflux. In our volunteers with a large waist circumference we observed shortening of the lower oesophageal sphincter after

the meal attributable to loss of the distal component. Acid was seen to move proximally within but not across the lower oesophageal sphincter evident by a more proximal positioning of the pH transition point relative to the upper border of the sphincter. After the meal the leading edge of this intrasphincteric acid was seen to encroach upon or even cross the peak sphincter pressure. We have suggested that this acid may then be influenced by a local pressure gradient promoting pooling or even retrograde flow of acid rather than distal clearance but this is speculation.

In previous similar work³⁷ the location of the leading edge of gastric acidity has been measured using a pH probe clipped in place to minimise movement artefact. We did not employ this approach in our studies instead opting to combine the high resolution pH probe to the manometry probe allowing close correlation of pH and manometry data. The pH transition point is defined by a 1u fall in mean pH which we have shown corresponds to a pH of less than 4 for 38 to 58 % of the time. We have defined short segment reflux at the sensor proximal to the pH transition point by the percentage of time the pH was below 4 and have interpreted acid exposure at these sites as proximal ingress of acid within the sphincter. However it is also possible that the pH sensor is recording intermittent gastric acidity due to the pH probe dipping into gastric acid with movement of the junction such as occurs with respiration and swallows. Whether or not this represents reflux, it holds true that this intermittent acid exposure occurs more proximally within the sphincter in association with obesity and indeed with hiatus hernia.

Interestingly in the volunteers with a large waist circumference the leading edge of gastric acidity was seen to move up in tandem with the squamo-columnar junction. How can we explain the observed proximal displacement of the SCJ? Perhaps this partly reflects the previously demonstrated lengthening of the cardiac mucosa. However since the difference between the groups in the length of the cardia is of the order of mm it is unlikely that this is the only explanation. Another possibility is that the proximal displacement of the squamo-columnar junction represents an early subclinical hiatus hernia in the large WC group with proximal movement of the intrinsic sphincter relative to the extrinsic. In support of this further work from our group has demonstrated that application of a waist

belt to apply external abdominal compression in those with obesity can induce a small hiatus hernia¹²⁵. This would exacerbate any tendency to excess local acid exposure.

Our final study in this series aimed to analyse the impact of hiatus hernia on the barrier function of the gastro-oesophageal junction in healthy volunteers. Much of the published work on hiatus hernia is in patients with known gastro-oesophageal reflux disease and its role in the pathophysiology of acid reflux in this context is well established.^{9, 24} As part of our study protocol we identified a subgroup of volunteers with hiatus hernia but without known reflux disease which provided us with an opportunity to study the effect of a hiatus hernia in this healthy population. There was no significant transsphincteric reflux in the group with hiatus hernias despite evidence of GOJ dysfunction. However there was short segment reflux and intrasphincteric acid reflux in this group compared to those without hiatus hernia.

Hiatus hernia was diagnosed by MRI or endoscopy with moderate concordance. Both endoscopy and radiology have their limitations with previously documented sensitivities of 73% for endoscopy and barium swallow.¹⁵⁶ There is little direct information on the role of MRI in this context but in one study the accuracy of dynamic MRI in diagnosing reflux related disorders including hiatus hernia was 79%.¹⁶¹ In our study population the hiatus hernias detected were small, 2-3cm in length. It is increasingly recognised that small hiatus hernias are intermittent rather than fixed and in consequence may be missed by diagnostic modalities limited to a snapshot in time. In addition endoscopy, performed with air insufflation of the stomach, represents non-physiological conditions. This has led some to suggest that high resolution manometry, having the advantage of continuous and prolonged recording of the pressure profile across the junction, may be more sensitive, up to 92% in a recent comparison¹⁵⁶. Comparisons are marred by the lack of a gold standard and for small hiatal hernias it may also be that we are artificially trying to separate a continuum into a dichotomy. Nevertheless we recognise that this diagnostic difficulty has the potential to impact on our analysis as it does on all similar work.

The prolonged manometry recordings in those with hiatus hernia demonstrated that the double peak was observed intermittently and only one volunteer demonstrated a fixed double pressure profile for the entire duration of the recording. This is consistent with the intermittent nature of early hiatus hernia and has been previously described.^{29, 30} Interestingly despite the absence of evidence for hiatus hernia on endoscopy or MRI, the control group also demonstrated a double peak on manometry for a similar proportion of recorded time. Whether or not this double peak reflects a hiatus hernia is unclear from our data. It is unlikely to be artefact as it was observed intermittently rather than persistently. It may represent separation of intrinsic and extrinsic sphincters or perhaps there is another pressure contribution to the profile such as sling and clasp fibres of the gastro-oesophageal flap valve.

When we studied the double pressure profiles of the hiatus hernia group compared to the control group several differences were apparent. The pH transition point and squamo-columnar junction were closer to the nares and to the upper border LOS in those with a hiatus hernia with the pH transition point traversing the proximal pressure peak in the HH group. It may be therefore that the double peak in the control group is actually a reflection of distal positioning of the intrinsic sphincter with respect to the extrinsic sphincter rather than proximal movement as would be seen with a hiatus hernia. This may also explain why we did not see a difference in the distance from the nares to the upper border of the LOS between the groups. If we assume that in the control group the proximal peak represents the extrinsic sphincter then measuring nares to the upper border would be a measurement of nares to extrinsic sphincter. As hiatus hernia develops the intrinsic sphincter would first move proximally within the hiatus and then across the hiatus so that the intrinsic sphincter was located proximal to the extrinsic. In this case the measurement of nares to upper border would be a reflection of nares to intrinsic sphincter now a few cm proximally displaced but only detectable as a minor difference from the nares.

Despite a lack of transsphincteric reflux, hiatus hernia in our healthy population was associated with increased distal acid exposure. This was measurable as excess short segment reflux and proximal positioning of the pH transition point

but was also reflected pathologically by lengthening of the cardiac mucosa in this group.

In summary therefore we have presented a series of studies examining the pathology and physiology of the gastro-oesophageal junction in healthy volunteers without gastro-oesophageal reflux disease. We have demonstrated a lengthening of the cardiac mucosa at the gastro-oesophageal junction in association with age, central obesity and hiatus hernia. We have further studied this mucosa with immunohistochemistry and proven it be histologically indistinguishable from Barrett's oesophagus without intestinal metaplasia. And finally we have hypothesised and demonstrated intrasphincteric acid exposure in the absence of traditional reflux as a plausible mechanism underlying the observed mucosal abnormalities. These observations are likely to be relevant to adenocarcinoma of the gastro-oesophageal junction.

References

1. Vakil N, van Zanten SV, Kahrilas P, et al. The Montreal definition and classification of gastroesophageal reflux disease: a global evidence-based consensus. *Am J Gastroenterol* 2006;101:1900-20; quiz 1943.
2. El-Serag HB, Sweet S, Winchester CC, et al. Update on the epidemiology of gastro-oesophageal reflux disease: a systematic review. *Gut* 2014;63:871-80.
3. Lundell LR, Dent J, Bennett JR, et al. Endoscopic assessment of oesophagitis: clinical and functional correlates and further validation of the Los Angeles classification. *Gut* 1999;45:172-80.
4. Morson BC, Belcher JR. Adenocarcinoma of the oesophagus and ectopic gastric mucosa. *Br J Cancer* 1952;6:127-30.
5. Lepage C, Drouillard A, Jouve JL, et al. Epidemiology and risk factors for oesophageal adenocarcinoma. *Dig Liver Dis* 2013;45:625-9.
6. Jemal A, Bray F, Center MM, et al. Global cancer statistics. *CA Cancer J Clin* 2011;61:69-90.
7. Boeckstaens G, El-Serag HB, Smout AJ, et al. Symptomatic reflux disease: the present, the past and the future. *Gut* 2014;63:1185-93.
8. Chandrasoma P. Controversies of the cardiac mucosa and Barrett's oesophagus. *Histopathology* 2005;46:361-73.
9. Lee YY, McColl KE. Pathophysiology of gastroesophageal reflux disease. *Best Pract Res Clin Gastroenterol* 2013;27:339-51.
10. Helm JF, Dodds WJ, Pelc LR, et al. Effect of esophageal emptying and saliva on clearance of acid from the esophagus. *N Engl J Med* 1984;310:284-8.
11. Barham CP, Gotley DC, Mills A, et al. Precipitating causes of acid reflux episodes in ambulant patients with gastro-oesophageal reflux disease. *Gut* 1995;36:505-10.
12. Dent J, Holloway RH, Toouli J, et al. Mechanisms of lower oesophageal sphincter incompetence in patients with symptomatic gastroesophageal reflux. *Gut* 1988;29:1020-8.
13. van Herwaarden MA, Samsom M, Smout AJ. Excess gastroesophageal reflux in patients with hiatus hernia is caused by mechanisms other than transient LES relaxations. *Gastroenterology* 2000;119:1439-46.
14. Dodds WJ, Dent J, Hogan WJ, et al. Mechanisms of gastroesophageal reflux in patients with reflux esophagitis. *N Engl J Med* 1982;307:1547-52.
15. Mittal RK, Fisher MJ. Electrical and mechanical inhibition of the crural diaphragm during transient relaxation of the lower esophageal sphincter. *Gastroenterology* 1990;99:1265-8.
16. Holloway RH, Penagini R, Ireland AC. Criteria for objective definition of transient lower esophageal sphincter relaxation. *Am J Physiol* 1995;268:G128-33.
17. Lee YY, Whiting JG, Robertson EV, et al. Kinetics of transient hiatus hernia during transient lower esophageal sphincter relaxations and swallows in healthy subjects. *Neurogastroenterol Motil* 2012;24:990-e539.
18. Trudgill NJ, Riley SA. Transient lower esophageal sphincter relaxations are no more frequent in patients with gastroesophageal reflux disease than in asymptomatic volunteers. *Am J Gastroenterol* 2001;96:2569-74.

19. Pandolfino JE, Shi G, Trueworthy B, et al. Esophagogastric junction opening during relaxation distinguishes nonhernia reflux patients, hernia patients, and normal subjects. *Gastroenterology* 2003;125:1018-24.
20. Kahrilas PJ, Dodds WJ, Hogan WJ, et al. Esophageal peristaltic dysfunction in peptic esophagitis. *Gastroenterology* 1986;91:897-904.
21. Dent J, Dodds WJ, Hogan WJ, et al. Factors that influence induction of gastroesophageal reflux in normal human subjects. *Dig Dis Sci* 1988;33:270-5.
22. Westhoff B, Brotze S, Weston A, et al. The frequency of Barrett's esophagus in high-risk patients with chronic GERD. *Gastrointest Endosc* 2005;61:226-31.
23. Zagari RM, Fuccio L, Wallander MA, et al. Gastro-oesophageal reflux symptoms, oesophagitis and Barrett's oesophagus in the general population: the Loiano-Monghidoro study. *Gut* 2008;57:1354-9.
24. Kahrilas PJ, Lin S, Chen J, et al. The effect of hiatus hernia on gastro-oesophageal junction pressure. *Gut* 1999;44:476-82.
25. Beaumont H, Bennink RJ, de Jong J, et al. The position of the acid pocket as a major risk factor for acidic reflux in healthy subjects and patients with GORD. *Gut* 2010;59:441-51.
26. Sloan S, Kahrilas PJ. Impairment of esophageal emptying with hiatal hernia. *Gastroenterology* 1991;100:596-605.
27. Clarke AT, Wirz AA, Manning JJ, et al. Severe reflux disease is associated with an enlarged unbuffered proximal gastric acid pocket. *Gut* 2008;57:292-7.
28. Pandolfino JE, Kim H, Ghosh SK, et al. High-resolution manometry of the EGJ: an analysis of crural diaphragm function in GERD. *Am J Gastroenterol* 2007;102:1056-63.
29. Bredenoord AJ, Weusten BL, Carmagnola S, et al. Double-peaked high-pressure zone at the esophagogastric junction in controls and in patients with a hiatal hernia: a study using high-resolution manometry. *Dig Dis Sci* 2004;49:1128-35.
30. Bredenoord AJ, Weusten BL, Timmer R, et al. Intermittent spatial separation of diaphragm and lower esophageal sphincter favors acidic and weakly acidic reflux. *Gastroenterology* 2006;130:334-40.
31. Corley DA, Buffler PA. Oesophageal and gastric cardia adenocarcinomas: analysis of regional variation using the Cancer Incidence in Five Continents database. *Int J Epidemiol* 2001;30:1415-25.
32. Derakhshan MH, Arnold M, Brewster DH. Worldwide Inverse Association between Gastric Cancer and Esophageal Carcinoma Suggesting a Common Environmental Factor Exerting Opposite Effects. *Am J Gastroenterol* 2015.
33. Steevens J, Botterweck AA, Dirx MJ, et al. Trends in incidence of oesophageal and stomach cancer subtypes in Europe. *Eur J Gastroenterol Hepatol* 2010;22:669-78.
34. Olsen CM, Pandeya N, Green AC, et al. Population attributable fractions of adenocarcinoma of the esophagus and gastroesophageal junction. *Am J Epidemiol* 2011;174:582-90.
35. Corley DA, Levin TR, Habel LA, et al. Surveillance and survival in Barrett's adenocarcinomas: a population-based study. *Gastroenterology* 2002;122:633-40.
36. Fletcher J, Wirz A, Young J, et al. Unbuffered highly acidic gastric juice exists at the gastroesophageal junction after a meal. *Gastroenterology* 2001;121:775-83.
37. Clarke AT, Wirz AA, Seenan JP, et al. Paradox of gastric cardia: it becomes more acidic following meals while the rest of stomach becomes less acidic. *Gut* 2009;58:904-9.

38. Hila A, Bouali H, Xue S, et al. Postprandial stomach contents have multiple acid layers. *J Clin Gastroenterol* 2006;40:612-7.
39. Kuiken S, Van Den Elzen B, Tytgat G, et al. Evidence for pooling of gastric secretions in the proximal stomach in humans using single photon computed tomography. *Gastroenterology* 2002;123:2157-8; author reply 2158.
40. Pandolfino JE, Zhang Q, Ghosh SK, et al. Acidity surrounding the squamocolumnar junction in GERD patients: "acid pocket" versus "acid film". *Am J Gastroenterol* 2007;102:2633-41.
41. Sauter M, Curcic J, Menne D, et al. Measuring the interaction of meal and gastric secretion: a combined quantitative magnetic resonance imaging and pharmacokinetic modeling approach. *Neurogastroenterol Motil* 2012;24:632-8, e272-3.
42. Simonian HP, Vo L, Doma S, et al. Regional postprandial differences in pH within the stomach and gastroesophageal junction. *Dig Dis Sci* 2005;50:2276-85.
43. Mitchell DR, Derakhshan MH, Robertson EV, et al. The Role of the Acid Pocket in Gastroesophageal Reflux Disease. *Am J Gastroenterol* 2015;In Press.
44. Goetze O, Treier R, Fox M, et al. The effect of gastric secretion on gastric physiology and emptying in the fasted and fed state assessed by magnetic resonance imaging. *Neurogastroenterol Motil* 2009;21:725-e42.
45. Bredenoord AJ, Weusten BL, Curvers WL, et al. Determinants of perception of heartburn and regurgitation. *Gut* 2006;55:313-8.
46. Cicala M, Emerenziani S, Caviglia R, et al. Intra-oesophageal distribution and perception of acid reflux in patients with non-erosive gastro-oesophageal reflux disease. *Aliment Pharmacol Ther* 2003;18:605-13.
47. Emerenziani S, Zhang X, Blondeau K, et al. Gastric fullness, physical activity, and proximal extent of gastroesophageal reflux. *Am J Gastroenterol* 2005;100:1251-6.
48. Fletcher J, Wirz A, Henry E, et al. Studies of acid exposure immediately above the gastro-oesophageal squamocolumnar junction: evidence of short segment reflux. *Gut* 2004;53:168-73.
49. Mekapati J, Knight LC, Maurer AH, et al. Transsphincteric pH profile at the gastroesophageal junction. *Clin Gastroenterol Hepatol* 2008;6:630-4.
50. Loughney T, Maydonovitch CL, Wong RK. Esophageal manometry and ambulatory 24-hour pH monitoring in patients with short and long segment Barrett's esophagus. *Am J Gastroenterol* 1998;93:916-9.
51. Pandolfino JE, Lee TJ, Schreiner MA, et al. Comparison of esophageal acid exposure at 1 cm and 6 cm above the squamocolumnar junction using the Bravo pH monitoring system. *Dis Esophagus* 2006;19:177-82.
52. Seguro FC, Santo MA, Szachnowicz S, et al. Use of multiple channel pH monitoring for evaluation of ultra-distal reflux in patients after fundoplication for treatment of Barrett's esophagus. *Dis Esophagus* 2011;24:381-7.
53. Chandrasoma P, Makarewicz K, Wickramasinghe K, et al. A proposal for a new validated histological definition of the gastroesophageal junction. *Hum Pathol* 2006;37:40-7.
54. Manning JJ, Wirz AA, McColl KE. Nitrogenous chemicals generated from acidification of saliva influence transient lower oesophageal sphincter relaxations. *Scand J Gastroenterol* 2007;42:1413-21.
55. Hayward J. The lower end of the oesophagus. *Thorax* 1961;16:36-41.

56. Spechler SJ, Zeroogian JM, Antonioli DA, et al. Prevalence of metaplasia at the gastro-oesophageal junction. *Lancet* 1994;344:1533-6.
57. Sharma P, Morales TG, Sampliner RE. Short segment Barrett's esophagus--the need for standardization of the definition and of endoscopic criteria. *Am J Gastroenterol* 1998;93:1033-6.
58. McClave SA, Boyce HW, Jr., Gottfried MR. Early diagnosis of columnar-lined esophagus: a new endoscopic diagnostic criterion. *Gastrointest Endosc* 1987;33:413-6.
59. Sharma P, Dent J, Armstrong D, et al. The development and validation of an endoscopic grading system for Barrett's esophagus: the Prague C & M criteria. *Gastroenterology* 2006;131:1392-9.
60. Lagergren J, Bergstrom R, Lindgren A, et al. Symptomatic gastroesophageal reflux as a risk factor for esophageal adenocarcinoma. *N Engl J Med* 1999;340:825-31.
61. Gulmann C, Rathore O, Grace A, et al. 'Cardiac-type' (mucinous) mucosa and carditis are both associated with *Helicobacter pylori*-related gastritis. *Eur J Gastroenterol Hepatol* 2004;16:69-74.
62. Chandrasoma PT, Der R, Ma Y, et al. Histology of the gastroesophageal junction: an autopsy study. *Am J Surg Pathol* 2000;24:402-9.
63. Chandrasoma PT, Der R, Ma Y, et al. Histologic classification of patients based on mapping biopsies of the gastroesophageal junction. *Am J Surg Pathol* 2003;27:929-36.
64. Glickman JN, Fox V, Antonioli DA, et al. Morphology of the cardia and significance of carditis in pediatric patients. *Am J Surg Pathol* 2002;26:1032-9.
65. Marsman WA, van Sandick JW, Tytgat GN, et al. The presence and mucin histochemistry of cardiac type mucosa at the esophagogastric junction. *Am J Gastroenterol* 2004;99:212-7.
66. Oberg S, Peters JH, DeMeester TR, et al. Inflammation and specialized intestinal metaplasia of cardiac mucosa is a manifestation of gastroesophageal reflux disease. *Ann Surg* 1997;226:522-30; discussion 530-2.
67. Zhou H, Greco MA, Daum F, et al. Origin of cardiac mucosa: ontogenic consideration. *Pediatr Dev Pathol* 2001;4:358-63.
68. Kilgore SP, Ormsby AH, Gramlich TL, et al. The gastric cardia: fact or fiction? *Am J Gastroenterol* 2000;95:921-4.
69. Sarbia M, Donner A, Gabbert HE. Histopathology of the gastroesophageal junction: a study on 36 operation specimens. *Am J Surg Pathol* 2002;26:1207-12.
70. Der R, Tsao-Wei DD, Demeester T, et al. Carditis: a manifestation of gastroesophageal reflux disease. *Am J Surg Pathol* 2001;25:245-52.
71. Kim A, Park WY, Shin N, et al. Cardiac mucosa at the gastroesophageal junction: An Eastern perspective. *World J Gastroenterol* 2015;21:9126-33.
72. Csendes A, Maluenda F, Braghetto I, et al. Location of the lower oesophageal sphincter and the squamous columnar mucosal junction in 109 healthy controls and 778 patients with different degrees of endoscopic oesophagitis. *Gut* 1993;34:21-7.
73. Chandrasoma PT, Lokuhetty DM, Demeester TR, et al. Definition of histopathologic changes in gastroesophageal reflux disease. *Am J Surg Pathol* 2000;24:344-51.
74. Chandrasoma PT. Histologic definition of gastro-esophageal reflux disease. *Curr Opin Gastroenterol* 2013;29:460-7.

75. Olefson S, Moss SF. Obesity and related risk factors in gastric cardia adenocarcinoma. *Gastric Cancer* 2015;18:23-32.
76. Dubecz A, Solymosi N, Stadlhuber RJ, et al. Does the Incidence of Adenocarcinoma of the Esophagus and Gastric Cardia Continue to Rise in the Twenty-First Century?-a SEER Database Analysis. *J Gastrointest Surg* 2013.
77. Wang Y, Beydoun MA. The obesity epidemic in the United States--gender, age, socioeconomic, racial/ethnic, and geographic characteristics: a systematic review and meta-regression analysis. *Epidemiol Rev* 2007;29:6-28.
78. Brown L, Christie S, Gill V, et al. The Scottish Health Survey: Volume 1: Main Report, 2014:31880.
79. Nguyen DM, El-Serag HB. The epidemiology of obesity. *Gastroenterol Clin North Am* 2010;39:1-7.
80. Samanic C, Chow WH, Gridley G, et al. Relation of body mass index to cancer risk in 362,552 Swedish men. *Cancer Causes Control* 2006;17:901-9.
81. Turati F, Tramacere I, La Vecchia C, et al. A meta-analysis of body mass index and esophageal and gastric cardia adenocarcinoma. *Ann Oncol* 2013;24:609-17.
82. Ji BT, Chow WH, Yang G, et al. Body mass index and the risk of cancers of the gastric cardia and distal stomach in Shanghai, China. *Cancer Epidemiol Biomarkers Prev* 1997;6:481-5.
83. Chow WH, Blot WJ, Vaughan TL, et al. Body mass index and risk of adenocarcinomas of the esophagus and gastric cardia. *J Natl Cancer Inst* 1998;90:150-5.
84. Abnet CC, Freedman ND, Hollenbeck AR, et al. A prospective study of BMI and risk of oesophageal and gastric adenocarcinoma. *Eur J Cancer* 2008;44:465-71.
85. Corley DA, Kubo A, Zhao W. Abdominal obesity and the risk of esophageal and gastric cardia carcinomas. *Cancer Epidemiol Biomarkers Prev* 2008;17:352-8.
86. Lagergren J, Bergstrom R, Nyren O. Association between body mass and adenocarcinoma of the esophagus and gastric cardia. *Ann Intern Med* 1999;130:883-90.
87. Merry AH, Schouten LJ, Goldbohm RA, et al. Body mass index, height and risk of adenocarcinoma of the oesophagus and gastric cardia: a prospective cohort study. *Gut* 2007;56:1503-11.
88. Ryan AM, Rowley SP, Fitzgerald AP, et al. Adenocarcinoma of the oesophagus and gastric cardia: male preponderance in association with obesity. *Eur J Cancer* 2006;42:1151-8.
89. Wu AH, Wan P, Bernstein L. A multiethnic population-based study of smoking, alcohol and body size and risk of adenocarcinomas of the stomach and esophagus (United States). *Cancer Causes Control* 2001;12:721-32.
90. Lindblad M, Rodriguez LA, Lagergren J. Body mass, tobacco and alcohol and risk of esophageal, gastric cardia, and gastric non-cardia adenocarcinoma among men and women in a nested case-control study. *Cancer Causes Control* 2005;16:285-94.
91. Tran GD, Sun XD, Abnet CC, et al. Prospective study of risk factors for esophageal and gastric cancers in the Linxian general population trial cohort in China. *Int J Cancer* 2005;113:456-63.
92. Falk GW, Thota PN, Richter JE, et al. Barrett's esophagus in women: demographic features and progression to high-grade dysplasia and cancer. *Clin Gastroenterol Hepatol* 2005;3:1089-94.
93. Kubo A, Corley DA. Marked multi-ethnic variation of esophageal and gastric cardia carcinomas within the United States. *Am J Gastroenterol* 2004;99:582-8.

94. Steffen A, Huerta JM, Weiderpass E, et al. General and abdominal obesity and risk of esophageal and gastric adenocarcinoma in the European Prospective Investigation into Cancer and Nutrition. *Int J Cancer* 2015;137:646-57.
95. O'Doherty MG, Freedman ND, Hollenbeck AR, et al. A prospective cohort study of obesity and risk of oesophageal and gastric adenocarcinoma in the NIH-AARP Diet and Health Study. *Gut* 2012;61:1261-8.
96. Wu AH, Tseng CC, Bernstein L. Hiatal hernia, reflux symptoms, body size, and risk of esophageal and gastric adenocarcinoma. *Cancer* 2003;98:940-8.
97. Derakhshan MH, Malekzadeh R, Watabe H, et al. Combination of gastric atrophy, reflux symptoms and histological subtype indicates two distinct aetiologies of gastric cardia cancer. *Gut* 2008;57:298-305.
98. Engel LS, Chow WH, Vaughan TL, et al. Population attributable risks of esophageal and gastric cancers. *J Natl Cancer Inst* 2003;95:1404-13.
99. Garcia Rodriguez LA, Lagergren J, Lindblad M. Gastric acid suppression and risk of oesophageal and gastric adenocarcinoma: a nested case control study in the UK. *Gut* 2006;55:1538-44.
100. Poulsen AH, Christensen S, McLaughlin JK, et al. Proton pump inhibitors and risk of gastric cancer: a population-based cohort study. *Br J Cancer* 2009;100:1503-7.
101. Tseng CH, Tseng FH. Diabetes and gastric cancer: the potential links. *World J Gastroenterol* 2014;20:1701-11.
102. Jiang X, Bernstein L, Tseng CC, et al. Diabetes and risk of esophageal and gastric adenocarcinomas. *Int J Cancer* 2012;131:1417-22.
103. Neale RE, Doekke JD, Pandeya N, et al. Does type 2 diabetes influence the risk of oesophageal adenocarcinoma? *Br J Cancer* 2009;100:795-8.
104. Lin SW, Freedman ND, Hollenbeck AR, et al. Prospective study of self-reported diabetes and risk of upper gastrointestinal cancers. *Cancer Epidemiol Biomarkers Prev* 2011;20:954-61.
105. Bertuccio P, Rosato V, Andreano A, et al. Dietary patterns and gastric cancer risk: a systematic review and meta-analysis. *Ann Oncol* 2013;24:1450-8.
106. Kamangar F, Dawsey SM, Blaser MJ, et al. Opposing risks of gastric cardia and noncardia gastric adenocarcinomas associated with *Helicobacter pylori* seropositivity. *J Natl Cancer Inst* 2006;98:1445-52.
107. Islami F, Kamangar F. *Helicobacter pylori* and esophageal cancer risk: a meta-analysis. *Cancer Prev Res (Phila)* 2008;1:329-38.
108. Jeffery PL, McGuckin MA, Linden SK. Endocrine impact of *Helicobacter pylori*: focus on ghrelin and ghrelin o-acyltransferase. *World J Gastroenterol* 2011;17:1249-60.
109. Lane JA, Murray LJ, Harvey IM, et al. Randomised clinical trial: *Helicobacter pylori* eradication is associated with a significantly increased body mass index in a placebo-controlled study. *Aliment Pharmacol Ther* 2011;33:922-9.
110. Ioannou GN, Weiss NS, Kearney DJ. Is *Helicobacter pylori* seropositivity related to body mass index in the United States? *Aliment Pharmacol Ther* 2005;21:765-72.
111. Aleman JO, Eusebi LH, Ricciardiello L, et al. Mechanisms of obesity-induced gastrointestinal neoplasia. *Gastroenterology* 2014;146:357-73.
112. Alexandre L, Long E, Beales IL. Pathophysiological mechanisms linking obesity and esophageal adenocarcinoma. *World J Gastrointest Pathophysiol* 2014;5:534-49.

113. Duggan C, Onstad L, Hardikar S, et al. Association between markers of obesity and progression from Barrett's esophagus to esophageal adenocarcinoma. *Clin Gastroenterol Hepatol* 2013;11:934-43.
114. Donohoe CL, Doyle SL, McGarrigle S, et al. Role of the insulin-like growth factor 1 axis and visceral adiposity in oesophageal adenocarcinoma. *Br J Surg* 2012;99:387-96.
115. Siahpush SH, Vaughan TL, Lampe JN, et al. Longitudinal study of insulin-like growth factor, insulin-like growth factor binding protein-3, and their polymorphisms: risk of neoplastic progression in Barrett's esophagus. *Cancer Epidemiol Biomarkers Prev* 2007;16:2387-95.
116. Ishikawa M, Kitayama J, Kazama S, et al. Plasma adiponectin and gastric cancer. *Clin Cancer Res* 2005;11:466-72.
117. Kant P, Fazakerley R, Hull MA. Faecal calprotectin levels before and after weight loss in obese and overweight subjects. *Int J Obes (Lond)* 2013;37:317-9.
118. de Vries DR, van Herwaarden MA, Smout AJ, et al. Gastroesophageal pressure gradients in gastroesophageal reflux disease: relations with hiatal hernia, body mass index, and esophageal acid exposure. *Am J Gastroenterol* 2008;103:1349-54.
119. Pandolfino JE, El-Serag HB, Zhang Q, et al. Obesity: a challenge to esophagogastric junction integrity. *Gastroenterology* 2006;130:639-49.
120. Derakhshan MH, Robertson EV, Fletcher J, et al. Mechanism of association between BMI and dysfunction of the gastro-oesophageal barrier in patients with normal endoscopy. *Gut* 2012;61:337-43.
121. Lee YY, McColl KE. Disruption of the gastroesophageal junction by central obesity and waist belt: role of raised intra-abdominal pressure. *Dis Esophagus* 2015;28:318-25.
122. Dodds WJ, Hogan WJ, Miller WN, et al. Effect of increased intraabdominal pressure on lower esophageal sphincter pressure. *Am J Dig Dis* 1975;20:298-308.
123. Mittal RK, Fisher M, McCallum RW, et al. Human lower esophageal sphincter pressure response to increased intra-abdominal pressure. *Am J Physiol* 1990;258:G624-30.
124. Menon S, Trudgill N. Risk factors in the aetiology of hiatus hernia: a meta-analysis. *Eur J Gastroenterol Hepatol* 2011;23:133-8.
125. Lee YY, Wirz AA, Whiting JG, et al. Waist belt and central obesity cause partial hiatus hernia and short-segment acid reflux in asymptomatic volunteers. *Gut* 2014;63:1053-60.
126. Wu JC, Mui LM, Cheung CM, et al. Obesity is associated with increased transient lower esophageal sphincter relaxation. *Gastroenterology* 2007;132:883-9.
127. Fraser A, Delaney BC, Ford AC, et al. The Short-Form Leeds Dyspepsia Questionnaire validation study. *Aliment Pharmacol Ther* 2007;25:477-86.
128. Moayyedi P, Duffett S, Braunholtz D, et al. The Leeds Dyspepsia Questionnaire: a valid tool for measuring the presence and severity of dyspepsia. *Aliment Pharmacol Ther* 1998;12:1257-62.
129. Moons LM, Bax DA, Kuipers EJ, et al. The homeodomain protein CDX2 is an early marker of Barrett's oesophagus. *J Clin Pathol* 2004;57:1063-8.
130. Weimann A, Rieger A, Zimmermann M, et al. Comparison of six immunohistochemical markers for the histologic diagnosis of neoplasia in Barrett's esophagus. *Virchows Arch* 2010;457:537-45.
131. Glickman JN, Chen YY, Wang HH, et al. Phenotypic characteristics of a distinctive multilayered epithelium suggests that it is a precursor in the development of Barrett's esophagus. *Am J Surg Pathol* 2001;25:569-78.

132. Weimann A, Zimmermann M, Gross M, et al. CDX2 and LI-cadherin expression in esophageal mucosa: use of both markers can facilitate the histologic diagnosis of Barrett's esophagus and carcinoma. *Int J Surg Pathol* 2010;18:330-7.
133. Warson C, Van De Bovenkamp JH, Korteland-Van Male AM, et al. Barrett's esophagus is characterized by expression of gastric-type mucins (MUC5AC, MUC6) and TFF peptides (TFF1 and TFF2), but the risk of carcinoma development may be indicated by the intestinal-type mucin, MUC2. *Hum Pathol* 2002;33:660-8.
134. Going JJ, Keith WN, Neilson L, et al. Aberrant expression of minichromosome maintenance proteins 2 and 5, and Ki-67 in dysplastic squamous oesophageal epithelium and Barrett's mucosa. *Gut* 2002;50:373-7.
135. Robertson EV, Lee YY, Derakhshan MH, et al. High-resolution esophageal manometry: addressing thermal drift of the manoscan system. *Neurogastroenterol Motil* 2012;24:61-4, e11.
136. Hansen S, Vollset SE, Derakhshan MH, et al. Two distinct aetiologies of cardia cancer; evidence from premorbid serological markers of gastric atrophy and *Helicobacter pylori* status. *Gut* 2007;56:918-25.
137. Sotoudeh M, Derakhshan MH, Abedi-Ardakani B, et al. Critical role of *Helicobacter pylori* in the pattern of gastritis and carditis in residents of an area with high prevalence of gastric cardia cancer. *Dig Dis Sci* 2008;53:27-33.
138. Voutilainen M, Farkkila M, Mecklin JP, et al. Chronic inflammation at the gastroesophageal junction (carditis) appears to be a specific finding related to *Helicobacter pylori* infection and gastroesophageal reflux disease. The Central Finland Endoscopy Study Group. *Am J Gastroenterol* 1999;94:3175-80.
139. Gerson LB, Shetler K, Triadafilopoulos G. Prevalence of Barrett's esophagus in asymptomatic individuals. *Gastroenterology* 2002;123:461-7.
140. El-Serag HB, Kvapil P, Hacken-Bitar J, et al. Abdominal obesity and the risk of Barrett's esophagus. *Am J Gastroenterol* 2005;100:2151-6.
141. Lean ME, Han TS, Deurenberg P. Predicting body composition by densitometry from simple anthropometric measurements. *Am J Clin Nutr* 1996;63:4-14.
142. Fitzgerald RC, di Pietro M, Ragnath K, et al. British Society of Gastroenterology guidelines on the diagnosis and management of Barrett's oesophagus. *Gut* 2014;63:7-42.
143. Vallbohmer D, DeMeester SR, Peters JH, et al. Cdx-2 expression in squamous and metaplastic columnar epithelia of the esophagus. *Dis Esophagus* 2006;19:260-6.
144. Wang KK, Sampliner RE, Practice Parameters Committee of the American College of G. Updated guidelines 2008 for the diagnosis, surveillance and therapy of Barrett's esophagus. *Am J Gastroenterol* 2008;103:788-97.
145. Takubo K, Aida J, Naomoto Y, et al. Cardiac rather than intestinal-type background in endoscopic resection specimens of minute Barrett adenocarcinoma. *Hum Pathol* 2009;40:65-74.
146. Kelty CJ, Gough MD, Van Wyk Q, et al. Barrett's oesophagus: intestinal metaplasia is not essential for cancer risk. *Scand J Gastroenterol* 2007;42:1271-4.
147. Harrison R, Perry I, Haddadin W, et al. Detection of intestinal metaplasia in Barrett's esophagus: an observational comparator study suggests the need for a minimum of eight biopsies. *Am J Gastroenterol* 2007;102:1154-61.
148. Dias Pereira A, Ramalho PM, Chaves P. Characteristics of cardiac epithelium at the esophagogastric junction of a pediatric population with gastroesophageal reflux. *Dis Esophagus* 2014;27:709-14.

149. Chaves P, Cruz C, Dias Pereira A, et al. Gastric and intestinal differentiation in Barrett's metaplasia and associated adenocarcinoma. *Dis Esophagus* 2005;18:383-7.
150. Lord RV, Wickramasinghe K, Johansson JJ, et al. Cardiac mucosa in the remnant esophagus after esophagectomy is an acquired epithelium with Barrett's-like features. *Surgery* 2004;136:633-40.
151. Theisen J, Oberg S, Peters JH, et al. Gastro-esophageal reflux disease confined to the sphincter. *Dis Esophagus* 2001;14:235-8.
152. Seenan JP, Wirz AA, Robertson EV, et al. Effect of nitrite delivered in saliva on postprandial gastro-esophageal function. *Scand J Gastroenterol* 2012;47:387-96.
153. Robertson EV, Derakhshan MH, Wirz AA, et al. Central obesity in asymptomatic volunteers is associated with increased intrasphincteric acid reflux and lengthening of the cardiac mucosa. *Gastroenterology* 2013;145:730-9.
154. Derakhshan MH, Robertson EV, Yeh Lee Y, et al. In healthy volunteers, immunohistochemistry supports squamous to columnar metaplasia as mechanism of expansion of cardia, aggravated by central obesity. *Gut* 2015;64:1705-14.
155. Kunkel ME, Herkommer A, Reinehr M, et al. Morphometric analysis of the relationships between intervertebral disc and vertebral body heights: an anatomical and radiographic study of the human thoracic spine. *J Anat* 2011;219:375-87.
156. Weijenborg PW, van Hoeij FB, Smout AJ, et al. Accuracy of hiatal hernia detection with esophageal high-resolution manometry. *Neurogastroenterol Motil* 2015;27:293-9.
157. Scheffer RC, Bredenoord AJ, Hebbard GS, et al. Effect of proximal gastric volume on hiatal hernia. *Neurogastroenterol Motil* 2010;22:552-6, e120.
158. Miller L, Dai Q, Vegesna A, et al. A missing sphincteric component of the gastro-oesophageal junction in patients with GORD. *Neurogastroenterol Motil* 2009;21:813-e52.
159. Cohen S, Harris LD. Does hiatus hernia affect competence of the gastroesophageal sphincter? *N Engl J Med* 1971;284:1053-6.
160. De Hertogh G, Van Eyken P, Ectors N, et al. On the existence and location of cardiac mucosa: an autopsy study in embryos, fetuses, and infants. *Gut* 2003;52:791-6.
161. Kulinna-Cosentini C, Schima W, Lenglinger J, et al. Is there a role for dynamic swallowing MRI in the assessment of gastroesophageal reflux disease and oesophageal motility disorders? *Eur Radiol* 2012;22:364-70.

Appendix 1: Protocol for Endoscopy Study Day

The volunteer attends fasted from the previous evening.

Ensure the following specific equipment is available:

1. Radial jaw 4 forceps without spike
2. Re-usable clip fixing device and a supply of clips.

Perform the following steps:

1. Position the volunteer in the left lateral position as for a standard endoscopy.
2. Check the function of the endoscope.
3. Ensure that the clip fixer fits through the working channel of the endoscope and can be passed out the distal end.
4. Load the first clip into the clip fixing device
5. Ensure that expertise is available for immediate handling and orientation of the biopsies and for intra-procedure feedback of biopsy adequacy.

The procedure:

The volunteer should be offered a choice of sedation or throat spray as for a standard diagnostic endoscopy. The following guidance assumes competency in endoscopic techniques

1. Intubate the upper oesophagus under direct vision and perform an examination of the oesophagus and stomach.
2. Take a biopsy from the antrum.

3. Visualise the cardia in retroflexion.
4. Grade the appearance according to Hill's criteria for the gastro-oesophageal flap valve.
5. Photograph the cardia in retroflexion.
6. Take a biopsy from the gastric body.
7. Withdraw the endoscope to the level of the gastro-oesophageal junction.
8. Record the distance from the incisors of the:
 - a. Diaphragm
 - b. Top of gastric folds
 - c. Squamo-columnar junction
9. Take three biopsies of the gastro-oesophageal junction:
 - a. Orientation should be in a cranio-caudal direction across the Z-line.
 - b. Each biopsy should include enough squamous mucosa to confirm positioning at the squamo-columnar junction but should be predominantly cardia.
10. Junctional biopsies are immediately examined using a magnifier and light source to confirm that an adequate biopsy has been obtained. If there is doubt as to the adequacy of the biopsies consider a further attempt provided the procedure is well tolerated by the volunteer.
11. Clipping of the gastro-oesophageal junction:
 - a. Insert the clip fixing device through the working channel of the endoscope.

- b. Watching the endoscopic view, push the device through until the metal is visible.
- c. Ask your assistant to put the 'clip out' slowly and watch the endoscopic view. The clip should be protruded until the white plastic wings can be seen on the screen. Protruding the clip further will cause it to fall off.
- d. At this stage ask the assistant to 'open slowly'. This action will bring the plastic wings back until they are flush with the metal covering and start to open the clip.
- e. Position the clip at the gastro-oesophageal junction and deploy the clip at the Z line under direct vision.
- f. Ask your assistant to load a second clip and repeat the clipping procedure (11-15) to deploy a second clip at the squamo-columnar junction.

12. Confirm positioning of the clips and remove the endoscope.

After the procedure:

1. Thank the volunteer and confirm the arrangements for the final study visit.
2. Ensure the process for handling and orientating the biopsies is followed.
3. Enter a report using endoscope and file a copy of this in the volunteers study file as well as mailing a copy to the GP.

Appendix 2: Protocol for Recording Manometry and pH Data

Manometry Set Up

1. Switch on DELL computer and Manoscan.
2. Attach selected HRM probe to manoscan: red connector to red port with dots apposed; blue connector to blue port with dots apposed.
3. Insert catheter into pressure chamber to 42cm depth. Tighten washer.
4. Open *Manoscan Acquisition* from Desktop
5. Select probe screen will display automatically. Using mouse click on desired probe to highlight and press select button. Probe number is found on....
 - a. EAN0426
 - b. EAN0001
6. Main display screen will appear in contour display mode. At this stage the screen should appear blue.
7. Press *start* button on menu to right of screen display. This will display a *Patient Information Screen*
8. Enter the required data indicated by blue highlight or *
9. Click *OK*

Calibrating the Manometry Probe

1. Following the instructions in the box to the top right of the screen press *Next*
2. Calibration display screen will appear. Press *start* to begin pressure calibration. Pressure indicator will climb to 300 mmHg and fall to 0mmHg.
3. Click *OK*
4. Remove the catheter from the pressure chamber and apply manosheath:
 - a. Slide manosheath over catheter
 - a. Fold at end at dot
 - b. Use slider to expel excess air.
 - c. Secure sheath in place by wrapping elastic tie three times around catheter and attaching onto peg.

. pH Set-Up

- 1) Switch on Viglen computer and open Polygram NET on the desktop
- 2) Attach 12 sensor antimony pH probe to polygraph box. 1-6 are the proximal sensors and attach to the connector labelled P. 7-12 are the distal sensors and attach to the connector labelled D.
- 3) Ensure polygraph box is switched on.
- 4) On polygram>*Home tab*>12 pH sensors. This will open *studies tab* with 12 sensor pH protocol.
- 5) Follow menu on left screen
- 6) Study details:

- a. Enter study ID and additional information as required
 - b. Enter patient details by either selecting existing patient from right menu or create new patient by selecting patient button (red figure, bottom left of screen)
- 7) To verify connections: Equipment>12channel pH>Connections. Ensure all sensors have green status box

Calibrating the pH Probe:

- 1) Under equipment>12channel pH>Calibration
- 2) Go to calibrate group. Select button 2 from bottom left menu.
- 3) Immerse all sensors and reference electrode in pH buffer 7.01 (clear) and select ✓
- 4) Polygram will enter timer based calibration for high level signal. All sensor channels should read pH 7
- 5) When prompted remove pH probe from buffer 7. Immerse all sensors and reference electrode in pH buffer 1.07 (pink) and select ✓
- 6) Polygram will enter timer based calibration for low level signal. All sensor channels should read pH 1.
- 7) A message box will appear with the message *calibration successful*. Click *OK*
- 8) If system fails to calibrate check sensor channels for rogue reading to identify culprit sensor.

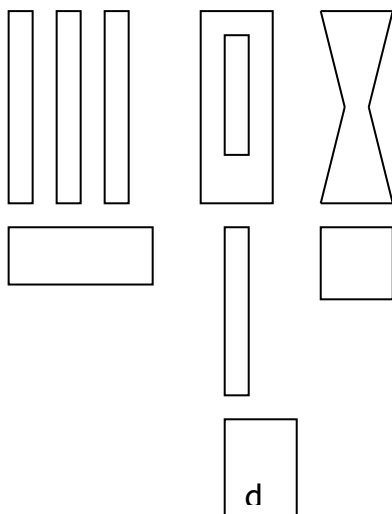
Data Capture:

- 1) Select Capture from left menu>LES


- 2) Capture screen appears with 12 sensors display. Criss-crossed background indicates not in recording mode.

Combining pH and Manometry Apparatus

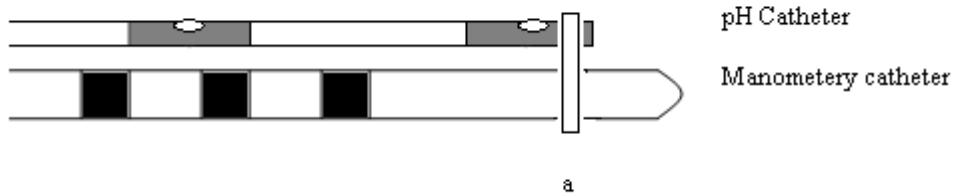
1. Identify sensor 29 on the manometry catheter. (The most distal sensor is 36)
2. Identify sensor 7 on the pH catheter. (The most distal sensor is 12)
3. Align the probes such that sensor 29 and sensor 7 are in alignment.
4. Cut sheath into the following shapes using sharp scissors:



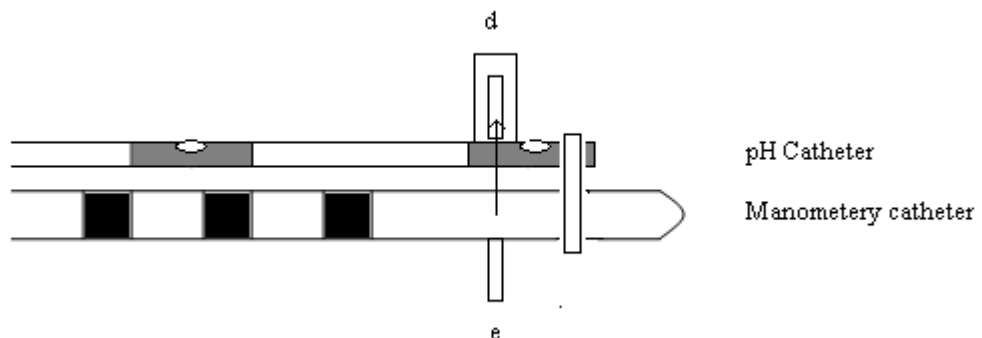
5. Use shape *f* to reinforce the end of the manometry catheter (only required where sheath used). Attach to end and double back as shown:



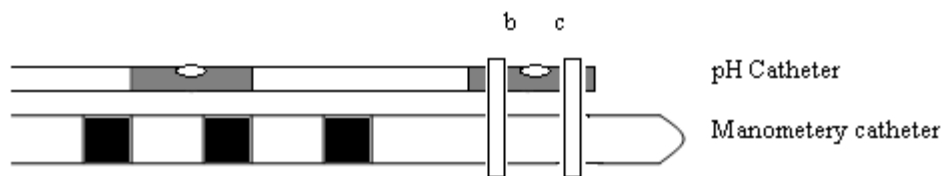
- Attach the catheters together using shape a ensuring that sensor 29 on the manometry aligns with sensor 7 on the pH. Ensure that the sensing element of the pH sensor is uncovered and facing outward from the manometry catheter. Wind sleek round catheters to attach.



- Attach shape d to pH catheter and shape e to manometry catheter. Shape e slips through the central hole in d and attaches to pH catheter. Shape d now attaches to manometry catheter.



- Wind shapes b and c over attachments created as above as reinforcement.



9. Finally use sleek to attach catheters together more proximally on the part of the apparatus that will remain external. e.g.60cm.
10. When ready to intubate hold apparatus aloft ensuring no external pressure influences on manometry probe and select ALT/Z to zero channels.

Thermal Calibration Procedure

1. The water bath designed for in vivo calibration of the manoview apparatus must be used. Fill the water bath to 2 centimetres depth with water at 37degrees centigrade
2. Commence recording on pH and manometry systems simultaneously:
 - a. On the manoview acquisition display use the mouse to select the Start recording button on the bottom left corner of the display. Recording will be indicated by the appearance of a red line at top of recording and the appearance of stopwatch on top left of screen.
 - b. On the polygram software use the mouse to depress the green record button on the bottom left of the screen. Recording screen will appear. Plain background and timer indicate recording
3. Place the combined apparatus in the water bath ensuring that all the manometry sensors are covered.
4. Use the timer on the manoview acquisition software to time three minutes.

5. After three minutes remove the combined apparatus from the water bath and mark the recording using the *wet swallow* button on the menu to the right of the display.

The apparatus is ready for intubation.

Appendix 3: Protocol for Recording pH and Manometry

Prior to the Arrival of the Volunteer:

1. Set up the pH and manometry systems as described in the protocol *Initial Set Up pH and Manometry*. The thermal calibration procedure can be carried out once the volunteer has arrived and is ready for intubation.
2. Obtain Phillips BV Pulsera from radiology and ensure availability of radiographer.

The volunteer will attend fasted from the previous evening. Ask the volunteer to empty the bladder and to change into scrubs. Women should remove their bra.

Placement of the Combined apparatus:

1. Begin with the volunteer fasted and in the upright position.
2. Start recording on both systems simultaneously.
3. Perform the thermal calibration procedure described in the *Initial set up pH and Manometry Protocol*.
4. Use lignocaine spray to selected nostril as a local anaesthetic.
5. Attach the pH reference electrode to the left upper arm using contact gel.
6. Pass the combined pH/manometry apparatus through the nose and carefully advance it until both upper and lower oesophageal sphincters are visible on the manometry display.
7. Record the Insertion Distance on the proforma for study day 4.

Recording Protocol:

1. Allow a period of accommodation of at least 10 minutes. After this period talking should be minimised to reduce artefact on the MVS trace.
2. Carry out recordings in the following sequence:

Fasted	Erect	15 mins
	Supine	15 mins

Meal		20mins
-------------	--	--------

Post-Prandial	Erect	45 mins
	Supine	30mins

Fasting Erect:

1. During the first 15 minutes of recording identify radiographer and clarify time of first screening episode.
2. Estimate timing of meal and arrange pick up of fish and chips from chip shop.
3. The first screening episode is undertaken at the end of the fasting upright period.
4. For each screening episode:
 - a. Ensure availability of lead aprons for all present.

- b. Enter volunteer details on the Phillips workstation if not already done by radiographer.
- c. Position C-arm to screen in the area of the GO junction.
- d. Radiographer will perform a check screen. During this episode check the following:
 - i. The clip should be visible.
 - ii. The ends of both catheters are seen
 - iii. The exposure is adequate and the lumbar spine and diaphragm are in view.
- e. When ready to screen, ask the volunteer to swallow then to breathe normally and avoid swallowing for the duration of the recording.
- f. Move event marker into field to be screened.
- g. Ask assistant to be ready to activate fluoroscopy event marker on polygram software.
- h. Perform the following sequence of events:
 - i. Ask the radiographer to “Start screening”
 - ii. Count 3,2,1 mark. On “mark” remove the event marker from the field of screening and simultaneously use the fluoroscopy event marker on the polygram to mark the pH tracing.
 - iii. Record the time on the proforma.
 - iv. Continue screening for around 30seconds in total
 - v. Ask the radiographer to “Stop screening”

Fasting Supine:

1. Reposition volunteer to lie flat on back and continue recording
2. Note time on proforma
3. Re-orientate C-arm to screen across GO junction in preparation for next screening episode.
4. Repeat sequence of events as outlined in *for each screening episode* above
5. Record time on proforma.
6. Continue recording for 15 minutes

Meal:

1. Weigh meal and record weight on proforma
2. Offer volunteer standardised meal consisting of fish and chips.
3. Record time on proforma.
4. Do not interrupt pH and manometry recordings as this will entail repeating the entire set up.
5. Ask volunteer to eat until full over a twenty minute period.
6. Weigh leftovers and record on proforma.

Post-Prandial Upright:

1. Record time on proforma
2. Continue pH and manometry recordings for 45 minutes in the upright position.

3. During this time ensure availability of radiographer for screening.
4. The third screening episode is carried out at the end of this period.
5. Perform screening as outlined above and record time on proforma.

Post-Prandial Supine:

1. Reposition volunteer and record time on proforma.
2. Perform final screening episode and record time on proforma.
3. Continue recording for 30 minutes.

Completing Study and Saving Data:

1. On completion of the study gently remove the combined apparatus from the volunteer.
2. Hold sensors free from external pressure influence for sixty seconds to allow thermal drift calculation.
3. Stop both recordings simultaneously
 - a. On the manoview programme use the mouse to press the *Stop Recording* Button on the bottom left of the screen. The end of the red line at the top of the screen confirms end of recording.
 - b. On the polygram programme use the mouse to press the *Stop Recording* Button on the bottom left of the screen. The appearance of the hatched pattern confirms the end of the recording.

Saving the Studies: Manoview

1. Go To File>Close/Save Current.
2. A message box will appear. Confirm Close/Save Current Study

3. Save. File will automatically save into directory: program Files>SSI>ManoScan Acquisition>Patients>CSO Fat Study

Saving the Studies: pH

1. Go to study details on left menu.
2. Tick study completed box.
3. Go back to *studies tab* and identify the newly created study from list displayed.
4. Right click the required study using the mouse.
5. On the displayed menu>ASCII export.
6. A pop up screen appears with *Save As*. Save with .asc file extension in desired directory. For this study files are saved in My documents>Elaine>ASCII files pH.
7. Close polygram.

Completing the Study

1. Carefully separate the pH and manometry apparatus using scissors of required.
2. Clean the pH catheter and send for decontamination.
3. Test the integrity of the manosheath using the equipment provided.
4. If the manosheath has a leak (usually suspected by artefact during recording) the probe will have to be decontaminated using the TRISTEL system.

Appendix 4: Protocol for Exporting pH and Manometry Data

Exporting the Manometry Data:

1. Open *ManoScan Acquisition* on desktop
2. Go to file on main menu>review patient file.
3. Select desired study (.mvs file extension)
4. Click *open*
5. Main display screen will appear with compressed patient data
6. Compress data to 150000 using the scale on the bottom left of the screen.
7. Activate smart mouse using the button on the top right of the screen. This should change to *smart mouse on*.
8. Use the right mouse button with the smart mouse function on to highlight all the compressed data
9. Select file>save selected then *save as* screen appears. Save as text file with .txt file extension. File will automatically save into directory: program Files>SSI>ManoScan Acquisition>Patients
10. To retrieve the saved text file go to Start menu>My computer>C drive>Program files>SSI>Manoscan Acquisition>Patients folder. There is a shortcut on the desktop entitled patients.

Exporting the pH Data

- 1) The pH data is backed up in ASCII file format in the directory >My documents>Elaine>ASCII files pH

- 2) Go to this directory and select created file.
- 3) Right click file and on displayed menu >Open with>Notepad.
- 4) From notepad screen go to file >save as>. Save with .txt file extension in required directory (For this study Desktop>Shortcut to ManpH data>CSO Fat Study pH text files

Appendix 5: Study Questionnaire

Volunteer Identifier: _____

Date: _____

Heartburn is a burning feeling behind the breastbone. How often have you had this feeling within the last 2 months?

- Not at all
- Less than once a month
- Between once a month and once a week
- Between once a week and once a day
- Once a day or more

Indigestion is a pain or discomfort in the upper abdomen. How often have you has this symptom over the last 2 months

- Not at all
- Less than once a month
- Between once a month and once a week
- Between once a week and once a day
- Once a day or more

Regurgitation is an acid taste coming up into your mouth from your stomach. How often have you had this symptom over the last 2 months?

- Not at all
- Less than once a month
- Between once a month and once a week
- Between once a week and once a day
- Once a day or more

Nausea is a feeling of sickness without actually being sick. How often have you had this symptom within the last 2 months?

- Not at all
- Less than once a month
- Between once a month and once a week
- Between once a week and once a day

Once a day or more

Which, if any, of these symptoms has been the most troublesome to you in the last 2 months?

Heartburn

Dyspepsia

Regurgitation

Nausea

None of the above

DIETARY INTAKE

Please record your oral intake in the past 24 hour period, starting from waking up yesterday. Include all meals and snacks as well as times of eating

Time	Food Taken	Portion size*
	<i>Rice krispies with semi-skimmed milk, White bread toasted with butter and jam Banana Orange juice</i>	<i>1 medium bowl Two slices 1 whole 1 cup</i>
Before Breakfast		
Breakfast		
Mid- morning		
Lunch		
Mid- afternoon		
Evening meal		
Later evening		
Other snacks		

**See guide for portion sizes.*

Weight History

Please enter the following details regarding your weight:

What is your current weight? _____

What was your weight one year ago? _____

What was your weight five years ago? _____

What was your weight aged twenty? _____

MEDICAL HISTORY

Do you have any medical conditions for which you regularly attend your GP or a hospital clinic? If so please give details:

Have you previously attended your GP or hospital clinic for any medical conditions? If so please give details:

Have you ever been admitted to hospital? If so please give details

DRUG HISTORY

Do you take any regular prescribed medications? If so please give details

Have you taken any over the counter medications in the past month? If so please give details

Do you take any herbal medications or alternative therapies? If so please give details

Have you used any remedies for heartburn or indigestion in the past six months?

No

Yes

-Less than once a month

-Between once a month and once a week

-Between once a week and once a day

-Once a day or more

If so please give the name of the medications you have taken.

Have you ever been treated for helicobacter pylori?

Yes

No

Smoking/Alcohol History

Do you currently smoke?

Yes

No

What age were you when you started smoking? _____

How many cigarettes do you smoke each day? _____

Do you drink alcohol?

Yes

No

How many units of alcohol do you drink in a week? (A unit is a small glass of wine, half a pint of beer or a pub measure of spirits)
