



University
of Glasgow

Kelly, Padraig G. (2016) *Studies on serial resting and dynamic endoscopic examination of thoroughbred yearlings*. MVM(R) thesis.

<http://theses.gla.ac.uk/7148/>

Copyright and moral rights for this thesis are retained by the author

A copy can be downloaded for personal non-commercial research or study

This thesis cannot be reproduced or quoted extensively from without first obtaining permission in writing from the Author

The content must not be changed in any way or sold commercially in any format or medium without the formal permission of the Author

When referring to this work, full bibliographic details including the author, title, awarding institution and date of the thesis must be given



Studies on serial resting and dynamic endoscopic examinations of Thoroughbred yearlings

Submitted in accordance with the requirements of the University of Glasgow for
the degree of Master of Veterinary Medicine

By

Padraig G Kelly

May 2015

Abstract

Resting endoscopic examination of Thoroughbred (TB) yearlings is a frequently performed procedure, the interpretation of which can have a profound effect on the financial value of the horse. In some instances this procedure is performed by multiple people and on multiple occasions and this has potential welfare implications for the animal. It is also accepted that poor correlation exists between the results of resting and dynamic endoscopic examinations in older horses however no comparison has been performed in the TB Yearling. The objective of this study was to investigate the application of dynamic endoscopic examination in this age group and in doing so to correlate the results of resting and dynamic examinations.

The study was divided into two parts. In Part I, resting and dynamic endoscopic examination of a cohort of juvenile horses was performed and the results of each examination were compared. In Part II, further longitudinal resting and dynamic endoscopic examinations were performed and the results were correlated with those identified in Part I.

Dynamic examination was very well tolerated and minimal complications were observed. Disease not previously reported in TB yearlings was identified. Comparison of the results of resting and dynamic examination identified poor correlation between these two diagnostic techniques with a greater prevalence of disease identified during dynamic examination. Comparison of the results obtained at different time points indicate that there is considerable variability in the endoscopic appearance of the larynx and pharynx during both resting and dynamic examinations with a decrease in the prevalence of IDDSP as the horses mature and fitness increases.

It is concluded that dynamic endoscopic examination of TB yearlings is a safe and viable technique that provides a more accurate assessment of current airway function than resting endoscopic examination. This study provides valuable information on the progression of disease in young racehorses, however, based on these results our ability to accurately and reliably predict future airway function remains limited and significant further studies are required.

Table of contents

Studies on serial resting and dynamic endoscopic examinations of Thoroughbred yearlings	1
1 Introduction	12
1.1 Aims.....	13
1.2 Hypothesis	14
2 Literature review	15
2.1 Obstructive Disease of the Equine Pharynx and Larynx.....	15
2.1.1 Laryngeal Neuropathy	15
2.1.2 Intermittent dorsal displacement of the soft palate and palatal instability.....	21
2.1.3 Epiglottic abnormalities.....	26
2.1.4 Other disease.....	28
2.2 Endoscopic examination of the Thoroughbred racehorse	32
2.2.1 Resting examination	32
2.2.2 Dynamic examination	32
2.3 Interpretation of the results of endoscopic examination	34
2.3.1 Laryngeal Neuropathy	34
2.3.2 Intermittent dorsal displacement of the soft palate	35
2.4 Endoscopic examination of the Thoroughbred yearling: Specific considerations.....	36
2.4.1 Laryngeal Neuropathy	36
2.4.2 Intermittent dorsal displacement of the soft palate	37
2.4.3 Epiglottic structure and epiglottic abnormalities	37
2.4.4 Other disease assessed in Thoroughbred yearlings	38
3 Materials and Methods.....	40
3.1 Study design.....	40
3.1.1 Part I	40
3.1.2 Part II	40
3.2 Ethical approval.....	40
3.3 Horses.....	40
3.3.1 Part I	41
3.3.2 Part II	43
3.4 Endoscope.....	43
3.5 Electrocardiogram	44
3.6 Global positioning satellite receiver	44
3.7 Endoscopic examination.....	45
3.7.1 Part I (Exam I - yearling examination).....	45
3.7.2 Part II (Two year old examinations).....	46
3.8 Video analysis:	46
3.9 Statistical analysis	49
4 Comparison of dynamic and resting endoscopy of the upper portion of the respiratory tract in 57 Thoroughbred yearlings	51
4.1 Introduction	51
4.2 Results	51
4.2.1 Heart rates and GPS data	52
4.2.2 Upper respiratory tract diseases	55
4.2.3 Mucopurulent material	57
4.2.4 Abnormal respiratory noise.....	58
4.2.5 History of upper respiratory tract infection	58
4.2.6 Complications.....	58
4.3 Discussion	59

5	Comparison between the results of dynamic endoscopic examination performed in a group of Thoroughbred racehorses as yearlings and as two year olds	63
5.1	Introduction	63
5.2	Results	63
5.2.1	Heart rates, GPS data and distance galloped	64
5.2.2	Complications	65
5.2.3	Upper respiratory tract disease.....	65
5.2.4	Variation in the occurrence of disease between <u>35 horses</u> examined on all three occasions and association between conditions	69
5.2.5	Results of analysis when <u>all horses</u> from each Exam were included.....	75
5.2.6	Associations between findings	77
5.3	Discussion	78
6	General discussion	84

List of Tables

Table 1-1: Conditions of sale (Tattersalls UK)	12
Table 2-1: Havemeyer scale for subjective grading of laryngeal function (Havemeyer 2004)	18
Table 2-2: Grading scale of laryngeal function during exercise (Havemeyer 2004)	18
Table 4-1: Horses not examined and reason	52
Table 4-2: Heart rate	52
Table 4-3: Frequency of occurrence of disease at each examination (Part I) and results of statistical evaluation of associations between conditions	53
Table 5-1: Horses not examined during Part II, Exam II and reason	64
Table 5-2: Horses not examined during Part II, Exam III and reason	64
Table 5-3: Frequency of occurrence of respiratory tract disease during Exam II (42 horses)	66
Table 5-4: Frequency of occurrence of respiratory tract disease during Exam III (45 horses)	67
Table 5-5: Frequency of occurrence of respiratory tract disease during Exams I, II and III (35 horses)	68

List of Figures

Figure 3-1: Image of yearling ready for endoscopic examination.	42
Figure 3-2: Image of yearling following lunging exercise	42
Figure 3-3: Example of GPS data acquired during examination.....	44
Figure 3-4: Aerial photograph of the training facility	47
Figure 3-5: Epiglottic structure grade 0-4.....	48
Figure 3-6: Still image showing moderate axial deviation of the aryepiglottic folds	48
Figure 5-1: Graphic showing number of horses with each LF grade pre-exercise in each Exam	70
Figure 5-2: Graphic showing number of horses with “any” and “significant” IDDSP in each Exam.	71
Figure 5-3: Graphic showing number of horses with a each grade of ES at rest pre exercise in each Exam	72
Figure 5-4: Graphic showing number of horses with each grade of axial deviation of the aryepiglottic folds in each Exam	73
Figure 5-5: Graphic showing number of horses with each grade of VCC in each Exam.....	74

List of accompanying material

Kelly, P.G. et al., (2013) Comparison of dynamic and resting endoscopy of the upper portion of the respiratory tract in 57 Thoroughbred yearlings. *Equine Veterinary Journal*, 45 (6), pp. 700-4

Preface

The Project was conceived and designed by the author and project supervisor. The author completed all examinations and prepared the thesis and manuscripts with advice and mentorship from the project supervisor.

Part I of this study has been published (see accompanying material) and the results of this study have been presented at the national and international conferences listed below. The results of this study have facilitated the development of further studies involving ultrasonographic assessment of the larynx.

Presentations:

1. BEVA Overground endoscopy users Course, Newmarket 2013

 'Dynamic endoscopic examination of the Juvenile Thoroughbred'
2. Dick - Weipers meeting 2013

 'Repeat dynamic endoscopic examination of Juvenile TB racehorses'
3. Dick - Weipers meeting 2012

 'Dynamic endoscopy of the TB yearling'
4. ECVS, Barcelona 2012

 'Comparison of resting and dynamic endoscopic examination in 40 TB yearlings'
5. ACVS, Washington 2012 (Accepted for presentation but conference cancelled)

 'Comparison of resting and dynamic endoscopic examination in 57 TB yearlings'

Acknowledgement

The author would like to acknowledge the support of all the staff of the Weipers Centre for Equine Welfare, University of Glasgow. The people and this institution have given me the opportunity to further progress my career and complete this Project. Particular thanks must go to Prof Sandy Love for his guidance and facilitation of this project. I would especially like to thank the Nurses and Office staff that looked after the equipment and sourced anything I needed. The students who endured the long car journeys must also be thanked for their assistance and much-needed comic relief, I hope they got something in return.

Mark Johnston racing and especially Veterinary Surgeons John Martin MRCVS, Niall Mechie MRCVS and Fia Brink MRCVS who facilitated this project and provided all the clinical and historical data.

Special thanks go to Patrick Pollock and Richard Reardon. Both provided me with the skill set to complete the project and spent endless hours reviewing videos. As project supervisor Patrick gave me the fantastic opportunity to do this study and provided the knowledge, motivation, inspiration and support to complete it.

Finally I would like to thank my family and friends and for their support and friendship.

Author declaration

This thesis contains original work completed by the author between 2012 and 2013.

Definitions/abbreviations

1. ADAF Axial deviation of the aryepiglottic folds
2. CAD Cricoarytenoideus Dorsalis
3. CAL Cricoarytenoideus Lateralis
4. DRS Dynamic respiratory scope
5. ECG Electrocardiogram
6. ECVS European College of Veterinary Surgeons
7. ES Epiglottic structure
8. GPS Global positioning satellite
9. IAD Inflammatory airway disease
10. IDDSP Intermittent dorsal displacement of the soft palate
11. LF Laryngeal function
12. LN Laryngeal neuropathy
13. MPH Miles per hour
14. PI Palatal instability
15. PLH Pharyngeal lymphoid hyperplasia
16. TB Thoroughbred
17. URT Upper portion of the respiratory tract
18. VCC Vocal Cord Collapse

1 Introduction

Endoscopic examination of the Thoroughbred (TB) yearling is routinely performed to assess function of the upper portion of the respiratory tract (URT) and has become an important part of pre- and post-purchase examination at public auction (Pierce & Embertson 2001; Garrett et al. 2010). Examination is used to ensure the conditions of sale are satisfied (Table 1.1) and to aid in the assessment of suitability of a horse for training and as part of an evaluation of potential future racing performance. As such the interpretation of this examination can have a significant impact on the sale price of the horse but also on the horse's future use and potentially its welfare.

Table 1-1: Conditions of sale (Tattersalls UK)

<p>Any horse</p> <ul style="list-style-type: none"> (a) Which is a Whistler and/or a Roarer as hereinafter defined, or (b) Which has been tubed or otherwise operated upon for the correction of Whistling and/or Roaring, or (c) Which makes an abnormal inspiratory sound when actively exercised and which has <ul style="list-style-type: none"> i. rostral displacement of the palatopharyngeal arch (fourth branchial arch defect); or ii. chondroma or severe arytenoid chondritis; or iii. cleft palate <p>is returnable in accordance with this and Condition (11) unless so described or described as being "heard to make a noise" without qualification in which event the Lot is not returnable under sub-paragraphs (a), (b) or (c).</p> <p>In the case of a Lot to which this sub-condition applies, a Whistler and/or Roarer is a Lot which can be heard to make a characteristic abnormal inspiratory sound when actively exercised and which has Laryngeal Hemiplegia (Recurrent Laryngeal Neuropathy) when examined with the endoscope.</p>

The significance of pathology identified during static endoscopic examination and the effect of such pathologies on future racing performance have been investigated (Pierce & Embertson 2001; Stick et al. 2001; Garrett et al. 2010), however questions remain about the significance of certain conditions at rest, such as asynchronous movement of the left arytenoid, epiglottic structure (ES) and the occurrence of intermittent dorsal displacement of the soft palate (IDDSP).

It has been recognised that the use of a resting endoscopic examination has significant limitations when examining the URT of adult horses for disease which

is often dynamic (Lane et al. 2006a), and it has been extrapolated that similar limitations exist when assessing the URT of yearlings (Embertson 1998; Garrett et al. 2010). Variability in the endoscopic grading of laryngeal function (LF) has been described both in adult and juvenile horses and this further limits the ability to make an accurate predictive assessment of URT function at rest (Ducharme et al. 1991; Hackett et al. 1991; Anderson et al; 1997 Perkins et al. 2009). Furthermore, it has been suggested that the endoscopic appearance of laryngeal and pharyngeal function varies greatly between the immature and mature horse (Embertson 1998). As a result it is possible that examination of the URT of juvenile horses at rest is an inaccurate predictor of future racing performance.

Dynamic endoscopy of the URT in adult horses during ridden exercise is described (Desmaizieres et al. 2009; Pollock et al. 2009) and is now widely used. It may be possible to use this technique to examine the URT of TB yearling horses during exercise, to evaluate the association between findings at rest and exercise and also to further evaluate the association between the results of this examination in yearlings and the results of examination as horses mature and race.

1.1 Aims

1. To investigate the possibility of safely performing dynamic endoscopic examination of the TB yearling.
2. To compare the results of resting and dynamic endoscopic examination of the URT in a group of TB yearlings.
3. To assess the changes in URT function in a group of juvenile racehorses as these horses mature, enter training and race.
4. To establish the significance of disease identified during dynamic endoscopic examination of TB yearlings by comparing the results of serial examinations.

1.2 Hypothesis

Our hypothesis was that, when compared to resting endoscopic examination, dynamic examination of TB yearlings would be a more accurate predictor of future URT function.

2 Literature review

2.1 Obstructive Disease of the Equine Pharynx and Larynx

2.1.1 Laryngeal Neuropathy

Laryngeal neuropathy (LN) results in loss of abduction of the arytenoid cartilage, most commonly the left. Loss of abduction and greater negative pressure in the larynx results in progressive axial movement of the arytenoid during exercise leading to increasing obstruction of the upper portion of the airway.

Laryngeal neuropathy results from progressive loss of large myelinated axons in the recurrent laryngeal nerve. The pathology, while often present bilaterally is generally most severe on the left side resulting in predominance of left sided disease. Neurogenic atrophy of the intrinsic laryngeal musculature results in progressive loss of both abductor and adductor arytenoid function (Duncan et al. 1974). Atrophy of the adductor muscles i.e. the cricoarytenoid lateralis (CAL), vocalis, ventricularis and transverses arytenoideus is more severe than that noted in the arytenoid abductor, the cricoarytenoideus dorsalis (CAD)(Duncan et al. 1991). However, it is pathology of the CAD that results in clinically significant disease leading to dynamic collapse of the arytenoid cartilage during exercise, thereby significantly impairing performance. The degree of pathology in the muscle is positively correlated with the degree of pathology in the nerve and the degree of functional impairment (Cahill & Goulden 1987; Duncan et al. 1991).

2.1.1.1 Pathogenesis of Laryngeal Neuropathy

The pathogenesis of LN is yet to be fully elucidated, however the disease affects the distal ends of long nerve fibres and large axons providing an explanation for the greater severity of left sided disease (the left recurrent laryngeal nerve being of greater length than the right) and the higher prevalence of disease in large horses (Cahill & Goulden 1987). It is uncertain whether physical factors such as stretch or compression of the nerve are involved in the pathogenesis of disease and the underlying mechanisms may be related to abnormal energy metabolism or co-factor deficiency.

Laryngeal neuropathy is a mononeuropathy making it very different from any human or canine neuropathy (Hahn et al. 2008). Genetic factors have historically been considered to play a significant role in the pathogenesis of LN and it has been shown that affected stallions are more likely than unaffected counterparts to have affected progeny (Poncet & Montavon 1989). More recently a significant association of LN with the LCORL/NCAPG locus was demonstrated (Boyko et al. 2014). These loci are significantly linked to body size and this study reports both clinical and genetic correlations (>90%) between body size and LN. The exact mechanism and mode of inheritance are unclear and despite having a high heritability it is unlikely that predisposition is determined by a single or even a small number of genes (Dupuis et al. 2011).

Clinical evidence for progression of LN is described in 52 of 351 horses and this was supported by repeat endoscopic examination in 30 cases (Dixon et al. 2002). However improvement in endoscopic grading has also been noted in which cases it has been suggested that re-innervation of the CAD muscle may be responsible (Duncan et al. 1974; Anderson et al. 1997;).

2.1.1.2 Diagnosis of Laryngeal Neuropathy

Diagnosis of LN is currently based on clinical, endoscopic or ultrasonographic examination. Examination of the TB yearling relies on a composite test that varies depending on the sales company but may include the detection of abnormal respiratory sounds during exercise, laryngeal palpation and endoscopy (Lane et al. 1987).

2.1.1.2.1 Clinical examination

Clinical examination including observation of the horse during exercise and determination of the presence of any abnormal inspiratory noises remains the most common screening test for horses. Palpation of the larynx including the muscular process of the arytenoids is used to evaluate symmetry of the CAD muscles (Cook 1965), with asymmetry being only suggestive of neurogenic atrophy. Fremitus of the muscular process has been reported in horses with LN. The 'slap test' or 'laryngeal adductor test' was also advocated as a means of assessing LF. This test is performed by observing the larynx endoscopically to assess arytenoid movement when the contralateral thorax or saddle area is

slapped. As the adductor muscles and therefore the CAL muscle is affected first it was hypothesised that absence of the adductory flick would indicate a defect in the efferent portion of the reflex arc i.e. the recurrent laryngeal nerve and therefore LN (Ainsworth & Hackett 2004; Greet et al. 1980). However investigation would suggest that this is not an accurate means of assessing or predicting current or future laryngeal function (Newton-Clarke et al. 1994) and this test is now rarely applied clinically.

The presence of inspiratory noise specifically that which is characterised as 'whistling' or 'roaring' is often the first clinical sign noted in horses affected with LN. However the presence of any noise was shown to be poorly correlated with disease. The specificity of whistling or roaring noise was found to be high for diagnosis of vocal cord collapse (VCC) or laryngeal asymmetry at exercise, however the sensitivity is low (Witte et al. 2011).

2.1.1.2.2 Endoscopic examination

Endoscopic examination of the URT, both resting and exercising is frequently performed to examine arytenoid function. Resting endoscopic examination is performed with the horse in an enclosed environment and generally restrained by means of a nose twitch. Assessment of LF is achieved by observing the arytenoid cartilages for a period of time and assessing symmetry of left and right movements. This is frequently assessed either during nasal occlusion or after swallowing, at which time both maximal abduction and maintenance of abduction should be achieved. Various subjective grading systems for LF as assessed during endoscopy of the airway exist, however recently a consensus was achieved and it is now becoming standard practice to use the Havemeyer scale (Havemeyer 2004) (See Table 2.1). A separate dynamic scale is used for grading of LF during exercise (see table 2.2). Significant intra-horse and both intra- and inter- observer variability in the endoscopic grading of LF at rest exists, leading to difficulty in assessing true laryngeal function (Perkins et al. 2009; Hackett et al. 1991). This variability and inability to accurately predict LF during exercise has led to the development of exercising endoscopy. This topic is discussed in greater detail in section 2.3.1.

Table 2-1: Havemeyer scale for subjective grading of laryngeal function (Havemeyer 2004)

Grade	Description	Sub-grade
I	All arytenoid cartilage movements are synchronous and symmetrical and full arytenoid abduction can be achieved and maintained	
II	Arytenoid cartilage movements are asynchronous and/or larynx asymmetry is seen at times but full arytenoid abduction can be achieved and maintained	<ol style="list-style-type: none"> 1. Transient asynchrony, flutter or delayed movements are seen 2. There is asymmetry of the rima glottidis much of the time due to reduced mobility of the affected arytenoid and vocal fold but there are occasions, typically after swallowing or nasal occlusion when full symmetrical abduction is achieved and maintained
III	Arytenoid cartilage movements are asynchronous and or/asymmetric. Full arytenoid cartilage abduction cannot be achieved and maintained	<ol style="list-style-type: none"> 1. There is asymmetry of the rima glottidis much of the time due to reduced mobility of the arytenoid cartilage and vocal fold but there are occasions, typically after swallowing or nasal occlusion when full symmetrical abduction is achieved but not maintained 2. Obvious arytenoid abductor deficit and asymmetry. Full abduction is never achieved 3. Marked but not total abductor deficit and asymmetry with little arytenoid movement. Full abduction is never achieved
IV	Complete immobility of the arytenoid cartilage and vocal fold	

Table 2-2: Grading scale of laryngeal function during exercise (Havemeyer 2004)

Laryngeal grade	Description
A.	Full abduction of the arytenoid cartilages during inspiration
B.	Partial abduction of the left arytenoid cartilages (between full abduction and resting position)
C.	Abduction less than resting position including collapse into the contralateral half of the rima glottidis during inspiration

2.1.1.2.3 Ultrasonographic examination

Ultrasonographic examination of the larynx has been described (Chalmers et al. 2006) and in contrast to endoscopy, allows investigation of the non-luminal structures of the larynx and pharynx.

The association between dynamic examination and ultrasonography has been investigated. Muscular hyperechogenicity is a characteristic of neurogenic atrophy and therefore hyperechogenicity of the CAL muscle was investigated as a means of assessing arytenoid function. Ultrasonographic examination of the CAL had a sensitivity of 90%, specificity of 98% and accuracy of 96% for predicting abnormal arytenoid function during highspeed treadmill exercise endoscopy (Garrett et al. 2011). Resting URT endoscopy had sensitivity of 80%, specificity of 81% and accuracy of 81% for predicting abnormal arytenoid function during exercise (Garrett et al. 2011). This would suggest that ultrasonographic examination is the more accurate test for arytenoid function and the presence of LN. In the same study when horses were categorised according to their resting endoscopy results alone, 33% of horses with grade II.2-III.2 would have been miscategorised (when resting grade \leq II.2 is assumed to be normal at exercise and III.1-III.2 is assumed to be abnormal). In comparison ultrasonographic examination would have only miscategorised 7% of horses (Garrett et al. 2011).

Despite recent advance in endoscopic and ultrasonographic examination of the larynx, accurate diagnosis of LN and prediction of future arytenoid function remains challenging.

2.1.1.3 Prevalence of Laryngeal neuropathy in the general population

The prevalence of laryngeal asymmetry or asynchrony in multiple populations has been investigated endoscopically with higher prevalence noted in TBs and draught horses when compared to other breeds (Fulton et al. 2012). Hillidge (1985) described the prevalence of laryngeal asynchrony in one stud farm where 94 horses (55.6%) had evidence of asynchrony of the left arytenoid at rest, pre exercise. However full symmetrical arytenoid function was noted in 86 of these horses following exercise. Examination of 744 TB racehorses identified grade II and III LF in 10 horses (1.3%) and grade IV LF in two horses (0.3%) with evidence

of prosthetic laryngoplasty in four (0.5%) suggesting an overall prevalence of 2.1% (Brown et al. 2005). Sweeney et al (1991) identified LN in 1.8% of 678 horses.

In a study of draught horses at one event, 64 of 183 (35%) had either grade III or grade IV LF or had a history of laryngoplasty (Brakenhoff et al. 2006).

The prevalence of laryngeal asymmetry in juvenile horses is considerably greater. Of 197 TB foals examined, 37 (19%) had LF grade III or greater and when 187 of these that were re-examined as yearlings, 43 (23%) were grade III or greater (Havemeyer 2004). Endoscopic observation of laryngeal symmetry and movement in 452 young horses (439 TB, 23 SB) has been described. Of the 452 horses examined, 217 (48%) were grade I, 167 (37%) grade II, 67 (15%) grade III and one (0.2%) grade 4 on the left side. On a second examination of 109 of the original 452 horses performed 16 months later, 57 (52%) were grade I, 36 (33%) grade II, 15 (14%) grade III and one (1%) grade IV on the left side (Anderson et al. 1997).

The prevalence of laryngeal asymmetry in TB yearlings is also considered greater than that of the general population (Embertson 1998; Stick et al. 2001; Garrett et al. 2010). This is discussed in greater detail in section 2.4.

From the literature it would appear that in the adult racing TB population the prevalence of clinically significant LN is approximately 2-3%, however that figure is significantly higher in a population of juvenile TBs. There are two possible reasons for this discrepancy:

- a) Significant wastage occurs and juvenile horses with suboptimal LF are removed from the racing population.
- b) Laryngeal asymmetry is transient in juvenile horses and as they mature LF improves.

Resting endoscopic examination remains the main diagnostic technique for investigation of LF. This is a flawed examination tool for both assessing LF at exercise and predicting future LF. It is possible that unnecessary wastage occurs

in the population of juvenile horses and therefore a more accurate (sensitive and specific) examination is required. No dynamic endoscopic examination of a population of juvenile horses has been performed and therefore the true prevalence of clinically significant LN is uncertain.

2.1.2 Intermittent dorsal displacement of the soft palate and palatal instability

Intermittent dorsal displacement of the soft palate (IDDSP) occurs when the soft palate comes to lie dorsal to the epiglottis. This results in an expiratory obstruction and is considered of clinical significance when it occurs during high intensity exercise (Sullivan & Parente 2003; Ducharme 2012). Dorsoventral movement of the caudal aspect of the soft palate is described as palatal instability (PI). This results in variable obstruction of the rima glottis during high-speed exercise. Palatal instability is frequently observed prior to the occurrence of IDDSP but is not a necessary precursor (Lane et al. 2006b; Allen & Franklin 2013a; Allen & Franklin 2013b).

IDDSP results in a reduction in minute ventilation and an associated decrease in tidal volume and ultimately impaired performance (Franklin et al. 2002). The significance of PI as a discrete disease is uncertain and it has been observed that the position of the endoscope may influence subjective assessment of the presence, or the degree of instability. However recent investigations have demonstrated a non significant trend for minute ventilation, tidal volume, oxygen consumption, and carbon dioxide production to decrease with increasing degrees of PI and the authors suggest that PI with rima glottis obstruction has negative effects on respiratory parameters that are not as great as that associated with IDDSP (Allen & Franklin 2013b).

2.1.2.1 Pathogenesis of dorsal displacement of the soft palate

The pathogenesis of IDDSP is uncertain and may be due to multiple aetiologies or syndromes (Barakzai & Hawkes 2010). No matter the aetiology, the condition is likely to be due to neuromuscular dysfunction of either the intrinsic or extrinsic musculature of the pharynx (Holcombe et al. 1999).

The position of the soft palate is partially determined by the coordinated function of four muscles; the tensor veli palatini, levator veli palatine, palatines and palatopharyngeus. The mandibular branch of the trigeminal nerve innervates the tensor veli palatini, while the others are innervated by the pharyngeal branch of the vagus (Hare 1975). The paired palatines lie on midline of the soft palate and arise from a broad tendonous aponeurosis extending from the hard palate. The palatines are surrounded by a connective sheath onto which some of the other palatal muscles insert. The levator veli and tensor veli palatini muscles arise laterally from the muscular process of the petrous temporal bone. The levator veli palatini inserts on midline ventral to the palatines muscle forming a sling and act to raise the soft palate during swallowing. The tensor veli palatine inserts laterally onto the aponeurosis and acts to tense the rostral portion of the soft palate and depress it towards the tongue (Hare 1975; Franklin 2005).

The extrinsic musculature of the pharynx ensures respiratory patency and alters the diameter of the nasopharynx by controlling the size of the oropharynx and the position of the larynx (Hare 1975; Ducharme 2012). The extrinsic musculature includes the geniohyoideus, thyrohyoideus, genioglossus, hyoglossus, styloglossus, sternohyoideus and sternothyroideus. The hypoglossal nerve innervates the geniohyoideus, genioglossus, styloglossus and the hyoglossus, while innervation to the sternohyoideus and sternothyroideus is supplied by the first and second cervical nerves. Debate exists as to the innervation of the thyrohyoideus with recent investigations in rabbits suggesting that the pharyngeal branch of the vagus nerve may be implicated (Fukushima et al. 2003) and not the hypoglossal, as is generally postulated (Cheetham et al. 2009).

The genioglossus is an extrinsic lingual muscle acting to protract the tongue and pull the basihyoid bone rostrally. The geniohyoideus originates on the mandibular symphysis and inserts on the basihyoid to pull the hyoid apparatus rostrally. The stylohyoid is a retractor of the tongue while the hyoglossus acts to retract and depress the base of the tongue. The sternohyoideus and sternothyroideus originate on the sternum manubrium and insert on the hyoid apparatus and thyroid cartilage respectively. Contraction of these muscles results in caudal retraction of the hyoid apparatus. The thyrohyoideus muscle extends from the lateral lamina of the thyroid cartilage to the caudal aspect of

the thyrohyoid bone and enhances soft palate stability by moving the larynx rostrad so the thyroid cartilage rests more rostral and dorsal in relation to the basihyoid (Ducharme et al. 2003).

The stability of the dorsal and lateral walls of the nasopharynx is achieved by contraction of the stylopharyngeus and pharyngeal constrictor muscles. The stylopharyngeus is innervated by the glossopharyngeal nerve and originates on the medial surface of the distal stylohyoid bone and ramifies on the dorsal wall of the nasopharynx. The pharyngeal constrictor muscles include the palatopharyngeus, pterygopharyngeus, hyopharyngeus and thyropharyngeus and all are innervated by branches of the vagus. Tonic activity of these muscles results in dilation of the pharyngeal walls (Hare 1975).

Dysfunction of one or more of the above muscles may be implicated in pharyngeal collapse including IDDSP.

2.1.2.1.1 Proposed pathogenesis of IDDSP

The pathogenesis of IDDSP remains poorly defined, however a number of investigations have been performed examining some of the proposed mechanisms. Three sequential studies investigated the role of each of the following in the pathogenesis of IDDSP (Holcombe et al. 1999).

a. Tensor veli palatine (Holcombe et al. 1997a)

Transection of the tensor veli palatini muscles did not cause DDSP but did result in instability of the rostral portion of the soft palate (Holcombe et al. 1997a).

b. The epiglottis (Holcombe et al. 1997b)

Bilateral blockade of the hypoglossal and glossopharyngeal nerve resulted in dysfunction of the hyoepiglotticus muscle and caused retroflexion of the epiglottis (Holcombe et al. 1997b). This did not however result in DDSP and therefore would suggest that contact between the epiglottis and the caudal portion of the soft palate is not critical in maintenance of the soft palate in a ventral position. In TB yearlings an association

between epiglottic structure or epiglottic appearance and performance has been identified (Garrett et al. 2010). However an association between ES and IDDSP is not a universally accepted concept and it is possible the caudal retraction of the larynx and elevation of the soft palate results in apparent flaccidity of the epiglottis (Ducharme 2012).

c. Palatines and palatopharyngeus muscles (Holcombe et al. 1998)

Anaesthesia of the pharyngeal branch of the vagus as it crosses the floor of the guttural pouch resulted in persistent DDSP and dysphagia. It was postulated that in the clinical case damage to the pharyngeal branch of the vagus, as might occur from lymphadenopathy of the retropharyngeal lymph nodes, could precipitate IDDSP (Holcombe et al. 1998).

The extrinsic muscles play a critical role in maintaining laryngohyoid position and altering the mechanics of the nasopharynx during exercise. Transection of the thyrohyoideus muscles resulted in more caudal positioning of the larynx and induced IDDSP in seven out of 10 horses (Ducharme et al. 2003). The endoscopic appearance of DDSP was identical to that occurring in clinical cases, supporting the hypothesis that the thyrohyoideus muscles are important in nasopharyngeal stability and specifically in preventing IDDSP.

Perineural anaesthesia of the hypoglossal nerve resulted in IDDSP in 10 out of 19 examinations (Cheetham et al. 2009). The hypoglossal nerve has two branches; the lateral branch innervates the styloglossus and hyoglossus and the medial branch innervates the genioglossus and geniohyoideus, i.e the retractors and protrudors of the tongue. Intermittent dorsal displacement of the soft palate only occurred at exercise suggesting that hypoglossal tone and function of the extrinsic muscles of the tongue may only be significant at exercise. The authors proposed that hypoglossal nerve block resulted in IDDSP, either by allowing caudal retraction of the hyoid apparatus or by preventing protrusion of the genioglossus muscle. A more recent study by the same group did not identify caudal retraction of the larynx following hypoglossal nerve block at rest. However electrical stimulation of the thyrohyoideus resulted in rostral and dorsal movement of the larynx and this is considered improve pharyngeal stability and decrease the likelihood of IDDSP (Zantingh et al. 2013).

Correlation between the presence of inflammatory airway disease (IAD) and tracheal inflammation with IDDS has been demonstrated. The association between the two entities is uncertain but IAD has been shown to result in impaired gas exchange during exercise (Courouge-Malblanc et al. 2010). This may therefore alter the pressure dynamics of the URT and induce IDDS.

2.1.2.2 Diagnosis of intermittent dorsal displacement of the soft palate

2.1.2.2.1 Clinical examination

Horses with IDDS are frequently presented for investigation of poor performance. Thoroughbred racehorses are commonly reported to perform well during the early part of a race but as the race continues there is either a gradual or in some cases a sudden loss of exercise tolerance. This is sometimes reported in association with the presence of respiratory noise. The presence of a gurgling, rattling or rough respiratory noise has been shown to be 71% sensitive and 62% specific for the diagnosis of IDDS with a positive predictive value and negative predictive value of 48% and 82% respectively (Witte et al. 2011). Therefore while there was a significant association between noise and IDDS this is not a reliable test. Of 92 horses diagnosed with IDDS on treadmill endoscopy only 62% had a history of respiratory noise (Parente et al. 2002). Lane et al (2006a) described IDDS without respiratory noise in 11% of horses. The occurrence of respiratory noise in conjunction with IDDS is variable as is the nature of the noise reported and this is now generally considered an unreliable means of diagnosis.

2.1.2.2.2 Ultrasonography

Correlation between laryngo-hyoid position and the occurrence of IDDS has been identified. Caudal positioning of the larynx has been associated with IDDS (Ducharme et al. 2003) and it has also been shown that more rostral and caudal positioning of the larynx following treatment is associated with improved racing performance (Cheetham et al. 2008). In human beings, a ventral/caudal position of the hyoid bone has been shown to be associated with pharyngeal obstruction and in horses an association between decreasing basi-hyoid depth and IDDS has been identified ($P < 0.03$) (Chalmers et al. 2009a). Ultrasonography may potentially be used to predict the occurrence of IDDS but further study and research is required before this technique can be reliably used clinically.

2.1.2.2.3 Endoscopic examination

Definitive diagnosis of IDDSP relies on the results of dynamic endoscopic examination. This will be discussed in section 2.3

2.1.2.3 Prevalence of intermittent dorsal displacement of the soft palate

The true prevalence of IDDSP is uncertain, however it is estimated to be between 10 and 20% in the two to three year old TB populations (Ducharme 2012) and it is suspected that the prevalence is greater in younger horses (Embertson 1998). Pollock et al (2009) described overground endoscopic examination of 67 Thoroughbred racehorses in which the prevalence of IDDSP was 19%.

IDDSP is considered to be the most common cause of dynamic respiratory obstruction in the TB racehorse and studies describing data from horses presenting for investigation of URT function and undergoing dynamic endoscopic examination report a prevalence varying from 39% (Tan et al. 2005) to 39.5% (Lane et al. 2006a).

2.1.3 Epiglottic abnormalities

Disease of the epiglottis is an infrequent cause of URT obstruction. The epiglottis lies dorsal to the soft palate during normal breathing. It is composed of elastic cartilage covered on its dorsal surface by tightly adhered mucosa and on its ventral surface by loose mucosa that is continuous with the aryepiglottic folds (Hare 1975). The most common abnormalities of the epiglottis include:

1. Epiglottic entrapment
2. Acute epiglottitis
3. Subepiglottic cysts
4. Subepiglottic granulomas
5. Epiglottic hypoplasia

6. Epiglottic retroversion

Epiglottic entrapment results when the subepiglottic mucosa and aryepiglottic folds become displaced dorsal to the epiglottis (Lacourt & Marcoux 2011) this can result in abnormal respiratory noise but not always poor performance (Ducharme 2012) but can also precede or result in IDDSP (Parente et al. 2002). The abnormality may be permanent or intermittent and diagnosis is uncomplicated in cases of permanent entrapment. If intermittent entrapment occurs no resting abnormalities or only subtle ulceration of the apex of the epiglottis may be evident and therefore dynamic endoscopic examination is required for definitive diagnosis.

Acute epiglottitis is uncommon and the aetiology is uncertain. Horses, generally juvenile TB racehorses present for investigation of abnormal respiratory noise or poor performance. Resting endoscopic examination identifies thickening of the epiglottis with or without ulceration of the mucosa. The response to conservative treatment is generally favourable, however permanent deformation of the epiglottis occurs in approximately 50% of cases (Hawkins & Tulleners 1994). In two cases of septic epiglottic chondritis, a likely progression of acute epiglottitis resulted in permanent deformity of the epiglottis and IDDSP (Infernuso et al. 2006).

Subepiglottic cysts are most commonly identified in juvenile TBs and are thought to develop from a congenital abnormality of the remnant of the thyroglossal duct, however an inflammatory aetiology has also been proposed (Dougherty & Palmer 2008). Juvenile horses and foals can present for investigation of respiratory noise or coughing and if the cyst is large, dysphagia may be evident (Ducharme 2012).

Subepiglottic granulomas occur as a result of inflammation or ulceration of the subepiglottic mucosa. This has also been recognised post-operatively in horses undergoing resection of the subepiglottic tissue. Clinical signs vary but in the TB racehorse this may result in IDDSP and poor performance.

Hypoplasia or flaccidity of the epiglottis has been associated with IDDSP (Haynes 1981), however much debate still remains regarding the significance of ES in the

aetiopathogenesis of IDDSP. No association between ES and IDDSP in adult horses was identified (Parente et al. 2002) and it has been shown that experimentally induced retroversion of the epiglottis does not result in subluxation or displacement of the soft palate (Holcombe et al. 1997b). However a relationship between epiglottic conformation graded as convex, flat or tipped up and PI and IDDSP is reported in adult horses undergoing treadmill examination (Allen & Franklin 2013b). It was also shown in this study that the appearance of the epiglottis varies during the examination. Epiglottic structure is generally assessed endoscopically by observing the length, width, flaccidity, marginal serrations and vasculature of the epiglottis (Holcombe 2007). It is now widely accepted that the appearance of the TB yearling larynx is different to that of the adult horse and therefore assessment of ES should not be made carefully until the horse has matured (Embertson 1998; Ducharme 2012). This will be discussed section 2.4.

Epiglottic retroversion is an infrequently occurring dynamic condition resulting in the epiglottis retroverting into the rima glottis. This results in abnormal respiratory noise and dynamic obstruction (Parente et al. 1998) and is likely due to disease of the hyoepiglotticus or geniohyoid muscle or the associated hypoglossal innervations. As discussed this does not necessarily result in IDDSP.

2.1.4 Other disease

2.1.4.1 Axial deviation of the aryepiglottic folds

Axial deviation of the aryepiglottic folds (ADAF) results in partial dynamic obstruction of the rima glottis (Fulton et al. 2012). The prevalence of ADAF varies between studies but the condition is reported in between 6% and 54.7% of cases, occurring in isolation in between 3.8% and 34% (King et al. 2001; Parente et al. 2002; Tan et al. 2005; Lane et al. 2006b). The reason for such a wide variation in prevalence is uncertain but this may reflect variation in the assessment of mild movements of the aryepiglottic folds and also a suspected higher prevalence in younger horses.

Axial deviation of the aryepiglottic folds in conjunction with LN has been reported and is thought to be the result increased negative pressure on the contralateral side of the larynx (Rakesh et al. 2008). An association between ADAF and IDDSP has been described, with 71 of 115 horses with ADAF having concomitant IDDSP (Lane et al. 2006b). An association between stability of the soft palate and severity of ADAF was also recently supported (Allen & Franklin 2013b). The pathogenesis behind this is uncertain and a definitive association has not been demonstrated in all studies (King et al. 2001; Tan et al. 2005). It is however possible that elevation of the soft palate prior to IDDSP results in loss of tension on the aryepiglottic folds predisposing to collapse (Allen & Franklin 2013; Kelly et al. 2013).

2.1.4.2 Ventromedial collapse of the apex of the corniculate process

Ventromedial collapse or ventroaxial luxation of the apex of the corniculate process of the arytenoids has been described. The prevalence is reported at 5% (12 TB and 3 SB) in a group of horses undergoing dynamic endoscopic examination (Dart et al. 2005) and as 5.2% (7/133 Clydesdales and one TB) during resting endoscopic examination (Barakzai et al. 2007). In the study by Dart et al (2005), all horses had collapse of the left corniculate under the right. Five horses had a history of surgical treatment for LN, however in the remaining 10 horses, no evidence of laryngeal asymmetry was identified at rest. Considering the predominance of left sided disease, the authors speculated that collapse was a result of LN with preferential atrophy of the transverse arytenoideus muscle. Barakzai et al (2007) described left sided laryngeal asymmetry in 6/8 horses at rest but both left and right collapse of the corniculate was noted (3 right, 5 left). Following dissection of one clinically affected cadaver the authors proposed elongation or laxity of the dorsal transverse arytenoid ligament as the cause of collapse.

2.1.4.3 Vocal cord collapse

Vocal cord collapse (VCC) frequently occurs in combination with LN where failure of arytenoid abduction results in laxity of the vocal cord, therefore predisposing to collapse. Primary vocal cord collapse occurs when maximal arytenoid abduction is present. Contraction of the short, paired cricothyroid

muscles tense the vocal cords. This muscle is innervated by the external branch of the cranial laryngeal nerve (branch of the vagus nerve) and dysfunction of this neuromuscular structure has been shown to result in vocal cord instability and collapse during exercise (Holcombe et al. 2006).

The prevalence of VCC alone without evidence of LN is reported to be low. Of 100 horses presented for investigation, three had VCC (two left and one right)(Kannegieter & Dore 1995). In an adult population of 600 horses undergoing dynamic endoscopy, VCC was identified alone in 10 horses (1.6%) (3 left, 3 right and 4 bilateral), in combination with laryngeal asymmetry in 36 horses (6%) and in combination with other disease such as IDDSP and ADAF in a further 19 horses (3%) (Lane et al. 2006b). Tan et al. (2005) described a prevalence of 22% with pathology occurring alone in 23% of those cases (Tan et al. 2005)

2.1.4.4 Pharyngeal collapse

Pharyngeal collapse is defined as collapse of the dorsal or lateral walls of the pharynx and is thought to be the result of neuromuscular dysfunction of the stylopharyngeus caudalis (dorsal collapse) (Tessier et al. 2004) or palatopharyngeus (lateral collapse) muscles. Mild collapse of the dorsal pharyngeal wall is normally seen at the end of expiration but in clinical cases collapse is noted at peak inspiration (Ducharme 2012). Prevalence has been reported at 20% in horses presenting for poor performance, with pharyngeal collapse the only disease identified in 5% of horses (Boyle et al. 2006). Reported prevalence in other studies range from 1.3-3%, with other URT abnormalities simultaneously identified in between 50% and 80% of these horses (Lane et al. 2006b; Tan et al. 2005). In a study in which racing performance subsequent to diagnosis of pharyngeal collapse was examined, horses greater than four years old had a significantly lower performance index post diagnosis (Boyle et al. 2006). It is thought that the prevalence is greatest in 2-3 year old TB racehorses (Ducharme 2012).

2.1.4.5 Cricotracheal ligament collapse

The cricotracheal ligament is a dense elastic structure that connects the caudal aspect of the cricoid and the first tracheal ring. Collapse has been infrequently described in TB racehorses (Goulden 1977; Kelly & Pollock 2015) and is thought

to be the result of an abnormally long cricotracheal space and increased sub-atmospheric pressure during exercise. It is however possible that caudal retraction of the larynx would reduce tension on the ligament and predispose to circumferential collapse. In most cases described by Kelly and Pollock (2015) disease was present with a number of other dynamic endoscopic abnormalities.

2.1.4.6 Dynamic ventrorostral displacement of the dorsal laryngeal mucosa

Dynamic ventrorostral displacement of the dorsal laryngeal mucosa is a recently described disease of unknown significance where the laryngeal mucosa obscures the interarytenoid notch during inspiration (Pollock et al. 2013).

2.2 Endoscopic examination of the Thoroughbred racehorse

Endoscopic examination of the TB racehorse is frequently performed during the assessment of poor performance and is also routinely performed in some yards prior to or following racing. Both resting and dynamic endoscopic examinations can be performed.

2.2.1 Resting examination

Resting endoscopic examination is generally performed on site. The horse is often restrained by means of a nose twitch and the endoscope is generally passed via the right nostril (this may vary depending on practitioner preference). Fibre-optic endoscopes remain the most commonly used in general practice and for use in the field. Video endoscopy is frequently used in the hospital setting and is used by some sales companies (New Zealand Blood Stock) when assessment of laryngeal function is performed in cases with asymmetry considered to require expert panel review.

2.2.2 Dynamic examination

Dynamic endoscopic examination is performed with the horse exercising on a high-speed treadmill or overground. High-speed treadmill examination is performed over a set distance and speed and the incline can be adjusted to further alter the intensity. The horse is acclimatised to the treadmill, generally over two sessions and on the third session the exercise test and endoscopic examination is carried out. A standard fibre-optic video endoscope is generally used for the examination (Martin et al. 1996; Tan et al. 2005; Lane et al. 2006a).

Dynamic overground endoscopy was recently described (Franklin et al. 2008; Desmaizieres et al. 2009; Pollock & Reardon 2009; Pollock et al. 2009; Van Erck 2011; Priest et al. 2012). In all reports examination is performed with an endoscope positioned in the pharynx, secured to a bridle and connected to a recording device and light source. These are positioned on the saddlecloth, on a backpack worn by the jockey or on the sulky. The horse is exercised over a distance and at an intensity comparable to that required during racing.

2.2.2.1 Comparison of treadmill and overground endoscopy

High-speed treadmill examination is performed with the horse exercising in an enclosed, unfamiliar environment and surface. A period of training is required and this is generally an expensive examination that requires transport of the horse and it has not been universally accepted by trainers of TB racehorses. However a recent review of 2258 treadmill examinations identified a complication rate of 5.4%, with only 13 serious injuries, 5 of which were exertional rhabdomyolysis (Franklin et al. 2010). The test is more repeatable and the examiner has control over the intensity of the examination allowing horses to be exercised to fatigue in an incremental fashion (Sloet van Oldruitenborgh-Oosterbaan & Clayton 1999; Allen & Franklin 2010b).

Overground examinations are generally more affordable and allow the horse to be examined in a more familiar environment and on a surface where normal locomotion can be achieved (Sloet van Oldruitenborgh-Oosterbaan & Clayton 1999). This test therefore has the potential to more accurately reproduce conditions encountered during racing. The intensity and duration of exercise is however often limited by the facilities available at the individual training establishment. In the UK the majority of training is performed on short (approx 6 furlong/0.75miles) uphill gallops. Horses are therefore rarely exercised to fatigue but do perform an interval-training regimen. It has been suggested and also demonstrated by a direct comparison in four horses, that treadmill endoscopy may be more sensitive in the diagnosis of intermittent conditions such as IDDSP that occur during high intensity exercise (Allen & Franklin 2010a). This is considered more significant in national hunt horses performing over a greater distance than in flat horses or sprinters performing high intensity exercise over shorter distances. Indeed exercising sprint horses over an incremental test such as performed during treadmill examination may be inappropriate (Allen & Franklin 2010a). Overground examination also allows study of juvenile horses that may be more difficult to examine on a treadmill.

Dynamic endoscopic examination during lunging exercise of adult horses has been described and the results compared with those obtained during high-speed treadmill examination (Franklin et al. 2008). Lunging underestimated the

severity of disease but in none of the six horses examined was a false positive diagnosis obtained while lunging.

2.3 Interpretation of the results of endoscopic examination

Endoscopic examination of the URT provides information regarding luminal anatomical structure and function at the time of examination, however very little information is acquired regarding the aetiology, pathogenesis and progression of disease. For example, longitudinal endoscopic studies determine the progression of LN by assessing deterioration or improvement in the symmetry of laryngeal movements (Anderson et al. 1997; Dixon et al. 2002; Davidson et al. 2007). This is an indirect and therefore potentially inaccurate assessment of the progression of disease involving the recurrent laryngeal nerve and cricoarytenoideus dorsalis muscle.

Resting endoscopic examination has the potential to identify numerous diseases of the URT; however, combined with the limitations described above, this is a static examination and diagnosis of dynamic conditions is therefore difficult and prone to error. Significant variability in interpretation exists, including the significance of degree of laryngeal asymmetry and incidence of IDDSP.

2.3.1 Laryngeal Neuropathy

2.3.1.1 Intra/inter observer variability

Numerous studies have investigated the limitations of assessing LF at rest. These include intra- and inter- observer variability and intra-horse variability. Reported intra- and inter- observer repeatability varies from 76.3-83.3% and from 63.1-79% respectively (Hackett et al. 1991; Perkins et al. 2009). The first paper described the greatest variability between grades I and II, with improved repeatability between grades where full abduction can be achieved (I and II) and where maximal abduction cannot be achieved (III). When using the Havemeyer scale, Perkins et al. (2009) found that where both observers assigned different

grades, all horses were graded II.1, II.2 or III.1 at one of the examinations suggesting greatest variability in this range.

2.3.1.2 Intra-horse variability

Variability in the appearance of LF at rest has been described in the horse and it has been suggested that the results of resting endoscopic examination performed on a single day should be interpreted with caution. In one study fewer than half of 104 horses were graded the same on a second examination. Of these horses 43.3% were given a grade that differed by one, but more significantly 13.2% were given a grade that differed by two, 2.3% a grade differing by three and one horse improved by four grades (Perkins et al. 2009). These findings have significant potential implication during the sale and treatment of horses. It is unknown if similar variability exists using dynamic examination.

2.3.1.3 Comparison between the results of resting and dynamic examination

The correlation between LF grade during resting and dynamic endoscopic examination have been investigated. Barakzai & Dixon (2011) described good correlation between grades of LF at rest using the Havemeyer scale and LF at exercise (grades A-C). Other reports have also reported the relationship. Lane et al. (2006b) described 19% of horses with grade 4/5 laryngeal function having normal function at exercise and 7% of horses with normal LF at rest having dynamic arytenoid collapse during exercise. Mis-categorisation (when compared to the results of dynamic examination) of 33% of horses with LF grade II.2 and III.1 at rest has been reported (Garrett et al. 2011).

2.3.2 Intermittent dorsal displacement of the soft palate

Intermittent dorsal displacement of the soft palate does spontaneously occur at rest and although investigated, the association between the occurrence of IDDSP at rest and during exercise remains uncertain. The specificity of resting endoscopic examination for the diagnosis of IDDSP during exercise is often high (85-95.1%) however sensitivity is extremely low (15-25.5%) (Parente et al. 2002; Lane et al. 2006a; Barakzai & Dixon 2011), i.e. horses that are observed to have

DDSP at rest are likely to have it at exercise, but lack of DDSP at rest does not mean they will not have disease at exercise. Dynamic examination remains the gold standard for the diagnosis of IDDSP however consideration must be given to the appropriate intensity and duration of exercise as discussed in section 2.2.2.1

2.4 Endoscopic examination of the Thoroughbred yearling: Specific considerations.

Resting endoscopy of the TB yearling is performed in a similar fashion to adult horses. The horse is examined in a stable, a nose twitch is generally applied and the endoscope is passed via the right nostril along the ventral meatus until the pharynx and larynx are visible. Nasal occlusion is performed or swallowing is induced to assess LF, especially in horses where asymmetry is seen during non-stimulated observation.

2.4.1 Laryngeal Neuropathy

Assessment of LF is the primary focus of endoscopic examination of the TB yearling.

In one study, examination of 427 TB yearlings identified the following grades of LF, grade I in 149 yearlings, grade II in 171, grade III in 94, and grade IV in 13. There was a significant association between laryngeal LF and the ability of the horse to recoup its sale price, i.e horses that were grade I or II were more likely to do so than grade III or IV together or grade III alone (Stick et al. 2001). Therefore 25% had disease that was considered performance limiting. (Study performed using a four-grade scale where grade II can achieve and maintain full abduction but grade III cannot).

Endoscopic evaluation of arytenoid function in 2954 TB yearlings identified 571 horses with grade I LF, 1068 were grade II.1, 257 were grade II.2 and 55 were grade III. Horses with grade II.2 LF had lower mean total earnings per year at two and three, and significantly lower mean total earning at four. Horses with grade III LF had significantly lower mean of the total number of starts/horse and earnings at age three and four. Therefore 312 (11%) were considered abnormal

(Garrett et al. 2010). (Scale used resembled the Havemeyer scale with grade II.2 achieving and maintaining abduction at times and grade III neither achieving nor maintaining abduction)

From the above studies it is clear that no definitive consensus exists on what grade of LF at rest would be indicative of current or future performance limiting disease. Decisions regarding the suitability of horses with laryngeal asymmetry for sale vary between countries and between grading systems used. Using the Havemeyer scale it is however generally the case that LF grades I and II.1 are considered normal (full abduction can be achieved and maintained). Grades II.2 and III.1 (full abduction achieved but horses with grade III.1 cannot maintain abduction) are thought to be equivocal and grades greater than III.1 (full abduction is never achieved) are considered abnormal. Where endoscopic examination is requested by the sales company such as New Zealand Bloodstock, decisions regarding the suitability of horses with equivocal grades are made by an expert panel where video endoscopic examination is performed and independent assessment made followed by consensus. In other countries such as the UK and Ireland, horses are lunged by the sales company and only horses making an abnormal respiratory noise are endoscopically examined. It is therefore possible that horses with abnormal LF but that are not making a noise would not be examined.

2.4.2 Intermittent dorsal displacement of the soft palate

The incidence of IDDSP at rest in a juvenile population of TB horses is thought to be greater than that of mature animals (Embertson 1998). The significance of IDDSP alone occurring during evaluation of TB yearlings is uncertain. No negative correlation between the occurrence of IDDSP in TB yearlings at rest and future racing performance has been noted (Stick et al. 2001) and longitudinal studies assessing the palatal function of juvenile horses are lacking.

2.4.3 Epiglottic structure and epiglottic abnormalities

Assessment of ES in TB yearlings is based on the apparent length, width, flaccidity, marginal serrations and dorsal vasculature of the epiglottis. A grading scale (0-IV) is described (Pierce & Embertson 2001) and the association between

ES and future racing has been investigated with conflicting results. Stick et al. (2001) found no correlation and suggested that a short flaccid narrow epiglottis may be considered normal in TB yearlings while Garrett et al. (2001) found that horses with grade III or IV had lower earnings when compared to horses with lower grade of ES (Garrett et al. 2010). The mechanism by which ES would affect performance is uncertain and as previously discussed the correlation between ES and IDDSP in adult horses is poor.

Assessment of ES remains a significant part of the examination of TB yearlings and further clarification is required to assess the significance of ES and to characterise the changes that occur in the appearance of the epiglottis as horses mature.

Epiglottic entrapment (0.06%), subepiglottic cysts (0.14%) and epiglottitis are infrequently identified in the yearling TB (Lane 2003). Acute epiglottitis is more common in juvenile horses (Hawkins & Tulleners 1994) and was discussed previously.

2.4.4 Other disease assessed in Thoroughbred yearlings

2.4.4.1 Pharyngeal lymphoid hyperplasia

Pharyngeal lymphoid hyperplasia (PLH) is a common finding in the juvenile TB and results from activation of follicular lymphoid tissue in the nasopharynx. The exact aetiology and the effect of PLH on performance is uncertain (Auer et al. 1985) and association between the severity of PLH and lower airway inflammation has been identified (Koblinger et al. 2011). It is however speculated that PLH may result in, or be a symptom of URT inflammation that could result in neuromuscular dysfunction leading to instability of the URT or IDDSP (Holcombe et al. 1999).

2.4.4.2 Arytenoid mucosal lesions

Focal axial mucosal lesions have been described in TB yearlings with a prevalence of 0.63% (Kelly et al. 2003) and arytenoid abnormalities were detected in 33/2317 (1.4%) horses in a second study, four of which had arytenoid chondritis (Smith et al. 2006). In the latter study, of 29 horses that did not have

arytenoid chondritis, two horses developed URT abnormalities that were not considered related to the mucosal lesion (laryngeal neuropathy). Kelly et al. (2003) identified healing in 15 of 18 horses during repeat endoscopic examination. Of the horses identified with mucosal lesions alone, 10% developed granulomas and 5% developed arytenoid chondritis with all three requiring further treatment, therefore suggesting that mucosal ulceration is a significant finding.

2.4.4.3 Other

Vocal cord collapse, ventromedial luxation of the apex of the corniculate process, ADAF and pharyngeal collapse are dynamic conditions of the URT that have not been diagnosed dynamically in TB yearlings. It is however possible that these conditions would result in abnormal respiratory noise during the exercise portion of a yearling examination (if performed) and are therefore of potential significance in the population examined in this thesis. These diseases have been discussed in section 2.1.4.

3 Materials and Methods

3.1 Study design

This study was designed as a prospective cohort study and was divided into two parts.

3.1.1 Part I

Endoscopic examinations of 57 TB yearlings (one year old as of the 1st January 2011) at rest pre exercise, during lunging exercise and at rest post exercise were performed in September and October 2011. Comparison between the results of each examination was undertaken.

3.1.2 Part II

Repeat examination of horses included in Part I was performed during ridden exercise, both at the beginning of the horses two year old racing season (Exam II - April 2012) and at the end of the two year old season (Exam III - October /November 2012). Comparison between the results of each examination (Exam I, II and III) was performed and association between disease investigated.

3.2 Ethical approval

This project was approved by the University of Glasgow, School of Veterinary Medicine, Ethics and Welfare Committee. Informed consent to examine the horses was obtained from the trainer prior to the start of the project. If abnormalities were identified, advice on management and treatment options were given. This examination constituted clinical screening and although Home Office approval was received, this was not required.

3.3 Horses

All TB yearlings at a single flat racing yard were available for examination. This cohort of juvenile TB yearlings was managed in a similar manner on one yard for the duration of the study.

Horses were required to be free from musculoskeletal abnormalities or systemic illness and to have a suitable level of fitness to complete the exercise test without increased risk of injury. Horses were presented and included in the study based on the decisions of the trainer, the onsite Veterinary Surgeon and the author. Therefore not all horses in the age group on the yard were available at the time of the initial examination. Repeat examination for Part II was also not possible in all horses, and some horses not examined in April 2012 were examined in October/November 2012 and vice versa. This was considered a limitation of the study but one that was unavoidable in ensuring that the welfare of the horses was maintained. This will be discussed further in the relevant chapters.

3.3.1 Part I

The initial examination was performed within one month of the yearlings' arrival at the yard and before ridden exercise was introduced, however all horses were accustomed to having a saddle placed. All horses were presented for examination wearing a standard bridle with cavesson noseband, loose ring snaffle bit, knee boots, brushing boots and over reach boots. Signalment, previous medical histories and exercise schedules were recorded for each horse. Each horse was examined for external evidence of respiratory tract infection such as nasal or ocular discharge or coughing. The presence of any other physical abnormalities was also recorded.



Figure 3-1: Image of yearling ready for endoscopic examination. (1=recording medium and flush mechanism with video processor and battery in the same position on the right side, 2= endoscope adjusting unit with flush attachment, 3= telemetric ECG cable (unit in saddle pack on left side) 4= GPS



Figure 3-2: Image of yearling following lunging exercise showing arrangement of the endoscope on the bridle.

3.3.2 Part II

Repeat dynamic endoscopic examination was carried out during ridden exercise. Horses were available for examination if they were not due to race in the following five days and if they were in regular training i.e. were fit enough to perform the exercise test. As previously discussed, during both Exam II and III some individual horses were excluded. Horses were presented for examination following a warm up period and a gallop of equal distance to the exercise test. Standard tack was used on all occasions (a loose ring snaffle bit, standard cavesson nose band and saddle). Standard tack was a requirement of the examination as alteration in tack such as the use of a modified bit and a drop nose band or grackle that could aid in maintaining the stability of the tongue and keep the mouth closed, both of which have been considered to alter dynamics of the URT and have also been considered as a treatment for IDDSP (Barakzai & Dixon 2005). Signalment, previous medical history and current exercise schedule were recorded. The horse was again examined for evidence of respiratory infection and any other abnormalities were recorded.

3.4 Endoscope

The Optomed®¹ DRS wireless video endoscope (Pollock et al. 2009) was used for all examinations. Horses were fitted with the customised saddle-cloth containing the recording medium and battery, which was secured in place by the saddle and girth. A customised bridle was placed for attachment of the endoscope and a nose twitch was applied to the horse for placement. The insertion tube of the endoscope was placed along the ventral meatus of the right nasal cavity into the nasopharynx and positioned just rostral to the epiglottis, allowing a clear view of the larynx and caudal portion of the soft palate. After the endoscope was positioned, it was retroflexed at the level of the right nostril and attached to the customised bridle using clips and cable ties. The nose twitch was then removed.

¹Optomed, Les Ulis, France

3.5 Electrocardiogram

In order to determine the maximal heart rate (HR_{max}) attained during the exercise test, standard base-apex, lead II telemetric ECG recordings (Kruuse Televet 100)² were obtained in 20 randomly selected yearlings in Exam I and in 23 randomly selected horses during Exam III. The HR_{max} was determined using automated R-R analysis. During Exam II a commercially available human heart rate monitor was used (Garmin)³. Analysis of these data identified a high degree of variability and while a representative sample was obtained, achieving a consistent reading in all horses was difficult and so an ECG was used for Exam III

3.6 Global positioning satellite receiver

A GPS device (Garmin)³ set at a data collection interval of 1 Hz was attached to the saddle (Part I) or given to the rider (Part II). This was started at the beginning of each examination and was used to record: duration of evaluation, horse speed and distance travelled. (See Figs 3-1 and 3-3)

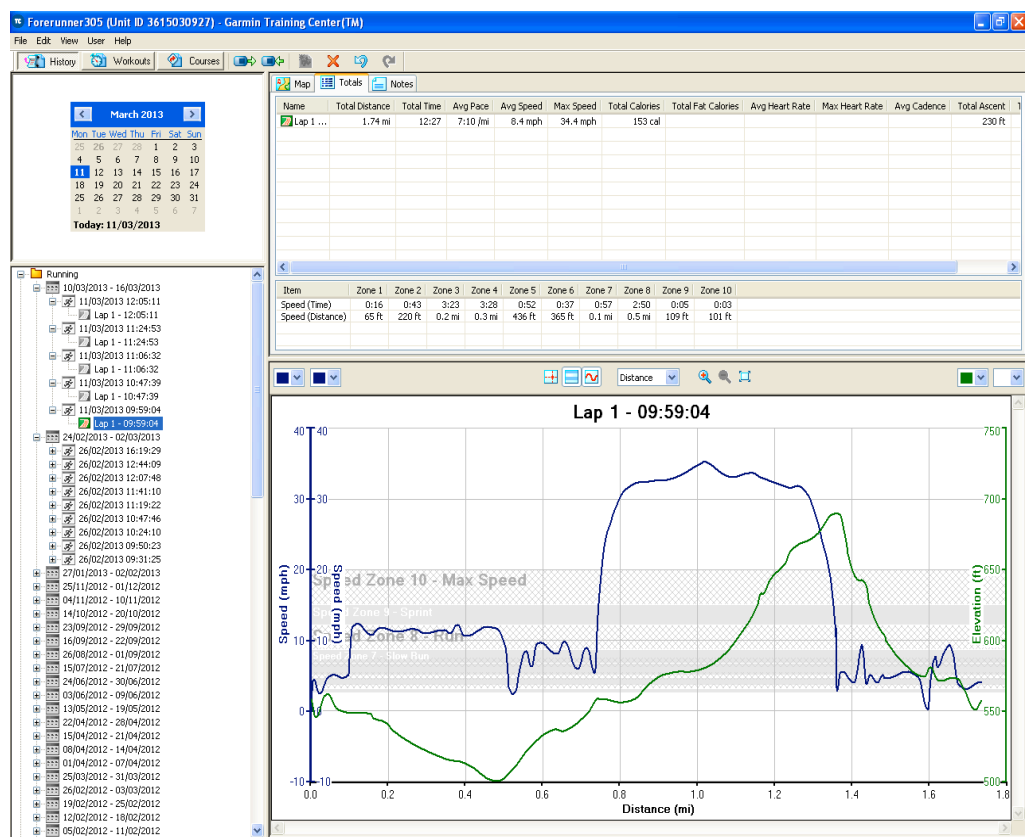


Figure 3-3: Example of GPS data acquired during examination.

² Kruuse, Havretøften, DK-5550, Langeskov, Denmark

³ Garmin forerunner 305, Olathe, Kansas, USA med

3.7 Endoscopic examination

Following endoscope placement, video endoscopic recording was begun and continued throughout the examination. A chapter break was placed in the recording between each part of examination (resting pre- and post- exercise and exercise) to facilitate subsequent analysis.

3.7.1 Part I (Exam I - yearling examination)

3.7.1.1 Rest Pre-Exercise

Following endoscope placement the twitch was removed and the horse was allowed to stand at rest for a minimum of one minute, prior to being led to the site of the exercise test. At least one swallowing event was observed in all videos, nasal occlusion was not performed as this was resented and symmetry post swallowing has been shown to be a better indication of laryngeal function (Parente & Martin 1995).

3.7.1.2 Exercise

All horses were lunged in an enclosed 12-meter lunging arena on a surface that was a mixture of sand and woodchip. Each horse was lunged at a canter for five minutes or until fatigued i.e. they were unable to maintain that gait. Locomotor respiratory coupling was achieved and sustained in all cases. The examination was observed by the author and at least one other Veterinary Surgeon experienced in the dynamic examination of the upper portion of the respiratory tract. Any abnormal respiratory noises were recorded.

3.7.1.3 Rest Post-Exercise

Following the exercise test the horses were allowed to stand at rest for a minimum of one minute in the lunging arena. After the allotted time, the endoscope (and ECG, when used) was removed and the horses were checked for any complications, such as epistaxis. Any complications that occurred during the examinations were recorded.

3.7.2 Part II (Two year old examinations)

Each horse was presented following warm up and one piece of exercise identical to that performed during the examination. The horse was exercised over a distance that was appropriate when considering the fitness and intended racing distance of the horse.

3.7.2.1 Exam II (April 2012 - Beginning of two year old season)

Each horse was exercised at a gallop over either three or four furlongs. The three furlong gallop was straight with a 143ft incline. The four furlong gallop had a 234ft incline. This gallop initially curved on a right hand bend before the beginning of the incline. One minute of resting pre exercise and post exercise video was acquired. All examinations were observed and any noise reported by the jockey was recorded.

3.7.2.2 Exam III (October/November 2012 - End of two year old season)

Horses were exercised between three and ten furlongs. The six furlong gallop incorporated the four furlong gallop as described above with the same end point. The ten furlong gallop incorporates the three furlong and six furlong gallop as described above with the three furlong gallop being used in reverse (see figure 3-4). This was considered consistent with the greater fitness and maturity of the horses. Fitness however did vary depending on the consistency of training for individual horses and the occurrence of injury or illness. All other parts of the examination were as described for the April examination.

3.8 Video analysis:

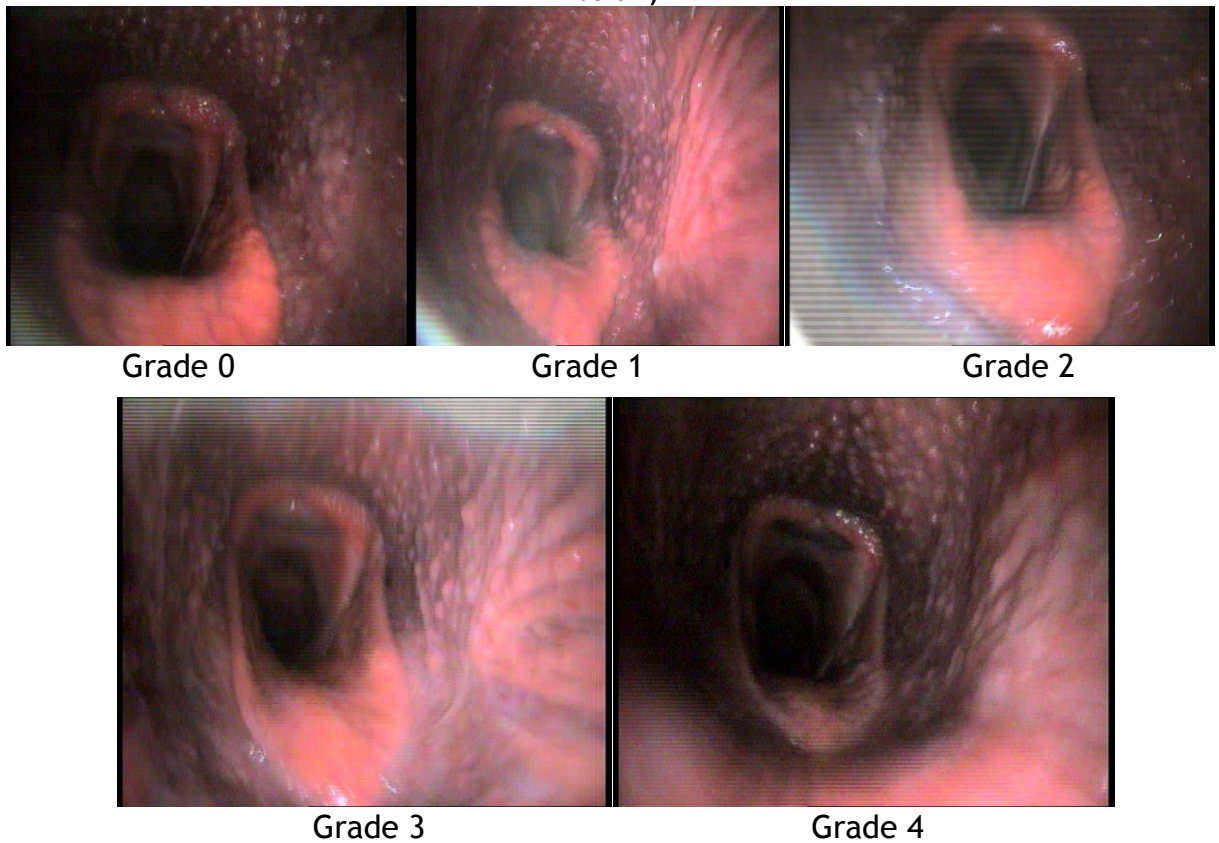
Videos were divided into: pre-exercise, exercise and post-exercise files, randomly labelled, and blindly reviewed. The author and two ECVS diplomats experienced in the dynamic evaluation of the URT reviewed videos for exams I and II, the author and a single ECVS diplomate reviewed exam III. Following individual assessment, any case where a difference in grading occurred, was identified and reviewed by the examining clinicians following which a consensus was achieved. This consensus grading is reported in this thesis and was used for statistical analysis.

Figure 3-4: Aerial photograph of the training facility showing the start point for each exercise test.



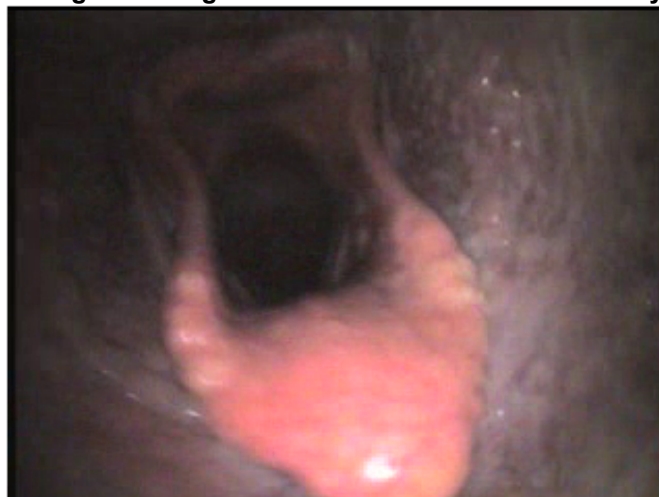Laryngeal function (Havemeyer scale at rest/Grade A-C at exercise) (Havemeyer 2004; Rakestraw et al. 1991; Strand et al. 2009; Strand et al. 2012) epiglottic structure (ES) (Grade 0-4) (Garrett et al. 2010) and degree of pharyngeal lymphoid hyperplasia (PLH) (grade 0-4) (Holcombe 2007) were recorded and graded. The grading of ES was based on a previously published scale, however this is not a universally accepted grading system and therefore the author's interpretation with representative images is shown in figure 3-5. Presence or absence of: vocal cord collapse (VCC) (mild, moderate, severe) (Kannegieter & Dore 1995; Lane et al. 2006b; Strand et al. 2012) axial deviation of the aryepiglottic folds (ADAF) (mild, moderate, severe) (Fig 6) (King et al. 2001; Lane et al. 2006b; Strand et al. 2012) intermittent dorsal displacement of the soft palate (IDDSP) (Rehder et al. 1995; Lane et al. 2006b), pharyngeal collapse (mild, moderate, severe) (Boyle et al. 2006; Strand et al. 2012), and mucopurulent secretions at the rima glottis (mild, moderate, severe) were also recorded and graded for all examinations, using previously described grading systems where applicable. Any other abnormalities noted were also recorded.

Figure 3-5: Epiglottic structure grade 0-4 (still images representing grades as described below)



Grade 0	Good marginal serration, dorsal vasculature, good thickness and length
Grade 1	Thinner, with some flaccidity
Grade 2	Loss of marginal serrations and dorsal vasculature, thinner with flaccidity
Grade 3	Thin and flaccid
Grade 4	Short flaccid and thin

Figure 3-6: Still image showing moderate axial deviation of the aryepiglottic folds



3.9 Statistical analysis⁴

Laryngeal function and ES grades were compared between resting and exercising examinations (Part I) and between resting pre-exercise and exercise for all three examination (Part II) using Wilcoxon signed rank tests. Grade of VCC, ADAF, ES and PLH was also compared between all three examinations (Part II) using Wilcoxon signed rank tests. Using McNemar's tests the occurrence of IDDSP was compared between resting and exercising examinations (Part I) and between all exercising examinations (Part II) taking McNemar's significance probability to assess significance.

In an attempt to evaluate clinically significant grades of disorders, the following categorisations were also performed:

Laryngeal function scores were categorised in two ways: as either "Symmetrical" (Grade 1 at rest/grade A at exercise) or "Asymmetrical" (Grade \geq II.1 at rest or grade B or C at exercise) and as either "Within Normal Limits" (Grade $<$ II.2 at rest/grade A at exercise) or "Abnormal" (Grade $>$ II.1 at rest/grade B or C at exercise); Intermittent dorsal displacement of the soft palate was categorised as either "Significant" (IDDSP that was either frequent ($>$ 3 times), or prolonged ($>$ 8 seconds) (Rehder et al. 1995; Lane et al. 2006b) or "Any" (IDDSP that was not frequent or prolonged); and ES grade was categorised as either "Low" (Grade 0-2) or "High" (Grade 3-4) (Pierce & Embertson 2001; Garrett et al. 2010). Categories were compared between resting and exercising during exam I (Part I). In Part II the following comparisons were made between Exam I, II and III; LF at rest pre-exercise and during exercise, IDDSP, VCC and ADAF during exercise and ES and PLH at rest pre exercise.

Chi-squared tests (or Fisher's exact tests, when any expected group size was 5 or less) were used to examine the associations between the occurrences of the pathological conditions identified, for example, whether IDDSP was more common in cases with ADAF. The categorisations described above were used for the comparisons, in addition PLH Grade was categorised as; "Severe" ($>$ 2) or "Mild" (\leq 2); The presence of ADAF was categorised as "Mild" (small Medial

⁴ Minitab, Minitab Ltd, Coventry UK

movements) or “Moderate to Severe” (large Medial movements); the presence of mucopurulent material was categorised as “Mild” (small amount of mucus material) or “Moderate to Severe” (increased amounts of material); and the occurrence of VCC was categorised as “Mild” (minimal movement or instability in the vocal cords) or “Moderate to Severe” (more pronounced movement of the vocal cords).

In Part I associations between pathological conditions identified at rest pre exercise, during exercise and at rest post exercise were examined. In Part II the result of each examination (Exam I, II and III) were combined and associations were investigated.

Significance was set at $P < 0.05$.

4 Comparison of dynamic and resting endoscopy of the upper portion of the respiratory tract in 57 Thoroughbred yearlings

4.1 Introduction

Resting endoscopic examination of the TB yearling is frequently performed and has been discussed in the literature review; however, to our knowledge no report of dynamic endoscopic examination of TB yearlings exists.

The objectives of this part of the study were:

1. To assess the feasibility of performing dynamic endoscopic examination in a group of TB yearlings during exercise and to report the results of a set examination procedure.
2. To examine the association between resting and dynamic endoscopic examination findings within this group.

The general hypothesis of this part of the study was that there would be a poor association between the results of resting and dynamic examination.

Examination was performed as described in Chapter 3, General Materials and Methods.

4.2 Results

At the time of examination 63 horses that fitted the inclusion criteria were present on the yard. Fifty eight horses were presented for examination. Of these, one horse severely resented application of the twitch and placement of the DRS was not possible. Examination was well tolerated in the 57 horses that were examined, both at rest and during exercise. Fifty seven horses were examined and six horses were excluded (Table 4-1).

Table 4-1: Horses not examined and reason

Horse	Reason for not examining
58	In field/not in exercise
59	In field/not in exercise
60	In field/not in exercise
61	In field/not in exercise
62	In field/not in exercise
63	Resented placement of endoscope or twitch

4.2.1 Heart rates and GPS data

Global positioning data including speed and distance travelled was acquired for 51 horses. In six horses, GPS data were not acquired, due to failure of the system to maintain satellite signal. The mean maximum speed attained during the examination was 11.7MPH (range 7.6-33.5) and mean distance travelled 0.42miles (range 0.19-0.67). The median “maximum heart rate” for the twenty horses recorded on the ECG was 201 (range 174-220) (Table 4-2).

Table 4-2: Heart rate

Horse	ECG HR
5	220
6	174
7	212
8	205
9	196
10	178
11	204
12	180
13	200
14	214
15	198
18	196
36	208
37	204
38	212
39	196
40	205
41	208
42	205
43	200

Table 4-3: Frequency of occurrence of disease at each examination (Part I) and results of statistical evaluation of associations between conditions

	Number Pre-Exercise (%)	Number Exercise (%)	Number Post-Exercise (%)
LF Grade			
I/grade A at exercise	28 (49)	54 (95)	32 (56)
II.1/grade B at exercise	21 (37)	3 (5)	21 (37)
II.2	7 (12)	0	3 (5)
III.1	1 (2)	0	1 (2)
LF Grade >1 at rest/grade B at exercise (Asymmetrical)	29 (51) ^a	3 (5) ^{a,b}	25 (44) ^{b,c}
LF Grade >II.1 at rest/Grade B at exercise (Abnormal)	8 (14)	3(5)	4 (7)
IDDSP			
Present (Any)	13 (23) ⁱ	19 (33) ^{j,k,l}	11 (19)
Prolonged or Frequent (Significant)	5 (9) ^d	8 (14) ^{e,f,g,h}	3 (5)
ES Score			
0	12 (21)	13 (23)	15 (26)
1	19 (33)	20 (35)	23 (40)
2	20 (35)	12 (21)	9 (16)
3	5 (9)	12 (21)	9 (16)
4	1 (2)	0	1 (2)
ES Score >2 (High)	6 (11) ^{d,g,i,n}	12 (21) ^{e,j,m}	10 (18)
PLH Grade			
0	0	0	0
1	0	3 (5)	1 (2)
2	13 (22.8)	5 (9)	3 (5)
3	22 (38.6)	22 (39)	15 (26)
4	22 (38.6)	27 (47)	38 (67)
PLH Grade >2 (Severe)	44 (77)	49 (86)	53 (93)
ADAF			
Present	0	27 (47) ^{m,o,p}	0
Moderate	0	3 (5) ^{q,r}	0
Mucopurulent material			
Present	33 (58) ⁿ	34 (60)	27 (47) ^c
>Mild	6 (11)	8 (14)	4 (7)
Vocal Cord Collapse			
>Mild	1 (1.8)	20 (35) ^{o,q}	0
	0	7 (12) ^{p,r}	
Harsh or gurgling Respiratory Noise			
	N/A	17 (30) ^{f,k}	N/A
History of Resp. Infection			
	8 (14)	8 (14) ^{h,l}	8 (14)

Key: N/A=not applicable, LF = Laryngeal function, IDDSP = intermittent dorsal displacement of the soft palate, ES = epiglottic structure, PLH = pharyngeal lymphoid hyperplasia, ADAF = axial deviation of the aryepiglottic folds; Superscript letters highlight variable pairs found to have significant differences between groups or where there were significant associations.

Superscript Key:

- (a) A significant difference between the proportion of horses in the pre-exercise group with LF grade >1 compared to the proportion of horses with grade B in the exercise group.
- (b) A significant difference between the proportion of horses in the post-exercise group with LF grade >1 compared to the proportion of horses with grade B in the exercise group.
- (c) A significant association between the presence of mucopurulent material and the occurrence of LF grade >1 in the post-exercise examination.
- (d) A significant association between ES >2 pre-exercise and prolonged or frequent IDDSP pre-exercise.
- (e) A significant association between ES >2 during exercise and prolonged or frequent IDDSP during exercise.
- (f) A significant association between the occurrence of prolonged or frequent IDDSP during exercise and the presence of a harsh or gurgling respiratory noise.
- (g) A significant association between the occurrence of prolonged or frequent IDDSP during exercise and ES score > 2 pre-exercise.
- (h) A significant association between the occurrence of prolonged or frequent IDDSP during exercise and a history of respiratory tract infection.
- (i) A significant association between the presence of IDDSP pre-exercise and ES score >2 pre-exercise.
- (j) A significant association between the presence of IDDSP during exercise and ES score >2 during exercise.
- (k) A significant association between the presence of IDDSP during exercise and a harsh or gurgling respiratory noise.
- (l) A significant association between the presence of IDDSP during exercise and a history of respiratory tract infection.
- (m) A significant association between ES score >2 during exercise and the presence of ADAF during exercise.
- (n) A significant association between ES score >2 pre-exercise and the presence of mucopurulent material at the rima glottis.
- (o) A significant association between the presence of ADAF during exercise and VCC during exercise.
- (p) A significant association between the presence of ADAF during exercise and VCC > mild during exercise.
- (q) A significant association between the presence of moderate ADAF during exercise and VCC during exercise.
- (r) A significant association between the presence of moderate ADAF during exercise and VCC > mild during exercise.

4.2.2 Upper respiratory tract diseases

Laryngeal asymmetry (29 cases) was the most frequent finding identified at rest whilst IDDSP (19 cases) was the most common during exercise. Details of the frequency of occurrence of the most common abnormalities at each examination are shown in Table 4-3.

4.2.2.1 Laryngeal function

Laryngeal function scores varied between examinations and are shown in Table 4-3. Laryngeal function grades were not significantly different between the pre- and post-exercise resting examinations ($P=0.14$). No horse had grade C LF during exercise.

There were significantly more cases of laryngeal asymmetry (\geq grade II.1) at rest both pre- and post-exercise than during exercise (grade B) ($P<0.001$ and $P<0.001$ respectively), whilst the number of cases of asymmetry were not significantly different between the pre- and post-exercise resting examinations ($P=0.52$). There were significantly more cases with LF grades greater than II.1 at rest pre-exercise than there were grade B at exercise ($P=0.008$), but no significant difference between exercise and post-exercise, or between pre and post-exercise.

The presence of “any” mucopus at the rima glottis was observed to be associated with an increased proportion of cases with LF grades \geq II.1 in the post-exercise examinations ($P=0.025$). No other significant associations were identified.

4.2.2.2 Intermittent dorsal displacement of the soft palate

The occurrence of “any” and “significant” IDDSP varied between examinations and are reported in Table 4-3. No significant differences were observed between the occurrence of “any” or “significant” IDDSP between the examinations. Of horses with “significant” IDDSP during exercise, 63% (5/8) had demonstrated either “any” or “significant” IDDSP at rest pre-exercise. As a test for “significant” IDDSP during exercise, “significant” IDDSP at rest pre exercise was 25% sensitive and 94% specific. Positive and negative predictive values were 40%

and 88% respectively, indicating that in this population, resting endoscopy was not a good predictor of the occurrence of IDDSP at exercise.

Pre-exercise the presence of “any” or “significant” IDDSP was significantly associated with ES scores >2 ($P=0.02$ and 0.006 respectively). During exercise the presence of “any” or “significant” IDDSP was also significantly associated with ES scores >2 ($P=0.009$ and 0.007 respectively). Epiglottic structure score >2 pre-exercise was also significantly associated with the occurrence of “significant” IDDSP during exercise.

The presence of “any” or “significant” IDDSP during exercise was significantly associated with a history of URT infection ($P=0.013$ and $P<0.001$ respectively).

4.2.2.3 Epiglottic structure

Grading of ES was based on assessment of epiglottic length, width, flaccidity and the presence or absence of dorsal vasculature and marginal serrations as previously described (Figure 3-5). All grades of ES were observed at each examination, except during exercise, at which no grade 4 was observed. Counts of the ES grades from each examination are shown in Table 4-3.

There were no significant differences in the ES grades or the occurrence of “High” ES grades between the examinations. “High” ES grades pre-exercise were significantly associated with the presence of “significant” IDDSP during exercise ($P=0.03$).

During exercise, “High” ES grades were significantly associated with each of “significant” IDDSP ($P=0.007$) and the presence of ADAF ($P=0.006$).

4.2.2.4 Pharyngeal lymphoid hyperplasia

All horses had some degree of PLH. There were no significant differences between the grades of PLH or the occurrence of “Severe” PLH grades between the examinations.

4.2.2.5 Axial deviation of the aryepiglottic Folds

Axial deviation of the aryepiglottic folds was only observed during exercise and was considered greater than “mild” in three of the 27 cases identified.

The presence of “any” ADAF was significantly associated with: “High” ES score (see above) and both “any” and “greater than mild” VCC (P=0.012 and 0.037 respectively).

The presence of ADAF “greater than mild” was also significantly associated with: “any” and “greater than Mild” VCC (P=0.039 and 0.037 respectively).

4.2.2.6 Vocal cord collapse

A single mild case of VCC was observed at rest pre-exercise and no cases were observed post-exercise. Vocal cord collapse was observed in 20 cases at exercise, of which seven were considered to be greater than “mild” in severity. The condition was observed to be significantly associated with ADAF, see previous.

4.2.2.7 Other findings

Collapse of the apex of the corniculate process was noted during exercise in four horses. This was bilateral in two and unilateral in two horses (one with right sided collapse and the other with left). Cricotracheal ligament collapse (5 cases) and pharyngeal collapse (3 cases) were also observed at exercise.

4.2.3 Mucopurulent material

Mucopurulent material was identified in approximately 50% of videos (range 47 to 60%) and was graded as “moderate to severe” in approximately 10% of videos (range 7 to 14%).

The presence of mucopurulent material was significantly associated with LF grade >1 post-exercise (see previous), and ES Score >2 pre-exercise (see previous).

4.2.4 Abnormal respiratory noise

Abnormal respiratory noises were recorded in 17 cases at exercise. The abnormal noises were reported as: Whistling (1), Gurgling (4) and Harsh (14).

Two horses were noted to make both a harsh and a gurgling respiratory noise. A gurgling or harsh respiratory noise was observed to be significantly associated with “Significant” IDDSP during exercise ($P < 0.001$).

4.2.5 History of upper respiratory tract infection

Eight of the horses had a history of previous URT infection. A significant association between history of respiratory tract infection and occurrence of “any” and “significant” IDDSP was observed (see previous description). No other significant associations were observed.

4.2.6 Complications

Positioning of the endoscope was considered sub-optimal in 11 horses, although the videos were still considered diagnostic by all those viewing the recordings. Hyperaemia of the tip of the epiglottis was observed in three horses and was presumed to be the result of contact with the tip of the insertion tube of the endoscope. A mild, right sided, serous nasal discharge was noted in one horse. One horse tripped during the exercise test and was subsequently lame, the examination was discontinued after four minutes.

4.3 Discussion

Upper respiratory tract endoscopy of TB yearlings was successfully performed with minimal complications. Similar to previously reported findings in adult horses, increased numbers of, and different diseases were identified during exercise compared to those identified at rest (Kannegieter & Dore 1995; Parente et al. 2002; Lane et al. 2006a; Barakzai et al. 2009; Barakzai & Dixon 2011), suggesting that exercising endoscopy is a potentially useful adjunct during the evaluation of URT function in TB yearlings.

This study benefits from access to a population of horses that were all of similar age and stage of training. Performing the examination during the horses' normal training was also a potential benefit, as it removed the need to introduce a new and potentially stressful examination environment or the need for additional travel. Exercising overground endoscopy was extremely well tolerated in most horses and minimal complications occurred. All horses underwent the same exercise test and evaluations of a proportion (20/57) of the horses' heart rates would suggest that adequate exertion was achieved (Rakestraw et al. 1991). Notably, this population of horses were specific to one flat training yard and would have been subject to selection by that individual trainer and may not be representative of the general population. It is also possible that a factor affecting the population examined, such as respiratory tract infection around the time of examination, could have affected the results.

Laryngeal function:

The incidence of laryngeal asymmetry recorded at rest in this study was lower than that previously reported in TB yearlings (Stick et al. 2001; Garrett et al. 2010). All horses in this study had been through the sales process, which may have resulted in selection bias for horses without asymmetry. Not all horses would have undergone endoscopic examination but all would have passed an exercise test and met the conditions of sale as required by the sales company. In contrast to most previous studies, resting examination in this group was performed following removal of the twitch and this may have impacted on the grading of LF, however further investigation into the effect of restraint with a twitch would be required to confirm this. Nasal occlusion was not performed

during the resting examination as this was resented without twitch restraint. It has also been suggested that assessment of laryngeal symmetry following swallowing may be a better assessment of LF during exercise than following nasal occlusion (Parente & Martin 1995).

Horses with laryngeal grade I and II.1 at rest were frequently (48/49), observed to have symmetrical larynges during exercise, whilst, 2 of 8 horses in this study with grade II.2 or grade III.1 laryngeal grade at rest were noted to have laryngeal asymmetry during exercise. Previous studies investigating the association between racing performance resting endoscopic examination of yearlings have shown that horses with grade II.2 and grade III Laryngeal grades subsequently obtain reduced mean total career earnings (Garrett et al. 2010). However, longitudinal studies investigation laryngeal function at rest in foals and juvenile horses, have shown poor consistency between the results of examinations as the horses mature (Anderson et al. 1997; Lane 2003) It is therefore possible that similar change in LF i.e. both improvement and deterioration would be noted in these horses during repeat exercising examinations and this is further discussed in chapter 5.

Intermittent dorsal displacement of the soft palate:

The incidence of IDDSP during exercise in a group of TB yearlings has not previously been reported. In this study the occurrence of “any” or “significant” IDDSP varied between examinations and were found to be significantly associated with ES grade > 2 and a history of URT infection. It was observed that the occurrence of IDDSP at rest had a low positive predictive value (40%) for “significant” IDDSP during exercise, suggesting that resting endoscopy may not be a particularly useful test for this condition.

Whilst every attempt was made to provide a consistent exercise test for all horses in the study, for some, maintenance of a steady canter was difficult, with several horses breaking into a trot on occasion. The effect of this on the incidence of IDDSP is uncertain as the condition is frequently recognised at the end of exercise in adult horses, when if transient, it is often considered to be within normal limits. The condition was therefore categorised and examined as previously described to try to reduce the impact of this.

It is generally accepted that an increased prevalence of IDDSP occurs in TB yearlings compared to adults during resting endoscopic examination (Embertson 1998), however the reason for this is not known. Yearlings with a history of URT infection since arrival on the yard were significantly more likely to have IDDSP than those that did not. This concurs with a recent report of an association between evidence of respiratory tract inflammation and IDDSP (Courouce-Malblanc et al. 2010). This may also support research suggesting that inflammation of the URT can lead to neuromuscular dysfunction leading to airway instability and result in IDDSP (Holcombe et al. 1998). The association between the occurrence of IDDSP in a TB yearling and the occurrence as the horse matures has not been investigated and therefore the true significance of the above-identified disease cannot be established. Longitudinal evaluation during Part II (chapter 5) of this study will further investigate this subject.

Epiglottic structure:

Assessment of ES is considered by some to be an important part of URT examination in TB yearlings (Embertson 1998; Garrett et al. 2010) however the significance of variation in appearance is uncertain. Horses with ES grade >2 have been shown to have lower performance at age 2 and 4 (Garrett et al. 2010), however other studies suggest that epiglottic abnormalities were not significantly associated with racing performance (Stick et al. 2001) and greater tolerance of sub-optimal ES has been suggested (Pierce & Embertson 2001).

Assessment of epiglottic appearance during exercise has only recently been reported (Allen & Franklin 2013b; Kelly et al. 2013). In this study ES grade > 2 either pre- or during exercise was significantly associated with 'significant' IDDSP during exercise. Variation in the appearance of the epiglottis between resting and exercising examinations was noted. It was also observed that on some occasions, prior to the occurrence of IDDSP, apparent flattening of the epiglottis was evident and this is likely to result in increased epiglottic grade at exercise in horses with IDDSP. It is unknown if these subjectively assessed variations in the appearance of the epiglottis reflect true changes in ES or whether they may in fact be the result of alteration in pharyngeal or palatal function. In reality it is unlikely that the physical structure of the epiglottis changes and the author would consider the changes in the appearance of the

epiglottis to be a function of tone of the hyoepiglottidis and dorsal elevation of the soft palate. The use of the term ES in the scientific literature is therefore questionable and reference to the appearance of the epiglottis might be more appropriate. The exact mechanism by which ES would impact on the occurrence of disease is unknown and it has been shown that experimentally induced retroflexion of the epiglottis does not result in IDDSP; therefore questioning the hypothesis that flaccidity or hypoplasia of the epiglottis resulted in IDDSP (Holcombe et al. 1997b).

A high prevalence of VCC and ADAF was identified and ADAF was observed to be associated with high ES grade. The prevalence of both VCC and ADAF was greater than that reported in an adult population (Kannegieter & Dore 1995; King et al. 2001; Parente et al. 2002; Tan et al. 2005; Lane et al. 2006b). The reason for this increased prevalence in a yearling population is uncertain but may reflect greater instability due to poor neuromuscular function. It is also plausible that flaccidity or elevation of the epiglottis would reduce tension on the aryepiglottic fold, resulting in axial deviation.

In conclusion this Part I of this study demonstrates that dynamic endoscopic examination of the TB yearling is a safe and potentially useful diagnostic tool for the assessment of URT function. Differences in the occurrence of abnormalities between rest and exercise were recognised, suggesting that resting endoscopy may not be sufficient to predict URT disease during exercise.

5 Comparison between the results of dynamic endoscopic examination performed in a group of Thoroughbred racehorses as yearlings and as two year olds

5.1 Introduction

Longitudinal studies investigating the dynamic function of the URT are limited to small numbers of adult horses, with LF generally the main focus of examination (Davidson et al. 2007). To the author's knowledge there are no studies presenting the results of serial dynamic URT endoscopic examination of a cohort of juvenile horses. Dynamic pathology such as IDDSP, pharyngeal collapse, VCC and ADAF are frequently identified during dynamic endoscopic examination of the URT in horses, however there is some debate surrounding the significance of these findings in juvenile racehorses, particularly relating to whether spontaneous resolution can occur with maturation and increased fitness (Kelly et al. 2013).

The objective of Part II of this study was to investigate the progression of URT disease as TB yearlings enter and progress through training in a flat training yard in the UK. This was achieved by repeating the examination of horses included in Part I, both in April 2012 when ridden exercise and normal training had commenced and again in October/ November 2012 at the end of the flat racing season. Our hypothesis was that significant improvement in URT function would be identified as horses matured and entered training.

5.2 Results

Of the 57 horses examined in Part I (chapter 4), 45 horses were presented for examination in April 2012 (Exam II), twelve were not examined (table 5-1). Forty two horses were presented in October/November 2012 (Exam III), with 15 of the original 57 not examined (see Table 5-2)

Table 5-1: Horses not examined during Part II, Exam II and reason

Horse	Reason
3	Dead
5	Lame
6	Surgery
8	Entered
18	Lame
20	Lame
28	Sold
44	Surgery
45	Fracture
48	Lame
49	Lame
53	Lame

Table 5-2: Horses not examined during Part II, Exam III and reason

Horse	Reason
1	Fracture
2	Sold
3	Dead
6	Sold
8	Sold
12	Not fit
14	Dead
16	Sold
19	Lame
22	Sold
23	Not fit
28	Not fit
32	Not fit
49	Lame
52	Lame

Only five horses not examined during Exam II were excluded during Exam III, of which only two were excluded for the same reason, one being dead and a second being lame. Thirty five horses were examined on all three occasions.

5.2.1 Heart rates, GPS data and distance galloped

GPS data and distance galloped as decided by the onsite Veterinary Surgeon and the author was recorded for all examinations. During Exam II, 39 horses exercised over three furlongs and six over four furlongs with an average speed of 31.73 MPH (range 24.3 - 37.5). Heart rate was monitored as described in materials and methods using a commercially available surcingle mounted GPS HR monitoring strap. During this examination it was also noted that slipping of the

surcingle frequently occurred and retrospective analysis of this data identified variation in range and multiple obvious inaccuracies. It was considered that this was an inconsistent means of measuring heart rate and thus the technique was discontinued for Exam III.

During Exam III, four horses were exercised over three furlongs, 18 over four furlongs, 17 over six furlongs and three over 10 furlongs. Of the four horses exercising over three furlongs two were recovering from fracture injuries and one from sinus surgery and therefore were not fully fit. Average maximum speed recorded was 32.46MPH (range 26.9-37.5). Heart rate was recorded using telemetric ECG in 23 horses as per Part I and average maximum heart rate was 222bpm (range 200-253).

5.2.2 Complications

No complications were observed during Part II of this study.

5.2.3 Upper respiratory tract disease

The frequency of disease identified during each phase of Exam II (45 horses) and III (42 horses) are shown in tables 5-3 and 5-4 respectively. As in Exam I, laryngeal asymmetry was the most common finding at rest however a decrease in the occurrence of IDDSP was noted both at rest and during exercise.

Table 5-3: Frequency of occurrence of respiratory tract disease during Exam II (42 horses)

	Number Pre-Exercise (%)	Number Exercise (%)	Number Post-Exercise (%)
LF Grade			
I/grade A at exercise	26(58)	42(93)	37(82)
II.1/grade B at exercise	17(38)	2(4)	7(16)
II.2	2(4)	0	1(2)
III.1	0	0	0
LF Grade >1 at rest/grade B at exercise (Asymmetrical)	19(42)	2(4)	8(18)
LF Grade >II.1 at rest/Grade B at exercise (Abnormal)	2(4)	2(4)	1(2)
IDDSP			
Present (Any)	0	3(7)	1(2)
Prolonged or Frequent (Significant)	0	3(7)	0
ES Score			
0	1(2)	0	0
1	20(44)	6(13)	11(24)
2	20(44)	30(67)	30(67)
3	4(9)	9(20)	4(9)
4	0	0	0
ES Score >2 (High)	4(9)	9(20)	4(9)
PLH Grade			
0	0	0	0
1	0	0	0
2	15(33)	18(40)	20(44)
3	26(58)	24(53)	21(47)
4	4(9)	3(7)	4(9)
PLH Grade >2 (Severe)	30(67)	27(60)	25(56)
ADAF			
Present	0	17(38)	0
Moderate	0	1(2)	0
Mucopurulent material			
Present	22(49)	36(80)	17(38)
>Mild	11(24)	9(20)	7(16)
Vocal Cord Collapse			
>Mild	0	22(49)	0
	0	0	0
Respiratory Noise			
Harsh or gurgling	0	3(7)	0
Whistling	0	2(4)	0
History of Resp. Infection	3(7)	3(7)	3(7)

Key: LF = Laryngeal function; IDDSP = intermittent dorsal displacement of the soft palate, ES = epiglottic structure, PLH = pharyngeal lymphoid hyperplasia, ADAF = axial deviation of the aryepiglottic folds

Table 5-4: Frequency of occurrence of respiratory tract disease during Exam III (45 horses)

	Number Pre-Exercise (%)	Number Exercise (%)	Number Post-Exercise (%)
LF Grade			
I/grade A at exercise	20(48)	40(95)	25(60)
II.1/grade B at exercise	17(40)	2(6)	12(29)
II.2	4(1 rt side)(10)	0	4(10)
III.1	0	0	1(2)
LF Grade >1 at rest/grade B at exercise (Asymmetrical)	22(52)	0	17(40)
LF Grade >II.1 at rest/Grade B at exercise (Abnormal)	5(12)	2(6)	5(12)
IDDSP			
Present (Any)	0	4(10)	0
Prolonged or Frequent (Significant)	0	3(7)	0
ES Score			
0	3(7)	0	1(2)
1	30(71)	17(40)	17(40)
2	9(21)	21(50)	22(52)
3	0	4(10)	2(6)
4	0	0	0
ES Score >2 (High)	0	4(10)	2(6)
PLH Grade			
0	0	0	0
1	7(17)	6(14)	4(10)
2	21(50)	26(62)	27(64)
3	12(28)	8(19)	9(21)
4	2(6)	2(6)	2(6)
PLH Grade >2 (Severe)	14(33)	10(24)	11(26)
ADAF			
Present	0	19(45)	0
Moderate		4(10)	0
Mucopurulent material			
Present	14(33)	15(36)	17(40)
>Mild	6(14)	5(12)	3(7)
Vocal Cord Collapse			
>Mild	0	18(43)	0
		0	0
Harsh or gurgling Respiratory Noise	0	3(7)	0
History of Resp. Infection	0	0	0

Key: LF = Laryngeal function; IDDSP = intermittent dorsal displacement of the soft palate, ES = epiglottic structure, PLH = pharyngeal lymphoid hyperplasia, ADAF = axial deviation of the aryepiglottic folds

Table 5-5: Frequency of occurrence of respiratory tract disease during Exams I, II and III (35 horses)

Exam No.	Number Pre-Exercise (%)			Number Exercise (%)			Number Post-Exercise (%)		
	Exam			Exam			Exam		
	I	II	III	I	II	III	I	II	III
LF Grade I/grade A at exercise:	16(46)	20(57)	18(51)	35	33(94)	33(94)	21(60)	29(83)	21(60)
II.1/grade B at exercise:	16(46)	15(42)	14(40)	0	2(6)	2(6)	12(34)	5(14)	9(26)
II.2	2(6)	0	3(9)				2(6)	1(3)	4(11)
III.1	1(3)	0	0				0	0	1(3)
LF grade >1 at rest/grade B at exercise (Asymmetrical):	19(54)	15(43)	17(49)	0	2(6)	2(6)	14(40)	6(17)	14(40)
LF Grade >II.1 at rest/Grade B at exercise (Abnormal):	3(9)	0	3(9)	0	0	0	2(6)	1(3)	5(14)
IDDSP Present (Any):	8(22)	0	0	11(31)	3(9)	3(9)	6(17)	0	0
Prolonged or Frequent (Significant)	3(9)	0	0	5(14)	3(9)	2(6)	2(6)	0	0
ES Score 0	7(20)	1(3)	3(9)	5(14)	0	0	11(31)	0	1(3)
1	13(37)	17(48)	25(71)	15(43)	5(14)	14(40)	11(31)	10(29)	14(40)
2	11(31)	14(40)	7(20)	9(26)	22(63)	17(48)	6(17)	21(60)	18(51)
3	3(9)	3(9)	0	6(17)	8(23)	4(11)	7(20)	4(11)	2(6)
4	1(3)	0	0	0	0	0	0	0	0
ES Score >2 (High)	4(11)	3(9)	0	6(17)	8(23)	4(11)	7(20)	4(11)	2(6)
PLH Grade 1	0	0	7(20)	1(3)	0	4(11)	0	0	3(9)
2	5(14)	12(34)	15(43)	3(9)	16(46)	22(63)	2(6)	16(46)	22(63)
3	14(40)	20(57)	11(31)	12(34)	17(49)	7(20)	10(29)	16(46)	8(23)
4	16(46)	3(9)	2(6)	19(54)	2(6)	2(6)	23(66)	3(9)	2(6)
PLH Grade >2 (Severe)	30(86)	23(66)	13(37)	31(89)	19(54)	9(26)	33(94)	19(54)	10(29)
ADAF Present Moderate				18(51) 3(9)	14(40) 1(3)	21(60) 4(11)			
Mucopurulent material Present >Mild	20(57) 4(11)	18(51) 9(26)	14(40) 6(17)	24(69) 7(20)	28(80) 8(23)	17(49) 5(14)	19(54) 4(11)	13(37) 6(17)	15(43) 3(9)
Vocal Cord Collapse >Mild				14(40) 7(20)	20(57) 0	18(51) 0			

Key: LF = Laryngeal function; IDDSP = intermittent dorsal displacement of the soft palate, ES = epiglottic structure, PLH = pharyngeal lymphoid hyperplasia, ADAF = axial deviation of the aryepiglottic folds

5.2.4 Variation in the occurrence of disease between 35 horses examined on all three occasions and association between conditions

Statistical analysis of the variation in the occurrence of disease was performed between the 35 horses examined on all three occasions during this study. The results of each examination are summarised in table 5-5.

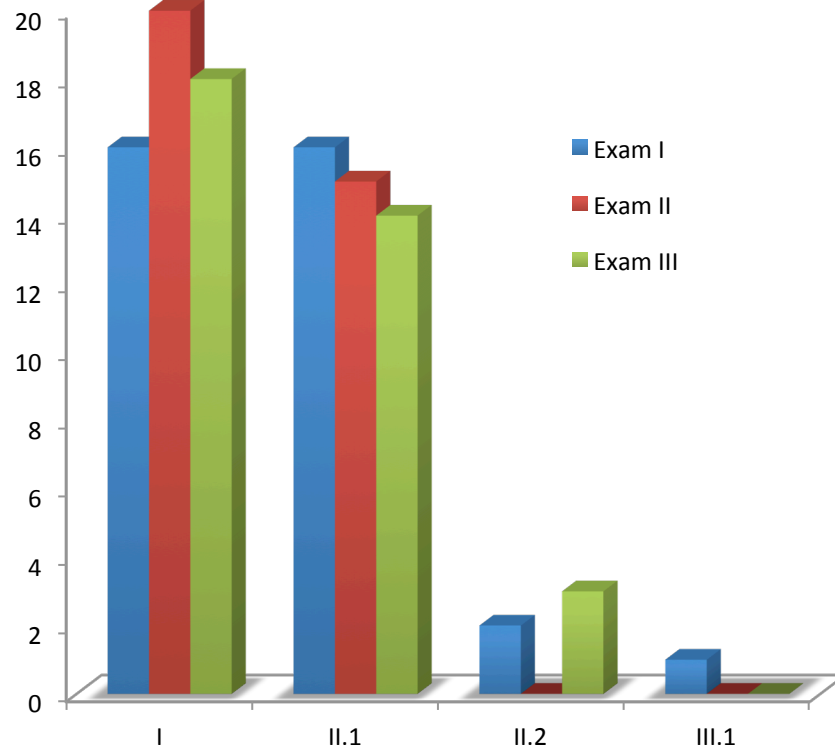
5.2.4.1 Laryngeal function

Laryngeal function grades varied between all three exams and are shown in table 5-5.

During Exam I, 19 horses were identified with asymmetrical LF at rest pre exercise. Of these, 15 were identified with laryngeal asymmetry during a later examination, seven during both Exams II and III, three during Exam II only and five during Exam III only. None of the 35 horses examined on three occasions had asymmetrical LF during exercise in Exam I. Two horses were identified with grade B LF during Exam II one of which had grade B LF during exam III.

There was no significant difference in the occurrence of grades of LF or of “asymmetrical” or “abnormal” LF between examinations at rest pre-exercise or during exercise in the 35 horses examined on all three occasions.

Figure 5-1: Graphic showing number of horses with each LF grade pre-exercise in each Exam



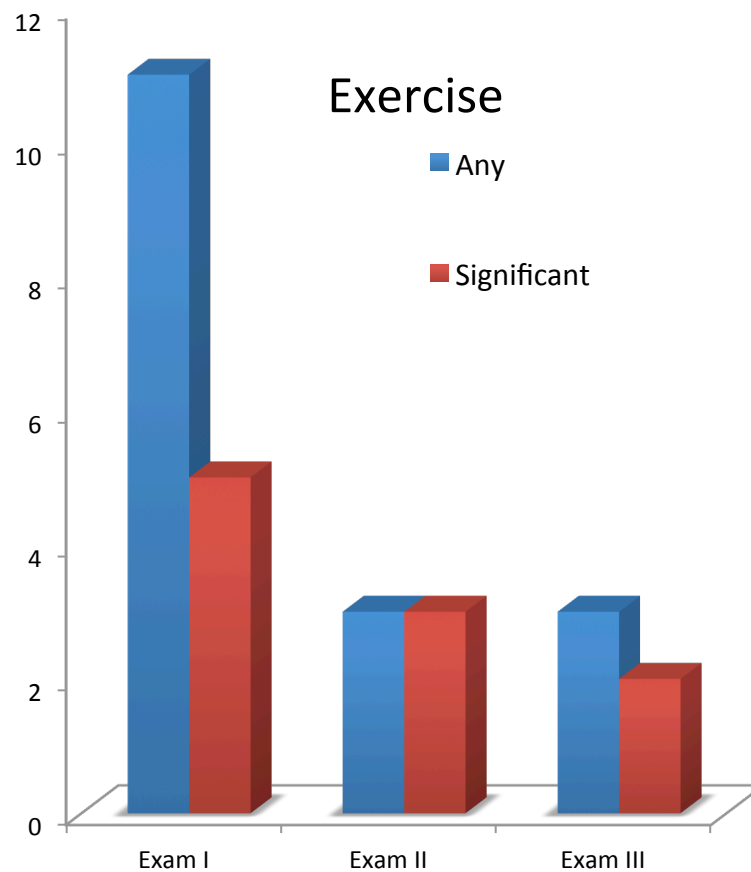
5.2.4.2 Intermittent dorsal displacement of the soft palate

The occurrence of “any” and “significant” IDDSP varied between examinations and is shown in table 5-5.

During Exam I, 22% and 17% of horses were identified with IDDSP at rest pre and post exercise respectively. No horse was identified with IDDSP during the resting phases of exams II or III

During exercise three horses in Exam II were identified with “significant” IDDSP none of which were noted to have “any” IDDSP during exercise in Exam I and only one had “any” IDDSP during Exam III. A significant difference between the occurrence of “any” IDDSP was noted during exercise between Exam I and III ($p=0.04$) with more cases observed in Exam I. No other significant variation was noted.

Figure 5-2: Graphic showing number of horses with “any” and “significant” IDDSP in each Exam.

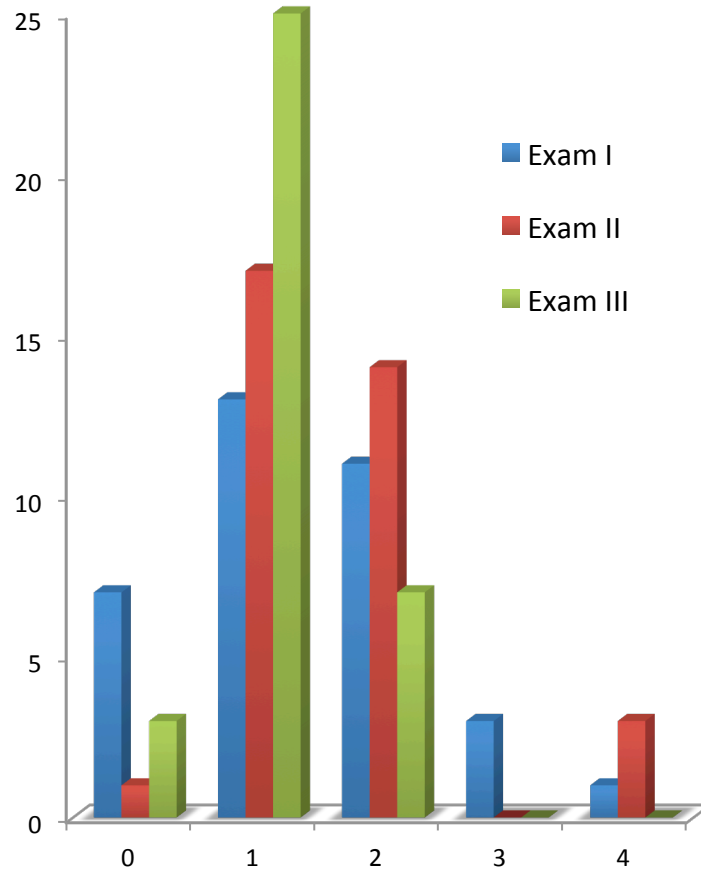


5.2.4.3 Epiglottic structure

Epiglottic structure grades pre exercise varied between examinations as shown in table 5-5. Sixteen horses had an ES grade that was lower in Exam III than Exam I, 9 the same grade and 10 had a higher grade.

There was a significant difference between ES grades pre-exercise during exam II and III ($p=0.0039$) with no horse having ES grade >2 during Exam III, however no significant variation was noted between the occurrences of “High” ES grades between any examinations at rest pre-exercise.

Figure 5-3: Graphic showing number of horses with a each grade of ES at rest pre exercise in each Exam



5.2.4.4 Pharyngeal Lymphoid hyperplasia

Pharyngeal lymphoid hyperplasia grades are shown in table 5-5. Severe PLH grades were recorded in 86%, 66% and 37% of horses during Exams I, II and III respectively at rest pre-exercise. Only one horse had a PLH grade greater in Exam I than Exam III and 27 had a lower grade.

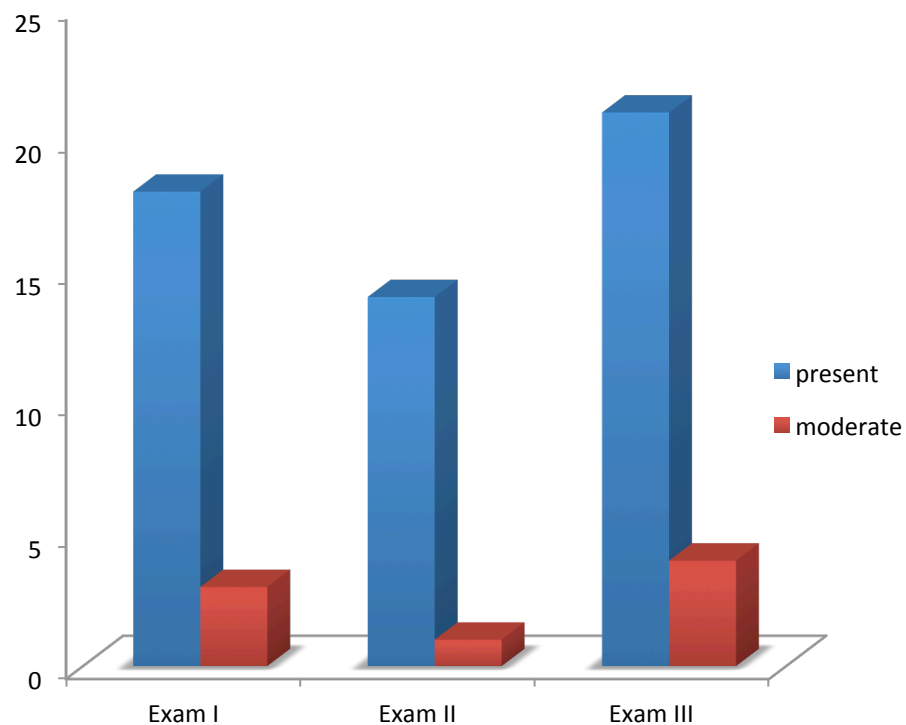
Significant variation in PLH grade pre-exercise was identified between Exams I and II ($p=0.0003$), I and III ($p=0$) and II and III ($p=0.0021$). Significant variation in “severe” PLH grade was noted between Exam I and II ($p=0.04$) I and III ($p=0$) and II and III ($p=0.01$). In all cases the grade or severity of PLH was lower in the later Exam.

5.2.4.5 Axial deviation of the aryepiglottic folds

The occurrence and grade of ADAF during exercise is shown in table 5-5. Of the 18 horses identified with any ADAF in Exam I, the disorder was not identified at a second examination in six.

No significant variation was noted between examinations when assessing the presence of ADAF. Significant variation in the grade of ADAF was identified between Exams II and III ($p=0.01$) with more horses identified with ADAF greater than mild during exam III(4) than exam II(1).

Figure 5-4: Graphic showing number of horses with each grade of axial deviation of the aryepiglottic folds in each Exam

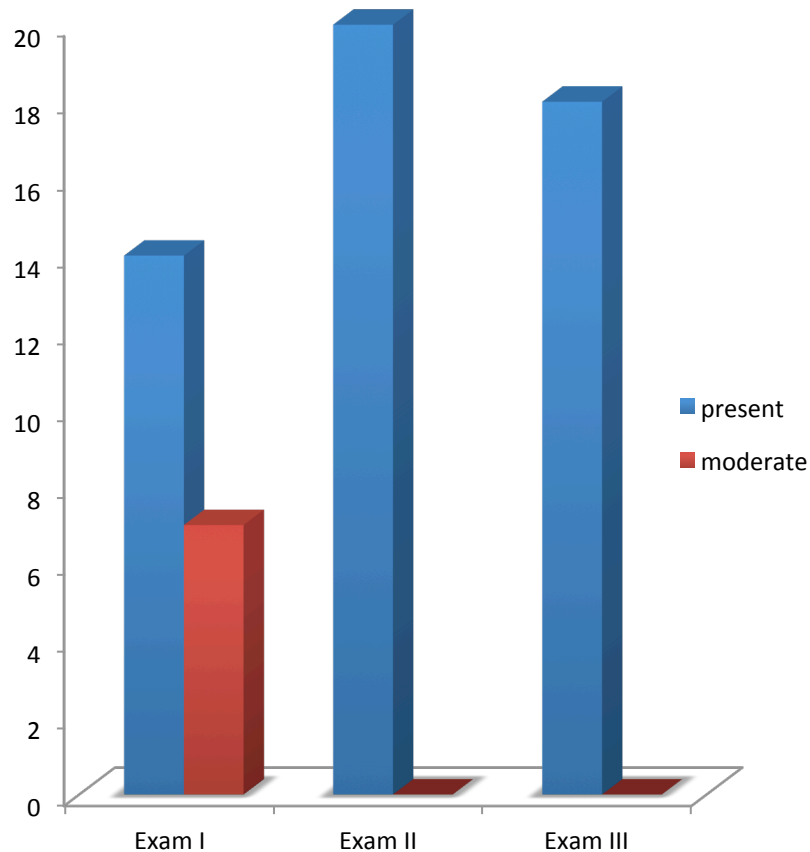


5.2.4.6 Vocal cord collapse

The prevalence of VCC for each examination is shown in table 5-5. Of the 18 horses with VCC in Exam III, all were graded mild and 14 had VCC identified at a previous examination, 8 in Exam I, 12 in Exam II and 5 in both Exam I and II. No significant variation was noted between the grades or the occurrence of “any” VCC between the examinations. No horse had VCC greater than mild in Exam II

or III and therefore significant variation in the occurrence of VCC greater than mild was noted between Exam I and II ($p=0.016$) and Exam I and III ($p=0.016$).

Figure 5-5: Graphic showing number of horses with each grade of VCC in each Exam



5.2.4.7 Other findings

Dynamic pharyngeal collapse was identified in two of the 35 horses examined on all three occasions during Exam I and again in one of these individual horses in Exam II and III. Resolution was noted in the horse with dorsal collapse but not in the case of the more severe lateral collapse.

Only one horse with ventroaxial collapse of the apex of the corniculate process was examined on all three occasions. This horse had bilateral collapse and this persisted throughout the period of the study.

Dynamic ventro-rostral displacement of the dorsal laryngeal mucosa was identified in one horse in Exam I that was examined on both subsequent occasions during which no disease was noted.

Cricotracheal ligament collapse was noted in four horses during Exam I, and collapse was not identified in any of these horses during Exam II or III.

5.2.5 Results of analysis when all horses from each Exam were included.

In this section the result of all 57 horses from Exam I, 42 from Exam II and 45 from Exam III are presented. Differences between the outcomes of analysis are highlighted.

5.2.5.1 Laryngeal function

Of the three horses with Grade B LF grade during exercise in Exam I, all were examined dynamically at one subsequent examination (two in Exam II and one in Exam III) and symmetrical LF was identified in all three horses. Two horses had grade B LF in Exam III, only one of which had asymmetry at a previous exam. Inclusion of all horses in the statistical model as for the 35 horses described above did not result in any statistically significant findings.

5.2.5.2 Intermittent dorsal displacement of the soft palate

Of the 8 horses with “significant” IDDSP identified during exercise in Part I of the study six had a repeat dynamic exercise endoscopy on at least one occasion. None of these horses were diagnosed with “significant” IDDSP during a subsequent exam. Three horses were diagnosed with “significant” IDDSP during Exam III only one of which had “any” IDDSP during Exam II.

When included in the statistical model a significant difference between the occurrence of “any” IDDSP was noted between both Exams I and II ($p=0.007$) but not between Exams II and III ($p=0.057$). This is the reverse of the findings when only 35 horses are included. There was also a significant difference between the occurrence of “significant” IDDSP between Exams I and II ($p=0.03$).

5.2.5.3 Epiglottic Structure

Statistical analysis performed when all horses were included did not significantly alter the results. A significant difference between Exam II and III was again identified ($p=0.004$). Of the three horses with “significant” IDDSP during Exam III none had ES grade >2 pre exercise.

5.2.5.4 Pharyngeal lymphoid hyperplasia

When all horses were included in the statistical analysis, there was no significant variation in ‘severe’ PLH pre exercise between Exams I and II. Significant variation was noted between all other exams for both grade and ‘severity’ of PLH.

5.2.5.5 Axial deviation of the aryepiglottic folds

Axial deviation considered greater than mild was identified in three, one and four horses during Exams I, II and III respectively. Two of the three horses with ‘moderate’ ADAF in Exam I had ADAF identified at a subsequent examination and all the horses with ‘moderate’ ADAF in Exam III had ADAF at a previous examination of which one was considered moderate. When all horses were included the only significant difference was again between Exam II and III with the grade of ADAF being greater in Exam III.

5.2.5.6 Vocal cord collapse

Seven horses had VCC greater than mild in Exam I and all of these horses had VCC identified at a subsequent examination, 5 of which had VCC in Exam III. However only three had three examinations. There was no difference in the statistically significant results of analysis when all horses were included or when the 35 horses examined on all three occasions were included.

5.2.5.7 Other findings

Of the three horses with Dynamic pharyngeal collapse in Exam I, two were examined on a further occasion (see 35 horses above) and resolution of disease was noted in the horse with dorsal collapse. One horse that did not have

pharyngeal collapse in Exam I did have collapse in Exam II but this horse was not subsequently examined.

Of the four horses identified with ventroaxial collapse of the apex of the corniculate process in Part I, disease was again identified in the two cases with bilateral collapse in a subsequent exam. Resolution of disease was noted in the two cases of unilateral collapse.

Epiglottic entrapment was identified in one horse in Exam I but this horse was not subsequently examined due to lameness. One horse had Epiglottic entrapment during Exam II but this did not occur during Exam III.

5.2.6 Associations between findings

When investigating the associations between pathologies in Part II, all horses examined during each examination were included.

No significant associations were identified between LF and any other pathology. Significant associations were identified between the occurrence VCC “greater than mild” and “moderate” ADAF ($p=0.048$). Axial deviation of the aryepiglottic folds was significantly associated with each of “significant” IDDSP ($p=0.023$) and “high” ES grade ($p=0.04$). “Significant” IDDSP was associated with “high” ES grade at rest pre exercise ($p=0.03$).

5.3 Discussion

This study presents the results of longitudinal dynamic endoscopic examination of a group of TB yearlings and demonstrates variation in the occurrence of disease of the URT as horses mature and enter training.

As in part I, this study benefits from access to a population of horses managed and trained in a similar manner. It is possible that some bias existed with some horses being removed from the study group or unavailable for examination, however this was thought to have limited impact on the conclusions of the study. Some of the horses that were removed were considered to be the better horses in the yard and theoretically least likely to have performance limiting disease.

Some variation in the level of fitness and the amount of work done by each horse prior to the examination was inevitable in this study, however only three horses that were exercised over three furlongs in exam III had a degree of fitness that was considered less than the others in the cohort as they were returning from injury.

It has been suggested that dynamic overground endoscopy, when compared to treadmill examination may be less sensitive for the diagnosis of pathology due to decreased intensity of the overground exercise test. However exercising a juvenile horse to exhaustion could result in significant injury and impair the horse's ability to train. Also this population of horses could be difficult to examine on a treadmill due to temperament and trainer/owner consent for such an examination would be difficult to obtain. All horses were exercised at intensity greater than that of normal training and analysis of the max HR achieved during Exam III would support this (Rakestraw et al. 1991). Use of a commercially available HR monitor during Exam II was not considered reliable, however given the horses exercise levels at that time it was considered that the degree of exertion achieved was similar to Exam III.

Laryngeal function:

Variation in the appearance and grading of LF at rest and during exercise between Exams I, II and III was observed in this study. Inter-observer and intra-horse variation in the grading or appearance of LF at rest has been previously described (Hackett et al. 1991; Perkins et al. 2009) and longitudinal studies investigating the grading of LF in juvenile horses have shown considerable inconsistency (Anderson et al. 1997; Lane 2003).

Variation in the appearance of LF was also noted during exercise and this has not previously been reported. Three of the 57 horses examined in Part I had grade B LF during exercise. These horses had only one subsequent exam but in each case LF was considered symmetrical (grade A). One of the two horses in Exam II with grade B LF had symmetrical movement in Exam III. This may indicate that in young horses assessment of LF during exercise is prone to limitations, as at rest. In this study inter-observer variability was not examined but a consensus grading following independent blinded review was achieved for each examination to minimise the impact of such variance. If observer variability is not considered a factor, the mechanism behind such intra-horse variability is uncertain. It may be a result of normal variation in muscular activity or could possibly be due to re-innervation of the CAD muscle (Duncan et al. 1974; Anderson et al. 1997)

Intermittent dorsal displacement of the soft palate:

The prevalence of IDDSP varied between examinations both at rest and during exercise. No horse was identified with IDDSP at rest during Exams II or III. This is in agreement with suggestions by other authors that the prevalence of IDDSP at rest in yearlings is greater than adult horses and is not predictive of future disease (Embertson 1998; Stick et al. 2001).

Significant variation in the occurrence of “significant” IDDSP during exercise was identified between Exams I and II when all horses were included in the model but not when only the 35 horses examined on all three occasions were included. This was most likely due to the small number of horses with pathology in exams II and III. However, no horse with “any” or “significant” IDDSP during exercise in Exam I had “any” or “significant” IDDSP during Exam II and only one had “any”

IDDSP during Exam III. This would suggest that the occurrence of IDDSP during exercise examination in a TB yearling is not a good indicator of future disease. The potential impact of lunging exercise on the occurrence of IDDSP in Exam I was discussed in chapter 4; however previous authors have shown that lunging exercise is more likely to result in a false negative than false positive diagnosis (Franklin et al. 2008). The use of a bit in juvenile horses can be resented and they are frequently noted to 'play with the bit'. This may disrupt the lip seal and allow increased pressure within the oropharynx. This theory is not supported by any direct scientific evidence but likewise it cannot be entirely refuted. In the yearlings used in this study, the lunge line was attached to the bit and if the above theory were to hold this may indeed have further disrupted the seal and altered pressures within the oropharynx leading to elevation of the soft palate and disruption of the ostium intrapharyngium (Cook 2002).

Resolution of pathology in a proportion of two and three year old horses with IDDSP has been reported (Kelly et al. 2013) and this study would also indicate that improvement in pharyngeal function does occur as horses mature and attain increased fitness.

Dysphagia due to disruption of the pharyngeal phase of swallowing is described in foals and the condition is considered similar to that observed in neonates of other species (Ducharme 2012; Holcombe et al. 2012). In human beings the exact aetiopathogenesis is often uncertain but recovery frequently occurs (Kohda et al. 1994). Morphological abnormalities of the innervation of the larynx and pharynx that resolve with age have been noted in human infants and it has been speculated that such abnormalities may occur in horses (Ducharme 2012). It could also be hypothesised that pharyngeal disorders noted during respiration may also be a result of immaturity of the innervation of the pharynx and therefore a reduction in the prevalence of respiratory disorders such as IDDSP could be expected with increasing age.

Epiglottic structure:

Variation in ES grades was noted between examination and a significant variation was noted between Exam II and III with a trend for decreasing ES grade between examinations. It has been suggested that higher ES grades (shorter flaccid

epiglottis) could be considered normal in yearlings (Stick et al. 2001) and from the results of this study there is evidence to suggest that the appearance of ES improves with age and fitness. An association between “high” ES grade and “significant” IDDSP was noted, however this is most likely due to the results of Exam I, as no horse in Exam II or III with “any” or “significant” IDDSP had a “high” ES grade during that Exam. As discussed in Chapter 2, contradictory reports describing the impact of ES grade on future performance exist (Embertson 1998; Pierce & Embertson 2001; Stick et al. 2001; Garrett et al. 2010). The results of this study would suggest that while assessment of ES grade in yearlings may be associated with dynamic pathology at that time, it is not a good predictor of the occurrence of disease as the horse matures.

The appearance of the epiglottis varied throughout the dynamic part of the examination and therefore applying an accurate grade was very difficult and statistical analysis was not used to examine correlations between exercising grades in Part II of the study. The assessment of ES or epiglottic conformation during exercise has recently been reported in a second paper and an association with IDDSP described (Allen & Franklin 2013b). In that paper the authors assessed the conformation of the epiglottis over the last 10 seconds of the exercise test or in the 10 seconds prior to DDSP. This study therefore selects a specific time point that is either directly related to the presence or absence of disease. As previously mentioned the appearance of the epiglottis changes during exercise and therefore this author is of the opinion that this creates significant bias and is a method that would not be applicable in a survey of potentially normal horses.

Other findings:

The grade of PLH reduced as horses matured and entered training. This finding is consistent with previous reports and with the author’s personal experience. It would also suggest that the assessment of PLH during yearling endoscopy is of little future relevance. Association between PLH and respiratory infection was noted in Part I of this study but an association in older horses is debatable (Auer et al. 1985, Koblinger et al. 2011) and no conclusion can be made from this study due to the fact that no horses with overt respiratory infection were presented for either Exam II or III and no significant association was identified between the

presence of mucus at the rima glottis and PLH. However it is possible that the reduction in PLH grade represents a decreased prevalence of infection or environmental challenge in these horses. It has also been hypothesised that inflammation may impact on the pharyngeal branch of the vagus nerve (Holcombe et al. 1998) and therefore resolution may result in a decrease in associated pathology such as IDDSP, however the true impact of this finding on airway dynamics is unproven and no association between the severity of PLH and the presence of disease was noted in Part II of this study.

Axial deviation of the aryepiglottic fold grades varied between examinations and they were associated with “high” ES grade at rest pre exercise and “any” or “significant” IDDSP during exercise. Grading of the degree of deviation is subjective, however there was good consistency in the diagnosis of and therefore presumably the persistence of ADAF between exams. This would suggest that if ADAF is present during dynamic examination in a TB yearling it may persist into its two year old season. There was a strong association between ADAF and IDDSP. In all cases of “any” or “significant” IDDSP in Exam III, ADAF was identified during that Exam and at least one previous Exam. As discussed in chapter 4, elevation of the epiglottis prior to displacement of the soft palate would explain these associations with ADAF. The association between ADAF and “high” ES grade was noted throughout the study and all horse with a “high” ES grade in Exam II (no horse had a high ES grade in exam III) had ADAF at that exam, however obviously not all horses with ADAF had a “high” ES grade at rest pre-exercise. This would suggest that ES has an impact on stability of the aryepiglottic folds.

As the aryepiglottic folds do not have a muscular component, the association between VCC and ADAF is unlikely to have a combined specific neuromuscular pathogenesis and this association may be explained by an alteration in flow dynamics in the URT. The severity of VCC in this population decreased as horses matured and fitness increased. The greater prevalence of VCC in this population of horses when compared to other studies is likely explained by the age profile and it is likely that a reduction would be noted as horses mature further (Lane et al. 2006b) and this could be explained by improved function of the cricothyroid muscle or its innervation. It is interesting that 14 out of the 18 horses with VCC

during Exam III had disease noted at a previous examination and this does demonstrate persistence of the disease into the horses racing career.

Collapse of the apex of the corniculate process was identified in four horses in part I, two bilateral and two unilateral. Each of the horses with unilateral collapse were examined on one further occasion only, at which time no pathology was noted. Of the horses bilaterally affected, one was examined twice with pathology identified on both examinations and one once, at which time pathology was also noted. The true effect of this pathology on airway dynamics is uncertain but if bilateral disease is identified in juveniles it is reasonable to assume that it is likely to persist. Pharyngeal collapse is a performance limiting disease and in this study, persistence of disease was identified in a horse with what was considered significant collapse of the lateral pharyngeal walls. No subsequent abnormalities were identified in both cases of mild dorsal collapse. This may indicate that significant collapse can persist and could be performance limiting, whereas mild dorsal collapse, as is more frequently seen in combination with other evidence of pharyngeal dysfunction such as palatal instability or IDDSP may resolve.

Cricotracheal ligament collapse was noted in five horses in Part I and was not identified in these horses at a subsequent examination. This would support previous studies that have reported resolution of this pathology in a proportion of younger horses (Kelly & Pollock 2015).

In conclusion, this study would suggest that intra horse variability in the appearance of laryngeal function occurs during exercise and that a reduction in the occurrence and severity of many pathologies but most notably IDDSP occurs as horses mature and enter training. This information should be considered when interpreting the results of dynamic endoscopic examination of juvenile horses presenting for clinical evaluation.

6 General discussion

This is the first study that prospectively investigates our ability to predict future airway function in TB yearlings using resting and dynamic endoscopic evaluation and it is clear that dynamic endoscopic examination of the URT does increase our ability to definitively identify disease.

The overall aim of this study was to test the hypothesis that dynamic examination of the upper portion of the URT of the TB yearling could be used to more accurately predict which animals would subsequently develop significant and potentially performance limiting disease. While this study contributes to the literature and our knowledge base it is also apparent that further investigation is required before this hypothesis can be definitively proven.

Dynamic endoscopic examination of the TB yearling had not previously been described and this study demonstrates that this diagnostic technique can be applied safely and with minimal complication during examination of the TB yearling. Part I of this study also demonstrated significant variation between the results of resting and dynamic examination and that increased numbers of, and different pathologies were identified during exercise. No study has previously investigated the prevalence of IDDSP during exercise in TB yearlings, however it was thought to be higher than that of the general population (Embertson 1998). This study effectively demonstrates a higher prevalence within a population of yearlings, during both resting and dynamic examination.

The findings of Part II of this study support those presented by previous authors suggesting that the grade of LF at rest changes as horses mature, with both improvement and deterioration noted (Anderson et al. 1997; Havemeyer 2004). It is also evident from this study that laryngeal symmetry during exercise varies between examinations and it is therefore suggested that observation of mild laryngeal asymmetry in a yearling is not definitively predictive for the presence of laryngeal asymmetry as the horse matures. It was also recognised that there was poor association between the occurrence of IDDSP at rest and during exercise and that the results of dynamic examinations of juvenile horses were poorly predictive for the presence of IDDSP as horses mature and enter training. Contradictory evidence surrounding the significance of variation in epiglottic

appearance is reported (Stick et al. 2001; Garrett et al. 2010) and the published grading scale is also not universally accepted as variation in the appearance of the epiglottis is reported (Estes 2010). A non-significant trend for decreasing ES grade as horses mature was observed and a correlation between IDDSP and ES grade was noted in the yearling population but this was not recognised in subsequent examinations. The results of this study would therefore support evidence that ES grade is not predictive for future disorders of the URT.

This study also provides potentially useful information for clinicians observing or investigating respiratory noise in juvenile horses. Gurgling or swallowing is frequently reported in yearlings during exercise and based on the evidence presented in Part I of this study; the occurrence of IDDSP is likely. A high prevalence of VCC and ADAF is to be expected in TB yearlings and the results of this study indicate that this is likely to persist as the horse enters racing but is likely to be mild and therefore probably has minimal effect on airway function. The author has also examined TB yearlings outside this study presenting for investigation of abnormal respiratory noise during exercise with no significant disorders identified during resting endoscopy and dynamic abnormalities such as pharyngeal collapse and collapse of the apex of the corniculate process were diagnosed during dynamic examination. The results of this study indicate a relatively high prevalence of collapse of the apex of the corniculate processes and that when this condition is present bilaterally; persistence of the condition is likely. Pharyngeal collapse does vary markedly in severity and in the one case in this study where collapse was identified during all three examinations, pathology was considered moderate. This would suggest, as is the author's experience, that in cases of moderate to severe collapse, the condition may be persistent.

This study also highlights with great clarity a large number of areas that warrant further investigation. The author has identified significant changes and variability in the function of the URT, however our understanding of the anatomical and physiological function and development of the URT is very limited. This knowledge gap needs to be addressed. Endoscopic examination of the pharynx and larynx is an indirect assessment of abnormalities of the extraluminal pharyngeal and laryngeal musculature. Ultrasonographic examination could provide additional useful information regarding position of

the laryngohyoid apparatus and echogenicity of the laryngeal musculature (Chalmers et al. 2006, Chalmers et al. 2009b). Correlation between the results of ultrasonographic examination of the pharynx and larynx and the result of endoscopy has been described but not in TB yearlings. This is a readily accessible imaging modality and future studies should combine dynamic endoscopic and ultrasonographic examination that may provide additional information to better aid in predicting the progression of disease.

The volume of surgical intervention performed with limited evidence is a potential welfare and financial concern for the racing industry and advancing our understanding of the pathophysiology and prevalence of disease is essential. Our ability to identify and predict the progression of disease is core to this objective and this study adds to that knowledge base.

In conclusion, this study does demonstrate that overground endoscopic examination is a valid diagnostic technique and can be used in yearlings presenting for investigation of URT Disease. Significant avenues for further research have been identified and weakness in the current method for evaluating TB yearlings has been further highlighted. The results of this prospective longitudinal study demonstrate that the prevalence of disease within different age groups varies, that improvement in airway function occurs as horses mature and that the prevalence of disease such as IDDSP decreases.

References

- Ainsworth, D.M. & Hackett, R.P., 2004. *Equine internal medicine* 2nd ed. S. M. Reed, W. M. Bayly, & D. C. Sellon, eds., St Louis: Saunders, pp. 289-343
- Allen, K. & Franklin, S., 2013a. The effect of palatal dysfunction on measures of ventilation and gas exchange in Thoroughbred racehorses during high intensity exercise. *Equine Veterinary Journal*, 45(3), pp.350-54.
- Allen, K. & Franklin, S., 2013b. Characteristics of palatal instability in Thoroughbred racehorses and their association with the development of dorsal displacement of the soft palate. *Equine Veterinary Journal*, 45(4), pp.454-59.
- Allen, K.J. & Franklin, S.H., 2010a. Assessment of the exercise tests used during overground endoscopy in UK Thoroughbred racehorses and how these may affect the diagnosis of dynamic upper respiratory tract obstructions. *Equine Veterinary Journal*, 42 (Suppl 3), pp.587-91.
- Allen, K.J. & Franklin, S.H., 2010b. Comparisons of overground endoscopy and treadmill endoscopy in UK Thoroughbred racehorses. *Equine Veterinary Journal*, 42(3), pp.186-91.
- Anderson, B.H., Kannegieter, N.J. & Goulden, B.E., 1997. Endoscopic observations on laryngeal symmetry and movements in young racing horses. *New Zealand veterinary Journal*, 45(5), pp.188-92.
- Auer, D.E., Wilson, R.G. & Groenendyk, S., 1985. Pharyngeal lymphoid hyperplasia in Thoroughbred racehorses in training. *Australian veterinary Journal*, 62(4), pp.124-26.
- Barakzai, S.Z. et al., 2007. Ventroaxial luxation of the apex of the corniculate process of the arytenoid cartilage in resting horses during induced swallowing or nasal occlusion. *Veterinary Surgery*, 36(3), pp.210-13.
- Barakzai, S.Z. & Dixon, P.M., 2005. Conservative treatment for Thoroughbred racehorses with intermittent dorsal displacement of the soft palate. *Veterinary record*, 157(12), pp. 337-40

- Barakzai, S.Z. & Dixon, P.M., 2011. Correlation of resting and exercising endoscopic findings for horses with dynamic laryngeal collapse and palatal dysfunction. *Equine veterinary journal*, 43(1), pp.18-23.
- Barakzai, S.Z., Finnegan, C. & Boden, L.A., 2009. Effect of “tongue tie” use on racing performance of Thoroughbreds in the United Kingdom. *Equine Veterinary Journal*, 41(8), pp.812-16.
- Barakzai, S.Z. & Hawkes, C.S., 2010. Dorsal displacement of the soft palate and palatal instability. *Equine Veterinary Education*, 22(5), pp.253-64.
- Boyko, A.R. et al., 2014. Genomic analysis establishes correlation between growth and laryngeal neuropathy in Thoroughbreds. *BMC Genomics*, 15(1), p.259.
- Boyle, A.G. et al., 2006. Dynamic pharyngeal collapse in racehorses. *Equine Veterinary Journal Supplement*, 36(36), pp.546-50.
- Brakenhoff, J.E. et al., 2006. The prevalence of laryngeal disease in a large population of competition draft horses. *Veterinary Surgery*, 35(6), pp.579-83.
- Brown, J.A. et al., 2005. Prevalence of pharyngeal and laryngeal abnormalities in Thoroughbreds racing in Australia, and their association with performance. *Equine Veterinary Journal*, 37(5), pp.397-401.
- Cahill, J.I. & Goulden, B.E., 1987. The pathogenesis of equine laryngeal hemiplegia-a review. *New Zealand Veterinary Journal*, 35(6), pp.82-90.
- Chalmers, H.J. et al., 2006. Ultrasonography of the equine larynx. *Veterinary Radiology & Ultrasound*, 47(5), pp.476-481.
- Chalmers, H.J., Yeager, A.E. & Ducharme, N., 2009a. Ultrasonographic assessment of laryngochoyoid position as a predictor of dorsal displacement of the soft palate in horses. *Veterinary Radiology & Ultrasound*, 50(1), pp.91-96.

Chalmers, H.J., Yeager, A.E. & Ducharme, N., 2009b. Ultrasonographic assessment of laryngo-hyoid position as a predictor of dorsal displacement of the soft palate in horses. *Veterinary Radiology & Ultrasound*, 50(1), pp.91-96.

Cheetham, J. et al., 2008. Racing performance following the laryngeal tie-forward procedure: a case-controlled study. *Equine veterinary journal*, 40(5), pp.501-7.

Cheetham, J. et al., 2009. Role of the hypoglossal nerve in equine nasopharyngeal stability. *Journal of applied physiology*, 107(2), pp.471-7.

Cook, R., 2002. Bit-induced asphyxia in the horse: Elevation and dorsal displacement of the soft palate at exercise. *Journal of Equine Veterinary Science*, 22(1), pp.618-621.

Cook, W.R., 1965. The diagnosis of respiratory unsoundness in the horse. *Veterinary Record*, 77, pp.516-27.

Courouge-Malblanc, A. et al., 2010. Physiological measurements and prevalence of lower airway diseases in trotters with dorsal displacement of the soft palate. *Equine veterinary journal. Supplement*, 42(38), pp.246-55.

Dart, A.J., Dowling, B. a & Smith, C.L., 2005. Upper airway dysfunction associated with collapse of the apex of the corniculate process of the left arytenoid cartilage during exercise in 15 horses. *Veterinary Surgery*, 34(6), pp.543-7.

Davidson, E.J., Martin, B.B. & Parente, E.J., 2007. Use of successive dynamic videoendoscopic evaluations to identify progression of recurrent laryngeal neuropathy in three horses. *Journal of the American Medical Veterinary Association*, 230(4), pp.555-8.

Desmaizieres, L.-M. et al., 2009. Dynamic respiratory endoscopy without treadmill in 68 performance Standardbred, Thoroughbred and Saddle horses under natural training conditions. *Equine Veterinary Journal*, 41(4), pp.347-52.

- Dixon, P.M. et al., 2002. Clinical and endoscopic evidence of progression in 152 cases of equine recurrent laryngeal neuropathy (RLN). *Equine Veterinary Journal*, 34(1), pp.29-34.
- Dougherty, S.S. & Palmer, J.L., 2008. Use of intralesional formalin administration for treatment of a subepiglottic cyst in a horse. *Journal of the American Veterinary Medical Association*, 233(3), pp.463-5.
- Ducharme, N.G. et al., 1991. The reliability of endoscopic examination in assessment of arytenoid cartilage movement in horses. Part II. Influence of side of examination, reexamination, and sedation. *Veterinary Surgery*, 20(3), pp.180-4.
- Ducharme, N.G. et al., 2003. Investigations into the role of the thyrohyoid muscles in the pathogenesis of dorsal displacement of the soft palate in horses. *Equine Veterinary Journal*, 35(3), pp.258-63.
- Ducharme, N.G., 2012. Pharynx. In J. A. Auer & J. A. Stick, eds. *Equine Surgery*. St.Louis: Saunders, pp. 569-91.
- Duncan, I.D. et al., 1974. The pathology of equine laryngeal hemiplegia. *Acta neuropathologica*, 27(4), pp.337-48.
- Duncan, I.D. et al., 1991. Preferential denervation of the adductor muscles of the equine larynx. I: Muscle pathology. *Equine Veterinary Journal*, 23(2), pp.94-8.
- Dupuis, M.C.C. et al., 2011. Results of a haplotype-based GWAS for recurrent laryngeal neuropathy in the horse. *Mammalian Genome*, 22(9-10), pp.613-20.
- Embertson, R., 1998. Evaluation of the Young Horse Upper Airway: What Is normal, and what Is acceptable? *Proceedings Association of American Equine Practitioners*, 1998, 44, pp.34-38.
- Estes, R., 2010. Comments on grading system for epiglottic structure. *Journal of the American Veterinary Medical Association*, 236(6), p.1169.

Franklin, S.H., 2005. Intrinsic Stability of the Upper Airway. In D. M. Ainsworth et al., eds. *Third World Equine Airway Symposium*. Ithaca.

Franklin, S.H. et al., 2010. Investigation of the incidence and type of injuries associated with high-speed treadmill exercise testing. *Equine Veterinary Journal*, 42 Suppl 3, pp.70-5.

Franklin, S.H., Burn, J.F. & Allen, K.J., 2008. Clinical trials using a telemetric endoscope for use during over-ground exercise: A preliminary study. *Equine Veterinary Journal*, 40(7), pp.712-15.

Franklin, S.H., Naylor, J.R.J. & Lane, J.G., 2002. Effect of dorsal displacement of the soft palate on ventilation and airflow during high-intensity exercise. *Equine Veterinary Journal. Supplement*, 34(34), pp.379-83.

Fukushima, S. et al., 2003. Role of the pharyngeal branch of the vagus nerve in laryngeal elevation and UES pressure during swallowing in rabbits. *Dysphagia*, 18(1), pp.58-63.

Fulton, I.C. et al., 2012. Larynx. In J. A. Auer & J. A. Stick, eds. *Equine Surgery*. St Louis: Saunders, pp. 592-623.

Garrett, K.S., Woodie, J.B. & Embertson, R.M., 2011. Association of treadmill upper airway endoscopic evaluation with results of ultrasonography and resting upper airway endoscopic evaluation. *Equine veterinary journal*, 43(3), pp.365-71.

Garrett, K.S. et al., 2010. Endoscopic evaluation of arytenoid function and epiglottic structure in Thoroughbred yearlings and association with racing performance at two to four years of age: 2,954 cases (1998-2001). *Journal of the American Veterinary Medical Association*, 236(6), pp.669-73.

Goulden, B.E., 1977. Some unusual cases of abnormal respiratory noises in the horse. *New Zealand veterinary journal*, 25(12), pp.389-90.

Greet, T.R. et al., 1980. The slap test for laryngeal adductory function in horses with suspected cervical spinal cord damage. *Equine Veterinary Journal*, 12(3), pp.127-31.

Hackett, R.P. et al., 1991. The reliability of endoscopic examination in assessment of arytenoid cartilage movement in horses. Part I: Subjective and objective laryngeal evaluation. *Veterinary Surgery*, 20(3), pp.174-9.

Hahn, C.N. et al., 2008. Histological and ultrastructural evidence that recurrent laryngeal neuropathy is a bilateral mononeuropathy limited to recurrent laryngeal nerves. *Equine Veterinary Journal*, 40(7), pp.666-672.

Hare, W.C., 1975. Equine Respiratory system. In R. Getty, ed. *Sisson and Grossman's: The anatomy of Domestic Animals*. London: W.B. Saunders company, pp. 498-524.

Havemeyer, 2004. Proceedings of a Workshop on equine recurrent laryngeal neuropathy. In P. Dixon, E. Robinson, & J. F. Wade, eds. *Havemeyer Foundation Monograph Series*. R&W Publications (Newmarket) Limited, pp. 93-97.

Hawkins, J.F. & Tulleners, E.P., 1994. Epiglottitis in horses: 20 cases (1988-1993). *Journal of the American Veterinary Medical Association*, 205(11), pp.1577-80.

Haynes, P.F., 1981. Persistent dorsal displacement of the soft palate associated with epiglottic shortening in two horses. *Journal of the American Veterinary Medical Association*, 179(7), pp.677-81.

Hillidge, C., 1985. Prevalence of laryngeal hemiplegia on a Thoroughbred horse farm. *Journal of Equine Veterinary Science*, 5, pp.3-5.

Holcombe, S.J. et al., 2006. Cricothyroid muscle function and vocal fold stability in exercising horses. *Veterinary Surgery*, 35(6), pp.495-500.

Holcombe, S.J. et al., 2012. Dysphagia associated with presumed pharyngeal dysfunction in 16 neonatal foals. *Equine Veterinary Journal*, 44(41), pp.105-8.

Holcombe, S.J. et al., 1998. Effect of bilateral blockade of the pharyngeal branch of the vagus nerve on soft palate function in horses. *American Journal Of Veterinary Research*, 59(4), pp.504-8.

Holcombe, S.J. et al., 1997a. Effect of bilateral tenectomy of the tensor veli palatini muscle on soft palate function in horses. *American Journal Of Veterinary Research*, 58(3), pp.317-21.

Holcombe, S.J. et al., 1997b. Effects of bilateral hypoglossal and glossopharyngeal nerve blocks on epiglottic and soft palate position in exercising horses. *American Journal Of Veterinary Research*, 58(9), pp.1022-26.

Holcombe, S.J. et al., 1999. Pathophysiology of dorsal displacement of the soft palate in horses. *Equine veterinary journal. Supplement*, 30, pp.45-8.

Holcombe, S.J., Ducharme N.D., 2007. Disorders of the nasopharynx and soft palate. In McGorum B.C., Dixon P.M., et al., eds. *Equine Respiratory Medicine and Surgery*. Philadelphia PA: Saunders, pp 437-57.

Infernuso, T., Watts, A.E. & Ducharme, N.G., 2006. Septic epiglottic chondritis with abscessation in 2 young Thoroughbred racehorses. *The Canadian Veterinary Journal*, 47(10), pp.1007-10.

Kannegieter, N.J. & Dore, M.L., 1995. Endoscopy of the upper respiratory tract during treadmill exercise: a clinical study of 100 horses. *Australian Veterinary Journal*, 72(3), pp.101-7.

Kelly, G. et al., 2003. Idiopathic mucosal lesions of the arytenoid cartilages of 21 Thoroughbred yearlings: 1997-2001. *Equine Veterinary Journal*, 35(3), pp.276-281.

Kelly, P.G. et al., 2013. Comparison of dynamic and resting endoscopy of the upper portion of the respiratory tract in 57 Thoroughbred yearlings. *Equine Veterinary Journal*, 45(6), pp.700-4.

Kelly, P.G. & Pollock, P.J., 2015. Diagnosis and treatment of dynamic collapse of the cricotracheal ligament in Thoroughbred racehorses. *Veterinary Surgery*, 44, pp162-7.

Kelly, P.G., Pollock, P.J. & Reardon, R.J.M., 2013. Repeat dynamic endoscopic examination of 34 Thoroughbred racehorses diagnosed with intermittent dorsal displacement of the soft palate. In *Proceedings European college of veterinary surgeons*. p. 36.

King, D.S. et al., 2001. Clinical experiences with axial deviation of the aryepiglottic folds in 52 racehorses. *Veterinary Surgery*, 30(2), pp.151-160.

Koblinger, K. et al., 2011. Endoscopic assessment of airway inflammation in horses. *Journal of Veterinary Internal Medicine*, 25(5), pp.1118-26.

Kohda, E., Hisazumi, H. & Hiramatsu, K., 1994. Swallowing dysfunction and aspiration in neonates and infants. *Acta oto-laryngologica. Supplementum*, 517, pp.11-16.

Lacourt, M. & Marcoux, M., 2011. Treatment of epiglottic entrapment by transnasal axial division in standing sedated horses using a shielded hook bistoury. *Veterinary surgery*, 40(3), pp.299-304.

Lane, J.G, 2003. Non - RLN upper respiratory tract disorders found in a survey of 3,497 Thoroughbred yearlings. In P. Dixon, E. Robinson, & J. F. Wade, eds. *Proceedings of a workshop on Equine Recurrent Laryngeal neuropathy*. R&W Publications (Newmarket) Limited, pp. 49-50.

Lane, J.G., 2004. Long term longitudinal study of 887 foals. In P. Dixon, E. Robinson, & J. F. Wade, eds. *Proceedings of a workshop on Equine Recurrent Laryngeal neuropathy*. R&W Publications (Newmarket) Limited, pp. 31-32.

Lane, J.G. et al., 2006a. Dynamic obstructions of the equine upper respiratory tract. Part 2: comparison of endoscopic findings at rest and during high-speed treadmill exercise of 600 Thoroughbred racehorses. *Equine Veterinary Journal*, 38(5), pp.401-7.

Lane, J.G. et al., 2006b. Dynamic obstructions of the equine upper respiratory tract. Part 1: observations during high-speed treadmill endoscopy of 600 Thoroughbred racehorses. *Equine Veterinary Journal*, 38(5), pp.393-9.

Lane, J.G., Ellis, D.R. & Greet, T.R., 1987. Observations on the examination of Thoroughbred yearlings for idiopathic laryngeal hemiplegia. *Equine Veterinary Journal*, 19(6), pp.531-36.

Martin, B.B. et al., 1996. Causes of poor performance of horses during training, racing, or showing: 348 cases (1992 - 1996). *Journal of the American Veterinary Medical Association*, 216(4), pp.554-8.

Newton-Clarke, M.J., Divers, T.J. & Valentine, B.A, 1994. Evaluation of the thoraco-laryngeal reflex ('slap test') as an indicator of laryngeal adductor myopathy in the horse. *Equine Veterinary Journal*, 26(5), pp.355-7.

Parente, E.J. et al., 2002. Dorsal displacement of the soft palate in 92 horses during high-Speed treadmill examination (1993-1998). *Veterinary Surgery*, 31(6), pp.507-12.

Parente, E.J. & Martin, B., 1995. The correlation between standing endoscopic examinations and endoscopic examinations during high speed exercise in horses: 150 cases. In *Proceedings 5th Annual American College of Veterinary Surgeons Symposium 1995*; . p.17.

Parente, E.J., Martin, B, B. & Tulleners, E, P., 1998. Epiglottic retroversion as a cause of upper airway obstruction in two horses. *Equine Veterinary Journal*, 30(3), pp.270-2.

Perkins, J.D. et al., 2009. Variability of resting endoscopic grading for assessment of recurrent laryngeal neuropathy in horses. *Equine Veterinary Journal*, 41(4), pp.342-6.

- Pierce, S.W. & Embertson, R.M., 2001. Correlation of racing performance to yearling endoscopic evaluation. *Veterinary Surgery*, 47, pp.113-4.
- Pollock, P.J. et al., 2009. Dynamic respiratory endoscopy in 67 Thoroughbred racehorses training under normal ridden exercise conditions. *Equine Veterinary Journal*, 41(4), pp.354-60.
- Pollock, P.J. et al., 2013. Dynamic ventrorostral displacement of the dorsal laryngeal mucosa in horses. *Veterinary record*, 172(19), p.501.
- Pollock, P.J. & Reardon, R.J.M., 2009. Dynamic respiratory endoscopy without a treadmill: Initial experiences. *Equine Veterinary Education*, 21(7), pp.367-70.
- Poncet, P.A. & Montavon, S., 1989. A preliminary report on the possible genetic basis of laryngeal hemiplegia. *Equine Veterinary Journal*, 21(2), pp.137-8.
- Priest, D.T. et al., 2012. Dynamic respiratory endoscopy of Standardbred racehorses during qualifying races. *Equine Veterinary Journal*, 44(5), pp.529-34.
- Rakesh, V. et al., 2008. Implications of different degrees of arytenoid cartilage abduction on equine upper airway characteristics. *Equine Veterinary Journal*, 40(7), pp.629-35.
- Rakestraw, P.C. et al., 1991. Arytenoid cartilage movement in resting and exercising horses. *Veterinary surgery*, 20(2), pp.122-7.
- Rehder, R.S. et al., 1995. Measurement of upper airway pressures in exercising horses with dorsal displacement of the soft palate. *American Journal of Veterinary Research*, 56(3), pp.269-274.
- Sloet van Oldruitenborgh-Oosterbaan, M.M. & Clayton, H.M., 1999. Advantages and disadvantages of track vs. treadmill tests. *Equine Veterinary Journal Supplement*, 30, pp.645-7.
- Smith, R.L. et al., 2006. Arytenoid mucosal injury in young Thoroughbred horses - investigation of a proposed aetiology and clinical significance. *New Zealand Veterinary Journal*, 54(4), pp.173-7.

Stick, J.A. et al., 2001. Endoscopic assessment of airway function as a predictor of racing performance in Thoroughbred yearlings: 427 cases (1997-2000). *Journal of the American Veterinary Medical Association*, 219(7), pp.962-967.

Strand, E. et al., 2009. Effect of poll flexion and dynamic laryngeal collapse on tracheal pressure in Norwegian Coldblooded Trotter racehorses. *Equine Veterinary Journal*, 41(1), pp.59-64.

Strand, E. et al., 2012. Relative prevalence of upper respiratory tract obstructive disorders in two breeds of harness racehorses (185 cases: 1998-2006). *Equine Veterinary Journal*, 44(5), pp.518-23.

Sullivan, E.K. & Parente, E.J., 2003. Disorders of the pharynx. *Veterinary Clinics of North America: Equine Practice*, 19(1), pp.159-67.

Sweeney, C.R., Maxson, A.D. & Soma, L.R., 1991. Endoscopic findings in the upper respiratory tract of 678 Thoroughbred racehorses. *Journal of the American Veterinary Medical Association*, 198(6), pp.1037-38.

Tan, R.H.H., Dowling, B.A. & Dart, A.J., 2005. High-speed treadmill videoendoscopic examination of the upper respiratory tract in the horse: the results of 291 clinical cases. *Veterinary journal*, 170(2), pp.243-248.

Tessier, C. et al., 2004. Effects of stylopharyngeus muscle dysfunction on the nasopharynx in exercising horses. *Equine Veterinary Journal*, 36(4), pp.318-23.

Van Erck, E., 2011. Dynamic respiratory videoendoscopy in ridden sport horses: Effect of head flexion, riding and airway inflammation in 129 cases. *Equine Veterinary Journal*, 43, pp.18-24.

Witte, S.H.P. et al., 2011. Association of owner-reported noise with findings during dynamic respiratory endoscopy in Thoroughbred racehorses. *Equine Veterinary Journal*, 43(1), pp.9-17.

Zantingh, A.J. et al., 2013. Effects of hypoglossal nerve block and electrical stimulation of the thyrohyoideus muscles on position of the larynx and hyoid

apparatus in healthy horses. *American Journal of Veterinary Research*, 74(5), pp.784-9.