



University
of Glasgow

Marshall, Victoria Louise (2006) Clinical and functional imaging correlates in Parkinson's disease. MD thesis

<http://theses.gla.ac.uk/7012/>

Copyright and moral rights for this thesis are retained by the author

A copy can be downloaded for personal non-commercial research or study, without prior permission or charge

This thesis cannot be reproduced or quoted extensively from without first obtaining permission in writing from the Author

The content must not be changed in any way or sold commercially in any format or medium without the formal permission of the Author

When referring to this work, full bibliographic details including the author, title, awarding institution and date of the thesis must be given.

**CLINICAL AND FUNCTIONAL IMAGING CORRELATES
IN PARKINSON'S DISEASE**

Victoria Louise Marshall

A thesis submitted for the degree of MD in the Department of Neurology,

Faculty of Medicine, University of Glasgow

Department of Neurological Sciences,

August 2006

Department of Neurology

Institute of Neurological Sciences

Southern General Hospital

Glasgow G51 4TF

ABSTRACT

Parkinson's disease (PD) is misdiagnosed throughout its disease course for conditions such as essential tremor, drug-induced parkinsonism, vascular pseudo-parkinsonism, Alzheimer's disease and other degenerative parkinsonian diseases. Functional brain dopaminergic imaging (e.g. with [¹²³I] FP-CIT SPECT) is used to distinguish degenerative parkinsonism from essential tremor where it is known to be accurate in established disease. Less is known about its accuracy in early disease or for distinguishing PD from its other non-degenerative parkinsonian/ tremor mimics. A minority with clinically diagnosed PD have normal dopaminergic imaging.

This thesis aims to verify the accuracy of dopaminergic imaging in early and uncertain parkinsonian/ tremor disorders through 3 studies. The first is a prospective United Kingdom multicentre assessment of [¹²³I] FP-CIT SPECT use in 190 patients in pre-defined diagnostic categories and with particular focus on clinical features to assess the influence of imaging in routine practice. The second is a 2 year follow-up study of 150 consecutive patients with normal SPECT, with specific attention to clinical progression and antiparkinson medication use, and includes focus on a subgroup who fulfilled PD criteria where successful antiparkinson medication withdrawal was achieved. The third is a multicentre prospective European study of the accuracy of [¹²³I] FP-CIT SPECT in 99 patients that included serial clinical and imaging assessments.

Notably, when initial diagnosis/ scan mismatch cases occurred, and with awareness of the scan result, the clinician invariably changed the diagnosis in line with the scan result which confirms the considerable influence of imaging on the practising clinician. Parkinson's disease is clinically overdiagnosed early in its disease course,

whereas imaging is more specific. In the vast majority of cases with normal dopaminergic imaging, there was no evidence of clinical or imaging progression which would be in keeping with degenerative parkinsonism.

DECLARATION

I hereby declare that the work presented in this thesis is original and was conducted solely by the author except where collaboration with others is acknowledged.

Of the studies in this thesis;

Two thirds of patients entered into the first study (the UK Case Collection Study which comprises chapters 2, 3 and 4) were contributed by Glasgow and the other 7 United Kingdom centres contributed the remainder. The analysis and interpretation of these results was conducted by me. The follow-up studies of patients with normal SPECT imaging (chapter 5) was a single centre study conducted by myself in Glasgow. The last study (chapter 6) was a European multi-centre study, 32 subjects were contributed by Glasgow and the remainder (67) from the other 8 centres. Some aspects of statistical design are acknowledged from their statistical source. Some statistical analysis was performed in collaboration with professional statisticians. The analysis and interpretation of results as presented in this thesis was conducted by myself.

ACKNOWLEDGEMENTS

I am indebted to my supervisor, Dr D Grosset. I would like to express my sincere gratitude for his constant and enthusiastic support, skilful direction and unfaltering patience.

I would like to thank Dr J Patterson, Department of Clinical Physics, for his continuous guidance and advice.

I am also grateful to Professor I Bone, Department of Neurology, for his counsel over the years.

I would like to thank Dr K Grosset, Department of Neurology, for her advice and encouragement during this time.

I would like to express particular thanks for the support and patience from Mrs E Jackson (Research Secretary), Mrs R Tracey and Miss A McMillan.

I am thankful to the Research Nurses; Mrs T Murphy, Mrs E Tyrell, and Miss A O'Donnell for valuable contributions towards these studies.

Also, my thanks to the contributors from each centre within the United Kingdom and European FP-CIT study groups.

Finally, and importantly, I am thankful and very grateful to all of the patients for their participation in this research.

ABBREVIATIONS

| | |
|---------------------------|---|
| CT | Computed Tomography |
| AD | Alzheimer's Disease |
| BTPD | Benign Tremulous Parkinson's Disease |
| CBD | Corticobasal Degeneration |
| DAT | Dopamine Transporter |
| DIP | Drug-induced parkinsonism |
| DLB | Dementia with Lewy Bodies |
| DRD | Dopa Responsive Dystonia |
| ET | Essential Tremor |
| FDG | [¹⁸ F]- 2-fluoro-2-deoxy-glucose |
| H & Y | Hoehn and Yahr |
| MRI | Magnetic resonance imaging |
| MSA | Multiple system atrophy |
| PD | Parkinson's disease |
| PET | Positron Emission Tomography |
| PSP | Progressive Supranuclear Palsy |
| SPECT | Single Photon Emission Computed Tomography |
| SWEDD | Subject (with scan) Without Evidence of Dopaminergic Deficiency |
| UPDRS | Unified Parkinson's Disease Rating Scale |
| VP | Vascular parkinsonism |
| VT | Vascular tremor |
| VMAT | Vesicular monamine oxidase transporter |
| ROI | Region Of Interest |
| [¹¹ C] RTI-32 | 3 β -(4-methylphenyl)-tropane-2-carboxylic acid methyl ester |

| | |
|--|---|
| [¹¹ C] CFT | 2 β -carbomethoxy-3 β -(4-[(18)F]-fluorophenyl)tropane |
| [¹⁸ F] dopa | ¹⁸ F-fluoro-L-3,4-dihydroxyphenylalanine |
| [^{99m} Tc] TRODAT | (2 β -(N,N'-bis(2-mercaptoethyl)ethylene diamino)methyl), 3 β -(4-chlorophenyl)tropane) |
| [¹²³ I] [¹²³ I] FP-CIT | ¹²³ I-N-fluoropropyl-2 β -carbomethoxy-3 β -(4-iodophenyl)nortropane |
| [¹²³ I] IBZM | ¹²³ I- iodobenzamide |
| [¹²³ I] β-CIT | ¹²³ I- β -carbomethoxy-3 β -(4-iodophenyl)-tropane |
| [¹²³ I] IPT | ¹²³ I- N-(3-iodopropen-2-yl)-2 β -carbomethoxy-3 β -(4-chlorophenyl)tropane |

PUBLICATIONS

Marshall VL, Oertel WH, Patterson J, Hadley DM, Pogarell O, Höffken H, Gerstner A, Grosset DG. Diagnostic Accuracy in Early Parkinson's Disease: A Clinical and Imaging Follow up Study [Abs]. J Neurol Neurosurg Psychiatry. 2002;74(10);1458,[P54].

Marshall VL, Grosset DG. Role of dopamine transporter imaging in routine clinical practice. Mov Disord. 2003;18(12);1415-1423.

Marshall VL, Grosset DG. Role of dopamine transporter imaging in the diagnosis of atypical tremor disorders. Mov Disord. 2003;18(Suppl 7);S22-S27.

Marshall VL, Kolokouris D, Patterson J, Hadley DM, Wyper D, Dempsey MF, Grosset DG. Differentiating Vascular Parkinsonism from True Parkinsonism; Audit of [¹²³I] FP-CIT SPECT Imaging in clinical practice [Abs]. J Neurol Neurosurg Psychiatry. 2004;75(5);797-806,[P080].

Marshall VL, Patterson J, Hadley DM, Grosset KA, Grosset DG on behalf of the UK FP-CIT Study Group. Differentiating drug-induced parkinsonism from Parkinson's disease with [¹²³I] FP-CIT SPECT: Preliminary results [Abs]. J Neurol Neurosurg Psychiatry. 2005;76(9);1323, [054].

Marshall VL, Patterson J, Hadley DM, Grosset KA, Grosset DG on behalf of the UK FP-CIT Study Group. Use of [¹²³I] FP-CIT SPECT (DaTSCAN) as an aid to differentiate Parkinson's disease and psychogenic parkinsonism [Abs]. Parkinsonism & Related Disorders. 2005;1(3);150[PT013-01].

Marshall VL, Patterson J, Hadley DM, Grosset KA, Grosset DG on behalf of the UK FP-CIT Study Group. The Use and Influence of [¹²³I] FP-CIT SPECT in current practice. UK experience of 190 patients with uncertain parkinsonism [Abs]. J Neurol Neurosurg Psychiatry. 2006; 77(12):1398[054].

Marshall VL, Patterson J, Hadley DM, Grosset KA, Grosset DG. Two year follow-up in 150 consecutive cases with normal dopamine transporter imaging. Nucl Med Commun. 2006 Dec;27(12):933-7.

Marshall VL, Patterson J, Hadley DM, Grosset KA, Grosset DG. Successful antiparkinson medication withdrawal in patients with parkinsonism and normal [¹²³I] FP-CIT SPECT. Mov Disord. 2006 Oct 31; [Epub ahead of print].

Contents

| | |
|---|-----------|
| TITLE..... | i |
| ABSTRACT..... | ii |
| DECLARATION..... | iv |
| ACKNOWLEDGEMENTS..... | v |
| LIST OF ABBREVIATIONS..... | vi |
| PUBLICATIONS..... | viii |
| CONTENTS..... | x |
| LIST OF FIGURES | xiii |
| LIST OF TABLES..... | xiv |
| SUMMARY..... | xvi |
| | |
| CHAPTER 1 : INTRODUCTION | 1 |
| 1. Clinical diagnosis and differential diagnosis of parkinsonism..... | 2 |
| The misdiagnosis of Parkinson's disease and its parkinsonian mimics | 2 |
| 1a) Parkinson's disease and other causes of degenerative parkinsonism | 4 |
| 1b) Essential tremor | 9 |
| 1c) Vascular parkinsonism | 11 |
| 1d) Drug-induced parkinsonism..... | 13 |
| 1e) Psychogenic movement disorders and psychogenic parkinsonism..... | 14 |
| 1f) Dopa-responsive dystonia..... | 15 |
| 1g) Juvenile onset Parkinson's disease or Young onset Parkinson's disease | 16 |
| 1h) Parkinsonism and dementia | 16 |
| 2. Adjuncts to clinical diagnosis | 17 |
| 2a) Levodopa and apomorphine challenge tests | 17 |
| 2b) Olfactory testing | 18 |
| 2c) Genetic testing..... | 18 |
| 2d) Structural brain imaging | 18 |
| 2e) Functional imaging | 19 |
| 3. Functional Brain Imaging with dopamine transporter imaging | 21 |
| 3a) Comparison to other dopamine imaging techniques..... | 21 |
| 3b) Clinical application of dopamine transporter imaging..... | 23 |
| 3c) Subjects with a clinical diagnosis of Parkinson's disease with scans without evidence of dopaminergic deficit (SWEDD's) | 29 |
| 4. Summary of DAT imaging areas that require clarification | 30 |

| | |
|---|-----------|
| CHAPTER 2 : UK FP-CIT CASE COLLECTION STUDY OVERVIEW: APPLICATION OF [¹²³I] FP-CIT SPECT IN CLINICAL PRACTICE IN THE UNITED KINGDOM, EXPERIENCE IN 190 PATIENTS WITH UNCERTAIN PARKINSONISM | 33 |
| Introduction | 34 |
| Methods | 35 |
| Results | 37 |
| Discussion | 38 |
| Conclusion..... | 42 |
| CHAPTER 3 : A PROSPECTIVE ASSESSMENT OF THE USEFULNESS OF [¹²³I] FP-CIT SPECT IN UNCERTAIN TREMOR DISORDERS IN CLINICAL PRACTICE. A SUBGROUP OF THE UK FP-CIT CASE COLLECTION..... | 47 |
| Introduction | 48 |
| Methods | 48 |
| Results | 48 |
| Discussion | 51 |
| Conclusion..... | 55 |
| CHAPTER 4 : [¹²³I] FP-CIT SPECT CLARIFIES UNDERLYING DOPAMINERGIC STATUS IN PARKINSONISM ASSOCIATED WITH DRUG USE. A SUBGROUP OF THE UK FP-CIT CASE COLLECTION | 68 |
| Introduction | 69 |
| Aims and Methods | 70 |
| Results | 70 |
| Discussion | 72 |
| Conclusion..... | 79 |
| CHAPTER 5 : PROLONGED FOLLOW-UP OF PATIENTS WITH NORMAL [¹²³I] FP-CIT SPECT IMAGING | 83 |
| Introduction | 84 |
| Methods | 85 |

| | |
|--|------------|
| Study 1: Two year follow-up of 150 consecutive cases with normal dopamine transporter imaging | 87 |
| Methods | 87 |
| Results | 87 |
| Discussion | 90 |
| Conclusion..... | 93 |
| Study 2: Successful antiparkinson medication withdrawal in patients with parkinsonism and normal [¹²³I] FP-CIT SPECT | 96 |
| Methods | 96 |
| Results | 97 |
| Discussion | 98 |
| Conclusion..... | 99 |
| | |
| CHAPTER 6 : PARKINSON'S DISEASE IS OVERDIAGNOSED CLINICALLY: A 3-YEAR EUROPEAN STUDY WITH REPEAT [¹²³I] FP-CIT SPECT | 102 |
| Introduction | 103 |
| Methods | 104 |
| Results | 108 |
| Discussion | 110 |
| | |
| CHAPTER 7 : DISCUSSION AND INTERPRETATION | 121 |
| | |
| REFERENCES..... | 130 |

List of Figures

| | |
|---|-----|
| Figure 1-1 Schematic diagram of the pre and post synaptic dopaminergic neurone with reference to the specific components which can be radiolabelled and imaged with PET or SPECT..... | 32 |
| Figure 2-1 Visual assessment of [¹²³ I] FP-CIT SPECT according to baseline diagnosis in 190 patients with uncertain parkinsonism | 44 |
| Figure 3-1 Pre-scan to post-scan diagnostic mismatch rate in 50 patients with uncertain tremor disorders | 58 |
| Figure 4-1 Semiquantitative [¹²³ I] FP-CIT uptake in putamen according to post-scan diagnosis in patients with parkinsonism associated with drug use..... | 81 |
| Figure 4-2 Semiquantitative [¹²³ I] FP-CIT uptake in caudate according to post-scan diagnosis in patients with parkinsonism associated with drug use..... | 82 |
| Figure 5-1 Final clinical diagnosis after follow-up in 150 patients with normal [¹²³ I] FP-CIT SPECT | 94 |
| Figure 6-1 Disposition of subjects within the 3 year study of accuracy of [¹²³ I] FP-CIT SPECT in early and uncertain parkinsonian/ tremor disorders | 115 |

List of Tables

| | |
|--|-----|
| Table 2-1 Pre and post-scan most likely diagnoses and [¹²³ I] FP-CIT SPECT result in 190 patients with clinically uncertain parkinsonism..... | 43 |
| Table 2-2 Congruence between [¹²³ I] FP-CIT SPECT result and clinical diagnosis after knowledge of SPECT result in 190 patients | 45 |
| Table 2-3 Relationship of individual and combination parkinsonian signs to abnormal [¹²³ I] FP-CIT SPECT (in a parkinsonian distribution) in 190 patients..... | 46 |
| Table 3-1 Comparison of pre and post-scan diagnoses according to [¹²³ I] FP-CIT SPECT of 50 patients with uncertain tremor disorders | 56 |
| Table 3-2 Visual grade of [¹²³ I] FP-CIT SPECT according to pre-scan diagnosis in 50 patients with uncertain tremor disorders..... | 57 |
| Table 3-3 Clinical characteristics of 10 'mismatch' tremor cases | 59 |
| Table 3-4 Stratification of [¹²³ I] FP-CIT SPECT result and post-scan diagnosis according to tremor type in 50 cases..... | 60 |
| Table 3-5 Post-scan diagnosis according to symmetry of predominant tremor type in 25 patients | 62 |
| Table 3-6 Detailed clinical features of 25 subjects with uncertain tremor disorders undergoing [¹²³ I] FP-CIT SPECT | 63 |
| Table 3-7 Relationship of individual and combinations of parkinsonian signs to abnormal [¹²³ I] FP-CIT SPECT in a degenerative parkinsonian distribution in patients with uncertain tremor disorders | 67 |
| Table 4-1 Provisional clinical diagnosis compared to post-scan diagnosis (made with knowledge of the [¹²³ I] FP-CIT SPECT result) in 49 patients with parkinsonism associated with drug use..... | 80 |
| Table 5-1 Presence and certainty of cardinal parkinsonian features in 150 patients with normal [¹²³ I] FP-CIT SPECT..... | 95 |
| Table 5-2 Antiparkinson medication use in 150 patients with normal [¹²³ I] FP-CIT SPECT, according to presence of definite clinical features..... | 95 |
| Table 5-3 Clinical features of 11 patients with normal [¹²³ I] FP-CIT SPECT treated with antiparkinson medication which was later successfully withdrawn | 101 |
| Table 6-1 Baseline demographic and clinical data for 99 subjects with [¹²³ I] FP-CIT SPECT according to the consensus video diagnosis..... | 116 |
| Table 6-2 Motor scoring and antiparkinson medication use at <i>t</i> = 0 and 36 months according to consensus video diagnosis | 117 |

| | |
|--|-----|
| Table 6-3 Motor scoring and antiparkinson medication use at $t = 0$ and 36 months according to baseline visual assessment of [123 I] FP-CIT SPECT | 117 |
| Table 6-4 Change in motor UPDRS and antiparkinson medication use according to consensus video diagnosis and baseline visual assessment of [123 I] FP-CIT SPECT | 118 |
| Table 6-5 Diagnostic sensitivity, specificity, predictive values and accuracy of clinical and imaging diagnoses compared to the 3 year consensus video diagnosis | 119 |
| Table 6-6 Consensus video diagnosis versus baseline on-site diagnosis and baseline visual assessment of [123 I] FP-CIT SPECT | 120 |

Summary

The clinical diagnosis of Parkinson's disease (PD) and differentiation from some of its parkinsonian/ tremor mimics is often straightforward but misdiagnosis does occur, even in late stage disease. Misdiagnosis leads to inappropriate treatment, (with potential morbidity from treatment side-effects or even lack of treatment), incorrect prognostic advice (in some cases lack of recognition of a potentially reversible disorder) and there are additional concerns over inappropriate placement of patients without Parkinson's disease into PD studies.

A number of adjuncts to improve the clinical diagnosis are under scrutiny, including radioisotope imaging of the brain dopaminergic neurone. In particular, radiolabelling the presynaptic dopaminergic neurone with ligands such as ^{123}I -N-fluoropropyl-2 β -carbomethoxy-3 β -(4-iodophenyl)nortropine (^{123}I FP-CIT) is an accurate method to differentiate patients with established Parkinson's disease from those with essential tremor. It can differentiate Parkinson's disease from disorders without disruption of the presynaptic dopaminergic neurones (such as essential tremor or drug-induced parkinsonism) but cannot differentiate between Parkinson's disease and other types of degenerative parkinsonism. Little is known about its precision or usefulness in early uncertain Parkinson's disease and its parkinsonian mimics.

The aim of this thesis is to investigate the utility and accuracy of ^{123}I FP-CIT SPECT in early and uncertain parkinsonian conditions.

In the introduction (Chapter 1), a review of the differential diagnosis of Parkinson's disease and clinical diagnostic accuracy is followed by a description of the tools available or being developed as an adjunct to clinical acumen. There then follows a

review of functional dopaminergic brain imaging and current knowledge on the accuracy of imaging of the presynaptic neurone.

The UK Case Collection Study was a large prospective study of the current use of [¹²³I] FP-CIT SPECT in uncertain parkinsonism in routine clinical practice (Chapters 2, 3 and 4). There were pre-specified diagnostic pairings with prospective documentation of clinical features and diagnoses. The aim was to identify differences in rates of concurrence of initial uncertain diagnosis, SPECT result and post-scan diagnoses with reference to the cardinal features of parkinsonism.

Chapter 1 gives an overview of all 190 subjects within the study where an overall, unexpected scan result (according to pre-scan uncertain diagnosis) occurred in around one-quarter of patients. There were more unexpected scan results within subjects labelled initially as vascular parkinsonism than in other categories, suggesting more clinical diagnostic difficulty within this group. Up to 40% of patients fulfilling basic criteria for PD had normal imaging. SPECT visual assessment gave a clear answer of normal or abnormal in 97%. Chapter 3 considers in detail the utility of [¹²³I] FP-CIT SPECT in differentiating between uncertain tremor disorders and Chapter 4 focuses on subjects with parkinsonism associated with drug use.

The issue of whether evidence of degenerative parkinsonism may emerge over time in subjects with normal [¹²³I] FP-CIT SPECT is considered in 2 follow-up studies in Chapter 5. A 2 year follow-up in 150 consecutive cases with normal dopamine transporter imaging concluded that there was no evidence of clinical deterioration or response to antiparkinson therapy, and thus there was no indication of emerging degenerative parkinsonism. The vast majority of this series had diagnoses of non-degenerative parkinsonism/ tremor conditions. In the second study, successful antiparkinson therapy withdrawal in 11 subjects who had suspected Parkinson's

disease but who had normal [¹²³I] FP-CIT SPECT was achieved without clinical deterioration after follow-up.

The accuracy of [¹²³I] FP-CIT SPECT to differentiate between early uncertain parkinsonism/ tremor disorders is examined within the blinded prospective European 3 year follow-up study of 99 patients in Chapter 6. Imaging was repeated at 3 time points and a very high interrater agreement was found for visual assessment of SPECT for abnormal or normal. Evidence of clinical over-diagnosis of PD at baseline was identified. Specificity of baseline imaging was 97% with a lower sensitivity of 78%. Fifteen of 71 subjects (21%) with a 3 year diagnosis of Parkinson's disease had normal baseline imaging. Imaging remained repeatedly normal in all but 1 case. These subjects had no significant change in clinical rating scores, which differentiated these cases from patients with PD and abnormal SPECT.

In summary, visual inspection of [¹²³I] FP-CIT SPECT in subjects with uncertain parkinsonian conditions gives clear results in most cases, with good agreement between SPECT readers of the scans' result. In routine clinical practice, there is an unexpected scan result according to initial uncertain diagnosis in a quarter of cases. The influence of the SPECT scan is notable, as a change in diagnosis was made in most mismatch cases in line with the scan result. Up to 40% of patients fulfilling basic Parkinson's disease criteria have normal imaging, and long term follow-up of these cases finds no evidence of emerging parkinsonian disorders and antiparkinson therapy can be withdrawn successfully. Clinicians overdiagnose PD, but high specificity for baseline [¹²³I] FP-CIT SPECT suggests that combining clinical and imaging assessments could reduce overdiagnosis of PD at an early stage. [¹²³I] FP-CIT SPECT gave normal results in a proportion of patients given a PD diagnosis 3 years later. We found evidence within this group with normal scans of a different

clinical and imaging progression to those who definitely have PD, suggesting either a different form of PD or a non-PD diagnosis.

In conclusion, [¹²³I] FP-CIT SPECT imaging will not replace clinical acumen but can be used as an adjunct to clinical diagnosis and has marked diagnostic influence in routine clinical practice. The clinician should be wary of a subject suspected to have PD who has a normal [¹²³I] FP-CIT SPECT as we have provided evidence that this group has a lack of clinical and imaging progression, and a poor antiparkinson therapy response.

Chapter 1 : Introduction

1. Clinical diagnosis and differential diagnosis of parkinsonism

The misdiagnosis of Parkinson's disease and its parkinsonian mimics

The term 'parkinsonism' is a description of the clinical features of bradykinesia, accompanied by one or more of rigidity, postural instability or resting tremor. Parkinsonism results from idiopathic Parkinson's disease (PD) as well as other neurodegenerative disorders, cerebrovascular disease and can also be drug-induced. Clinical diagnosis of parkinsonism is quite often straightforward and additional investigations are often not required. However, clinicopathological correlation in patients diagnosed in life with idiopathic Parkinson's disease shows that 10 - 25% have alternative diagnoses. Applying diagnostic criteria increases accuracy but reduces sensitivity, which can affect management of the individual case(1-5). Eight percent (65 of 800) patients entered into a trial of a possible neuroprotective drug by movement disorder specialists with a diagnosis of early Parkinson's disease were found to have alternative diagnoses after 7.6 years of follow-up(6). A community study in London found 15% (15/100) of patients with a diagnosis of Parkinson's disease were misdiagnosed according to strict diagnostic criteria and detailed neurology review with follow-up(7). Another study in North Wales confirmed a diagnosis of parkinsonism in 74% (299/402) and clinically probable Parkinson's disease in only 53% (213/402) of patients receiving antiparkinsonian medication(8). It is in the early or atypical or overlap disorders that further investigations are necessary to improve clinical diagnostic certainty. Investigations such as structural or functional cranial imaging or drug challenge tests are most commonly employed.

Progressive supranuclear palsy (PSP), multiple system atrophy (MSA), Alzheimer's disease (AD) and vascular parkinsonism (VP) were most commonly misdiagnosed as Parkinson's disease in hospital based practice whereas in the community, essential tremor (ET), Alzheimer's disease and vascular parkinsonism were commoner(8) as diagnostic errors. Patients on neuroleptics were excluded from many of these studies. Despite the exclusion of obvious cases of drug-induced parkinsonism, 3% of cases with parkinsonism in the North Wales study were finally considered to have drug-induced parkinsonism(8). Other causes of parkinsonism such as hydrocephalus, Wilson's disease, intracerebral tumour or akinetic-rigid presentations of Huntington's are rare but may need to be considered.

Strict classification schemes based on the presence of clinical features of parkinsonism exist and are useful particularly in clinical trials or studies (see Brain Bank criteria part 1 below), but in the clinical setting the presence of parkinsonism itself can be uncertain (e.g. in the presence of only limited bradykinesia or other 'partial' fulfilment of the criteria, e.g. when there is only one of the following: reduced arm swing, mild slowing of finger taps, reduced facial expression or cogwheeling). The term 'uncertain parkinsonism' refers to a lack of confidence of either the presence of true parkinsonism or of the underlying cause. Understanding the potential causes of this is imperative for the accurate differentiation of PD from other disorders, including those traditionally not associated with parkinsonism such as essential tremor.

The importance of an accurate diagnosis

A correct initial diagnosis is important, as is monitoring and reconsideration of the correct diagnosis over time. Prognosis varies from one condition to another.

Essential tremor is believed to give no change in life expectancy but previous beliefs of low disability have been questioned, particularly among those seeking specialist

advice(9). Parkinson's disease causes functional impairment in most patients and probably reduces life expectancy(10). Drug management varies, with potential for secondary prevention in stroke disease where there is vascular parkinsonism and withdrawal of offending medication in drug-induced parkinsonism. The potential harm from reversal of an initial incorrect diagnosis and accompanying removal of support services should preferably be avoided.

1a) Parkinson's disease and other causes of degenerative parkinsonism

Degenerative parkinsonism is a term used to encompass Parkinson's disease, multiple system atrophy, progressive supranuclear palsy and corticobasal degeneration (CBD). All syndromes may share similar features but each have distinct pathologies. The terms atypical parkinsonism or "Parkinson Plus" are used by some to describe MSA, PSP and CBD.

Parkinson's disease

Parkinson's disease is now considered more of a syndrome due to a number of both genetic and environmental factors. It has a prevalence of 1.6% in a European study(11) and does not seem to vary much worldwide. It is the most common cause of parkinsonism in the population(12;13) or referred to hospital neurology clinics(14), although drug-induced parkinsonism may be more common in certain settings such as geriatric department referrals(15).

Parkinson's disease typically presents with unilateral 4 - 6 Hz resting tremor and stiffness in one limb, which progresses over time usually to affect all limbs but typically with retained predominance for the side of onset, and 'asymmetry' between the upper and lower limbs with the arms being involved to the greater extent(16). In some cases, as the disease progresses, the side of predominance may change, or rest tremor may become less pronounced(17). It is the motor symptoms that usually attract medical attention although the disorder commonly affects the sensory and

autonomic systems as well as cognition, sleep and emotion(18). Of 100 cases with histologically confirmed Parkinson's disease, mean disease onset was 62.4 (S.D. 9.2) years, asymmetry was present in 72% and upper limbs alone were involved in 65%, with tremor in 69%. Levodopa was commenced a mean of 3.2 years after first symptoms were noted(19). In a retrospective study of 253 patients with a clinical diagnosis of Parkinson's disease, tremor was the presenting complaint in 63%, and the tremor spread to the leg on the same side between 0.8 and 1.4 years from onset, and spread to the contralateral side after 2.1 to 3.4 years(20). Parkinson's disease may present atypically, for example with asymmetrical long duration postural tremor(21) or foot dystonia(22).

The characteristic loss of dopaminergic neurons and formation of Lewy bodies within the remaining degenerating nigral neurones is actually the third stage in a proposed staging system(23). Lewy bodies are found within the dorsal motor nucleus of the glossopharyngeal and vagal neurones and anterior olfactory nucleus in earlier disease(23). Nigral dopaminergic neurones project to the putamen and caudate (corpus striatum) and after a loss of 50 - 80%(24;25) a patient becomes symptomatic. More severe neurone loss occurs within the ventrolateral tier of the substantia nigra(26). Neurones project to the putamen from the ventral tier(27). Post-mortem of Parkinson's disease patients finds a loss of presynaptic dopaminergic neurones which is more pronounced in the dorsal and caudal parts of the putamen(28).

The direct mean annual cost per patient is £5,993 for all patients, calculated in 1998 in the United Kingdom(29) which increases with age and disease severity.

The retrospective application of recommended diagnostic criteria(30) improved the diagnostic accuracy of a post-mortem diagnosis of Parkinson's disease from 76% (for

a diagnosis made in life by neurologists or geriatricians) to 82%(1). These criteria follow 3 steps.

- Step 1 requires the presence of bradykinesia plus one of rigidity, 4 - 6 Hz rest tremor and postural instability not caused by primary visual, vestibular, cerebellar or proprioceptive dysfunction. The requirement of the presence of bradykinesia eliminates cases of essential tremor with cogwheeling which would satisfy less strict criteria.
- Step 2 excludes any patient with a history of repeated strokes with stepwise progression of parkinsonian features, repeated head injury, definite encephalitis, oculogyric crises, neuroleptic treatment at onset of symptoms, more than one affected relative, sustained remission, strictly unilateral features after 3 years, supranuclear gaze palsy, cerebellar signs, early severe autonomic involvement, early severe dementia, presence of the babinski sign, presence of cerebral tumour or communicating hydrocephalus on CT scan, negative response to large dose of levodopa and MPTP exposure.
- Step 3 refers to supportive prospective positive criteria for Parkinson's disease (3 or more required for a diagnosis of definite Parkinson's disease). These are unilateral onset, presence of a rest tremor, a progressive disorder, persistent asymmetry affecting the side of onset most. Excellent response (70 - 100%) to levodopa, severe levodopa induced chorea, levodopa response for 5 years or more and a clinical course of 10 years or more(30).

Application of further multiple criteria improves the specificity and positive predictive value for an PD diagnosis but to the detriment of excluding 32% of pathologically confirmed cases of PD(31). An identical study a decade later found that the accuracy of a PD diagnosis was 90%, and increased only slightly to 92% by the retrospective

application of Brain Bank criteria(32). These criteria can not be applied comparably in other settings, for example in early disease.

Multiple system atrophy (MSA), progressive-supranuclear palsy (PSP) and corticobasal degeneration (CBD)

They are all most often sporadic adult onset neurodegenerative disorders with distinct neuropathology (MSA is an alpha-synucleinopathy whilst PSP and CBD are regarded as tauopathies). All may respond to levodopa at least partially in the initial stages but are usually considered as levodopa-unresponsive conditions, and all can have overlapping features with Parkinson's disease or other neurodegenerative disorders for which they sometimes misdiagnosed. Clinical criteria exist, although not all have pathological verification and their sensitivity early in disease is poor(33).

Multiple system atrophy

Multiple system atrophy is currently classified according to whether patients demonstrate primarily parkinsonism (MSA-P) or cerebellar (MSA-C) features. Previously these were known as striatonigral degeneration or sporadic olivopontocerebellar degeneration respectively and a third type (Shy-Drager) has been described in those with primarily autonomic features. The newer classification takes into account the fact that the same pathology is found in all subtypes, and autonomic features may be prominent in either MSA-P or MSA-C. Pathologically there is gliosis and neuronal loss and alpha-synuclein positive oligodendroglial cytoplasmic inclusions within the striatum, substantia nigra, inferior olives, pons and cerebellum, intermediolateral cell columns and Onuf's nucleus within the spinal cord(34).

The prevalence of MSA in London is 4.4 per 100,000 although this is likely to be an underestimate(35). Apart from parkinsonism, cerebellar or autonomic disturbances, red flag features include early restriction to a wheelchair (the 'wheelchair' sign),

irregular jerky postural and action tremor with jerkiness being due to stimulus sensitive myoclonus, rapid disease progression, and disturbances of the peripheral microcirculation with cold, dusky, violaceous extremities, sleep apnoea, stridor, involuntary inspiratory sighs or gasps during the day. Speech may be quite distinctive with a quivery croaky strained element. Emotional incontinence and REM sleep behaviour disorder are common but not specific. Dementia is unusual. Dystonia unrelated to levodopa may be found with camptocormia in some. A clinicopathological study found that 8 of 59 (14%) patients with final diagnosis of MSA had alternative diagnoses, most commonly PD (6), PSP (1) and cerebrovascular disease (1)(36).

Progressive supranuclear palsy (PSP or Steele-Richardson-Olszewski syndrome)

The typical clinical features of progressive supranuclear palsy include early postural instability often with backwards falls, a fixed stare with markedly reduced blinking, and a fixed retracted neck with retrocollis. Impaired vertical gaze and early difficulties with swallowing combine to cause problems with spilling of food onto clothes (the 'messy-tie' sign). A sub-cortical cognitive deficit often exists. PSP is characterised by the destruction of a number of sub-cortical structures including the substantia nigra, globus pallidus, subthalamic nucleus and midbrain and pontine reticular formation where neurofibrillary tangles, neuropil threads and tufted astrocytes are found. These inclusions are made from insoluble aggregates of tau phosphoprotein. Tau-positive glial inclusions are also present. A neuro-pathological study found 43 of 180 (24%) referred with a diagnosis of PSP actually had other diagnoses including corticobasal degeneration, multiple system atrophy and dementia with Lewy bodies(37). A prevalence of 1.39 to 14.3 per 100,000 has been found(38). The median duration from disease onset to death is 5.8 to 5.9 years(39).

Corticobasal degeneration (CBD)

The core clinical features are of asymmetrical rigidity and apraxia together with other findings of cortical dysfunction such as sensory loss, alien limb phenomenon or myoclonus. Pathologically asymmetrical frontoparietal cortical atrophy with basal ganglia and nigral degeneration is found, there are ballooned, achromatic neurones found within the cortex and abnormal collections of tau protein within the neurones and glia. The main differential diagnosis of CBD includes Parkinson's disease, multiple system atrophy and progressive supranuclear palsy. Rarely, Alzheimer's disease can present in a similar fashion.

1b) Essential tremor

This is the most common type of tremor with a quoted prevalence of 300 to 415 per 100,000(40).

This figure is likely to be unreliable, as only a minority of patients seek medical advice. Typically, it is a bilateral postural (6 - 8 Hz) and kinetic tremor of the upper limbs but it may also affect the head, voice, legs, jaw, face, trunk and tongue(41;42) and is often mild(43). Those attending hospital clinics tend to have more severe and disabling disease. Some patients may have a rest component that usually occurs later in the disease course(44). Of 176 patients with a clinical diagnosis of ET, 10.2% had additional rest tremor(45). Postural instability and an ataxic gait are sometimes found(9) although are usually not predominant features. The cogwheel phenomenon is also a common confounding factor in ET. Tremor is sometimes asymmetrical and rarely can be unilateral. A positive family history occurs in around 50% of cases, and response to alcohol and beta-blockers is variable(46). In addition, subtle extrapyramidal signs (such as reduced facial expression, reduced arm swing, or stooped posture) are often found in the elderly. When these are present in patients with ET, they may reduce certainty of diagnosis. Post-mortem studies of ET have

failed to show abnormalities of the substantia nigra(47), although the localised presence of Lewy bodies within the locus ceruleus has been reported recently in a patient with longstanding typical essential tremor without parkinsonism(48), raising questions about the link between some patients with clinical essential tremor and restricted (non-nigral) forms of Lewy body disease.

In a retrospective review of 201 consecutive patients attending our movement disorder clinic (Benamer and Grosset, unpublished observations), 68 (34%) had tremor only or a tremor-dominant syndrome. Of these, 31 had a diagnosis made by the referring clinician (mainly nonspecialist). Specialist clinical diagnosis concurred with the referral diagnosis in 14 of 21 cases referred as PD, but was changed from PD to ET in 6 cases, and from PD to uncertain in one case. Of 8 patients referred as a diagnosis of ET, 2 cases were confirmed in the clinic, but 5 cases were amended to PD. Of 2 patients referred with atypical tremor, the final diagnosis was 1 PD and 1 ET. Additionally, 7% of initial diagnoses made by the movement disorder specialists changed during follow-up: 3 initial ET diagnoses changed to 2 PD and 1 possible cerebrovascular disease; 2 initial diagnoses of non-specific basal ganglia dysfunction were diagnosed with benign tremulous PD; 11 cases (16%) had tremor disorders of uncertain diagnosis throughout. These results emphasise that a shift between diagnoses occurs between tremor and degenerative parkinsonism, which is less than ideal not least from a patient and carer perspective.

As ET is a relatively common disorder, some patients will develop both conditions, typically with initial features of ET and later the emergence of PD(49). The literature is inconclusive on the subject of whether there is a higher risk of PD developing in patients with ET, with some reports of no greater risk(50) and others of greater than expected risk(51;52). This uncertainty exists in part because clinical features of tremor sometimes fail to distinguish ET from PD cases. Prospective data is lacking on cases with initial normal functional imaging (in the ET phase) with subsequent

abnormal imaging (as PD develops), although there is some evidence for this process in rare families with a tendency to develop both ET and PD. The use of the term 'indeterminate tremor disorder'(53) is advocated by some to avoid the reversal of an initial incorrect diagnosis of ET or PD or even dystonic tremor. This definition applies to patients who satisfy the criteria of ET as set by the Tremor Investigation Group (TRIG) but exhibit other neurological signs of uncertain significance not sufficient to make the diagnosis of a recognisable disorder (for example, mild extrapyramidal features, such as hypomimia, decreased arm swing, or mild bradykinesia).

1c) Vascular parkinsonism

Arteriosclerotic or vascular parkinsonism was initially described by Critchley(54) in 1929 but the concept has been controversial since, particularly because the initial description was not backed up by neuropathological correlations. A number of descriptions exist which include 'lower body parkinsonism' which describes gait ignition failure and parkinsonism in the legs and the term 'vascular pseudo-parkinsonism' is perhaps more preferable in this context(55). Acute vascular parkinsonism, often secondary to lacunes in or near the ventrolateral nucleus of thalamus or globus pallidus externa tends to present with unilateral parkinsonism or shuffling gait with parkinsonism, whereas a more insidious type often related either to basal ganglia lacunes or diffuse small vessel disease more often presents bilaterally with shuffling gait, instability and falls, but later in the disease process these types are indistinguishable(56). An insidious onset with a latent period after acute stroke can also occur(56). Rest tremor occurs uncommonly but is not of the typical pill-rolling type, and the upper limbs are commonly affected(56). There may be associated features of pyramidal tract signs or dementia or emotional lability.

The levodopa response is reported to be less although some patients will exhibit a positive response(57) associated with lesions in or close to the nigro-striatal pathway, and therefore this is not useful to differentiate between disorders on an individual patient basis. It is misdiagnosed as Parkinson's disease up until death, and a form which is similar to progressive supranuclear palsy has been described(58).

Of 1500 consecutive patients assessed for movement disorders post-stroke, 5 developed parkinsonism after 3 months and 1 developed it 10 months post-stroke which persisted in 5 of the 6 patients for over 3 years(59). Vascular parkinsonism comprises 3 - 6%(60) of subjects with parkinsonism. A mean illness duration of 3.1 (range 1 to 9) years in a post-mortem series of 27 patients(61) and 10.9 (\pm 5.5) years in another series of 17 patients(56) was found in patients with a post-mortem diagnosis of vascular parkinsonism which is significantly different to the prognosis of Parkinson's disease. Co-existent vascular disease and Parkinson's disease worsens disease severity(62), and potentially could affect dopaminergic response although this has not been investigated.

Diagnostic criteria were proposed in 2004(56) as follows;

- a) *Parkinsonism: bradykinesia* and at least one of the following: rest tremor, muscular rigidity or postural instability (not due to primary visual, cerebellar, vestibular, proprioception dysfunction).
- b) *Cerebrovascular disease*, defined by evidence of relevant cerebrovascular disease on brain imaging (CT or MRI) or the presence of focal signs or symptoms that are consistent with stroke.
- c) *A relationship between the above 2 disorders.*

In practice:

- An acute or delayed onset with infarcts in or near areas that increase the basal ganglia motor output (globus pallidus externa or substantia nigra compacta) or decrease the thalamocortical drive directly (ventrolateral nucleus of the thalamus, large frontal lobe infarct). The parkinsonism at onset consists of a contralateral bradykinetic rigid syndrome or shuffling gait, within a year of stroke.
- An insidious onset of parkinsonism with extensive subcortical white matter lesions, bilateral symptoms at onset, and the presence of early shuffling gait, or early cognitive dysfunction.

1d) Drug-induced parkinsonism

Drug-induced parkinsonism is the second commonest form of parkinsonism after PD(63), involving dopamine antagonists used in psychiatry, and antiemetics.

Typically it presents with less tremor, and more symmetrical and milder parkinsonian features, however it may be indistinguishable from PD(64) with asymmetrical parkinsonism and all the cardinal features(65-68). Depending on referral patterns, as many as 51% of new cases may be associated with dopamine antagonist drugs(69).

The incidence of extrapyramidal side effects with low dose neuroleptics is 32%(70).

Drug induced parkinsonism (DIP) is easily recognised if there is a close relationship between onset of parkinsonism and use of dopamine depletors, but some patients can be taking drugs for years prior to onset of parkinsonism and recovery after drug can rarely take up to 18 months(71). "Unmasking" of pre-clinical PD by drug therapy has been confirmed at post mortem(72) and is reported in between 5 and 16% of drug-induced cases(15;73-76).

1e) Psychogenic movement disorders and psychogenic parkinsonism

A 'psychogenic' movement disorder is a term which encompasses movement disorders which are somatoform or factitious or due to malingering and may exist alone or in combination with underlying organic disease. However, the distinction between 'non-organic' and 'organic' disorders is grey. A comparison of regional blood flow in patients with weakness due to hysteria versus controls and feigners showed that patients with hysteria exhibited a significant relative hypoactivity in the left prefrontal area regardless of laterality of symptom onset, an area which is specifically related to the internal 'choice' of action(77). Some feel that psychogenic movement disorders are under-recognised(78), but psychogenic parkinsonism is probably quite rare. Twenty-eight (3.3%) of 842 consecutive patients presenting with movement disorders to a specialty movement disorder clinic were diagnosed with psychogenic movement disorders(79) of which tremor (50%) was the most common followed by dystonia(18%), myoclonus (14%) and parkinsonism (7%) and 25% were felt to co-exist with an underlying organic movement disorder. The outlook for patients with psychogenic movement disorders is not favourable with persistence in 90% after an average of 3.2 years follow-up and 95% of subjects have a diagnosis of mental illness(80). No examination finding or test specifically diagnoses psychogenic parkinsonism. The tremors of psychogenic parkinsonism and psychogenic tremor have the same characteristics including sudden onset, variable amplitude, variable type of tremor (complex) and evidence of remissions, distractibility, and entrainment of tremor frequency to another part of the body(81). Unlike true bradykinesia where there is a gradual reduction in amplitude and hesitation, the slowness found in psychogenic parkinsonism has a constant amplitude. Stiffness may be felt as a voluntary resistance to movement which differs from the cogwheeling or leadpipe rigidity in Parkinson's. The rigidity may decrease with synkinetic movements. The

arm may be held stiffly extended and adducted to the side, quite distinct to the reduced arm swing of PD(82).

Diagnostic criteria for psychogenic movement disorders have been adopted(83).

- Documented*: Persistent relief by psychotherapy, suggestion or placebo has been demonstrated, which may be helped by physiotherapy, or the patient was seen without the movement disorder when believing him- or herself unobserved.
- Clinically established*: The movement disorder is incongruent with a classical movement disorder or there are inconsistencies in the examination, plus at least one of the following three: other psychogenic signs, multiple somatisations, or an obvious psychiatric disturbance.
- Probable: The movement disorder is incongruent or inconsistent with typical movement disorder, or there are psychogenic signs or multiple somatisations.
- Possible: Evidence of an emotional disturbance.

*As only the first two categories provide a clinically useful degree of diagnostic certainty they have been combined to one category of "Clinically Definite".

These criteria may help to reduce inappropriate diagnosis of psychogenic movement disorders, but many physicians remain unwilling to positively and formally identify patients with psychogenic disorder because of clinical uncertainty and historical awareness of misdiagnosis of organic disorders as psychogenic.

1f) Dopa-responsive dystonia

Dopa-responsive dystonia is an autosomal dominant condition with reduced penetrance causing nigrostriatal dopamine deficiency due to defects in dopamine synthesis without dopaminergic cell loss. Onset is usually in childhood with crural

dystonia, imbalance and slowness with marked diurnal variation, parkinsonism and sustained response to low dose levodopa without the long term side effects noted with Parkinson's disease(84). Rarely, patients may have few (e.g. only exercise induced cramps or dystonic posturing) or no symptoms during childhood and develop pure parkinsonism after the age of 40.

1g) Juvenile onset Parkinson's disease or Young onset Parkinson's disease

Onset of parkinsonism under the age of 21 is described as juvenile parkinsonism and between 21 and 40 as young onset parkinsonism. Juvenile parkinsonism is very rare and most do not have Lewy bodies at post-mortem, whereas young onset Parkinson's patients do. Distinction needs to be made from other rare disorders causing parkinsonism such as DRD, Wilson's and the akinetic-rigid presentation of Huntington's disease(85).

1h) Parkinsonism and dementia

Dementia with Lewy bodies (DLB) accounts for 11% of community patients with dementia while Alzheimer's disease (AD) accounts for 31%(86); clinical features are at times similar. In DLB fluctuating dementia, visual hallucinations and hypersensitivity to neuroleptic medication coexist with parkinsonian features in 41 - 85%(87;88), but levodopa responsiveness is poorer than in PD and cognitive side effects greater(89). In AD progressive memory and higher cortical function decline, with neuropsychiatric features and myoclonus, which may be supplemented with parkinsonian signs in 5 -19% of cases(87;88). Parkinsonism in both conditions is milder than for PD, consisting mostly of rigidity and bradykinesia, while resting tremor is rare(90;91).

Clinical diagnostic accuracy for DLB improved from 50% in a clinicopathological study of 10 patients (in which 4 patients thought to have DLB had AD pathologically) to a sensitivity of 83% and specificity of 95% in part due to improved consensus criteria(92;93). In AD the positive predictive value of clinical diagnosis was 81% against autopsy(94). However, some patients with pathologically confirmed DLB who had been misdiagnosed in life with AD did not show any typical features of DLB normally used to separate the two conditions(95).

Extensive Lewy bodies are found in DLB and PD dementia (to distinguish the two, an arbitrary cut-off exists; if the onset of parkinsonism is more than 1 year prior to dementia then the diagnosis is PD dementia). Neurofibrillary tangles and senile plaques predominate in Alzheimer's. Included in the differential of these disorders is vascular dementia which can coexist and alter the clinical presentation. Corticobasal degeneration and Alzheimer's disease are sometimes mistaken as parkinsonism and apraxia can occur in both.

2. Adjuncts to clinical diagnosis

2a) Levodopa and apomorphine challenge tests

The clinical response to acute dopamine challenge can be a useful adjunct to clinical assessment. A meta-analysis on levodopa and apomorphine challenge testing found that sensitivity for the diagnosis of established Parkinson's disease was 75 - 86% and specificity was 85 - 87% for acute challenge tests(96). The improvement seen in PD can also be found in some patients with multiple system atrophy and progressive supranuclear palsy. Eighteen of 22 patients misdiagnosed with Parkinson's disease studied in the Brain Bank post-mortem series(1) had a definite initial response to levodopa. Caution is recommended in early untreated Parkinson's disease where the

false negative rate may be as high as 40%(97). A retrospective analysis of initial levodopa response in pathologically confirmed Parkinson's disease found 'nil and poor' recorded in 6/96 (6%), although 'moderate', 'good' or 'excellent' were more typical (17%, 53% and 24% respectively)(19).

2b) Olfactory testing

In the earliest stages of Parkinson's disease there is olfactory disturbance albeit asymptomatic. Whilst it is not at all specific, various combinations of tests including olfactory function are being assessed to develop screening tools for populations at high risk of PD(98-100).

2c) Genetic testing

A number of genetic loci have been identified in familial PD but it is a sporadic disorder in the majority of patients and genetic testing is recommended only in very selected circumstances(101).

2d) Structural brain imaging

CT and MRI Brain Imaging

Structural brain imaging with computed tomography (CT) or magnetic resonance imaging (MRI) is normal in Parkinson's disease and is used in the atypical case, to exclude parkinsonism caused by other pathologies such as hydrocephalus, cerebrovascular disease or tumours. Fairly specific abnormalities on conventional MRI in multiple system atrophy (MSA) in the putamen or infratentorial structures(102) have a low sensitivity in early disease when clinical diagnosis is less certain thereby limiting its usefulness as an aid to diagnosis in patients with inconclusive parkinsonism. In progressive supranuclear palsy (PSP), MR changes such as

atrophy of the superior cerebellar peduncle have low sensitivity(103). Advanced MR techniques such as diffusion weighted imaging may also be helpful to discriminate Parkinson's disease from atypical parkinsonism(104).

Transcranial Ultrasound

Transcranial ultrasound imaging of the midbrain through a bony window in the temporal area reveals increased acoustic signal within the substantia nigra (thought to reflect increased iron content) in Parkinson's disease but also in 9% of the normal population(105;106). It is currently being assessed as a screening tool for Parkinson's disease together with tests such as olfactory function(98;99) which have similar high sensitivity but insufficiently high specificity for individual use as diagnostic tools.

2e) Functional imaging

Functional Brain Imaging of the dopaminergic system

Indirect assessment of the presynaptic dopaminergic system involves radiolabelling fluoro-dopa (F-dopa), the vesicular monoamine oxidase transporter (VMAT) or the dopamine transporter (DAT) (Figure 1-1). The brain is imaged with SPECT (single photon emission computed tomography) or PET (positron emission tomography). F-dopa is a precursor of dopamine which is taken up by dopaminergic neurones and then dopa-decarboxylated by aromatic amino acid decarboxylase. Uptake of [¹⁸F]-dopa imaged with PET provides an assessment of dopa decarboxylation. Storage of the dopamine in synaptic vesicles via the vesicular monoamine transporter 2 can be imaged with [¹¹C] dihydrotetrabenazine PET. The dopamine transporter is a protein present only on the presynaptic dopaminergic neurone which actively re-uptakes dopamine and therefore regulates synaptic levels of dopamine. Single photon emission computerised tomography (SPECT) and positron emission tomography

(PET) are used to image ligands specific to the dopamine transporter, examples of which are,

- for SPECT; [¹²³I] FP-CIT, [¹²³I] β-CIT, [¹²³I] IPT, [^{99m}Tc] TRODAT
- and for PET; [¹¹C] CFT, [¹¹C] RTI-32.

Functional Brain Imaging of brain glucose metabolism with fluorodeoxyglucose (FDG) - PET

One hundred and thirty five patients with parkinsonism were referred for [¹⁸F] FDG PET to assist in the differential diagnosis and were followed up for an average of 2.1 years. Visual assessment of PET concurred with follow-up diagnosis in 88.4% for early PD, 97.2 % for late PD, 76% for MSA, 60% for PSP, 90.1% for CBD and 90.1% for normal volunteers. The concordance improved when an approach using statistical parametric mapping was used with a sensitivity of 100% and a specificity of 86% for a diagnosis of early PD as compared to normal controls(107).

Functional imaging of the myocardial sympathetic nervous system.

There is dysfunction of myocardial postganglionic sympathetic neurones in Parkinson's disease. Imaging of these neurones with Iodine-123 metaiodonenzylguanidine (MIBG) SPECT is abnormal in Parkinson's disease and may help differentiate PD from other disorders without postganglionic sympathetic dysfunction such as multiple system atrophy(108). The accuracy of this technique in the investigation of early disease is under investigation(109).

3. Functional Brain Imaging with dopamine transporter imaging

3a) Comparison to other dopamine imaging techniques.

DAT imaging enables in vivo demonstration of striatal dopamine activity (Figure 1-1). Results are in keeping with other observations (including autopsy studies) of the dopamine system(110-112). The DAT is a sodium chloride dependent protein on the presynaptic dopaminergic nerve terminal which controls dopamine levels by active reuptake of dopamine after its interaction with the post synaptic receptor(113). The DAT ligands for SPECT including [^{99m}Tc] TRODAT(114), [¹²³I] β-CIT(115), [¹²³I] IPT(116), [¹²³I] FP-CIT(117), have all shown significantly reduced striatal uptake in PD, including some rarer genetic forms(118;119). Abnormal uptake progresses from putamen to caudate, and matches contralaterally the clinically more affected side. The time of scan acquisition varies: 20 to 24 hours for [¹²³I] β-CIT; 3 to 4 hours for [¹²³I] FP-CIT(120) and 4 hours for [^{99m}Tc] TRODAT(121). Image analysis uses quantitative region of interest (ROI) ratios and/ or qualitative visual grading. Striatal uptake is typically calculated in relation to a reference site with negligible DAT density (occipital or cerebellar cortex). Ligands differ, preventing direct comparison: the normal striatal ratio for [¹²³I] FP-CIT was 2.3 in one study while for [¹²³I] β-CIT it was 5.5(122); for [^{99m}Tc] TRODAT the normal striatal ratio was approximately 2(121). DAT imaging is reproducible: test/retest variability in health controls and PD was 7% for [¹²³I] FP-CIT(123) and 13% in controls and 17% in PD for [¹²³I] β-CIT(124).

The effect of drugs on DAT expression needs consideration. Central nervous system stimulants (amphetamine, sympathomimetics including some nasal decongestants) are stopped for 4 weeks to prevent interaction. Theoretically an up-regulation of DAT expression secondary to dopamine excess should occur in patients treated with antiparkinson medication, but this has not been identified in animal or human drug studies(125). Antiparkinsonian therapy showed no significant effect on striatal [¹²³I] β-

CIT uptake with L-dopa or selegiline over 4 - 6 weeks(126) nor with pramipexole or levodopa over 10 weeks(127) and [¹²³I] FP-CIT uptake did not change in patients taking levodopa monotherapy chronically after a washout period of 20 days(128). Pergolide was associated with a non-significant trend to increase striatal [¹²³I] β-CIT uptake over 6 weeks(129). Effects of chronic antiparkinson therapy on DAT expression are less well studied, partly because of the interaction with changes from disease progression.

Downregulation of DAT in early PD in an effort to maintain synaptic dopamine levels(130) does not negatively affect the sensitivity of the SPECT technique(131;132), even in very early presentation(133) and probably increases its sensitivity compared to [¹⁸F]-dopa PET. DAT abnormalities in patients with unilateral parkinsonism (Hoehn and Yahr 1) suggest significant preclinical dopaminergic nerve cell loss(134-136) and symptom threshold has been estimated from studies of patients with hemiparkinson's disease at between 42% and 64%(114;135-139) reduction of dopamine transporter uptake compared to controls. [¹²³I] β-CIT identified asymptomatic cases amongst anosmic relatives of patients with PD(140). Striatal uptake correlates with duration and severity assessed by the Unified Parkinson Disease Rating Scale (UPDRS) motor scores and Hoehn and Yahr (H & Y) scores(134;141) and with age(142;143). The yearly rate of loss (or progression) of presynaptic dopaminergic neurones can be assessed by the reduction of the striatal uptake of radioligands and rates are similar whether assessed by dopamine transporter imaging radioligands (SPECT or PET) or [¹⁸F]-dopa PET and is in the region of 3 - 13% for PD and 0 - 2.5% in normals(115;127;144-156) and has become the focus for testing potentially neuroprotective drugs.

DAT imaging is considered safe and radiation doses acceptable being roughly equivalent for a [¹²³I] FP-CIT scan and a CT brain scan. A number of economic

assessments of the utility of DAT in patients with uncertain parkinsonism in different populations have been performed, with cost savings apparent at a prevalence of underlying true parkinsonism in the test population of 50% and below(157;158).

3b) Clinical application of dopamine transporter imaging

In clinical practice DAT imaging assists mainly in patients in whom there is diagnostic doubt between true parkinsonism and other movement disorders. Testing may occur at baseline, or when clinically acceptable, after a period of monitoring which may include assessing therapy responses.

Parkinsonism versus Essential Tremor

The typical unilateral parkinsonian 4 - 6 Hz rest tremor is readily distinguished from the isolated postural symmetrical 6 - 12 Hz essential tremor. Additional parkinsonian features can secure a clinical diagnosis. However resting and postural tremor often coexist in both ET and PD(159). In PD, the action tremor may take two forms, a pure action tremor with no latent period which occurred in 61% and a tremor that occurs after a latent period, known as re-emergent tremor and thought to represent a form of rest tremor, which occurred in 32% at a mean of 8 (SD 5) years after symptom onset and correlated to the severity of a rest tremor but not rigidity or bradykinesia(159). The tremorolytic effect of alcohol or propranolol is not specific to ET; the action tremor of PD responded in 46% of cases(46). When bradykinesia, rigidity or postural instability are mild or absent in early disease or have possible alternative causes, DAT imaging may prove invaluable in guiding accurate diagnosis and treatment plans. DAT studies are consistently normal in ET(160-162) in keeping with post mortem findings(47). Specificity of 100% (all of 27 cases) fulfilling clinical criteria for ET, and revision of diagnosis following normal [¹²³I] FP-CIT results, with a 97% (154 out of 158) sensitivity for parkinsonism, provided the cornerstone for the

technique(161). Clinical diagnostic inaccuracy has been highlighted in further DAT imaging series: between 2%(127) and 14%(163) of patients labelled PD had normal [¹²³I] β-CIT, and 15% of early true parkinsonism diagnoses by movement disorder specialists and 30% of community neurologist diagnoses had normal [¹²³I] β-CIT SPECT, with increased congruence between imaging and clinical diagnoses at 6 months(164). Longer follow up and ideally pathological confirmation is needed for a definitive resolution of rare persisting clinical image mismatches. Cases of possible ET (short-duration postural tremor, no other neurological features) consistently have normal DAT imaging(160;165), while mixed rest and postural tremor may be abnormal even in the absence of other significant parkinsonian features (2 of 6 cases)(165). Abnormal dopamine transporter imaging was found in patients presenting with long duration asymmetrical isolated postural tremor initially diagnosed as ET and later fulfilling PD criteria(21). Inconclusive parkinsonian signs and normal [¹²³I] FP-CIT led to a change of diagnosis to essential tremor in 5 of 24 cases(166). In conclusion, DAT imaging is helpful in tremor disorders particularly mixed postural and rest tremor with otherwise equivocal parkinsonian features.

Idiopathic Parkinson's Disease versus Atypical Parkinsonism

Clinical features of PD and atypical parkinsonian syndromes (PSP, MSA, CBD) overlap, but emerging "red flag" features often assist differentiation. A trend towards more symmetrical DAT loss in MSA and PSP compared to PD(167;168) and CBD(169) does not help individual case definition(168;170).

Combined DAT imaging and postsynaptic D2 receptor imaging may differentiate PD (DAT abnormal, D2 normal) from MSA and PSP (DAT and D2 both abnormal)(170). [¹²³I] β-CIT and [¹²³I] IBF were separated by one week but a combined [^{99m}Tc] TRODAT-1 and [¹²³I] IBZM or [¹²³I] IBF SPECT suggests that image quality is adequate from simultaneous studies of DAT and D2(171). D2 imaging itself seems

to have poor sensitivity in early atypical parkinsonism, normal postsynaptic imaging in the early stages of an atypical disorder does not exclude MSA, PSP or CBD(172). Group analysis of brain blood flow with [^{99m}Tc] ECD SPECT in patients with MSA or PD may aid differentiation of groups, but is unlikely to help differentiation in individuals(173).

Parkinsonism versus Vascular Pseudo Parkinsonism (VP)

Vascular parkinsonism (VP) in its classic form has predominantly lower body involvement with rigidity, short shuffling gait, less tremor, and poorer levodopa response than PD(174), but there is a wide spectrum of clinical manifestation and VP and PD may co-exist(175). [^{99m}Tc] TRODAT SPECT tested normal in 14 patients with VP and distinguished VP from PD(176). A [¹²³I] β-CIT study showed a 40% age corrected reduction in PD, greater left-right asymmetry, and lesser putamen-caudate ratios, all of which contrasted with near normal levels in VP(177). Typical PD DAT abnormalities were found in 11 of 20 patients initially fulfilling vascular parkinsonism diagnostic criteria challenging the concept of vascular parkinsonism as a distinct entity and suggesting that cerebrovascular disease often co-exists with underlying PD(178). DAT imaging may be abnormal in VP if there is focal basal ganglia infarction but the pattern of this "punched-out" SPECT deficit differs from the PD pattern(179).

Dementia with Lewy Bodies versus Alzheimer's Disease

The post mortem evidence of dopamine dysfunction in DLB (72% reduction) and normal DAT in Alzheimer's disease(180) is largely confirmed in vivo: DAT binding was reduced in 27 patients with DLB and normal in 17 cases of Alzheimer's disease, in caudate and anterior putamen. However, contralateral posterior putamen activity was 10% lower in AD than in controls, possibly due to age differences or inadvertent

inclusion of DLB patients misdiagnosed as AD(181). Post mortem diagnosis in 10 cases correlated better with [¹²³I] FP-CIT than with clinical diagnosis which showed a tendency to overdiagnose DLB. A sensitivity of 78% and a specificity of 94% with a positive predictive value of 90% was found when [¹²³I] FP-CIT SPECT was used to separate AD and DLB groups fulfilling criteria, and of note 3 patients with DLB and no parkinsonism had abnormal DAT uptake although it was noted that further studies are required to assess accuracy of this technique in pre-motor DLB(182).

Regional cerebral perfusion with [^{99m}] Tc-HMPAO or [^{99m}] Tc-ECD are abnormal in both AD and DLB but with different perfusion patterns. In DLB the temporal-parietal hypoperfusion typical of AD is present but in addition occipital "horseshoe" hypoperfusion was noted (6 of 7 patients). Combination perfusion and DAT studies may differentiate difficult cases(183). In conclusion DAT imaging differentiates AD for DLB, but it should be noted that DAT imaging may be abnormal in any dementia with nigrostriatal degeneration (e.g. fronto-temporal dementia with parkinsonism)(184). While post mortem is the gold standard, imaging studies are important with developments in dementia drug therapy.

Parkinson's Disease versus Drug Induced Parkinsonism

Parkinson's disease and DIP can present identically. Unmasking of subclinical PD by dopamine depletors occurs in a small but significant proportion of drug-induced cases(15;73-76) and antipsychotic medication withdrawal is not always desirable or achievable. As DAT density in the striatum is not altered by antipsychotic medication (because of the postsynaptic (D2) site of action of these drugs(185)) DAT imaging is potentially useful to differentiate those patients with pure drug-induced forms from those with underlying degenerative parkinsonism(65;122;186), especially in cases of unexpectedly severe or prolonged parkinsonism.

Dopa-Responsive Dystonia

Dopa-responsive dystonia (DRD) and juvenile Parkinson's disease (JPD) are young-onset familial disorders with parkinsonism and dystonia. Clinical distinction is important as prognosis and levodopa benefit differs. Imaging with [¹²³I] β-CIT SPECT and [¹²³I] FP-CIT shows normal dopamine transporter density in DRD and abnormal activity in JPD and PD(187-190). Imaging of the presynaptic striatal dopaminergic neurones with [¹⁸F] - dopa PET is normal even in the later onset cases with pure parkinsonism(191). Diagnostic difficulty such as in cases with negative family history can be assisted by DAT imaging.

Psychogenic Tremor Disorders

Clinically, psychogenic disorders are often complex with resting, postural and kinetic components and diagnosis is easier in the presence of variable tremor frequency, distractibility, or absence of other neurological signs(81). Diagnosis tends to be one of exclusion and is a protracted process, particularly when supporting features are not present. DAT imaging aids differentiation of psychogenic tremor from its main differential of PD(166;192;193) and has been used in combination with electrophysiological tremor recordings to improve diagnostic confidence(194).

Other Uses for Dopamine Transporter Imaging

Abnormal striatal DAT occurs in Wilson's disease to a level comparable with PD(195). [¹²³I] TRODAT-1 striatal uptake was significantly reduced in 10 patients with spinocerebellar ataxia (SCA) 3 (Machado Joseph Disease)(196) and [¹²³I] FP-CIT is reduced in patients with SCA2 without parkinsonism(197) and in SCA17(198). Striatal [¹²³I] IPT binding was moderately reduced in 18 patients with sporadic amyotrophic lateral sclerosis(199). [¹²³I] FP-CIT is normal in patients with mitochondrial disorders such as chronic progressive external ophthalmoplegia(200). In Gilles de la Tourette syndrome striatal [¹²³I] β-CIT binding was 37% higher than

healthy controls(201). [¹²³I] β-CIT binding is normal in idiopathic cervical dystonia(202). [¹²³I] β-CIT and [¹²³I] IPT is normal in patients with restless leg syndrome(203). Dopamine transporter imaging has been studied in small numbers in schizophrenia, alcohol dependence, cocaine, and methamphetamine dependence but these should be considered exploratory studies.

Abnormal striatal uptake of [¹⁸F]-dopa PET in patients with neuroacanthocytosis, dentato-rubro-pallido-luysian atrophy and post-encephalitic parkinsonism has been described(204-207), although not reported with dopamine transporter imaging but one would expect similar changes.

The impact of DAT imaging in patients with inconclusive parkinsonian syndromes.

In inconclusive parkinsonism there are only 2 blinded prospective studies of the utility of dopamine transporter imaging, and both found the imaging diagnosis (of degenerative parkinsonism or not) to have a higher sensitivity and specificity than a specialist neurologist diagnosis at baseline when compared to a gold standard of blinded specialist diagnosis at 3(133) or 6 months(208;209). However, it has not yet been validated with longer term follow-up studies of patients with early tremor disorders to ensure congruence and to confirm correct clinical diagnoses.

Application of DAT imaging in clinical case series guides application in routine practice as reported in the following 3 studies. In 33 patients with inconclusive parkinsonism followed for 2 - 4 years, 24 had no dopamine deficit, of whom 19 were diagnosed as non presynaptic parkinsonism, 3 had no confirmed diagnosis, one had MSA and one had PD. These 2 cases were described as clinically atypical(166). A therapy change was instigated in 72% of 118 patients after [¹²³I] FP-CIT SPECT imaging results(210). A significant change in management or treatment was

undertaken in 28% of 90 patients studied retrospectively; scan results correlated well with clinical diagnoses during 14 months' observation(186).

3c) Subjects with a clinical diagnosis of Parkinson's disease with scans without evidence of dopaminergic deficit (SWEDD's)

Between 4 and 14% of patients diagnosed with early Parkinson's Disease and enrolled into trials of potential neuroprotective agents by movement disorder specialists have unexpectedly normal F-dopa or DAT imaging(163;211;212). These cases have been labelled as Subjects with scans Without Evidence of Dopaminergic Deficit (SWEDD's) and the interpretation of their significance is debated(213-215).

There are three possibilities:

1. Patients have been misdiagnosed as having Parkinson's disease and have a non-degenerative disorder such as essential tremor, vascular parkinsonism or drug-induced parkinsonism.
2. Patients have Parkinson's disease but of a type not associated with nigrostriatal dysfunction.
3. The sensitivity of the imaging in early Parkinson's disease is poor due to false negative results.

Braaks' proposed neuropathological staging of Parkinson's disease suggests that nigrostriatal degeneration occurs at stage 3 after neuronal loss and Lewy body formation in the glossopharyngeal and olfactory nuclei(23). Theoretically, imaging prior to stage 3 should be normal. Stages 1 and 2 may manifest with anosmia or other non-motor features which are usually asymptomatic and in Braaks' study these subjects had escaped clinical recognition as PD. Because parkinsonism occurs after severe nigrostriatal depletion of 50 - 80%(24;25) and presynaptic dopaminergic

imaging detects 42 - 64% depletion in the asymptomatic putamen of patients with hemiParkinson's disease(114;135-139), imaging would be expected to be abnormal.

Evidence of misdiagnosis comes from a number of sources. If the imaging technique had low sensitivity, but a progressive loss of uptake of 3 - 13% per annum(115;144-148;151;152;154;156) then normal images would become abnormal over time. In each of REAL PET(212), CALM-PD(211) and ELLDOPA(163) imaging was repeatedly normal up to 48 months. No progressive loss of radioligand uptake was seen on serial measurements over 48 months within the putamen in SWEDD's although this was seen in subjects with PD and abnormal scans(213). There is some evidence of an inverse relationship between the proportion of SWEDD's and the duration of disease, at least in the clinical trial population(163;211;212;215). Thus the accuracy of a PD diagnosis increases with longer follow-up. In ELLDOPA, SWEDD's did not have any response to levodopa even at high doses, which distinguished them from those with dopaminergic deficit(163). Further, the clinical validity of normal scans was supported by blinded video review of patients in ELLDOPA; 7 of 13 SWEDD patients (54%) were thought unlikely to have PD by 3 or more out of 5 raters compared to 3 of 72 patients (4%) with abnormal scans(216). Finally, further evidence that movement disorder specialists do misdiagnose PD on entry into drug studies is found in follow-up of patients within the DATATOP study where 8.1% had alternative diagnoses after 7.6 years although this included some cases of other degenerative parkinsonism(6).

4. Summary of DAT imaging areas that require clarification

Within the field of diagnostic dopamine transporter imaging there are therefore a number of questions that require clarification:

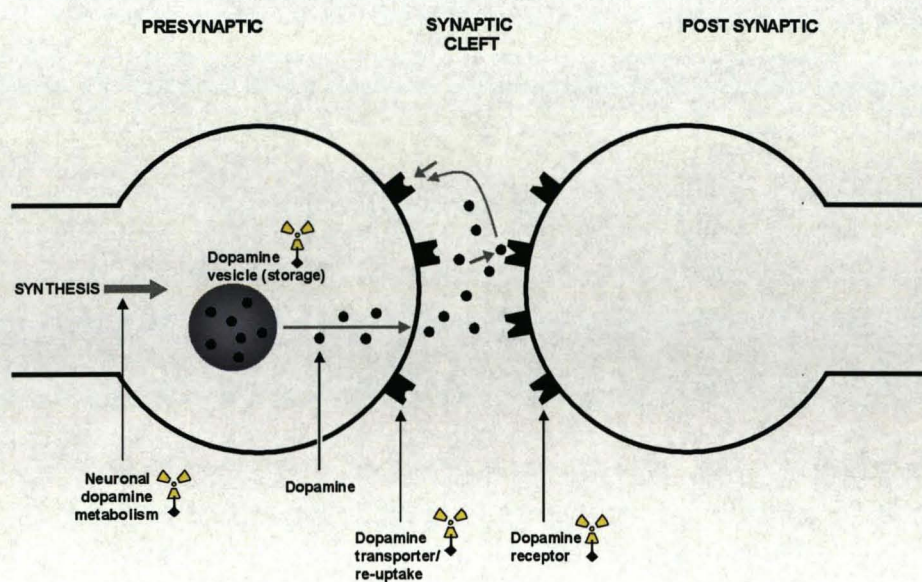
How do the findings of high accuracy of dopamine transporter imaging shown in those who fulfil criteria for Parkinson's disease and essential tremor(161;162) translate to its use in routine clinical practice?

How useful is DAT imaging to differentiate between degenerative parkinsonism and other mimics such as drug-induced parkinsonism or vascular parkinsonism and is it just as useful in each condition?

What is the accuracy of DAT imaging in early, uncertain parkinsonian conditions?

What is the meaning of normal DAT imaging in subjects with a PD diagnosis (SWEDD's)?

Figure 1-1 Schematic diagram of the pre and post synaptic dopaminergic neurone with reference to the specific components which can be radiolabelled and imaged with PET or SPECT



| | Presynaptic | | Postsynaptic |
|-------|--|--------------------------|--|
| | Dopamine re-uptake (DAT) | Dopamine storage (VMAT2) | Dopamine metabolism (DDC) |
| | D2 receptor | | |
| PET | [¹⁸ F] or [¹¹ C] CFT, FP-CIT or β-CIT. [¹¹ C] RTI-32 [¹¹ C] nomifensine | [¹¹ C] DHTBZ | [¹⁸ F] dopa [¹¹ C] raclopride |
| SPECT | [¹²³ I] β-CIT [¹²³ I] FP-CIT [¹²³ I] IPT [¹²³ I] altropane [^{99m} Tc] TRODAT | | [¹²³ I] IBZM |

Chapter 2 : UK FP-CIT Case Collection Study

**Overview: Application of [¹²³I] FP-CIT SPECT in
clinical practice in the United Kingdom, experience in
190 patients with uncertain parkinsonism**

Introduction

Several reports conclude that presynaptic dopaminergic imaging is useful in the differential diagnosis between degenerative and non-degenerative disorders featuring parkinsonism and/ or tremor(133;161;162;164;166;186;210;217). Sensitivity ranges between 82 and 100% and specificity between 69 and 100%. However, there is an inherent bias in defining sensitivity and specificity when the results of the test under scrutiny have contributed to the working clinical diagnosis(166;186;210;217). With the exception of dementia conditions (and considering the differential diagnosis between Alzheimer's disease and Lewy body dementia), in which autopsy results corroborate dopaminergic imaging results(181), the veracity of the imaging results are primarily based on clinical diagnosis with follow-up for periods varying between 3 months(133;164;186) and 4 years(166;217). The resulting lack of a 'truth' standard led one group to suggest that such testing was not yet appropriate in clinical care(218). On the other hand, [¹²³I] FP-CIT SPECT scanning is licensed in Europe for the differential diagnosis of tremor and parkinsonism, and is in widespread use. An alternative approach to examine clinical utility is to study the effect of conducting dopamine transporter imaging on the prevailing clinical diagnosis. If the test is contributory to accurate diagnosis and management in clinically uncertain parkinsonism/ tremor, changes in diagnosis and treatment plan post-scan should occur compared to pre-scan. Results might differ, and clinical utility vary, according to the clinical question raised and the potential differential diagnoses. Further, the presence of cardinal clinical features of degenerative parkinsonism should relate to abnormal [¹²³I] FP-CIT scanning, more so when such features are definite than when they are possible(133).

The present study therefore examined the clinical application of [¹²³I] FP-CIT SPECT in patients with uncertain parkinsonism with 'paired' differential diagnoses (in each

case degenerative versus non-degenerative parkinsonism/ tremor). The predicted and actual scan result was compared, and the mismatch rate compared amongst the diagnostic pairings. This approach also allowed quantification of the proportion of [¹²³I] FP-CIT SPECT scans in which a clear differentiation could be made between normal and abnormal, which is crucial in clinical care in the patient with clinical uncertainty(219).

Methods

A multicentre prospective study in patients with uncertain parkinsonism where [¹²³I] FP-CIT SPECT scanning was undertaken. Participating centres included Glasgow (x2), Aberdeen, Preston, London, Southampton, Northampton and Surrey. Patients with a definite or established clinical syndrome were excluded. Baseline clinical features and working diagnosis were registered centrally prior to imaging.

Diagnostic pairings were between

- degenerative parkinsonism (idiopathic Parkinson's disease, Dementia with Lewy Bodies, multiple system atrophy, progressive supranuclear palsy or corticobasal degeneration)

and the following:

- essential tremor (ET) or 'benign' tremor;
- drug-induced parkinsonism (DIP);
- vascular parkinsonism (VP);
- dementia (Alzheimer's or vascular);
- psychogenic parkinsonism and
- dopa-responsive dystonia.

Any change in diagnosis after the referring clinician had reviewed the SPECT was recorded. Features were reported definite, possible or absent for each of rest and postural tremor, bradykinesia, rigidity and postural instability. Antiparkinson medication use, and the use of drugs with potential to cause drug-induced parkinsonism, previous and current, was recorded.

Imaging procedures

[¹²³I] FP-CIT SPECT was performed according to standardised methodology at each centre. Dopaminergic and other medication were continued except for agents that interfere with striatal [¹²³I] FP-CIT uptake (central nervous system stimulants, anti-anorexia and obesity treatments and sympathomimetics).

Data processing

[¹²³I] FP-CIT SPECT scans were evaluated at each site in conjunction with clinical details. Visual grading was described as previously(161;179): *normal* for largely symmetrical uptake in putamen and caudate nuclei; *abnormal grade 1* for asymmetrically reduced putamen activity; *abnormal grade 2* for significant bilaterally reduced putamen uptake with activity confined to the caudate nuclei; and *abnormal grade 3* for virtually absent uptake bilaterally affecting both putamen and caudate nuclei; *abnormal - focal* as due to a structural lesion as detailed previously; and *abnormal - other* if abnormal ligand uptake was in an atypical pattern (e.g. caudate loss greater than putamen, without a focal pattern). In calculating mismatches between clinical and imaging findings, an abnormal image (grade 1, 2 or 3) was defined as degenerative parkinsonism, while a normal or focal pattern was defined as non-degenerative, since a focal striatal vascular lesion does not always produce motor symptoms(220)). Abnormal (other) scans were considered separately.

Semiquantitative assessments for data sets acquired with the multidetector single slice system (SME 810, Neurofocus™) were performed in one centre using predetermined region of interest templates were from *Talairach Daemon* (online at <http://ric.uthscsa.edu/projects/talairachdaemon.html> accessed July 14th 2006) and based on the Co-planar Stereotaxic Atlas of the Human Brain(221). Specific: non-specific ratios were calculated from three adjacent axial slices through the regions of interest (ROI). The occipital region was used as reference for ROI analysis. The mean specific:non-specific ratios were calculated from the right and left-sided readings. Striatal readings were designated contralateral or ipsilateral according to the symptom onset side. A correction factor of 4% per decade was applied for each subject in keeping with published reports(137).

Chapters relating to the UK Case Collection are arranged as follows:

- This chapter (2) provides an overview of all cases and allows comparison of the application of [¹²³I] FP-CIT SPECT within different subcategories and identification of patterns of diagnostic change across the different diagnostic pairings.
- Chapters 3 & 4 relate to [¹²³I] FP-CIT SPECT use in tremor disorders (mostly essential tremor) and drug induced parkinsonism respectively allowing appraisal of use and investigation of clinical features within these subgroups.

Results

One hundred and ninety patients (96 females: 94 males) aged 27-89 years (mean 65, SD 13) underwent [¹²³I] FP-CIT SPECT in 8 centres. Around two thirds of these patients were contributed from the Glasgow site. In all patients diagnosis was judged inconclusive by the referring specialist. [¹²³I] FP-CIT SPECT was performed 1.3 months after entry (95% CI 0.9 -1.7). Antiparkinson medication was used previously

but now discontinued in 7 (4%), currently in 37 (19%), never in 142 (75%) patients and not documented in 4 (2%).

Of 190 patients entered, 101 patients (53%) had a pre-scan diagnosis of a non-degenerative parkinsonian syndrome. SPECT was normal in 72 of those (71%) and abnormal in 29 (29%), consisting of 22 with a degenerative parkinsonian pattern, 4 with focal lesions and 3 'other'. The post-scan diagnosis was amended to degenerative parkinsonism in 20 of the 22 cases with abnormal SPECT in a parkinsonian distribution.

Eighty nine (47%) had a pre-scan diagnosis of degenerative parkinsonism, of whom 63 (70%) had an abnormal (degenerative parkinsonian) pattern ($n = 60$) or other pattern ($n = 3$). Twenty-six of this group of 89 (30%) had normal imaging; in 23 of these the post-scan diagnosis was amended (Table 2-1). SPECT results according to baseline diagnosis as degenerative or non-degenerative parkinsonism are shown in Figure 2-1.

Overall the SPECT diagnosis and pre-scan clinical diagnosis disagreed in 49/190 (26%), and agreed in 135 (71%) patients. In 6/190 (3%) the scan was abnormal (other). Excluding cases with abnormal (other) SPECT, congruence improved to 179/182 (98.5%) between imaging and post-scan diagnosis (Table 2-2). Definite bradykinesia or definite rigidity were the strongest individual predictors of an abnormal SPECT. The strongest combined predictor of abnormal SPECT was definite bradykinesia, rigidity plus rest tremor (Table 2-3).

Discussion

This study reflects current application of [123 I] FP-CIT SPECT in multiple United Kingdom centres. It is a unique prospective evaluation of the effect of [123 I] FP-CIT

SPECT when considering diagnostic pairings in patients with tremor/parkinsonism. The study, and the proportion of potential drug-induced, psychogenic, or vascular causes, is one of the largest series involving functional diagnostic imaging.

Concurrence rate in different diagnostic pairings

Overall, the imaging result concurred with a similar proportion of cases when the clinical pre-scan diagnosis was non-degenerative parkinsonism (75%) as when it was degenerative parkinsonism (69%).

However, the concurrence rate was only 44% for a pre-scan diagnosis of vascular parkinsonism, suggesting that degenerative parkinsonism is under diagnosed in patients with vascular risk factors. The clinician agreed with the abnormal scan in this group, changing the diagnosis to degenerative parkinsonism in 91% post-scan.

Vascular parkinsonism represents 3 - 5% of cases of parkinsonism(55) with some evidence of under(61) or over diagnosis(1). Co-existence of PD and cerebrovascular disease is 10 times more common than vascular parkinsonism alone(55), and cerebrovascular disease alters the phenotype of PD(62). Some imaging studies find normal or near-normal scans(176;177). A focal pattern matching structural change(179) was seen in 2% of our patients, not all of whom had a VP diagnosis, which is in keeping with asymptomatic striatal infarctions(220). Although almost half of the cases diagnosed as VP in two series had subnormal uptake(178;217) this was interpreted as coexisting degenerative parkinsonism, and in one series such patients were more likely to respond to levodopa(178). While uptake ratios may be reduced in VP, the pattern of abnormality is more symmetrical than in PD(177). The present results in the context of prior reports suggest that VP is likely when the scan is normal or shows a focal deficit, and is unlikely when graded putamenal then caudate loss is seen in the typical PD pattern.

Psychogenic parkinsonism is a rare but challenging diagnosis. In patients within this category, the scan agreed with a pre-scan psychogenic parkinsonism diagnosis in most (93%), much higher than the abnormal imaging rate (5 of 9 cases, 56%) in suspected psychogenic cases reported recently(194). However, in our series half of those patients where the pre-scan differential favoured degenerative rather than psychogenic parkinsonism had normal scans. An abnormal scan in this setting had a more specific effect on diagnosis (leading to a diagnosis of degenerative parkinsonism), but a normal scan led to a revised diagnosis of psychogenic PD in only half, others being labelled 'benign tremor disorder'. Adjunctive electrophysiological testing and prolonged clinical assessment has been suggested(194), but an alternative diagnosis may supervene.

For a differential between drug-induced parkinsonism and degenerative parkinsonism 27% had abnormal imaging, which is lower than a rate of between 30%(222) and 55%(65) reported in series of neuroleptic-induced parkinsonism. Differentiation is sometimes difficult as DIP can strongly mimic PD, with asymmetrical parkinsonism and cardinal features(65-68), improvement can be lengthy after drug cessation(71) and unmasking of presymptomatic PD occurs in between 5 and 16% of drug-induced cases(15;73-76).

A change in diagnosis post-scan occurred in a quarter of cases (with increased congruence to imaging) but was more likely to occur in subgroups where parkinsonism was associated with dementia (43%) or dystonia (44%) than essential tremor (12%), vascular parkinsonism (29%), drug-induced parkinsonism (27%) or psychogenic parkinsonism (15%).

Overall, 31% of patients thought more likely to be degenerative parkinsonism before imaging had normal scans, although rates were higher (50 to 67%) within dementia,

psychogenic, and dystonic subcategories. The rate dropped to 2% post-scan, reflecting a strong influence of the scan result on clinical interpretation. Normal presynaptic dopaminergic imaging in patients diagnosed as early PD occurs in between 4 and 14% of cases entered in neuroprotective studies(127;147;212), which have been termed 'subjects with scans without evidence of dopaminergic deficit' (SWEDD's). Repeat normal imaging in these studies up to 48 months(127;147;212) found no evidence of progressive decline in uptake(213) which is counter to the anticipated reductions if PD was the correct diagnosis. Additionally patients with normal scans showed no therapeutic response even to high doses of levodopa(147) and blinded specialist video reviewers thought PD unlikely in 53% of SWEDD patients compared to only 4% with abnormal scans in ELLDOPA(216). Although there is theoretical potential for PD to test normal with SPECT scan(214), this occurrence is rare.

Ninety-seven percent of images were readily categorised in this study, leaving only 6 cases (3%) where the images did not fall into a recognisable pattern. Three (1.5%) had mildly reduced or borderline normal uptake whereas 3 (1.5%) had markedly reduced uptake in an atypical pattern. Atypical patterns may occur in atypical parkinsonian disorders where a symmetrical diffuse reduction of striatal uptake can occur, but this is not sufficiently discriminatory to differentiate PD from either MSA/PSP or CBD(167;168;223;224). Two of 3 cases with borderline normal SPECT results were within the possible drug-induced category (1 neuroleptic, and 1 valproate). These cases may be examples of pre-symptomatic degenerative parkinsonism being unmasked by dopamine depleting drugs(219). SPECT was borderline in a similarly small proportion of cases of clinically uncertain parkinsonism in two other studies: between 1%(210) and 6%(186). In such cases, visual assessment, semiquantitative data, and age matching along with caudate/ putamen

asymmetry indices and with structural imaging may be helpful together with clinical monitoring.

It is notable that each of the cardinal features of PD is more definite when the scan is abnormal. This was reported previously(133), but in the current study the proportion of patients with definite signs and normal scans was higher, such that 43% of cases who fulfilled Brain Bank criteria part 1 had normal imaging. As expected, postural tremor had a stronger association with normal scans than other clinical features.

In inconclusive parkinsonism there are only 2 blinded prospective studies of the utility of dopamine transporter imaging, and both found the imaging diagnosis (of degenerative parkinsonism or not) to have a higher sensitivity and specificity than a specialist neurologist diagnosis at baseline when compared to a gold standard of blinded specialist diagnosis at 3(133) or 6 -12 months(209;216). Our study does not define the accuracy of dopamine transporter imaging but provides measures of its clinical utility in routine practice and identifies which categories of patients appear to have higher rates of misdiagnosis of parkinsonian conditions.

Conclusion

This large multicentre study found that in patients with diagnostic uncertainty between pairings of degenerative and non-degenerative parkinsonism, [¹²³I] FP-CIT SPECT categorised 97% of scans as either normal or abnormal (degenerative, or focal). In one quarter of patients, the baseline clinical diagnosis was inconsistent with the SPECT result, leading invariably to a revised clinical diagnosis. In the 3% of patients with other abnormal /borderline [¹²³I] FP-CIT SPECT results, diagnosis remains less certain.

Table 2-1 Pre and post-scan most likely diagnoses and [¹²³I] FP-CIT SPECT result in 190 patients with clinically uncertain parkinsonism

| Diagnosis pre-scan | [¹²³ I] FP-CIT SPECT result | Diagnosis post-scan |
|--|--|---|
| <i>[¹²³I] FP-CIT SPECT expected to be normal (or focal) (101)</i> | | |
| Non-degenerative parkinsonism (101) | Normal (72) | Non-degenerative parkinsonism (70) Not yet diagnosed (1) Normal (1) |
| | Abnormal grade 1,2 or 3 (22) | Degenerative parkinsonism (21) Non-degenerative parkinsonism (1) |
| | Abnormal (focal) (4) Abnormal (other) (3) | Non-degenerative parkinsonism (4) Non-degenerative parkinsonism (1) Uncertain (2) |
| <i>[¹²³I] FP-CIT SPECT expected to be abnormal (degenerative parkinsonism pattern) (89)</i> | | |
| Degenerative parkinsonism (89) | Normal (26) | Non-degenerative parkinsonism (23) Degenerative parkinsonism (2) Normal (1) |
| | Abnormal grade 1,2 or 3 (60) | Degenerative parkinsonism (60) |
| | Abnormal (other) (3) | Degenerative parkinsonism (1) Non-degenerative parkinsonism (1) Uncertain (1) |

For definitions of scan grades see text

Figure 2-1 Visual assessment of [¹²³I] FP-CIT SPECT according to baseline diagnosis in 190 patients with uncertain parkinsonism

- a. (upper panel) patients with an initial diagnosis of degenerative parkinsonism
 b. (lower panel) patients with an initial diagnosis of non-degenerative parkinsonism

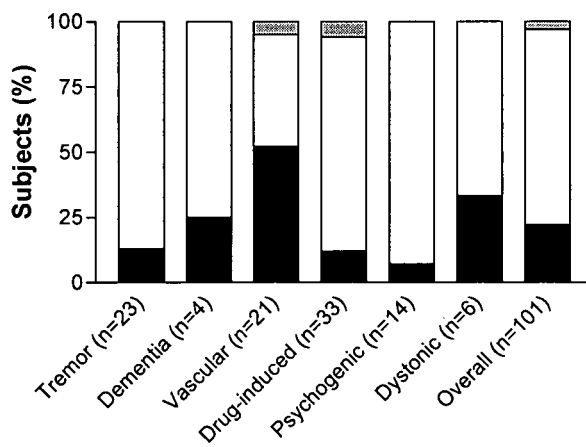
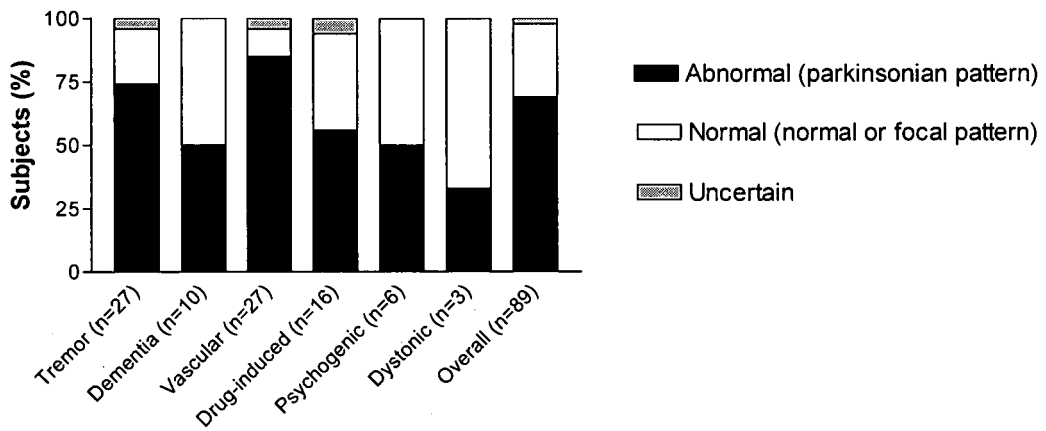


Table 2-2 Congruence between [¹²³I] FP-CIT SPECT result and clinical diagnosis after knowledge of SPECT result in 190 patients

| SPECT result | SPECT & post-scan diagnosis match | SPECT & post-scan diagnosis mismatch | Uncertain | Total |
|---|--|---|------------------|--------------|
| <i>Patients with easily categorised [¹²³I] FP-CIT SPECT</i> | | | | |
| Normal | 94 | 2 | 2* | 98 |
| Abnormal (degenerative parkinsonism) | 81 | 1 | 0 | 82 |
| Abnormal (focal) | 4 | 0 | 0 | 4 |
| Total | 179/184 (97%) | 3/184 (2%) | 2/184 (1%) | 184 |
| <i>Patients with [¹²³I] FP-CIT SPECT in 'other' distribution</i> | | | | |
| Abnormal (other) | - | - | 6** | 6 |
| Total | | | | 190 |

* = diagnosis not yet known

** = cases in this group not assigned match or mismatch as scan interpretation is uncertain

Table 2-3 Relationship of individual and combination parkinsonian signs to abnormal [¹²³I] FP-CIT SPECT (in a parkinsonian distribution) in 190 patients

| | Definite | Possible |
|--|--|-----------------|
| | Abnormal scans / total cases with feature (%) | |
| Bradykinesia | 56/97 (58%) | 15/47 (32%) |
| Rigidity | 56/93 (60%) | 14/28 (50%) |
| Postural Instability | 27/46 (59%) | 4/10 (40%) |
| Rest tremor | 49/105 (47%) | 3/7 (43%) |
| Postural tremor | 26/91 (29%) | 3/7 (43%) |
| Bradykinesia and Rigidity and Rest tremor | 29/47 (62%) All scored definite | |
| Brain Bank criteria (part 1) | 53/93 (57%) All scored definite | |
| Bradykinesia and Rigidity and/or rest tremor | 52/97 (54%) Each scored either definite or possible | |

**Chapter 3 : A prospective assessment of the
usefulness of [¹²³I] FP-CIT SPECT in uncertain tremor
disorders in clinical practice. A subgroup of the UK
FP-CIT Case Collection**

Introduction

The commonest disorders presenting to neurology or movement disorders clinics with a tremor are essential tremor and idiopathic Parkinson's disease. These are usually easily differentiated. In cases where the clinical diagnosis is not so clear cut, functional imaging of the presynaptic dopaminergic neurones can be helpful. This chapter focuses on cases entered into the United Kingdom FP-CIT Case Collection Study where the pre-scan categorisation was into the diagnostic pairing of PD versus essential tremor. The usefulness of dopamine transporter imaging in movement disorder clinics has been characterised with [¹²³I] FP-CIT SPECT in prospective studies of early stage tremor patients(133), clinically uncertain parkinsonism(166;210) and both retrospectively and prospectively with [¹²³I] β-CIT SPECT(164;186). However, prior studies have been criticised as being mostly single centre in patients with established clinical diagnosis(225). The aim of this prospective study was to identify what proportion of patients with clinically uncertain tremor disorders have abnormal [¹²³I] FP-CIT SPECT imaging, and relate that to the pre-scan working diagnosis, and to the documented clinical features. It relates to the routine practice of specialists in movement disorders and neurology in the United Kingdom.

Methods

Methods are detailed within Chapter 2 (Overview of the UK [¹²³I] FP-CIT Case Collection Study)

Results

Fifty patients (30 females: 20 males) of median age 66 (interquartile range [IQ] 58 - 74) years underwent [¹²³I] FP-CIT SPECT in 6 centres. In all cases, diagnosis was judged inconclusive by the referring movement disorder specialist (*n* = 47) or general

neurologist ($n = 3$). Patients' data was transmitted centrally prior to imaging in all but 6 cases (88%). [^{123}I] FP-CIT SPECT was performed 33 days after entry (95% confidence interval [CI] 23 - 90).

SPECT result and post-scan diagnoses according to pre-scan diagnosis

Of 50 patients entered, 27 (54%) had a provisional, pre-scan diagnosis of idiopathic Parkinson's disease, of whom 20 of 27 (74%) had an abnormal scan in keeping with the clinical diagnosis. Seven of 27 (26%) had normal imaging; in 6 of these the post-scan diagnosis was amended to non-PD; in one the diagnosis of PD remained despite normal imaging (Table 3-1).

Twenty-three patients (46%) had a pre-scan diagnosis of essential tremor and SPECT was normal in 19 (83%) supporting the clinical diagnosis. In 3 patients (13%) it was abnormal indicating presynaptic dopaminergic degeneration and in all 3 the post-scan diagnosis was PD. In the 1 remaining case (4%) there was a focal deficit related to previous cerebral haemorrhage and the post-scan diagnosis remained essential tremor. Visual grading of all SPECT images is summarised in Table 3-2. An overall comparison of expected and actual SPECT results found unexpected SPECT findings (mismatches) in 10 of 50 (20%), and 9 of these 10 mismatches (90%) changed diagnostic groupings accordingly (therefore, the pre to post-scan diagnostic mismatch rate was 18%, Figure 3-1). Table 3-3 charts the clinical characteristics of these mismatch cases.

Tremor characteristics

Table 3-4 shows [^{123}I] FP-CIT SPECT results and post-scan diagnosis according to clinicians' scoring of tremor characteristics with descending order of tremor type (categorised according to the presence of rest and postural components). Two of 10 patients (20%) with definite rest tremor without a postural component had normal

scans with a post-scan diagnosis of a benign tremor disorder. Two of 8 patients (25%) with definite postural tremor without a rest component had abnormal imaging and a post-scan diagnosis of PD. Tremor asymmetry and post-scan diagnosis are detailed in Table 3-5 and detailed information regarding tremor duration, predominant type, distribution and asymmetry and motor sub-score of Unified Parkinson's Disease Rating Scale (UPDRS) was available in 25 cases (Table 3-6).

Relationship of clinical certainty in cardinal features to abnormal [¹²³I] FP-CIT SPECT

Twelve of 20 cases (60%) with definite bradykinesia had an abnormal [¹²³I] FP-CIT and 6 of 20 cases (30%) with possible bradykinesia had abnormal scans. Twelve of 20 cases (71%) with definite rigidity had abnormal scans which was the strongest individual cardinal feature of parkinsonism which predicted an abnormal scan.

Definite postural tremor was scored in 12 of 35 cases (34%) with abnormal imaging. The strongest combined clinical profile in those with abnormal scans was definite bradykinesia, rigidity and rest tremor. Individual and combinations of clinical features are reported in relation to abnormal [¹²³I] FP-CIT SPECT in Table 3-7.

Diagnostic confidence

The average diagnostic confidence in those cases where the scan concurred with the clinician's initial diagnosis of PD was 70% (95% CI 66 - 74) and post-scan it was 94% (95% CI 93 - 95). For an ET diagnosis pre-scan confidence was 65% (95% CI 60 - 70) and post-scan 87% (95% CI 85 - 89). For all cases where pre and post scan diagnoses matched, the clinician's confidence increased from 68% pre to 90% post-scan.

Influence of [¹²³I] FP-CIT SPECT or clinical progression on management plan

The management plan changed post-scan in 30/50 (60%). In 29/50 (58%) this was attributable to the scan (plus other reasons in 4) and 1/50 (2%) to clinical progression only.

Discussion

According to the pre-scan diagnosis, the predicted and actual [¹²³I] FP-CIT SPECT result differed in one fifth of cases and the post-scan diagnosis was changed by the referring clinician in almost all of the mismatch cases in line with the scan result. In these mismatches the management plan changed in nearly all patients and in most this related to the scan result. These results are a measure of the strong influence of the [¹²³I] FP-CIT SPECT on the clinicians' diagnosis and management of patients with atypical tremor disorders.

In a large blinded series of 158 patients who fulfilled diagnostic criteria, the sensitivity of [¹²³I] FP-CIT imaging for the clinical diagnosis of parkinsonism was 97% and specificity for ET was 100%(161) whereas a similar study with 96 patients and [¹²³I] β-CIT SPECT, found a sensitivity of 98% and specificity of 83%(162) for a diagnosis of degenerative parkinsonism. Diagnostic error is present even when patients fulfil clinical criteria. The 'last visit pre-mortem' diagnosis is incorrect for between 10(32) and 25% for PD(19). Since [¹²³I] FP-CIT SPECT cannot reliably distinguish amongst degenerative parkinsonism, not all of the misdiagnoses can be corrected with this test. In the original Brain Bank study 12 of 25 cases (52%) where PD was misdiagnosed (or 12% of the whole population with an PD diagnosis) would be expected to show normal dopamine transporter or F-dopa imaging (these 12 cases were made up of the following: Alzheimer's or Alzheimer-type pathology $n = 6$; vascular $n = 3$; nigral atrophy $n = 2$ and normal $n = 1$). Higher mismatch rates earlier

in the clinical course and in patients with greater clinical uncertainty would be expected.

Concurrence of clinical diagnosis and [¹²³I] FP-CIT SPECT result

The baseline mismatch rate between preliminary diagnosis and SPECT result was one fifth which is similar to that reported in studies of uncertain parkinsonism of between 14% and 34%(133;164;186). Comparisons between studies can be made, but are somewhat limited because not all described the baseline diagnosis, blinding of the studies varied and some were retrospective assessments. These studies are reviewed below.

A mismatch between referral diagnosis and [¹²³I] β-CIT SPECT was found in a retrospective study in 23% of 90 patients who had a primary, tentative diagnosis of parkinsonism. At a mean of 14 months later, a high proportion of clinical diagnoses concurred with baseline imaging with an imaging sensitivity of 97% and a specificity of 83%(186). Similar sensitivity (96%) was found in our study but we found higher specificity of imaging for the post-scan diagnosis of degenerative parkinsonism (100%). In a study of 33 patients with inconclusive parkinsonian syndromes and [¹²³I] FP-CIT SPECT, clinical diagnosis after 2 - 4 years concurred with the scan result in 31 cases(166) and gave a sensitivity of 82% and a specificity of 100%. Our study was not a follow-up study; rather it assessed the immediate influence of imaging on diagnosis and management. The calculation of sensitivities and specificities for an imaging result according to a diagnostic gold standard which is influenced by the imaging result itself is circular. Clearly post-mortem is the true gold-standard but this is difficult to achieve in tremor disorders especially when including benign cases and there are no reports of such patients available. Nevertheless, our standard provides the radiologist/ nuclear medicine physician with an indication of the influence of

dopamine transporter imaging on diagnostic thinking by the movement disorder physician/ neurologist.

Evidence that blinded clinical diagnosis concurs with baseline scan results after follow-up is found in 2 studies of early and uncertain parkinsonian disorders. In the first study, mismatch between baseline blinded clinical diagnosis and baseline imaging occurred in 11 of 62 patients (18%) which decreased to 10% at 3 months with amendment of blinded clinical diagnoses(133). Three year follow-up of these patients, within an extended multicentre study, is reported in Chapter 6. In the second study, mismatch between baseline [¹²³I] β-CIT SPECT and referral diagnosis was between 14% and 34% (lower for movement disorder experts versus community neurologists) which reduced at blinded clinical review at 3 to 6 months to 9% of patients. No mismatches were identified at 12 month blinded review(226), although numbers completing the 12 month follow-up were low.

Change in management after knowledge of [¹²³I] FP-CIT SPECT result

The largest study to assess [¹²³I] FP-CIT SPECT in uncertain parkinsonian disorders(210) found an impact in most of 118 patients (increased confidence or change in diagnosis) with a change in baseline diagnosis after imaging in 53/109 (49%) and change in clinical management in 72%, which included changes in current and planned pharmacological management. Just over half of the patients in our tremor study had a change in management which was attributed by the local clinician to the imaging result.

Post-scan diagnoses

The heterogeneity of the post-scan diagnosis of those cases with normal [¹²³I] FP-CIT SPECT is interesting. Clearly not all cases have a straightforward diagnosis of essential tremor but have contributions from other conditions such as vascular

disease or tremorogenic medications and represents the complex mix of conditions that are seen in everyday practice rather than cases that strictly fulfil criteria and are thereby invited to clinical trial entry or observational clinical research(53). This study therefore confirms the utility of dopamine transporter imaging in this mixed patient population.

One patient kept a diagnosis of Parkinson's disease despite the unexpectedly normal [¹²³I] FP-CIT SPECT. This has been previously observed in numerous studies assessing usefulness of functional dopaminergic imaging in early or uncertain parkinsonian disorders(133;166;186). Booij found that after clinical follow-up, 2 of 24 (8%) patients had a diagnosis of true parkinsonian syndrome despite no evidence of nigrostriatal degeneration on imaging(166). Baseline imaging of patients with a clinical diagnosis of early PD into CALM-PD(127), REAL-PET(212) and ELLDOPA(147) therapy trials showed normal scans in 4, 11 and 14% respectively. This issue of these so called 'SWEDD's' (subjects without evidence of dopaminergic deficit) is controversial. While some believe that clinical diagnosis is correct and consider imaging techniques in de novo patients to be poorly sensitive(227), others consider these patients to have been misdiagnosed.

Clinical features of tremor disorders

Our study concurs with other studies that find an atypical presentation of PD in some cases, such as patients with postural tremor (and no rest component)(21;228), predominant postural tremor (with rest component) and symmetrical tremor, and of asymmetrical rest tremor in ET(229). We did not attempt to describe whether postural tremors when present were due to a re-emergent rest tremor(230), nor whether the rest component was classic pill-rolling type associated with PD or of flexion/ extension type often associated with essential tremor, although this is likely to have been clinically useful. The presence of 3 cardinal features scored as definite

(rest tremor, rigidity and bradykinesia) predicted an abnormal [¹²³I] FP-CIT SPECT in only three-quarters of cases in the current series which is lower than that found in a 2-centre prospective study of early tremor disorders (100%)(133). Also, less than two thirds of patients fulfilling Brain Bank criteria part 1 in the current series had abnormal imaging which emphasises that the presence of cardinal features is not specific to the presence of an abnormal scan.

Conclusion

The clinical misdiagnosis rate in early tremor disorders with parkinsonism in routine practice is high and [¹²³I] FP-CIT SPECT influences diagnosis, management and clinicians confidence in the majority of cases. Although this was an observational study and clinicians were not blind to the SPECT result, the improved congruence between diagnosis and imaging was in keeping with that found in blinded studies and reaffirms the utility of dopamine transporter imaging in uncertain tremor/ parkinsonian disorders in routine clinical practice.

Table 3-1 Comparison of pre and post-scan diagnoses according to [¹²³I] FP-CIT SPECT of 50 patients with uncertain tremor disorders

| Pre-scan diagnosis | [¹²³ I] FP-CIT SPECT | Post-scan diagnosis |
|---|--|--|
| Parkinson's disease (scan expected to be abnormal) (n = 27) | Abnormal - parkinsonian distribution (n = 19) | 17 PD 1 atypical parkinsonian disorder (loss of D2 receptors detected by [¹²³ I] IBZM SPECT and PSP diagnosis) |
| | Abnormal - other* (n = 1) | 1 atypical parkinsonian disorder |
| | Normal (n = 7) | 1 PD 4 ET 1 atypical ET or vascular 1 ET ± valproate tremor |
| Essential tremor (scan expected to be normal) (n = 23) | Abnormal - parkinsonian distribution (n = 3) | 2 PD 1 PD + ET |
| | Abnormal - focal (n = 1) | 1 ET |
| | Normal (n = 19) | 16 ET (2 with contributions from lithium, valproate, dystonic or vascular component) 1 orthostatic tremor 1 drug induced (trifluoperazine) ± vascular 1 vascular ± alcohol excess |

ET = essential tremor, PD = Parkinson's disease, *SPECT has reduced uptake in a symmetrical pattern and is unlike that seen typical in PD.


Table 3-2 Visual grade of [¹²³I] FP-CIT SPECT according to pre-scan diagnosis in 50 patients with uncertain tremor disorders

| Pre-scan diagnosis | Normal SPECT | Abnormal SPECT* | | | | |
|--------------------|--------------|-----------------|---------|---------|-------|------------------|
| | | Grade 1 | Grade 2 | Grade 3 | Focal | Other |
| PD (n = 27) | 7 | 6 | 11 | 2 | 0 | 1 atypical ** |
| ET (n = 23) | 19 | 2 | 1 | 0 | 1 | 0 |

*For visual grade definition see introduction

**There was no preferential loss of [¹²³I] FP-CIT from the putamen.

Figure 3-1 Pre-scan to post-scan diagnostic mismatch rate in 50 patients with uncertain tremor disorders



*Includes vascular, dystonic, atypical, orthostatic tremors where [¹²³I] FP-CIT SPECT expected to be normal. **One case here had a normal scan but clinician scored it still as PD.

Table 3-3 Clinical characteristics of 10 'mismatch' tremor cases

| | No (sex, age) | Symptom and Signs | Pre-scan diagnostic confidence | Post-scan diagnosis and confidence | Change in management plan? Due to scan? | Management plan |
|--|---------------------|--|--------------------------------------|---|---|---|
| Pre-scan diagnosis PD; normal [¹²³I] FP-CIT SPECT; post-scan diagnosis non-PD (n = 6) | 118 (F, 66) | Tremor right hand, worse carrying pans, micrographia. Definite rest and postural tremor, predominantly postural in both arms with definite rigidity and bradykinesia. On valproate | PD 70% | ET or DIP 80% | Yes Due to scan result | Anti tremor therapy and/or change of anti epileptic medication under consideration |
| | 4 (F, 65) | Definite rest and postural tremor, possible bradykinesia | PD 65% | ET 70% | No | Anti tremor therapy under consideration |
| | 13 (M, 51) | Definite rest tremor, possible postural tremor, bradykinesia and postural instability | PD 50% | ET 95% | Yes Due to scan result | Anti tremor therapy to be started |
| | 17 (F, 44) | Definite rest tremor and rigidity | PD 60% | Atypical ET or vascular 60% | Yes Due to scan result | Anti tremor therapy under consideration |
| | 20 (F, 81) | Definite rest and postural tremor and possible bradykinesia | PD 70% | ET 70% | Yes Due to scan result | Anti tremor therapy under consideration |
| | 24 (M, 58) | Definite rest and postural tremor and possible bradykinesia. On antiparkinson medications prior to imaging | PD 60% | ET 85% | Yes Due to scan result | Plan to reduce or stop antiparkinson medication and thalamic deep brain stimulation under consideration |
| Pre-scan diagnosis PD; normal [¹²³I] FP-CITSPECT; post-scan diagnosis PD (n = 1) | 6 (F, 52) | Definite bradykinesia and rigidity with possible rest and postural tremor | PD 90% | PD 90% | No | Antiparkinson therapy to start |
| Pre-scan diagnosis ET; abnormal [¹²³I] FP-CIT SPECT; post-scan diagnosis degenerative parkinsonism (n = 3) | 126 (F, 66) | Long history of tremor diagnosed as essential tremor with recent progression, falls & deteriorating mobility. Symmetrical and definite rest and postural tremor, bradykinesia, rigidity and postural instability | ET 5% | PD 100% and ET | Yes Due to scan result and because of specialist review | Reduce to stop anti tremor therapy and start antiparkinson therapy |
| | 1 (F, 67) | Definite rest tremor, possible bradykinesia | ET 25% | PD 95% | Yes Due to scan result | Start antiparkinson therapy |
| | 12 (F, 55) | Definite rest and postural tremor, possible bradykinesia and rigidity | ET 50% | PD 70% | Yes Due to scan result | Antiparkinson therapy under consideration |

Table 3-4 Stratification of [¹²³I] FP-CIT SPECT result and post-scan diagnosis according to tremor type in 50 cases

| Patient No (sex, age) | Tremor type | | SPECT* | Post-scan diagnosis |
|--------------------------|-------------|----------|--------|-------------------------------|
| | Rest | Postural | | |
| 103 (M, 61) | Y | | 1 | PD |
| 124 (F, 80) | Y | | 2 | PSP |
| 110 (M, 82) | Y | | 2 | PD |
| 01 (F, 67) | Y | | 1 | PD |
| 02 (M, 67) | Y | | 1 | PD |
| 14 (M, 71) | Y | | 2 | PD |
| 15 (M, 70) | Y | | 2 | PD |
| 23 (F, 70) | Y | | 2 | PD |
| 08 (F, 82) | Y | | Normal | ET |
| 17 (F, 44) | Y | | Normal | Atypical ET & vascular tremor |
| 111 (M, 67) | Possibly | | 2 | PD |
| 104 (M, 59) | Y | Possibly | 3 | PD |
| 106 (F, 45) | Y | Y | 2 | PD |
| 109 (F, 77) | Y | Y | 2 | PD |
| 119 (F, 75) | Y | Y | Other | Atypical PD** |
| 126 (F, 66) | Y | Y | 2 | PD + ET |
| 03 (M, 57) | Y | Y | 1 | PD |
| 12 (F, 55) | Y | Y | 1 | PD |
| 16 (F, 44) | Y | Y | 1 | PD |
| 19 (M, 63) | Y | Y | 1 | PD |
| 21 (M, 66) | Y | Y | 3 | PD |
| 25 (M, 80) | Y | Y | 1 | PD |
| 26 (M, 64) | Y | Y | 2 | PD |
| 102 (F, 74) | Y | Y | Normal | ET |
| 105 (F, 72) | Y | Y | Normal | ET |
| 107 (M, 65) | Y | Y | Normal | ET |
| 108 (F, 55) | Y | Y | Normal | ET |
| 112 (F, 75) | Y | Y | Normal | ET + VP |
| 117 (F, 62) | Y | Y | Normal | ET |
| 118 (F, 66) | Y | Y | Normal | ET OR DIP |
| 120 (F, 56) | Y | Y | Normal | VP ± DIP |
| 09 (F, 59) | Y | Y | Normal | ET |
| 122 (F, 75) | Y | Y | Normal | ET |
| 123 (M, 64) | Y | Y | Normal | VP or alcohol related tremor |
| 125 (F, 76) | Y | Y | Normal | ET |
| 04 (F, 65) | Y | Y | Normal | ET |
| 11 (F, 74) | Y | Y | Normal | ET or Lithium |
| 13 (M, 51) | Y | Y | Normal | ET |
| 20 (F, 81) | Y | Y | Normal | ET |
| 24 (M, 58) | Y | Y | Normal | ET |
| 22 (F, 81) | Y | Y | FOCAL | ET |
| 115 (M, 47) | | Y | 2 | PD |
| 116 (F, 75) | | Y | 2 | PD |
| 113 (M, 35) | | Y | Normal | ET |
| 114 (M, 63) | | Y | Normal | ET |
| 121 (F, 48) | | Y | Normal | ET OR DIP |
| 07 (F, 70) | | Y | Normal | ET |
| 10 (F, 74) | | Y | Normal | ET & orthostatic |
| 18 (M, 55) | | Y | Normal | Dystonic Tremor |
| 06 (F, 52) | Possibly | Possibly | Normal | PD |

Y = yes, BLANK = NO, ET = essential tremor, PD = Parkinson's disease, DIP = drug induced parkinsonism, VP = vascular parkinsonism, Atypical PD = atypical degenerative parkinsonian disorder, PSP = progressive supranuclear palsy.

*[¹²³I] FP-CIT SPECT is reported as normal or graded 1, 2 or 3 (see text) or other.

Other = striatal uptake is markedly reduced but does not have the preferential reduction in uptake in the putamen. ** FOCAL = focal reduction in striatal uptake thought to be related to previous cerebral haemorrhage.

Table 3-5 Post-scan diagnosis according to symmetry of predominant tremor type in 25 patients

| Asymmetrical | | Symmetrical |
|--|--|--|
| 4 PD 1 PSP 1 ET | Rest (n = 7) | 1 PD |
| 1 ET | Rest & postural predominate (n = 2) | 1 PD |
| 3 PD 1 atypical pd 5 ET 1 VP or alcohol related | Postural (n = 16) | 2 ET 1 ET + VP 2 ET or DIP 1 VP ± DIP |

PD = Parkinson's disease, PSP = progressive supranuclear palsy, ET = essential tremor, atypical PD = atypical degenerative parkinsonism, VP = vascular parkinsonism, DIP = drug-induced parkinsonism.

Table 3-6 Detailed clinical features of 25 subjects with uncertain tremor disorders undergoing [¹²³I] FP-CIT SPECT

Subjects are arranged according to predominant tremor type

| Patient (sex, age) | Duration (yrs) | Symptoms | Tremor | | | | | Additional signs | SPECT | UPDRS (motor) | | Post- scan diagnosis |
|--------------------------|-------------------|---|--------|------|--------------------------|-----------------|------|---|--------|------------------|--------|----------------------------|
| | | | Rest | Post | Predom tremor type | Distribution | SYM | | | total | tremor | |
| 103 (M, 61) | 0.4 | Right arm tremor | Y | | Rest | Right arm | Asym | Increased right wrist tone with activation | 1 | - | - | PD |
| 110 (M, 82) | 1.1 | Left arm and leg tremor, generally slowed, softer voice | Y | | Rest | Left arm, leg | Asym | Reduced facial expression, blinking and voice volume, bradykinesia in left arm, postural instability, stooped posture | 2 | 23 | 6 | PD |
| 124 (F, 80) | 0.7 | Unsteadiness, falls | Y | | Rest | Left leg | Asym | Parkinsonian gait but no other definite features | 2 | 13 | 1 | PSP |
| 111 (M, 67) | 0.9 | Speech arrest then tremor right hand, slowed down and stiff. | P | | Rest | Arms | Asym | Reduced facial expression, impaired saccadic eye movement, tone slightly increased in legs, positive palmomental reflexes | 2 | 31 | 2 | PD |
| 104 (M, 59) | 0.3 | Tremor left arm and leg | Y | P | Rest | Left arm, leg | Asym | Slight cogwheeling | 3 | 7 | 3 | PD |
| 126 (F, 66) | 11 | Long history of tremor diagnosed as essential tremor with recent progression, falls, deteriorating mobility | Y | Y | Rest | Arms, legs | Sym | Slow, shuffling gait, poor turning, stooped, rigidity and bradykinesia | 2 | 51 | 14 | PD + ET |
| 107 (M, 65) | 23 | Mild head and hand tremor started about 20 years ago, but worse in past year with general slowing | Y | Y | Rest | Right arm, head | Sym | Slight postural instability, reduced arm swing | Normal | 6 | 2 | ET |

| Patient (sex, age) | Duration (yrs) | Symptoms | Tremor | | | | | Additional signs | SPECT | UPDRS (motor) | | Post- scan diagnosis |
|--------------------------|-------------------|--|--------|------|--------------------------|-----------------|------|--|--------|------------------|--------|----------------------------|
| | | | Rest | Post | Predom tremor type | Distribution | SYM | | | total | tremor | |
| 108 (F, 55) | 0.4 | Arm tremor worse on right | Y | Y | Both | Arms | Asym | Reduced facial expression and reduced blinking, positive frontal reflexes, activated rigidity right wrist | Normal | 5 | 1 | ET |
| 119 (F, 75) | 2 | Right arm, head and sometimes whole body tremor, relates it to wide local excision of right breast carcinoma, axillary node clearance and radiotherapy | Y | Y | Postural | Right arm | Asym | Jerky tremor, possible bradykinesia | Other | 24 | 8 | Atyp PD* |
| 109 (F, 77) | 2.1 | Initially right arm then leg tremor, micrographia, reduction in voice strength | Y | Y | Postural | Arms, legs head | Asym | General bradykinesia and rigidity | 2 | 39 | 9 | PD |
| 115 (M, 47) | 3.5 | Tremor right arm worse drinking tea and yawning, micrographia, has noticed reduced arm swing. | | Y | Postural | Right arm | Asym | Bradykinesia right side and rigidity on activation only, positive frontal reflexes, reduced arm swing on right | 2 | 17 | 7 | PD |
| 116 (F, 75) | 1.1 | Unsteadiness on feet, difficulty with fine hand movements, micrographia, alcohol improved | | Y | Postural | Right arm | Asym | Rigidity with activation both arms, mild bradykinesia, reduced arm swing, | 2 | 15 | 2 | PD |
| 102 (F, 74) | 2 | Right arm and head tremor worse on holding cups, stiffness and generally slow | Y | Y | Postural | Right arm, head | Asym | Rigidity with activation right arm | Normal | 6 | 5 | ET |
| 105 (F, 72) | 2.6 | Right greater than left arm tremor, difficulty with lifting cups etc | Y | Y | Postural | Arms, head | Asym | | Normal | 21 | 8 | ET |
| 113 (M, 35) | | Tremor left arm, heaviness left arm and leg | | Y | Postural | Left arm | Asym | Mild cogwheel rigidity right wrist and mild bradykinesia bilaterally | Normal | - | - | ET |

| Patient (sex, age) | Duration (yrs) | Symptoms | Tremor | | | | | Additional signs | SPECT | UPDRS (motor) | | Post- scan diagnosis |
|--------------------------|-------------------|---|--------|------|--------------------------|-----------------|------|--|--------|------------------|--------|----------------------------|
| | | | Rest | Post | Predom tremor type | Distribution | SYM | | | total | tremor | |
| 122 (F, 75) | 10 | Diagnosed with Parkinson's for 10 years, tremor in lips and right hand | Y | Y | Postural | Right arm, head | Asym | Head, jaw and voice tremor, good arm swing, no rigidity or bradykinesia (but on antiparkinson medication) | Normal | 11 | 7 | ET |
| 123 (M, 64) | 7.2 | Right arm tremor, pains in legs | Y | Y | Postural | Right arm | Asym | Bradykinesia right arm, positive post, broad based gait, dysarthria | Normal | 21 | 8 | VP or alcohol related |
| 117 (F, 62) | 1.1 | Tremor (bilateral right worse than left), stiffness and slowness (unilateral), family history of tremor | Y | Y | Postural | Arms, head | Asym | Mild bradykinesia in arms | Normal | 11 | 8 | ET |
| 112 (F, 75) | 4.5 + | Long' history of tremor with positive family history and alcohol effect. Difficulty turning in bed, shuffling walking | Y | Y | Postural | Arms | Sym | Dysphonic, bradykinetic, asymmetrical cogwheeling, shuffling gait, postural instability. Possible improvement with levodopa but no deterioration on withdrawal | Normal | 39 | 10 | ET + VP |
| 118 (F, 66) | 0.7 | Tremor right hand worse carrying pans, micrographia | Y | Y | Postural | Arms | Sym | Rigidity and bradykinesia both arms, positive palmomental reflexes | Normal | 17 | 6 | ET or DIP |
| 120 (F, 56) | 5.7 | Tremor left then right arm, stiffness in arms and slowness of walking, positive family history for tremor, no alcohol effect, betablocker possibly improved | Y | Y | Postural | Arms | Sym | Possible rigidity with activation and mild bradykinesia left arm, positive frontal reflexes | Normal | - | - | VP ± DIP |

| Patient (sex, age) | Duration (yrs) | Symptoms | Tremor | | | | | Additional signs | SPECT | UPDRS (motor) | | Post- scan diagnosis |
|--------------------------|-------------------|---|--------|------|--------------------------|--------------|-----|--|--------|------------------|--------|----------------------------|
| | | | Rest | Post | Predom tremor type | Distribution | SYM | | | total | tremor | |
| 114 (M, 63) | 40 | Tremor in fingers for most of life, worsened recently, positive alcohol response & family history of tremor | | Y | Postural | Arms | Sym | Postural instability, reduced arm swing on right | Normal | 8 | 7 | ET |
| 121 (F, 48) | 5 | Tremor left arm, falls, stiffness in joints, untidy writing | | Y | Postural | Arms | Sym | Possible bradykinesia in left hand | Normal | 4 | 4 | ET or DIP |

Y = feature present, P = feature possibly present, BLANK = feature absent, SYM = symmetry, Asym = asymmetrical, Sym = symmetrical
 ET = essential tremor, PD = Parkinson's disease, VP = vascular parkinsonism, DIP = drug-induced parkinsonism
 PSP = progressive supranuclear palsy, Atyp PD = atypical parkinsonism

Table 3-7 Relationship of individual and combinations of parkinsonian signs to abnormal [¹²³I] FP-CIT SPECT in a degenerative parkinsonian distribution in patients with uncertain tremor disorders

| | Definite | Possible |
|--|--|-----------------|
| | Abnormal scans / total cases with feature (%) | |
| Bradykinesia | 12/20 (60%) | 6/20 (30%) |
| Rigidity | 12/17 (71%) | 6/10 (60%) |
| Postural Instability | 5/10 (50%) | 0/1 (0%) |
| Rest tremor | 20/38 (53%) | 1/2 (50%) |
| Postural tremor | 12/35 (34%) | 2/2 (100%) |
| Bradykinesia and Rigidity and Rest tremor | 6/8 (75%) All scored definite | |
| Brain Bank criteria (part 1) | 12/20 (60%) All scored definite | |
| Bradykinesia and Rigidity and/or rest tremor | 14/21 (67%) Each scored either definite or possible | |

Table includes all 23 patients who had abnormal SPECT in a parkinsonian distribution, and does not include one patient with a focal abnormality

**Chapter 4 : [¹²³I] FP-CIT SPECT clarifies underlying
dopaminergic status in parkinsonism associated with
drug use. A subgroup of the UK FP-CIT Case
Collection**

Introduction

Drug induced parkinsonism (DIP) causes 7 - 37% of all cases of parkinsonism (13;231-234) which is second only to idiopathic Parkinson's disease (PD). It is found commonly in certain populations such as the hospitalised elderly(15) or psychiatric inpatient(235). Underlying PD is present in up to 15% of cases(15;73;74;76;236;237), the presence of Lewy bodies has been confirmed by post-mortem studies(236;238) and drug cessation only temporarily improves parkinsonian features.

DIP can be clinically indistinguishable from PD(15;68) so that initial misdiagnosis as PD is common(239). The asymmetry in clinical features which is classical of PD is also seen in 30 - 75% of DIP, for each of the cardinal features(66;240;241). Rest tremor is typical in PD but also occurs in 44% of DIP(67). Distinguishing features of DIP are: gait disturbance occurs only rarely(67;242) levodopa response is poor(68;243) and orofacial dyskinesia may co-exist(244). DIP onset often coincides with drug prescription but can develop insidiously over years(245) and resolution after drug cessation rarely takes up to 18 months(71). DIP is most often caused by antipsychotics or antiemetics due to post-synaptic dopamine blockade; in other cases e.g. valproate, less is known about the pathophysiology.

Functional imaging of the presynaptic dopaminergic neurone in DIP

The presynaptic dopaminergic neurone is normal in DIP with normal functional imaging(65;122;164;186) but if imaging is abnormal it predicts clinical progression in keeping with degenerative parkinsonism(222). The application of functional imaging to separate DIP from PD has been reported only in small mainly single centre studies(65;122;164;186) and a UK Parkinson's Disease Society consensus report suggests that functional imaging may be appropriate when there is severe parkinsonism following neuroleptic treatment; in patients with atypical clinical

features, and in patients with comorbidity which might confound clinical diagnosis(246).

Aims and Methods

The design and methodology of this study is detailed in Chapter 2. This chapter reports on the subcategory of the UK Case Collection Study where [¹²³I] FP-CIT SPECT was applied to differentiate degenerative parkinsonism (mainly Parkinson's disease) from drug-induced parkinsonism. Clinical features of DIP were noted in patients where underlying degenerative parkinsonism was excluded. Patients with parkinsonism were included in this diagnostic pairing if they had been exposed to potential dopamine-depleting drug therapy, but degenerative parkinsonism was considered possible on clinical grounds by the referring clinician. Further clinical features were requested for any of the 190 patients within the UK Case Collection Study with a post-scan diagnosis of DIP (i.e. not just in the pre-scan diagnostic pairing of DIP versus PD) which included the referring clinician's assessment of symmetry of clinical features, and resolution of parkinsonism with follow-up.

Semiquantitative assessments were performed in one centre as detailed in Chapter 2.

Results

Forty nine patients (27F: 22M) with mean age 62 years (SD 13; range 43 - 82) underwent [¹²³I] FP-CIT SPECT in 8 centres. Patients were imaged a median of 1.5 months after baseline characteristics were logged. Thirteen patients were on traditional neuroleptics, an additional 13 on atypical neuroleptics, 18 on other dopamine depletors (such as prochlorperazine or metoclopramide), 12 'others' (such as sodium valproate in 9) and 18 used antidepressants. These medicines were used in combination in 19 and alone in 30 patients. UK Brain Bank criteria (step 1) were fulfilled in 42 of 49 (86%) (bradykinesia scored definite or possible plus one other

feature). Baseline clinical diagnoses compared to post-scan diagnoses are presented in Table 4-1. SPECT gave clear results in 45 of 49 (92%) which were either normal or abnormal in a graded parkinsonian or focal pattern, but in 2 (4%) there was diffuse symmetrical markedly abnormal [¹²³I] FP-CIT uptake, 1 (2%) had diffuse symmetrical mildly abnormal uptake, and 1 (2%) was borderline normal with a possible unilateral putamen defect. In 13 of 49 cases (27%) the initial most likely diagnosis did not concur with the scan findings, and clinical diagnosis was amended. Thirty-one patients had normal SPECT, 29 of whom had a post-scan diagnosis of DIP (7 with a contribution from other disorders such as cerebrovascular disease, essential tremor or non-PD dementia) and 2 had drug-induced tremor, while none had a diagnosis of degenerative parkinsonism. One had a focal abnormality on SPECT and a post-scan diagnosis of DIP and co-existent cerebrovascular disease. Semiquantative data for [¹²³I] FP-CIT uptake in contralateral and ipsilateral putamen and caudate is shown in Figure 4-1 & 4-2 for 26 patients in one centre according to post-scan diagnosis.

Clinical features including asymmetry and follow-up data were available in 28 of the 32 patients with a post-scan diagnosis of drug-induced parkinsonism (without underlying degenerative parkinsonism). A further 2 patients with a post-scan diagnosis of DIP who were identified from other categories within the UK Case Collection Study were included, making a total of 30 patients with available detailed examination and follow-up data. There were 9 males and 21 females, mean age 66 years (SD 11, range 41 - 83). Of the 30 patients, 9 had concomitant neurological diagnoses, as follows: cerebrovascular disease ($n = 6$), non-parkinson dementia ($n = 2$), and essential tremor ($n = 1$). Bradykinesia was present in 29 (97%), rest tremor in 21 (70%), postural tremor in 21 (70%), and 16 (53%) had both rest and postural components. Rigidity was present in 20 (67%) and postural instability in 9 (30%). Parkinsonism was asymmetrical in 21 of 30 (70%). Step 1 of the Brain Bank criteria

was fulfilled by 26 (87%). [¹²³I] FP-CIT SPECT was normal in 29 (97%) while in one (3%) there was a possible unilateral putamen defect. The main offending medication was prochlorperazine (14 of 30 cases, 47%). Sodium valproate was considered causative in 3 and a potential contributor with other drugs in an additional 6. Other drugs were metoclopramide ($n = 2$), amiodarone ($n = 2$), traditional neuroleptics ($n = 4$), and atypical neuroleptics ($n = 4$). Melphalan was a potential cause in one, in whom metoclopramide was also used later. Medications were started mostly for depressive illness (12/30), or dizziness or vertigo (8/30); other indications included epilepsy, vomiting/ nausea, cardiac arrhythmia or dyspepsia. Follow-up occurred at a median of 10 months (interquartile range 4 -17 months) and culprit medications were withdrawn or reduced in 23, with complete resolution of parkinsonism in 5 patients, incomplete resolution in 15 and no improvement in 3.

Discussion

Clinical and imaging mismatch rates in drug-induced parkinsonism

[¹²³I] FP-CIT SPECT is useful to demonstrate underlying presynaptic dopaminergic deficiency in patients who present with parkinsonism with a differential diagnosis between drug-induced parkinsonism and Parkinson's disease. The clinicians' diagnosis post-scan matched in each case the scan diagnosis, and in particular no patients were thought to have PD with normal [¹²³I] FP-CIT SPECT. The mismatch between most-likely diagnosis pre-scan and scan diagnosis of around a quarter is in keeping with previous studies that suggest misdiagnosis between PD and drug-induced parkinsonism occurs commonly.

Misdiagnosis between PD and DIP, is confirmed by community and post-mortem though many of these studies tended to exclude patients on neuroleptics (so as to study only degenerative parkinsonism), and therefore misdiagnosis rates might be higher. One community study found that 12 of 402 (3%) patients with presumed PD

examined by hospital specialists actually had DIP instead(8), and DIP accounted for up to 1% of all cases misdiagnosed as PD in post-mortem series(247). Six of 8 patients (75%) diagnosed with DIP had alternative causes for parkinsonism identified pathologically which included Lewy body disease(248). Abnormal [¹²³I] β-CIT SPECT was identified in 3 of 4 (75%) of patients with an initial pre-scan diagnosis of DIP and diagnoses were amended to degenerative parkinsonism (PD in 1 and PD plus in 2)(186) but none with an initial PD diagnosis (with normal or abnormal imaging) had a post-scan diagnosis of DIP. Between 30%(222) and 55%(65) of patients with parkinsonism associated with neuroleptic use had abnormal imaging which was interpreted as underlying degenerative parkinsonism. Functional imaging studies reflect the proportion of underlying PD from a movement disorder clinic population (as patients are referred for imaging by movement disorder experts, not psychiatrists) which is more likely to see patients with more severe parkinsonism and higher clinical uncertainty rather than that seen in psychiatry wards where the overall proportion with underlying PD is likely to be lower.

Functional imaging of the dopaminergic neurone in psychiatric disorders

It is important to know whether an underlying psychiatric disorder is itself associated with an altered presynaptic dopaminergic neurone, particularly as neuroleptic naïve patients with first episode of psychosis have a higher prevalence of parkinsonism(249;250) than the general population. Further to this a change in the dopamine transporter due to medications for psychosis needs to be considered. Functional imaging studies have explored this and are summarised as follows:

When considering schizophrenics without parkinsonism:

Imaging in drug-naïve or previously treated schizophrenics without parkinsonism with [¹²³I] FP-CIT SPECT(185) and [¹²³I] β-CIT SPECT(251) were found to be normal, however a slight decrease in striatal uptake (overlapping with control group and not

within the parkinsonian range) was found in chronically medicated schizophrenics without parkinsonism with [¹⁸F] CFT PET(252) whereas an increase was found with [¹²³I] β-CIT SPECT(253).

In patients on neuroleptics with parkinsonism:

Reduced striatal [¹²³I] FP-CIT SPECT uptake was found in schizophrenics with and without short-term risperidone-induced parkinsonism which was significantly different from normals(254) but was not compared to an PD range, and the authors postulated that this could be related to schizophrenic disease or secondary to antipsychotic treatment. In severe neuroleptic induced parkinsonism functional imaging has been used to identify marked presynaptic dopaminergic dysfunction and dichotomize patients into 2 groups, the abnormal uptake group being considered to have underlying degenerative parkinsonism(65;222). The only follow-up study confirmed that abnormal [¹⁸F] -dopa PET found in 4 of 13 patients was associated with progression of parkinsonism in keeping with PD unmasked by dopamine depleting medication whereas a normal scan predicted subsequent clinical improvement(222).

Application of dopamine transporter imaging in clinical practice

Regarding the application of functional imaging in patients with uncertain parkinsonism, there is evidence of normal dopamine transporter imaging in a small number of patients with a post-scan diagnosis of DIP, and none had abnormal imaging(122;164;186).

Without [¹²³I] FP-CIT SPECT, withdrawal of a potential offending medication and monitoring will be sufficient in many cases to assess if parkinsonism is drug-induced or not. However improvement in some can be lengthy and in some cases underlying PD might not be apparent until a few years after initial clinical improvement in the case of drug unmasked PD. Withdrawal of psychotropic medication or trial of

dopaminergics or anticholinergics might sometimes exacerbate an active psychiatric condition or have problematic side effects. In these situations, [¹²³I] FP-CIT SPECT can prevent prolonged uncertainty or adverse medication effect.

Clear [¹²³I] FP-CIT SPECT result in most patients

Scans with a borderline result between normal or abnormal may be problematic if numerous; however the visual assessment of [¹²³I] FP-CIT SPECT gave a clear result of normal or abnormal scan in most patients and is confirmed by the semi-quantitative data in this study which dichotomises nearly all patients with a post-scan diagnosis of degenerative parkinsonism and drug-induced parkinsonism.

Borderline scan results and unmasked degenerative parkinsonism

There were only 2 (4%) patients with borderline normal or mildly abnormal scans and uncertain post-scan diagnoses. As this was not a blinded study, the report of a 'borderline' scan may have influenced the clinicians' diagnosis of an uncertain condition. The finding of borderline scans raises questions about the sensitivity of imaging. We understand the sensitivity of presynaptic dopaminergic imaging to be high for the dopamine transporter loss which accompanies PD, due to a preclinical phase of the condition before motor symptoms emerge; imaging is also abnormal in some asymptomatic relatives of PD patients, who are in the preclinical phase(140). Theoretically, however, a borderline or normal presynaptic SPECT could occur in the early preclinical phase of PD, in the presence of a post-synaptic dopamine blocking agent. This might explain our case in whom parkinsonism developed while taking prochlorperazine, and in whom SPECT showed a slightly reduced unilateral putamen uptake, matching asymmetric clinical involvement. We intend to re-scan at an interval in case of progressive loss of [¹²³I] FP-CIT uptake in keeping with PD. The other patient had symmetrical parkinsonism on valproate therapy, SPECT uptake was mildly and symmetrically reduced, and follow-up diagnosis was between a

Parkinson's plus disorder and valproate induced parkinsonism. We postulate that 3 categories (DIP: definite PD: early unmasked PD) will have different [¹²³I] FP-CIT uptake indices. DIP will be normal, the definite PD cases will almost certainly be abnormal but unmasked cases could be at the lower end of normal.

Clinical features of drug-induced parkinsonism

Asymmetry of parkinsonism, and rest tremor are both classical features of PD.

Adding asymmetry to core diagnostic features in cases of parkinsonism improves diagnostic specificity for PD(30) and rest tremor is universally regarded as the most specific tremor type for PD. Our finding of asymmetry in 70% and rest tremor in 70% of DIP cases is similar to other reports quoting figures for asymmetry in 30% to 58%(66-68). Unmasked PD was not excluded in these studies which might account for asymmetry in a proportion but the use of [¹²³I] FP-CIT SPECT in our study helps reduce the risk of co-existent PD, and when dopaminergic imaging was normal, asymmetrical signs were identical to those with underlying PD(65).

Although clinical asymmetry may have contributed to diagnostic uncertainty and therefore the selection for entry to our study, the proportion with asymmetrical features was similar to an unselected series(67;68).

Tardive dyskinesia or akathisia was noted in individual cases but these features were not systematically recorded. These and the absence of olfactory deficit would help support a diagnosis of DIP. Greater characterisation of tremor into components that might be helpful to separate PD from DIP was beyond the scope of this project.

Our cases are a selected series of patients who typically present to movement disorder clinics, and have less well recognised variants of DIP. The characteristics of mainly younger patients with schizophrenia who are treated in psychiatry may well differ from the present series; those cases are classically considered to present symmetrically without tremor, and to improve with anticholinergic drugs or on drug discontinuation.

Prolonged persistence of parkinsonism in drug-induced parkinsonism

We found prolonged persistence of parkinsonism in selected cases, even after therapy withdrawal, which is also consistent with other studies(222;255). Incomplete recovery after stopping the offending medication, in the presence of normal functional imaging of the presynaptic dopaminergic system, has been identified in 5 of 8 patients with normal [¹⁸F] -dopa PET followed up for a median of 12 (range 6-32) months(222), while two patients treated with sodium valproate and with normal [¹²³I] β-CIT SPECT had incomplete recovery at one year(255). This raises the possibility that some form of persistent chemical change may have been caused by the offending medication and that a proportion of these cases might ultimately develop Parkinson's disease.

Gold-standard

In the absence of the ideal gold standard of parkinsonism occurring with appropriate drug and normal brain histology, an appropriate reference for DIP would be parkinsonism improving after drug withdrawal. Drawbacks to this method deserve consideration regarding appropriate standards when offending medication cannot be withdrawn or in the case of incomplete improvement after drug cessation. In this situation [¹²³I] FP-CIT SPECT is useful to exclude nigrostriatal degeneration, although as we included the SPECT result in the reference standard in this study it is possible that we may have overestimated its utility. For example some patients with normal imaging and lack of improvement after drug-withdrawal due to underlying vascular parkinsonism may have been inadvertently included.

Culprit medications in drug-induced parkinsonism

A substantial proportion of patients considered to have drug-induced parkinsonism were on one or more potentially offending medications. Drug combinations increasing the likelihood of parkinsonism has been considered and reported previously(256) and the mechanisms whereby medications cause parkinsonism differ between drugs(257). Our study contained a surprisingly high number of patients with DIP on atypical antipsychotics (many were on combination therapy including valproate or antidepressants). Atypical antipsychotics are now a first line treatment option(258) because of improved tolerability (including less extrapyramidal side effects) compared to typical antipsychotics, however DIP is well documented to occur in atypicals also and the present series confirms that in the movement disorder clinic setting an equal number of patients being referred for imaging were on typicals and atypicals. Taking into account a now much larger prescription rate for atypical antipsychotics(259;260) because of guidelines for appropriate antipsychotic use, this would tend to indicate a lower risk than typicals, though it could be influenced by referral bias and interestingly, one recent study found the risk of drug-induced parkinsonism with high dose atypical antipsychotic use was comparable to that with traditional antipsychotics(261).

Nine of our patients with DIP were treated with sodium valproate, an association highlighted in an epilepsy clinic report in which 3 of 50 consecutive patients (6%) were affected(255). The occurrence of reversible levodopa responsive parkinsonism with alkylating chemotherapy(262) has similarities to our patient with myeloma treated with melphalan. However, metoclopramide was also used later in the disease course, but his parkinsonism predated its use, raising the possibility of myeloma being contributory.

Conclusion

This multicentre study provides evidence that it can be difficult to differentiate between drug-induced parkinsonism and degenerative parkinsonism clinically and [¹²³I] FP-CIT SPECT clearly verifies the status of the dopaminergic neurones in 94%, with diagnostic change in line with this. The minority have borderline changes with diagnostic uncertainty remaining. Asymmetry of parkinsonism and rest tremor both occur in drug-induced parkinsonism and neither is specific for idiopathic Parkinson's disease. Improvement after withdrawing offending medication in cases of drug-induced parkinsonism may be delayed, and does not necessarily indicate underlying PD.

**Table 4-1 Provisional clinical diagnosis compared to post-scan diagnosis
(made with knowledge of the [¹²³I] FP-CIT SPECT result) in 49 patients with
parkinsonism associated with drug use**

| Baseline diagnosis | Scan diagnosis | Post-scan diagnosis | |
|--------------------|---|---------------------|---|
| PD 16 | Abnormal (in PD distribution) | 9 | PD 7 Progressive supranuclear palsy 1 Lewy Body Dementia 1 |
| | Abnormal (not PD distribution) Diffuse, mild symmetrical reduction | 1 | PD plus and/or DIP (uncertain) 1 |
| | Normal | 6 | DIP 5 DIP and evidence of cerebrovascular disease 1 |
| | DIP 33 | Normal | 25 |
| | Abnormal (in PD distribution) | 4 | PD 4 |
| | Abnormal (not PD distribution) Focal lesion | 4 | DIP and evidence of cerebrovascular disease 1 Underlying PD or VP with DIP (uncertain) 1 |
| | Markedly abnormal | | VP with DIP 1 |
| | Markedly abnormal Very mild asymmetrical reduction | | DIP: unmasked PD possible (uncertain) 1 |

PD = Parkinson's disease, DIP = drug-induced parkinsonism, VP = vascular parkinsonism, ET = essential tremor

Figure 4-1 Semiquantitative [¹²³I] FP-CIT uptake in putamen according to post-scan diagnosis in patients with parkinsonism associated with drug use

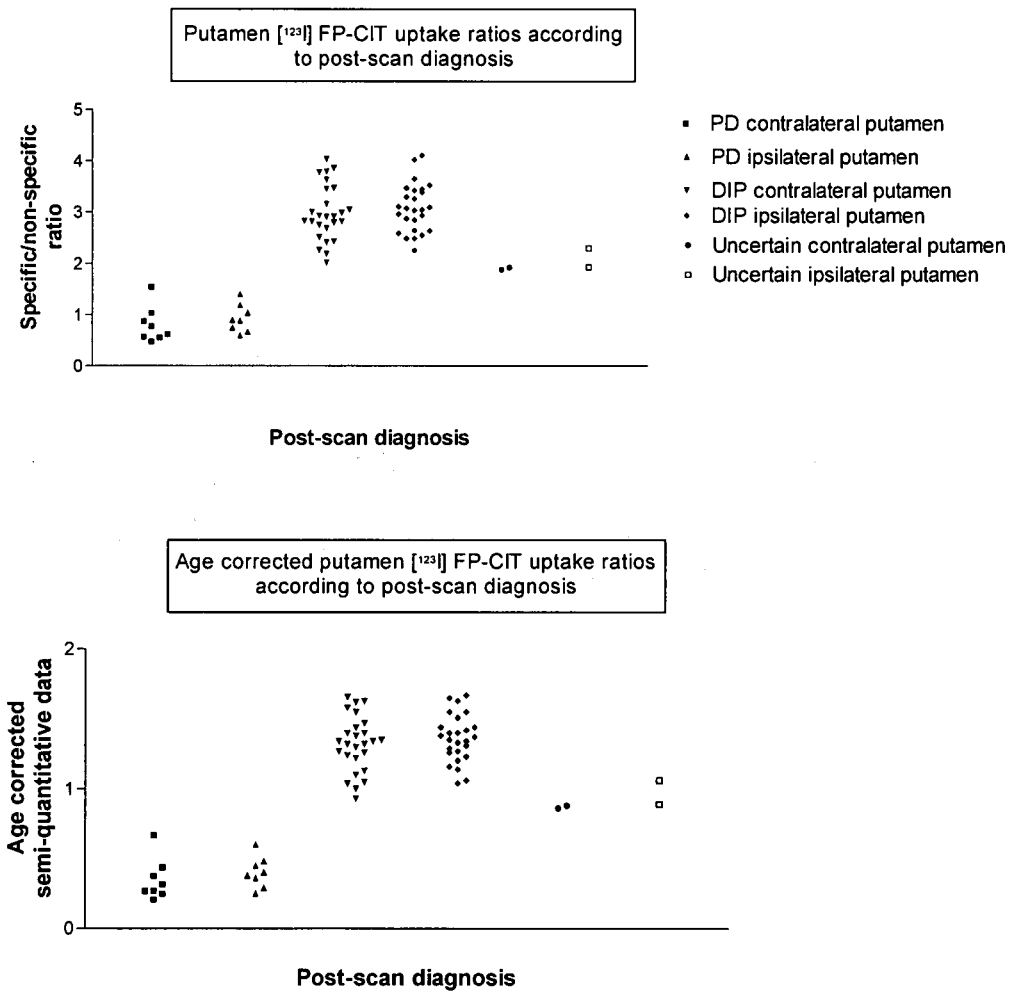
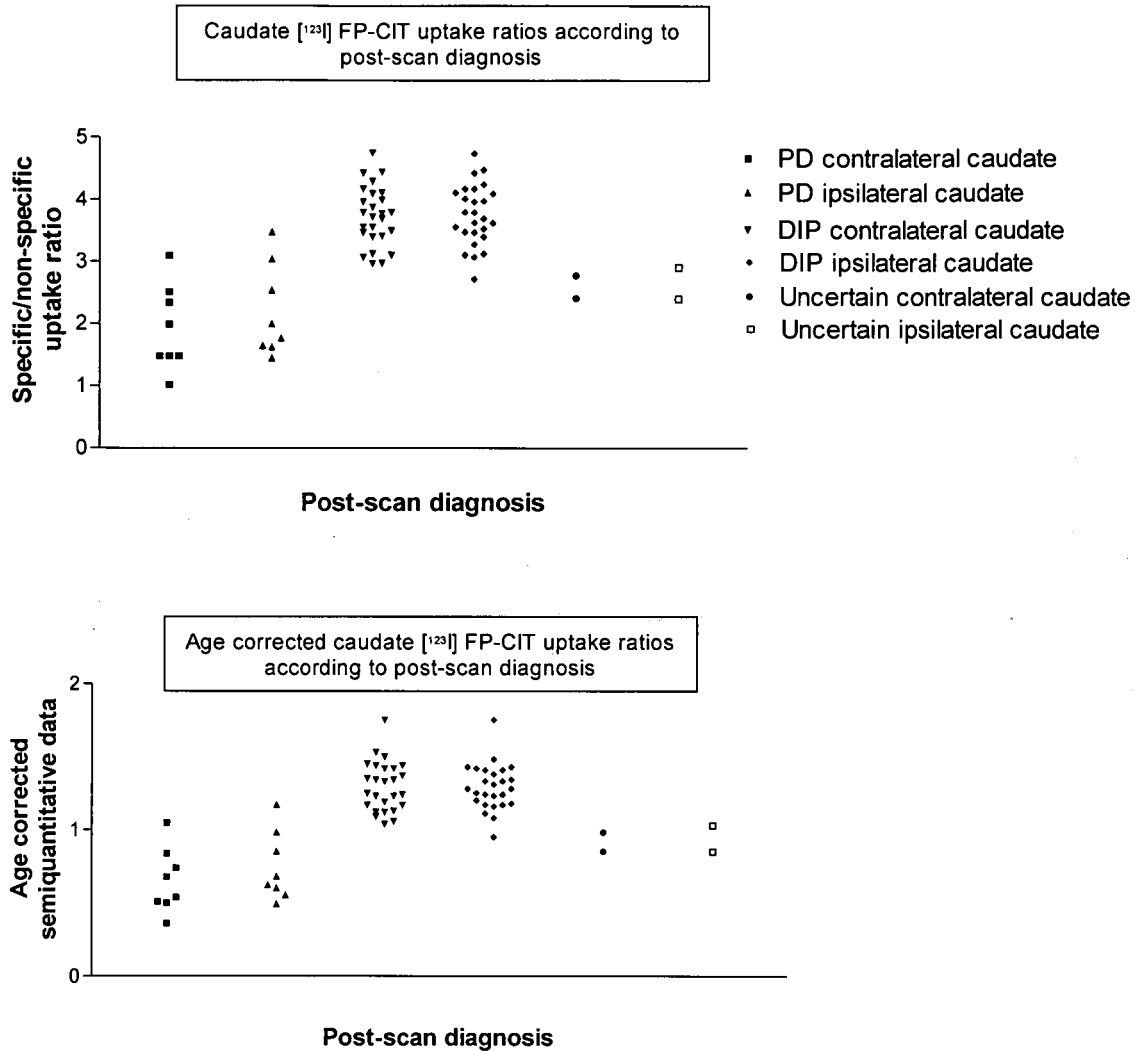


Figure 4-2 Semiquantitative [¹²³I] FP-CIT uptake in caudate according to post-scan diagnosis in patients with parkinsonism associated with drug use



For figures 4-1 and 4-2

Upper panels: Specific: non-specific uptake ratios for contralateral and ipsilateral caudate according to post-scan diagnosis in 36 patients imaged in 1 centre. Lower panels: ratios corrected for age (for method see text), a figure of 1 is the lower limit of expected normal uptake. One patient with degenerative parkinsonism considered to be PSP is included in the PD category above. DIP cases included those with coexistent non-PD dementia, cerebrovascular disease or ET.

**Chapter 5 : Prolonged follow-up of patients with
normal [¹²³I] FP-CIT SPECT imaging**

Introduction

The recognition of inaccuracies in the clinical diagnosis in early(6) and late(1) idiopathic Parkinson's disease (PD) both by community(7;8) and hospital specialists has led to improvement in clinical criteria(4;32), improving specificity but lowering sensitivity of a PD diagnosis. Diagnosis of a parkinsonian syndrome remains primarily dependent upon recognition of a clinical syndrome, but dopamine transporter imaging with [¹²³I] FP-CIT SPECT has been shown to be sensitive and specific in differentiating tremor disorders fulfilling diagnostic criteria for PD and essential tremor (ET)(161). This has also been shown for cases not fulfilling clinical criteria, in whom there is increased clinical concurrence to baseline scan diagnosis at 3 months(133) (blind to imaging results). Similar findings are reported for [¹²³I] β-CIT SPECT at 6 months' follow-up(164). Additionally, presynaptic dopaminergic deficit in the asymptomatic striatum in patients with hemiparkinsonism(134) and in relatives of PD patients who later become symptomatic, suggests early sensitivity of such imaging(140).

Despite this, 4 - 14% of patients diagnosed with early PD being entered into trials of putative neuroprotective agents had normal presynaptic dopaminergic imaging(127;163;212). These have been termed subjects with scans without evidence of dopaminergic deficiency or SWEDD's. Possible explanations include a lack of sensitivity of the scan in early disease, difficulty in the early diagnosis of idiopathic Parkinson's disease (misdiagnosis) or Parkinson's disease without presynaptic dopaminergic dysfunction. However, patients with normal imaging tend not to progress in the same way as patients with abnormal imaging and a diagnosis of PD, and normal imaging tends to remain abnormal when repeated after an interval(263). The longer term follow-up of SWEDD's with specific reference to clinical features, diagnosis and antiparkinson therapy response is currently

insufficient. Antiparkinson medication use have previously been identified in community studies in patients who have no clinical evidence of degenerative parkinsonism(7;8). However, withdrawal of antiparkinson medication in such patients is not reported.

Patients in the following studies underwent SPECT imaging (with normal results) as part of routine clinical practice. In each subject SPECT was applied because of clinical uncertainty surrounding the presence or absence of underlying presynaptic dopaminergic deficiency. The first study: "Two year follow-up in 150 consecutive cases with normal dopamine transporter imaging: Experience in a regional movement disorders centre", primarily focuses on the longer term diagnosis of patients and the second study: "Successful antiparkinson medication withdrawal in patients with parkinsonism and normal [¹²³I] FP-CIT SPECT", focuses on 11 patients who fulfilled basic idiopathic Parkinson's disease diagnostic criteria (Brain Bank criteria part 1) but later had antiparkinson therapy withdrawn.

Methods

In each study the protocol for scan acquisition was as follows. [¹²³I] FP-CIT with activity in the range 111 - 185 MBq was administered intravenously over approximately 15 seconds and followed by a saline flush. SPECT images were obtained using a dedicated multi-detector scanner (NeuroFocus Scanner, NeuroPhysics Corp, Shirley MA) which acquires 10 - 12 sequential single transaxial sections, 5mm apart, through the basal ganglia. Energy window was 140-180 keV, and linear attenuation correction was applied (0.008mm^{-1}). Scanning was started and finished between 3 and 6 hours after administration of [¹²³I] FP-CIT. Scans were reported by visual assessment as previously defined(161) by unblinded raters. Cases where there was focal reduction suggesting a structural lesion were included, since this does not indicate degenerative parkinsonism. Semiquantitative assessments

were performed using predetermined region of interest templates were from *Talairach Daemon* (online at <http://ric.uthscsa.edu/projects/talairachdaemon.html> assessed online 14th July 2006) and based on the Co-planar Stereotaxic Atlas of the Human Brain(221). Specific: non-specific ratios were calculated from three adjacent axial slices through the caudate and putamen. The mean specific:non-specific ratios were calculated from the right and left-sided reading.

Study 1: Two year follow-up of 150 consecutive cases with normal dopamine transporter imaging

Methods

Consecutive patients with normal [¹²³I] FP-CIT SPECT undertaken in a regional neuroradiology unit from October 2000 to December 2003 were reviewed. Assessment during a minimum follow-up of 2 years after imaging noted clinical features, progression, working clinical diagnosis and use and response to antiparkinson medication. Case record review was supplemented whenever necessary by contacting the treating neurologist and/ or general practitioner. SPECT was applied because of clinical uncertainty about the presence or absence of underlying presynaptic dopaminergic deficiency. Reasons for undertaking SPECT were compared to suggested guidelines(246). Data are presented as mean (standard deviation, SD) when normally distributed, otherwise median (interquartile range, IQ). Chi-squared analysis was used to test differences of antiparkinson therapy use between groups.

Results

Demographics

Of 462 [¹²³I] FP-CIT SPECT scans undertaken, 150 fulfilled the entry criteria and had available follow-up records (a further 30 with normal scans had incomplete follow-up and are not included). SPECT was requested by 16 hospital specialists and visual assessment was normal in 146 (97%) and focal reduction in 4 (3%). Semiquantitative analysis showed radioligand uptake within 2 SD of age-matched normals in all striatal subregions, apart from the 4 scans with a focal reduction. The mean age was 63 (SD 12) years; 84 were female (56%) and 66 male (44%). Patients had movement disorder symptoms for 2.7 (IQ 1.3 - 5.9) years at imaging. Case note review occurred

2.4 (IQ 2.2 - 3.1) years after SPECT and the median follow-up duration from first clinic attendance was 3.2 (IQ 2.5 - 4.3) years.

Favoured pre-scan diagnoses and reasons for uncertainty

Whilst uncertainty occurred in all cases, the favoured documented diagnosis pre-scan was degenerative parkinsonism in 73 (49%), non degenerative disorder in 44 (29%) and in 33 (22%) no favoured diagnosis was documented. The commonest documented reasons for clinical uncertainty and [¹²³I] FP-CIT SPECT request were atypical pattern of tremor (96), equivocal bradykinesia or rigidity (65), equivocal levodopa response (15) and severe parkinsonism whilst on dopamine depletors (16) and 2 or more reasons were documented for [¹²³I] FP-CIT SPECT request in 59 cases (39%).

Clinical features

The predominant disorders were tremor in 112 (75%) or gait in 18 (12%), and the other 20 comprised of mixed syndromes with cognitive difficulties noted in 7 of these. A family history of PD was noted in 13 (1st degree relative = 9, 2nd degree = 4); other tremor disorders in 20; while 2 had a family history of both PD and possible essential tremor. Documented clinical features are outlined in Table 5-1. Twenty five patients fulfilled part 1 United Kingdom Brain Bank criteria, while an additional 37 had incomplete fulfilment through the presence of only possible features. Considering the more specific criteria for PD, 7 patients fulfilled these through the presence of cardinal features, asymmetrical onset, and absence of any other possible causes of a parkinsonian syndrome(30).

Antiparkinson therapy use

Antiparkinson therapy was used in 36 (24%) (levodopa in 30, of whom 7 also had used dopamine agonists: combinations of anticholinergics, amantadine, dopamine

agonists and selegiline without levodopa were used in 6). This figure of 36 included 23 of the 44 subjects (51%) who had a pre-scan diagnosis of degenerative parkinsonism. Medication was used prior to SPECT in 34 cases and afterwards in two. Antiparkinson therapy was later withdrawn in 27 of 36 (75%), who had either no therapy response (10) or an uncertain or unsustained response (17) but restarted in two of those 27 with clinical worsening (worse UPDRS motor score in 1; during hospital admission with terminal acute-on-chronic liver failure and uncertain benefit in 1). In the remaining 25 patients there was no deterioration off antiparkinson therapy. Antiparkinson therapy withdrawal is planned in two of the remaining cases, not planned in six, and not documented in one. Table 5-2 presents antiparkinson therapy use and effect of any withdrawal according to criteria fulfilment. Patients strictly fulfilling Brain Bank criteria (part 1) were more likely to undergo a trial of antiparkinson therapy ($p < 0.05$) but were no more likely to remain on, show a sustained response to, or try more than one type of antiparkinson therapy compared to those who did not fulfil criteria (overall $p = 0.95$).

Structural brain imaging

Structural brain imaging was performed in 99 (CT = 53, MR = 57, both = 11) which showed atrophy alone in 9, vascular changes in 40, and miscellaneous abnormalities in 5. Of the 4 patients with focal striatal reduction in [123 I] FP-CIT uptake, only one had a matching vascular putamenal lesion on CT (diagnosis: VP and unclassified degenerative parkinsonism), repeat SPECT in the second patient became normal after 2.5 years (diagnosis: VP and DIP), the third had no structural disease on CT (diagnosis: non-degenerative parkinsonism) and the last patient with a left striatal focal reduction had evidence of widespread vascular disease including the right striatum (diagnosis: VP).

Diagnosis after follow-up

The diagnosis after follow-up was non-degenerative parkinsonism or tremor in 146 cases (Figure 5-1). In 4 patients the diagnosis was degenerative parkinsonism (1 PD, 1 corticobasal degeneration, 2 unclassified).

Of 150 patients, 48 are currently still under regular hospital review, 91 are discharged, 7 did not attend hospital appointment and 4 are known to have died.

Discussion

Presynaptic dopaminergic imaging is a potential adjunct to differentiate degenerative parkinsonism from its mimics in cases of clinical uncertainty(164;166;186;210). It is abnormal in early and preclinical disease, e.g. in the asymptomatic striatum in unilateral PD(134-136) and in anosmic relatives of patients with PD(140).

Theoretically a small proportion of scans may initially be normal in patients with early idiopathic PD(214), or have a normal or near-normal scan due to unmasking of PD by dopamine depleting drugs(219). In our series, 3% with normal SPECT retained a diagnosis of degenerative parkinsonism and those cases had a 3-year symptom duration when SPECT was performed; none was on dopamine depleting medication. Repeat scanning after an interval is a possible approach in such cases. At least some scans should become abnormal if there is degenerative parkinsonism, since the progressive loss of striatal uptake in early PD is 3 to 13% per annum(115;150;151;156;264). Since the time period of this study we found all of 22 normal SPECT scans which were repeated (15 through participation in a study protocol and 7 because of remaining clinical uncertainty) to remain normal in 21, at an interval of 18 (IQ 17 - 19) months. The other subject had repeat imaging at 3.3 years when new reduced focal putamenal uptake was noted to match a vascular lesion on CT. Two subjects with a remaining diagnosis of degenerative parkinsonism

were within this group even though repeat imaging showing no evidence of emerging parkinsonian dopaminergic loss.

Repeat normal imaging at up to 4 years was identified in 3 trials of antiparkinson therapy in between 4 and 15% of patients enrolled as early PD(162;163;212). These have been termed subjects with scans without evidence of dopamine deficiency (SWEDD's). The progressive loss of striatal uptake seen in PD is not seen in SWEDD's(213), and expert video review blind to scan results challenged the diagnosis of PD in over half the cases(216).

Misdiagnosis also occurred in earlier clinical trials with 8.1% of 800 patients after 8 years' follow-up undergoing diagnostic change(6) which included non-degenerative disorders and was supported by post-mortem in selected cases. In 100 patients diagnosed clinically as PD, post-mortem examination showed misdiagnosis in 25(1) of whom 12 would be expected to show normal presynaptic dopaminergic imaging. Stricter clinical criteria would reduce the misdiagnosis rate in those with normal SPECT to 1%, but at the expense of increased diagnostic uncertainty in patients with PD(32).

There is however limited post-mortem verification of functional dopaminergic imaging results. An 80% correlation of the [¹²³I] FP-CIT SPECT diagnosis with post-mortem was found in 10 patients with dementia(181). In one of the mismatch cases, a unilateral putamen vascular lesion was misinterpreted as early degenerative parkinsonism. Different patterns of abnormalities are reported in atypical parkinsonian disorders, for example a diffuse(224;265) rather than asymmetrical reduction, and caudate loss preceding putamen loss. Combining visual with semiquantitative assessments may help in some difficult cases, but there is always

going to be a small proportion of cases where the scan appearances are not diagnostic.

Seven of 13 patients in our series had abnormal or borderline D2 imaging raising the possibility of post-synaptic parkinsonism without presynaptic abnormalities. One such case was considered previously(166) and abnormal D2 imaging with normal presynaptic imaging can be seen in Huntington's disease(266), dystonic conditions(267), vascular parkinsonism patients(268) and is sometimes attributed to neuroleptic or dopamine agonist use. The cause of abnormal D2 imaging was clear in only 3 of these 7 patients (neuroleptic related in 1 and vascular in 2), and the follow-up diagnoses were ET (1), drug induced parkinsonism (1), vascular parkinsonism (2), unclassified degenerative parkinsonism (1) and unknown but not degenerative parkinsonism (2).

Dopamine transporter imaging results have a strong diagnostic influence(210), and for this reason we conducted longer term follow-up, to seek any evidence of emerging degenerative parkinsonism. Our results agree with blinded studies in uncertain parkinsonism, in which there is increased congruence with a baseline scan result over 3(133) to 6(164) months. In our series 8 (5%), of whom 6 were clinically thought to be benign disorders and 2 to have degenerative parkinsonism, did not obtain a definitive diagnosis during follow-up. Unclassifiable parkinsonism at a rate of 4 - 5% in specialist clinics was reported before(269), and poor or equivocal response to antiparkinson medication was the main reason for uncertainty.

The therapeutic approach in patients with normal [¹²³I] FP-CIT SPECT and clinical features of a movement disorder is worth review. Firstly, to identify clinical features of patients who may have a false-negative scan, i.e. where idiopathic or degenerative parkinsonism is present, and benefit might accrue from antiparkinson therapy.

Secondly, to assess what proportion of cases are commenced on antiparkinson

therapy, the clinical response, and effects of any withdrawal. Patients strictly fulfilling Brain Bank criteria (part 1) were more likely to undergo a trial of antiparkinson therapy but were no more likely to remain on therapy compared to those who did not fulfil criteria. The results suggest a closer correlation between [¹²³I] FP-CIT SPECT and therapy response than with criteria fulfilment, but require comparative data from patients with abnormal scans.

Documented reasons for referral for [¹²³I] FP-CIT SPECT in our study concurred with suggested guidelines(246).

Conclusion

The emerging clinical profile of lack of clinical progression in line with degenerative parkinsonism and lack of response to antiparkinson medication or repeat normal [¹²³I] FP-CIT SPECT imaging where this has been applied suggests that nearly all patients with normal baseline [¹²³I] FP-CIT SPECT scan have a benign movement disorder rather than degenerative parkinsonism. A subset of patients with normal [¹²³I] FP-CIT SPECT fulfils clinical criteria for PD, but even in these cases there is negligible response to antiparkinson therapy, which is therefore seldom maintained.

Figure 5-1 Final clinical diagnosis after follow-up in 150 patients with normal [¹²³I] FP-CIT SPECT

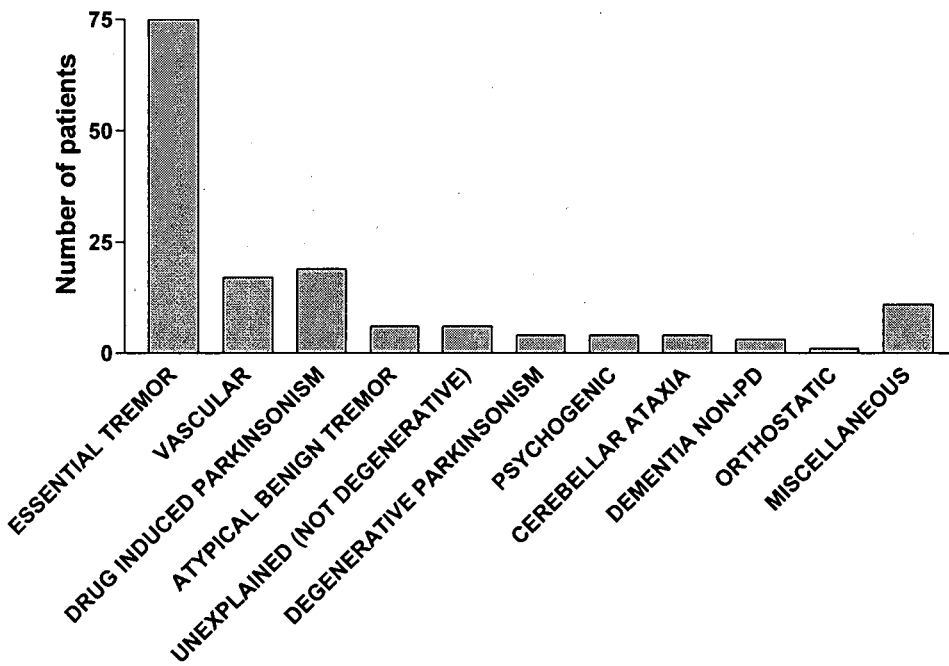


Table 5-1 Presence and certainty of cardinal parkinsonian features in 150 patients with normal [¹²³I] FP-CIT SPECT

| | | Definite | Possible | |
|----------------------|-------------------|----------|----------|--|
| Bradykinesia | | 29 | 41 | one site only, e.g. reduced arm swing <i>n</i> = 31 an additional 2 had spasticity and 1 had myotonia |
| Rigidity | | 36 | 31 | |
| Tremor | Rest only | 10 | 0 | |
| | Postural only | 43 | 0 | |
| | Rest and postural | 62 | 1 | |
| Postural instability | | 16 | 7 | |

Table 5-2 Antiparkinson medication use in 150 patients with normal [¹²³I] FP-CIT SPECT, according to presence of definite clinical features

| Criteria (total number fulfilling) | Antiparkinson therapy use (used and maintained, used and worse on withdrawal, used and stopped without deterioration, never used) |
|--|--|
| Brain Bank criteria part 1 (25) | 2, 0, 9, 14 |
| Brain Bank part 1 plus asymmetry + no exclusions (7) | 1, 0, 0, 6 |
| Bradykinesia plus rigidity & rest tremor (11) | 2, 0, 4, 5 |

Study 2: Successful antiparkinson medication withdrawal in patients with parkinsonism and normal [¹²³I] FP-CIT SPECT

Methods

Cases with parkinsonism, normal [¹²³I] FP-CIT SPECT imaging and prior use of antiparkinson medication were identified by two methods:

- 1) prospectively screening cases attending the movement disorder clinic over a 2-year period
- 2) retrospective review of 462 patients with diagnostic uncertainty who underwent [¹²³I] FP-CIT SPECT from November 2000 to December 2003 from the radiology database.

Three movement disorder specialists (VM, KG, DG) ascertained clinical features and criteria fulfilment and therapy response from a combination of clinical and case note review. All patients had attended movement disorder specialists. Parkinsonism was defined according to the Parkinson's Disease Society Brain Research Centre of the United Kingdom(30) and required the presence of bradykinesia and at least one of the following: 4 - 6 Hz rest tremor, rigidity, or postural instability not caused by primary visual, vestibular, cerebellar or proprioceptive dysfunction. Classification was performed for tremor disorders(53), other degenerative parkinsonian syndromes(33) and vascular parkinsonism(56) using published criteria. Antiparkinson medication response was graded based on a previously reported method(57). Response was categorised as excellent if described as "dramatic", "excellent", or "spectacular"; good if motor symptoms improved substantially; moderate where "modest" or "moderate" were used and absent when no useful response was documented. Effect of

antiparkinson therapy withdrawal was noted as "deterioration", "possible deterioration" or "no deterioration".

Levodopa dose equivalents were calculated using published theoretical equivalent data(270) as follows:

levodopa dose + bromocriptine (mg) x 10 + cabergoline or pramipexole (mg) x 67 + ropinirole (mg) x 20 + pergolide (mg) x 100 + apomorphine (mg) x 8. We placed the levodopa equivalence of selegiline 5 or 10mg at 100mg.

Results

Demographics

Eleven patients, 6 men and 5 women, mean age 65 years (SD 8) were identified. Mean symptom duration prior to SPECT was 5.6 years (SD 3.4, range 2 - 13). In 10 of the 11 cases, clinical features were tremor-predominant (Table 5-3). A clinical diagnosis of PD (by a hospital specialist) was documented in 7 of the 11 cases, while 3 were considered to have an atypical tremor disorder, and one had features of vascular parkinsonism and/ or PD.

Antiparkinson therapy response, withdrawal and clinical features

Antiparkinson medication was prescribed (by hospital specialist in all 11 cases) for a median of 7 months (IQ 2 - 11). The cumulative levodopa equivalent dose per patient was 20g (IQ 11 - 100g). [¹²³I] FP-CIT SPECT was normal by visual assessment and the uptake ratios for caudate and putamen (contralateral and ipsilateral) were within 2 SD's of age matched normal controls. [¹²³I] FP-CIT SPECT was normal on repeat in 2 patients after 7 and 36 months. There was no antiparkinson medication response in 9 cases, but a positive initial response in 2 (excellent levodopa response at 300mg per day over 84 months in one; moderate response to ropinirole 3 mg per day over 12 months in the other) - cases 7 and 9. During follow-up, 8 cases failed Brain Bank

exclusions (Step 2 of criteria), mainly through emerging evidence of an absent levodopa response and remaining unilateral, while 4 failed Brain Bank prospective criteria (Step 3). Although 3 cases continued to fulfill all 3 steps of the Brain Bank criteria, a lack of progression and normal [¹²³I] FP-CIT scans raised sufficient doubt to justify stopping therapy. Follow-up was for a minimum of 1 year (median 3 years, IQ 2 - 4) after antiparkinson therapy withdrawal, which was not associated with any clinical deterioration.

Discussion

Antiparkinson therapy withdrawal in patients with clinical features of parkinsonism and normal presynaptic dopaminergic imaging is previously unreported. Our cases would have qualified at presentation for entry into clinical trials of antiparkinson medication such as the 3 recent studies(163;211;212) in each of which patients termed SWEDD's were identified. During this period, 282 patients had abnormal imaging, so the rate of SWEDD's amongst cases with abnormal scan was 4%.

Expert blinded video review of SWEDD's, disputed a PD diagnosis in 54%, but consideration to alternative diagnoses was not given(216). Seven of our patients would be classified with follow-up as indeterminate tremor syndrome(53), in which essential tremor is accompanied by some features of parkinsonism (e.g. hypomimia, reduced arm swing, mild bradykinesia).

The experience of treatment benefits in SWEDD patients in the recent studies has been variable, but was well documented by repeat UPDRS measurements. In the 2 trials comparing a dopamine agonist with levodopa, the therapy response was similar in SWEDD patients to those with abnormal scans(211;212). In the ELLDOPA study, even high dose levodopa did not improve SWEDD cases(163). One explanation may be the inclusion of a placebo arm in ELLDOPA but not in the other studies, which

influenced interpretation of therapy effects. Lack of response to antiparkinson therapy contributes significantly to evolving uncertainty about an initial PD diagnosis(269), and was a main contributor in our cases. Starting antiparkinson medication early has received some recent support(271), which may necessitate diagnostic revision and therapy withdrawal more than is currently practised.

The documented benefit from antiparkinson therapy in 2 of our cases is significant as a trial of therapy can aid the diagnostic process, but is subjective. A false-positive response is likely, since later therapy withdrawal did not cause deterioration. A false-positive levodopa response can occur in patients thought to have PD during life but having no post-mortem evidence of degenerative parkinsonism(3). A positive response to antiparkinson therapy in some cases of vascular parkinsonism is documented(57), but has not been subjected to placebo controlled evaluation. While acute challenges (apomorphine or levodopa) have low sensitivity and specificity especially in early disease, a formalized protocol for the out-patient approach has, perhaps surprisingly, not been developed, and would benefit future work of this type. In vascular parkinsonism, escalating levodopa to 1g daily is suggested(57), but is not widespread practice. Our definition of therapy response, and the doses of antiparkinson medication used, are limitations, but used established methodology. Moreover, the evolving clinical picture in conjunction with normal dopaminergic imaging is more in favour of an inaccurate baseline diagnosis. Some non-specific therapy effects may influence interpretation of the diagnostic response: levodopa speeds reaction time to sensorimotor tasks(272); pramipexole improves depression even in the absence of PD(273).

Conclusion

In conclusion, this report identifies a subset of patients initially diagnosed as idiopathic PD, but in whom antiparkinson therapy was later withdrawn without

deterioration. The emerging profile of such patients, all of whom had normal presynaptic dopaminergic imaging, differs significantly from idiopathic PD. Vigilance regarding the likely presence of such cases is important in clinical practice and clinical trials.

Table 5-3 Clinical features of 11 patients with normal [¹²³I] FP-CIT SPECT treated with antiparkinson medication which was later successfully withdrawn

| Patient Age (sex) | Symptom duration (years) | Clinical features | H & Y | Antiparkinson medications |
|-------------------|--------------------------|---|-------|--|
| 1. 58 yrs (m) | 3 | Asymmetrical rest, postural & action tremor, & rigidity on co-activation, reduced arm swing, stooped, slight postural instability. MR brain - cerebrovascular disease | 2.5 | Levodopa > 100mg/d, Pramipexole 0.375mg/d 8 months |
| 2. 62 yrs (f) | 6 | Hemibody rest and postural tremor, mild bradykinesia, reduced arm swing. Postural instability | 1 | Levodopa 150mg/d 12 months |
| 3. 60 yrs (f) | 8 | Unilateral reduced movement with foot dragging. Possible bradykinesia and cogwheeling. MR brain - normal | 1 | Levodopa > 100mg/d 1 month (intolerant) |
| 4. 68 yrs (f) | 6 | Slightly asymmetrical rest tremor in parkinsonian range, symmetrical postural tremor with bradykinesia, reduced arm swing | 2 | Levodopa 300mg/d 10 months |
| 5. 70 yrs (f) | 9 | Bilateral postural arm tremor. New signs of rest tremor, hypomimia, cogwheeling, bradykinesia and reduced arm swing | 2.5 | Levodopa 400mg/d 12 months |
| 6. 66 yrs (m) | 3 | Asymmetrical arm rest tremor and leg tremor on standing. Bilateral postural tremor with bradykinesia & hypomimia. CT brain - atrophy | 2 | Levodopa > 100mg/d 3 months |
| 7. 68 yrs (m) | 3 | Jerky & asymmetrical rest, postural and action tremor, possible rigidity & bradykinesia. Progressive. CT brain - cerebrovascular disease | 2 | Ropinirole 3mg/d 12 months |
| 8. 60 yrs (m) | 3 | Asymmetrical rest, postural & action tremor, hypomimia, slight bradykinesia, reduced arm swing | 2 | Levodopa 50mg/d 3 months |
| 9. 55 yrs (m) | 13 | Asymmetrical rest, postural & action tremor, cogwheeling and possible bradykinesia. CT brain - normal | 2 | Levodopa 300mg/d 84 months |
| 10. 84 yrs (m) | 2 | Asymmetrical postural & action tremor, rigidity, possible bradykinesia, short steppage, postural instability, slow turning gait. CT brain - cerebrovascular disease | 3 | Levodopa 100mg/d 7 months |
| 11. 62 yrs (f) | 7 | Unilateral onset rest & postural tremor, possible bradykinesia, reduced arm swing | 2 | Levodopa 300mg/d 1.5 months |

**Chapter 6 : Parkinson's Disease is overdiagnosed
clinically: a 3-year European Study with repeat [¹²³I]**

FP-CIT SPECT

Introduction

The misdiagnosis of idiopathic Parkinson's disease (PD) is recognized in many settings. A PD diagnosis is still dependent upon the clinical recognition of asymmetrical parkinsonism responsive to antiparkinson therapy, and no diagnostic test is specific to idiopathic PD.

The difficulty with clinical separation of PD and essential tremor (ET)(7;8) can be attributed in some circumstances to uncertain presence of parkinsonian features or atypical presentations of PD such as with postural tremor(21), whilst in ET the occurrence of asymmetry(274), rest tremor(229), cogwheeling or the co-existence of soft parkinsonian features particularly in elderly populations(275) may all contribute. In post-mortem series(1;32), other types of degenerative parkinsonism (e.g. multiple system atrophy, progressive supranuclear palsy or corticobasal degeneration), Alzheimer's disease, and vascular parkinsonism are most commonly misdiagnosed as PD. Specific prognostic information exists for each of these, and correct diagnosis limits unnecessary and inappropriate medication.

Misdiagnosis is more common in non-specialist settings(8;164), and the highest clinical diagnostic accuracy is accredited to movement disorder specialists(4;6;164). Even so, some consider that 4 -14% of patients entered as early PD in neuroprotective studies(163;211;212) by movement disorder specialists who have normal imaging of the presynaptic dopaminergic neurone have been misdiagnosed as PD(164), whilst others believe that low sensitivity of dopaminergic imaging or a form of degenerative parkinsonism not associated with striatal dopaminergic neuronal loss is more likely(227). So far, the final diagnosis of these SWEDD's (subjects with scans without evidence of dopaminergic deficiency) is unknown.

Dopamine transporter imaging of the presynaptic dopaminergic neurone is an established accurate method to differentiate between subjects fulfilling PD or ET criteria(161;162), but few blinded imaging studies assess precision of dopamine transporter imaging in early, uncertain parkinsonian conditions(164), and none has longer term follow-up.

We aimed to determine the accuracy of dopamine transporter imaging to differentiate between degenerative parkinsonism (mostly PD) and its non-degenerative tremor mimics (mostly ET) by assessment of serial imaging and clinical assessments over 3 years. Follow-up of previously reported 3 month data(133) is reported here, along with additional cases from extension of the study to multiple centres.

Methods

Patients of either sex aged 30 to 90 years were included if there was clinical uncertainty about their diagnosis. Patients were recruited from the following centres: Glasgow, Wolverhampton, Southampton and Newcastle (UK);Marburg (Germany); Coimbra (Portugal); Yvoir (Belgium) and 2 sites in Barcelona (Spain). Fulfilment of UK Brain Bank criteria step 1(30) and Findley and Koller criteria for definite or probable essential tremor(276) was recorded. Diagnostically certain cases were excluded (e.g. positive response to dopaminergic therapy, clinical history over 5 years). The Unified Parkinson's Disease Rating Scale (UPDRS) part III (motor) score at entry was prespecified as ≤ 16 . Subjects gave written informed consent and the study had Ethics Committee approval. Patients with other potential causes of parkinsonism/ tremor were excluded (cerebrovascular disease, structural brain lesion, psychiatric illness other than depression, dementia, head injury, neuroleptic use at symptom onset; features of multiple system atrophy or progressive supranuclear palsy, hyperthyroidism, tremorogenic medication). Patients with major comorbid illness or iodine sensitivity were also excluded.

Imaging with [¹²³I]FP-CIT SPECT occurred at $t = 0$, 18 and 36 months. On-site clinical diagnosis, UPDRS and Hoehn & Yahr (H & Y) scores (12 hours off parkinsonian medications) blind to SPECT result were noted at $t = 0$ and $t = 3$ months and repeated unblinded to SPECT result at 18 and 36 months.

A video recording of UPDRS part III taken after 12 hours off medication at $t = 36$ months was scored by 2 independent assessors blind to SPECT and working clinical diagnosis. Subject-specific information was provided: a description of symptom onset, results of structural cranial imaging, on-site findings for UPDRS rigidity, H & Y score, and medication use. Any disagreement was reviewed and the consensus agreement at $t = 36$ months was defined as the “consensus video diagnosis” and was the gold-standard.

Imaging procedures

[¹²³I]FP-CIT SPECT was performed according to established protocol in each centre. Dopaminergic and other medications were continued except for agents interfering with striatal [¹²³I]FP-CIT uptake (e.g. central nervous system stimulants, anti-anorexia and obesity treatments, sympathomimetics) which were stopped for at least 4 weeks. Each subject received a thyroid blocking preparation and a single slow intravenous injection of [¹²³I]FP-CIT (N- ω -fluoropropyl-2 β -carbomethoxy-3 β -[4-iodophenyl]nortropine) at between 111-185 MBq (3-5mCi). Images were acquired 3 to 6 hours after injection using either a multi-detector single slice system or multi-headed gamma cameras (both capable of SPECT acquisition, reconstruction, and producing transverse slices with a clear visualisation of the striatum).

Data processing

[¹²³I] FP-CIT SPECT scans were evaluated by an on-site reader, and also by three independent nuclear physicians. Readers were experienced in scan reporting, and knew the subject's age but not other clinical details. Visual assessment graded scans as: *normal* largely symmetrical in putamen and caudate; *abnormal grade 1* asymmetrically reduced putamen activity; *abnormal grade 2* significant bilaterally reduced putamen uptake, activity confined to the caudate; and *abnormal grade 3* virtually absent uptake bilaterally affecting both putamen and caudate nuclei(161); or as *other* when not defined by one of these categories. Scans were divided into 2 groups: normal or abnormal (corresponding to grade 1, 2 or 3, or 'other'). Scans with movement artefact or reconstruction problems prohibiting interpretation were excluded from analysis. Predefined options for clinical diagnosis were: early probable PD fulfilling Brain Bank criteria step 1; early possible PD not fulfilling Brain Bank criteria step 1; possible ET, benign tremulous PD, or other.

To compare [¹²³I] FP-CIT SPECT results with the consensus video diagnosis, the clinical diagnosis was considered degenerative parkinsonism (which should correspond to an abnormal SPECT image) or non-degenerative parkinsonism (where SPECT should be normal). Probable PD, possible PD, and benign tremulous PD, multiple system atrophy and progressive supranuclear palsy were all categorised as degenerative parkinsonism. ET, dystonic tremor, and vascular parkinsonism were classified as non-degenerative parkinsonism. The efficacy of [¹²³I] FP-CIT SPECT in the differentiation of early degenerative parkinsonism from other forms of tremor (e.g. ET) was assessed by comparing the results of the visual assessment of [¹²³I] FP-CIT SPECT images at $t = 0$ with the consensus video diagnosis.

Two-hundred and two subjects were screened (including 3 age-matched healthy volunteers). The efficacy population (patients who completed imaging at 3 time points and with a video consensus report at $t = 36$) consisted of 99 subjects (Figure 6-1).

Statistics

Continuous variables were summarised by descriptive statistics. Statistical tests were carried out at the 5% level of significance, unless otherwise specified. The calculations of positive predictive value (PPV), negative predictive value (NPV), sensitivity, specificity and accuracy were calculated as follows:

| Gold standard (video assessment) | Read of [123 I>] FP-CIT SPECT images | |
|--|--|--|
| | Abnormal (degenerative parkinsonism) | Normal (non-degenerative parkinsonism) |
| Abnormal (degenerative parkinsonism) | True positive (TP) | False negative (FN) |
| Normal (non-degenerative parkinsonism) | False positive (FP) | True negative (TN) |

PPV = $TP / (TP + FP)$: NPV = $TN / (FN + TN)$: Sensitivity = $TP / (TP + FN)$: Specificity = $TN / (TN + FP)$: Accuracy = $(TP + TN) / (TP + FP + TN + FN)$

Efficacy population

Subjects were included in the efficacy population when both the [123 I>] FP-CIT SPECT at $t = 0$ and the clinical consensus diagnosis (gold standard) at $t = 36$ video were available (Figure 6-1).

The primary endpoint was a comparison of the $t = 0$ SPECT scan reading to the consensus clinical diagnosis from video at $t = 36$ months. Secondary endpoints included a comparison for each imaging endpoint to the on-site clinical diagnosis at t

= 18 and $t = 36$ months. Cohens Kappa coefficients were calculated to assess inter-reader agreement between [123 I] FP-CIT SPECT readers (both on-site and independent) between all normal and abnormal imaging findings at each imaging time point. Kappa coefficients were calculated for agreement between the independent inter-video readers at $t = 18$ and 36 months of a diagnosis of degenerative parkinsonism or non-degenerative parkinsonism diagnosis and included all available subjects at each time point. Chi squared testing was used to compare levels diagnostic disagreement between video readers in patients where clinical and imaging data matched versus patients where clinical and imaging data did not match. Two-tailed paired t-tests were used to assess significance of change of UPDRS motor scoring from 0 to 36 months.

Results

Baseline demographic and clinical data is shown in Table 6-1 according to the gold standard diagnosis at 36 months. There were 71 subjects with a gold-standard diagnosis of degenerative parkinsonism (66 classified as probable PD who fulfilled Brain Bank criteria step 1, and 5 with possible PD who did not fulfill criteria). Baseline [123 I] FP-CIT SPECT was abnormal in 56 of 66 (85%) classified as probable PD but was normal in the 5 classified as possible PD at 36 month video diagnosis. Twenty-eight subjects were classified as non-degenerative parkinsonism of whom 1 (4%) had abnormal imaging.

Baseline and 3 year motor scoring and antiparkinson medication use is categorized according to 3 year consensus video diagnosis (Table 6-2) and baseline imaging result (Table 6-3). The increase in motor score (UPDRS) over 3 years was significant in patients with a consensus video diagnosis of probable PD ($p < 0.0001$), but did not reach significance in those diagnosed as possible PD or non-degenerative parkinsonism/ tremor (Table 6-4). When categorized according to baseline imaging

(abnormal or normal), a significant increase in UPDRS was found for both abnormal (+10.2, SD 10.5, $p < 0.0001$) and normals (+2.3, SD 7.0, $p = 0.04$). Similarly, the number of subjects on antiparkinson medication increased by 27% in those with a probable PD diagnosis, but did not increase in those with possible PD or those with non-degenerative parkinsonism, whilst the increase was 30% for abnormal and 2% for normal baseline imaging.

The sensitivity of the independent SPECT read at $t = 0$ months compared to the 3-year gold-standard diagnosis ranged from 77.5 to 78.5% and the specificity was 96.6% for all 3 readers (Table 6-5). For the on-site clinical diagnosis (blinded to SPECT results) at $t = 0$ the sensitivity was 93% and the specificity was 46.3% compared to the gold standard. Fifteen of 81 patients (18%) with an on-site PD diagnosis at baseline were assessed as non-degenerative parkinsonism (mostly essential tremor/ benign tremor disorders) by the 3-year gold-standard. Fourteen of these 15 had normal baseline SPECT. Five of 18 (28%) with an on-site non-degenerative parkinsonism diagnosis at baseline were assessed as PD by the 3-year gold-standard. Two of these 5 had abnormal baseline SPECT (Table 6-6).

Inter-reader agreement between SPECT readers

Combined kappa coefficients for all independent SPECT readers were 0.97 (CI 0.88 to 1) at $t = 0$; 0.94 (CI 0.84 to 1) at $t = 18$; and 0.97 (CI 0.85 to 1) at $t = 36$. Between on-site SPECT readers and independent readers kappa coefficients were lower at each time point, ranging from 0.82 to 0.96.

Inter-reader agreement between video readers at $t = 18$ and $t = 36$

At $t = 18$ months, 23 of 122 videos (19%) assessed by both readers were diagnosed differently, which gave a kappa coefficient of 0.37 (CI 0.17 to 0.58). At $t = 36$, 13 of

99 videos (13%) were diagnosed differently, with a kappa coefficient of 0.68 (CI 0.53 to 0.83).

Discussion

Parkinson's disease was over-diagnosed clinically at baseline in this series, when compared to the gold standard of the consensus video diagnosis after 3 years.

Eighteen percent of patients with a baseline PD diagnosis were revised to a diagnosis of non-degenerative parkinsonism at 3 years, and most of those (93%) had a normal baseline SPECT. In contrast, the specificity of baseline SPECT was higher than baseline clinical diagnosis, as only 2% with abnormal SPECT at $t = 0$ had a non-degenerative diagnosis at 3 years. This clinical over-diagnosis of PD has been found in 15 to 47% of cases within the community(7;8) and in hospital studies where post-mortem confirmation of non-PD diagnoses occurred in 10 to 24%(1;32;247;277).

Other types of degenerative parkinsonism accounted for around a half of these misdiagnoses, while non-degenerative diagnoses were primarily vascular parkinsonism, Alzheimer's disease and non-parkinsonian tremor disorders. As we did not differentiate in our gold standard between different types of degenerative parkinsonism (as SPECT would be abnormal in all), our study might actually underestimate the over-diagnosis of PD (e.g. for MSA). However, subjects with tremor disorders were deliberately targeted for entry into this study and patients with features suggesting atypical parkinsonism were excluded, which would be expected to reduce the number of cases of PSP, MSA or CBD. The positive predictive value of an abnormal baseline SPECT is therefore higher than that of the baseline clinical diagnosis.

Only one case would be considered a 'false positive' result from [123 I] FP-CIT SPECT according to gold-standard diagnosis. This patient did not have any movement disorder features in the 3-year video assessment and had abnormal baseline and

subsequent [¹²³I] FP-CIT SPECT (graded 2 and 3). This 37 year old had a baseline H & Y of 1.5 with UPDRS (motor subscore) of 11, 5 and 8 at $t = 0, 18$ and 36 months respectively and was on a dopamine agonist. On-site clinical diagnosis was degenerative parkinsonism throughout. This raises the possibility that the gold standard diagnosis was incorrect, perhaps because of mild signs masked by antiparkinson medication.

While baseline imaging was highly specific for degenerative parkinsonism according to the consensus video diagnosis, the sensitivity is lower (77 - 80%) in this study of early parkinsonism compared to those with a definite diagnosis fulfilling clinical criteria (97 - 98%)(161;162). In the current study a gold-standard diagnosis of degenerative parkinsonism occurred in conjunction with normal imaging in 15 of 71 subjects (21%), a population that we consider similar to "SWEDD's", which were initially recognized in a notable proportion of subjects entered as PD into 3 large trials(147;211;212). Potential reasons for this 'mismatch' between clinical and imaging findings include an incorrect gold standard diagnosis, poor sensitivity of functional imaging to nigrostriatal degeneration, or an undescribed form of degenerative parkinsonism without striatal cell loss. These are now considered.

The videotaped examination is imperfect, but was necessary to allow the treating clinician access to the SPECT results. The sensitivity of clinical video-diagnosis in parkinsonism was 86 - 91% and specificity 98 - 100%(278;279) against identification of normal adults. Lower sensitivity was noted in milder/ shorter duration disease(279), which includes at least a proportion of our cases and is in keeping with the observation that agreement between our video raters improved from 18 to 36 months. Additionally, the video-rater was aware of antiparkinson therapy, which was considered necessary to interpret signs in the context of prevailing therapy. Given the on-site clinical overdiagnosis of PD, and the associated use of antiparkinson therapy,

the gold-standard diagnosis may therefore have been biased towards a PD diagnosis. The alternative of a blinded clinical examiner might prove more definitive.

If the imaging technique had low sensitivity, the annual 7 to 14% loss of uptake in PD suggests that some normal images would become abnormal over time. In SWEDD's from REAL PET, CALM-PD and ELLDOPA(147;211;212) imaging remained repeatedly normal at up to 4 years and serial semiquantitative measurements shows no reduction(213).

The consensus report of imaging at $t = 0$ for the 15 SWEDD patients was of normal uptake, however 3/ 15 had the report of 'abnormal' at least once by one or more reporters and in 1 case the consensus opinion of the SPECT readers graded this scan at $t = 36$ months as abnormal (grade 1 with asymmetrically reduced putamen uptake). This patient had a UPDRS III of 13 at $t = 0$, 12 at $t = 18$, and 17 at $t = 36$ months and had a predominantly symmetrical akinetic-rigid syndrome. There was additional uncertainty in the video-rating, which considered vascular pseudoparkinsonism and multiple system atrophy. The patient was not on any medications known to interfere with the dopamine system. The possibility of normal early imaging in some forms of degenerative parkinsonism is raised by another report of a post-mortem verified case of corticobasal degeneration with normal radioligand uptake(181). In another study (without dopaminergic imaging) 2 patients had post-mortem verified "minimal change" multiple system atrophy restricted to the substantia nigra (without striatal cell loss)(280). Functional imaging would likely be normal in such cases, although this is rare amongst cases of MSA(34). "Minimal change" PD has not been reported in functional imaging studies; although the Braak(23) hypothesis suggests this might occur at a very early clinical stage, this applies to pre-motor presentations of PD, which are also uncommon, and progression to striatal loss and motor features is considered inevitable.

The present study adds to the limited clinical information available regarding SWEDD's. The inverse relationship between the duration of symptoms and the proportion of SWEDD's(215) argues against a persistently non-nigral form of PD in which the proportion would remain constant. In our study, SWEDD's decline from 31% at baseline (and symptom duration of 3.3 years) to 21% after 3 years (symptom duration of 6.3 years). This is notably higher than rates of 14% of SWEDD's (mean disease duration 6.5 months) in ELLDOPA(163), 11% SWEDD's (16 months' duration) in REAL-PET(212), 4% SWEDD's (18 months' duration) in CALM-PD(216), and 1.4% (23 months' duration) in NIL-A-CIT(215). One explanation is that this study is representative of a population of uncertain parkinsonism/ tremor disorders with potentially higher rates of misdiagnosis.

Of the 15 SWEDD patients at $t = 36$, 12 had a baseline PD diagnosis and another 3 patients were not classified as PD at baseline. The on-site clinician disagreed with a PD diagnosis in 8 of 15 of these SWEDD's at $t = 36$ but bias had been introduced through awareness of SPECT result. Agreement rates between video readers (at 36 months) were lower in SWEDD's (disagreement between a degenerative and a non-degenerative disorder occurred in 4 of 15, 27%) compared to those with the expected abnormal scan result (2 of 56, 4%) whereas average confidence of a degenerative parkinsonian diagnosis at $t = 36$ months was lower in subjects with unexpected normal imaging at 72% compared to those with expected abnormal imaging at 92%. Antiparkinson medication was not used over 3 years in 7 of these 15 SWEDD patients (47%) over 3 years which is surprising given the mean disease duration of 6.3 years (it was never used in 7 of 56 patients (12%) with a PD diagnosis and abnormal imaging and mean disease duration of 5 years)(163) A non-significant increase in UPDRS (motor) of an average 5 points (SD 10) over 3 years contrasts to the significant increase seen with subjects with expected abnormal imaging. Further

to this, it is notable that the SWEDD population had a positive family history of tremor disorder in 67% (versus 19% for subjects with baseline abnormal SPECT imaging), and an alcohol response was noted in 7% (versus 5% for those with abnormal imaging).

The final diagnosis of the SWEDD population cannot be answered by this study, however, we find evidence that SWEDD's have a different imaging and clinical course to those with degenerative parkinsonism and imaging evidence of dopamine deficit and this is supported by observations in other studies of poor levodopa response(163), lack of progression in sequential dopaminergic imaging(213), and consideration that a PD diagnosis is unlikely in over half of SWEDD's after consensus panel video review(216).

We have demonstrated a very high interrater agreement between scan reports (of normal or abnormal) confirmed by the high Kappa coefficients for the SPECT readers which is important in clinical practice. And the notable stability of sensitivity and specificity of the independent blinded SPECT at each time point compared to the gold-standard diagnosis (Table 6-6) results from imaging that remains normal or abnormal in most cases.

Conclusion

PD was overdiagnosed clinically in this series. The gold-standard clinical diagnosis (at 3 years) indicates a high specificity for baseline [¹²³I] FP-CIT SPECT, suggesting that combining clinical and imaging assessments could reduce overdiagnosis of PD in this category of patients. A fifth of patients with a 3 - year diagnosis of degenerative parkinsonism had normal scans; their clinical and imaging course differs from that expected with degenerative parkinsonism.

Figure 6-1 Disposition of subjects within the 3 year study of accuracy of [¹²³I] FP-CIT SPECT in early and uncertain parkinsonian/ tremor disorders

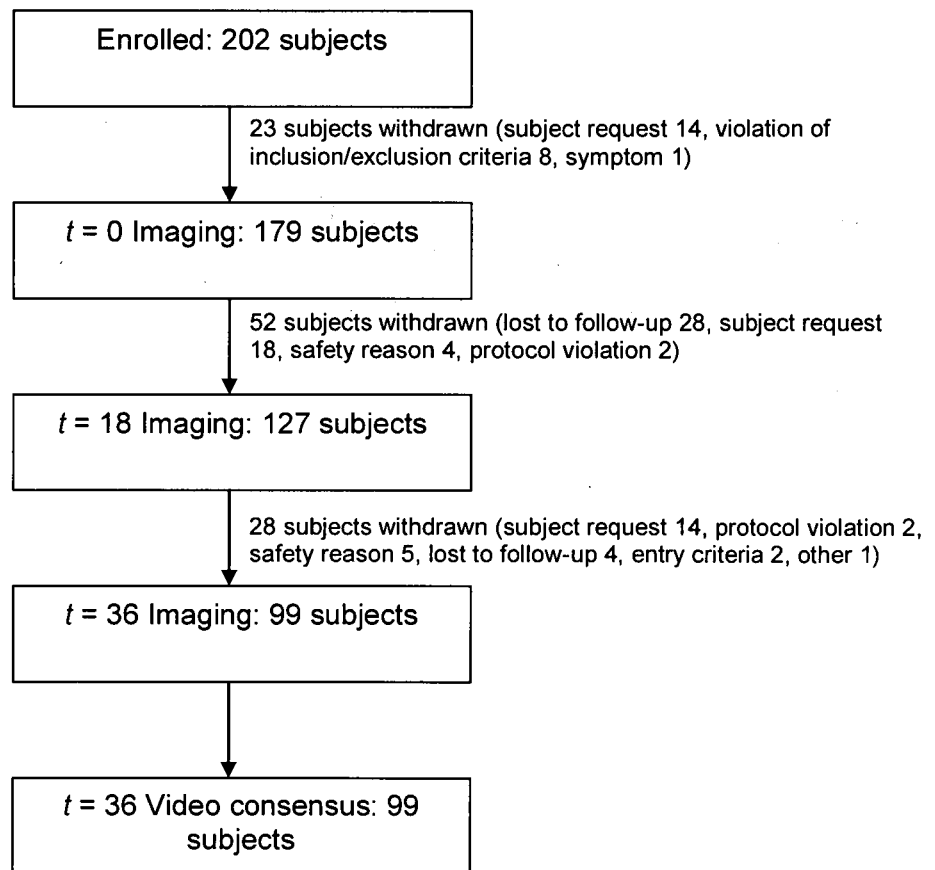


Table 6-1 Baseline demographic and clinical data for 99 subjects with [¹²³I] FP-CIT SPECT according to the consensus video diagnosis

| | Consensus video diagnosis at <i>t</i> = 36 months | | |
|--|---|-------------|--|
| | Degenerative parkinsonism <i>n</i> (%) | | Non-degenerative parkinsonism <i>n</i> (%) |
| | Probable PD | Possible PD | |
| | 66 (66.7) | 5 (5.1) | 28 (28.3) |
| Age (years) | 61 (10) | 69 (9) | 59 (12) |
| Sex Male (%) | 57 (56%) | 2 (40%) | 19 (68%) |
| Height (cm) | 167 (9) | 165 (12) | 170 (9) |
| Weight (kg) | 72 (14) | 66 (13) | 79 (14) |
| H & Y score (<i>n</i> , %) | | | |
| 1 | 31 (47) | 3 (60) | 13 (46) |
| 1.5 | 8 (12) | 0 (0) | 1 (4) |
| 2 | 21 (32) | 2 (40) | 13 (46) |
| 2.5 | 4 (6) | 0 (0) | 1 (4) |
| 3 | 2 (3) | 0 (0) | 0 (0) |
| UPDRS motor <i>t</i> = 0 | 11 (4) | 12 (2) | 6 (4) |
| Symptom duration (years) | 2 (1.5) | 4 (1) | 3 (3) |
| SPECT result at <i>t</i> = 0 | | | |
| Abnormal | 56 (85%) | 0 (0%) | 1 (4%) |
| Normal | 10 (15%) | 5 (100%) | 27 (96%) |
| History of alcohol response (%) | 4 (6%) | 0 (0%) | 2 (7%) |
| Family history of tremor disorder (%) | 17 (26%) | 4 (80%) | 15 (54%) |

Data are mean (SD) unless otherwise specified

UPDRS = Unified Parkinson's Disease Rating Scale, H & Y = modified Hoehn and

Yahr score

Table 6-2 Motor scoring and antiparkinson medication use at $t = 0$ and 36 months according to consensus video diagnosis

| | Probable PD <i>n</i> = 66 | | Possible PD <i>n</i> = 5 | | Non-PD <i>n</i> = 28 | |
|--------------------------|------------------------------|---------------|-----------------------------|---------------|-------------------------|---------------|
| | <i>t</i> = 0 | <i>t</i> = 36 | <i>t</i> = 0 | <i>t</i> = 36 | <i>t</i> = 0 | <i>t</i> = 36 |
| UPDRS | 11 (4) | 21 (11) | 12 (2) | 12 (4) | 6 (4) | 7 (5) |
| H & Y | 1.5 (0.6) | 2.2 (0.7) | 1.4 (0.5) | 1.6 (0.5) | 1.6 (0.5) | 1.7 (0.8) |
| Antiparkinson medication | 35 (53%) | 53 (80%) | 1 (20%) | 1 (20%) | 1 (4%) | 1 (4%) |
| L-dopa | 16 (24%) | 33 (50%) | 0 (0%) | 1 (20%) | 0 (0%) | 0 (0%) |

Table 6-3 Motor scoring and antiparkinson medication use at $t = 0$ and 36 months according to baseline visual assessment of [123 I] FP-CIT SPECT

| | Baseline [123 I] FP-CIT SPECT result | | | |
|--------------------------|--|---------------|-------------------------|---------------|
| | Abnormal <i>n</i> = 57 | | Normal <i>n</i> = 42 | |
| | <i>t</i> = 0 | <i>t</i> = 36 | <i>t</i> = 0 | <i>t</i> = 36 |
| UPDRS | 11 (4) | 21 (11) | 8 (5) | 10 (8) |
| H & Y | 1.5 (0.6) | 2.1 (0.7) | 1.5 (0.5) | 1.8 (0.8) |
| Antiparkinson medication | 32 (56%) | 49 (86%) | 5 (11%) | 6 (14%) |
| L-dopa | 14 (25%) | 30 (53%) | 2 (5%) | 4 (10%) |

Table 6-4 Change in motor UPDRS and antiparkinson medication use according to consensus video diagnosis and baseline visual assessment of [¹²³I] FP-CIT SPECT

| | UPDRS motor change (SD) | Increase in number of subjects on antiparkinson medication (%) | Increase in number of subjects on L-dopa (%) |
|--|-----------------------------|--|--|
| According to gold-standard video consensus diagnosis at <i>t</i> = 36 months | | | |
| Probable PD <i>n</i> = 66 (SPECT 56 abnormal: 10 normal scans) | +10.0 (10.6) ^{***} | +27.0% | +26.0% |
| Possible PD <i>n</i> = 5 (SPECT 5 normal scans) | 0.0 (5.4) ^{ns} | 0.0% | +20.0% |
| Non-PD <i>n</i> = 28 (SPECT 27 normal: 1 abnormal scan) | +0.7 (4.1) ^{ns} | 0.0% | 0.0% |
| According to baseline imaging result | | | |
| Abnormal <i>n</i> = 57 | +10.2 (10.5) ^{***} | +30.0% | +28.0% |
| Normal <i>n</i> = 42 | +2.3 (7.0) [*] | +2.0% | +5.0% |

Data are mean (SD) unless otherwise stated. All changes are over 3 year study period. UPDRS = Unified Parkinson's Disease Rating Scale; *t* = time from study entry

*** = $p < 0.0001$, * = $p < 0.05$, ^{ns} = not significant $p > 0.05$

Table 6-5 Diagnostic sensitivity, specificity, predictive values and accuracy of clinical and imaging diagnoses compared to the 3 year consensus video diagnosis

| time (months) | Diagnosis method | Sensitivity | Specificity | PPV | NPV | Accuracy |
|---------------|----------------------------|-------------|-------------|-----|---------|----------|
| <i>t</i> = 0 | On-site clinical diagnosis | 93 (84-98) | 46 (27-66) | 81 | 72 | 80 |
| | On-site SPECT read | 80 (69-89) | 90 (74-98) | 95 | 67 | 83 |
| | Independent SPECT read* | 77.5 - 78.5 | 96.6 | 98 | 65 - 67 | 83 - 84 |
| <i>t</i> = 18 | Independent SPECT read* | 77.5 - 81.5 | 92.9 - 96.4 | - | - | - |
| <i>t</i> = 36 | Independent SPECT read* | 75 - 77.9 | 96.3 | - | - | - |

Data are % (95% confidence interval). *Values for independent SPECT readings are ranges as values were calculated separately for each of 3 readers. *t* = time from study entry, PPV = positive predictive value, NPV = negative predictive value.

Table 6-6 Consensus video diagnosis versus baseline on-site diagnosis and baseline visual assessment of [¹²³I] FP-CIT SPECT

| | Probable PD | | | Possible PD | | | Benign tremulous PD | | Non-PD | | |
|--|-------------|-----------|-----------|-------------|-----------|-------------|---------------------|------------|------------|-----------|-------------|
| | 44 | | | 31 | | | 6 | | 18 | | |
| <i>t</i> = 0 On-site diagnosis | ↓ | | | ↓ | | | ↓ | | ↓ | | |
| <i>t</i> = 36 'Gold standard' video diagnosis | Prob PD | Poss PD | Non-PD | Prob PD | Poss PD | Non-PD | Prob PD | Poss PD | Prob PD | Poss PD | Non-PD |
| | 38 (86%) | 2 (5%) | 4 (9%) | 19 (61%) | 1 (3%) | 11 (36%) | 5 (83%) | 1 (17%) | 4 (22%) | 1 (6%) | 13 (72%) |
| SPECT <i>t</i> = 0 Abnormal: normal | ↓ | ↓ | ↓ | ↓ | ↓ | ↓ | ↓ | ↓ | ↓ | ↓ | ↓ |
| | 35:3 | 0:2 | 0:4 | 16:3 | 0:1 | 1:10 | 3:2 | 0:1 | 2:2 | 0:1 | 0:13 |

t = time in months from study entry

Chapter 7 : Discussion and interpretation

Discussion

Although the development of diagnostic dopamine transporter imaging showed high accuracy in differentiating patients fulfilling criteria for Parkinson's disease from those with essential tremor(161;162), the application of this technique in routine clinical practice requires a different analysis. The comparative utility of SPECT imaging to differentiate between degenerative parkinsonism and other mimics such as drug-induced parkinsonism or vascular parkinsonism are additional diagnostic pairings which are of clinical importance. The meaning of a normal SPECT(214) is one of the most important areas under debate and relates to the clinical features and the final diagnosis of subjects with a PD diagnosis but unexpected normal dopaminergic imaging, a field where little information is available. The lack of large blinded long-term clinical assessments of dopamine transporter imaging in early and uncertain parkinsonism has received criticism(218), as it is often early in the disease course when there is the most clinical uncertainty.

The main aims of this research were therefore:

- 1) To further the understanding of the current clinical use of dopamine transporter imaging in uncertain parkinsonian disorders, and in particular to provide information on trends of imaging use, diagnosis and scan mismatch or misdiagnosis between different diagnostic pairings, with reference to the clinical features in 190 subjects in the multicentre UK Case Collection study (Chapters 2, 3 and 4),
- 2) Clarification of the meaning of normal dopamine transporter imaging in the context of clinical uncertainty between degenerative parkinsonism and a non-degenerative mimic. Evidence is derived to answer this question from the 3 year follow-up of 150 consecutive subjects with normal [¹²³I] FP-CIT SPECT and more specifically, follow-up of antiparkinson therapy withdrawal in 11

subjects who fulfilled criteria for parkinsonism (Chapter 5), together with the assessment of precision of baseline SPECT imaging in a large long-duration blinded prospective European-wide study of 99 subjects with uncertain parkinsonian conditions (Chapter 6).

- 3) To obtain facts to add to the few available, on the clinical and imaging characteristics of subjects with scans without evidence of dopaminergic deficit (SWEDD's) who have a diagnosis of Parkinson's disease, which has been accomplished through follow-up and withdrawal of antiparkinson medication in 11 patients (Chapter 5) and through the blinded European-wide study in 99 subjects with uncertain parkinsonism (Chapter 6).

A number of features make this work unique:

Whilst there have been a number of contributions from the literature on the utility of dopamine transporter imaging in routine clinical practice(122;186;281), few have been prospective assessments, nor on such a large scale such as the UK Case Collection (Chapters 2, 3 and 4). Neither do they focus on the diagnostic subgroupings to allow inter-group comparisons of scan/ diagnosis mismatch rates which can potentially raise clinicians' awareness of difficult diagnostic areas and fuel future research.

We provide the first ever account of the follow-up of 150 subjects with normal SPECT and of a smaller but more specifically defined group with antiparkinson therapy withdrawal (Chapter 5) which has not been described before in the literature.

The European-wide blinded prospective study of [¹²³I] FP-CIT SPECT in early parkinsonism and tremor disorders (Chapter 6) is unique because of its scale, and because the gold-standard diagnosis was made 3 years after presentation (which is 2 years longer than that of the only previous blinded study in uncertain parkinsonism(164)), which potentially allows for a 'more accurate' gold standard

diagnosis. It is also the first study to use the video-rater diagnosis as a gold standard in this context.

The main contributions of this thesis are therefore directed toward advancing the understanding of the diagnostic utility of dopamine transporter imaging in early and uncertain parkinsonian tremor disorders within routine clinical practice and within the blinded trial setting and are summarised as follows:

The use of dopamine transporter imaging in routine clinical practice in uncertain parkinsonian syndromes

The UK Case Collection Study reflects the use of dopamine transporter imaging in routine clinical practice. The initial tentative clinical diagnosis was incorrect in a quarter of cases according to the post-scan revised diagnosis (mismatch) which is influenced by knowledge of the SPECT result. A third of patients considered to have degenerative parkinsonism had normal imaging (only 2% had a diagnosis of degenerative parkinsonism post-scan) and a quarter suspected to have non-degenerative parkinsonism had abnormal imaging. Patterns of higher mismatch rate were identified for a pre-scan diagnosis of vascular parkinsonism which was incorrect in nearly a half, and unexpected abnormal imaging was found in a parkinsonian distribution (not a focal reduction pattern). Additionally, a higher rate of diagnostic change after imaging occurred when parkinsonism was associated with dementia or dystonia. A large proportion (43%) fulfilling Brain Bank Criteria part 1 (bradykinesia plus at least one of tremor, rigidity or postural instability) had normal scans. This figure may appear high, but it must be realised that patients were selected for diagnostic uncertainty regarding the presence or absence of parkinsonism, and that fulfilment of other Brain Bank criteria was not required. Nevertheless, this is a representative proportion of cases with uncertain parkinsonism in the clinical practice of UK movement disorder experts.

SPECT by visual assessment was usually either clearly abnormal or normal, with a few cases (3%) of abnormal/ borderline results which were clearly not helpful in aiding the diagnostic decision.

An assessment of the clinical features of diagnostic pairing between degenerative parkinsonism and essential tremor, identified rarer clinical presentations such as prominent asymmetrical postural tremor without rest tremor occurring in degenerative parkinsonism(21) and normal scans occurring in the context of definite rest tremor without a postural component (in which the post-scan diagnosis was a benign tremor disorder), and asymmetrical tremor was a common feature in patients with ET.

Within the diagnostic pairing of degenerative parkinsonism and drug-induced parkinsonism there are a number of interesting clinical and imaging findings.

Asymmetry and rest tremor were often documented in patients with drug-induced parkinsonism, which adds to the current evidence that DIP can present identically to PD(65). A proportion of patients with DIP did not improve or only partially improved after the follow-up time-period, suggesting either dual pathology, or that clinical improvement may sometimes be considerably delayed after withdrawal of drugs which cause DIP. As well as the usual dopamine depleting culprits, we identified 9 subjects with DIP where valproate was used. This complements the recent identification of valproate induced parkinsonism(255).

Additionally in this drug-induced diagnostic pairing, we identified 2 with borderline normal imaging results, which is of great interest considering the potential for patients with subclinical Parkinson's disease (where the dopaminergic imaging might still be normal) to be unmasked by the post-synaptic blockade effect of dopamine-depletors, resulting in a near-normal scan. This scenario has already been highlighted(219), and here we identified patients at risk of this but so far without evidence of imaging progression and clinical progression after drug withdrawal.

The meaning of normal dopamine transporter imaging

Nearly all of the 150 patients (Chapter 5) who had normal [¹²³I] FP-CIT SPECT had final diagnoses of non-degenerative parkinsonism or benign tremor disorders (mostly essential tremor), despite a most likely pre-scan diagnosis of degenerative parkinsonism in half of them, and antiparkinson medication use in one third. The lack of clinical progression and lack of response to antiparkinson medication (in those who used it) is not in keeping with emerging degenerative parkinsonism. Uncertain (and non-classifiable) parkinsonism occurs in around 5% of consecutive parkinsonian cases attending specialist clinics, and in our study a proportion of patients had non-classifiable disorders which were considered to be non-degenerative in origin in most, although in 4 a diagnosis of degenerative parkinsonism (although uncertain) remained. This was despite repeat normal imaging in 2 subjects.

More specifically, we reviewed 11 patients with normal SPECT who fulfilled Brain Bank criteria and were on antiparkinson medication, many of whom could have been considered for entry into studies with PD. Medication was stopped without deterioration and diagnoses were revised away from degenerative parkinsonism - mostly to essential tremor, because of a combination of knowledge of the imaging result and emergence of clinical features which argued against PD. These patients had symptom duration of 5.6 years prior to SPECT and follow-up for a further 3 years. We consider these patients similar to SWEDD's and withdrawal of medication in these patients - successful or otherwise - has not been reported previously. This series is therefore instructive to the movement disorder community, in that misdiagnoses of non-degenerative parkinsonism/ benign tremor disorders do occur, even in the context of the fulfilment of Brain Bank criteria (all 3 criteria continued to be fulfilled in 3 of 11 subjects).

Sensitivity and specificity of [¹²³I] FP-CIT SPECT in early and uncertain parkinsonian disorders

In the European-wide study of early parkinsonism/ tremor disorders, there are a number of interesting observations.

When considering the primary study objective, the sensitivity of the baseline imaging was around 78% and specificity was very high at 97%. However, the on-site baseline clinical diagnosis over-diagnosed PD according to the 3 year gold standard diagnosis. This means that the baseline imaging has a higher positive predictive value than a baseline clinical diagnosis, but a lower negative predictive value. That is, according to this gold-standard a baseline SPECT can rule in degenerative parkinsonism but it cannot rule it out. The reasons for this poorer sensitivity have been considered in depth in Chapter 6. These sensitivity results are lower than those reported in a smaller blinded prospective study of dopamine transporter imaging(208) which is surprising. When comparing this group of SWEDD's (subjects with scans without evidence of dopaminergic deficit) to those with a PD diagnosis and evidence of dopaminergic deficiency, there are important differences. The cases reported here displayed no significant change in motor rating scales over 3 years, and around half of SWEDD's remained off PD medication, suggesting a different rate of clinical deterioration than is seen in true idiopathic PD. There was additional evidence that such patients are a difficult group to diagnose; there was higher video-rater disagreement between a degenerative parkinsonism versus non-degenerative diagnosis, and lower confidence in diagnosis in the SWEDD's. Additionally in half of the SWEDD cases the on-site clinician disagreed with a diagnosis of degenerative parkinsonism (although they were aware of SPECT result which may have biased them towards this).

Importantly, repeated imaging in the SWEDD group remained normal in virtually all cases. One subject had imaging which changed from normal to abnormal. This subject was rated by one video-rater at each time point as having either multiple

system atrophy or vascular parkinsonism and we have discussed in Chapter 6 the possibility of the rare occurrence of minimal change MSA(280) or CBD(181), where the scan might be normal or borderline. We have not found evidence that this scenario occurs more than rarely. Over the 3 year monitoring period, most SWEDD's have a lack of clinical progression and a different antiparkinson therapy requirement and an imaging course which is out of keeping with that expected in degenerative parkinsonism.

Limitations

The unblinded nature of the UK multicentre case collection leads to a potentially circular argument of the utility of imaging and misdiagnosis rates based on the clinician's belief of the accuracy, and especially the sensitivity of dopamine transporter imaging. However, this particular study relates to day-to-day application of dopamine transporter imaging and its influence in routine clinical practice, rather than its 'correctness'. Also it is unlikely that a clinician would be comfortable changing from a degenerative parkinsonism diagnosis if clinical deterioration were apparent in keeping with degenerative parkinsonism, nor would we expect it would deter a trial of antiparkinson therapy in such a setting. This is supported by the evidence that over 3 years the vast majority of patients with normal imaging did not deteriorate or experience antiparkinson medication benefit which would be in keeping with an emerging degenerative parkinsonian diagnosis.

Conclusion

In routine clinical practice, one quarter of patients with uncertain parkinsonism undergoing [¹²³I] FP-CIT SPECT initially have an incorrect clinical diagnosis. Diagnostic change occurred in the vast majority of cases in line with the scan result, which is demonstrative of the considerable influence of dopamine transporter imaging.

A substantial proportion of patients who fulfil basic criteria (Brain Bank part 1) for Parkinson's disease actually have normal dopamine transporter imaging. Prolonged follow-up of these subjects identifies a lack of clinical progression, and a poor antiparkinson therapy response which is not in keeping with emerging degenerative parkinsonism. Additionally patients initially considered to have a PD diagnosis with fulfilment of PD criteria, but with normal SPECT are able to successfully stop antiparkinson therapy without deterioration.

Parkinson's disease is clinically over-diagnosed at an early stage, and clinicians might benefit from the superior ability of early SPECT to 'rule in' degenerative parkinsonism. Subjects with a gold standard of degenerative parkinsonism but normal SPECT follow a different clinical and imaging course to those with evidence of dopaminergic deficit on imaging.

If SPECT imaging is normal in the case of a patient with parkinsonism, this is a major indication that the patient suffers from a non-degenerative parkinsonian condition.

Subsequent to this, unless we can be certain that these subjects definitely have PD (and we provide evidence to the contrary), it would be pertinent to use functional dopaminergic imaging as an adjunctive tool to ensure that in the trial setting, therapy is not tested on patients with normal imaging whom we have shown to have a different clinical progression and antiparkinson medication requirement and response to those with a confirmed PD diagnosis.

Reference List

- (1) Hughes AJ, Daniel SE, Kilford L, Lees AJ. Accuracy of clinical diagnosis of idiopathic Parkinson's disease: a clinico-pathological study of 100 cases. *J Neurol Neurosurg Psychiatry* 1992; 55(3):181-184.
- (2) Fearnley JM, Lees AJ. Striatonigral degeneration. A clinicopathological study. *Brain* 1990; 113 (Pt 6):1823-1842.
- (3) Hughes AJ, Ben Shlomo Y, Daniel SE, Lees AJ. What features improve the accuracy of clinical diagnosis in Parkinson's disease: a clinicopathologic study. *Neurology* 2001; 57(10 Suppl 3):S34-S38.
- (4) Hughes AJ, Daniel SE, Ben Shlomo Y, Lees AJ. The accuracy of diagnosis of parkinsonian syndromes in a specialist movement disorder service. *Brain* 2002; 125:861-870.
- (5) Roeber S, Neumann M, Kretschmar HA. The accuracy of diagnosis of parkinsonian syndromes: Clinico-pathological study of the German Brain Bank "Brain-Net". *Parkinsonism & Related Disorders*. 11 Suppl 2, 165-166. 2005.
- (6) Jankovic J, Rajput A, McDermott M. The Evolution of Diagnosis in Early Parkinson Disease. *Arch Neurol* 57[3], 369-372. 2000.
- (7) Schrag A, Ben Shlomo Y, Quinn N. How valid is the clinical diagnosis of Parkinson's disease in the community? *J Neurol Neurosurg Psychiatry* 73, 529-534. 2002.
- (8) Meara J, Bhowmick BK, Hobson P. Accuracy of diagnosis in patients with presumed Parkinson's disease. *Age Ageing* 1999; 28(2):99-102.
- (9) Louis ED. Essential tremor. *Lancet Neurology* 2005; 4(2):100-110.
- (10) de Lau LMLM, Schipper CM, Hofman AM, Koudstaal PJM, Breteler MMBM. Prognosis of Parkinson Disease: Risk of Dementia and Mortality: The Rotterdam Study. [Article]. *Arch Neurol* 2005; 62(8):1265-1269.

- (11) de Rijk MC, Tzourio C, Breteler MMB, Dartigues JF, Amaducci L, Lopez-Pousa S et al. Prevalence of parkinsonism and Parkinson's disease in Europe: the EUROPARKINSON collaborative study. *J Neurol Neurosurg Psychiatry* 62[1], 10-15. 1997.
- (12) Benito-Leon J, Bermejo-Pareja F, Rodriguez J, Molina JA, Gabriel R, Morales JM. Prevalence of PD and other types of parkinsonism in three elderly populations of central Spain. *Mov Disord* 2003; 18(3):267-274.
- (13) Benito-Leon J, Bermejo-Pareja F, Morales-Gonzalez JM, Porta-Etessam J, Trincado R, Vega S et al. Incidence of Parkinson disease and parkinsonism in three elderly populations of central Spain. *Neurology* 2004; 62(5):734-741.
- (14) Cardoso F, Camargos ST, Silva GA, Jr. Etiology of parkinsonism in a Brazilian movement disorders clinic. *Arquivos de Neuro-Psiquiatria* 1998;(2):171-175.
- (15) Stephen PJ, Williamson J. Drug-induced parkinsonism in the elderly. *Lancet* 1984; 2(8411):1082-1083.
- (16) Lee CS, Schulzer M, Mak E, Hammerstad JP, Calne S, Calne DB. Patterns of asymmetry do not change over the course of idiopathic parkinsonism: Implications for pathogenesis. *Neurology* 1995;(31):435-439.
- (17) Toth C, Rajput M, Rajput AH. Anomalies of asymmetry of clinical signs in Parkinsonism. *Mov Disord* 2004;(2):151-157.
- (18) Chaudhuri KR, Yates L, Martinez-Martin P. The non-motor symptom complex of Parkinson's disease: A comprehensive assessment is essential. *Current Neurology & Neuroscience Reports* 2005;(4):275-283.
- (19) Hughes AJ, Daniel SE, Blankson S, Lees AJ. A clinicopathologic study of 100 cases of Parkinson's disease. *Arch Neurol* 1993; 50(2):140-148.
- (20) Poewe WH, Wenning GK. The natural history of Parkinson' disease. *Annals of Neurology* 1998; 44(3 SUPPL. 1):S1-S9.

- (21) Chaudhuri KR, Buxton-Thomas M, Dhawan V, Peng R, Meilak C, Brooks DJ. Long duration asymmetrical postural tremor is likely to predict development of Parkinson's disease and not essential tremor: clinical follow up study of 13 cases. *J Neurol Neurosurg Psychiatry* 2005; 76(1):115-117.
- (22) Bozi M, Bhatia KP. Paroxysmal Exercise-Induced Dystonia as a Presenting feature of Young-Onset Parkinson's Disease. *Mov Disord* 18[12], 1545-1547. 2003.
- (23) Braak H, Del Tredici K, Rüb U, de Vos RAI, Jansen Steur ENH, Braak E. Staging of brain pathology related to sporadic Parkinson's disease. *Neurobiol Aging* 24, 197-211. 2003.
- (24) Jellinger KA. Overview of morphological changes in Parkinson's disease. *Adv Neurol* 45, 1-18. 1986.
- (25) Pakkenberg B, Møller A, Gunderson HJG, Dam AM, Pakkenberg H. The absolute number of nerve cells in substantia nigra in normal subjects and in patients with Parkinson's disease estimated with an unbiased stereological method. *J Neurol Neurosurg Psychiatry* 54, 30-33. 1991.
- (26) Fearnley JM, Lees AJ. Ageing and Parkinson's disease: substantia nigra regional selectivity. *Brain* 1991; 114 (Pt 5):2283-2301.
- (27) Gerfen CR, Herkenham M, Thibault J. The neostriatal mosaic: II. Patch- and matrix-directed mesostriatal dopaminergic and non-dopaminergic systems. *J Neuroscience* 1987; 7(12):3915-3934.
- (28) Kish SJ, Shannak K, Hornykiewicz O. Uneven pattern of dopamine loss in the striatum of patients with idiopathic Parkinson's disease. Pathophysiologic and clinical implications. *N Engl J Med* 1988; 318(14):876-880.
- (29) Findley L, Aujla M, Bain PG, Baker M, Beech C, Bowman C et al. Direct economic impact of Parkinson's disease: a research survey in the United Kingdom. *Mov Disord* 2003; 18(10):1139-1145.

- (30) Gibb WRG, Lees AJ. The significance of the Lewy body in the diagnosis of idiopathic Parkinson's disease. *Neuropath & Applied Neurobiology* 1989;(1):27-44.
- (31) Hughes AJ, Ben Shlomo Y, Daniel SE, Lees AJ. What features improve the accuracy of clinical diagnosis in Parkinson's disease: A clinicopathologic study. *Neurology* 42, 1142-1146. 1992.
- (32) Hughes AJ, Daniel SE, Lees AJ. Improved accuracy of clinical diagnosis of Lewy body Parkinson's disease. *Neurology* 2001; 57(8):1497-1499.
- (33) Litvan I, Bhatia KP, Burn DJ, Goetz CG, Lang AE, McKeith I et al. SIC task force appraisal of clinical diagnostic criteria for parkinsonian disorders. *Mov Disord* 2003; 18(5):467-486.
- (34) Jellinger KA, Seppi K, Wenning GK. Grading of neuropathology in multiple system atrophy: proposal for a novel scale. *Mov Disord* 2005; 20 Suppl 12:S29-S36.
- (35) Schrag A, Ben Shlomo Y, Quinn NP. Prevalence of progressive supranuclear palsy and multiple system atrophy: A cross-sectional study. *Lancet* Vol 1999; 354(9192):1771-1775.
- (36) Osaki Y, Ben Shlomo Y, Wenning GK, Daniel SE, Hughes A, Lees AJ et al. Do published criteria improve clinical diagnostic accuracy in multiple system atrophy? *Neurology* 2002; 59(10):1486-1491.
- (37) Joseph JA, Dickson DW. Diagnostic accuracy of progressive supranuclear palsy in the Society for Progressive Supranuclear Palsy brain bank. *Mov Disord* 18, 1018-1026. 2003.
- (38) Burn DJ, Lees AJ. Progressive Supranuclear Palsy: Where are we now? *Lancet Neurology* 1, 359-369. 2002.
- (39) Maher ER, Lees AJ. The clinical features and natural history of the Steele-Richardson-Olszewski syndrome (progressive supranuclear palsy). *Neurology* 36, 1005-1008. 1986.

- (40) Brin MF, Koller W. Epidemiology and Genetics of Essential Tremor. *Mov Disord*. 13[Supplement 3], 55-63. 1998.
- (41) Lou JS, Jankovic J. Essential tremor: clinical correlates in 350 patients.[see comment]. *Neurology* 1991; 41(2:(Pt 1):t-8.
- (42) Rajput AH, Rozdilsky B. Essential leg tremor. *Neurology* 40, 1909. 1990.
- (43) Louis ED, Ford B, Wendt KJ, Cameron G. Clinical Characteristics of Essential Tremor: Data From a Community-Based Study. *Mov Disord* 13[5], 803-808. 1998.
- (44) Rajput AH, Rozdilsky B, Ang L, Rajput A. Significance of Parkinsonian manifestations in Essential Tremor. *Can.J.Neurol.Sci.* 20, 114-117. 1993.
- (45) Borges V, Ferraz HB, de Andrade LA. Essential Tremor: clinical characterization in a sample of 176 patients. *Arquivos de Neuro-Psiquiatria* 52[2], 161-165. 1994.
- (46) Rajput AH, Jamieson H, Hirsch S, Quraishi A. Relative efficacy of alcohol and propranolol in action tremor. *Can.J.Neurol.Sci.* 2[1], 31-35. 1975.
- (47) Rajput AH, Rozdilsky B, Ang L, Rajput A. Clinicopathologic observations in essential tremor: report of six cases. *Neurology* 1991; 41(9):1422-1424.
- (48) Louis ED, Honig LS, Vonsattel JPG, Maraganore DM, Borden S, Moskowitz CB. Essential tremor associated with focal nonnigral Lewy bodies: A clinicopathologic study. *Arch Neurol* 2005;(6):1004-1007.
- (49) Rajput A, Rajput M. Essential Tremor and Parkinsonism. *Adv Neurol* 91, 397-399. 2003.

- (50) Rajput A, Robinson CA, Rajput AH. Essential tremor course and disability. A clinicopathological study of 20 cases. *Neurology* 62, 932-936. 2004.
- (51) Geraghty JJ, Jankovic J, Zetuský WJ. Association between essential tremor and Parkinson's disease. *Ann Neurol* 17, 329-333. 1985.
- (52) Koller WC, Busenbark K, Miner K. The Relationship of Essential Tremor to Other Movement Disorders: Report on 678 patients. *Ann Neurol* 35, 717-723. 1994.
- (53) Deuschl G, Bain P, Brin M. Consensus statement of the Movement Disorder Society on Tremor. Ad Hoc Scientific Committee. *Mov Disord* 1998; 13 Suppl 3:2-23.
- (54) Critchley M. Arteriosclerotic parkinsonism. *Brain* 52, 23-83. 1929.
- (55) Sibon I, Fenelon G, Quinn NP, Tison F. Vascular parkinsonism. *J Neurol* 2004; 251(5):513-524.
- (56) Zijlmans JCM, Daniel SE, Hughes AJ, Révész T, Lees AJ. Clinicopathological investigation of vascular parkinsonism, including clinical criteria for diagnosis. *Mov Disord*. 19[6], 630-640. 2004.
- (57) Zijlmans JCM, Katzenschlager R, Daniel SE, Lees AJL. The L-dopa response in vascular parkinsonism. *J Neurol Neurosurg Psychiatry* 2004; 75(4):545-547.
- (58) Winikates J, Jankovic J. Vascular progressive supranuclear palsy. *J Neural Transm Suppl* 1994; 42:189-201.
- (59) Alarcón F, Zijlmans JCM, Dueñas G, Cevallos N. Post-stroke movement disorders: report of 56 patients. *J Neurol Neurosurg Psychiatry* 75, 1568-1574. 2003.
- (60) Foltynie T, Barker R, Brayne C. Vascular parkinsonism: a review of the precision and frequency of the diagnosis. [Review] [48 refs]. *Neuroepidemiology* 2002; 21(1):1-7.

- (61) Jellinger KA. Vascular parkinsonism--neuropathological findings. *Acta Neurologica Scandinavica* 2002; 105(5):414-415.
- (62) Papapetropoulos S, Ellul J, Argyriou AA, Talelli P, Chroni E, Papapetropoulos T. The effect of vascular disease on late onset Parkinson's disease. *Eur J Neurology* 2004; 11(4):231-235.
- (63) Rajput AH, Offord KP, Beard CM, Kurland LT. Epidemiology of parkinsonism: incidence, classification, and mortality. *Ann Neurol* 1984; 16(3):278-282.
- (64) Montastruc JL, Llau ME, Rascol O, Senard JM. Drug-induced parkinsonism: a review. *Fundamental & Clinical Pharmacology* 1994; 8(4):293-306.
- (65) Lorberboym M, Treves TA, Melamed E, Lampl Y, Hellmann M, Djaldetti R. [(123)I]-FP/CIT SPECT imaging for distinguishing drug-induced parkinsonism from Parkinson's disease. *Mov Disord* 2006; 21(4):510-514.
- (66) Sethi KD, Zamrini EY. Asymmetry in clinical features of drug-induced parkinsonism. *J Neuropsychiatry Clin Neurosci* 1990; 2(1):64-66.
- (67) Hassin-Baer S, Sirota P, Korczyn AD, Treves TA, Epstein B, Shabtai H et al. Clinical characteristics of neuroleptic-induced parkinsonism. *J Neural Transm* 108, 1299-1308. 2001.
- (68) Hardie RJ, Lees AJ. Neuroleptic-induced Parkinson's syndrome: clinical features and results of treatment with levodopa. *J Neurol Neurosurg Psychiatry* 51, 850-854. 1988.
- (69) Stephen PJ, Williamson J. Drug-induced parkinsonism in the elderly. *Lancet* 1984; 2:1082-1083.
- (70) Caligiuri MP, Lacro JP, Jeste DV. Incidence and predictors of drug-induced parkinsonism in older psychiatric patients treated with very low doses of neuroleptics. *J Clin Psychopharm* 1999; 19(4):322-328.
- (71) Klawans HL, Jr., Bergen D, Bruyn GW. Prolonged drug-induced Parkinsonism. *Confin Neurol* 1973; 35(6):368-377.

- (72) Rajput AH, Rozdilsky B, Hornykiewicz O, Shannak K, Lee T, Seeman P. Reversible drug-induced parkinsonism. Clinicopathologic study of two cases. *Arch Neurol* 1982; 39(10):644-646.
- (73) Chabolla DR, Maraganore DM, Ahlskog JE, O'Brien PC, Rocca WA. Drug-induced parkinsonism as a risk factor for Parkinson's disease: a historical cohort study in Olmsted County, Minnesota. *Mayo Clin Proc* 1998; 73(8):724-727.
- (74) Marti-Masso JF, Poza JJ. Cinnarizine-induced parkinsonism: ten years later. *Mov Disord* 1998; 13(3):453-456.
- (75) Marti Masso JF, Carrera N, Urtasun M. Drug-induced parkinsonism: a growing list. *Mov Disord* 1993; 8(1):125.
- (76) Marti Masso JF, Poza JJ. [Drug-induced or aggravated parkinsonism: clinical signs and the changing pattern of implicated drugs]. *Neurologia* 1996; 11(1):10-15.
- (77) Spence SA, Crimlisk HL, Cope H, Ron MA, Graseby PM. Discrete neuropsychological correlates in prefrontal cortex during hysterical and feigned disorder of movement. *Lancet* 355, 1243-1244. 2000.
- (78) Schrag A, Lang AE. Psychogenic movement disorders. *Curr Opin Neurol* 18, 399-404. 2005.
- (79) Factor SA, Podskalny GD, Molho ES. Psychogenic movement disorders: frequency, clinical profile, and characteristics. *Journal of Neurol, Neurosurg & Psychiatry*. 59[4], 406-412. 1995.
- (80) Feinstein A, Stergiopoulos V, Fine J, Lang AE. Psychiatric outcome in patients with a psychogenic movement disorder: a prospective study. *Neuropsychiatry Neuropsychol Behav Neurol* 14[3], 169-176. 2001.
- (81) Koller WC, Lang A, Vetere-Overfield RN, Findley L, Cleaves L, Factor S et al. Psychogenic tremors. *Neurology* 1989; 39:1094-1099.
- (82) Lang AE, Koller WC, Fahn S. Psychogenic Parkinsonism. *Arch Neurol* 52[8], 802-810. 1995.

- (83) Williams DT, Ford B, Fahn S. Phenomenology and psychopathology related to psychogenic movement disorder. *Adv Neurol* 65, 231-257. 1995.
- (84) Nygaard TG. Dopa-responsive dystonia. Delineation of the clinical syndrome and clues to pathogenesis. [Review] [92 refs]. *Adv Neurol* 1993; 60:577-585.
- (85) Paviour DC, Surtees RA, Lees AJ. Diagnostic considerations in juvenile parkinsonism. [Review] [131 refs]. *Mov Disord* 1919;(2):123-135.
- (86) Stevens T, Livingston G, Kitchen G, Manela M, Walker Z, Katona C. Islington study of dementia subtypes in the community. *British J Psychiatry* 2002; 180:270-276.
- (87) McKeith IG, Fairbairn AF, Perry RH, Thompson P. The clinical diagnosis and misdiagnosis of senile dementia of Lewy body type (SDLT). *British J Psychiatry* 1994; 165(3):324-332.
- (88) Ala TA, Yang KH, Sung JH, Frey WH. Hallucinations and signs of parkinsonism help distinguish patients with dementia and cortical Lewy bodies from patients with Alzheimer's disease at presentation: a clinicopathological study. *J Neurol Neurosurg Psychiatry* 1997; 62(1):16-21.
- (89) Swanberg MM, Cummings JL. Benefit-risk Considerations in the Treatment of Dementia with Lewy bodies. *Drug Safety* 2002; 25(7):511-523.
- (90) Ditter SM, Mirra SS. Neuropathologic and clinical features of Parkinson's disease in Alzheimer's disease patients. *Neurology* 1987; 37:754-760.
- (91) Hansen L, Salmon D, Galasko D, Masliah E, Katzman R, DeTeresa R et al. The Lewy body variant of Alzheimer's disease: A clinical and pathologic entity. *Neurology* 1990; 40:1-8.

- (92) McKeith IGM, Galasko DM, Kosaka KM, Perry EKD, Dickson DWM, Hansen LAM et al. Consensus guidelines for the clinical and pathologic diagnosis of dementia with Lewy bodies (DLB): Report of the consortium on DLB international workshop. *Neurology* 1996; 47(5):1113-1124.
- (93) McKeith IGM, Ballard CGM, Perry RHM, Ince PGM, O'Brien JTD, Neill DP et al. Prospective validation of Consensus criteria for the diagnosis of dementia with Lewy bodies. *Neurology* 2000; 54(5):1050-1058.
- (94) Bowler JV, Munoz DG, Merskey H, Hachinski V. Fallacies in the pathological confirmation of the diagnosis of Alzheimer's disease. *J Neurol Neurosurg Psychiatry* 1998; 64(1):18-24.
- (95) Perneczky R, Mosch D, Neumann M, Kretschmar H, Muller U, Busch R et al. The Alzheimer variant of lewy body disease: a pathologically confirmed case-control study. *Dementia & Geriatric Cognitive Disorders* 1920;(2-3):89-94.
- (96) Clarke CE, Davies P. Systematic review of acute levodopa and apomorphine challenge tests in the diagnosis of idiopathic parkinson's disease. *J Neurol Neurosurg Psychiatry* 2000; 69:590-594.
- (97) Albanese A, Bonuccelli U, Brefel C, Chaudhuri KR, Colosimo C, Eichhorn T et al. Consensus Statement on the Role of Acute Dopaminergic Challenge in Parkinson's Disease. *Mov Disord* 16[2], 197-201. 2001.
- (98) Wolters EC, Francot C, Bergmans P, Winogrodzka A, Booij J, Berendse HW et al. Preclinical (premotor) Parkinson's disease. *J Neurol* 2000; 247 Suppl 2:II103-II109.
- (99) Sommer U, Hummel T, Cormann K, Mueller A, Frasnelli J, Kropp J et al. Detection of Presymptomatic Parkinson's Disease: Combining Smell Tests, Transcranial Sonography, and SPECT. *Mov Disord* 2004; 19(10):1196-1202.

- (100) Jennings DL, Tabamo R, Seibyl JP, Marek K. Olfactory Identification Testing as an Early Marker for Parkinsonian Syndrome. *Neurology* 64 Suppl 1, A202. 2005.
- (101) McInerney-Leo A, Hadley DW, Gwinn-Hardy K, Hardy J. Genetic testing in Parkinson's Disease. *Mov Disord* 1, 1-10. 2005.
- (102) Schrag A, Kingsley D, Phatouros C, Mathias CJ, Lees AJ, Daniel SE et al. Clinical usefulness of magnetic resonance imaging in multiple system atrophy. *J Neurol Neurosurg Psychiatry* 1998; 65(1):65-71.
- (103) Paviour DC, Price SL, Stevens JM, Lees AJ, Fox NC. Quantitative MRI measurement of superior cerebellar peduncle in progressive supranuclear palsy. *Neurology* 64[4], 675-679. 2005.
- (104) Seppi K, Schocke MFH. An update on conventional and advanced magnetic resonance imaging techniques in the differential diagnosis of neurodegenerative parkinsonism. *Curr Opin Neurol* 18, 370-375. 2005.
- (105) Walter U, Wittstock M, Benecke R, Dressler D. Substantia nigra echogenicity is normal in non-extrapyramidal cerebral disorders but increased in Parkinson's disease. *J Neural Transm* 2002; 109(2):191-196.
- (106) Walter U, Niehaus L, Probst T, Benecke R, Meyer BU, Dressler D. Brain parenchymal sonography discriminates Parkinson's disease and atypical parkinsonian syndromes. *Neurology* 60, 74-77. 2003.
- (107) Eckert T, Barnes A, Dhawan V, Frucht S, Gordon MF, Feigin AS et al. FDG PET in the differential diagnosis of parkinsonian disorders. *Neuroimage* 2005; 26(3):912-921.
- (108) Braune S, Reinhardt M, Schnitzer R, Riedel A, Lücking CH. Cardiac uptake of [123I]MIBG separates Parkinson's disease from multiple system atrophy. *Neurology* 53, 1020-1025. 1999.

- (109) Spiegel J, Möllers M, Jost WH, Fuss G, Samnick S, Dillman U et al. FP-CIT and MIBG Scintigraphy in Early Parkinson's Disease. *Mov Disord* 20[5], 552-561. 2005.
- (110) Wilson JM, Levey AI, Rajput A, Ang L, Guttman M, Shannak K et al. Differential changes in neurochemical markers of striatal dopamine nerve terminals in idiopathic Parkinson's disease. *Neurology* 1996; 47(3):718-726.
- (111) Kaufman MJ, Madras BK. Severe depletion of cocaine recognition sites associated with the dopamine transporter in Parkinson's-diseased striatum. *Synapse* 1991; 9(1):43-49.
- (112) Niznik HB, Fogel EF, Fassos FF, Seeman P. The dopamine transporter is absent in parkinsonian putamen and reduced in the caudate nucleus. *J Neurochem* 1991; 56(1):192-198.
- (113) Jaber M, Jones S, Giros B, Caron MG. The dopamine transporter: a crucial component regulating dopamine transmission. *Mov Disord* 1997; 12(5):629-633.
- (114) Mozley PD, Schneider JS, Acton PD, Plossl K, Stern M, Siderowf A et al. Binding of [99mTc]TRODAT-1 to Dopamine Transporters in Patients with Parkinson's Disease and in Healthy Volunteers. *J Nucl Med* 2000; 41:584-589.
- (115) Marek K, Innis RB, Van Dyck CH, Fussell B, Early M, Eberly S et al. [123I]beta-CIT SPECT imaging assessment of the rate of Parkinson's disease progression. *Neurology* 2001; 57:2089-2094.
- (116) Kim HJ, Im JH, Yang SO, Moon DH, Ryu JS, Bong JK et al. Imaging and Quantitation of Dopamine Transporters with Iodine-123-IPT in Normal and Parkinson's Disease Subjects. *J Nucl Med* 1997; 38:1703-1711.
- (117) Booij J, Tissingh G, Boer GJ, Speelman JD, Stoof JC, Janssen AG et al. [123I]FP-CIT SPECT shows a pronounced decline of striatal dopamine transporter labelling in early and advanced Parkinson's disease. *J Neurol Neurosurg Psychiatry* 1997; 62(2):133-140.

- (118) Kessler KR, Hamscho N, Morales B, Menzel C, Barrero F, Vives F et al. Dopaminergic function in a family with the PARK6 form of autosomal recessive Parkinson's syndrome. *J Neural Transm* 2005; 112(10):1345-1353.
- (119) Khan NL, Jain S, Lynch JM, Pavese N, Abou-Sleiman P, Holton JL et al. Mutations in the gene LRRK2 encoding dardarin (PARK8) cause familial Parkinson's disease: clinical, pathological, olfactory and functional imaging and genetic data. *Brain* 128(Pt 12):2786-96, 2005.
- (120) Abi-Dargham A, Gandelman MS, DeErausquin GA, Zea-Ponce Y, Zoghbi SS, Baldwin RM et al. SPECT imaging of dopamine transporters in human brain with iodine-123-fluoroalkyl analogs of beta-CIT. *J Nucl Med* 1996; 37(7):1129-1133.
- (121) Kao P-F, Tzen K-Y, Yen T-C, Lu C-S, Weng Y-H, Wey S-P et al. The optimal imaging time for [99mTc]TRODAT-1/SPET in normal subjects and patients with Parkinson's disease. *Nucl Med Comm* 2001; 22(2):151-154.
- (122) Booij J, Tissingh G, Winogrodzka A, Boer GJ, Stoof JC, Wolters EC et al. Practical benefit of [123I]FP-CIT SPET in the demonstration of the dopaminergic deficit in Parkinson's disease. *Eur J Nucl Med* 1997; 24(1):68-71.
- (123) Booij J, Habraken JB, Bergmans P, Tissingh G, Winogrodzka A, Wolters EC et al. Imaging of dopamine transporters with iodine-123-FP-CIT SPECT in healthy controls and patients with Parkinson's disease. *J Nucl Med* 1998; 39(11):1879-1884.
- (124) Seibyl JP, Marek K, Sheff K, Baldwin RM, Zoghbi S, Zea-Ponce Y et al. Test/retest reproducibility of iodine-123-betaCIT SPECT brain measurement of dopamine transporters in Parkinson's patients. *J Nucl Med* 1997; 38(9):1453-1459.
- (125) Winogrodzka A, Booij J, Wolters EC. Disease-related and drug-induced changes in dopamine transporter expression might undermine the reliability of imaging studies of disease progression in

Parkinson's disease. *Parkinsonism & Related Disorders* 2005;(8):475-484.

- (126) Innis RB, Marek K, Sheff K, Zoghbi S, Castronuovo J, Feigin A et al. Effect of treatment with l-dopa/carbidopa or l-selegiline on striatal dopamine transporter SPECT imaging with [123 I] beta-CIT. *Mov Disord* 1999; 14(3):436-442.
- (127) Marek K. Pramipexole versus Levodopa in the CALM-PD CIT study: Effects on Parkinson's disease progression assessed by dopamine transporter imaging. Parkinson Study Group. Presentation EFNS Vienna 2002.
- (128) Schillaci O, Pierantozzi M, Filippi L, Manni C, Brusa L, Danieli R et al. The effect of levodopa therapy on dopamine transporter SPECT imaging with (123)I-FP-CIT in patients with Parkinson's disease. *Eur J Nucl Med & Molecular Imaging* 2005; 32(12):1452-1456.
- (129) Ahlskog JE, Uitti RJ, O'Connor MK, Maraganore DM, Matsumoto JY, Stark KF et al. The effect of dopamine agonist therapy on dopamine transporter imaging in Parkinson's disease. *Mov Disord* 1999; 14(6):940-946.
- (130) Lee CS, Samii A, Sossi V, Ruth TJ, Schulzer M, Holden JE et al. In vivo positron emission tomographic evidence for compensatory changes in presynaptic dopaminergic nerve terminals in Parkinson's disease. *Ann Neurol* 2000; 47(4):493-503.
- (131) Haapaniemi TH, Ahonen A, Torniainen P, Sotaniemi KA, Myllyla VV. [123I]beta-CIT SPECT Demonstrates Decreased Brain Dopamine and Serotonin Transporter Levels in Untreated Parkinsonian Patients. *Mov Disord* 2001; 16(1):124-130.
- (132) Tissingh G, Bergmans P, Booij J, Winogrodzka A, van Royen EA, Stoof JC et al. Drug-naive patients with Parkinson's disease in Hoehn and Yahr stages I and II show a bilateral decrease in striatal dopamine transporters as revealed by [123I]beta-CIT SPECT. *J Neurol* 1998; 245(1):14-20.

- (133) Benamer HT, Oertel WH, Patterson J, Hadley DM, Pogarell O, Hoffken H et al. Prospective study of presynaptic dopaminergic imaging in patients with mild parkinsonism and tremor disorders: part 1. Baseline and 3-month observations. *Mov Disord* 2003; 18(9):977-984.
- (134) Benamer HT, Patterson J, Wyper DJ, Hadley DM, Macphee GJ, Grosset DG. Correlation of Parkinson's disease severity and duration with ¹²³I-FP-CIT SPECT striatal uptake. *Mov Disord* 2000; 15(4):692-698.
- (135) Filippi L, Manni C, Pierantozzi M, Brusa L, Danieli R, Stanzione P et al. ¹²³I-FP-CIT semi-quantitative SPECT detects preclinical bilateral dopaminergic deficit in early Parkinson's disease with unilateral symptoms. *Nucl Med Comm* 2005; 26(5):421-426.
- (136) Marek K, Seibyl J, Zoghbi SS, Zea-Ponce Y, Baldwin RM, Fussell B et al. [¹²³I]beta-CIT/SPECT imaging demonstrates bilateral loss of dopamine transporters in hemi-Parkinson's disease. *Neurology* 1996; 46:231-237.
- (137) Booij J, Bergmans P, Winogrodzka A, Speelman JD, Wolters EC. Imaging of dopamine transporters with [¹²³I]FP-CIT SPECT does not suggest a significant effect of age on the symptomatic threshold of disease in Parkinson's disease. *Synapse* 2001; 39(2):101-108.
- (138) Schwarz J, Linke R, Kerner M, Mozley PD, Trenkwalder C, Gasser T et al. Striatal dopamine transporter binding assessed by [¹²³I]IPT and single photon emission computed tomography in patients with early Parkinson's disease: implications for a preclinical diagnosis. *Arch Neurol* 2000; 57(2):205-208.
- (139) Weng YH, Yen TC, Chen MC, Kao PF, Tzen KY, Chen RS et al. Sensitivity and specificity of ^{99m}Tc-TRODAT-1 SPECT imaging in differentiating patients with idiopathic Parkinson's disease from healthy subjects. *J Nucl Medicine* 2004.
- (140) Berendse HW, Booij J, Francot CM, Bergmans PL, Hijman R, Stoof JC et al. Subclinical dopaminergic dysfunction in asymptomatic Parkinson's disease patients' relatives with a decreased sense of smell. *Ann Neurol* 2001; 50(1):34-41.

- (141) Seibyl JP, Marek KL, Quinlan D, Sheff K, Zoghbi S, Zea-Ponce Y et al. Decreased Single-Photon Emission Computed tomographic [¹²³I] β-CIT Striatal Uptake Correlates with Symptom Severity in Parkinson's Disease. *Ann Neurol* 1995; 38:589-598.
- (142) Lavalaye J, Booij J, Reneman L, Habraken J, van Royen EA. Effect of age and gender on dopamine transporter imaging with [123 I] FP-CIT SPET in healthy volunteers. *Eur J Nucl Med* 27, 867-869. 2000.
- (143) Van Dyck CH, Seibyl JP, Malison RT, Laruelle M, Wallace E, Zoghbi S et al. Age-Related decline in Striatal Dopamine Transporter Binding with Iodine-123-β-CIT SPECT. *J Nucl Med* 1995; 36:1175-1181.
- (144) Chouker M, Tatsch K, Linke R, Pogarell O, Hahn K, Schwarz J. Striatal dopamine transporter binding in early to moderately advanced Parkinson's disease: monitoring of disease progression over 2 years. *Nucl Med Comm* 2001; 22(6):721-725.
- (145) Nurmi E, Ruottinen HM, Kaasinen V, Bergman J, Haaparanta M, Solin O et al. Progression in Parkinson's disease: a positron emission tomography study with a dopamine transporter ligand [18F]CFT. *Ann Neurol* 2000; 47(6):804-808.
- (146) Nurmi E, Bergman J, Eskola O, Solin O, Vahlberg T, Sonninen P et al. Progression of dopaminergic hypofunction in striatal subregions in Parkinson's disease using [¹⁸F]CFT PET. *Synapse* 2003; 48(3):109-115.
- (147) Parkinson Study Group. Levodopa and the Progression of Parkinson's Disease. *N Engl J Med* 2004; 351(24):2498-2508.
- (148) Pirker W, Djamshidian S, Asenbaum S, Gerschlager W, Tribl G, Hoffmann M et al. Progression of Dopaminergic Degeneration in Parkinson's Disease and Atypical Parkinsonism: A Longitudinal beta-CIT SPECT study. *Mov Disord* 2002; 17(1):45-53.
- (149) Staffen W, Mair A, Unterrainer J, Trinka E, Ladurner G. Measuring the progression of idiopathic Parkinson's disease with [123I] beta-CIT SPECT. *J Neural Transm* 2000; 107(5):543-52.

- (150) Winogrodzka A, Bergmans P, Booij J, van Royen EA, Stoof JC, Wolters EC. [¹²³I]beta-CIT SPECT is a useful method for monitoring dopaminergic degeneration in early stage Parkinson's disease. *J Neurol, Neurosurg & Psychiatry* 2003;(3):294-298.
- (151) Winogrodzka A, Bergmans P, Booij J, van Royen EA, Janssen AG, Wolters EC. [¹²³I]FP-CIT SPECT is a useful method to monitor the rate of dopaminergic degeneration in early-stage Parkinson's disease. *J Neural Transm* 2001; 108(8-9):1011-1019.
- (152) Morrish PK, Sawle GV, Brooks DJ. An [¹⁸F]dopa-PET and clinical study of the rate of progression in Parkinson's disease. *Brain* 1996; 119 (Pt 2):585-591.
- (153) Morrish PK, Rakshi JS, Bailey DL, Sawle GV, Brooks DJ. Measuring the rate of progression and estimating the preclinical period of Parkinson's disease with [¹⁸F]dopa PET. *J Neurol Neurosurg Psychiatry* 1998; 64(3):314-319.
- (154) Morrish PK, Sawle GV, Brooks DJ. The rate of progression of Parkinson's disease. A longitudinal [¹⁸F]DOPA PET study. *Adv Neurol* 1996; 69:427-431.
- (155) Nurmi E, Ruottinen HM, Bergman J, Haaparanta M, Solin O, Sonninen P et al. Rate of progression in Parkinson's disease: a 6-[¹⁸F]fluoro-L-dopa PET study. *Mov Disord* 2001; 16(4):608-615.
- (156) Brück A, Aalto S, Nurmi E, Vahlberg T, Bergman J, Rinne JO. Striatal subregional 6-[¹⁸F]fluoro-L-dopa uptake in early Parkinson's disease: A two-year follow-up study. *Mov Disord* published online. 2006.
- (157) Busca MR, Antonini A, Lopatriello S, Berto P. Economic evaluation of SPECT-DaTSCAN in the diagnosis of patients with clinically uncertain parkinsonism in Italy. *Parkinsonism & Related Disorders* 11 Suppl 2, 141 PT009-03. 2005.
- (158) Brüggjenjürgen B, Smala A, Chambers M. Outcomes and costs of DaTSCAN in the diagnosis of parkinsonism. *Parkinsonism & Related Disorders* 11 Suppl 2, 151 PT013-07. 2005.

- (159) Louis ED, Levy G, Cote LJ, Mejia H, Stanley F, Marder K. Clinical Correlates of Action Tremor in Parkinson Disease. *Arch.Neurol.* 58[10], 1630-1634. 2001.
- (160) Asenbaum S, Pirker W, Angelberger P, Bencsits G, Pruckmayer M, Brucke T. [123I]beta-CIT and SPECT in essential tremor and Parkinson's disease. *J Neural Transm* 1998; 105(10-12):1213-1228.
- (161) Benamer TS, Patterson J, Grosset DG, Booij J, de Bruin K, van Royen E et al. Accurate differentiation of parkinsonism and essential tremor using visual assessment of [123I]-FP-CIT SPECT imaging: the [123I]-FP-CIT study group. *Mov Disord* 2000; 15(3):503-510.
- (162) Parkinson Study Group. A multicentre assessment of dopamine transporter imaging with DOPASCAN/SPECT in parkinsonism. *Neurology* 2000; 55:1540-1547.
- (163) Fahn S, Shoulson I, Kieburtz K, Rudolph A, Lang A, Olanow CW et al. Levodopa and the progression of Parkinson's disease. *New England Journal of Medicine* 2004; 351(24):2498-2508.
- (164) Jennings DL, Seibyl JP, Oakes D, Eberly S, Murphy J, Marek K. [123I] β -CIT and single-photon emission computed tomographic imaging vs clinical evaluation in parkinsonian syndrome: unmasking an early diagnosis. *Arch Neurol* 61[8], 1224-1229. 2004.
- (165) Lee MS, Kim YD, Im JH, Kim HJ, Rinne JO, Bhatia KP. 123I-IPT brain SPECT study in essential tremor and Parkinson's disease. *Neurology* 1999; 52(7):1422-1426.
- (166) Booij J, Speelman JD, Horstink MW, Wolters EC. The clinical benefit of imaging striatal dopamine transporters with [123I]FP-CIT SPET in differentiating patients with presynaptic parkinsonism from those with other forms of parkinsonism. *Eur J Nucl Med* 2001; 28(3):266-272.
- (167) Brucke T, Asenbaum S, Pirker W, Djamshidian S, Wenger S, Wober C et al. Measurement of the dopaminergic degeneration in Parkinson's disease with [123I] beta-CIT and SPECT. Correlation with clinical

- findings and comparison with multiple system atrophy and progressive supranuclear palsy. *J Neural Transm Suppl* 1997; 50:9-24.
- (168) Varrone A, Marek KL, Jennings D, Innis RB, Seibyl JP. [¹²³I]beta-CIT SPECT imaging demonstrates reduced density of striatal dopamine transporters in Parkinson's disease and multiple system atrophy. *Mov Disord* 2001; 16(6):1023-1032.
- (169) Pirker W, Asenbaum S, Bencsits G, Prayer D, Gerschlager W, Deecke L et al. [123I]beta-CIT SPECT in multiple system atrophy, progressive supranuclear palsy, and corticobasal degeneration. *Mov Disord* 2000; 15(6):1158-1167.
- (170) Kim YJ, Ichise M, Ballinger JR, Vines D, Erami SS, Tatschida T et al. Combination of Dopamine Transporter and D2 Receptor SPECT in the Diagnostic Evaluation of PD, MSA, and PSP. *Mov Disord* 2002; 17(2):303-312.
- (171) Dresel SH, Kung MP, Huang XF, Plossl K, Hou C, Meegalla SK et al. Simultaneous SPECT studies of pre- and postsynaptic dopamine binding sites in baboons. *J Nucl Med* 1999; 40(4):660-666.
- (172) Plotkin M, Amthauer H, Klaffke S, Kuhn A, Ludemann L, Arnold G et al. Combined (123)I-FP-CIT SPECT and (123)I-IBZM SPECT for the diagnosis of parkinsonian syndromes: a study on 72 patients. *J Neural Transm* 112[5], 677-692. 2005.
- (173) Cilia R, Marotta G, Benti R, Pezzoli G, Antonini A. Brain SPECT imaging in multiple system atrophy. *J Neural Transm* 2005; 112(12):1635-1645.
- (174) Winikates J, Jankovic J. Clinical correlates of vascular parkinsonism. *Arch Neurol* 1999; 56(1):98-102.
- (175) Daniel SE, Lees AJ. Parkinson's Disease Society Brain Bank, London: overview and research. *J Neural Transm Suppl* 1993; 39:165-172.
- (176) Tzen KY, Lu CS, Yen TC, Wey SP, Ting G. Differential diagnosis of Parkinson's disease and vascular parkinsonism by (99m)Tc-TRODAT-1. *J Nucl Med* 2001; 42(3):408-413.

- (177) Gerschlager W, Bencsits G, Pirker W, Bloem BR, Asenbaum S, Prayer D et al. [123I]B-CIT SPECT distinguishes vascular parkinsonism from Parkinson's disease. *Mov Disord.* 518-523. 2002.
- (178) Lorberboym M, Djaldetti R, Melamed E, Sadeh M, Lampl Y. ¹²³I-FP-CIT SPECT Imaging of Dopamine Transporters in Patients with Cerebrovascular Disease and Clinical Diagnosis of Vascular Parkinsonism. *J Nucl Med* 45, 1688-1693. 2004.
- (179) Peralta C, Werner P, Holl P, Kiechl S, Willeit J, Seppi K et al. Parkinsonism following striatal infarcts: incidence in a prospective stroke unit cohort. *J Neural Transm* 111[10-11], 1473-1483. 2004.
- (180) Piggott MA, Marshall EF, Thomas N, Lloyd S, Court JA, Jaros E et al. Striatal dopaminergic markers in dementia with Lewy bodies, Alzheimer's and Parkinson's diseases: rostrocaudal distribution. *Brain* 1999; 122(Pt 8):1449-1468.
- (181) Walker Z, Costa DC, Walker RW, Shaw K, Gacinovic S, Stevens T et al. Differentiation of dementia with Lewy bodies from Alzheimer's disease using a dopaminergic presynaptic ligand. *J Neurol Neurosurg Psychiatry* 2002; 73(2):134-140.
- (182) O'Brien JT, Colloby S, Fenwick J, Williams ED, Firbank M, Burn D et al. Dopamine transporter loss visualized with FP-CIT SPECT in the differential diagnosis of dementia with Lewy bodies. *Arch Neurol* 2004; 61(6):919-925.
- (183) Donnemiller E, Heilmann J, Wenning GK, Berger W, Decristoforo C, Moncayo R et al. Brain perfusion scintigraphy with 99mTc-HMPAO or 99mTc-ECD and 123I-beta-CIT single-photon emission tomography in dementia of the Alzheimer-type and diffuse Lewy body disease. *Eur J Nucl Med* 1997; 24(3):320-325.
- (184) Rinne JO, Laine M, Kaasinen V, Norvasuo-Heila MK, Nagren K, Helenius H. Striatal dopamine transporter and extrapyramidal symptoms in frontotemporal dementia. *Neurology* 2002; 58(10):1489-1493.

- (185) Lavalaye J, Linszen DH, Booij J, Dingemans PM, Reneman L, Habraken JB et al. Dopamine transporter density in young patients with schizophrenia assessed with [123I]FP-CIT SPECT. *Schizophrenia Research* 2001; 47(1):59-67.
- (186) Løkkegaard A, Werdelin LM, Friberg L. Clinical Impact of diagnostic SPET investigations with a dopamine re-uptake ligand. *Eur J Nucl Med* 2002; 29(12):1623-1629.
- (187) Booij J, Rijk-van Andel PJ, Noorden RA. No loss of striatal dopamine transporters and D2 receptors in patients with autosomal recessive dopa-responsive dystonia. *J Nucl Med* 1999; 40(5):-67.
- (188) Jeon BS, Jeong JM, Park SS, Kim JM, Chang YS, Song HC et al. Dopamine transporter density measured by [123I]beta-CIT single-photon emission computed tomography is normal in dopa-responsive dystonia. *Ann Neurol* 1998; 43(6):792-800.
- (189) Naumann M, Pirker W, Reiners K, Lange K, Becker G, Brucke T. [123I]beta-CIT single-photon emission tomography in DOPA-responsive dystonia. *Mov Disord* 1997; 12(3):448-451.
- (190) O'Sullivan JD, Costa DC, Gacinovic S, Lees AJ. SPECT imaging of the dopamine transporter in juvenile-onset dystonia. *Neurology* 2001; 56(2):266-267.
- (191) Takahashi H, Snow BJ, Nygaard TG, Calne DB. Clinical heterogeneity of dopa-responsive dystonia: PET observations. *Adv Neurol* 1993; 60:586-590.
- (192) O'Sullivan JD, Costa DC, Lees AJ. Confirming Parkinson's disease with 123I FP-CIT SPECT (abstract). *Eur J Neurology* 1999; 6(3):-131.
- (193) Gaig C, Nakamae F, Martí MJ, Paredes P, Valldeoriola F, Tolosa E. Diagnostic value of 123I-lobflupane SPECT in psychogenic parkinsonism [abstract]. 20 Suppl 10, S110 [P370]. 2005.
- (194) Benaderette S, Zanotti Fragonara P, Apartis E, Nguyen C, Trocillo JM, Vidailhet M. Psychogenic Parkinsonism: Combination of clinical, electrophysiological and [123I]-lobflupane SPECT scan explorations

- improves diagnostic accuracy. *Mov Disord* 20 Suppl 10, S130 [P440]. 2005.
- (195) Jeon B, Kim JM, Jeong JM, Kim KM, Chang YS, Lee DS et al. Dopamine transporter imaging with [123I]-beta-CIT demonstrates presynaptic nigrostriatal dopaminergic damage in Wilson's disease. *J Neurol Neurosurg Psychiatry* 1998; 65(1):60-64.
- (196) Yen TC, Lu CS, Tzen KY, Wey SP, Chou YH, Weng YH et al. Decreased dopamine transporter binding in Machado-Joseph disease. *J Nucl Med* 2000; 41(6):994-998.
- (197) Varrone A, Salvatore E, De Michele G, Barone P, Sansone V, Pellecchia MT et al. Reduced striatal [123 I]FP-CIT binding in SCA2 patients without parkinsonism. *Ann Neurol* 2004.
- (198) Gunther P, Storch A, Schwarz J, Sabri O, Steinbach P, Wagner A et al. Basal ganglia involvement of a patient with SCA 17- a new form of autosomal dominant spinocerebellar ataxia. *J Neurol* 251, 896-897. 2004.
- (199) Borasio GD, Linke R, Schwarz J, Schlamp V, Abel A, Mozley PD et al. Dopaminergic deficit in amyotrophic lateral sclerosis assessed with [I-123] IPT single photon emission computed tomography. *J Neurol Neurosurg Psychiatry* 1998; 65(2):263-265.
- (200) Minnerop M, Kornblum C, Joe AY, Tatsch K, Kunz WS, Klockgether T et al. Dopamine transporter SPECT in patients with mitochondrial disorders. [Report]. *J Neurol Neurosurg Psychiatry* 2005; 76(1):118-120.
- (201) Malison RT, McDougle CJ, Van Dyck CH, Scahill L, Baldwin RM, Seibyl JP et al. [123I]beta-CIT SPECT imaging of striatal dopamine transporter binding in Tourette's disorder. *Am J Psych* 1995; 152(9):1359-1361.
- (202) Naumann M, Pirker W, Reiners K, Lange KW, Becker G, Brucke T. Imaging the pre- and postsynaptic side of striatal dopaminergic

- synapses in idiopathic cervical dystonia: a SPECT study using [123I] epidepride and [123I] beta-CIT. *Mov Disord* 1998; 13(2):319-323.
- (203) Wetter TC, Eisensehr I, Trenkwalder C. Functional neuroimaging studies in restless legs syndrome. *Sleep Medicine* 5, 401-406. 2004.
- (204) Brooks DJ, Ibanez V, Playford ED, Sawle GV, Leigh PN, Kocen RS et al. Presynaptic and postsynaptic striatal dopaminergic function in neuroacanthocytosis: a positron emission tomographic study. *Ann Neurol* 30[2], 166-171. 1991.
- (205) Minami T, Otsuka M, Ichiya Y, Nomura A, Ueda K. Different patterns of [18F]dopa uptake in siblings with hereditary dentato-rubro-pallidoluysian atrophy. *Brain Dev* 16[4], 335-338. 1994.
- (206) Caparros-Lefebvre D, Cabaret M, Godefroy O, Steinling M, Remy P, Samson Y et al. PET study and neuropsychological assessment of a long-lasting post-encephalitic parkinsonism. *J Neural Transm* 1998; 105(4-5):489-495.
- (207) Ghaemi M, Rudolf J, Schmulling S, Bamborschke S, Heiss WD. FDG- and Dopa-PET in postencephalitic parkinsonism. *J Neural Transm* 2000; 107(11):1289-1295.
- (208) Jennings D, Seibyl J, Marek K. β -CIT SPECT versus Clinical Examination in Parkinsonian Syndrome: Unmasking and Early Diagnosis (abstract). *Mov Disord* 2002; 17(5):-1108.
- (209) Jennings DL, Tabamo R, Seibyl JP, Marek K. Evaluation of Dopamine Transporter Imaging as a Tool for the Early Diagnosis of Parkinsonian Syndromes. *Neurology* 64 Suppl 1, A253. 2005.
- (210) Catafau AM, Tolosa E, DaTSCAN Clinically Uncertain Parkinsonian Syndromes Study Group. Impact of dopamine transporter SPECT using 123I-lobflupane on diagnosis and management of patients with clinically uncertain Parkinsonian syndromes. *Mov Disord* 2004; 19(10):1175-1182.

- (211) Parkinson Study Group. Dopamine transporter brain imaging to assess the effects of pramipexole vs levodopa on Parkinson disease progression. *JAMA* 2002; 287(13):1653-1661.
- (212) Whone AL, Watts RL, Stoessl AJ, Davis M, Reske S, Nahmias C et al. Slower progression of Parkinson's disease with ropinirole versus levodopa: The REAL-PET study. *Ann Neurol* 2003; 54(1):93-101.
- (213) Marek K, Jennings DL, Seibyl JP. Long-Term Follow-Up of Patients with Scans without Evidence of Dopaminergic Deficit (SWEDD) in the ELLDOPA Study. *Neurology* 64 Suppl 1, A274. 2005.
- (214) Morrish P, Marshall V, Grosset D. The meaning of negative DAT SPECT and F-Dopa PET scans in patients with clinical Parkinson's disease (multiple letters) [2]. *Mov Disord* 2005; 20(1):117-118.
- (215) Seibyl J, Jennings D, Tabamo R, Marek K. The role of neuroimaging in the early diagnosis and evaluation of Parkinson's disease. *Minerva Medica* 2005;(5):353-364.
- (216) Marek KL. Dopamine transporter imaging - challenging the evidence (platform presentation at the International Congress on Parkinson's Disease and Related Disorders, Berlin, Germany). 2005.
- (217) Eerola J, Tienari PJ, Kaakkola S, Nikkinen P, Launes J. How useful is [123I]beta-CIT SPECT in clinical practice? *J Neurol Neurosurg Psychiatry* 2005; 76(9):1211-1216.
- (218) Ravina B, Eidelberg D, Ahlskog JE, Albin RL, Brooks DJ, Carbon M et al. The role of radiotracer imaging in Parkinson disease. *Neurology* 2005; 64(2):208-215.
- (219) Kemp PM. Imaging the dopaminergic system in suspected parkinsonism, drug induced movement disorders, and Lewy body dementia. *Nucl Med Comm* 2005; 26(2):87-96.
- (220) Bhatia KP, Marsden CD. The behavioural and motor consequences of focal lesions of the basal ganglia in man. *Brain* 1994; 117 (Pt 4):859-876.

- (221) Talairach J, Tournoux P. Co-Planar stereotactic atlas of the human brain. 3-Dimensional proportional system: an approach to cerebral imaging. Stuttgart: Georg Thieme Verlag, 1998.
- (222) Burn DJ, Brooks DJ. Nigral dysfunction in drug-induced parkinsonism: an 18F-dopa PET study. *Neurology* 1993; 43:552-556.
- (223) Stoffers D, Booij J, Bosscher L, Winogrodzka A, Wolters EC, Berendse HW. Early-stage [¹²³I]beta-CIT SPECT and long-term clinical follow-up in patients with an initial diagnosis of Parkinson's disease. *Eur J Nucl Med & Molecular Imaging* 2005;(6):689-695.
- (224) Filippi L, Manni C, Pierantozzi M, Brusa L, Danieli R, Stanzione P et al. 123I-FP-CIT in progressive supranuclear palsy and in Parkinson's disease: a SPECT semiquantitative study. *Nucl Med Comm* 2006; 27(4):381-386.
- (225) Samii A, Nutt JG, Ransom BR. Parkinson's disease. *Lancet* 2004; 363:1783-1793.
- (226) Jennings DL, Seibyl JP, Tabamo R, Marek K. Evaluating the diagnostic accuracy of [123-I]β-CIT and SPECT in parkinsonian syndrome. *Mov Disord.* 19 (Suppl.9), S385. 2004.
- (227) Morrish PK. REAL and CALM: What Have We Learned? *Mov Disord.* 18[7], 839-840. 2003.
- (228) Brooks DJ, Playford ED, Ibanez V, Sawle GV, Thompson PD, Findley L et al. Isolated tremor and disruption of the nigrostriatal dopaminergic system: An 18F-dopa PET study. *Neurology* 1992; 42:1554-1560.
- (229) Cohen O, Pullman S, Jurewicz E, Watner D, Louis ED. Rest tremor in patients with essential tremor: prevalence, clinical correlates, and electrophysiological characteristics. *Arch Neurol* 60[3], 405-410. 2003.
- (230) Jankovic J, Schwartz KS, Ondo W. Re-emergent tremor of Parkinson's disease. *J Neurol, Neurosurg & Psychiatry.* 67[5], 646-650. 1999.

- (231) Baldereschi M, Di Carlo A, Rocca WA, Vanni P, Maggi S, Perissinotto E et al. Parkinson's disease and parkinsonism in a longitudinal study: two-fold higher incidence in men. ILSA Working Group. Italian Longitudinal Study on Aging. *Neurology* 2000; 55(9):1358-1363.
- (232) Bower JH, Maraganore DM, McDonnell SK, Rocca WA. Incidence and distribution of parkinsonism in Olmsted County, Minnesota, 1976-1990. *Neurology* 1999; 52(6):1214-1220.
- (233) Rajput AH, Offord KP, Beard CM, Kurland LT. Epidemiology of parkinsonism: incidence, classification, and mortality. *Ann Neurol* 1984; 16(3):278-282.
- (234) Barbosa MT, Caramelli P, Maia DP, Cunningham MCQ, Guerra HL, Lima-Costa MF et al. Parkinsonism and Parkinson's disease in the elderly: A community-based survey in Brazil (the Bambui study). *Mov Disord* , epub. 2006.
- (235) Hansen TE, Brown WL, Weigel RM, Casey DE. Underrecognition of tardive dyskinesia and drug-induced parkinsonism by psychiatric residents. *General Hospital Psychiatry* 1992; 14(5):340-344.
- (236) Bower JH, Dickson DW, Taylor L, Maraganore DM, Rocca WA. Clinical correlates of the pathology underlying parkinsonism: a population perspective. *Mov Disord* 2002; 17(5):910-916.
- (237) Goetz CG. Drug-induced Parkinsonism and idiopathic Parkinson's disease. *Arch Neurol* 1983; 40(5):325-326.
- (238) Rajput AH, Rozdilsky B, Hornykiewicz O, Shannak K, Lee T, Seeman P. Reversible drug-induced parkinsonism. Clinicopathologic study of two cases. *Arch Neurol* 1982; 39(10):644-646.
- (239) Mutch WJ, Dingwall-Fordyce I, Downie A, Paterson JG, Roy SR. Parkinson's disease in a Scottish city. *BMJ* 292, 534-536. 1986.
- (240) Caligiuri MP, Bracha HS, Lohr JB. Asymmetry of neuroleptic-induced rigidity: development of quantitative methods and clinical correlates. *Psychiatry Res* 1989; 30(3):275-284.

- (241) Arblaster LA, Lakie M, Mutch WJ, Semple M. A study of the early signs of drug induced parkinsonism. *J Neurol Neurosurg Psychiatry* 1993; 56(3):301-303.
- (242) Giladi N, Kao R, Fahn S. Freezing phenomenon in patients with parkinsonian syndromes. *Mov Disord* 1997; 12(3):302-305.
- (243) Merello M, Starkstein S, Petracca G, Cataneo EA, Manes F, Leiguarda R. Drug-induced parkinsonism in schizophrenic patients: motor response and psychiatric changes after acute challenge with L-Dopa and apomorphine. *Clin Neuropharmacol* 1996; 19(5):439-443.
- (244) Indo T, Ando K. Metoclopramide-Induced Parkinsonism. *Arch Neurol* 39, 494-496. 1982.
- (245) Marsden CD, Tarsy D, Baldessarini RJ. Spontaneous and Drug-Induced Movement Disorders in Psychotic Patients. 219-266. 1975.
- (246) Parkinson's Disease Society. DaTSCAN-SPECT Diagnostic Imaging in the Management of Parkinson's Disease. (A consensus report from the Parkinson's Disease Society.). Oxford: Darwin Medical Communications Limited 2002.
- (247) Jellinger KA. How valid is the clinical diagnosis of Parkinson's disease in the community?[comment]. *J Neurol, Neurosurg & Psychiatry* 2003; 74(7):1005-1006.
- (248) Bower JH, Dickson DW, Taylor L, Maraganore DM, Rocca WA. Clinical correlates of the pathology underlying parkinsonism: a population perspective. *Mov Disord* 2002; 17(5):910-916.
- (249) Siow AC, Subramaniam M, Verma S. Spontaneous parkinsonism in antipsychotic-naive patients with first-episode psychosis. *Canadian Journal of Psychiatry* 2005; 50(7):429-431.
- (250) Honer WG, Kopala LC, Rabinowitz J. Extrapyrarnidal symptoms and signs in first-episode, antipsychotic exposed and non-exposed patients with schizophrenia or related psychotic illness. *J Psychopharmacol* 2005; 19(3):277-285.

- (251) Laruelle M, Abi-Dargham A, van Dyck C, Gil R, Dsouza DC, Krystal J et al. Dopamine and serotonin transporters in patients with schizophrenia: an imaging study with (¹²³I) beta-CIT. *Biol Psychiatry* 2000; 47:371-379.
- (252) Laakso A, Vilkkumäki H, Alakare B, Haaparanta M, Bergman J, Solin O et al. Striatal dopamine transporter binding in neuroleptic-naive patients with schizophrenia studied with positron emission tomography. *Am J Psych* 2000; 157(2):269-271.
- (253) Sjøholm H, Bratlid T, Sundsfjord J. ¹²³I-β-CIT SPECT demonstrates increased presynaptic dopamine transporter binding sites in basal ganglia in vivo in schizophrenia. *Psychopharm* 2004; 173:27-31.
- (254) Mateos JJ, Lomenchosa F, Parellada E, Font M, Fernandez E, Pavia J et al. Decreased striatal dopamine transporter binding assessed with [¹²³I] FP-CIT in first-episode schizophrenic patients with and without short-term antipsychotic-induced parkinsonism. *Psychopharm* 2005; 181(2):401-406.
- (255) Easterford K, Clough P, Kellet M, Fallon K, Duncan S. Reversible parkinsonism with normal β-CIT-SPECT in patients exposed to sodium valproate. *Neurology* 62, 1435-1437. 2004.
- (256) Schillevoort I, van Puijenbroek EP, de Boer A, Roos RAC, Jansen PAF, Leufkens HGM. Extrapyramidal syndromes associated with selective serotonin reuptake inhibitors: a case-control study using spontaneous reports. *Int Clin Psychopharmacol* 2002; 17:75-79.
- (257) Jiménez-Jiménez FJ, García-Ruiz PJ, Molina JA. Drug-Induced Movement Disorders. *Pharmacoepidemiology* 1997; 16(3):180-204.
- (258) Mortimer AM. Antipsychotic treatment in schizophrenia: Atypical options and NICE guidance. *European Psychiatry: the Journal of the Association of European Psychiatrists* 2003; 18(5):209-219.
- (259) Holmes J, Millard J, Greer D, Silcock J. Trends in psychotropic drug use in older patients in general hospitals. *Pharmaceutical Journal* 2003; 271(7272):584-586.

- (260) Kaye JA, Bradbury BD, Jick H. Changes in antipsychotic drug prescribing by general practitioners in the United Kingdom from 1991 to 2000: a population-based observational study. [Miscellaneous Article]. *British Journal of Clinical Pharmacology* 2003; 56(5):569-575.
- (261) Rochon PAM, Stukel TAP, Sykora KM, Gill SM, Garfinkel SM, Anderson GMM et al. Atypical Antipsychotics and Parkinsonism. [Article]. *Archives of Internal Medicine* 2005; 165(16):1882-1888.
- (262) Chuang C, Constantino A, Balmaceda C, Eidelberg D, Frucht SJ. Chemotherapy-induced Parkinsonism responsive to levodopa: An underrecognized entity. *Mov Disord* 2003; 18(3):328-331.
- (263) Zweig RM. The Role of Radiotracer imaging in Parkinson disease. *Neurology* 2005; Epub prior to publication.
- (264) Nurmi E, Ruottinen HM, Kaasinen V, Bergman J, Haaparanta M, Solin O et al. Progression in Parkinson's disease: A positron emission tomography study with a dopamine transporter ligand [18f]CFT. *Ann Neurol* 2000; 47(6):804-808.
- (265) Lai SC, Weng YH, Yen TC, Tsai CC, Chang HC, Wey SP et al. Imaging early-stage corticobasal degeneration with [99mTc]TRODAT-1 SPET. *Nucl Med Comm* 2004; 25(4):339-345.
- (266) van Oostrom JC, Maguire RP, Verschuuren-Bemelmans CC, Veenma-van der Duin L, Pruijm J, Roos RA et al. Striatal dopamine D2 receptors, metabolism, and volume in preclinical Huntington disease. *Neurology* 2005; 65(6):941-943.
- (267) Naumann M, Pirker W, Reiners K, Lange KW, Becker G, Brucke T. Imaging the pre- and postsynaptic side of striatal dopaminergic synapses in idiopathic cervical dystonia: A SPECT study using [123I] epidepride and [123I] beta-CIT. *Mov Disord* 1998; 13(2):319-323.
- (268) Terashi H, Nagata K, Hirata Y, Hatazawa J, Utsumi H. Study on dopamine D₂ binding capacity in vascular parkinsonism. [Japanese]. *Clinical Neurology* 2001;(10):659-664.

- (269) Katzenschlager R, Cardozo A, Cobo MRA, Tolosa E, Lees AJ. Unclassifiable parkinsonism in two European tertiary referral centres for movement disorders. *Mov Disord* 2003; 18(10):1123-1131.
- (270) Evans AH, Katzenschlager R, Paviour D, O'Sullivan JD, Appel S, Lawrence AD et al. Punding in Parkinson's Disease: Its relation to the dopamine dysregulation syndrome. *Mov Disord*. 19[4], 397-405. 2004.
- (271) Schapira AHV, Obeso J. Timing of Treatment Initiation in Parkinson's Disease: A Need for Reappraisal? *Ann Neurol* 59[3], 559-562. 2006.
- (272) Hasbroucq T, Tandonnet C, Micallef-Roll J, Blin O, Possamai C-A. An electromyographic analysis of the effect of levodopa on the response time of healthy subjects. *Psychopharmacology* 2003; 165(3):313-316.
- (273) Zarate Jr CA, Payne JL, Singh J, Quiroz JA, Luckenbaugh DA, Denicoff KD et al. Pramipexole for bipolar II depression: A placebo-controlled proof of concept study. *Biol Psychiatry* 2004; 56(1):54-60.
- (274) Louis ED, Wendt KJ, Pullman SL, Ford B. Is essential tremor symmetric? Observational data from a community-based study of essential tremor. *Arch Neurol* 55[12], 1553-1559. 1998.
- (275) Bennett DA, Beckett LA, Murray AM, Shannon KM, Goetz CG, Pilgrim DM et al. Prevalence of parkinsonian signs and associated mortality in a community population of older people. *N Engl J Med* 1996; 334(2):71-76.
- (276) Findley LJ, Koller WC. Definitions and behavioural classifications. In: Findley LJ, Koller WC, editors. *Marcel Dekker*, 1995: 1-5.
- (277) Rajput AH, Rozdilsky B, Rajput A. Accuracy of clinical diagnosis in parkinsonism--a prospective study. *Can J Neurol Sci* 1991; 18(3):275-278.
- (278) Camicioli R, Grossmann SJ, Spencer PS, Hudnell K, Kent AW. Discriminating mild parkinsonism: Methods for epidemiological research. *Mov Dis* 2001; 16(1):33-40.

- (279) Louis ED, Levy G, Cote LJ, Mejia H, Fahn S, Marder K. Diagnosing Parkinson's disease using videotaped neurological examinations: Validity and factors that contribute to incorrect diagnoses. *Mov Dis* 2002; 17(3):513-517.
- (280) Wenning GK, Quinn N, Magalhaes M, Mathias C, Daniel SE. 'Minimal change' multiple system atrophy. *Mov Dis* 1994; 9(2):161-166.
- (281) Tolosa E, Catafau AM. Clinical Impact of performing SPECT imaging with the dopamine transporter imaging agent 123 I-ioflupane (DaTSCAN) in patients with a clinically uncertain diagnosis of parkinsonian syndromes (abstract). *Eur J Neurology* 2002; 9(supplement 2):-27.