



University
of Glasgow

Almuzian, Mohammed Ahmed Younis (2014) *The immediate impact of bonded rapid maxillary expansion on the naso-pharyngeal airway patency: a prospective CBCT study*. D.Clin.Dent.Orthodontics thesis.

<http://theses.gla.ac.uk/6252/>

Copyright and moral rights for this work are retained by the author

A copy can be downloaded for personal non-commercial research or study, without prior permission or charge

This work cannot be reproduced or quoted extensively from without first obtaining permission in writing from the author

The content must not be changed in any way or sold commercially in any format or medium without the formal permission of the author

When referring to this work, full bibliographic details including the author, title, awarding institution and date of the thesis must be given

Enlighten:Theses
<http://theses.gla.ac.uk/>
theses@gla.ac.uk

**The Immediate Impact of
Bonded Rapid Maxillary Expansion
on The Naso-pharyngeal Airway Patency
A prospective CBCT study**

Mohammed Ahmed Younis Almuzian

*BDS (Hons.), MSc.(Orthodontics), MFDS RCS (Edinburgh), RCSP
(Glasgow), MSc. Healthcare Administration (Atlanta, US), MFD RCS
(Ireland), MJDF RCS (England), MOrth RCS(Edinburgh), MRCDS Ortho
(Australia), IMOrth (RCS England/RCPS Glasgow)*

This thesis was submitted in part fulfilment
of the requirement for the degree
Doctorate of Clinical Dentistry in Orthodontics (D.Clin.Dent.Orthodontics)
The Orthodontic Department
Dental School
College of Medical, Veterinary and Life Sciences
University of Glasgow, United Kingdom
September, 2014

ABSTRACT

Introduction

Recent studies have utilised cone beam computed tomography (CBCT) for the assessment of the volume of the nasopharyngeal airway space (Guijarro-Martínez and Swennen, 2013, Lenza et al., 2010, Woodside and Linder-Aronson, 1979, Chang et al., 2013). Some of these investigations are based on the analysis of slice data obtained from three dimensional (3D) radiographic images. The usage of a CBCT scan to measure the nasopharyngeal airway volume has drawbacks which include the effect of respiration and tongue position (Abbott et al., 2004), the impact of head posture, lordosis (cranio-cervical inclination) and mandibular morphology on the accuracy of measuring air oro-pharyngeal airways. In addition, published figures to date has not considered the detailed anatomical boundaries of the nasal cavity space, paranasal airway space and other pharyngeal sections collectively (Chang et al., 2013).

Aims and objectives

The aim of the study was to assess the validity of the free access software package like ITK Snap in measuring the airways spaces, investigate, using CBCT, the three-dimensional effect of rapid maxillary expansion on the maxillary sinus, the lower part of the nasal cavity, the upper nasopharynx and the upper oropharynx (upper and lower retropalatal spaces), and to correlate the changes in these anatomical spaces with the measured RME appliance split, the dentoalveolar expansion and the gender of the subjects.

Materials and methods

This study was carried out on seventeen patients (8 boys, 9 girls; mean age 12.6 ± 1.8 years) who required maxillary expansion for the management of narrow upper dental arch. Sample size was calculated using the Researcher's Toolkit calculator and this indicated that a sample size of 14 patients would produce an Alpha error level or confidence level at 95% and a Beta error level at 20%. Therefore, it was decided to recruit 17 subjects to overcome potential exclusion due to irreproducibility in the head orientation and lordosis. Pretreatment (T1) and immediate post-RME (T2) CBCT images were taken for all the patients.

In all CBCT images, head orientation and lordosis were measured using OnDemand 3D software packages. Cases were excluded from the study if the difference in the head orientation and lordosis between the CBCT of T1 and CBCT of T2 was more than 5 degrees. The two scans, T1, T2, were orientated according to a specific protocol and superimposed on the cranial base to standardise the volumetric segmentation and measurements.

The impact of RME was assessed by measuring, using ITK snap and OnDemand 3D software packages, the changes in the distance between the intermolar dentoalveolar width at level of molar alveolar crest (IMD), the magnitude of appliance expansion (AE), the volume of respiratory region or the lower part of the nasal cavity (LNC), the volume of the right and left maxillary sinus (RMS and LMS), the volume of the upper nasopharynx (UNP), the subdivisions of the upper oropharynx including the upper and lower retropalatal space (URP and LRP) at T1 and T2. Segmentation of the oro-naso-pharyngeal spaces into multiple segments allows a detailed localisation of the changes and aids in exclusion of any potential masking change of one airway space on adjacent or remote

airway space as each segment is associated anatomically and physiologically to different function and/or disorder. The normality of the data was tested using Kolmogorov–Smirnov test. The reproducibility of measurements was analysed using Paired t-test and interclass correlation coefficient. The volumetric and linear changes was assessed using Student t-test ($P < 0.05$) and Pearson correlation coefficients was used to test the correlation of these changes.

Results

Bonded RME has an effective dentoalveolar expansion effect in growing patients ($P = 0.001$) and produced a significant increase in UNP ($P = 0.045$). There was a statistically significant reduction on the URP space ($P = 0.042$), especially in males. There was strong correlation between the increase of the volume of the right and left maxillary sinuses ($PCC = 0.86$) and between appliance expansion and dentolavelar expansion ($PCC = 0.75$).

Conclusions

ITK-SNAP software is a reliable package and a single threshold value (-450 grey) is an accurate value. Additionally, this software can be used to measure the size of bony defect in patient with cleft palate before secondary alveolar bone grafting.

Bonded RME was an effective dentoalveolar expander in growing patients and the immediate expansion of LNC and UNP might be associated with a reduction in nasal resistance, improvement in the nasal breathing and it can be considered as an option for treatment of Paediatric Obstructive Sleep Apnea Syndrome. Findings of this study showed that there is a sexual dysmorphism secondary to RME but did not reach the statistical significance. Generally, the effect of the RME on the upper

naso-oro-pharyngeal airway spaces followed a mushroom like pattern with the upper parts expanded, the middle part was significantly narrowed while the lower part was mildly, but insignificantly statistically, reduced. However, it is essential to consider that regardless of the benefit of the increase nasal patency of this orthopedic procedure, it should not be done merely for the above purposes solely but only when it is linked to a right indication for RME.

A future study could include a colour mapping for detailed assessment of changes in different parts of the oro-naso-pharyngeal space, as the shape changes of the airway space are as important as volumetric changes. Finally, a further randomised clinical trial or comparative study with a larger sample size and long term follow up would be beneficial in estimating the real impact of the RME on the airway and confirm the findings of this study.

TABLE OF CONTENTS

Contents

ABSTRACT	1
TABLE OF CONTENTS.....	5
LIST OF TABLES.....	10
LIST OF FIGURES.....	12
ACKNOWLEDGMENTS	15
DECLARATION	16
DEFINITIONS AND ABBREVIATIONS.....	17
CHAPTER ONE	19
1. LITERATURE REVIEW	20
1.1. The History of Rapid Maxillary Expansion	20
1.2. Growth and Development of the Nasomaxillary Complex	22
1.3. Anatomy of the Facial Skeleton and Nasal Cavity.....	23
1.3.1. The Maxilla and Palatine Bone.....	24
1.3.2. Circum-maxillary and Facial Sutures	25
1.3.3. Upper Airway Spaces	26
1.4. Nasal Obstruction and the Relation to Anatomical Structure.....	33
1.5. The Aetiology of Maxillary Constriction	34
1.6. Designs of Rapid Maxillary Expanders.....	35
1.6.1. Banded Appliances	35
1.6.1.1. The Haas-Type Appliance.....	35
1.6.1.2. The Hyrax/Biedermann-Type Appliance	36
1.6.1.3. The Derichsweiler-Type Appliance.....	36
1.6.1.4. The Isaacson-Type Appliance.....	37
1.6.2. Bonded or Cemented Appliances.....	37
1.6.2.1. Metallic Cap Splints	37

1.6.2.2.	Acrylic Cap Splints.....	38
1.6.3.	Bone-Borne Expanders	38
1.7.	The Biomechanics of Rapid Maxillary Expansion.....	39
1.8.	The Success of RME	42
1.9.	Clinical Characteristics	43
1.9.1.	Indications and Clinical Considerations.....	43
1.9.2.	Amount of Expansion.....	46
1.9.3.	Activation Regimes	47
1.9.4.	Force Generated During RME Treatment.....	48
1.9.5.	Relapse and Retention.....	48
1.9.6.	Side Effects of RME	49
1.10.	Evaluation of the Effect of Rapid Maxillary Expansion	51
1.10.1.	Introduction.....	51
1.10.2.	Skeletal Effects	52
1.10.3.	Dentoalveolar Effects	56
1.10.4.	Effects on the Median Palatal Suture and Craniofacial Suture ..	58
1.10.5.	Effects on the Nasal Cavity	59
1.10.5.1.	Changes in Nasal Cavity Dimensions.....	59
1.10.5.2.	Changes in Nasal Cavity Function	61
1.10.5.3.	Nasal Airway Resistance	65
1.11.	Three-dimensional modalities and their application in the assessment of the effects of RME	65
1.11.1.	Introduction.....	65
1.11.2.	The Finite Element Model.....	66
1.11.3.	Computed Tomography and Cone-Beam Computed Tomography Scanning	68
1.11.4.	Magnetic Resonance Imaging Scanning (MRI)	70
1.11.5.	RME effects as measured using the 3D modalities.....	71

1.11.5.1.	Skeletal Effects	71
1.11.5.2.	Dentoalveolar Effects	72
1.11.5.3.	Periodontal Effects	72
1.11.5.4.	Nasal Changes	73
1.11.5.5.	Effects of RME on the Soft Tissue	74
1.12.	Maxillary Constriction and Obstructive Sleep Apnoea (Cordasco et al.)	75
CHAPTER 2	79
2.	Aim and Null Hypothesis.....	80
2.1.	Statement of the Study Aim.....	80
2.2.	The Aim of the Study	82
2.3.	The Null Hypothesis	82
CHAPTER 3	83
3.	Materials and Methods.....	84
3.1.	Study Design	84
3.2.	Subjects	84
3.3.	Inclusion Criteria.....	84
3.4.	Exclusion Criteria	85
3.5.	Sample Size Calculation	85
3.6.	Clinical Procedures	86
3.6.1.	Treating clinician.....	86
3.6.2.	Upper and Lower Dental Impressions.....	87
3.6.3.	The RME Appliance.....	87
3.6.4.	Cementation of the RME	87
3.6.5.	Activation Regime.....	87
3.7.	CBCT scan	89
3.7.1.	The CBCT Machine.....	89
3.7.2.	Field of View (FOV)	89

3.7.3.	CBCT Settings.....	90
3.7.4.	CBCT Calibration	90
3.7.5.	Pilot Scan	91
3.8.	Virtual 3D Model Construction	92
3.8.1.	OnDemand3D analysis.....	93
3.8.2.	The ITK-SNAP Software.....	107
3.9.	Statistical Analysis.....	117
3.10.	Error of the Study	117
CHAPTER 4		119
4.	Results	120
4.1.	Sample Characteristics.....	120
4.2.	Descriptive Analysis	122
4.3.	Errors of the Method	131
4.4.	Transverse Dentoalveolar Linear Changes	136
4.5.	Volumetric Changes in the Nasopharyngeal Space as a Result of RME	136
4.6.	The correlation between gender, change in the volume of the nasopharyngeal space, degree of appliance expansion and dentoalveolar expansion.....	137
CHAPTER 5		143
5.	Discussion	144
5.1.	Introduction.....	144
5.1.1.	Methodology	145
5.1.1.1.	Consistency, Reproducibility and Methodological Errors..	145
5.1.1.2.	Assessment of magnitude of the transverse expansion....	147
5.1.1.3.	Assessment of RME's effect on Nasopharyngeal Volumes	147
Further Thoughts on This Study		152
Clinical Implications		154

CHAPTER 6	155
Conclusion	156
CHAPTER 7	157
7. Appendices	158
7.1. Copy of the Ethical Approval Letter (NHS Greater Glasgow and Clyde) 158	
7.2. Copy of the Ethical Approval Letter (NHS Fife).....	163
7.3. Copy of the Consent Form	164
7.3.1. Patient Consent Form (Adult)	164
7.3.2. Parental Assent Form	165
7.3.3. Child Assent/Information Form	166
7.4. Presentation	167
References	168

LIST OF TABLES

Table 1: Points and landmarks	94
Table 2: Lines and planes	97
Table 3: Cephalometric angles	98
Table 4: Volumes of interest and their boundaries	110
Table 5: Gender distribution	120
Table 6: Descriptive analysis for the IMD and AE measurements at W1	126
T1: measurements on the 1st occasion, T2: measurements on the 2nd occasion, IMD: intermolar dentoalveolar expansion, AE=appliance expansion separation, SD: Standard deviation.	
Table 7: Descriptive analysis for the IMD and AE measurements at W2	126
Table 8: Reproducibility for orientation measurements for T1 at W1 and W2	132
Table 9: Reproducibility for orientation measurements for T2 at W1 and W2	133
Table 10: Reproducibility for volumetric and linear measurements for T1 at W1 and W2	134
Table 11: Reproducibility for volumetric and linear measurements for T2 at W1 and W2	135
Table 12: Dentoalveolar linear measurements of the 3D volumetric images before and after RME.....	138
T1: measurements on the 1st occasion, T2: measurements on the 2nd occasion, IMD: intermolar dentoalveolar expansion, AE=appliance expansion separation, SD: Standard deviation.	
Table 13: Nasopharyngeal volumetric measurements of the 3D volumetric images before and after RME for both genders	138
Table 14: Nasopharyngeal volumetric measurements of the 3D volumetric images before and after RME for males	140

Table 15: Nasopharyngeal volumetric measurements of the 3D
volumetric images before and after RME for females 141

Table 16: Pearson correlation coefficients for volumetric changes in
relation to the nasopharyngeal space, gender, AE and IMD as a result of
RME 142

LIST OF FIGURES

Figure 1: Frontal and lateral view of skull (Netter, 2010)	25
Figure 2: Nose and nasal cavity (SEER Training Modules. Nose & Nasal Cavities: National Institutes of Health, National Cancer Institute)	31
Figure 3: Schematic diagram of the airway (Chang et al., 2013).....	32
Figure 4: The Haas appliance (Timms, 1981)	40
Figure 5: The Hyrax appliance (Timms, 1981).....	40
Figure 6: The Derichsweiler appliance (Timms, 1981)	40
Figure 7: The Isaacson appliance (Timms, 1981)	40
Figure 8: Metallic cap splint	41
Figure 9: Acrylic cap splint.....	41
Figure 10: Bone-borne expander	41
Figure 11: AR nose tip adaptation (from Eccovision® Quick Setup Guide, Hood Labs, Pembroke, MA, USA)	67
Figure 12: Technique for holding AR wave tubes (from Eccovision® Quick Setup Guide, Hood Labs, Pembroke, MA, USA).....	67
Figure 13: Alginate used during the study.....	88
Figure 14: The cast cap splint RME constructed of a silver-copper alloy with full tooth coverage from the first molar to the canines.....	88
Figure 15: Glass ionomer cement used during the study	88
Figure 16: The iCAT CBCT scanner used during the study.....	91
Figure 17: P angle.....	99
Figure 18: R angle	100
Figure 19: Y angle.....	101
Figure 20: L angle	102
Figure 21: The standardised orientation technique	104
Figure 22: Superimposition on the cranial base	105

Figure 23: Diagram showing a coronal slice post RME: the red line represents AE; the blue line represents IMD width.....	106
Figure 24: Volumes of interest and their boundaries	114
Figure 25: Segmentation procedure using ITK-SNAP	115
Figure 26: Three-dimensional visualisation of nasal, paranasal and oropharyngeal cavities and spaces.....	116
Figure 27: T1-T2 head orientation and lordosis.....	121
Figure 28: Descriptive analysis for the orientation measurements before and after RME for both genders at W1	123
Figure 29: Descriptive analysis for the orientation measurements before and after RME for males at W1.....	123
Figure 30: Descriptive analysis for the orientation measurements before and after RME for females at W1.....	124
Figure 31: Descriptive analysis for the orientation measurements before and after RME for both genders at W2	124
Figure 32: Descriptive analysis for the orientation measurements before and after RME for male at W2	125
Figure 33: Descriptive analysis for the orientation measurements before and after RME for female at W2	125
Figure 34: Descriptive analysis for the volumetric measurements, both genders, at W1.....	128
Figure 35: Descriptive analysis for the volumetric measurements, male, at W1	128
Figure 36: Descriptive analysis for the volumetric measurements, female, at W1	129
Figure 37: Descriptive analysis for the volumetric measurements, both genders, at W2 (second week).....	129
Figure 38: Descriptive analysis for the volumetric measurements, male, at W2	130

Figure 39: Descriptive analysis for the volumetric measurements,
female, at W2 130

Figure 40: Colour mapping of object No. 7 showing the pre-treatment
(Solid) and the post-treatment (mesh) changes..... 153

ACKNOWLEDGMENTS

First, I want to thank **God** for giving me the patience and the inspiration
throughout my life.

I would to thank my supervisors,

Professor J.P. McDonald and

Professor A. Ayoub.

Last but not least; I would like to thank my wife ***Dr. Lubna AlMuzian***

for her personal support and great patience at all times, my *daughters*

(Mariam, Sara and Laila), my *mother* and *brothers* for their support and

encouragement.

DECLARATION

“I declare that, except where explicit reference is made to the contribution of others, that this dissertation is the result of my own work and has not been submitted for any other degree at the University of Glasgow or any other institution.

Signature:

Mohammed Ahmed Younis Al Muzian

DEFINITIONS AND ABBREVIATIONS

2D	Two Dimensional
3D	Three Dimensional
ANS	Anterior Nasal Spine
AR	Acoustic Rhinometry
Ba	Basion
BMI	Body Mass Index
CBCT	Cone Beam Computed Tomography
cm	Centimeter
CO₂	Carbon Dioxide
CPAP	Continuous Positive Airway Pressure
CT	Computed Tomography
DICOM	Digital Imaging and Communications in Medicine
ENT	Ear, Nose And Throat
FEM	Finite Element Model
FOV	Field of View
GIC	Glass Ionomer Cement
H - angle	Holdway Angle
ITK	Insight Toolkit
KVP	Kilo Voltage
L	Litre
mA	Milli Amperage
MAD	Mandibular Advancement Device
Me	Menton Point

min	Minute
mm	Millimeter
MRI	Magnetic Resonance Imaging
N	Nasion
NHP	Natural Head Position
NHS	National Health Service (UK)
OSA	Obstructive Sleep Apnoea
OSAS	Obstructive Sleep Apnoea/Hypopnea Syndrome
PNS	Posterior Nasal Spine
QA	Quality Assurance
RME	Rapid Maxillary Expansion
SD	Standard Deviation
SIGN	Scottish Intercollegiate Guidelines Network
SME	Slow Maxillary Expansion
Sn	Subnasale Point
T1	Before treatment
T2	After treatment
UPPP	Uvulo-Palato-Pharyngeal-Plasty
μSv	Micro-Sievert

CHAPTER ONE

LITERATURE REVIEW

1. LITERATURE REVIEW

1.1. The History of Rapid Maxillary Expansion

Rapid maxillary expansion (RME) is an orthodontic technique which was popularised by Angell 150 years ago. It is used for the management of maxillary constriction (Angell, 1860b, Proffit and Fields, 2000, Larsson, 1986, Linder-Aronson, 1970). In general, maxillary constriction affects 8–16% of the population in the UK, with no reported gender difference (Foster et al., 1969). However, 16–50% of these discrepancies are self-correcting (Petrén and Bondemark, 2008), and 80% are associated with mandibular displacement (Thilander and Myrberg, 1973).

The rationale of RME was first described by Angell (Angell, 1860b); it relies on the use of heavy intermittent forces that cause midpalatal suture split. Angell's first RME appliance consisted of a jackscrew appliance attached to the maxillary premolars and activated once per day over a 2-week period. At the end of this time, Angell showed that the mid-palatal suture had separated laterally, and that it subsequently filled with bone. However, the efficacy of the procedure was originally opposed and challenged by members of the dental community. Antagonists of RME perceived that the procedure was anatomically impossible because of the surrounding buttressing and circummaxillary sutures. Hence, interest in RME began to decline (McQuiellen, 1860, Cryer, 1913). Recently, the effect of RME has been compared to slow maxillary expansion (SME).

The latest systematic review has suggested that SME is a superior technique in expanding molar region of maxillary arch when compared to RME (Zhou et al., 2013); however, it is worth mentioning that this study included reference to non-randomised controlled trial (RCT) studies like the McNamara study, which in turn relied on historical data from the Michigan Growth Studies (McNamara Jr et al., 2003).

In Europe, RME attracted the interest of rhinologists due to its observed positive effect on the nasal airflow and positive impact on nasal obstruction (Wright, 1912a, Wright, 1912b). It has been claimed that RME is effective in straightening a deviated nasal septum and relieves nasal/pharyngeal membrane hypertrophy (Brown, 1903, Haas, 1965, Timms, 1986). Researchers were able to show an improvement in nasal airflow and a reduction in the nasal airway resistance as a direct result of an increase in the nasal dimension post RME (Korkhaus, 1953, Derichsweiler, 1959, Wertz, 1968, Hershey et al., 1976).

Studies on Rhesus monkeys' dry skulls (Jafari et al., 2003a) and Finite Element Models using dry human skulls (Akkaya et al., 1999, Boryor et al., 2008, Gautam et al., 2007, Provatidis et al., 2008b) showed that RME has different skeletal and dental effects. Additionally, these studies showed that RME can affect sutures remote to the palate, as in the circum-zygomatic, circum-maxillary, zygomatico-maxillary and zygomatico-temporal sutural systems (Cleall et al., 1965). However, these studies did not consider the impact of RME on the soft tissue and airway spaces, and the maxillary anatomy of Rhesus monkeys differs from that of humans. In addition, Finite Element Model studies do not

consider the potential longitudinal effects of RME (Chaconas and Caputo, 1982, Palomo et al., 2006, Podesser et al., 2007, Rungcharassaeng et al., 2007).

The introduction of cone-beam computed tomography (CBCT) has permitted the examination of the craniofacial complex in growing patients and provides detailed anatomical boundaries of the nasopharyngeal airway spaces (Kau et al., 2005, Lagravère et al., 2006a, Lagravère et al., 2006b).

1.2. Growth and Development of the Nasomaxillary Complex

Maxillary formation occurs through intramembranous ossification during the 5th weeks of intra-uterine life. The most important research describing the growth mechanisms of the maxilla was comprehensively documented by Bjork's implant studies (Björk, 1955, Björk and Skieller, 1977). These studies demonstrated that the increase in maxillary length is due to sutural apposition at the palatine bone and apposition on the maxillary tuberosity. In a vertical direction, the downward and forward displacement of the maxilla is due to bone apposition on the floor of the orbits, resorptive remodelling on the floor of the nasal cavity, apposition on the hard palate in the oral cavity and secondary displacement as a result of cranial base growth (Björk, 1955).

It has been shown that resorption in the anterior portion of the nasal cavity creates varying degrees of vertical rotation of the maxilla (Björk and Skieller, 1977). The median palatal suture has an important role in

the transverse growth of the maxilla (Keith and Campion, 1922) which is usually completed by the age of 3 years (Latham, 1971); however, this has been challenged by the findings of various implant-based studies (Björk, 1955, Björk and Skieller, 1977, Korn and Baumrind, 1990, Krebs, 1959, Krebs, 1964, Skieller, 1964, Snodell et al., 1993). Such studies have demonstrated that the median palatine suture growth continues beyond puberty, and this is similar to the distance and velocity curves that represent somatic growth. It is believed that growth at the mid-palatal suture continues until approximately the age of 13–15 years and is then followed by a continuation of bone apposition until the age of 18 years (Melsen, 1975). After the pubertal growth spurt, the changes in the transverse dimension of the maxilla are minimal, but have still been shown to be statistically significant (Björk and Skieller, 1977, Korn and Baumrind, 1990).

The average velocity of growth in the mid-palatine suture is estimated to be 0.18–0.43 mm per year. From the age of 4 years to adulthood, the mean increase in transverse growth of the median suture is estimated to be 6.5 mm, with 80% of growth occurring after 7 years of age (Keith and Campion, 1922).

1.3. Anatomy of the Facial Skeleton and Nasal Cavity

The detailed descriptive anatomy of the facial skeleton has been well documented by many researchers (Berkovitz and Moxham, 2002, Brand et al., 2003, Fehrenbach and Thomas, 1997, Netter, 2010) . Understanding the anatomy of the facial skeleton, as well as that of the

nasal cavity, is crucial to the understanding of the concept of RME (Figure 1).

1.3.1. The Maxilla and Palatine Bone

The second largest facial bone after the mandible is the maxilla. The pair of maxillary bones (halves) joins together at the intermaxillary suture. Medially, the maxilla articulates with the nasal process of the frontal bone, nasal bone and nasal cartilage. Laterally, it joins the zygomatic bone. Superiorly, it also articulates with the ethmoid, lacrimal, sphenoid, inferior nasal conchae, vomer and palatine bones. The body of the maxilla is pyramidal in shape and contains the maxillary sinus; its medial surface forms the lateral wall of the nasal cavity. There is a connection between these cavities at the upper posterior facet of the maxillary medial surface called the maxillary hiatus, which is superior to the inferior meatus and posterior to the nasolacrimal groove. Superior-medially, the nasal cavity is connected to the ethmoid and lacrimal bones (Berkovitz and Moxham, 2002, Brand et al., 2003, Fehrenbach and Thomas, 1997, Netter, 2010).

The hard palate is made up of the two palatine processes of the maxillary bone (the anterior two-thirds of the palate) and the palatine process of the palatine bone (the posterior one-third of the palate). Each process articulates with the contralateral side at the midline via the mid-palatine suture.

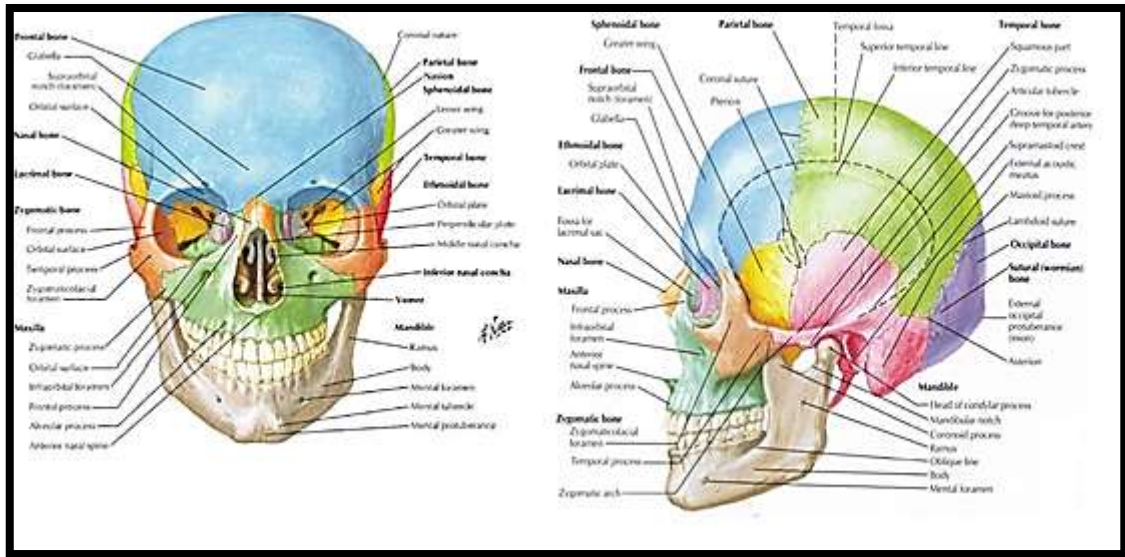


Figure 1: Frontal and lateral view of skull (Netter, 2010)

The maxilla and the palatine bone articulate via the transverse palatine suture. The middle part of the nasal surface of the anterior two-thirds of the hard palate forms the nasal crest, which articulates with the vomer. The most posterior part of the palatine bone at the midline is called the posterior nasal spine. (Berkovitz and Moxham, 2002, Brand et al., 2003, Fehrenbach and Thomas, 1997, Netter, 2010).

1.3.2. Circum-maxillary and Facial Sutures

Pritchard defined the suture as ‘the entire complex of cellular and fibrous tissues intervening between, and surrounding, the definitive bone edges’ (Pritchard et al., 1956b). Bones of the face are joined by sutures which include the fronto-maxillary suture, the fronto-zygomatic suture, the inter-maxillary suture, the transverse palatine suture and the

median palatine suture (Pritchard et al., 1956a). There are three stages of development of the mid-palatal suture; the infantile period, where the suture is short and wide; the juvenile period, in which the suture is tortuous; and the last adult stage, in which the bones are interdigitated (Melsen, 1975).

Sutural closure is called synostosis and occurs in the region of 15 years; this is generally considered to be the upper limit for the application of nonsurgical RME (Persson and Thilander, 1977). The synostosis of the mid-palatal suture increases the rigidity of the maxillary bone and is the main resistance force to palatal expansion (Melsen, 1975, Wertz, 1970).

1.3.3. Upper Airway Spaces

The upper airway space consists of the nasal and pharyngeal complexes.

1.3.3.1. The Nasal Complex

The nose and nasal cavity are a complex arrangement of hard and soft tissues. They are subdivided into the external nose with its anterior opening (the nares) and the nasal cavity, which opens to the nasopharynx posteriorly through the posterior nasal choanae. The nasal bone is attached to the cartilaginous nose superiorly, while the cartilaginous nose is attached to the anterior nasal spine inferiorly (Berkovitz and Moxham, 2002, Brand et al., 2003, Fehrenbach and Thomas, 1997, Netter, 2010).

1.3.3.1.1. The External Nose

The pyramid-shaped part of the nasal complex is the external nose, which is located in the median aspect of the midface. The main body, or the skeleton, of the external nose is mainly cartilaginous and is bounded latero-inferiorly by the maxilla and superiorly by the nasal bones. The cartilaginous portion consists of paired lateral nasal cartilage, specifically, major cartilages and several minor alar nasal cartilages. It is contiguous with the forehead and the tip projects anteriorly. The base of the external nose consists of two nostrils (nares) which are separated by the nasal septum and columella (Berkovitz and Moxham, 2002, Brand et al., 2003, Fehrenbach and Thomas, 1997, Netter, 2010).

1.3.3.1.2. The Nasal Cavity

The nasal cavity is the irregular space between the roof of the mouth and the cranial base (Figure 2). Through the use of magnetic resonance imaging (MRI), the volume of the human nasal cavity has been estimated to be 16 cm³ (McRobbie et al., 2003); however, this measurement increases to 28 cm³ in human cadavers due to post-mortem shrinkage of the nasal mucosa of the cadaveric specimen (Harkema, 1991, Lowe et al., 1986). As a pyramidal shape, it is wider inferiorly than superiorly and deepest in its central region vertically. The frontal, ethmoidal, maxillary and sphenoidal paranasal sinuses communicate with the nasal cavity, which in turn opens into the nasopharynx through the posterior nasal choanae. It is divided into

bilateral halves by the nasal septum, which in turn forms the medial wall of the nasal cavity (Figure 2). The nasal septum comprises the septal cartilage anteriorly, while posteriorly it is comprised of the perpendicular plate of the ethmoid bone postero-superiorly and vomer postero-inferiorly. The nasal crest, which is part of the maxillary and palatine bones, forms the base of the nasal cavity (Berkovitz and Moxham, 2002, Brand et al., 2003, Fehrenbach and Thomas, 1997, Netter, 2010).

The frontal, lacrimal, maxillary, nasal, palatine, sphenoid and vomer bones, along with the bones of the inferior nasal conchae comprise the remaining walls of the nasal fossa. The roof of the nasal fossa is formed by three parts; centrally, the cribriform plate of the ethmoid bone; anteriorly, the nasal bone and nasal spine of frontal bone; and posteriorly, the body of the sphenoid. The olfactory nerves, anterior ethmoidal nerves and vessels are transmitted through the cribriform plates which separate the nasal cavity from the anterior cranial base (Berkovitz and Moxham, 2002, Brand et al., 2003, Fehrenbach and Thomas, 1997, Netter, 2010).

The floor of the nasal cavity is formed by the palatine process of the maxilla anteriorly and the palatine bone posteriorly. On the anterior aspect of the floor of the nasal cavity and approximate to the nasal septum, there is the nasal opening of the incisive canal, which passes orally into the incisive fossa and transmits the long spheno-palatine neurovascular bundle. The lateral wall of the nasal cavity is bounded antero-inferiorly by the maxilla, posteriorly by the perpendicular plate of the palatine bone and superiorly by the labyrinth of the ethmoid

bone. Three shelves project from the lateral wall. The superior and the middle conchae are both part of the ethmoid bone; the inferior concha is part of the facial bone. The conchae curve inferio-medially, each groove called the meatus, which opens into the nasal cavity. Superior and posterior to the superior concha there is the sphenoidal recess. The region between the superior and middle conchae is the superior meatus, whilst between the middle and inferior conchae is the middle meatus (Berkovitz and Moxham, 2002, Brand et al., 2003, Fehrenbach and Thomas, 1997, Netter, 2010).

Anatomically, the nasal cavity extends from the vestibule to the choanae, or posterior nasal apertures. This is considered to be a space rather than a structure. Each choana is bounded medially by the vomer, inferiorly by the horizontal plate of the palatine bone, laterally by the medial pterygoid plate and superiorly by the body of the sphenoid bone (Janvier, 2004, O'Rahilly et al., 1967).

The nasal cavity is subdivided into the nasal vestibule and the olfactory and respiratory regions. The nasal vestibule extends from the external nares and to inside the nose proper, and is a slight dilatation inside the nostril. It is lined by skin with sweat, sebaceous glands and vibrissae. The olfactory region is located at the apex of the nasal cavity and bounded by the superior concha and the superior third of the nasal septum. It is lined by olfactory cells with olfactory receptors. The respiratory region is the largest, and is lined by a ciliated pseudostratified epithelium. Within the epithelium are interspersed mucous secreting goblet cells (O'Rahilly et al., 1967). A study by Cordasco defined the respiratory region as the space extending

anteroposteriorly from the anterior nasal spine (ANS) to the posterior nasal spine (PNS) and superiorly to the lower limit of the middle turbinate (Cordasco et al., 2012).

1.3.3.2. The Pharyngeal Complex

From an anatomical point of view, the pharyngeal airway is subdivided into three main segments, namely the nasopharynx, oropharynx and the laryngopharynx or hypopharynx (Romanes, 1986). Some studies have subdivided the upper airway into the nasopharynx, retropalatal airway (velopharynx), retroglossal airways and hypopharynx.

The nasopharynx is the uppermost portion of the airway, and is mainly the nose. It begins with the nares extending back to the hard palate at the superior portion of the soft palate (Figure 3). The boundaries of the velopharyngeal space are defined superiorly by the horizontal line passing through the posterior nasal spine to the basion and inferiorly by a plane passing through the postero-inferior point of the soft palate. From the inferior limits of the velopharynx, the retroglossal airways extend to the limit of the horizontal line passing through the most superior point of the epiglottis; Vallecula (Chang et al., 2013, Lenza et al., 2010, Subtelny, 1954, Zhao et al., 2010).

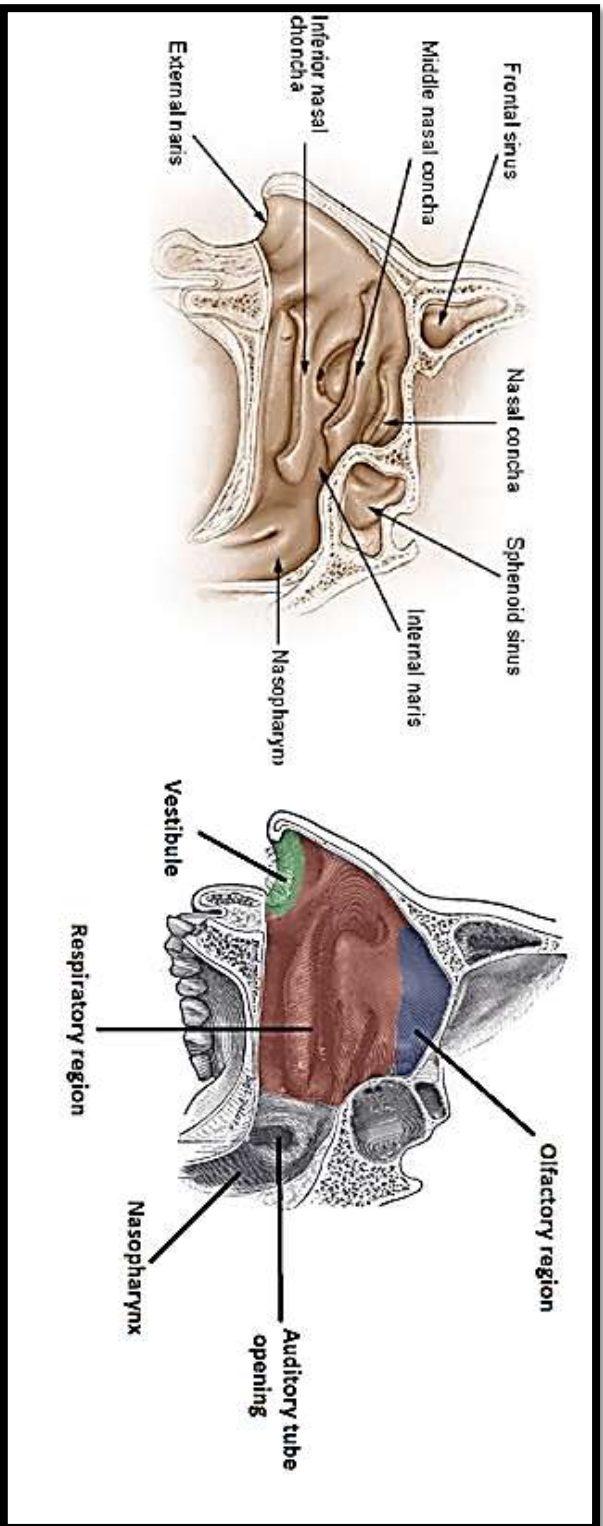


Figure 2: Nose and nasal cavity (SEER Training Modules. Nose & Nasal Cavities: National Institutes of Health, National Cancer Institute)

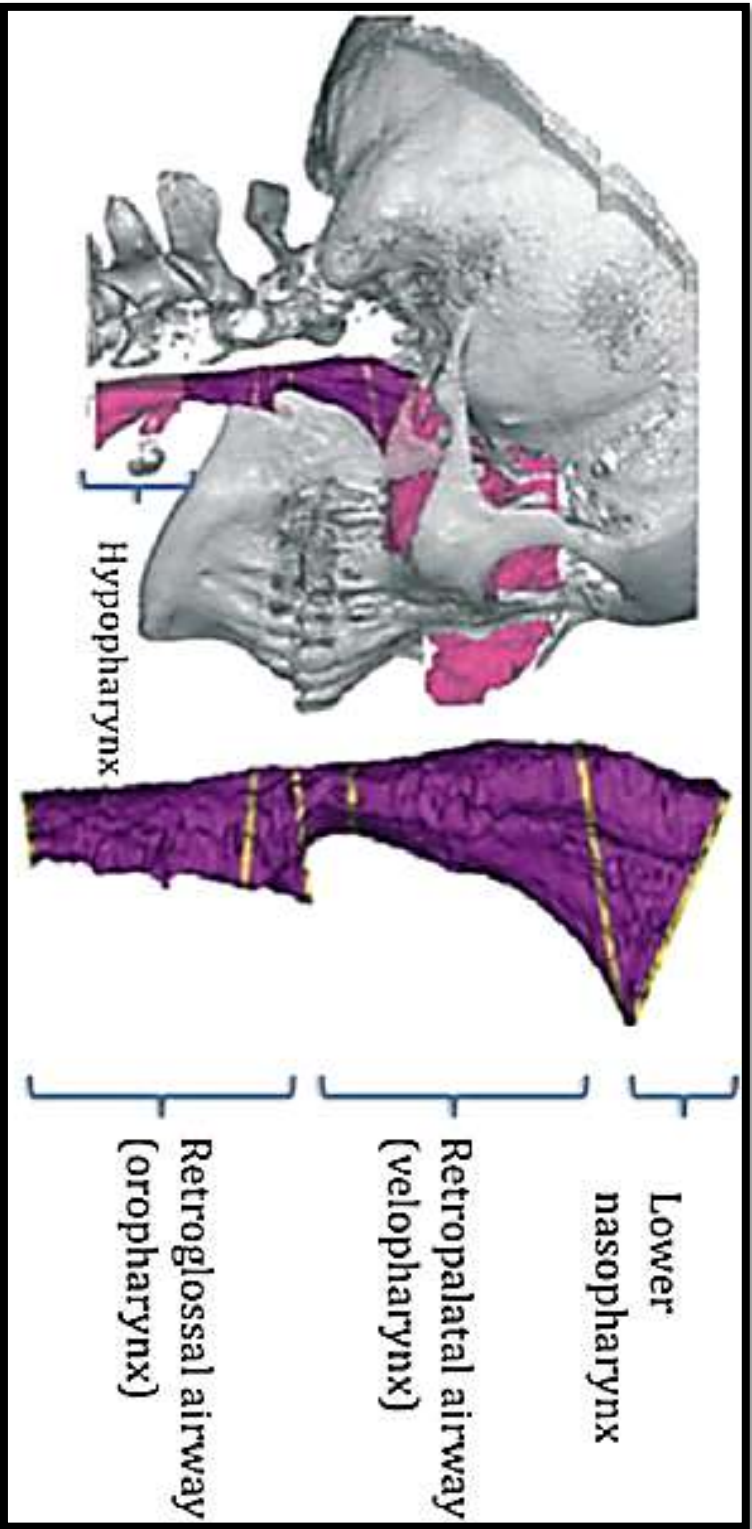


Figure 3: Schematic diagram of the airway (Chang et al., 2013)

1.4. Nasal Obstruction and the Relation to Anatomical Structure

The function of nasal respiration is to supply moistened, filtered, warmed air to the lower respiratory tract. During the early stages of life, humans are obligate nasal breathers (Van De Water and Staecker, 2006, Zavras et al., 1994, Bhakthavalsala and Newson, 2008). Habitual mouth breathing results from nasal obstruction (Gray, 1975, McNamara JR, 1981b, MCNAMARA JR, 1981a, Timms, 1974, Watson Jr et al., 1968, Linder-Aronson, 1970). Such obstruction may result from a variation in the normal anatomy, like a narrow nasal vault or a congenitally deviated septum. Other causes of fixed obstruction may be congenital, as in choanal stenosis; acquired, as in traumatic septal deviation, compensatory turbinate hypertrophy or post-Rhinoplasty; or pathological, as in nasal polyps, tumours, hypertrophic adenoids or foreign bodies (Wheeler and Corey, 2008). Other major causations of nasal obstruction may be reversible, involving mucosal engorgement (nasal congestion) or mucosal swelling. This can be a physiological response to changes in temperature/humidity, posture/body position, sleep, hormones, the nasal cycle or inflammatory reactions like rhinitis, rhino-sinusitis, sarcoidosis, inflammatory reactions or drug-induced swelling (Kase et al., 1994, Wheeler and Corey, 2008, Zavras et al., 1994). In a standard nasal passage, the left and right sides of the nose have similar mean airflow, resistance, amplitude and volume changes (Gungor et al., 1999).

‘Long-face syndrome’ and ‘adenoid facies’ are terms used to describe specific traits of patients with chronic mouth breathing that is usually

secondary to nasal obstruction. Typical features include a Class II incisor relationship with an increase in lower facial height, lip incompetency, narrow alar base, obligate mouth breathing, high palatal vault with narrow maxillary arch and posterior cross-bite (Linder-Aronson, 1970). In these patients, RME may assist in coordinating the arches and may increase the nasal cavity dimensions. It has been suggested that an involuntary conversion to oro-nasal breathing occurs once ventilation exceeds 40–45 L/min, whilst nasal resistance of 3.5 to 4 cm H₂O/L/min might cause partial mouth breathing (Proffit, 2007). However, other researchers claim that these changes in nasal respiratory function after RME have not been proven (Neeley II et al., 2007, Vig, 1998, White et al., 1989, Hartgerink and Vig, 1989).

1.5. The Aetiology of Maxillary Constriction

Maxillary constriction can be defined as a maxillary width dimension that is narrower than the expected norm for a particular age. Deficiencies in maxillary width can be caused by genetic factors, environmental factors or a combination of both. Many craniofacial syndromes present with maxillary constriction, most notably clefting of the palate. The environmental factors include loss of nasal function or alteration in respiration. Animal studies have shown that blocking the nasal airways of Rhesus monkeys leads to lower tongue position, rotation of the mandible, altered head posture and lateral collapse of the nasomaxillary complex (Harvold et al., 1972). Other environmental causes are severe allergies, described as being atopic, and digit habits,

which persist into the mixed dentition (Bishara and Staley, 1987). However, it is now generally accepted that the cause is multifactorial, involving the nasal airway function, skeletal base and dentoalveolar processes (Chaconas and Caputo, 1982).

1.6. Designs of Rapid Maxillary Expanders

It is generally accepted that Angell (Angell, 1860a, Angell, 1860b) was the first to introduce RME. Subsequently, other RME designs have been proposed (Bishara and Staley, 1987, Timms, 1981). As a general classification, RME can be achieved with either a banded or bonded approach using cemented appliances or bone-borne appliances.

1.6.1. Banded Appliances

Banding the first molars and first premolars is the norm in these appliances. In order to increase rigidity, wire may be soldered to the buccal or palatal aspects of the bands.

1.6.1.1. The Haas-Type Appliance

The Haas-type appliance consists of an acrylic base plate and a midline expansion screw placed near to the mid-palatal suture (Figure 4). It has been suggested that acrylic coverage allows the appliance to be tissue borne as well as dental, allowing for more parallel expansion forces to the alveolar components. However, this feature has the potential for tissue damage and irritation. Another feature of the Haas appliance is

the connecting bars which are soldered to the buccal and palatal surfaces of each pair of bands. The expansion screw can be either a spring-loaded or a non-spring-loaded jackscrew (Haas, 1961, Haas, 1970).

1.6.1.2. The Hyrax/Biedermann-Type Appliance

Biedermann created an alternative design to the Haas appliance which was initially referred to as the Biedermann or “hygienic” appliance, but later came to be known as the ‘Hyrax’ appliance (Biederman, 1968). The Hyrax design is similar to that of the Haas appliance, but the midline screw is a non-spring-loaded jackscrew and there is no acrylic coverage of the palate (Figure 5). It is suggested that this appliance causes less irritation to the palatal mucosa and is easier to keep clean. The frame is soldered to the bands on the abutment teeth (Biederman, 1968, Timms, 1981).

1.6.1.3. The Derichsweiler-Type Appliance

The bands used in the Derichsweiler RME design contain a welded or soldered tag on the palatal aspect to provide attachments for the acrylic connector that connects the premolars and first molars (Figure 6; (Timms, 1981).

1.6.1.4. The Isaacson-Type Appliance

The Isaacson appliance is also called a Minne expander because it contains a special coil spring that can be expanded by turning a nut to compress the coil; this is soldered directly to the bands without the use of acrylic connector. Its main drawback is the continuous expansion forces which occur during the retention phase, after completion of the expansion, unless it is partially deactivated (Figure 7) (Timms, 1981).

1.6.2. Bonded or Cemented Appliances

The advantages of bonded rapid palatal expansion appliances are increased rigidity, larger acrylic surface bonded to the teeth and bonding of the entire posterior arch simultaneously. At the same time, however, these features lead to the unwanted tipping and rotation of teeth, as well as tooth super-eruption (Sarver and Johnston, 1989).

1.6.2.1. Metallic Cap Splints

A metallic cap splint consists of a coverage plate that is cast using silver/copper alloy; the two halves with the expansion screw are then connected by an acrylic connector (Figure 8) (Timms, 1981).

1.6.2.2. Acrylic Cap Splints

Acrylic cap splints are similar to the metallic ones except that the metal is replaced with acrylic which is cemented to the teeth (Figure 9) (Memikoglu and Iseri, 1999, Memikoğlu and Iseri, 1997).

1.6.3. Bone-Borne Expanders

As previously mentioned, many appliances are used to facilitate the RME process. Among these are bone-borne expanders, which represent a new development in the field of RME (Figure 10). These appliances are inserted directly into the cortex of the palatal aspect of the maxillary bones. It has been reported that they can reduce the drawbacks associated with traditional tooth-borne and tooth-tissue-borne appliances, which include tooth tipping and periodontal damage to the anchor teeth (Gerlach and Zahl, 2003, Harzer et al., 2004, Mommaerts, 1999, Neyt et al., 2002). However, in a systematic review Verstraaten et al. (Verstraaten et al., 2010) showed that there is no difference between surgically assisted RME (SARME) using bone-borne expander and that using a tooth borne expander.

1.7. The Biomechanics of Rapid Maxillary Expansion

Since the teeth and the craniofacial bones are in a sense constrained, first by the periodontium and next by the sutures, the biomechanical principles involving tooth movement can be applied to the craniofacial bones (Braun et al., 2000). The magnitude of the forces required for moving or ‘bending’ bone (orthopaedic effect) is 900–4,500 g, whereas that required to move teeth is approximately 10–100 g. This force rapidly dissipates initially, but the decay then slows (Chaconas and Caputo, 1982).

Younger patients also dissipate forces more rapidly than older patients (Zimring and Isaacson, 1965). In a study on dry skulls using Finite Element Modelling, it has been confirmed that the forces that occur in RME can reach 120 Newton (N); however, after the suture ruptures, the force dramatically drops to 25 N (Sander et al., 2006). The resistance to separation comes from other bony articulations with the maxilla, and these areas of resistance can be shown graphically in photo-elastic visualisations.

Figure 4: The Haas appliance (Timms, 1981)

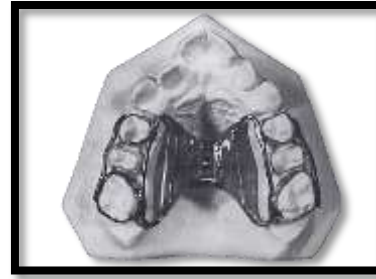

Figure 5: The Hyrax appliance (Timms, 1981)

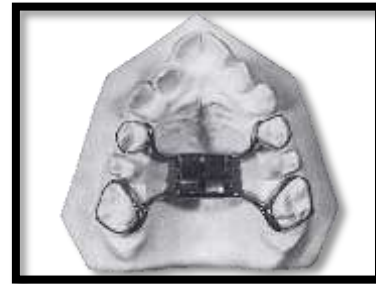

Figure 6: The Derichsweiler appliance (Timms, 1981)

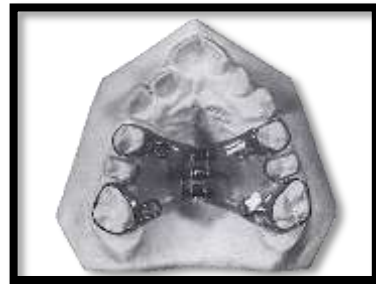

Figure 7: The Isaacson appliance (Timms, 1981)

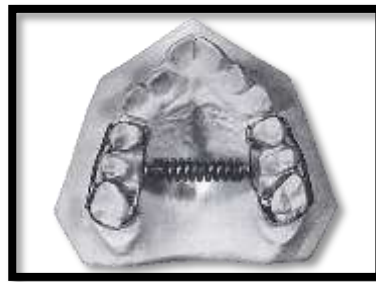

Figure 8: Metallic cap splint

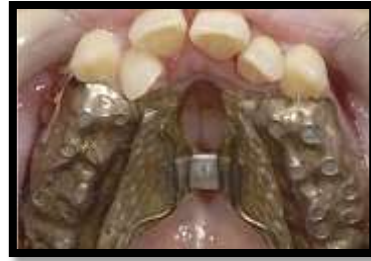

Figure 9: Acrylic cap splint

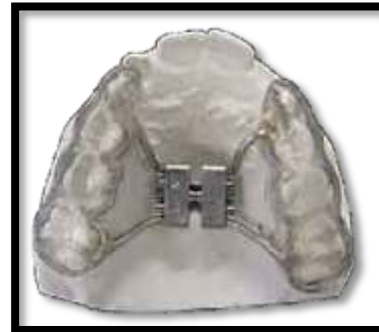
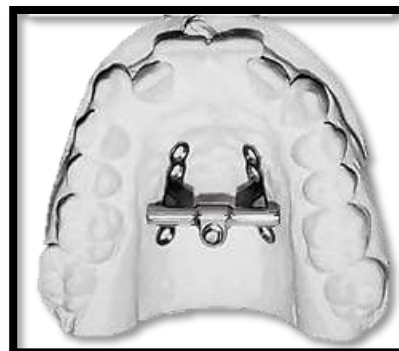
Figure 10: Bone-borne expander



1.8. The Success of RME

The success of RME usage depends on rigidity (resistance to rotation/tipping). To limit the tilting of dentoalveolar elements, the expanding screw should effectively transmit force generated by the screw to the basal maxillary bone (Timms, 1981). This feature helps in preventing relapse during the retention phase (Zimring and Isaacson, 1965). For this reason, the bonded RME appliance, which is more rigid than the banded one, is less prone to relapse (Spolyar, 1984, Sarver and Johnston, 1989).

Tooth utilisation, or the number of teeth included in the appliance, is another important factor. In order to spread the force over the entire alveolar component, it is advisable to incorporate as many teeth as possible (Timms, 1974). A wider distribution of force reduces the load on individual teeth and reduces the potential for damage. For this reason, the use of a cap splint which adapts to all teeth, rather than bands which can only be cemented to a few teeth, is advocated (Timms, 1981).

Another factor is the expansion unit. This can be either a spring or a screw. The use of a spring reduces the rigidity and control of the expansion; hence, springs are less popular than screws (Timms, 1981). The expansion screw which is most commonly used is the Hyrax screw (GAC, Bohemia, NY). Hygienic issues related to the RME however, may have deleterious effects, such as decalcification and inflammation of the palate, as the appliance needs to be cemented in the mouth for a considerable period of time; hence, a design which allows good

hygiene is generally preferred, like the Hyrax appliance, which exhibits minimal palatal and dental mucosal coverage.

The position of the screw in the appliance is vital. The centre of resistance lies in the middle of the palate in the primary dentition; in the permanent dentition, this position moves posteriorly to the embrasure between the second premolar and the first permanent molar. There are two moments, or centres of rotation, when the RME force is applied. The first is at the front-nasal suture and the second at the posterior mid-palatal suture. These moments' positions can be affected by placing the jackscrew more posteriorly or anteriorly (Jafari et al., 2003b).

Finally, the height of the RME can influence the degree of dental movement. A finite element model study showed that if the RME is placed close to the palate, an extrusive tendency and distal displacement may occur. However, if placed away from the palate, then buccal crown tipping could be enhanced with some mesial displacement tendencies (Araugio et al., 2013).

1.9. Clinical Characteristics

1.9.1. Indications and Clinical Considerations

RME can be used to treat unilateral or bilateral posterior crossbite due to a transverse deficiency in the maxillary arch. The underlying aetiology may be skeletal, dental or a combination of both (Bishara and Staley, 1987, Haas, 1970, Wertz, 1970).

Other applications include the management of narrow maxillary arches and mild crowding (Adkins et al., 1990, Bishara and Staley, 1987, Haas, 1980), as well as cleft palate with or without cleft lip before secondary alveolar bone grafting (Bishara and Staley, 1987, Haas, 1980, Isaacson and Ingram, 1964). RME is indicated if the transverse discrepancy between the maxillary and mandibular teeth is 4 mm or more. A more favourable prognosis for RME can be expected if there are many teeth contributing to the crossbite (Bishara and Staley, 1987). To avoid further dental tipping, it is recommended that conventional RME should not be used if the initial angulation of the maxillary molars and premolars are buccally inclined. A further consideration before using RME is the age of the patient. Since the timing of mid-palatal suture fusion is variable, it is proposed that the optimal age for RME is 13–15 years. If RME is applied to an older age group, there is a risk that the rigidity of the bones may limit the amount of maxillary expansion and the subsequent stability (Bishara and Staley, 1987).

RME is suitable for patients with anterior-posterior discrepancy in the maxillary arch (skeletal Class II Division 1 malocclusions with or without a posterior crossbite; patients with Class III malocclusions; and patients with borderline skeletal and pseudo Class III discrepancies associated with maxillary constriction; (Bishara and Staley, 1987, Haas, 1961). Moreover, RME aids in directing the development of the posterior teeth into normal occlusion. This allows more vertical closure of the mandible, eliminates any functional shift of the mandible and may prevent Temporomandibular Dysfunction (Bell, 1982).

RME can also be useful in the treatment of patients with a palatal impacted canine. Maxillary expansion is effective as an interceptive procedure for palatally impacted maxillary canines, with a reported success rate that is almost five times greater than that of untreated controls (Baccetti et al., 2009).

As an adjunctive appliance, RME can be used in conjunction with protraction headgear for Class III skeletal correction. Baik compared the forward and the downward movements of the maxilla using a protraction headgear with and without RME. The study found more forward movement of the maxilla in the protraction headgear in conjunction with the RME group (Baik, 1995). However, other studies have suggested no difference in antero-posterior dimension of 30 cases with Class III skeletal discrepancies (Ngan et al., 1996). Patients with nasal obstruction, characterised by obligate mouth breathing and a constricted nasal opening with the conchae compressed against the nasal septum, may exhibit improvement in nasal breathing following the application of RME (Haas, 1980).

Another possible indication for RME is conductive hearing loss due to Eustachian tube or middle ear obstruction. In such patients, the symptoms may improve after RME. The mode of action of RME in this case is by orthopaedic effects that normalise the function of the pharyngeal Ostia of the Eustachian tube (Gray, 1975, Lupton, 1981, Timms, 1974, Timms, 1976). Another explanation of this improvement is the decrease in the incidence of recurrent serous otitis media after RME (Gray, 1975). However, Ceylan et al. (Ceylan et al., 1996)

reported that any improvement in hearing occurring after active expansion by RME was not of a long-term nature.

Another application of RME is in children with nocturnal enuresis (NE). NE is identified as wetting the bed occurring in girls over the age of 5 years and boys over 6 years more than two nights per month (Rushton, 1989). NE has a strong correlation with upper airway obstruction, breathing problems and sleep apnoea (Gray, 1975, Timms, 1999). In 1970, Freeman showed an unexpected benefit of RME in the elimination of NE in ‘mentally retarded’ subjects (Freeman, 1970). This was also demonstrated in a retrospective study, where an improvement in NE was reported within 1–4 months following maxillary expansion (Timms, 1990). Similar findings were reported in other studies (Kurol et al., 1998, Schütz-Fransson and Kurol, 2008, Usumez et al., 2003).

Finally, RME may be used to treat patients with primary headache. It has been demonstrated that primary headache symptoms disappeared in 32 patients and were reduced in rate and intensity in 9 patients after RME therapy (Farronato et al., 2008).

1.9.2. Amount of Expansion

Overexpansion of the maxilla to allow tipped buccal posterior teeth to return to an upright position has been reported (Mew, 1983, Haas, 1965). Overexpansion of the molars by 2 to 4 mm beyond the required distance to allow for the expected post-treatment relapse is recommended. It is advisable to expand the upper arch until the

maxillary palatal cusps are level with the buccal cusps of the mandibular teeth to compensate for future relapse (Krebs, 1964, Timms, 1976, Timms, 1981).

A simple method of assessing the amount of expansion required was described by Bishara and Staley (Bishara and Staley, 1987). Initially, the distance between the most gingival extension of the buccal grooves on the mandibular first molars and the distance between the tips of the mesiobuccal cusps of the maxillary first molars was measured, and the mandibular measurement was subtracted from the maxillary measurement. This difference in individuals with normal occlusion was + 1.6 mm for males and + 1.2 mm for females. The maximum amount of maxillary expansion was 10–12 mm. If more expansion were needed, an orthodontic-surgical option should be considered.

1.9.3. Activation Regimes

Various protocols have been reported in the literature. One single turn of a screw after first cementation of the RME appliance followed by one turn in the morning and another in the evening daily until the desired expansion is achieved has been reported (Haas, 1961, Wertz, 1970). However, there are various expansion regimes which are selected depending on the patient's age group. Timms (Timms, 1981) suggested two quarter turns each day for patients under 15 years old, four 45° turns each day for patients aged 15–20 years old, and a reduction in the expansion rate for those more than 20 years old.

For younger patients, two turns per day for the first 4 to 5 days and one turn each day for the remainder of the RME treatment were suggested.

In adult patients, two turns per day for the first 2 days, one turn per day for the next 5 to 7 days, and one turn every other day for the remainder of the RME treatment has been considered (Zimring and Isaacson, 1965).

1.9.4. Force Generated During RME Treatment

The force produced by RME should be sufficient to overcome the skeletal resistance caused by the displacement of the maxillary shelves and the limitation of the tooth movement. Single activation of the expansion screw of the RME device can result in 1350–4500 g of force, with a cumulative of force more than 9000 g after multiple turns. The maximum load is produced immediately after activation and then starts to dissipate (Isaacson and Murphy, 1964).

1.9.5. Relapse and Retention

The aim of retention after RME is to hold the achieved expansion at the termination of RME activation. Since the greatest decrease in the load occurs in the first week of retention and dissipates within 5 to 7 weeks, use of rigid retention appliances has been advocated; the RME appliance fulfils this requirement (Zimring and Isaacson, 1965). Another aim of retention is to allow new bone to fill the gap created by the RME at the mid-palatal suture opening and resist the tendency to relapse. This can be achieved during the 3 months after the active treatment period (Haas, 1961, Sarver and Johnston, 1989, Wertz,

1970), or even up to several years after active treatment (Timms and Moss, 1971).

There are varying results with regard to the amount of relapse reported in the literature. Some have reported no relapse for the first 5 years after treatment (Haas, 1961, Haas, 1965, Haas, 1970), while others have shown that half of patients will relapse 5 to 15 years after RME (Stockfisch, 1969). Relapse is more likely in older patients compared to younger ones, which indicates that the amount of relapse is age-dependent and is perhaps associated with the rigidity of the craniofacial complex (Wertz and Dreskin, 1977). In a recent systematic review, it was concluded that the long-term stability of transverse skeletal maxillary expansion is better in pre-pubertal adolescents than in more mature groups of patients (Lagravere, 2005).

Other factors which might influence relapse after RME are onset, duration of retention and the type of the retention appliance used after expansion. The expected relapse could occur half of the time if no retention is used. Regarding the type of retention appliance, 2–3 months of retention using a fixed retainer allows 10–23% relapse, whereas removable retention allows 22–25% relapse (Hicks, 1978).

1.9.6. Side Effects of RME

One of the most common side effects of RME is pain. In 98% of cases treated with RME, some discomfort generally occurs during the first 6 turns as the palate splits, which diminishes thereafter. It has been found that pain is correlated with the expansion regime and the number of

expansion turns per day. For this reason, analgesics are recommended if the rate of expansion exceeds one turn per day (Needleman et al., 2000).

A second complication that might arise during the use of RME is palatal tissue irritation and palatal pressure necrosis. This is due to the proximity of the appliance to the gingival tissues, or to food and plaque entrapment around the appliance and the fact that some patients may have difficulty maintaining adequate hygiene in these areas. This side effect may require the premature removal of appliances, but may be alleviated by the provision of a blunt syringe to clean under the appliance (Alpern and Yurosko, 1987, Sardesai and Fernandesh, 2004).

Another common complication is root resorption of the buccal surface and lingual surfaces of the anchor teeth, which is mainly due to the heavy orthopaedic forces (Barber and Sims, 1981, Erverdi et al., 1994, Langford and Sims, 1982). Root resorption can involve non-anchored premolars (Barber and Sims, 1981). Fortunately, the resorbed roots tend to repair with cellular cementum (Langford and Sims, 1982). Since the applied force is distributed over the teeth and the palatal tissue with the Haas appliance (tissue borne), in comparison to the Hyrax appliance (tooth borne), less root resorption can be expected (Odenrick et al., 1991). However, Everdi reported no difference in resorption type and amount between the Haas group (tissue borne) and cast cap splint group (tooth borne; (Erverdi et al., 1994).

The side effects of RME extend to involve the periodontal tissue. Authors have reported that RME has a minimal effect on the bone level

and periodontal condition in comparison to controls (Greenbaum and Zachrisson, 1982). On the contrary, it was also reported in a longitudinal study that almost one-quarter of the patients treated with RME developed gingival recession compared with 6% in the group treated only with edgewise appliances (Vanarsdall, 1994).

Pulpal tissue damage can result from RME and may appear during and/or immediately after RME treatment. However, the teeth might show a transient change in response to stimuli, with the teeth remaining vital (Cho et al., 2010).

Other complications of RME reported in the literature include some potentially serious, though uncommon complications. One report showed paresis of the oculomotor nerve in a patient after surgical-assisted RME due to damage to the skull base as a result of skeletal distortion (Lanigan and Mintz, 2002).

1.10. Evaluation of the Effect of Rapid Maxillary Expansion

1.10.1. Introduction

Several methods have been considered to evaluate the effects of RME. These include the use of dental casts for direct measurement (Adkins et al., 1990, Geran et al., 2006, Handelman, 1997, Sandstrom et al., 1988), Rhinomanometry (Hilberg, 2002), acoustic Rhinomanometry (Kase et al., 1994) ; two-dimensional (2D) imaging methods (Chung and Font, 2004, Cross and McDonald, 2000, da Silva Filho et al., 1995, Davidovitch et al., 2005, Haas, 1961, Timms, 1980, Wertz, 1970),

histology-based studies (Cleall et al., 1965, Murray and Cleall, 1971, Starnbach et al., 1966), and Finite Element Model study (FEM), CBCT, CT scanning and laser scanning (da Silva Filho et al., 2005, Gordon et al., 2009, Hasso and Nickmeyer, 1994, Hilberg, 2002, Işeri et al., 1998, Miles, 2008, Tanne et al., 1989a, Tanne et al., 1989b, Timms et al., 1982).

1.10.2. Skeletal Effects

RME mainly increases the transverse dimensions of the maxillary arch by an orthopaedic effect through the separation of two maxillary halves, as well as by an orthodontic effect through the buccal movement of the posterior teeth and alveolar processes (da Silva Filho et al., 1995). Once the appliance is activated, there is an immediate compression of the periodontal ligament, bending of the alveolar processes, and tipping of the anchoring teeth. Skeletal expansion appears when the applied forces exceed the orthodontic tooth movement limits, and the final result is a distraction force on the mid-palatal suture which has not yet ossified (Bishara and Staley, 1987, Haas, 1961). As the inter-palatine suture opens, the articulating sphenoid bones are also affected with a resultant increase in width between the pterygoid hamuli (Timms, 1980).

In the permanent dentition, the ratio of the orthopaedic/orthodontic effect of RME is about 1:3 of the amount of screw activation, whilst the ratio in mixed and deciduous dentition is 1:2 (da Silva Filho et al., 1995). The amount of orthodontic effect is affected by a number of

factors, including the mode of activation, type of expansion appliance and age of the patient, which could influence the resistance of skeletal and soft tissue structures surrounding the maxilla (Braun et al., 2000). It had been claimed that RME expansion can cause downward and forward movement of the maxilla (Chung and Font, 2004, Davis and Kronman, 1969, Haas, 1961, McDonald, 1995). Moreover, it has been shown that an increase in the opening of the pterygomaxillary fissure is associated with the deposition of bone within the maxilla-cranial sutures (Haas, 1970). The nasomaxillary complex rotates in such a manner that the lateral structures move upward and midline structures downward after RME (Jafari et al., 2003b).

It has been reported that after RME, the maxilla move downward (1–2 mm) and forward (1.5 mm), and this is due to the disarticulation of the maxillary complex from the pterygoid process (Wertz, 1970). Another explanation for the forward movement of the maxilla is the lateral buttressing of the zygoma, which acts as the point of rotation (Biederman, 1973); however, this theory was rejected by Melsen and Melsen (Melsen and Melsen, 1982), who suggested that it is impossible to open the pterygomaxillary connection.

The RME force may affect various structures in the craniofacial complex, including the sphenoid and zygomatic bones. This effect of the RME force may be the reason for the downward and forward displacement of the maxilla (Jafari et al., 2003b). Other structures of the craniofacial skeleton which are affected by transverse orthopaedic forces include the nasal bone and the zygomatic bone, which may be displaced in a lateral, superior and posterior direction following RME.

The skeletal effect is influenced by the type and design of the RME, with a more backward displacement of the maxilla in bonded RME treatment than with a banded design (Sarver and Johnston, 1989).

The downward displacement of the maxilla has been associated with an increase in the total facial dimension. These changes may be beneficial in some cases, as in skeletal Class III patients, but may not be desirable in a skeletal Class II case. This type of maxillary displacement may not be required in cases with existing open bites or increased vertical dimensions (Haas, 1961, Haas, 1965, Haas, 1970, Wertz, 1970). The other explanations for the increased vertical dimension include a posterior tipping of the palatal plane, with a forward and downward rotation of point A, backward movement of point B and clockwise rotation of the mandible (Gardner and Kronman, 1971). Others have claimed that there is no anterior displacement of the maxilla (de Silva Fo et al., 1991). The extrusion and tipping of maxillary posterior teeth, together with alveolar bending, is considered an alternative explanation to downward and backward mandibular movement (Bishara and Staley, 1987). Others have shown that no vertical alterations could be found after RME treatment (Chang et al., 1997, Garib et al., 2006, Sari et al., 2003, Velázquez et al., 1996). A similar study reported that the vertical changes are transitory (Velázquez et al., 1996). The clockwise rotation of the mandible appears to diminish during the retention phase (Bishara and Staley, 1987) and fully recovers after removal of the appliance (Chang et al., 1997, Garib et al., 2006, Sari et al., 2003, Velázquez et al., 1996).

It has been stated that the transverse expansion of the RME occurs in a wedge-shaped or a pyramidal pattern, with the base at the palatal level and the apex within the nasal cavity (Bell, 1982, Biederman, 1968, Chung and Font, 2004, da Silva Filho et al., 2005, da Silva Filho et al., 1995, Garrett et al., 2008, Haas, 1961, Haas, 1965, Krebs, 1964, Lione et al., 2008, Timms, 1980, Ong et al., 2013). However, Wertz disagreed with these findings and suggested that the apex of expansion was in the area of the fronto-maxillary suture. Wertz associated the non-parallel expansion with the buttressing effect of the zygomatic arch, which acts as a fulcrum for the maxillary separation away from the activating screw of RME (Wertz, 1970). The location of this fulcrum is age-dependent (as it depends on the degree of calcification of the circummaxillary structures) and seems to be nearer to the activating force with an increase in patient age (Brossman et al., 1973, Isaacson and Ingram, 1964, Timms, 1981, Ong et al., 2013).

At the alveolar level, it had been found that the crowns of the teeth expand more than the alveolar arch, followed by the maxillary base; there is minimal separation within the nasal cavity (de Silva Fo et al., 1991). A metallic implant study showed that the mean increase in intermolar distance (measured in the study model); the infra-zygomatic ridge implants were 6 mm and 3.7 mm, respectively. The sutural opening represented more than 50% of the magnitude of the achieved dental arch expansion (Krebs, 1964). Similar findings have been drawn by others (da Silva Filho et al., 1995, Haas, 1961, Haas, 1965, Ong et al., 2013). Another factor which might influence the amount of transverse expansion is the presence of cleft lip and palate. It has been

found that there is less skeletal and more dental expansion in such patients (Isaacson and Ingram, 1964).

The mandibular arch responds to the RME indirectly at a ratio of 15.7–43.8% of the screw expansion, compared to 15.9–37.7% changes at the nasal width level and 0–16.5% changes in infra-orbital width (Chung and Font, 2004).

From the occlusal point of view, the maxillary halves split in a triangular or pyramidal form, with the base towards the anterior region of the maxilla, as a result of the weak buttressing effects of the anterior facial structure (Davidovitch et al., 2005, de Silva Fo et al., 1991, McDonald, 1995, Timms, 1980, Wertz, 1970, Ong et al., 2013). This is contradictory to the finding that the splitting of the maxillary halves occurs in a parallel form from the ANS to the PNS (Haas, 1961). The use of a rigid appliance which is located more posteriorly is believed to move the centre of rotation superiorly and posteriorly, which may result in a more linear separation of the bones. For this reason, it is believed that the acrylic cap expander lacks the appropriate stiffness and may produce less parallel expansion and a greater tipping effect (Braun et al., 2000).

1.10.3. Dentoalveolar Effects

A clinically significant increase in the arch perimeter post RME treatment has been reported by several authors; this is associated with a reduction in the arch depth (Davidovitch et al., 2005, McNamara Jr et al., 2003). The transverse dental changes of the RME are opposite to

those detected at the skeletal level; the posterior dentition undergoes the greatest expansion, and this is explained by the articulation of the palate posteriorly with other craniofacial structures (Davidovitch et al., 2005, Lagravère et al., 2006a, Lamparski Jr et al., 2003, Schneidman et al., 1990). This explains the dissipation of skeletal forces created by the RME appliance over the dentition (Davidovitch et al., 2005). Handelman et al. (Handelman et al., 2000) found a net gain of 4.8 mm in maxillary expansion for an adult sample 5 years after retention. Similar findings were reported by McNamara et al. (McNamara Jr et al., 2003). The intercanine width increased during expansion and it was stable after the retention period (Lagravere et al., 2005a, Lagravere et al., 2005b, Memikoglu and Iseri, 1999, Mutinelli et al., 2008). Vertically, since the force from the expander is coronal to the centre of rotation of the maxillary posterior teeth, the teeth tend to tip and extrude slightly with increased cuspal interferences and a resultant increase in the vertical dimension (Chung and Font, 2004).

A further dental effect of RME is the creation of a diastema between the central incisors which is approximately one-half of the total screw expansion; however, this should not be used as an indicator of the amount of suture separation. This diastema can reach a maximum of 4 mm (Haas, 1961, Wertz, 1970). During RME screw activation, the incisor roots diverge more than the crowns, but during the retention phase, the roots move medially and resume their original axial inclination in 4–6 months. This occurs due to the elastic recoil of transeptal fibres of the central incisors.

RME can affect the inclination and position of the maxillary incisors. The inclination of the upper incisor inclination can be increased (Sari et al., 2003) or decreased (Wertz, 1970, Sandikcioglu and Hazar, 1997). It has been reported that after removal of the appliance, the mesially tipped incisors distalize and become more upright; this was attributed to the effect of the transeptal fibres, as well as changes in muscle tension (Adkins et al., 1990, Wertz, 1970).

Maxillary posterior teeth inclination can be affected in a similar way to the incisors due to the initial alveolar bending and compression of the periodontal ligament (Asanza et al., 1997, Davidovitch et al., 2005, Kılıç et al., 2008). In a similar way to the incisors, molar crown tipping was observed at pre-treatment levels during the retention period. Buccal crown tipping of the posterior teeth occurs more frequently with the Hyrax expander (Davidovitch et al., 2005, Kiliç and Oktay, 2008).

The dental effect of the RME on mandibular expansion is related to the imbalance of equilibrium between forces of the soft tissue of the cheek and the inferiorly positioned tongue secondary to the expansion (Haas, 1961). Altered occlusal forces on the mandibular posterior teeth may also contribute to these changes (Wertz, 1970). Handelman et al. (Handelman et al., 2000) found a net gain of 0.7 mm in mandibular intermolar width in adult cases 5 years after RME.

1.10.4. Effects on the Median Palatal Suture and Craniofacial Suture

Histologically, the rapid, powerful expansion forces (4500–9000 g) applied through RME results in a breakdown of the mid-palatal suture,

with new bone formed in the bone defect so that the sutures are reformed to normal morphology after a retention period (Cleall et al., 1965). In addition to the effect of RME on the mid-palatine suture, histological studies in animals have shown that the nasal suture, maxillary-zygomatic suture and zygomatico-temporal suture demonstrate evidence of greater cellular activity compared to control animals (Starnbach et al., 1966).

1.10.5. Effects on the Nasal Cavity

The effect of RME on the nasal cavity was first described by Brown (Brown, 1903), and has subsequently been reported by others (Haas, 1961). The nasal effects of RME were assessed and studied either using change in nasal function via measurement of nasal airway resistance (McDonald, 1995) or through measurement of the change in nasal cavity dimension (Cross and McDonald, 2000). Nasal and pharyngeal mucous membrane hypertrophy were found to be alleviated after RME due to the increase in nasal width and permeability (Haas, 1961).

1.10.5.1. Changes in Nasal Cavity Dimensions

The effect of RME is an increase in intranasal capacity. This occurs as a result of lateral displacement of the outer wall of the nasal cavity, inferior turbinate bones and the conchae, which are attached to the nasal wall. In addition, due to the bending of the lateral alveolar

process and the inferior movement of the horizontal palatine process, the floor of the nose drops inferiorly, causing an increase in the nasal cavity dimension (Gray, 1975, Haas, 1965). Finally, the vertical dimension increases in the nasal cavity and straightens the nasal septum because RME causes the medial edge adjacent to the vomer to move laterally and downward (Gray, 1975).

It has been reported that the expansion in the nasal cavity is restricted to the lower part of the nasal cavity, and that there is a small but significant increase in nasal cavity height (Cross and McDonald, 2000). This is associated with outward rotation of the maxilla during expansion, with consequent lowering of the nasal floor (da Silva Filho et al., 1995, Haas, 1961, Wertz, 1970).

The medical uses of RME have been recognised since 1912. Involuntary conversion to oro-nasal breathing may occur once ventilation exceeds 40–45 L/min, while airway nasal resistance of 3.5–4 cm/L/min can result in partial mouth breathing (Timms, 1974). However, the degree of nasal expansion ranges from 1.4 to 4.5 mm in different studies. Thus, it is less likely for RME to relieve any nasal stenosis which is higher and more posteriorly located (Haas, 1961, Krebs, 1964, Wertz, 1970).

In general, the nasal effects of RME are related to age, with a greater increase in younger than in older subjects (Cross and McDonald, 2000, da Silva Filho et al., 1995, Krebs, 1964, Wertz, 1970). However, it has been reported there was no statistically significant difference in the amount of nasal cavity expansion when the mixed and permanent dentition group were compared (Sari et al., 2003).

It has been claimed that in some cases treated with RME, the vomer can disarticulate and remained joined to one palatal process (Gray, 1975). However, Timms (Timms, 1981) reported that complete disarticulation of the vomer occurred during maxillary separation.

1.10.5.2. Changes in Nasal Cavity Function

One of the explanations for the decrease in nasal airway resistance after RME is the increase in the nasal valve dimension as a result of lateral nasal wall expansion and the widening of the nasal cavity (Gordon et al., 2009). Doruk et al. (Doruk et al., 2007) suggested that lateral and posterior-anterior cephalometric radiographs were of little use in the measurement of nasal function and patency. They reported that the use of this type of radiographic imaging caused magnification of the imaged structure and consequently affected the measured object. The generalised enlargement of the image can vary from 6 to 15% (Adams et al., 2004). Alternative physical objective tests for the assessment of the nasal airway patency are Rhinomanometry and Acoustic Rhinometry.

1.10.5.2.1. Rhinomanometry

Rhinomanometry is a functional technique that provides a reading of airflow versus differential pressure in order to assess the patency of the nasal cavity (Hilberg and Pedersen, 2000). It involves recording pressure and flow simultaneously over a given time interval and allows

the relationship between pressure, air flow and time to be studied. The disadvantage of the method is that it requires the wearing of a mask while the measurements are being taken (Doruk et al., 2007, McDonald, 1995). Moreover, it cannot identify the site of the obstruction within the nasal passage (Hilberg and Pedersen, 2000). In addition, unreliability in detecting small changes in nasal patency and poor correlation with changes in nasal resistance have been suggested (Lane et al., 1996).

1.10.5.2.2. Acoustic Rhinometry (AR)

The use of AR in the nasal cavity was introduced by Hilberg (Hilberg et al., 1989). This technique measures cross-sectional areas and volume of nasal passages. It is used as a diagnostic evaluation for nasal structures prior to nasal surgery (Cole et al., 1997). Other uses include assessment of the changes resulting from various treatments to investigate the anatomy and pathology of the upper airways (Cole et al., 1997, Corey et al., 1997, Hilberg and Pedersen, 2000), to assess the results of nasal challenge (Lane et al., 1996), to assess the effects of medications (Ghani et al., 2004) and physiological and environmental conditions of the nasal passage.

The main advantage of this method is its reproducibility (Silkoff et al., 1999). It is widely accepted as a simple, non-invasive method for measuring the dimensions of the nasal cavity, and has demonstrated a reasonable correlation with CT and MRI for the first six centimetres of changes within the nasal cavity. In addition, it is painless and requires only minimal patient cooperation (Çakmak et al., 2003, Corey et al.,

1997, Dastidar et al., 1999, Doruk et al., 2007, Gilain et al., 1997, Hilberg et al., 1989, Hilberg et al., 1993, Numminen et al., 2003, Terheyden et al., 2000).

AR is based on the concept that changes in the acoustic impedance or the reflection of sound waves within the nasal cavity are proportionate to changes in a cross-sectional area (Hilberg and Pedersen, 2000). Acoustic pulses or audible sound impulses pass through the wave tube and enter the nasal passage to the nose-piece of the AR device. The reflected waves are detected by a microphone and then amplified, filtered, processed, compared to the original and digitalised. Finally, the data is converted to allow the computer to give three parameters of the nasal cavity, namely volume, area and resistance, in the graphic display format of the cross-section versus distance curve or rhinogram (Cole et al., 1997).

The procedure should be performed in a quiet room to eliminate the influence of external noise. Constant temperature and humidity should be standardised, since sound velocity increases with increased temperature and humidity. Doruk et al. (Doruk et al., 2007) using a CT scan, compared the reliability and accuracy of AR in measuring nasal airway dimensions. The investigators found that both methods were well correlated. One of the main prerequisites of this method is to measure the speed of the pulse sound and the echo return time, and the distance from the nose tip can be calculated (Hilberg et al., 1989). However, this technique carries some possible sources of error which should be minimised as per the recommendations of the European Rhinological Society standard operating procedures for AR (Clement

and Gordts, 2005, Hilberg and Pedersen, 2000). One of the main requirements is to obtain an adequate acoustic seal between the nose tip and the nostril, and this can be achieved using a water-based lubricant gel. Another requirement is an optimal connection to the nostril, with minimum or no deformation of the nasal tip during measurement (Figure 11). In order to avoid pressure changes in the nasal cavity as a response to airflow and any simultaneous respiratory noise production such as swallowing or throat clearing, the patient must be able to hold his or her breath for a short time (Tomkinson and Eccles, 1995). Lastly, the angle of the wave tube should be as parallel to the bridge of the nose as possible (Figure 12).

The use of AR has demonstrated significant increases in total volume and non-significant changes in the total minimum cross-sectional area following treatment with RME (Babacan et al., 2006, Ceroni Compadretti et al., 2006, Doruk et al., 2007, Wriedt et al., 2001). These changes were found to be more stable if expansion was performed before adulthood (Doruk et al., 2007).

AR can be applied in the assessment of RME's effect in children. It has been found that more than 50% of children with mouth-breathing habits and constricted maxillary arches showed a change in breathing mode from oral to nasal after RME or surgically assisted RME (Baraldi et al., 2007, Ceroni Compadretti et al., 2006, Wriedt et al., 2001).

1.10.5.3. Nasal Airway Resistance

A warm wire anemometer can be used to measure the velocity of air passing through the nasal cavity at maximum inspiration. However, the level of respiratory effort and patient anxiety are considered to be the main drawbacks of this method (Wertz, 1968).

To assess nasal airway resistance, a standard Rhinomanometry technique was used by Timms (Timms, 1986) in a retrospective study of 26 patients. An average reduction of 36.2% in nasal airway resistance was reported after RME. The author also evaluated the resolution of respiratory symptoms. It was emphasised that the greatest reduction in nasal airway resistance is usually associated with a high initial nasal airway resistance, not the greatest expansion.

1.11. Three-dimensional modalities and their application in the assessment of the effects of RME

1.11.1. Introduction

There is no recognised gold standard method to measure the three-dimensional (3D) effect of RME (Lam et al., 2006). Having evolved greatly over the last two decades, 3D imaging relies on a set of data collected using imaging equipment, computer software processing and display on a 2D monitor to give the illusion of depth (Hajeer et al., 2004).

1.11.2. The Finite Element Model

The Finite Element Model (FEM) relies on the mechanical analysis of stresses and strains induced in living structures (Tanne et al., 1989a, Tanne et al., 1989b). It provides a method of mimicking orthodontic force systems to allow analysis of the response of the craniofacial skeleton to this force in 3D space (Işeri et al., 1998). The advantages of FEM include that it is noninvasive, objective, valid and the study can be repeated as many times as required (Korioth and Versluis, 1997). The main drawback of this method is the inaccuracy of results, which is influenced by the precision of the model's geometric illustration (Holberg et al., 2005, Provatidis et al., 2008a). Işeri et al. (Işeri et al., 1998) reported a parallel separation of the mid-palatine suture using a Finite Element Model of 2349 complete skulls, with the greatest widening being observed in the dentoalveolar areas and gradually decreasing through the upper structure.

The nasomaxillary complex was found to rotate around the fulcrum of the upper border of the orbit, while the nasal cavity dimension increased significantly at the level of the floor of the nose and to a lesser extent at the postero-superior level. At the dental level, the maxillary central incisors and molars were slightly displaced inferiorly and anteriorly, with more inferior displacement of the former than the latter. Another observation of this study was the absence of the lateral displacement of the temporal, parietal, frontal, sphenoid and occipital bones. Similar results have been reported but with a pyramidal opening

of the palatine suture detected (Gautam et al., 2007, Jafari et al., 2003b, Provatidis et al., 2007, Provatidis et al., 2008a).

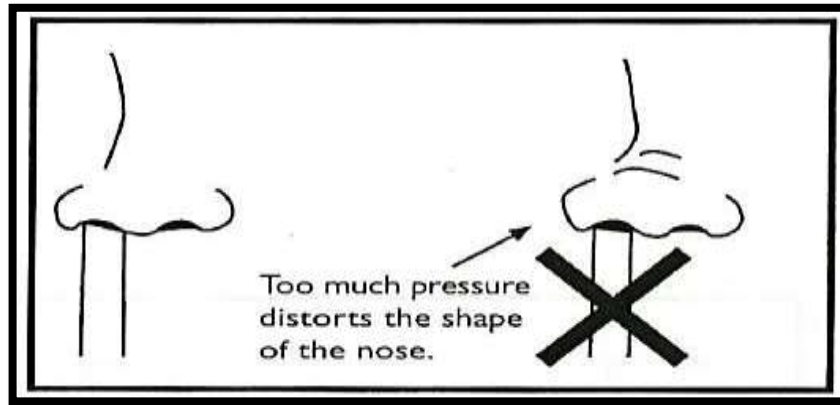


Figure 11: AR nose tip adaptation (from Eccovision® Quick Setup Guide, Hood Labs, Pembroke, MA, USA)

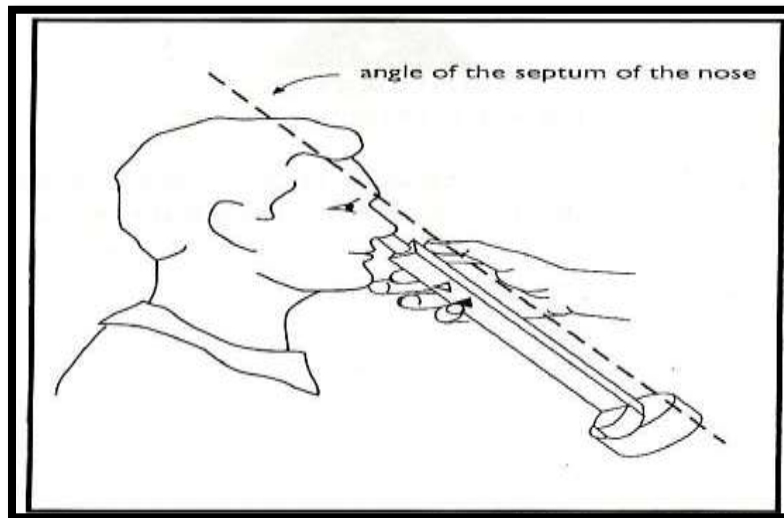


Figure 12: Technique for holding AR wave tubes (from Eccovision® Quick Setup Guide, Hood Labs, Pembroke, MA, USA)

1.11.3. Computed Tomography and Cone-Beam Computed Tomography Scanning

Extensive studies of RME have been conducted using 2D imaging, which involves lateral and posterior-anterior cephalometry (da Silva Filho et al., 1995), but there have been few studies using 3D imaging based on CT data (Ballanti et al., 2009, da Silva Filho et al., 2005, Garib et al., 2005, Garrett et al., 2008, Lione et al., 2008, Podesser et al., 2007, Timms et al., 1982, Ong et al., 2013). The drawbacks of 2D cephalometry are the inability to quantify the transverse dimension, as evident in the frontal plane, the inherent errors due to distortion and magnification with poor reproducibility of landmark identification (Ahlqvist et al., 1986, Baumrind and Frantz, 1971, Lenza et al., 2010, Aboudara et al., 2009).

The disadvantages of CT scanning are relatively low between-slice accuracy, high cost, high radiation dose exposure and artefacts created by metal objects (Hildebolt et al., 1990, Holberg et al., 2005). CBCT is becoming increasingly available for orthodontists (Gordon et al., 2009); this is also known as cone-beam volumetric tomography (CBVT), and was first developed as a tomographic scanning technology in the 1990s. CBCT scanner machines utilise a round or rectangular cone-shaped X-ray beam which rotates 360 degrees around the patient's head while acquiring a series of projections or images in less than 1 minute (Arai et al., 1999, Mozzo et al., 1998). These exposures are then detected by an X-ray detector system, and the end result of the image acquisition process is a stack of images that are

compiled into a volume of data. Through the computer process, the primary reconstruction is generated and then visualised in standardised 2D trans-axial, multi-planar format or by using 3D visualisation techniques such as surface reconstruction, volume rendering or any combination of 2D and 3D visualisation techniques (Miles, 2008).

The advantage of CBCT is the ability to image both hard tissue and soft tissues. However, it is unable to capture the true colour and texture of skin (Kau et al., 2005). CBCT scanning overcomes the limitations of 2D radiography and traditional CT, with a shorter capture time, and consequently lower exposure to radiation (Mah et al., 2003). Using the i-Cat CBCT scanner (Imaging Sciences International, Inc., Hatfield, PA), the scan time is approximately 20 seconds, and this might also reduce the likelihood of patient movement while the scan is being processed. On the other hand, the radiation from a CBCT scan (the effective dose of a CBCT is 200–400 μSv) is approximately equivalent to a full-mouth periapical radiographic exposure and around 20% of conventional CTs (an effective dose of 2000–8000 μSv ; (Kau et al., 2005, Mah and Hatcher, 2004, Mah et al., 2003). The measurement error obtained from CBCT in comparison to conventional CT ranges from only 0.45–1.44%, which is within a clinically tolerable range (Bryant et al., 2008, Cavalcanti et al., 1999).

CBCT-based 3D analyses (Dolphin software; Dolphin Imaging and Management Solutions, Chatsworth, CA) are clinically accurate for craniofacial evaluation (Periago et al., 2008). These were compared with the gold standard of physical measurement directly from skulls, and less than 1% relative error was demonstrated (Lagravère et al.,

2008, Stratemann et al., 2008). An error range from 0% to 5% for the accurate analysis of the airway using CBCT has been reported (Aboudara et al., 2009).

The Classic i-Cat (Imaging Sciences International, Inc.) CBCT scanner provides visualisation of the entire skull, since the field of view available is around 16 x 22 cm with a voxel size of 67 μ S. This allows for an analysis of the entire facial skeletal complex (Jacobson and White, 2007).

The first study to assess the effects of RME using CT data showed changes taking place in the palatal plane (Timms et al., 1982). Other studies have considered CT scans to evaluate skeletal changes (Ballanti et al., 2009, da Silva Filho et al., 2005, Garib et al., 2005, Garrett et al., 2008, Lione et al., 2008, Podesser et al., 2007, Ong et al., 2013), dental changes (Garib et al., 2005, Podesser et al., 2007, Rungcharassaeng et al., 2007), periodontal changes (Ballanti et al., 2009, Garib et al., 2006, Podesser et al., 2007, Rungcharassaeng et al., 2007) and nasal changes (Garib et al., 2005, Garrett et al., 2008) after RME.

1.11.4. Magnetic Resonance Imaging Scanning (MRI)

Disadvantages of Magnetic Resonance Imaging (MRI) include a longer examination time compared to CT and motion artefacts from breathing, carotid pulsations and swallowing (Wippold, 2007), as well as inaccuracy and insensitivity when it comes to detecting skeletal hard tissue (Kishi et al., 2007). MRI is a non-invasive imaging technique and is used more frequently for the diagnosis of pathological changes

when suspected in the extracranial head and neck region (Hasso and Nickmeyer, 1994, Hilberg, 2002). It is used for the diagnosis of cystic lesions (Kaneda, 2003) and the assessment of the Temporo-Mandibular Joint (TMJ) (Kanji Kishi et al., 1988). The principle of MRI is the interaction of the magnetic properties of hydrogen, an external magnetic field, with radio waves to produce detailed images of the body (Faulkner, 1996).

1.11.5. RME effects as measured using the 3D modalities

1.11.5.1. Skeletal Effects

A CT-based study to assess the sagittal expansion of the mid-palatal suture in young patients (mean age 8.2 years) following RME using a Haas fixed expander showed pyramidal expansion of the suture. The expansion was greater anteriorly (2.21 mm) compared to posteriorly (0.95 mm). Other studies reported opening at the posterior suture which constituted 40% of the anterior suture width (Garrett et al., 2008, Lione et al., 2008, Ong et al., 2013).

Christie et al. (Christie et al., 2010) showed the parallel expansion of the mid-palatal suture; here, the measurements of the suture opening were at the level of the teeth, and not at the ANS and PNS, as has been considered in other studies (da Silva Filho et al., 2005, Garrett et al., 2008, Lione et al., 2008). Several studies have assessed the skeletal effects of RME from the coronal sections of CT scans. The transverse expansion of the nasal floor corresponded to between one-third to one-

half of the amount of screw activation, with more expansion noted at the dental arch as compared to the basal region (Ballanti et al., 2009, Garib et al., 2005, Podesser et al., 2007, Ong et al., 2013).

1.11.5.2. Dentoalveolar Effects

RME can induce buccal inclination of the posterior teeth of approximately 6.7 degrees at the second premolar level (Garib et al., 2005). The reason for the second premolar tipping, which was recorded to be greater than the banded first premolar and molar, may be explained by the fact that the second premolars were expanded by a free lingual bar connecting the first premolar and first molar with the force applied to the crown far from the centre of resistance. This might have caused more buccal inclination. Another study reported similar results (Rungcharassaeng et al., 2007). The skeletal effect contributed about one-third of the total expansion, with more orthopaedic effects in the canine region (Podesser et al., 2007, Garrett et al., 2008)

1.11.5.3. Periodontal Effects

It has been reported that RME reduces the buccal bone thickness of supporting teeth by 0.6 to 0.8 mm (Ballanti et al., 2009, Garib et al., 2006, Rungcharassaeng et al., 2007). RME induced bone dehiscence on the buccal aspect of the anchored teeth and gum recession, especially using a tooth-borne expander (Garib et al., 2006, Ballanti et al., 2009). It has been suggested that a retention period longer than 3 months may

be necessary to allow the recovery of lingual and buccal bone plate thickness following RME (Ballanti et al., 2009, Garib et al., 2006).

1.11.5.4. Nasal Changes

The nasal and craniofacial sutures can be affected by RME (Garib et al., 2005, Garrett et al., 2008, Habersack et al., 2007, Christie et al., 2010). Conventional CT scans have been used to evaluate the change in the nasal cavity after RME (Palaisa et al., 2007). Here, the authors reported that the area and volume increased significantly in each region of the measured nasal cavity (anterior, middle and posterior); the overall volumetric increase was 10.7% with no relapse noted after a retention period of 3 months. The measured nasal width expansion was about one-third of the magnitude of the appliance expansion (Garib et al., 2005, Garrett et al., 2008, Habersack et al., 2007, Christie et al., 2010).

The cross-sectional area of the upper airway at the level of the posterior nasal spine was found to be significantly increased after RME (Chang et al., 2013). However, this study excluded the nasal cavity because of the difficulty of segmentation of the connecting air cavities, turbinates and rarefactions.

1.11.5.5. Effects of RME on the Soft Tissue

Using lateral cephalograms to assess soft tissue changes after RME (average expansion of 13 mm), Karaman et al. (Karaman et al., 2002) concluded that the nasal tip moved anteriorly by 2.50 mm, the nasolabial angle became more obtuse by 5.44° and the vertical dimensions of the lower-face (Sn-Me) and mid-face (N-Sn) increased by 2.10 mm and 0.93 mm, respectively, due to posterior rotation of the mandible. RME was claimed to affect the soft tissue facial angle, which was reduced by approximately 1.40 degree at the end of the retention.

Additionally, the H-angle and the profile convexity increased by 1.6 mm and there was no effect on nasal prominence post RME (Kılıç et al., 2008). Backward rotation of the mandible may account for the changes seen in the Holdway angle, profile convexity and soft tissue angle. A study by dos Santos concluded that bonded RME appliances did not cause significant changes in the soft tissue facial profile at the end of treatment (dos Santos et al., 2012).

For an assessment of the effects of RME on soft tissue, frontal photographic views have been utilised (Berger et al., 1999, Kılıç et al., 2008). Using this method, it was found that the nasal width measurement increased by 2.0 mm at the end of the active expansion process and the increase remained for 1 year following the removal of the appliance. It was concluded that 50% of the change in the RME appliance transverse width manifests itself as a change in the soft tissue nasal width (Berger et al., 1999).

Johnson et al. (Johnson et al., 2010) used digital callipers to measure the alar base width and the greater alar cartilage width in order to quantify the effect of RME on the nasal soft tissue width. The study concluded that the increases in alar base width and the greater alar cartilage width measurements were less than 1.5 mm, with no difference in soft tissue changes between the pre-pubertal and post-pubertal groups. These findings contradict those of previous studies (Baccetti et al., 2001, Cameron et al., 2002, Lagravere, 2005).

1.12. Maxillary Constriction and Obstructive Sleep Apnoea (Cordasco et al.)

Obstructive sleep apnoea (Cordasco et al.) is characterised by more than 10 episodes of upper airway obstruction during each hour of sleeping, usually associated with a reduction in blood oxygen level lower than 85% (de Souza Carvalho et al., 2012b). The American Academy of Sleep Medicine defines OSA as episodes of breathing cessation or absence of respiratory airflow for over 10 seconds despite respiratory effort.

There are two types of sleep apnoea classified according to their aetiology, namely central and obstructive. The only difference between centrally driven apnoea and OSA is that in the former, individuals present no effort to overcome the apnoea. The contributing factors of OSA (Cordasco et al.) could be a maxillary constriction, where the narrow maxilla can induce OSA through narrowing of the upper airway dimension and induction of low tongue posture (Goodday et al., 2001,

Anastassov and Trieger, 1998, Subtelny, 1954). Other factors include retrognathic mandible, reduced facial height, reduced pharyngeal width at the level of the PNS, an inferiorly positioned hyoid bone, a larger soft palate, macroglossia, functional impairment of the upper airway dilator muscles, congenitally reduced nasopharyngeal and/or oropharyngeal dimensions, as in some syndromes, including Achndroplasia and Downs, Apert and Pierre Robin syndromes. Additionally, smoking, alcohol consumption, obesity and sedatives are considered risk factors for OSA (Gaudette and Kimoff, 2010, Johal et al., 2007).

The pathophysiology of OSA can be explained by a respiratory blockage at the level of the nasopharynx or oropharynx when the tongue falls backward and blocks the airway during sleep, resulting in sleep being interrupted by periods of apnoea where the patient stops breathing for up to 15–20 seconds at a time. As a result, the carbon dioxide (CO₂) level in the blood rises to a certain point (hypercapnia), a sudden reflex intake of breath occurs and breathing starts again (Gaudette and Kimoff, 2010).

As a complication of OSA, the incidence of cardiovascular diseases such as hypertension, tachycardia, and atherosclerosis could increase, along with an increased risk of cerebrovascular accidents and angina or myocardial infarction. This is claimed to be the result of the intermittent hypoxic and hypercapnia episodes, which trigger homeostatic compensations in the body over time (Sharabi et al., 2004). Other complications are drowsiness during the day, with cognitive impairment, impaired ability to operate a machinery or motor vehicle

with an increased automobile accident rate (Goodday et al., 2001, Madani and Madani, 2007).

According to epidemiological studies, OSA affects 4% of men and 2% of women (Haskell et al., 2009). It is more common in American children than in Europeans, at approximately 1.2% and 0.7%, respectively, and more common in Afro-Caribbean than other racial groups. Additionally, OSA is more common in middle age (Bixler et al., 2009).

The signs and symptoms associated with OSA involve nocturnal drooling, Xerostomia, snoring, apnoea, restless sleep, lack of dreams, choking or gasping and Nocturia. The daytime signs and symptoms include morning headaches, excessive sleepiness, impaired concentration, depression, decreased libido and irritability (Goodday et al., 2001, Magliocca and Helman, 2005).

OSA can be diagnosed based on the history obtained from the patient and/or sleeping partner, ear, nose and throat (ENT) examination or overnight (polysomnography) sleep assessment to measure and trace the heart, brain and respiratory activity, oral and nasal airflow and sounds and body position (Magliocca and Helman, 2005). Treatment for OSA may include conservative treatment, especially weight loss and behavioural therapy to reduce risk factors like smoking or alcohol, sleeping pills and other sedatives. In addition, as part of the conservative treatment, a pharmacological option could be considered. However, according to Scottish Intercollegiate Guidelines Network (SIGN), pharmacological therapy should not be used as first line therapy for OSA/hypopnoea syndrome (OSAHS); (SIGN, 2003).

Other treatment options involve surgery to widen the nasopharynx, including septoplasty, turbinate surgery, tonsillectomy, Uvulo-Palato-Pharyngo-Plasty (UPPP or UP3), soft palate implants and tongue advancement. These techniques have a low success rate, however, because they only act at one level of airway obstruction (Mehra et al., 2001). Another surgical option may include mandibular advancement or maxilla-mandibular advancement with clockwise rotation (Mehra et al., 2001, Prinsell, 2000). Continuous positive airway pressure (CPAP) is considered the gold standard therapy for moderate to severe OSAHS according to the SIGN guidelines (de Souza Carvalho et al., 2012a, SIGN, 2003).

The use of a mandibular advancement device (MAD), which is similar to a functional appliance, is recommended in the SIGN guidelines as an alternative therapy for patients who are unable to tolerate CPAP. However, the Cochrane review by Carvalho et al. (Carvalho et al., 2007) for OSA in children found that at present, there is insufficient evidence to confirm that oral appliances or functional orthopaedic appliances are effective in the treatment of OSA in children. Another recent Cochrane review evaluating randomised trials in adults with OSA found that oral appliances were less effective than nasal CPAP and the use of oral appliances should be restricted to OSA subjects who are unwilling or unable to cope with nasal CPAP (Lim et al., 2006).

CHAPTER 2

AIM OF THE STUDY AND NULL HYPOTHESIS

2. Aim and Null Hypothesis

2.1. Statement of the Study Aim

Most present studies involve measurement of upper airway dimensional changes by analysing the post-treatment effects of RME using 2D cephalometric radiographs (Chung and Font, 2004, Cross and McDonald, 2000, Davidovitch et al., 2005, de Silva Fo et al., 1991, Haas, 1961, Mah and Hatcher, 2004, Timms, 1980, Wertz, 1970), Rhinomanometry (Zweiman et al., 1997) or Acoustic Rhinomanometry (Çakmak et al., 2003, Cole et al., 1997, Corey et al., 1997, Dastidar et al., 1999, Doruk et al., 2007, Gilain et al., 1997, Hilberg et al., 1989, Hilberg and Pedersen, 2000, Numminen et al., 2003, Silkoff et al., 1999, Terheyden et al., 2000, Usumez et al., 2003). However, the complex 3D arrangements of the anatomy of the upper airway spaces means that the effects of RME are difficult to assess accurately using 2D modalities due to the challenge of interpreting the superimposed structures.

Additionally, magnification and landmark identification errors may result in important changes being overlooked, which might cause inherent inaccuracies (Ludlow et al., 2003, Tso et al., 2009). A further problem in the measurement of the effect of RME on the upper airway using 2D modalities has to do with the numerous hard tissues which surround the upper airway; these have variable thicknesses, degrees of ossification and methods of attachment to the adjacent bone.

A further important disadvantage of 2D cephalograms is the lack of information about volumetric changes (Muto et al., 2008, Ravelli et al., 2002).

Studies utilising CBCT techniques to assess the skeletal and dentoalveolar effects and the upper airway changes of RME (Baraldi et al., 2007, Garib et al., 2006, Garib et al., 2005, Timms et al., 1982) have reported a significantly lower radiation dose and greater resolution than for medical CT, a high level of contrast between the hard and soft tissues, reduced cost and wider accessibility (Garrett et al., 2008, Tso et al., 2009, Vig, 1998). A number of studies have used CBCT for assessment of the changes as a valid method of measuring airway volume but most still report using slice data obtained after 3D CBCT scanning to compare the effect of RME (Guijarro-Martínez and Swennen, 2011).

Significant drawbacks of using a CBCT scan to measure the airway volume have not been addressed in previous studies, and include the effect of respiration and tongue position (Abbott et al., 2004), 3D CBCT definition of the anatomical boundaries of the upper airway (Guijarro-Martínez and Swennen, 2011, Guijarro-Martínez and Swennen, 2013), head posture, lordosis (craniocervical inclination) and mandibular morphology. The present study took in consideration these problems. To date, no research has assessed oro-naso-pharyngeal effect of RME collectively, as other studies have excluded nasal cavity analysis (Chang et al., 2013).

2.2. The Aim of the Study

The aim of the study is to assess the validity of the free access software package like ITK Snap in measuring the airways spaces, investigate the 3D effect of RME on the maxillary sinus, lower nasal cavity, nasopharynx and upper oropharynx (retropalatal airway), and to assess the influence of the amount of appliance expansion, intermolar expansion and gender in growing subjects via CBCT scan.

2.3. The Null Hypothesis

The null hypothesis is that “RME has no effect on the volume of the maxillary sinus, lower nasal cavity, nasopharynx and upper oropharynx (retropalatal airway), ITK Snap software is not valid in measuring the airway space volumes”.

CHAPTER 3

MATERIALS AND METHODS

3. Materials and Methods

3.1. Study Design

The overall aim of this study was to investigate and analyse, using CBCT, the upper airway volumetric changes resulting from RME and to correlate the changes to the magnitude of appliance expansion and the increase in intermolar dentoalveolar width.

Ethical approval was obtained from the Local Area Dental Ethics Committee of North Glasgow University Hospitals NHS Trust (Appendix 7.1.).

3.2. Subjects

Patients were recruited from the Orthodontic Department of the Victoria Hospital (Fife, Scotland). General dental practitioners, medical practitioners or hospital specialists referred the patients for treatment. Written consent was obtained from each patient and parent/guardian for participation in the study (Appendix 7.2.).

3.3. Inclusion Criteria

The following were the inclusion criteria for this study:

1. Patients between 10 and 16 years of age;
2. Caucasian;

3. Normal body mass index (BMI);
4. Good oral hygiene;
5. Constricted maxillary arch with unilateral or bilateral posterior crossbite;
6. Fully erupted maxillary permanent canines;
7. No previous tonsillar, nasal, adenoid, head or neck surgery;
8. No craniofacial deformity; and
9. No significant variation in the head and craniocervical orientation between the preoperative and postoperative CBCT scans (<5 degree).

3.4. Exclusion Criteria

The exclusion criteria for this study were as follows:

1. Patients above 16 years of age;
2. Previous or actual periodontal disease;
3. Previous orthodontic treatment; and
4. Lack of reproducibility of head posture (>5 degree).

3.5. Sample Size Calculation

The calculation of the sample size depends on the minimum difference between two groups, the degree or the confidence level used in the

study, the power of the test used in the study and the square root of the variance or the standard deviation (Vanarsdall).

The sample size calculation was based on using average values for two samples representing the volumetric changes before and after RME but within the same subjects. A previous study indicated that the average retropalatal airway volume before RME treatment (T1) was 228.77 mm³ (SD 97.7) and that after RME treatment (T2) was 328.2 mm³ (SD 107.1) (Chang et al., 2013). Sample size was calculated using the Researcher's Toolkit calculator and this indicated that a sample size of 14 patients would produce an Alpha error level or confidence level at 95% and a Beta error level at 20%. Therefore, it was decided to recruit 17 subjects to overcome potential exclusion due to irreproducibility in the head orientation and lordosis.

3.6. Clinical Procedures

3.6.1. Treating clinician

All clinical treatments were undertaken by a single clinician. Full baseline records including study models, CBCT and 3D clinical photographs were taken at Glasgow Dental Hospital and School. A consent form for all procedures was obtained from all participants, and ethical approval was gained for use of the records.

3.6.2. Upper and Lower Dental Impressions

Upper and lower dental impressions of each patient were taken using alginate (xantALGIN® select, Heraeus, Germany) and plaster models were produced (Sherafard-rock, John-Winters, Halifax).

3.6.3. The RME Appliance

The RME appliance was a cast cap fixed split acrylic appliance with an active expansion produced by a Hyrax screw (Forestadent, Germany). The cast cap splint was constructed of a silver-copper alloy (SP70, Skillbond, UK) with full tooth coverage from the first molar to the canines, and occlusal holes to aid removal (Figure 14).

3.6.4. Cementation of the RME

The RME appliance was cemented in situ with glass ionomer cement (AquaCem®, Dentsply, Germany) within 1 week of the impression being taken to ensure an accurate fit.

3.6.5. Activation Regime

The appliance was activated by the parent after the pre-treatment CBCT scan was taken; the patients were followed up regularly during the active expansion phase. The regime used was a quarter turn (0.25

mm) twice a day, that is, once in the morning and once in the evening, both after meals, until the palatal cusps of the upper molars were touching the buccal cusps of the lower molars. None of the subjects received brackets or wires in the maxillary arch until CBCT images were taken at T2.

Figure 13: Alginate used during the study.



Figure 14: The cast cap splint RME constructed of a silver-copper alloy with full tooth coverage from the first molar to the canines



Figure 15: Glass ionomer cement used during the study



3.7. CBCT scan

3.7.1. The CBCT Machine

All CBCT scans were taken at the Glasgow Dental Hospital using an iCAT cone beam CT scanner (Imaging Sciences International, Inc.) by a single trained radiographer. Each patient was positioned by a single experienced consultant orthodontist (Figure 16).

3.7.2. Field of View (FOV)

The field of view (FOV) used was determined for each patient in order to include the supraorbital ridge and upper occlusal plane of individual patients.

3.7.3. CBCT Settings

The patients were scanned at 120 kV (according to DICOM field 0018, 0060 KVP) and 48 mA (according to DICOM field 0018, 1151 X-ray tube current) for 20 seconds with a 0.4 mm voxel resolution.

3.7.4. CBCT Calibration

Scans were performed using a standardised scanning protocol (i-CATTM, Imaging Sciences International, Inc.). In order to ensure the same calibration parameters of the CBCT apparatus, the calibration was automatically checked daily, and verified manually every three months (phantom quality assessment [QA] calibration as recommended by the manufacturer) during the data acquisition period. The reliability and accuracy of CBCT in measuring the air space surrounded by soft tissues were high, and have been validated by previous researchers (Yamashina et al., 2008, Tso et al., 2009, Schendel and Hatcher, 2010, Ogawa et al., 2007, Kim et al., 2010).

For the scan, subjects were asked to remove any spectacles, jewellery and hairpins. Each patient was positioned with the Frankfort plane parallel to the floor and in natural head position (NHP) (Solow and Tallgren, 1971) and the head was stabilised by a headband which prevented unwanted movement during the 20-second scan. Patients were instructed to keep their eyes closed gently during scanning and maintain the teeth in centric occlusion. They were kept immobile

during the image capture, with the tongue in the normal relaxed position.

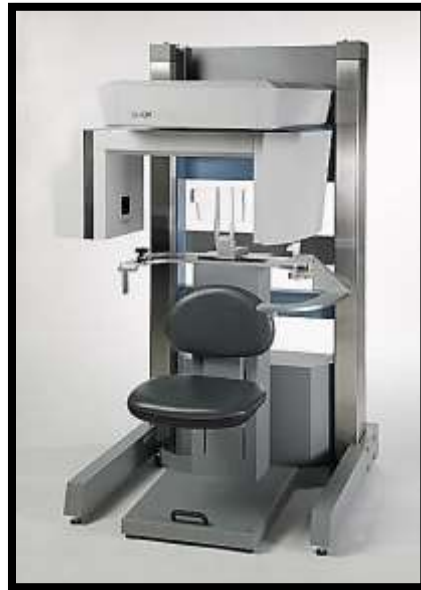

Figure 16: The iCAT CBCT scanner used during the study

3.7.5. Pilot Scan

A pilot scan was taken to ensure the FOV included an area from the supraorbital ridge to the upper occlusal plane. Once the FOV was correct, the full CBCT scan was taken. Two CBCT scans were taken for each patient, that is T1, pre-treatment (prior to RME appliance activation) and T2, immediately after RME expansion. The data files for the CBCT images were stored in DICOM. The 3D CBCT data for each patient was processed using two different types of DICOM Analyzer software.

3.8. Virtual 3D Model Construction

The 3D CBCT data for each patient were constructed using two software programmes. The first was OnDemand3D (Cybermed, Seoul, Republic of Korea) installed on a personal computer (Dell Optiplex 745, Intel Duo Core processor), while the second was ITK-SNAP open source software version 2.2.0 (An interactive image segmentation program; www.itksnap.org), which was installed on the same personal computer.

The first allowed for 2D transverse measurements of the intermolar alveolar crest width and the appliance expansion. Moreover, 3D cephalometric measurements of the head orientation and lordosis (craniocervical inclination) within the T1 and T2 scans were carried out and the radiographs were oriented and superimposed on the anterior and posterior cranial base as a stable structure using the same software package.

The segmentation and volumetric measurements within T1 and T2 scans were achieved using ITK-SNAP (The second analyzer software package used in this study), which stands for Insight Toolkit (ITK), a popular library of image analysis algorithm funded under the Visible Human Project by the U.S. National Library of Medicine (Ibanez et al., 2003). It is available free of charge both as a stand-alone application which can be installed and executed and as a source code that can be used to derive new software.

3.8.1. OnDemand3D analysis

The DICOM slice data for the first scans (T1 scans) produced by the i-CAT machine was imported and displayed using the OnDemand3D software package. Based on the reported validity of 3D cephalometric assessments (Gribel et al., 2010, de Oliveira et al., 2009), the following measurements were recorded in both the pre- and post-RME CBCT scans.

3.8.1.1. Head Orientation Measurements

The pre-RME 3D volumetric model of each patient was viewed using OnDemand3D software package. Landmarks and planes were applied as shown in Tables 1 and 2. Skeletal angular measurements and changes were recorded (Table 3; Figures 17–20). All the measurements were carried out by one examiner. Angular measurements were recorded to the nearest degree.

To avoid bias, these measurements were recorded separately for each set of CBCT scans (T1 and T2). Cases were excluded if there was significant change in head posture and/or lordosis between the T1 and T2 scans of more than +5 degrees (Shelton and Bosma, 1962, Muto et al., 2002, Stepovich, 1965).

Table 1: Points and landmarks

A	The deepest (most posterior) midline point on the curvature between the ANS and prosthion
ANS	The tip of the bony anterior nasal spine at the inferior margin of the piriform aperture, in the mid-sagittal plane' often used to define the anterior end of the palatal plane (nasal floor)
Basion	The most anterior inferior point on the margin of the foramen magnum, in the mid-sagittal plane.
C2sp (or C2od)	The superior–posterior extremity of the odontoid process of the second cervical vertebra
Cg	Most superior point of the crista galli
Cv2ig	Tangent point at the superior and posterior extremity of the odontoid process of the second cervical vertebra.
Cv2ip	The most inferio-posterior point on the body of the

second cervical vertebra.

Cvod The most superior point of the odontoid process of the second cervical vertebra (axis).

LOr The lowest point on the left inferior orbital margin.

Lpo The most superior point of the outline of the left external auditory meatus (anatomic porion).

LtLtPtg The most posterior point of the left lateral pterygoid plate as viewed from the coronal section.

Lzyg The most lateral point in the left frontozygomatic suture.

Molar alveolar crest (MAC) The point where the buccal alveolar crest intersects with buccal cusp of the maxillary first molar.

N The junction of the nasal and frontal bones at the most posterior point on the curvature of the nose.

PNS The most posterior point on the bony hard palate on the mid-sagittal plane.

ROr The lowest point on the right inferior orbital margin.

RtLtPtg The most posterior point of the right lateral pterygoid plate as viewed from the coronal section.

Rzyg The most lateral point in the right frontozygomatic suture.

S The centre of the hypophyseal fossa (sella tursica).

So Midpoint of the sella-basion line

Table 2: Lines and planes

AE(R)–AE(L)	AE, the distance of the maximum separation of the acrylic plate of the right and left sides
Cg-Cvod	Line connecting Cg and Cvod
LOr-LPo	Line connecting LOr and LPo
MAC(R)–MAC(L)	Intermolar alveolar crest width
PAL	Line through the Cv2ig and Cv2ip
ROr-LOr	Line connecting ROr with LOr
SN	Line connecting S to N
True horizontal line (THL)	A reference line constructed by drawing a perpendicular to the true vertical
True vertical line (TVL)	A reference line constructed perpendicular to the floor

Table 3: Cephalometric angles

Pitch angle (P angle)	The change in head orientation in the sagittal plane, measured by means of the cranial base inclination angle (SN-THL; Figure 17)
Roll angle (R angle)	The change in head orientation in the frontal plane, and measured by the angle of Lzyg-Rzyg to the THL line (Figure 18)
Yaw angle (Y angle)	The change in head orientation in the mediolateral plane measured by means of R angle (Cg-Cvod-RtLtPtg) and L angle (Cg-Cvod-LtLtPtg) angle (Figure 19)
Lordosis angle (L angle)	The antero-posterior craniocervical inclination, measured by the angle SN-PAL (Figure 20)

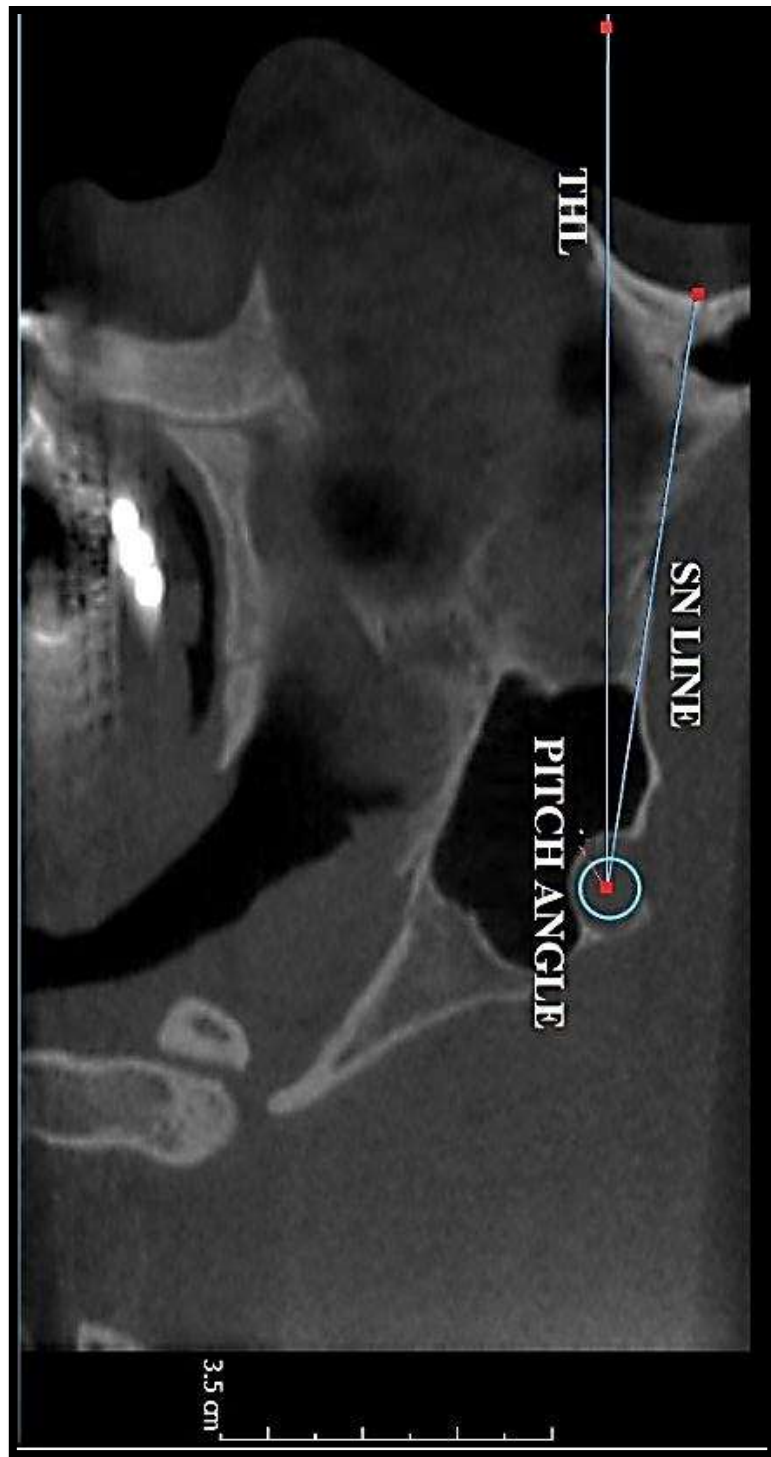


Figure 17: P angle

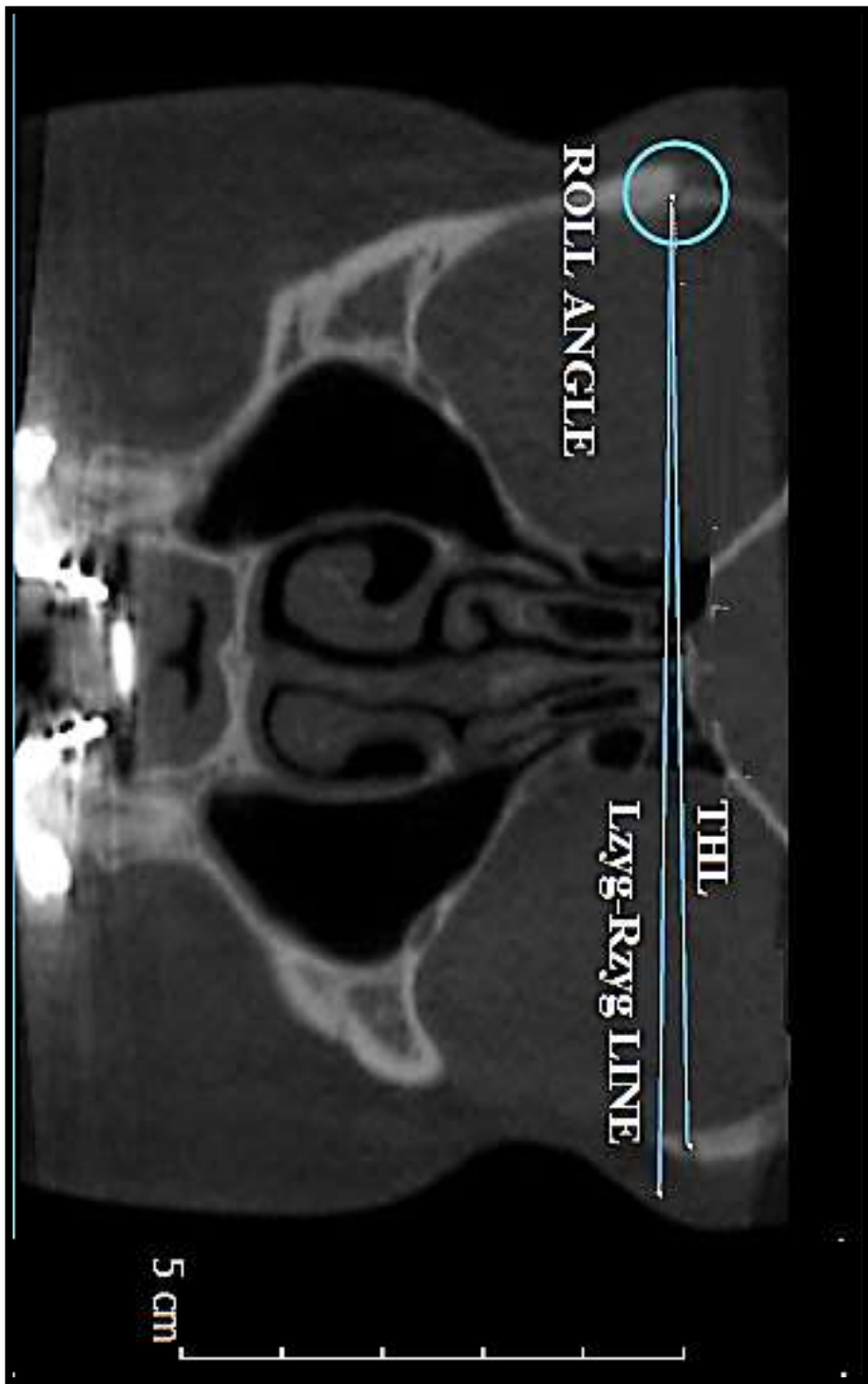


Figure 18: R angle

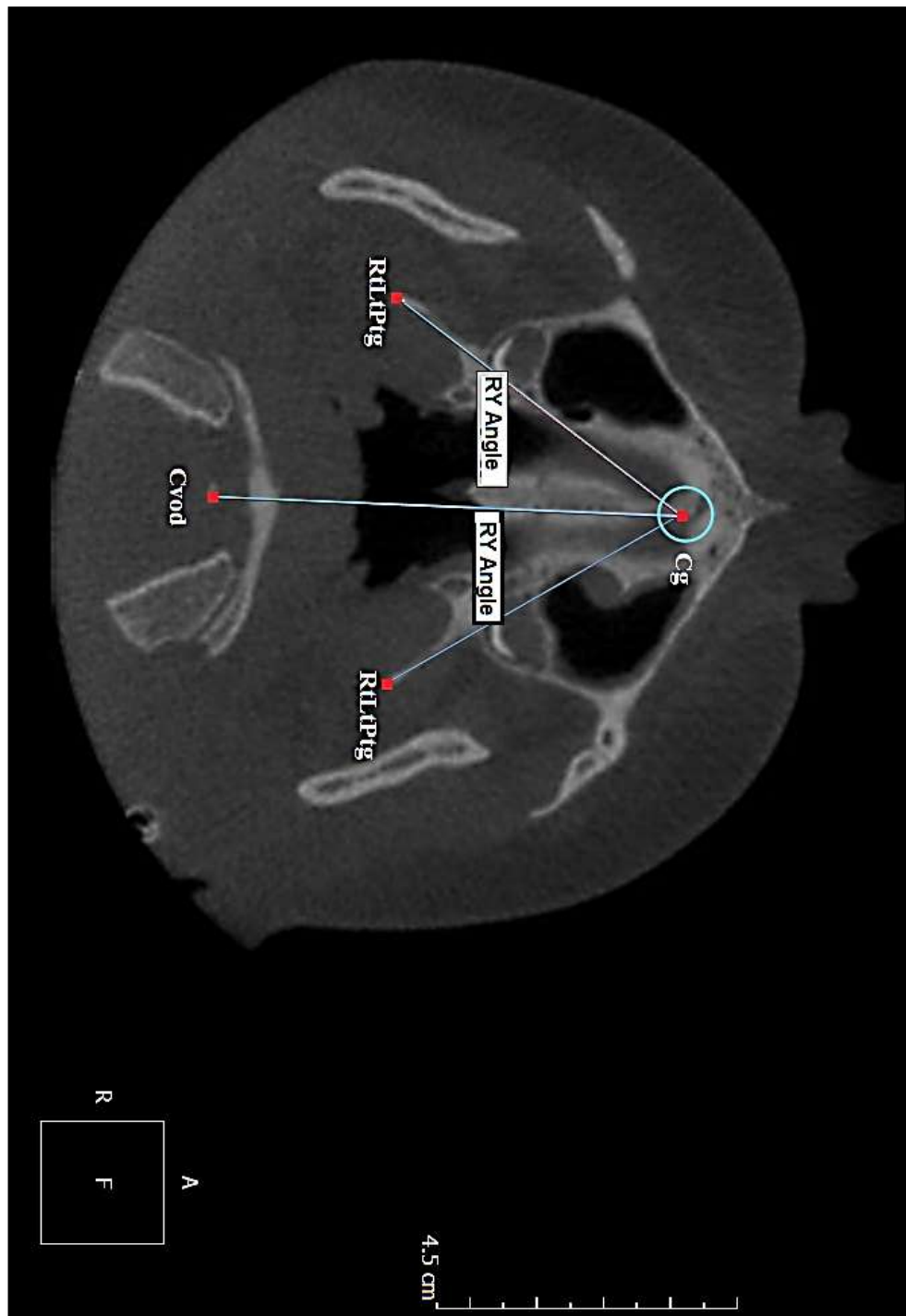


Figure 19: Y angle

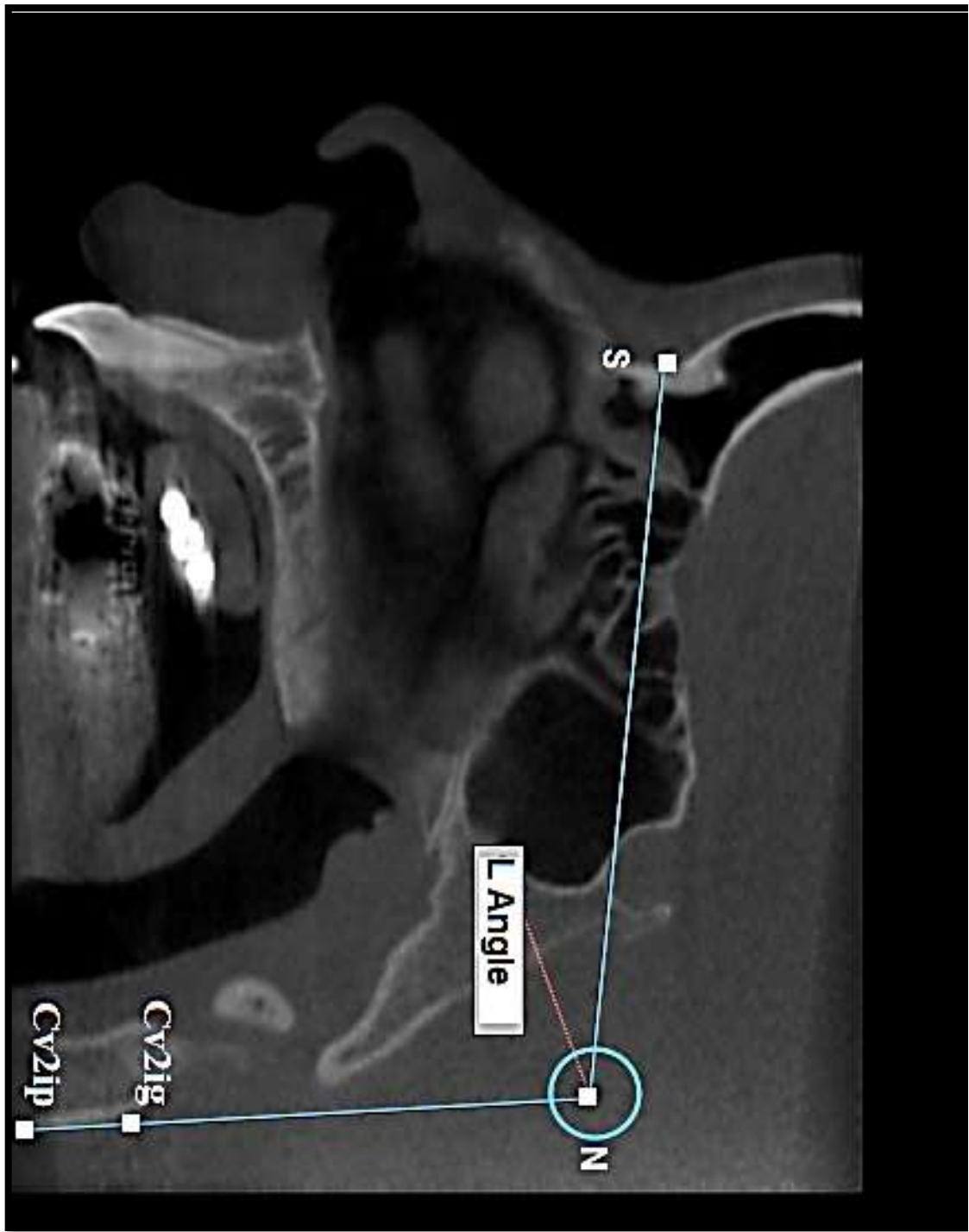


Figure 20: L angle

3.8.1.2. Virtual Head Reorientation and Superimposition

Using the ‘Axis and Reslice’ command of the OnDemand3D software, the T1 scans were oriented using the standardised guidelines according to specific landmarks and lines, as shown in Tables 1 and 2 and Figures 21 and 22.

In the frontal view, with the grid option active, the scans were oriented so that the right and left infra-orbital skeletal landmarks (ROr-LOr) were at the same level, parallel to the THL. In the left sagittal view, with the grid option being active, LOr and Lpo were placed at the same line parallel to the THL. For standardisation, the right sagittal view was not considered to avoid orientation problems related to asymmetrically positioned porions. Segmentation of the nasal cavity was therefore assessed from the anatomy of the LOr.

In the transverse view, the scan was oriented so that the crista galli and Cvod were at the same level; it was ensured that Yaw rotation (transversal rotation) of the zygomatic arches was avoided. The newly oriented T1 scans were saved in a separate file (T1 new). Next, the two scans (the oriented T1 and the original T2) were digitally fused using the auto-registration option on the anterior and posterior cranial base (stable structure). The newly oriented T2 scans were ‘Resliced’ and saved in a new file (T2 new). This process took approximately 15 minutes. The 3D images of the skulls were observed from different viewpoints.

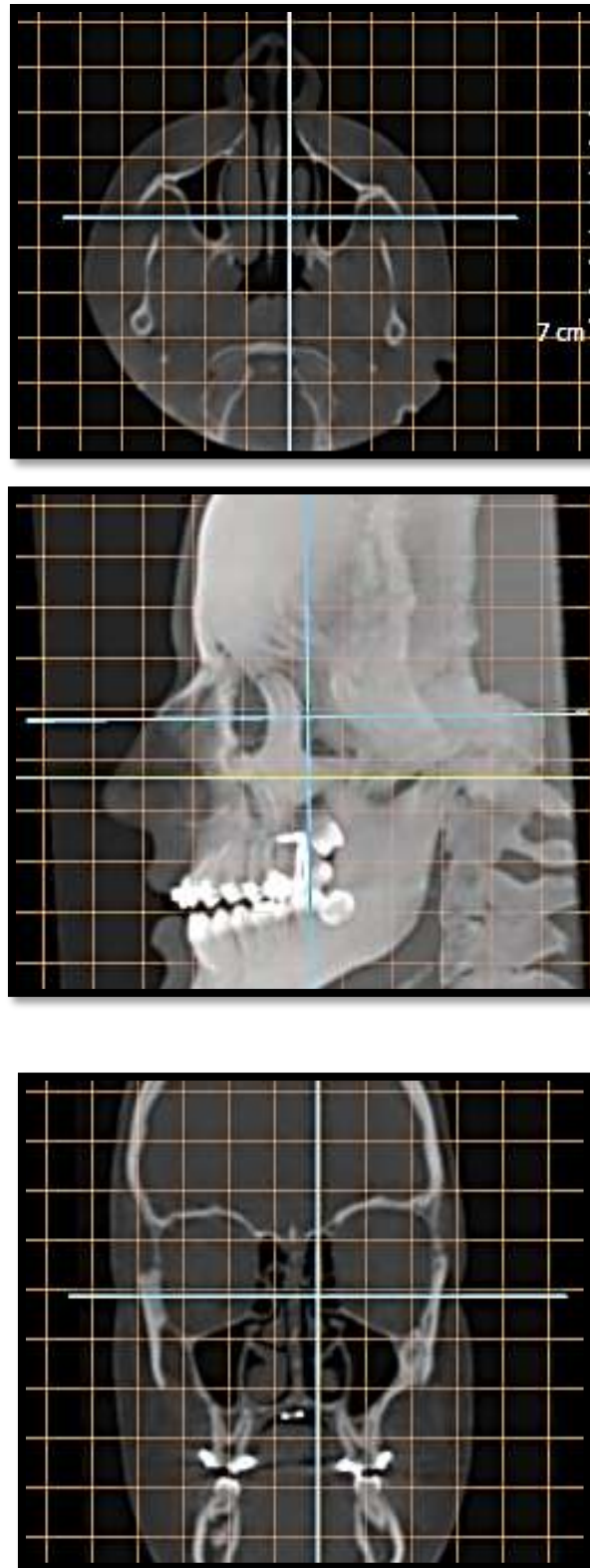


Figure 21: The standardised orientation technique

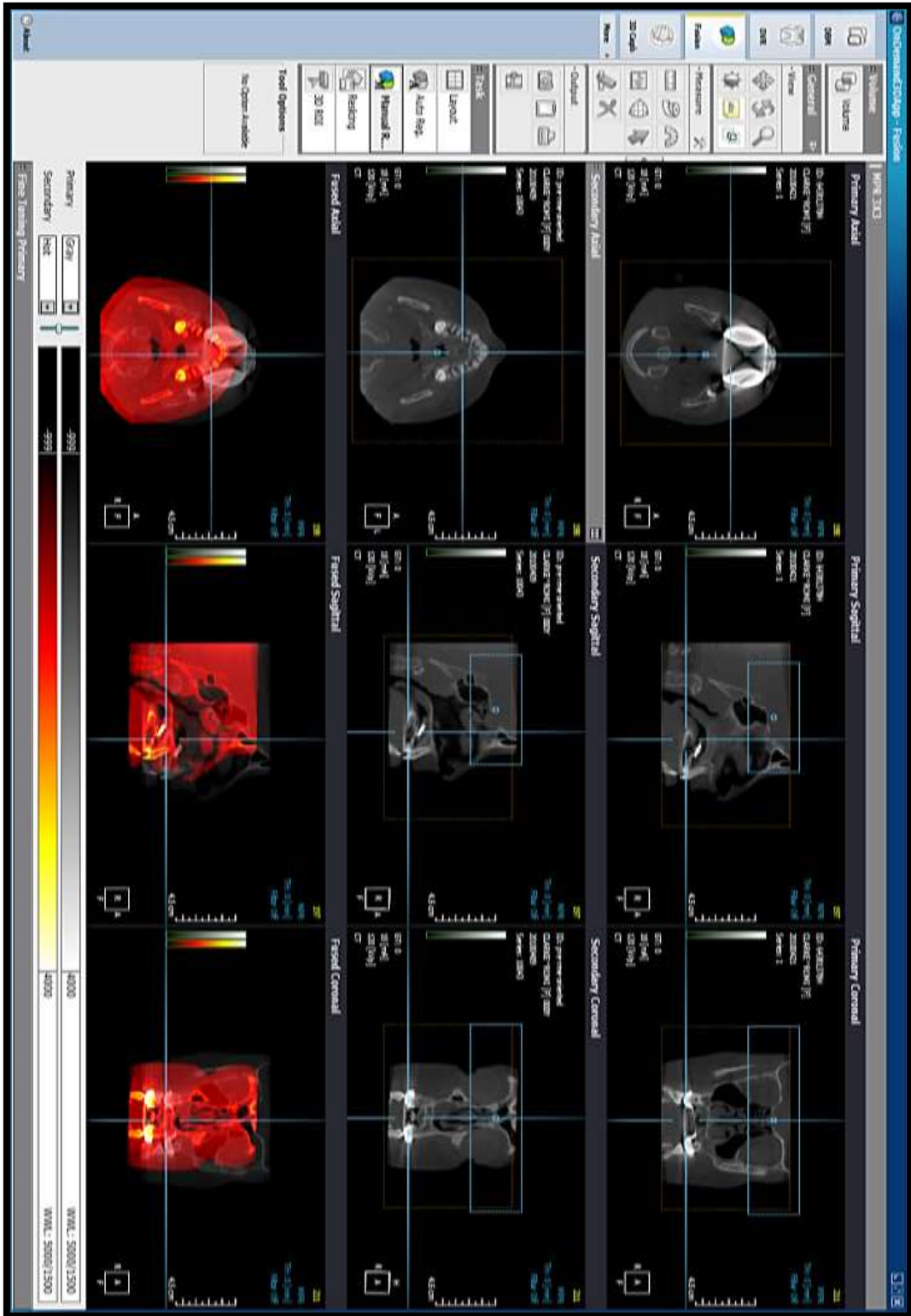


Figure 22: Superimposition on the cranial base

3.8.1.3. Skeletal Linear Measurements on the Reconstructed 3D Skull

A cross-sectional coronal slice was produced via OnDemand3D. Landmarks were placed on the coronal slice at the level of the mesiobuccal groove of the first molars and the following transverse measurements were recorded: intermolar dentoalveolar crest (IMD) width and appliance expansion (AE) (Figure 23; Tables 1 and 2).

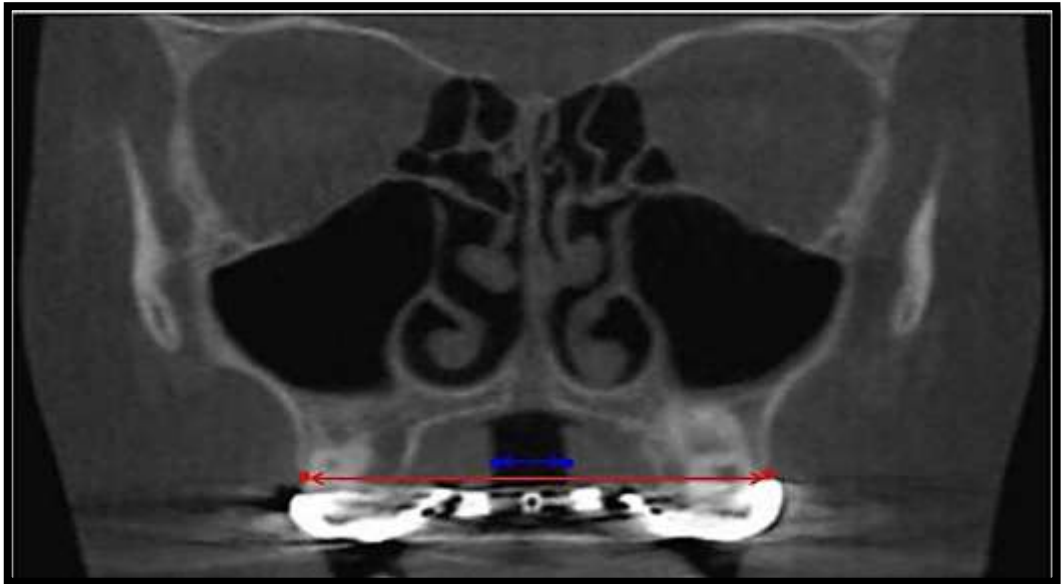


Figure 23: Diagram showing a coronal slice post RME: the red line represents AE; the blue line represents IMD width

3.8.2. The ITK-SNAP Software

The new DICOM slice data (T1 new and T2 new) were imported and displayed using ITK-SNAP version 2.2.0

3.8.2.1. Nasal and Pharyngeal Airway and Maxillary Sinus Segmentation

Segmentation was performed according to each software manufacturer's recommendations (Yushkevich et al., 2006). A standardised segmentation protocol was considered in this study.

3.8.2.1.1.1. Threshold Selection

A test of the threshold was performed by measuring the known volume of a hollow polymer-rubber phantom. The phantom was filled with water and the volume was calculated by converting mL to mm³ (ratio of 1:1). The structure was scanned by the i-Cat machine. The threshold was adjusted until the initial structure segmentation volume reached the actual physical volume of the polymer (-450 grey levels).

3.8.2.1.1.2. *Intensity Region Filtration*

Intensity region filtration was set for all patients with maximum edge smoothness for standardisation purposes. When a fixed threshold is chosen, all voxels with grey levels inside that interval are automatically selected to construct the 3D model in the form of ‘snake’ segmentation. *Snake* is a term used to describe the expanding 3D graphical object for the determination of the volume of interest, which in this study was the volume of the airway spaces. Its parameters had the following settings:

- Balloon force (the ability of the boundary to expand proportionally to the pre-processed image intensity) set at level 3; and
- Curvature force (which is a feature to make the boundary smoother and help in preventing leaks at corners and narrow spaces) was set at level 0.1 to include all narrow spaces between the conchae.

As a result of the complexity of the nasal cavity and its anatomical communications, segmentation was completed manually at the area of maxillary sinus hiatus.

3.8.2.1.2. Airway Spaces

Repeated measurements taken 1 week apart were taken to assess the reproducibility of the landmarks used for segmentation and the boundaries of the airway spaces (Figure 24; Tables 1-5).

3.8.2.1.3. Rendering and Measuring the Volumes

A 3D volumetric evaluation of the spaces was achieved using automatic and manual segmentation, as previously explained. Segmentation of the oro-naso-pharyngeal spaces into multiple segments allows a detailed localisation of the changes and aids in exclusion of any potential masking change of one airway space on adjacent or remote airway space as each segment is associated anatomically and physiologically to different function and/or disorder. The volume of these models was measured using the 'Volume and Statistics' command in ITK-SNAP and exported to a separate datasheet for statistical analysis (Figures 25 and 26).

Table 4: Volumes of interest and their boundaries

<i>Volume of interest</i>	<i>Boundaries</i>
Lower nasal cavity LNC (respiratory region of the nasal cavity)	<p>Anteriorly, bounded by a perpendicular plane to the true horizontal passing through point N (ANSV plane), as shown from the lateral view.</p> <p>If the mid-palatine split extends to involve the ANS, then the most posterior ANS is considered</p> <p>Posteriorly, bounded by a perpendicular plane to the true horizontal passing through the PNS (PNSV plane). If the mid-palatine split extends to involve the PNS, then the most posterior end of the palate is considered. This is a modified plane of that used in Lenza et al.'s study (Lenza et al., 2010), which was PNS-midpoint of the sella-basion line (So).</p> <p>Superiorly, limited to the respiratory space of the nasal cavity, to avoid inclusion of the paranasal sinuses and their related hiatus. The space was defined superiorly by a true horizontal plane</p>

tangent to LOr (LOrH plane)

Inferiorly, bounded by the nasal surface of the palatine process of the maxilla anteriorly and the palatine bone posteriorly (PPH)

Medially, bounded by the nasal septum (consisting of the septal cartilage anteriorly, the perpendicular plate of the ethmoid bone postero-superiorly, vomer postero-inferiorly and the nasal crest, which is part of the maxillary and palatine bones forming the base of the nasal septum)

Laterally, bounded by the nasal surface of the maxillary, nasal and palatine bones, as well as the bones of the inferior nasal conchae (part of the frontal bone), the perpendicular plate of the palatine bone and the nasal surface of nasal cartilages.

Right and left

The whole of the sinus cavities were included up

maxillary sinus (RMS and LMS) to the LOrH plane superiorly and their minimum constricted opening with the adjacent nasal and paranasal cavities.

Upper nasopharynx (UNP) Anteriorly, bounded by the perpendicular to true horizontal passing through the PNS

Posteriorly, bounded by the soft tissue contour of the pharyngeal wall. Manually, it is defined by the frontal plane perpendicular to the Frankfort Horizontal (FH) passing through C2sp (called C2sp VP)

Superiorly, bounded by the soft tissue contour of the pharyngeal wall. Technically defined by the LOrH plane

Inferiorly, bounded by the plane parallel to the FH passing through the PNS and extended to the posterior wall of the pharynx. This is called the PNSH plane

Medio-laterally, bounded by the soft tissue contour of the pharyngeal lateral walls. This was

defined by the sagittal plane perpendicular to the FH passing through the lateral walls of the maxillary sinus.

Boundaries of upper oropharynx (velopharynx or retropalatal space) Anteriorly, bounded by the perpendicular to the true horizontal passing through PNS
Posteriorly, bounded by C2sp VP
Superiorly, bounded by the PNSH plane
Inferiorly, bounded by the plane parallel to the FH plane passing through the most posterior point of the middle of the soft palate (Sp ip; (Chang et al., 2013).

The retropalatal space is subdivided into upper URP) and lower (LRP) parts by the line parallel to the FH plane passing through C2od (C2sp). This is called C2sp VP. If C2od is located superior to this segment, then the whole segment is considered the lower retropalatal space and vice versa

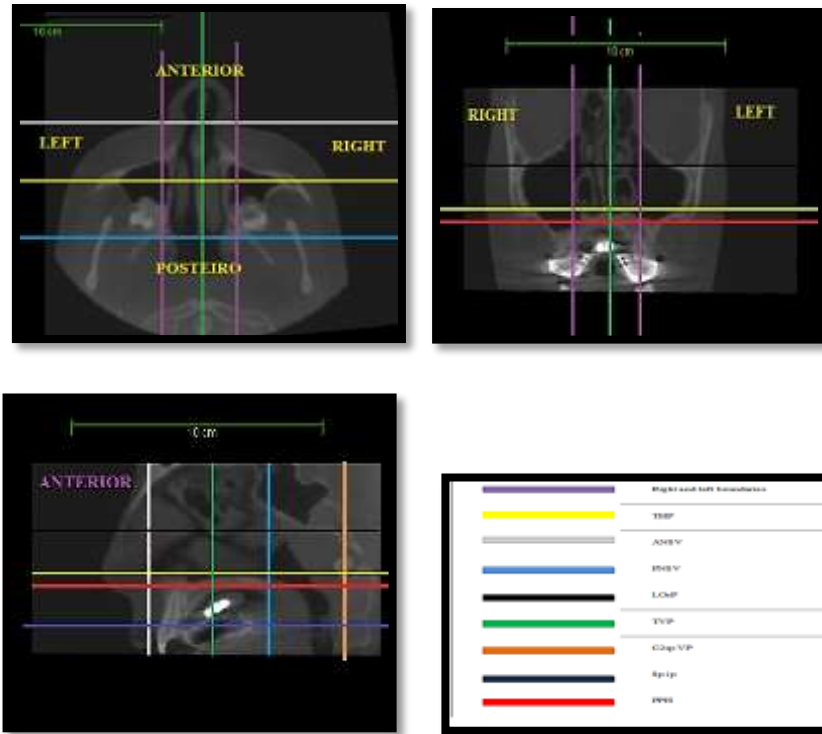


Figure 24: Volumes of interest and their boundaries

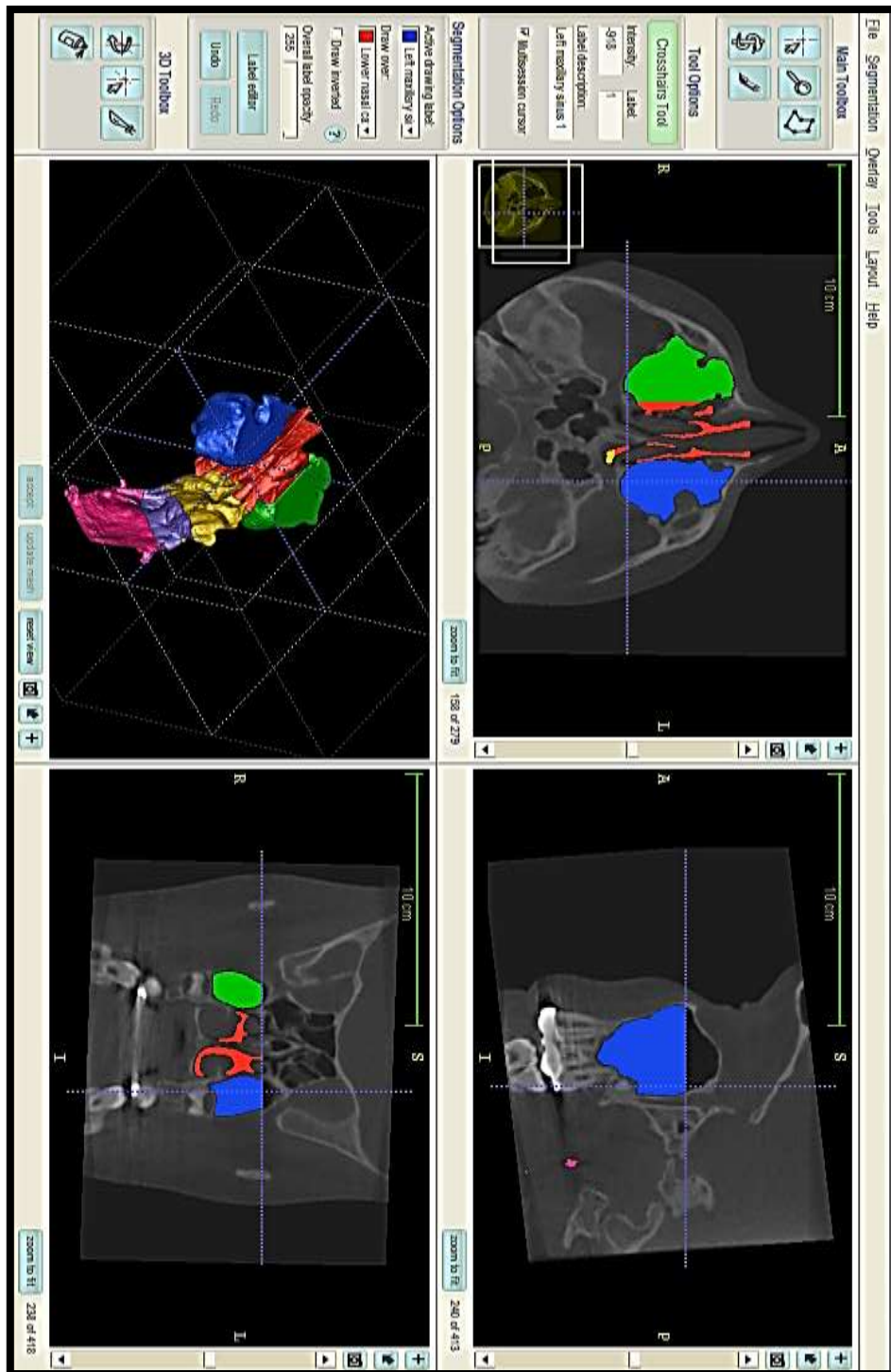


Figure 25: Segmentation procedure using ITK-SNAP

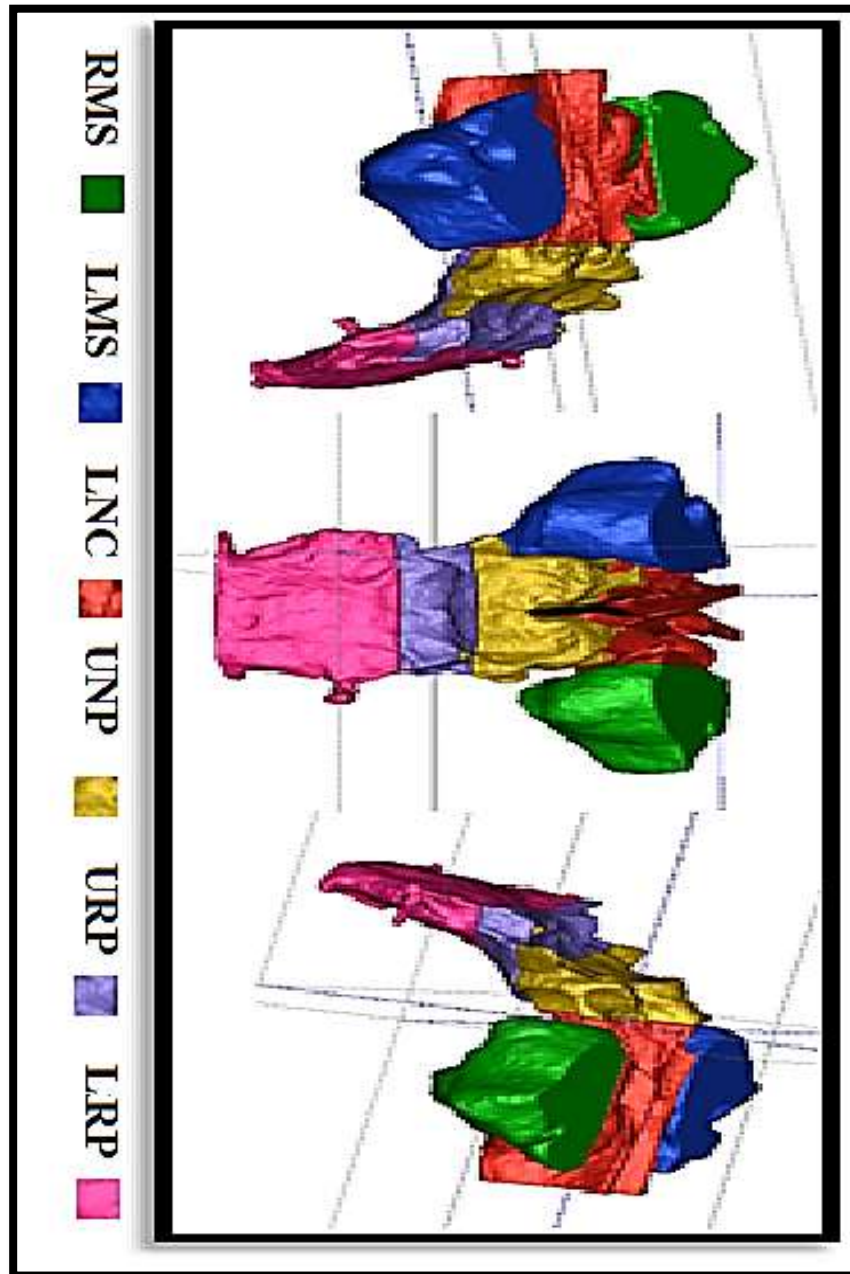


Figure 26: Three-dimensional visualisation of nasal, paranasal and oropharyngeal cavities and spaces

3.9. Statistical Analysis

The statistical analyses were carried out using SPSS (Version 13; SPSS, Chicago, IL, USA). All measurements were performed by the researcher (MA), who was trained to identify 3D landmarks on the axial, sagittal and coronal planes.

A descriptive analysis was carried out to obtain preliminary normative data for the whole sample and for each gender separately. The normal distribution of the sample was assessed using the Kolmogorov–Smirnov test, which showed normality of distribution for most of the parameters. A Student t-test ($P < 0.05$) was applied to determine gender differences and to compare the linear changes in the maxillary width and the expansion appliance, as well as to evaluate the significance of the volumetric changes in the nasopharyngeal spaces produced by RME.

Pearson correlation coefficients were applied to assess the correlation between gender, volumetric changes in the nasopharyngeal space, degree of expansion separation and the linear dentoalveolar expansion as a result of RME.

3.10. Error of the Study

The validity and reproducibility of the head orientation and volumetric measurements were assessed. All the measurements were repeated 1 week later by the same examiner (MA). The data were used to determine

intra-examiner systemic and random error following Houston (Houston, 1983).

Systemic error was assessed by paired t-tests; the random error of measurement was assessed using the intra-class correlation coefficient. The degree of reproducibility was assessed by Dahlberg coefficients of reliability (Dahlberg). The Friedman test was applied to stratify the changes in the two genders (Houston, 1983).

CHAPTER 4

RESULTS

4. Results

4.1. Sample Characteristics

For this study, the records of 17 subjects (9 females and 8 males) were obtained. One subject (subject number 9) was excluded because the head orientation and lordosis difference between T1 and T2 were more than 5 degrees. The mean ages for the subjects were 12.4 and 12.8 years for males and females respectively (Table 6; Figure 27).

The mean interval between T1 and T2 was 23 days (range, 12–56 days), and the mean for the active expansion was 14 days (range, 12–21 days).

Table 5: Gender distribution

Gender	Number	Mean age (years)	Range (years)
Male	8	12.4	10.5 to 14.08
Female	8	12.8	10 to 16.25




Figure 27: T1-T2 head orientation and lordosis

4.2. Descriptive Analysis

Descriptive analyses showing the spread of data (mean, median, SD, maximum and minimum) are presented in Figures 28–39 and Tables 6–13. There was no statistically significant difference between the genders ($P=0.75$) regarding head orientation and lordosis.

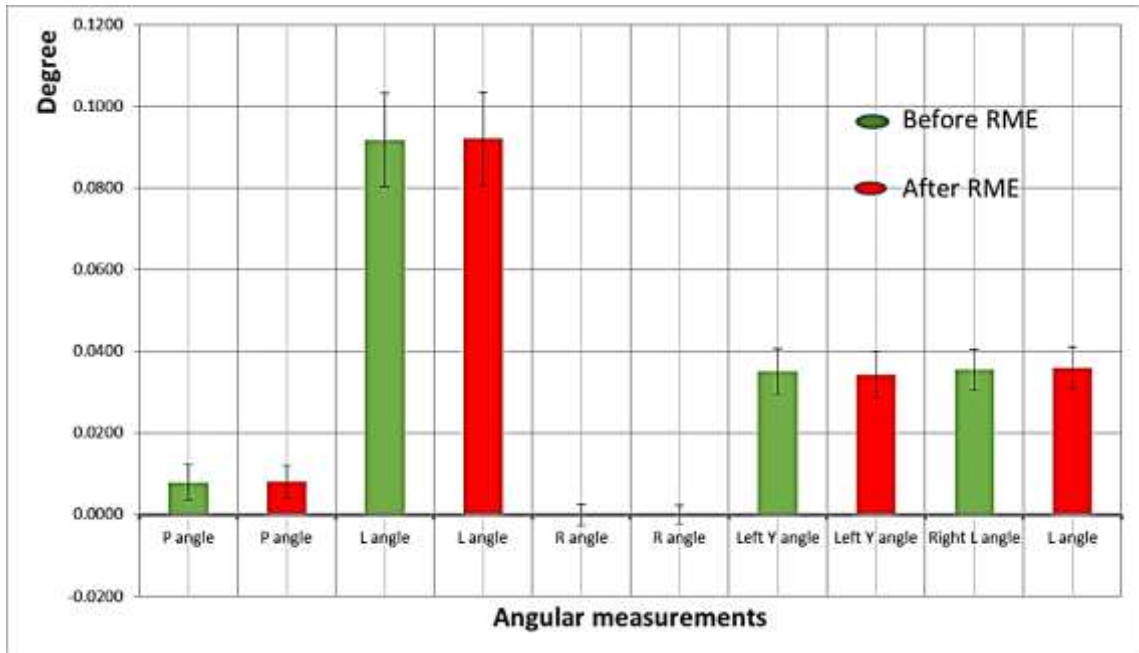


Figure 28: Descriptive analysis for the orientation measurements before and after RME for both genders at W1

P angle=Pitch angle (SN-THL), **R angle**=Roll angle (Lzyg-Rzyg to the THL line), **Y angle**=Yaw angle (Cg-Cvod-LtLtPtg), **L angle**=Lordosis angle (the antero-posterior craniocervical inclination, measured by the angle SN-PAL).

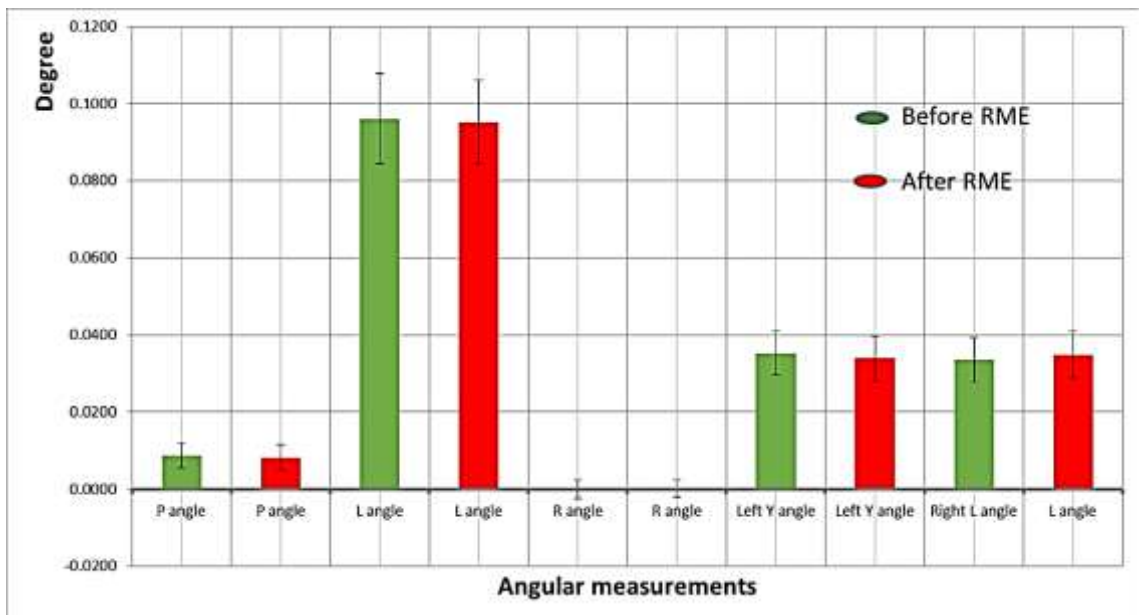


Figure 29: Descriptive analysis for the orientation measurements before and after RME for males at W1

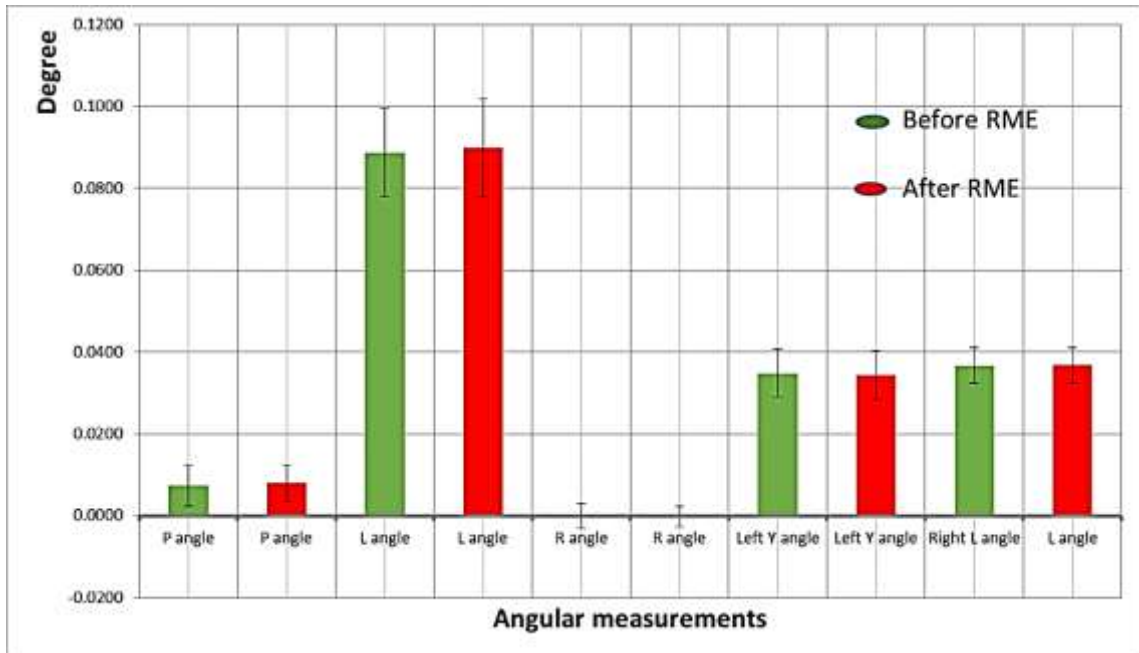


Figure 30: Descriptive analysis for the orientation measurements before and after RME for females at W1

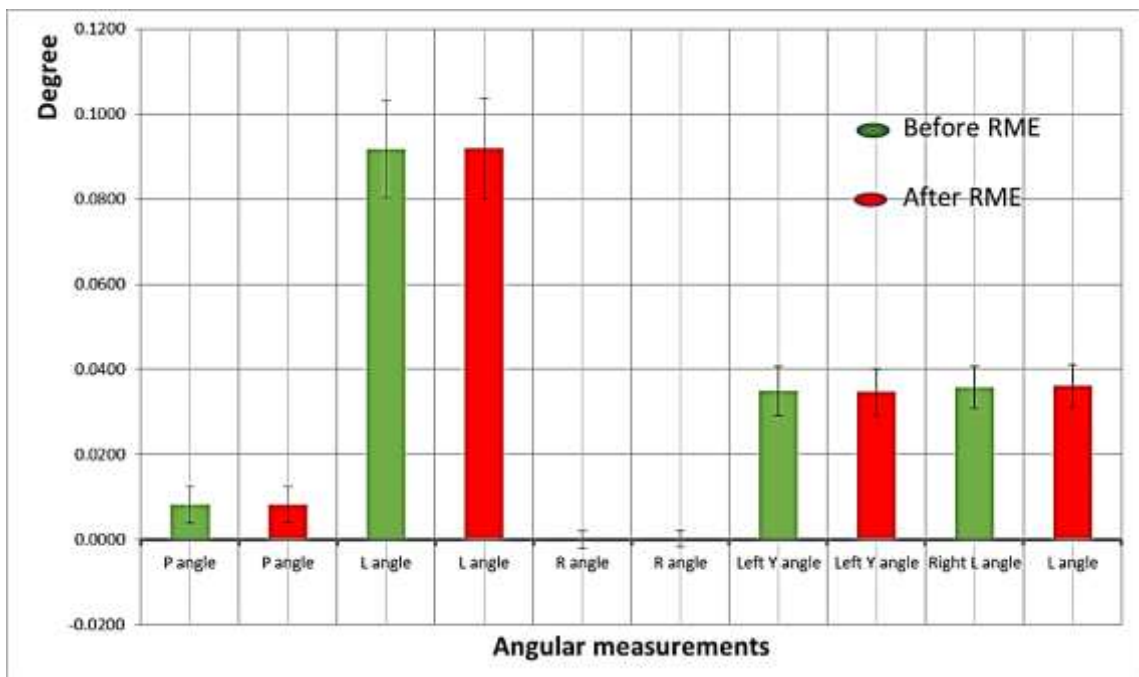


Figure 31: Descriptive analysis for the orientation measurements before and after RME for both genders at W2

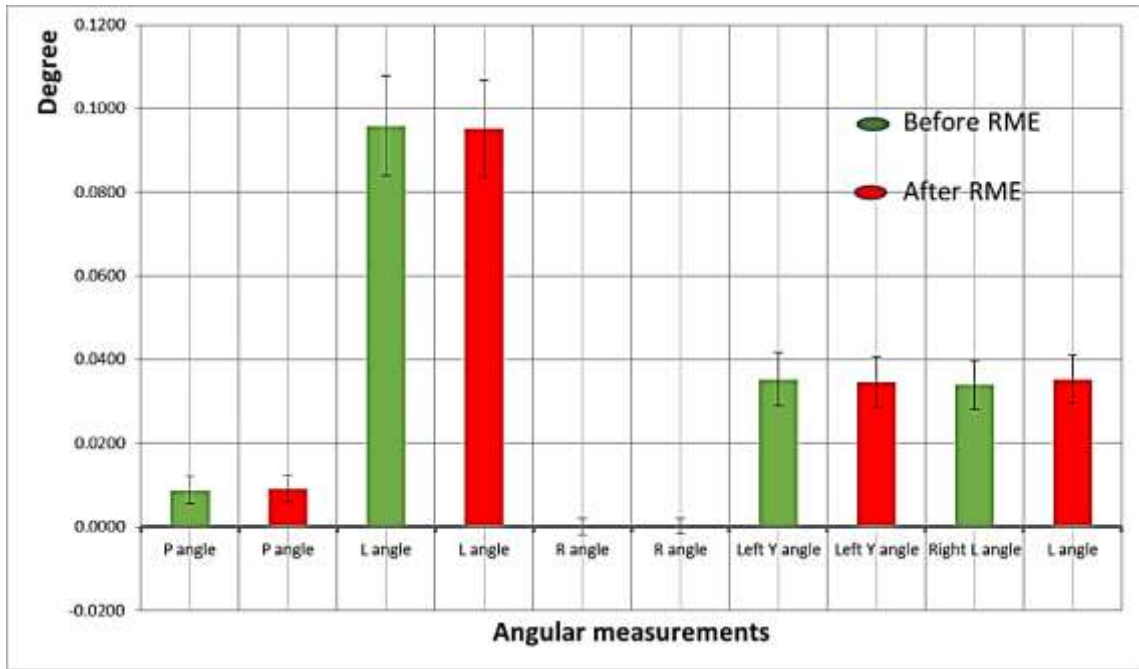


Figure 32: Descriptive analysis for the orientation measurements before and after RME for male at W2

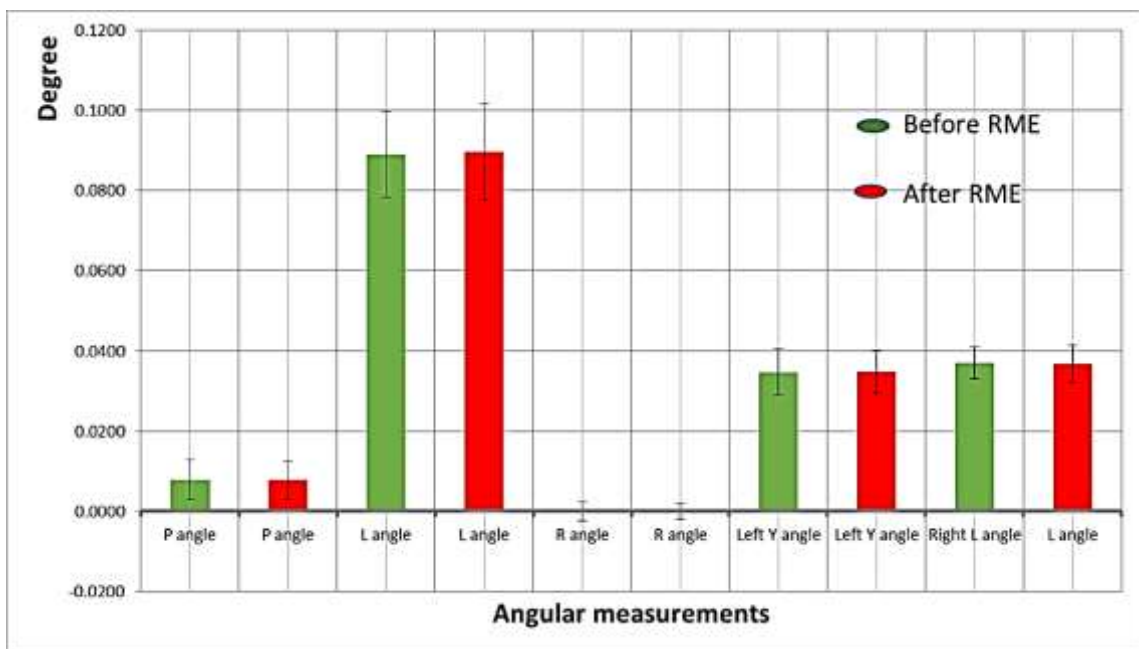


Figure 33: Descriptive analysis for the orientation measurements before and after RME for female at W2

Table 6: Descriptive analysis for the IMD and AE measurements at W1

	T1		T2	
	IMD	AE	IMD	AE
For both genders				
Mean	50.62	0.35	53.94	4.66
Median	49.27	0.32	53.63	4.64
SD	4.45	0.32	4.29	1.44
Maximum	61.06	1.24	61.96	8.90
Minimum	44.50	0.00	46.90	2.90
For males				
Mean	52.60	0.56	56.27	5.32
Median	52.82	0.51	56.64	5.03
SD	5.26	0.35	4.23	1.74
Maximum	61.06	1.24	61.96	8.90
Minimum	45.22	0.15	49.75	3.45
For females				
Mean	49.24	0.20	52.30	4.20
Median	49.03	0.18	51.84	4.05
SD	3.42	0.19	3.69	1.05
Maximum	56.00	0.50	59.60	6.29
Minimum	44.50	0.00	46.90	2.90

T1: measurements on the 1st occasion, T2: measurements on the 2nd occasion, IMD: intermolar dentoalveolar expansion, AE=appliance expansion separation, SD: Standard deviation.

Table 7: Descriptive analysis for the IMD and AE measurements at W2

	T1		T2	
	IMD	AE	IMD	AE
For both genders				
Mean	50.68	0.37	53.85	4.68
Median	50.00	0.30	53.70	4.60
SD	4.45	0.30	4.30	1.49
Maximum	61.20	1.25	62.10	9.00
Minimum	44.65	0.10	47.00	2.85
For males				
Mean	43.42	0.58	56.30	5.32
Median	52.61	0.50	56.70	4.98
SD	22.03	0.41	4.27	1.77
Maximum	61.20	1.25	62.10	9.00
Minimum	5.32	0.18	49.80	3.42
For females				
Mean	0.23	52.13	4.23	0.23
Median	0.19	51.90	4.10	0.19
SD	0.13	3.58	1.14	0.13
Maximum	0.46	58.50	6.50	0.46
Minimum	0.10	47.00	2.85	0.10

T1: measurements on the 1st occasion, T2: measurements on the 2nd occasion, IMD: intermolar dentoalveolar expansion, AE=appliance expansion separation, SD: Standard deviation.

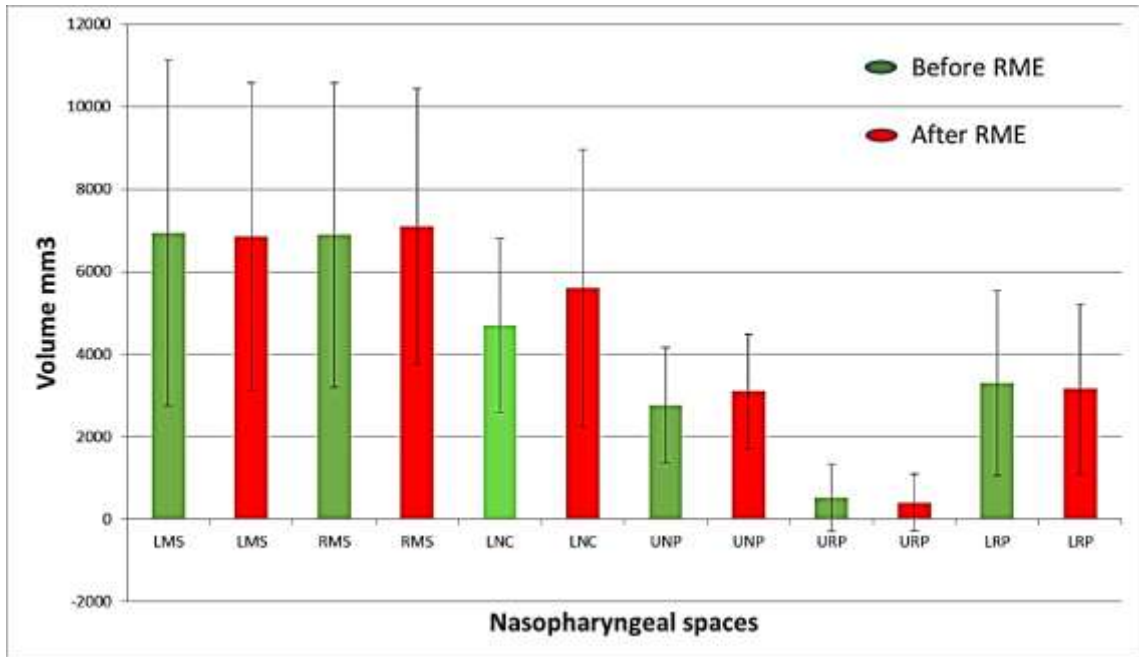


Figure 34: Descriptive analysis for the volumetric measurements, both genders, at W1

LMS=Left Maxillary Sinus, RMS= Right maxillary Sinus, LNC= Lower Nasal Cavity, UNP= Upper Naso-Pharynx, URP= Upper Retro-Palatal, RP= Lower Retro-Palatal, W1=first measurement at first week

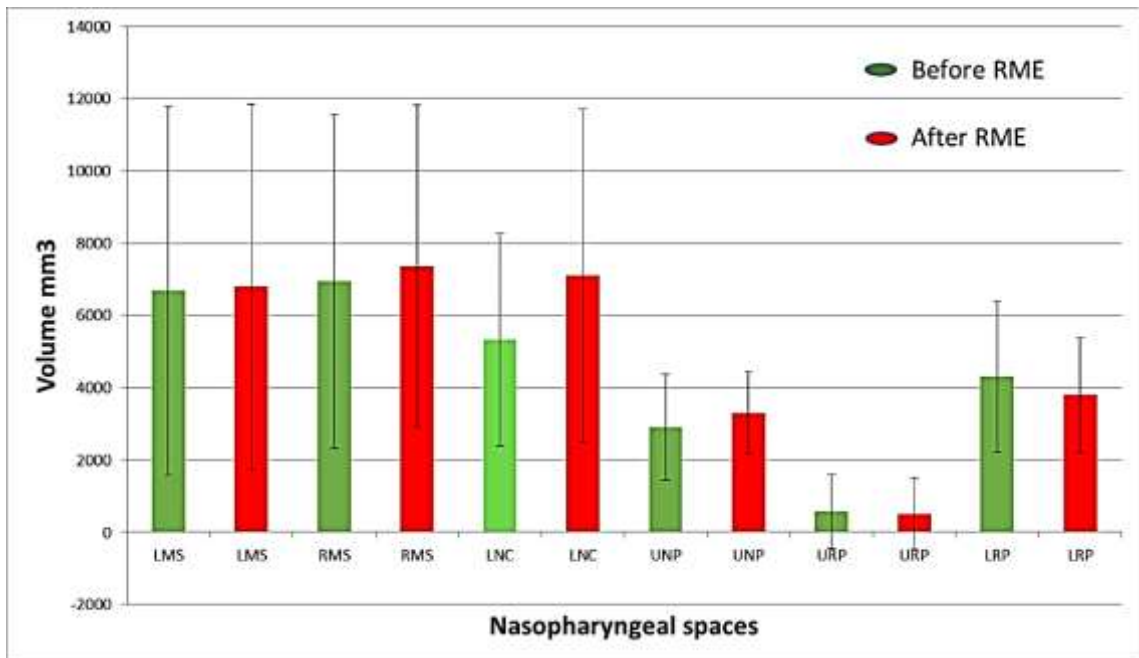


Figure 35: Descriptive analysis for the volumetric measurements, male, at W1

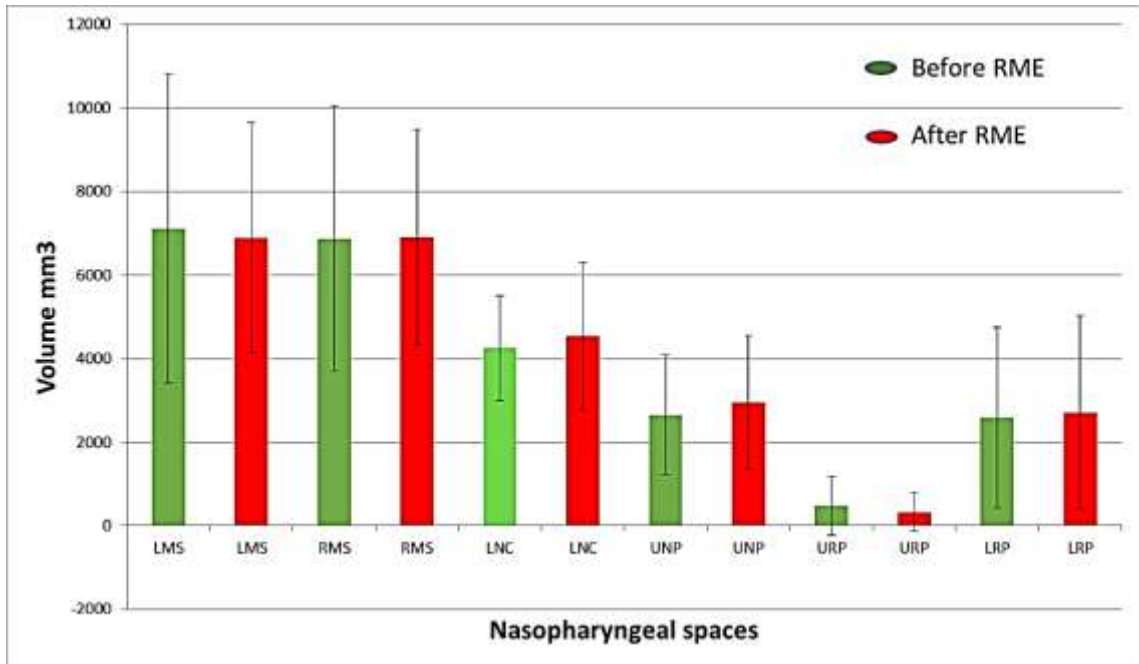


Figure 36: Descriptive analysis for the volumetric measurements, female, at W1

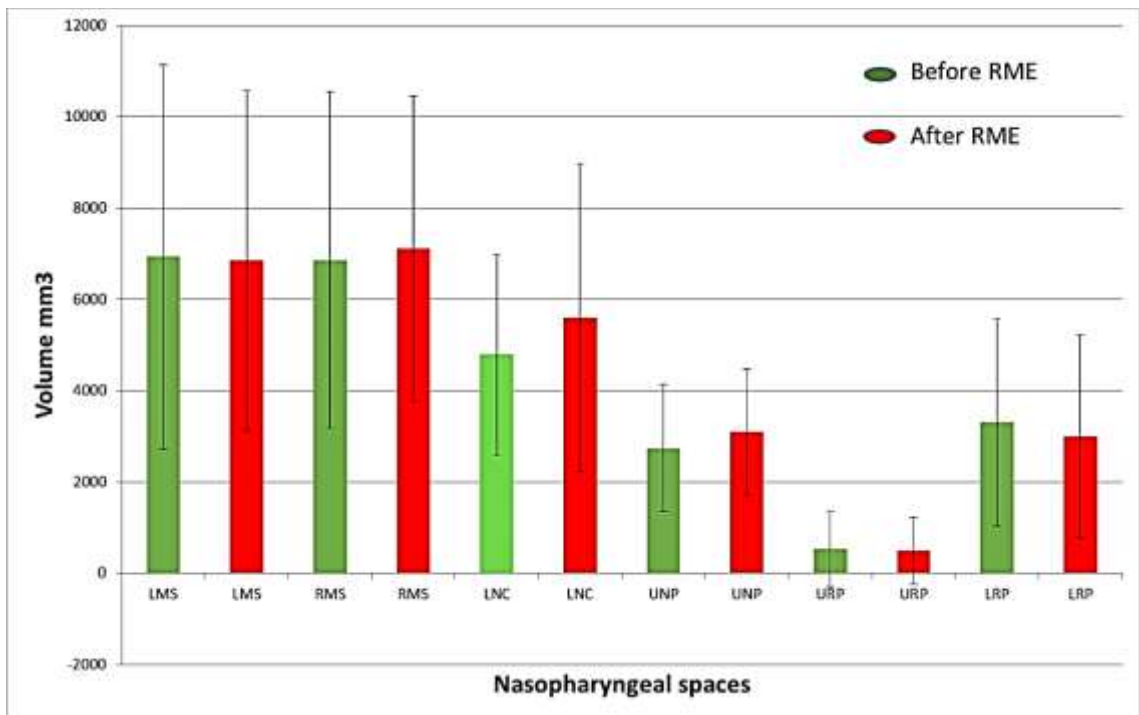


Figure 37: Descriptive analysis for the volumetric measurements, both genders, at W2 (second week)

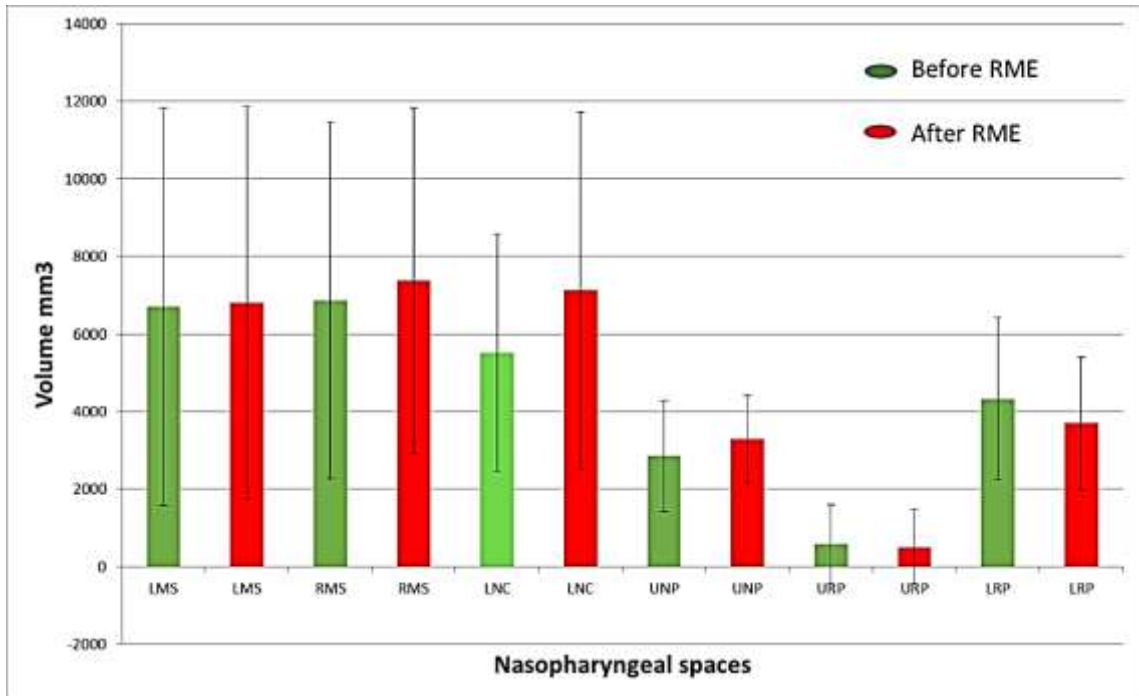


Figure 38: Descriptive analysis for the volumetric measurements, male, at W2

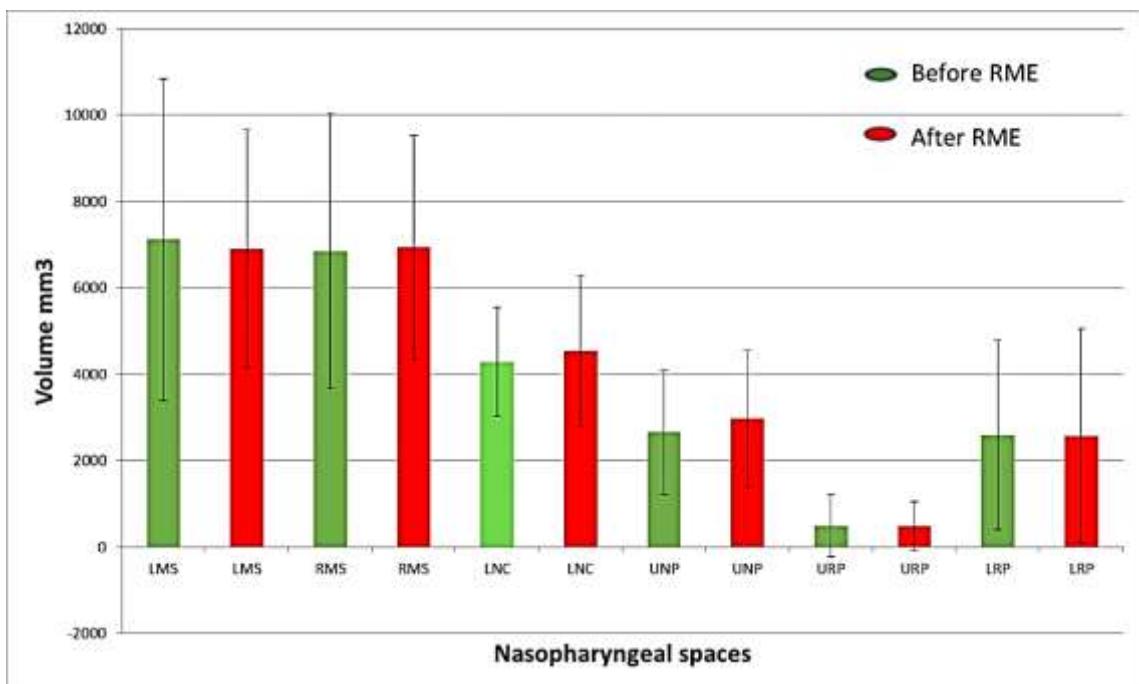


Figure 39: Descriptive analysis for the volumetric measurements, female, at W2

4.3. Errors of the Method

The results of the error of the method are presented in tables 14–17. Student t-test showed that there was no significant difference between the first (W1) and the second (W2) set of measurements ($P>0.05$).

Coefficients of reliability were above 95%. The intra-class correlation coefficient ranged from 0.93 to 1.000 for head orientation and from 0.9724 to 1.000 for volumetric measurements, which confirmed the satisfactory reproducibility of the measurements (Sayinsu et al., 2007).

Friedman test showed that there was no statistical significant difference in head orientation ($P=0.6511$) or volumetric measurements of the airway spaces ($P=0.2355$) between males and females in this study.

Table 8: Reproducibility for orientation measurements for T1 at W1 and W2

Measurements	T1W1		T1W2		T1W1:T1W2		
	Mean	SD	Mean	SD	DET	t-test	ICC
P angle	7.9412	4.40	8.25	4.26	0.28	0.45	0.93
Lordosis	91.78	11.40	91.79	11.42	0.15	0.94	1.00
Y angle	-0.06	2.66	0.01	2.17	0.13	0.69	0.95
RR angle	35.03	5.58	34.94	5.85	0.12	0.62	0.99
LR angle	33.40	5.04	35.73	4.93	0.17	0.23	0.98

T1W1: Pre-treatment measurements on the 1st occasion, T1W2: pre-treatment measurements on the 2nd occasion, SD: Standard deviation, DET: Dahlberg error test, ICC: interclass correlation

Table 9: Reproducibility for orientation measurements for T2 at W1 and W2

Measurement	T2W1		T2W2		T1W1:T1W2		
	Mean	SD	Mean	SD	DET	t-test	ICC
P angle	8.02	4.00	8.30	4.12	0.16	0.24	0.97
Lordosis	92.09	11.48	91.94	11.82	0.14	0.48	1.00
Y angle	0.00	2.30	0.14	1.93	0.12	0.43	0.95
RR angle	34.22	5.73	34.64	5.52	0.16	0.08	0.99
LR angle	35.97	5.04	36.14	4.98	0.17	0.48	0.98

T2W1: post-treatment measurements on the 1st occasion, T2W2: post-treatment measurements on the 2nd occasion, SD: Standard deviation, DET: Dahlberg error test, ICC: interclass correlation

Table 10: Reproducibility for volumetric and linear measurements for T1 at W1 and W2

	T1W1		T1W2		T1W1:T1W2		
	Mean	SD	Mean	SD	DET	t-test	ICC
LMS	6934.30	4189.88	6940.17	4206.67	7.53	0.59	1.00
RMS	6892.74	3694.83	6855.24	3681.14	17.98	0.16	1.00
LNC	4694.67	2108.27	4785.40	2194.93	41.73	0.14	0.99
UNP	2760.78	1409.09	2735.84	1394.70	13.72	0.22	1.00
URP	553.17	836.00	526.61	826.92	5.88	0.48	1.00
LRP	3296.41	2245.86	3304.75	2264.51	6.41	0.37	1.00
IMD	50.63	4.46	50.68	4.45	0.04	0.28	1.00
AE	0.35	0.32	0.37	0.30	0.01	0.32	0.97

T1W1: Pre-treatment measurements on the 1st occasion, T1W2: pre-treatment measurements on the 2nd occasion, SD: Standard deviation, DET: Dahlberg error test, ICC: interclass correlation

Table 11: Reproducibility for volumetric and linear measurements for T2 at W1 and W2

	T1W1		T1W2		T1W1:T1W2		
	Mean	SD	Mean	SD	DET	t-test	ICC
LMS	6849.20	3722.53	6855.12	3727.51	11.40	0.72	1.00
RMS	7095.59	3346.66	7113.25	3347.88	7.61	0.12	1.00
LNC	5596.88	3370.65	5599.76	3373.55	3.98	0.62	1.00
UNP	3098.51	1390.73	3101.38	1373.39	10.19	0.84	1.00
URP	402.02	692.10	491.78	730.62	1.40	0.38	1.00
LRP	3157.98	2059.65	3193.46	2151.04	62.25	0.38	0.99
IMD	53.94	4.29	53.85	4.30	0.07	0.37	1.00
AE	4.66	1.44	4.68	1.49	0.02	0.60	1.00

T2W1: post-treatment measurements on the 1st occasion, T2W2: post-treatment measurements on the 2nd occasion, SD: Standard deviation, DET: Dahlberg error test, ICC: interclass correlation

4.4. Transverse Dentoalveolar Linear Changes

The transverse dentoalveolar changes were measured at the alveolar crest level of the coronal sections of the CBCT scans using OnDemand3D software. On average, there was more dentoalveolar expansion in males than females. The average change of the IMD was 3.7mm for the male group and 2.8mm for the female group; the differences between the two groups were statistically insignificant (Table 18).

4.5. Volumetric Changes in the Nasopharyngeal Space as a Result of RME

The percentage of volumetric changes $[(T2/T1)-1*100]$ of LMS and RMS were limited in all the cases. The LNC volume has increased five folds in males compared to females, with an increase of 29.2% and 6.0%, respectively. However, the mean changes of the LNC volume for the entire sample as a result of RME were not statistically significant. Additionally, UNP has increased significantly with a similar pattern of changes in both genders.

URP was reduced significantly after treatment by 11.2% and 2.8% for the male and the female groups respectively. LRP was reduced as a result of treatment in both genders, the reduction was 20 times greater in

males than females (-14.6% in males and -0.6% in females, Table19-21).

4.6. The correlation between gender, change in the volume of the nasopharyngeal space, degree of appliance expansion and dentoalveolar expansion

There was a clear, direct correlation between the increase of the volume of the right and left maxillary sinuses and between AE and IMD (Pearson correlation coefficient =0.86, 0.75, respectively). A weak correlation was noted among other variables (table 22).

Table 12: Dentoalveolar linear measurements of the 3D volumetric images before and after RME.

VARIABLES	T1		T2		T2-T1	% of changes (T2/T1)-1*100	Paired t-test
	Mean	SD	Mean	SD			
Both genders							
IMD	50.68	4.45	53.85	4.30	3.2	6.2	0.00
AE	0.37	0.30	4.68	1.49	4.3	1064	0.00
Male group							
IMD	52.61	5.32	56.30	4.27	3.7	7.0	0.00
AE	0.57	0.37	5.32	1.77	4.7	724	0.00
Female group							
IMD	49.33	3.38	52.13	3.58	2.8	5.7	0.00
AE	0.23	0.13	4.23	1.14	4.0	1639	0.00

T1: measurements on the 1st occasion, T2: measurements on the 2nd occasion, IMD: intermolar dentoalveolar expansion, AE=appliance expansion separation, SD: Standard deviation.

Table 13: Nasopharyngeal volumetric measurements of the 3D volumetric images before and after RME for both genders

VARIABLES	T1		T2		T2-T1	% of changes (T2/T1)-1*100	Paired t-test
	Mean	SD	Mean	SD			
LMS	6940	4207	6855	3728	-85.1	-1.2	0.82
RMS	6855	3681	7113	3348	258	3.8	0.5
LNC	4785	2195	5600	3374	814.4	17.0	0.06
UNP	2736	1395	3101	1374	365.5	13.4	0.045
URP	527	827	492	731	-34.8	-6.6	0.042
LRP	3305	2265	2994	2226	-311	-9.4	0.27

T1: measurements on the 1st occasion, T2: measurements on the 2nd occasion, IMD: intermolar dentoalveolar expansion, AE=appliance expansion separation, SD: Standard deviation.

Table 14: Nasopharyngeal volumetric measurements of the 3D volumetric images before and after RME for males

VARIABLES	T1		T2		T2-T1	% of changes	Paired t-test
	Mean	SD	Mean	SD			
LMS	6696	5122	6800	5067	104.3	1.6	0.68
RMS	6871	4584	7371	4440	500.0	7.3	0.31
LNC	5512	3065	7123	4596	1611	29.2	0.08
UNP	2856	1439	3290	1111	434.3	15.2	0.11
URP	576	1021	511	971	-64.6	-11.2	0.10
LRP	4325	2099	3693	1701	-632	-14.6	0.13

T1: measurements on the 1st occasion, T2: measurements on the 2nd occasion, IMD: intermolar dentoalveolar expansion, AE=appliance expansion separation, SD: Standard deviation.

Table 15: Nasopharyngeal volumetric measurements of the 3D volumetric images before and after RME for females

VARIABLES	T1		T2		T2-T1	% of changes	Paired t-test
	Mean	SD	Mean	SD			
LMS	7111	3727	6894	2753	-218	-3.1	0.72
RMS	6844	3175	6933	2587	88.6	1.3	0.92
LNC	4277	1266	4533	1755	256.5	6.0	0.51
UNP	2652	1435	2969	1576	317.4	12.0	0.25
URP	492	719	478	565	-14.0	-2.8	0.12
LRP	2590	2191	2574	2476	-16.1	-0.6	0.67

T1: measurements on the 1st occasion, T2: measurements on the 2nd occasion, IMD: intermolar dentoalveolar expansion, AE=appliance expansion separation, SD: Standard deviation.

Table 16: Pearson correlation coefficients for volumetric changes in relation to the nasopharyngeal space, gender, AE and IMD as a result of RME

	Gender	LMS	RMS	LNC	UNP	URP	LRP	IMD	AE
Gender	1.00	-0.11	-0.16	-0.41	-0.08	-0.20	0.45	-0.22	-0.28
LMS	-0.11	1.00	0.86	0.31	0.53	0.74	0.20	-0.06	-0.12
RMS	-0.16	0.86	1.00	0.48	0.39	0.45	0.22	0.20	0.09
LNC	-0.41	0.31	0.48	1.00	0.06	0.19	0.01	0.15	0.41
UNP	-0.08	0.53	0.39	0.06	1.00	0.64	0.28	0.16	-0.14
URP	-0.20	0.74	0.45	0.19	0.64	1.00	0.02	0.08	0.07
LRP	0.45	0.20	0.22	0.01	0.28	0.02	1.00	-0.06	-0.51
IMD	-0.22	-0.06	0.20	0.15	0.16	0.08	-0.06	1.00	0.75
AE	-0.28	-0.12	0.09	0.41	-0.14	0.07	-0.51	0.75	1.00

CHAPTER 5

DISCUSSION

5. Discussion

5.1. Introduction

CBCT, is a low-dose radiographic modality for the analysis and measurement of the effect of RME on nasopharyngeal dimensions. No previous studies have investigated the potential comprehensive effects of RME on the volume of nasal cavity, upper nasopharyngeal space and maxillary sinus utilising CBCT. Studying the morphology of the upper airway using CBCT has a significant impact on the treatment of OSA and in evaluating the effect of craniofacial morphology and nasorespiratory function (Lenza et al., 2010). It has been hypothesised that maxillary constriction is an aetiological factor in OSA because of its association with the posterior-inferior tongue posture (Subtelny, 1954, Pirelli et al., 2004, Chang et al., 2013). Previous research has shown that RME can improve the patency of the upper airway due to a complex physiologic changes of the volume of related airway spaces (de Freitas et al., 2006).

The aim of this study was to investigate the 3D effect of RME on the maxillary sinus, lower nasal cavity, nasopharynx and upper oropharynx (retropalatal airway), and to correlate the changes in these anatomical spaces to the magnitude of the dentoalveolar expansion in growing patients using CBCT. The study was carried out on subjects who were referred to the Orthodontic Department of Victoria Hospital, Fife for the correction of deficient width of the maxillary dental arch with a unilateral or bilateral posterior cross bite. Based on the power calculation

in a previous study (Chang et al., 2013), a minimum of 14 subjects were required for this study at power of 95%, however, 17 subjects were recruited to compensate for any withdrawal from the study.

5.1.1. Methodology

5.1.1.1. Consistency, Reproducibility and Methodological Errors

The CBCT scans were taken before and after treatment, they were superimposed on the cranial base following a standardised protocol of radiographic capture and analysis (Guijarro-Martínez and Swennen, 2013, Guijarro-Martínez and Swennen, 2011). The pre-treatment CBCT (T1) was taken after cementation of RME to standardise the tongue position which is essential for accurate volumetric measurement of the airway spaces (Guijarro-Martínez and Swennen, 2011). Nevertheless, the systematic errors produced due to the RME device could not be totally excluded (Hernández-Alfaro et al., 2011).

Changes in the head inclination during scanning, which affect the pharyngeal airway volume and cross-section measurements, were detected by measuring the angles of head orientation and neck lordosis (Muto et al., 2002, Huggare, 1989, Cevidanes et al., 2009). This ensured that the sections of the pharynx that were measured in this study were not affected by positional changes of the head and vertebrae (Shelton and Bosma, 1962, Muto et al., 2002, Stepovich, 1965).

In this study, ITK-SNAP software was used for airway segmentation due to its proven high sensitivity (1.8% error) compared to the computer package OnDemand3D (6.4% errors) which is essential before airway analysis (Guijarro-Martinez and Swennen, 2011). Its reliability and accuracy have been verified and validated similar to other study (Weissheimer et al., 2012).

A key feature of ITK-SNAP is the existing facilities to segment and navigate through the volumetric data set in sagittal, coronal and axial views with a linked cursor system that allows tracking of a single voxel. ITK-SNAP allows regional semi-automatic segmentation employing user-initialised deformable implicit surfaces to identify the most appropriate border between neighbouring structures. The segmentation process allows construction of 3D virtual surface models to match the volumetric data by separation of the areas of interest from the rest (Grauer et al., 2009). The semi-automatic segmentation approach guided by the specific density values (grey levels), rather than the manual slice-by-slice segmentation, which was adopted in this study, facilitated the rapid processing of the data (El and Palomo, 2010).

The intensity region filter was set with a fixed threshold value of -450 grey levels rather than interactive thresholding, which is dependent on the operator's visual discrimination (Weissheimer et al., 2012). Fixed thresholding is more reliable, as it eliminates operator subjectivity in boundary selection (Weissheimer et al., 2012). The operator's visual discrimination of the airway boundaries is non-reproducible, as human

vision is influenced by lighting conditions, fatigue, the ability to discern the greyscale and visual acuity (Mah et al., 2010, El and Palomo, 2010).

5.1.1.2. Assessment of magnitude of the transverse expansion

In this study, RME resulted in splitting of the mid-palatal suture in all subjects similar to the results of Ong et al study (Ong et al., 2013). The transverse expansion in the alveolar bones of the maxillary first molar is a proof of the effectiveness of the bondable RME appliance in increasing the maxillary dentoalveolar width (Chang et al., 2013, Kartalian et al., 2010, Ong et al., 2013, Podesser et al., 2007). The transverse dentoalveolar expansion was about one-third of that reported by another studies (Podesser et al., 2007); this could be due to differences in the activation regime and the type of the used RME appliance . It is worth mentioning that the degree of dentoalveolar in males was greater than in females, the difference was not statistically significance. These noted differences may be due to the fact that male patients were of younger age group than females in this study.

5.1.1.3. Assessment of RME's effect on Nasopharyngeal Volumes

The volumetric changes were assessed by measuring the percentage of change in the volume of interest secondary to RME $[(T2/T1)-1*100]$.

The effect of RME on the maxillary sinus is variable in different studies. Garrett et al recorded a reduction of the maxillary sinus volume following RME (Garrett et al., 2008). Pangrazio-Kulbersh et al have reported an average of 9% increase in the maxillary sinus volume after RME (Pangrazio-Kulbersh et al., 2011). However, in this study, the volumetric changes in the maxillary sinuses were limited in both genders, similar to the results of Smith et al. (Smith et al., 2012), and it could be explained by the fact that the lateral structures of the nasomaxillary complex moved upward in relation to the fixed superior boundary of the maxillary sinuses (Jafari et al., 2003b). Another explanation is the possible reshaping of the maxillary sinuses secondary to maxillary expansion (Darsey et al., 2012). Alternatively, this variation might be due to the method used in this study for defining the boundaries of the maxillary sinus or it could be related to the fact that RME causes lateral bending and torque of the alveolar bone, which minimises the effective volume of the maxillary sinuses (Gray, 1975, Haas, 1965).

In this study, the lower part of nasal cavity was considered because RME's greatest effect was observed at the level of the nasal floor region (Holmberg et al., 2010). The volumetric changes in the LNC increased secondary to RME; however, this did not reach a statistically significant level. This occurred as a result of lateral displacement of the outer wall of the nasal cavity, the inferior turbinate bones and the conchae, which are all attached to the nasal wall. The internasal capacity has also increased due to the bending of the lateral alveolar process and the inferior movement of the horizontal palatine process

followed by inferior displacement of the nasal floor (da Silva Filho et al., 1995, Haas, 1961, Wertz, 1970). In this study, the LNC increased fivefold in males compared to females (29.2% in females and 6.0% in males) which is similar to the findings of other studies (da Silva Filho et al., 1995, Haas, 1961, Wertz, 1970). The detected difference may be due to the variation in the anatomical and physiological features between the genders, and the relative maturation differences despite similar chronological age. Another reason for this observation is the age difference; in general the male group in this study was younger than the female group, the younger the age the better the chance of mid-palatal suture splitting and more skeletal expansion (Lagravère, 2006). However in this study there was statistically insignificant difference in the skeletal expansion between males and females similar to other studies (Cross and McDonald, 2000, da Silva Filho et al., 1995, Krebs, 1964, Wertz, 1970). It is worth mentioning that other researchers have reported no statistically significant age difference in the amount of nasal cavity expansion secondary to RME (Sari et al., 2003). It is well documented that these changes are crucial in influencing the patterns of breathing (Baraldi et al., 2007, Ceroni Compadretti et al., 2006, Wriedt et al., 2001) and facial growth. An improved flow of air through the nasal cavity could initiate a constant stimulus for lateral growth of the maxilla and lowering of the palatal vault by bone remodelling (Moss, 1997).

Similar to other studies, this research proved that the UNP has increased significantly following RME and both genders showed

similar pattern of response (Zhao et al., 2010, Chang et al., 2013, Enoki et al., 2006). A possible explanation for the increase in the UNP is that the RME may have anteriorly displaced the two palatal shelves which are pivoting at the pterygoid-maxillary junction leading to the forward displacement of the PNS and the anterior boundary of the UNP and consequently an increase in the UNP.

The URP and LRP volumes were reduced as a result of RME, especially in males, but to statistically insignificant level; this contrasts with the results of Chang et al. (Chang et al., 2013). The trauma to the retropalatal tissue resulting from midpalatal suture separation may have reduced the volume of the URP and LRP space. In this study, the T2 CBCT scan was taken immediately after completion of maxillary expansion, whereas in the study by Chang et al. (Chang et al., 2013) they used a Hyrax expander and the T2 CBCT scan was taken 3–4 months after completion of expansion. This may have allowed more settling of soft tissue trauma. The forward displacement of the palatal shelves may have caused the stretching of the palato-pharyngeal muscle and subsequent narrowing and reduction of this space. It is also feasible that the lowering of the palatal plane secondary to RME might have caused an increase in UNP volume and reduction of the URP. Other explanation is the tongue positional movement at the time of image acquisition which may have altered the URP volume (Ribeiro et al., 2011).

The LRP was reduced more in males than females similar to previous reports (Smith et al., 2012). A possible explanation for this is that in males, the pharyngeal muscles are more collapsible due to their

anatomical features (Malhotra et al., 2002). It has been reported that males are likely to exhibit an increased size of the soft palate, therefore, these tissues are more susceptible to trauma resulting from the palatal suture separation with subsequent reduction in LRP (Brown et al., 1986, Malhotra et al., 2002). Similarly, it has been reported that females have an increased pharyngeal dilator muscle activity compared with males, resulting in more resistance to external effects (Malhotra et al., 2002, PILLAR et al., 2000).

Overall, the effect of RME on the airway space was limited to the upper part of the pharyngeal space due to the compensation of the surrounding pharyngeal muscle and soft tissues in the 3D frame of the upper part of pharyngeal spaces. Moreover, the statistically insignificant changes secondary to RME might be owed to the large standard deviation and to the small sample size. The sample size was re-calculated through post-hoc testing according to the collected values, it was found that 32 subjects are required for both groups and a larger sample size may have provided more conclusive findings (Levine and Ensom, 2001).

The Pearson correlation coefficients (PCC) showed a strong direct correlation between the change in the right and left maxillary sinus (PCC 0.86); this was due to the analogous anatomical structure and the identical articulation of bony structures surrounding the maxillary sinuses. Not surprisingly, there was a strong direct correlation between Appliance expansion (AE) separation and dentoalveolar expansion (IMD), which suggests that RME is an effective dentoalveolar expansion appliance in growing patients (Ong et al., 2013).

Further Thoughts on This Study

In this study the subjects were given special instructions for breathing and swallowing during the 20-second scan of the CBCT capture to avoid a blurred tongue position and unequal soft palate position as recommended by Chang et al. (Chang et al., 2013). Nevertheless, absolute control of the tongue position during radiographic scanning may not be possible.

A future studies could include a colour mapping for detailed assessment of changes in different part of the oro-naso-pharyngeal space, as the shape changes of the airway space is as important as volumetric changes (Figure 40). A long-term follow-up of patients might provide a better understanding of the stability of the effects on the nasopharyngeal region.

Finally, a further randomised clinical trial or comparative study with larger sample size would be beneficial in estimating the real impact of the RME on the airway confirm the findings of this study.

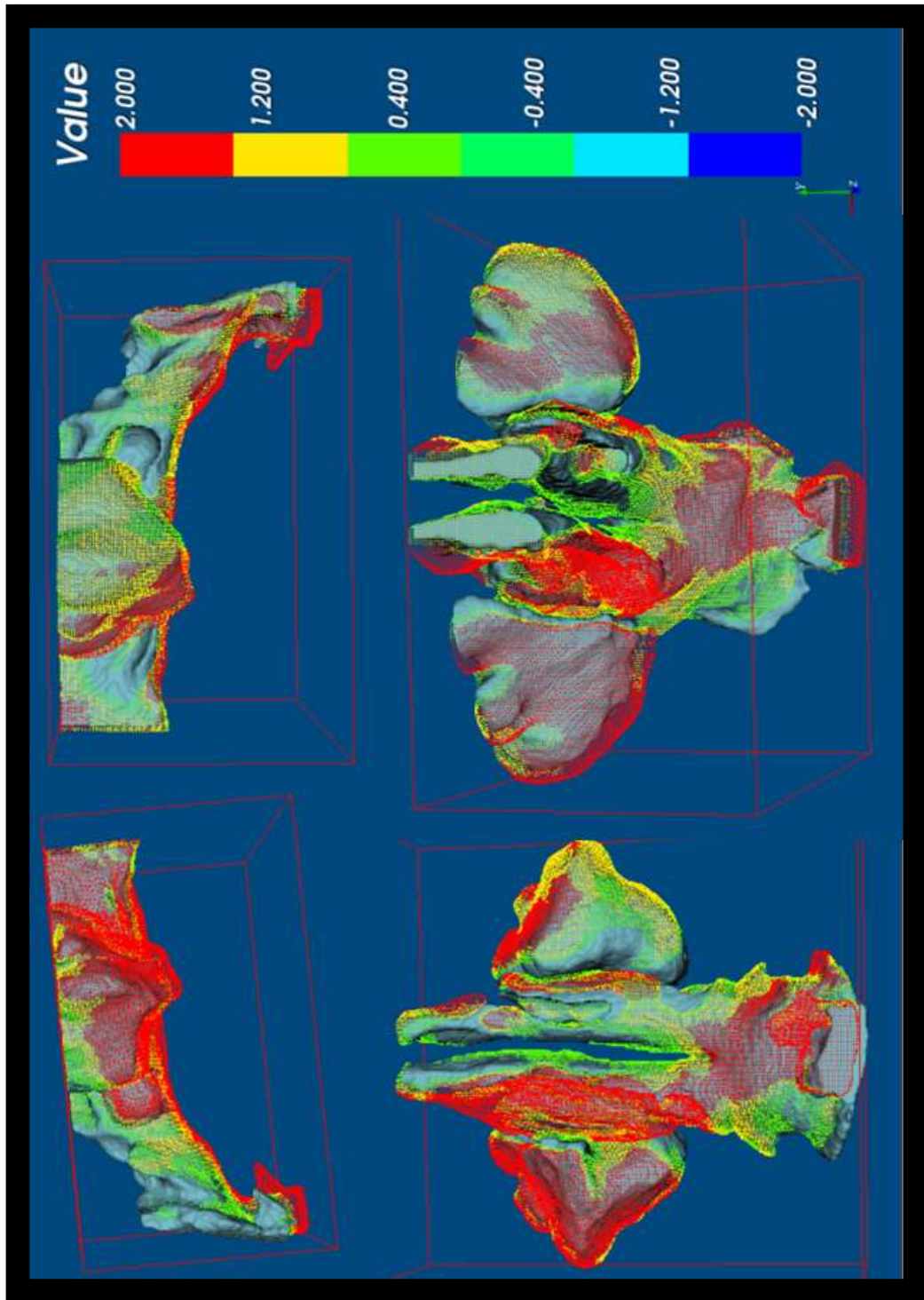


Figure 40: Colour mapping of object No. 7 showing the pre-treatment (Solid) and the post-treatment (mesh) changes

Clinical Implications

Although, the change in the LNC volume appears to be statistically insignificant, but 17% of immediate expansion of LNC could be considered clinically significant. This might be associated with a reduction in nasal resistance, improvement in the nasal breathing and it can be considered as an option for treatment of Paediatric Obstructive Sleep Apnea Syndrome. RME might have an effect in improving the quality of sleeping and treatment of snoring by expanding UNP in growing children. However, it is essential to consider that regardless of the benefit of the increase nasal patency of this orthopedic procedure, it should not done merely for the above purposes solely but only when it is linked to a right indication for RME. However, the immediate reduction in the URP might add another downfall to RME as it could be a causative factor of transient sleep apnea/hypopnea.

Additionally, the free-access ITK snap software package could be used to measure the size of bony defect in patient with cleft palate before secondary alveolar bone grafting.

CHAPTER 6

CONCLUSION

Conclusion

1. CBCT scanning is a beneficial imaging modality to analyse and gauge the effect of RME on nasopharyngeal dimensions.
2. ITK-SNAP software is a cost-effective and reliable package for measuring nasopharyngeal volumes.
3. Semi-automatic and automatic segmentation is an effective and suitable method to assess nasopharyngeal volumes.
4. A single threshold value (-450) is a reasonable value for the segmentation of nasopharyngeal spaces.
5. In general, the immediate post-RME effect on the volumetric changes of the nasopharyngeal airway spaces had a mushroom-like pattern, with the upper part (LNC and UNP) expanded, middle part significantly narrowed and the LRP mildly but statistically insignificantly reduced.
6. Sexual anatomical dimorphism may have contributed to the detected gender differences regarding airway changes secondary to RME.
7. A larger study sample and a longer follow up is required.
8. The Null Hypothesis was therefore partially rejected, as RME produced a statistically significant change in UNP and URP.

CHAPTER 7

APPENDICES

7. Appendices

7.1. Copy of the Ethical Approval Letter (NHS Greater Glasgow and Clyde)

WoSRES
West of Scotland Research Ethics Service

NHS
Greater Glasgow and Clyde
West of Scotland REC 2
Western Infirmary
Ground floor, Tennent Institute
38 Church Street
Glasgow
G11 6NT
Telephone: 0141 211 6238
Facsimile: 0141 211 1547

16 June 2009

Dr Balvinder Khambay
Senior Clinical Teacher in Orthodontics / Honorary Consultant
Level 5, Department of Orthodontics,
378 Sauchiehall Street,
Glasgow G2 3JZ

Dear Dr Khambay

Study Title: A study to investigate the skeletal and soft tissue changes produced by Rapid Maxillary Expansion (RME) using low dose CT scans and 3D Stereophotogrammetry.

REC reference number: 09/S0709/40

Protocol number: 1.0

Ethical opinion

The committee discussed their requested amendments as contained within your letter dated 26th May 2009 and approved these amendments

The members of the Committee present gave a favourable ethical opinion of the above research on the basis described in the application form, protocol and supporting documentation, subject to the conditions specified below.

Ethical review of research sites

The favourable opinion applies to all NHS sites taking part in the study, subject to management permission being obtained from the NHS/HSC R&D office prior to the start of the study (see "Conditions of the favourable opinion" below).

The favourable opinion applies to the following research site(s):

Research Site	Principal Investigator / Local Collaborator
NHS Greater Glasgow & Clyde	Dr Balvinder Khambay

Conditions of the favourable opinion

The favourable opinion is subject to the following conditions being met prior to the start of the study.

Delivering better health
www.nhs.uk

Management permission or approval must be obtained from each host organisation prior to the start of the study at the site concerned.

For NHS research sites only, management permission for research ("R&D approval") should be obtained from the relevant care organisation(s) in accordance with NHS research governance arrangements. Guidance on applying for NHS permission for research is available in the Integrated Research Application System or at <http://www.rdforum.nhs.uk>. Where the only involvement of the NHS organisation is as a Participant Identification Centre, management permission for research is not required but the R&D office should be notified of the study. Guidance should be sought from the R&D office where necessary.

Sponsors are not required to notify the Committee of approvals from host organisations.

It is responsibility of the sponsor to ensure that all the conditions are complied with before the start of the study or its initiation at a particular site (as applicable).

Approved documents

The documents reviewed and approved at the meeting were:

Document	Version	Date
report from Radiation Advisor		12 January 2009
CV for student		
Participant Consent Form	1.0	06 April 2009
Participant Information Sheet	1.0	06 April 2009
Covering Letter		06 April 2009
Protocol	1.0	06 April 2009
Investigator CV		06 April 2009
Application	2.0	06 April 2009
Parent Assent forms	1.0	26 May 2009
Child Assent Form SCO	1.0	26 May 2009
Response to Request for Further Information		26 May 2009
Participant Consent Form: SCO	V2	26 May 2009
Participant Information Sheet	V2 SCO	26 May 2009
Covering Letter		26 June 2009

Membership of the Committee

The members of the Ethics Committee who were present at the meeting are listed on the attached sheet.

Statement of compliance

The Committee is constituted in accordance with the Governance Arrangements for Research Ethics Committees (July 2001) and complies fully with the Standard Operating Procedures for Research Ethics Committees in the UK.

After ethical review

Now that you have completed the application process please visit the National Research Ethics Service website > After Review

You are invited to give your view of the service that you have received from the National Research Ethics Service and the application procedure. If you wish to make your views known please use the feedback form available on the website.

The attached document "After ethical review – guidance for researchers" gives detailed guidance on reporting requirements for studies with a favourable opinion, including:

- Notifying substantial amendments
- Adding new sites and investigators
- Progress and safety reports
- Notifying the end of the study

The NRES website also provides guidance on these topics, which is updated in the light of changes in reporting requirements or procedures.


We would also like to inform you that we consult regularly with stakeholders to improve our service. If you would like to join our Reference Group please email referencegroup@nres.npsa.nhs.uk.

09/S0709/40

Please quote this number on all correspondence

With the Committee's best wishes for the success of this project

Yours sincerely



Dr S Langridge
Chair

Email: andrea.torrie@ggc.scot.nhs.uk

Enclosures: *List of names and professions of members who were present at the meeting and those who submitted written comments*
"After ethical review – guidance for researchers" SL-AR2
Site approval form (SF1)

Copy to: *Dr Melissa McBride R ^& D WIG*

West of Scotland REC 2

Attendance at Committee meeting on 16 June 2009

Committee Members:

Name	Profession	Present	Notes
Dr A Crighton	Oral Medicine	No	
Rev R Currie	Clergy (Retired)	No	
Sister C Donald	Research Sister	No	
Dr Mark Drummond	Consultant Haematologist	Yes	
Dr Sue Humphreys	Research	Yes	
Dr S Langridge	General Practitioner	Yes	
Dr R Lindsay	Consultant Physician	No	
Mr S McGlynn	Pharmacist	Yes	
Mr J McLugh	Insurance	Yes	
Prof C Robertson	Statistician	No	
Dr A Shaikat	Consultant Clinical Oncologist	Yes	
Dr David Shaw	Lecturer in Ethics & Law	Yes	
Dr R Soutar	Consultant Haematologist	No	
Mrs J Wardlaw	Retired Pharmacist	Yes	

West of Scotland REC 2

LIST OF SITES WITH A FAVOURABLE ETHICAL OPINION

For all studies requiring site-specific assessment, this form is issued by the main REC to the Chief Investigator and sponsor with the favourable opinion letter and following subsequent notifications from site assessors. For issue 2 onwards, all sites with a favourable opinion are listed, adding the new sites approved.

REC reference number:	OS070340	Issue number:	1	Date of issue:	16 June 2009
Chief Investigator:	Dr Balinder Khambay				
Full title of study:	A study to investigate the skeletal and soft tissue changes produced by Rapid Maxillary Expansion (RME) using low dose CT scans and 3D Stereophotogrammetry.				
This study was given a favourable ethical opinion by West of Scotland REC 2 on 16 June 2009. The favourable opinion is extended to each of the sites listed below. The research may commence at each NHS site when management approval from the relevant NHS care organisation has been confirmed.					
Principal Investigator	Post	Research site	Site assessor	Date of favourable opinion for this site	Notes ⁽¹⁾
Dr Balinder Khambay	Senior Clinical Teacher in Orthodontics / Honorary Consultant	NHS Greater Glasgow & Clyde	West of Scotland REC 2	16/06/2009	

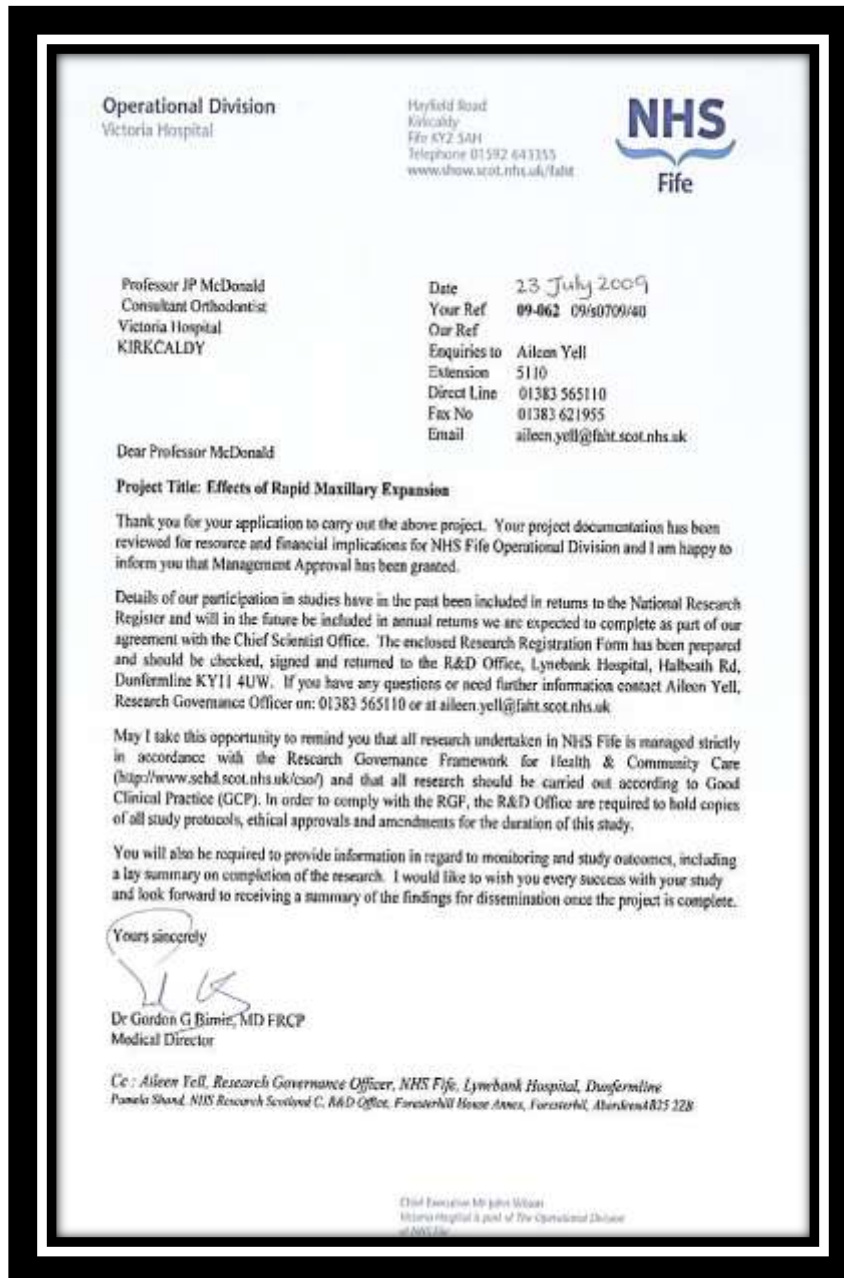Approved by the Chair on behalf of the REC:

Andrew H. Jones (Signature of Chair/Co-ordinator)

(delete as applicable)

AH Tolle (Name)


7.2. Copy of the Ethical Approval Letter (NHS Fife)



7.3. Copy of the Consent Form

7.3.1. Patient Consent Form (Adult)

Consent Form Version 1.0 BSK/SCO



North Glasgow University Hospitals Division

Patient Consent Form (Adult)

Pilot study: A study to investigate the skeletal, soft tissue and dental changes produced by Rapid Maxillary Expansion (RME) using low dose CT scans and 3D Stereophotogrammetry.

Patient's name: _____

Date of birth: _____

	Yes	No
1. Have you read the information sheet?	<input type="checkbox"/>	<input type="checkbox"/>
2. Do you understand the study?	<input type="checkbox"/>	<input type="checkbox"/>
3. Did we answer all of your questions?	<input type="checkbox"/>	<input type="checkbox"/>
4. Do you want to take part in this study?	<input type="checkbox"/>	<input type="checkbox"/>
5. Are you happy for your captured image to be used for publication?	<input type="checkbox"/>	<input type="checkbox"/>

Who have you spoken to?
Dr/Mr/Mrs/Prof. _____

Do you understand that you can change your mind at any time? Yes No

Signed: _____


Name (print): _____

Signature of witness: _____

Name (print): _____

7.3.2. Parental Assent Form

Parent Assent Form Version 1.0 BSK/SCO



North Glasgow University Hospitals Division

Parent Assent Form

Pilot study: A study to investigate the skeletal, soft tissue and dental changes produced by Rapid Maxillary Expansion (RME) using low dose CT scans and 3D Stereophotogrammetry.

Childs name: _____

Date of birth: _____

	Yes	No
1. Have you read the information sheet?	<input type="checkbox"/>	<input type="checkbox"/>
2. Do you understand the study?	<input type="checkbox"/>	<input type="checkbox"/>
3. Did we answer all of your questions?	<input type="checkbox"/>	<input type="checkbox"/>
4. Do you want your child to take part in this study?	<input type="checkbox"/>	<input type="checkbox"/>
5. Are you happy for your child's captured images to be used for publication?	<input type="checkbox"/>	<input type="checkbox"/>

Who have you spoken to?
Dr/Mr/Mrs/Prof. _____

Do you understand that your child can change their mind at any time? Yes No

Signed: _____

Name (print): _____

Signature of witness: _____

Name (print): _____

7.3.3. Child Assent/Information Form

North Glasgow University Hospitals Division

Child Assent / Information Form

My name is Prof Jim McDonald and I am from the Orthodontic Department at the University of Glasgow. I am conducting a research study entitled "A study to investigate the skeletal, soft tissue and dental changes produced by Rapid Maxillary Expansion (RME) using low dose CT scans and 3D Stereophotogrammetry". I am asking you to take part in this research study because I am trying to learn more about the changes to your teeth and jaw bone shape caused by the brace you are going to wear.

If you agree to be in this study, you will be asked to visit the Glasgow Dental Hospital where you will have a special 3D x-ray (scan) taken of your top jaw. In addition to this I would like to take a special 3D photograph. Both of these are totally painless and are like having a normal photograph taken – you just need to keep still for about a minute. You will be required to attend the Glasgow Dental Hospital the day the brace is fitted and the day the brace is removed.

Please talk about this study with your parents before you decide whether or not to participate. I will also ask your parents to give their permission for you to participate. Even if your parents say "yes" you can still decide not to participate. You may also change your mind before or during the study. No one will be upset with you if you don't want to participate or if you change your mind later.

You may ask me any questions about this study. You can call me at any time or talk to me the next time you see me.

By signing below, you are agreeing to participate with the understanding that your parents have given permission for you to take part in this project. You are participating in this study because you want to. You and your parents will be given a copy of this form after you have signed it.

Signed: _____


Name (print): _____

Signature of witness: _____

Name (print): _____

7.4. Presentation



Poster presentation, British Orthodontic Conference, EDINBURGH (18th – 20th September 2014)



3D Assessment of the Effect of Bonded RME on the Nasal Cavity, Maxillary Sinus and Upper Nasopharynx

A prospective CBCT study


M. Almuzian¹, A. Ayoub², J.P. McDonald³
¹Glasgow Dental Hospital and School, ²Victoria Hospital, Falkirk

Introduction

Current methods for volumetric measurement of the nasal and paranasal sinuses are:

- Transcranial Dopplerometry
- Computed Axial Tomography
- Magnetic Resonance Imaging



Most of previous studies, that used a CT/CBCT data, were based on the analysis of reconstructed slice data. In this study, computerized software of head volumetry and analysis while measuring the nasopharyngeal airway. 3-D effect of RME on the nasal cavity, and did they validate the software package "ITK Snap".


Aims

To assess and correlate the RME effect on the nasopharyngeal airway space and to assess the validity of the "ITK Snap" software package.

Methods

Subject:


Sample size was calculated using the Preceptor's T-test calculation and this indicated that a sample size of 14 patients, with confidence level at 95% and a Beta error level at 20%. It was decided to recruit 17 subjects (8 boys, 9 girls; mean age 15.9(±1.8 years) to overcome a potential dropout or exclusion. These patients required maxillary expansion for the management of maxillary agenesis dental arch and treated using a fixed-type bonded RME device (Figure 1). Ethical approval obtained from NHS Greater Glasgow and Western Hospital (13/08/10).



Pre-RME (T1) and immediate post-RME (T2) CBCT images were taken. Using "SimDensHD" software package, the head position, in three planes of space (Pitch, Roll and Yaw angles), and each position (Locking) were measured at first week (W1). Subject that showed a difference, of more than 2° in the head position or lockers was excluded. These measurements were repeated after one week (W2). T1 scans were oriented according to standardized method and the T2 scans were superimposed onto the anterior cranial base of the same T1 image and both saved.


Measurements of the anatomical changes

The changes in the maxillary dental arch width at level of maxillary alveolar crest (IMD) and the magnitude of appliance expansion (AE) were measured using "SimDensHD" software packages (Figure 2).




Volumetric measurements

In vitro study was performed to test the best threshold levels for accuracy of volumetric measurements. Hence, a (1-100) grey was chosen. Then, boundaries of the airway spaces were defined and tested for reproducibility (Figure 3).



The volume of the lower part of the nasal cavity (LNCA), right and left maxillary sinus spaces (RMS and LMS), upper nasopharynx (UNP), upper and lower paranasal space (URP and LRP) were measured using "ITK Snap" software package at W1 and repeated at W2 (Figure 4).



Statistical Analysis

Kolmogorov-Smirnov test showed a normal distribution of the data. Therefore, the reproducibility of the measurements were tested using paired t-test and intraclass correlation coefficient (ICC). A Student's t-test (P<0.05) was used to assess the volumetric and linear changes. Pearson Correlation Coefficient (PCC) was used to assess the correlation between volumetric and linear changes.

Results and Discussion

1. Reproducibility of the study



Student's t-test showed that there was no significant difference between the first (W1) and the second (W2) set of measurements (P=0.87). The ICC ranged from 0.93-1.000 for landmark points and from 0.9724-1.000 for volumetric measurements.

2. Linear Changes

RME produced statistically significant dimensional expansion (mean for the male group and 5.7mm for the female group). The greater displacements could be related to transcranial difference. However the different landmark points were statistically insignificant.

3. Volumetric Changes

The UNP has increased significantly, which might be due to inferior-inferior displacement of palatal shelves secondary to RME, with subsequent stretch of nasopharyngeal muscle leading to anterior displacement of the posterior pharyngeal wall, or due to trauma of the oropharynx tissue following maxillary canine split. Additionally, UNP has expanded significantly as a result of inferior-inferior displacement of palatal shelves. Maxillary displacement probably related to anatomical, physiological or chronological difference.

4. Correlation of the changes


PCC showed that there was a strong correlation between the volumetric changes of the right and left maxillary sinuses using 3D the statistical anatomical measurements. Similarly, there was strong correlation between AE and IMD. A weak correlation was found among other variables.

Potential Clinical Implications

The volumetric expansion of UNP and UNP secondary to RME might be associated with a reduction in nasal resistance, improvement in the nasal breathing and potentially reduce the frequency of Puffiness, DASH, Hay fever, etc. However, it is essential to consider the magnitude of the benefit of the maxillary expansion of the volumetric expansion. It should not draw results for the above mentioned benefits when it is related to a high resistance to RME.

Implications For Research

A future study should include a colour mapping for detailed localization of the changes in the morphological changes of the airway spaces in its importance in volumetric changes. A follow up CT or computerized study with better sample size and long term follow up would be beneficial (Figure 5).



Conclusion

ITK-SNAP software is a free and reliable package for measuring airway volumes. Bonded RME was an effective dental/oral expander in growing patients on short term basis. The mesializing effect of the RME on the volume of the nasopharyngeal airway spaces has musculoskeletal pattern, with the upper part (UNP and UNP) expanded, middle part (URP) significantly narrowed and the LRP still but statistically insignificantly reduced.

Poster by: Mohammed Almuzian, A. Ayoub, J. McDonald

References

1. ABBOTT, M. B., DONNELLY, L. F., DARDZINSKI, B. J., POE, S. A., CHINI, B. A. & AMIN, R. S. 2004. Obstructive sleep apnea: Mr imaging volume segmentation analysis1. *Radiology*, 232, 889-895.
2. ABOUDARA, C., NIELSEN, I., HUANG, J. C., MAKI, K., MILLER, A. J. & HATCHER, D. 2009. Comparison of airway space with conventional lateral headfilms and 3-dimensional reconstruction from cone-beam computed tomography. *American Journal of Orthodontics and Dentofacial Orthopedics*, 135, 468-479.
3. ADAMS, G. L., GANSKY, S. A., MILLER, A. J., HARRELL JR, W. E. & HATCHER, D. C. 2004. Comparison between traditional 2-dimensional cephalometry and a 3-dimensional approach on human dry skulls. *American journal of orthodontics and dentofacial orthopedics*, 126, 397-409.
4. ADKINS, M. D., NANDA, R. S. & CURRIER, G. F. 1990. Arch perimeter changes on rapid palatal expansion. *American Journal of Orthodontics and Dentofacial Orthopedics*, 97, 194-199.
5. AHLQVIST, J., ELIASSON, S. & WELANDER, U. 1986. The effect of projection errors on cephalometric length measurements. *The European Journal of Orthodontics*, 8, 141-148.
6. AKKAYA, S., LORENZON, S. & ÜÇEM, T. T. 1999. A comparison of sagittal and vertical effects between bonded rapid and slow maxillary expansion procedures. *The European Journal of Orthodontics*, 21, 175-180.

7. ALPERN, M. C. & YUROSKO, J. J. 1987. Rapid palatal expansion in adults: with and without surgery. *The Angle Orthodontist*, 57, 245-263.
8. ANASTASSOV, G. E. & TRIEGER, N. 1998. Edema in the upper airway in patients with obstructive sleep apnea syndrome. *Oral Surgery, Oral Medicine, Oral Pathology, Oral Radiology, and Endodontology*, 86, 644-647.
9. ANGELL, E. 1860a. The permanent or adult teeth. *San Fran Med Press*, 1, 83.
10. ANGELL, E. 1860b. Treatment of irregularity of the permanent or adult teeth. *Dental Cosmos*, 1, 540-4.
11. ARAI, Y., TAMMISALO, E., IWAI, K., HASHIMOTO, K. & SHINODA, K. 1999. Development of a compact computed tomographic apparatus for dental use. *Dentomaxillofacial Radiology*, 28, 245-248.
12. ARAUGIO, R. M. D. S., LANDRE JR, J., SILVA, D. D. L. A., PACHECO, W., PITHON, M. M. & OLIVEIRA, D. D. 2013. Influence of the expansion screw height on the dental effects of the hyrax expander: A study with finite elements. *American Journal of Orthodontics and Dentofacial Orthopedics*, 143, 221-227.
13. ASANZA, S., CISNEROS, G. J. & NIEBERG, L. G. 1997. Comparison of Hyrax and bonded expansion appliances. *The Angle Orthodontist*, 67, 15-22.
14. BABACAN, H., SOKUCU, O., DORUK, C. & AY, S. 2006. Rapid maxillary expansion and surgically assisted rapid maxillary expansion effects on nasal volume. *The Angle orthodontist*, 76, 66-71.

15. BACCETTI, T., FRANCHI, L., CAMERON, C. G. & MCNAMARA JR, J. A. 2001. Treatment timing for rapid maxillary expansion. *The Angle orthodontist*, 71, 343-350.
16. BACCETTI, T., MUCEDERO, M., LEONARDI, M. & COZZA, P. 2009. Interceptive treatment of palatal impaction of maxillary canines with rapid maxillary expansion: a randomized clinical trial. *American journal of orthodontics and dentofacial orthopedics*, 136, 657-661.
17. BAIK, H. S. 1995. Clinical results of the maxillary protraction in Korean children. *American Journal of Orthodontics and Dentofacial Orthopedics*, 108, 583-592.
18. BALLANTI, F., LIONE, R., FANUCCI, E., FRANCHI, L., BACCETTI, T. & COZZA, P. 2009. Immediate and post-retention effects of rapid maxillary expansion investigated by computed tomography in growing patients. *The Angle orthodontist*, 79, 24-29.
19. BARALDI, C., PRETTO, S. & PURICELLI, E. 2007. Evaluation of surgically assisted maxillary expansion using acoustic rhinometry and postero-anterior cephalometry. *International journal of oral and maxillofacial surgery*, 36, 305-309.
20. BARBER, A. F. & SIMS, M. 1981. Rapid maxillary expansion and external root resorption in man: a scanning electron microscope study. *American journal of orthodontics*, 79, 630-652.
21. BAUMRIND, S. & FRANTZ, R. C. 1971. The reliability of head film measurements: 1. Landmark identification. *American journal of orthodontics*, 60, 111-127.

22. BELL, R. A. 1982. A review of maxillary expansion in relation to rate of expansion and patient's age. *American journal of orthodontics*, 81, 32-37.
23. BERGER, J. L., PANGRAZIO-KULBERSH, V., THOMAS, B. W. & KACZYNSKI, R. 1999. Photographic analysis of facial changes associated with maxillary expansion. *American journal of orthodontics and dentofacial orthopedics*, 116, 563-571.
24. BERKOVITZ, B. K. & MOXHAM, B. J. 2002. *Head and neck anatomy: a clinical reference*, Martin Dunitz London.
25. BHAKTHAVALSALA, S. & NEWSON, T. 2008. *Crash course: paediatrics*, Elsevier Health Sciences.
26. BIEDERMAN, G. B. 1968. STIMULUS FUNCTION IN SIMULTANEOUS DISCRIMINATION¹. *Journal of the Experimental Analysis of Behavior*, 11, 459-463.
27. BIEDERMAN, W. 1973. Rapid correction of Class III malocclusion by midpalatal expansion. *American Journal of Orthodontics*, 63, 47-55.
28. BISHARA, S. E. & STALEY, R. N. 1987. Maxillary expansion: clinical implications. *American Journal of Orthodontics and Dentofacial Orthopedics*, 91, 3-14.
29. BIXLER, E. O., VGONTZAS, A. N., LIN, H.-M., LIAO, D., CALHOUN, S., VELA-BUENO, A., FEDOK, F., VLASIC, V. & GRAFF, G. 2009. Sleep disordered breathing in children in a general population sample: prevalence and risk factors. *Sleep*, 32, 731.
30. BJÖRK, A. 1955. Facial growth in man, studied with the aid of metallic implants. *Acta Odontologica*, 13, 9-34.

31. BJÖRK, A. & SKIELLER, V. 1977. Growth of the maxilla in three dimensions as revealed radiographically by the implant method. *British Journal of Orthodontics*, 4, 53.
32. BORYOR, A., GEIGER, M., HOHMANN, A., WUNDERLICH, A., SANDER, C., MARTIN SANDER, F. & SANDER, F. G. 2008. Stress distribution and displacement analysis during an intermaxillary disjunction—a three-dimensional FEM study of a human skull. *Journal of biomechanics*, 41, 376-382.
33. BRAND, R. W., ISSELHARD, D. E. & SATIN, E. 2003. *Anatomy of orofacial structures*, Mosby Saint Louis.
34. BRAUN, S., BOTTREL, J. A., LEE, K.-G., LUNAZZI, J. J. & LEGAN, H. L. 2000. The biomechanics of rapid maxillary sutural expansion. *American Journal of Orthodontics and Dentofacial Orthopedics*, 118, 257-261.
35. BROSSMAN, R., BENNETT, C. & MEROW, W. 1973. Facioskeletal remodelling resulting from rapid palatal expansion in the monkey (*Macaca cynomolgus*). *Archives of Oral Biology*, 18, 987-IN3.
36. BROWN, G. 1903. The application of orthodontia principles to the prevention of nasal disease. *Dent Cosmos*, 45.
37. BROWN, I. G., ZAMEL, N. & HOFFSTEIN, V. 1986. Pharyngeal cross-sectional area in normal men and women. *J Appl Physiol* (1985), 61, 890-5.
38. BRYANT, J., DRAGE, N. & RICHMOND, S. 2008. Study of the scan uniformity from an i-CAT cone beam computed tomography dental imaging system. *Dentomaxillofacial Radiology*, 37, 365-374.

- 39.ÇAKMAK, Ö., COŞKUN, M., ÇELİK, H., BÜYÜKLÜ, F. & ÖZLÜOĞLU, L. N. 2003. Value of acoustic rhinometry for measuring nasal valve area. *The Laryngoscope*, 113, 295-302.
- 40.CAMERON, C. G., FRANCHI, L., BACCETTI, T. & MCNAMARA JR, J. A. 2002. Long-term effects of rapid maxillary expansion: a posteroanterior cephalometric evaluation. *American journal of orthodontics and dentofacial orthopedics*, 121, 129-135.
- 41.CARVALHO, F., LENTINI-OLIVEIRA, D., MACHADO, M., PRADO, G., PRADO, L. & SACONATO, H. 2007. Oral appliances and functional orthopaedic appliances for obstructive sleep apnoea in children. *Cochrane Database Syst Rev*, 18.
- 42.CAVALCANTI, M. G., HALLER, J. W. & VANNIER, M. W. 1999. Three-dimensional computed tomography landmark measurement in craniofacial surgical planning: experimental validation in vitro. *Journal of oral and maxillofacial surgery*, 57, 690-694.
- 43.CERONI COMPADRETTI, G., TASCA, I., ALESSANDRI-BONETTI, G., PERI, S. & D'ADDARIO, A. 2006. Acoustic rhinometric measurements in children undergoing rapid maxillary expansion. *International journal of pediatric otorhinolaryngology*, 70, 27-34.
- 44.CEVIDANES, L., OLIVEIRA, A. E. F., MOTTA, A., PHILLIPS, C., BURKE, B. & TYNDALL, D. 2009. Head Orientation in CBCT-generated Cephalograms. *The Angle Orthodontist*, 79, 971-977.
- 45.CEYLAN, Í., OKTAY, H. & DEMIRCI, M. 1996. The effect of rapid maxillary expansion on conductive hearing loss. *The Angle Orthodontist*, 66, 301-308.

46. CHACONAS, S. J. & CAPUTO, A. A. 1982. Observation of orthopedic force distribution produced by maxillary orthodontic appliances. *American journal of orthodontics*, 82, 492-501.
47. CHANG, J. Y., MCNAMARA JR, J. A. & HERBERGER, T. A. 1997. A longitudinal study of skeletal side effects induced by rapid maxillary expansion. *American journal of orthodontics and dentofacial orthopedics*, 112, 330-337.
48. CHANG, Y., KOENIG, L. J., PRUSZYNSKI, J. E., BRADLEY, T. G., BOSIO, J. A. & LIU, D. 2013. Dimensional changes of upper airway after rapid maxillary expansion: A prospective cone-beam computed tomography study. *American Journal of Orthodontics and Dentofacial Orthopedics*, 143, 462-470.
49. CHO, J. J., EFSTRATIADIS, S. & HASSELGREN, G. 2010. Pulp vitality after rapid palatal expansion. *American Journal of Orthodontics and Dentofacial Orthopedics*, 137, 254-258.
50. CHRISTIE, K. F., BOUCHER, N. & CHUNG, C.-H. 2010. Effects of bonded rapid palatal expansion on the transverse dimensions of the maxilla: a cone-beam computed tomography study. *American Journal of Orthodontics and Dentofacial Orthopedics*, 137, S79-S85.
51. CHUNG, C.-H. & FONT, B. 2004. Skeletal and dental changes in the sagittal, vertical, and transverse dimensions after rapid palatal expansion. *American journal of orthodontics and dentofacial orthopedics*, 126, 569-575.
52. CLEALL, J. F., BAYNE, D. I., POSEN, J. M. & SUBTELNY, J. D. 1965. Expansion of the midpalatal suture in the monkey. *The Angle Orthodontist*, 35, 23-35.

- 53.CLEMENT, P. & GORDTS, F. 2005. Consensus report on acoustic rhinometry and rhinomanometry. *Rhinology*, 43, 169-179.
- 54.COLE, P., ROITHMANN, R., ROTH, Y. & CHAPNIK, J. 1997. Measurement of airway patency. A manual for users of the Toronto systems and others interested in nasal patency measurement. *The Annals of otology, rhinology & laryngology. Supplement*, 171, 1.
- 55.CORDASCO, G., NUCERA, R., FASTUCA, R., MATARESE, G., LINDAUER, S. J., LEONE, P., MANZO, P. & MARTINA, R. 2012. Effects of orthopedic maxillary expansion on nasal cavity size in growing subjects: A low dose computer tomography clinical trial. *International Journal of Pediatric Otorhinolaryngology*.
- 56.COREY, J. P., GUNGOR, A., NELSON, R., FREDBERG, J. & LAI, V. 1997. A comparison of the nasal cross-sectional areas and volumes obtained with acoustic rhinometry and magnetic resonance imaging. *Otolaryngology--Head and Neck Surgery*, 117, 349-354.
- 57.CROSS, D. L. & MCDONALD, J. P. 2000. Effect of rapid maxillary expansion on skeletal, dental, and nasal structures: a postero-anterior cephalometric study. *The European Journal of Orthodontics*, 22, 519-528.
- 58.CRYER, M. H. 1913. The influence exerted by the dental arches in regard to respiration and general health. *Items of Interest*, 35, 16-46.
- 59.DA SILVA FILHO, O., SILVA LARA, T., MALAGODI DE ALMEIDA, A. & CRISTINA DA SILVA, H. 2005. Evaluation of the midpalatal suture during rapid palatal expansion in

- children: a CT study. *Journal of Clinical Pediatric Dentistry*, 29, 231-238.
60. DA SILVA FILHO, O. G., DO PRADO MONTES, L. A. & TORELLY, L. F. 1995. Rapid maxillary expansion in the deciduous and mixed dentition evaluated through posteroanterior cephalometric analysis. *American Journal of Orthodontics and Dentofacial Orthopedics*, 107, 268-275.
61. DAHLBERG, G. *Statistical Methods for Medical and Biological Students* (1940). Interscience, New York.
62. DARSEY, D. M., ENGLISH, J. D., KAU, C. H., ELLIS, R. K. & AKYALCIN, S. 2012. Does hyrax expansion therapy affect maxillary sinus volume? A cone-beam computed tomography report. *Imaging science in dentistry*, 42, 83-88.
63. DASTIDAR, P., HEINONEN, T., NUMMINEN, J., RAUTIAINEN, M. & LAASONEN, E. 1999. Semi-automatic segmentation of computed tomographic images in volumetric estimation of nasal airway. *European archives of oto-rhino-laryngology*, 256, 192-198.
64. DAVIDOVITCH, M., EFSTATHIOU, S., SARNE, O. & VARDIMON, A. D. 2005. Skeletal and dental response to rapid maxillary expansion with 2-versus 4-band appliances. *American journal of orthodontics and dentofacial orthopedics*, 127, 483-492.
65. DAVIS, W. M. & KRONMAN, J. H. 1969. Anatomical Changes Induced by Splitting of the Midpalatal Suture*. *The Angle Orthodontist*, 39, 126-132.
66. DE FREITAS, M. R., ALCAZAR, N. M. P. V., JANSON, G., DE FREITAS, K. M. S. & HENRIQUES, J. F. C. 2006. Upper and lower pharyngeal airways in subjects with Class I and Class

- II malocclusions and different growth patterns. American journal of orthodontics and dentofacial orthopedics, 130, 742-745.
67. DE OLIVEIRA, A. E. F., CEVIDANES, L. H. S., PHILLIPS, C., MOTTA, A., BURKE, B. & TYNDALL, D. 2009. Observer reliability of three-dimensional cephalometric landmark identification on cone-beam computerized tomography. Oral Surgery, Oral Medicine, Oral Pathology, Oral Radiology, and Endodontology, 107, 256-265.
68. DE SILVA FO, O., BOAS, C. V. & CAPELOZZA, L. F. 1991. Rapid maxillary expansion in the primary and mixed dentitions: a cephalometric evaluation. American Journal of Orthodontics and Dentofacial Orthopedics, 100, 171-179.
69. DE SOUZA CARVALHO, A., MAGRO FILHO, O., GARCIA JUNIOR, I., ARAUJO, P. & NOGUEIRA, R. 2012a. Cephalometric and three-dimensional assessment of superior posterior airway space after maxillomandibular advancement. International journal of oral and maxillofacial surgery, 41, 1102-1111.
70. DE SOUZA CARVALHO, A. C. G., MAGRO FILHO, O., GARCIA JUNIOR, I. R., ARAUJO, P. M. & NOGUEIRA, R. L. M. 2012b. Cephalometric and three-dimensional assessment of superior posterior airway space after maxillomandibular advancement. International Journal of Oral and Maxillofacial Surgery, 41, 1102-1111.
71. DERICHSWEILER, H. 1959. Betrachtungen über Wachstumshemmungen und deren prognostische Bedeutung bei Lippen-Kiefer-Gaumenspalten. Journal of Orofacial Orthopedics/Fortschritte der Kieferorthopädie, 20, 239-255.

- 72.DORUK, C., SÖKÜCÜ, O., BIÇAKÇI, A. A., YILMAZ, U. & TAŞ, F. 2007. Comparison of nasal volume changes during rapid maxillary expansion using acoustic rhinometry and computed tomography. *The European Journal of Orthodontics*, 29, 251-255.
- 73.DOS SANTOS, B. M., STUANI, A. S., STUANI, A. S., FARIA, G., QUINTÃO, C. C. & STUANI, M. B. S. 2012. Soft tissue profile changes after rapid maxillary expansion with a bonded expander. *The European Journal of Orthodontics*, 34, 367-373.
- 74.EL, H. & PALOMO, J. M. 2010. Measuring the airway in 3 dimensions: A reliability and accuracy study. *American Journal of Orthodontics and Dentofacial Orthopedics*, 137, S50.e1-S50.e9.
- 75.ENOKI, C., VALERA, F. C. P., LESSA, F. C. R., ELIAS, A. M., MATSUMOTO, M. A. N. & ANSELMO-LIMA, W. T. 2006. Effect of rapid maxillary expansion on the dimension of the nasal cavity and on nasal air resistance. *International journal of pediatric otorhinolaryngology*, 70, 1225-1230.
- 76.ERVERDI, N., OKAR, I., KÜCÜKKELES, N. & ARBAK, S. 1994. A comparison of two different rapid palatal expansion techniques from the point of root resorption. *American Journal of Orthodontics and Dentofacial Orthopedics*, 106, 47-51.
- 77.FARRONATO, G., MASPERO, C., RUSSO, E., PERITI, G. & FARRONATO, D. 2008. Headache and Transverse Maxillary Discrepancy. *Journal of Clinical Pediatric Dentistry*, 33, 67-74.
- 78.FAULKNER, W. 1996. *Basic principles of MRI*. Outsource Inc.
- 79.FEHRENBACH, M. J. & THOMAS, P., BATH-BALOGH, 1997. *Illustrated dental embryology, histology, and anatomy*, Saunders.

- 80.FOSTER, T., HAMILTON, M. & LAVELLE, C. 1969. Dentition and dental arch dimensions in British children at the age of 212 to 3 years. *Archives of Oral Biology*, 14, 1031-1040.
- 81.FREEMAN, R. 1970. Psychopharmacology and the retarded child. *Psychiatric approach to mental retardation*. New York: Basic Books, 294-368.
- 82.GARDNER, G. E. & KRONMAN, J. H. 1971. Cranioskeletal displacements caused by rapid palatal expansion in the rhesus monkey. *American journal of orthodontics*, 59, 146-155.
- 83.GARIB, D. G., HENRIQUES, J. F. C., JANSON, G., DE FREITAS, M. R. & FERNANDES, A. Y. 2006. Periodontal effects of rapid maxillary expansion with tooth-tissue-borne and tooth-borne expanders: a computed tomography evaluation. *American journal of orthodontics and dentofacial orthopedics*, 129, 749-758.
- 84.GARIB, D. G., HENRIQUES, J. F. C., JANSON, G., FREITAS, M. R. & COELHO, R. A. 2005. Rapid maxillary expansion-tooth tissue-borne versus tooth-borne expanders: a computed tomography evaluation of dentoskeletal effects. *The Angle orthodontist*, 75, 548-557.
- 85.GARRETT, B. J., CARUSO, J. M., RUNGCHARASSAENG, K., FARRAGE, J. R., KIM, J. S. & TAYLOR, G. D. 2008. Skeletal effects to the maxilla after rapid maxillary expansion assessed with cone-beam computed tomography. *American Journal of Orthodontics and Dentofacial Orthopedics*, 134, 8. e1-8. e11.
- 86.GAUDETTE, E. & KIMOFF, R. 2010. Pathophysiology of OSA. *Sleep apnoea. European Respiratory Monograph*, 31-50.

87. GAUTAM, P., VALIATHAN, A. & ADHIKARI, R. 2007. Stress and displacement patterns in the craniofacial skeleton with rapid maxillary expansion: a finite element method study. *American Journal of Orthodontics and Dentofacial Orthopedics*, 132, 5. e1-5. e11.
88. GERAN, R. G., MCNAMARA JR, J. A., BACCETTI, T., FRANCHI, L. & SHAPIRO, L. M. 2006. A prospective long-term study on the effects of rapid maxillary expansion in the early mixed dentition. *American journal of orthodontics and dentofacial orthopedics*, 129, 631-640.
89. GERLACH, K. L. & ZAHL, C. 2003. Transversal palatal expansion using a palatal distractor. *Journal of Orofacial Orthopedics/Fortschritte der Kieferorthopädie*, 64, 443-449.
90. GHANI, S., MANNAN, A., SEN, S., UZZAMAN, M. & HARRISON, M. 2004. The problems of establishing modern cleft lip and palate services in Bangladesh. *The Journal of Surgery*, 2, 43-47.
91. GILAIN, L., COSTE, A., RICOLFI, F., DAHAN, E., MARLIAC, D., PEYNEGRE, R., HARF, A. & LOUIS, B. 1997. Nasal cavity geometry measured by acoustic rhinometry and computed tomography. *Archives of Otolaryngology—Head & Neck Surgery*, 123, 401.
92. GOODDAY, R. H., PRECIOUS, D. S., MORRISON, A. D. & ROBERTSON, C. G. 2001. Obstructive sleep apnea syndrome: diagnosis and management. *Journal-Canadian Dental Association*, 67, 652-658.
93. GORDON, J. M., ROSENBLATT, M., WITMANS, M., CAREY, J. P., HEO, G., MAJOR, P. W. & FLORES-MIR, C. 2009. Rapid palatal expansion effects on nasal airway

- dimensions as measured by acoustic rhinometry: a systematic review. *The Angle Orthodontist*, 79, 1000-1007.
94. GRAUER, D., CEVIDANES, L. S. H. & PROFFIT, W. R. 2009. Working with DICOM craniofacial images. *American Journal of Orthodontics and Dentofacial Orthopedics*, 136, 460-470.
95. GRAY, L. P. 1975. Results of 310 cases of rapid maxillary expansion selected for medical reasons. *J Laryngol Otol*, 89, 601-614.
96. GREENBAUM, K. R. & ZACHRISSON, B. U. 1982. The effect of palatal expansion therapy on the periodontal supporting tissues. *American Journal of Orthodontics*, 81, 12-21.
97. GRIBEL, B. F., GRIBEL, M. N., FRAZÃO, D. C., MCNAMARA, J. A. & MANZI, F. R. 2010. Accuracy and reliability of craniometric measurements on lateral cephalometry and 3D measurements on CBCT scans. *The Angle Orthodontist*, 81, 26-35.
98. GUIJARRO-MARTINEZ, R. & SWENNEN, G. 2011. Cone-beam computerized tomography imaging and analysis of the upper airway: a systematic review of the literature. *International journal of oral and maxillofacial surgery*, 40, 1227-1237.
99. GUIJARRO-MARTÍNEZ, R. & SWENNEN, G. R. J. 2011. Cone-beam computerized tomography imaging and analysis of the upper airway: a systematic review of the literature. *International Journal of Oral and Maxillofacial Surgery*, 40, 1227-1237.
100. GUIJARRO-MARTÍNEZ, R. & SWENNEN, G. R. J. 2013. Three-dimensional cone beam computed tomography definition of the anatomical subregions of the upper airway: a

- validation study. *International Journal of Oral and Maxillofacial Surgery*, 42, 1140-1149.
101. GUNGOR, A., MOINUDDIN, R., NELSON, R. H. & COREY, J. P. 1999. Detection of the nasal cycle with acoustic rhinometry: techniques and applications. *Otolaryngology-Head and Neck Surgery*, 120, 238-247.
 102. HAAS, A. 1980. Long-term posttreatment evaluation of rapid palatal expansion. *The Angle Orthodontist*, 50, 189-217.
 103. HAAS, A. J. 1961. Rapid expansion of the maxillary dental arch and nasal cavity by opening the midpalatal suture. *The Angle Orthodontist*, 31, 73-90.
 104. HAAS, A. J. 1965. The treatment of maxillary deficiency by opening the midpalatal suture. *The Angle Orthodontist*, 35, 200-217.
 105. HAAS, A. J. 1970. Palatal expansion: just the beginning of dentofacial orthopedics. *American Journal of Orthodontics*, 57, 219-255.
 106. HABERSACK, K., KAROGLAN, A., SOMMER, B. & BENNER, K. U. 2007. High-resolution multislice computerized tomography with multiplanar and 3-dimensional reformation imaging in rapid palatal expansion. *American Journal of Orthodontics and Dentofacial Orthopedics*, 131, 776-781.
 107. HAJEER, M., MILLETT, D., AYOUB, A. & SIEBERT, J. 2004. Current products and practices applications of 3D imaging in orthodontics: part I. *Journal of orthodontics*, 31, 62-70.
 108. HANDELMAN, C. S. 1997. Nonsurgical rapid maxillary alveolar expansion in adults: a clinical evaluation. *The Angle Orthodontist*, 67, 291-308.

109. HANDELMAN, C. S., WANG, L., BEGOLE, E. A. & HAAS, A. J. 2000. Nonsurgical rapid maxillary expansion in adults: report on 47 cases using the Haas expander. *The Angle Orthodontist*, 70, 129-144.
110. HARKEMA, J. R. 1991. Comparative aspects of nasal airway anatomy: relevance to inhalation toxicology. *Toxicologic pathology*, 19, 321-336.
111. HARTGERINK, D. V. & VIG, P. S. 1989. Lower anterior face height and lip incompetence do not predict nasal airway obstruction. *The Angle Orthodontist*, 59, 17-23.
112. HARVOLD, E. P., CHIERICI, G. & VARGERVIK, K. 1972. Experiments on the development of dental malocclusions. *American journal of orthodontics*, 61, 38-44.
113. HARZER, W., SCHNEIDER, M. & GEDRANGE, T. 2004. Rapid maxillary expansion with palatal anchorage of the Hyrax expansion screw—pilot study with case presentation. *Journal of Orofacial Orthopedics/Fortschritte der Kieferorthopädie*, 65, 419-424.
114. HASKELL, J. A., MCCRILLIS, J., HASKELL, B. S., SCHEETZ, J. P., SCARFE, W. C. & FARMAN, A. G. Effects of Mandibular Advancement Device (MAD) on airway dimensions assessed with cone-beam computed tomography. *Seminars in Orthodontics*, 2009. Elsevier, 132-158.
115. HASSO, A. N. & NICKMEYER, C. A. 1994. Magnetic resonance imaging of soft tissues of the neck. *Topics in Magnetic Resonance Imaging*, 6, 254-274.
116. HERNÁNDEZ-ALFARO, F., GUIJARRO-MARTÍNEZ, R. & MAREQUE-BUENO, J. 2011. Effect of Mono- and Bimaxillary Advancement on Pharyngeal Airway Volume:

Cone-Beam Computed Tomography Evaluation. *Journal of Oral and Maxillofacial Surgery*, 69, e395-e400.

117. HERSHEY, H. G., STEWART, B. L. & WARREN, D. W. 1976. Changes in nasal airway resistance associated with rapid maxillary expansion. *American journal of orthodontics*, 69, 274-284.
118. HICKS, E. P. 1978. Slow maxillary expansion: A clinical study of the skeletal versus dental response to low-magnitude force. *American Journal of Orthodontics*, 73, 121-141.
119. HILBERG, O. 2002. Objective measurement of nasal airway dimensions using acoustic rhinometry: methodological and clinical aspects. *Allergy*, 57, 5-39.
120. HILBERG, O., JACKSON, A., SWIFT, D. & PEDERSEN, O. 1989. Acoustic rhinometry: evaluation of nasal cavity geometry by acoustic reflection. *Journal of Applied Physiology*, 66, 295-303.
121. HILBERG, O., JENSEN, F. & PEDERSEN, O. 1993. Nasal airway geometry: comparison between acoustic reflections and magnetic resonance scanning. *Journal of Applied Physiology*, 75, 2811-2819.
122. HILBERG, O. & PEDERSEN, O. 2000. Acoustic rhinometry: recommendations for technical specifications and standard operating procedures. *Rhinology. Supplement*, 16, 3-17.
123. HILDEBOLT, C. F., VANNIER, M. W. & KNAPP, R. H. 1990. Validation study of skull three-dimensional computerized tomography measurements. *American journal of physical anthropology*, 82, 283-294.

124. HOLBERG, C., STEINHÄUSER, S., GEIS, P. & RUDZKI-JANSON, I. 2005. Cone-beam computed tomography in orthodontics: benefits and limitations. *Journal of Orofacial Orthopedics/Fortschritte der Kieferorthopädie*, 66, 434-444.
125. HOLMBERG, O., MALONE, J., REHANI, M., MCLEAN, D. & CZARWINSKI, R. 2010. Current issues and actions in radiation protection of patients. *European journal of radiology*, 76, 15-19.
126. HOUSTON, W. 1983. The analysis of errors in orthodontic measurements. *American journal of orthodontics*, 83, 382-390.
127. HUGGARE, J. 1989. Natural head position recording on frontal skull radiographs. *Acta Odontologica*, 47, 105-109.
128. IBANEZ, L., SCHROEDER, W., NG, L. & CATES, J. 2003. The ITK software guide.
129. ISAACSON, R. J. & INGRAM, A. H. 1964. Forces produced by rapid maxillary expansion: II. Forces present during treatment. *The Angle Orthodontist*, 34, 261-270.
130. ISAACSON, R. J. & MURPHY, T. D. 1964. Some Effects Of Rapid Maxillary Expansion In Cleft Lip And Palate Patients. *The Angle Orthodontist*, 34, 143-154.
131. İŞERİ, H., TEKKAYA, A. E., ÖZTAN, Ö. & BILGIC, S. 1998. Biomechanical effects of rapid maxillary expansion on the craniofacial skeleton, studied by the finite element method. *The European Journal of Orthodontics*, 20, 347-356.
132. JACOBSON, A. & WHITE, L. 2007. Radiographic cephalometry: From basics to 3-D imaging. *American Journal of Orthodontics and Dentofacial Orthopedics*, 131, S133.

133. JAFARI, A., SHETTY, K. S. & KUMAR, M. 2003a. Study of stress distribution and displacement of various craniofacial structures following application of transverse orthopedic forces--a three-dimensional FEM study. *Angle Orthod*, 73, 12-20.
134. JAFARI, A., SHETTY, K. S. & KUMAR, M. 2003b. Study of stress distribution and displacement of various craniofacial structures following application of transverse orthopedic forces-a three-dimensional FEM study. *The Angle Orthodontist*, 73, 12-20.
135. JANVIER, P. 2004. Wandering nostrils. *Nature*, 432, 23-24.
136. JOHAL, A., PATEL, S. I. & BATTAGEL, J. M. 2007. The relationship between craniofacial anatomy and obstructive sleep apnoea: a case-controlled study. *Journal of sleep research*, 16, 319-326.
137. JOHNSON, B. M., MCNAMARA JR, J. A., BANDEEN, R. L. & BACCETTI, T. 2010. Changes in soft tissue nasal widths associated with rapid maxillary expansion in prepubertal and postpubertal subjects. *The Angle Orthodontist*, 80, 995-1001.
138. KANEDA, T. 2003. MR imaging of maxillomandibular lesions. *Oral Radiology*, 19, 64-69.
139. KANJI KISHI, D., SATO, M., SUGIHARA, Y., YAMADA, A., TANAKA, H., NAKATSU, T., HIRAKAWA, K., IKUO JOJA, M. & KANAME AONO, M. 1988. The application of magnetic resonance imaging in maxillo-facial region: A comparison with CT. *Oral Radiology*, 4, 1-6.

140. KARAMAN, A., BASCIFTCI, F. & POLAT, O. 2002. Unilateral distal molar movement with an implant-supported distal jet appliance. *The Angle Orthodontist*, 72, 167-174.
141. KARTALIAN, A., GOHL, E., ADAMIAN, M. & ENCISO, R. 2010. Cone-beam computerized tomography evaluation of the maxillary dentoskeletal complex after rapid palatal expansion. *American Journal of Orthodontics and Dentofacial Orthopedics*, 138, 486-492.
142. KASE, Y., HILBERG, O. & PEDERSEN, O. F. 1994. Posture and nasal patency: evaluation by acoustic rhinometry. *Acta oto-laryngologica*, 114, 70-74.
143. KAU, C., RICHMOND, S., PALOMO, J. & HANS, M. 2005. Current Products and Practice Three-dimensional cone beam computerized tomography in orthodontics. *Journal of orthodontics*, 32, 282-293.
144. KEITH, A. & CAMPION, G. G. 1922. A contribution to the mechanism of growth of the human face. *International Journal of Orthodontia, Oral Surgery and Radiography*, 8, 607-633.
145. KİLİÇ, N., KIKI, A. & OKTAY, H. 2008. A comparison of dentoalveolar inclination treated by two palatal expanders. *The European Journal of Orthodontics*, 30, 67-72.
146. KILIÇ, N. & OKTAY, H. 2008. Effects of rapid maxillary expansion on nasal breathing and some naso-respiratory and breathing problems in growing children: a literature review. *International journal of pediatric otorhinolaryngology*, 72, 1595-1601.
147. KIM, Y.-J., HONG, J.-S., HWANG, Y.-I. & PARK, Y.-H. 2010. Three-dimensional analysis of pharyngeal airway in

- preadolescent children with different anteroposterior skeletal patterns. *American Journal of Orthodontics and Dentofacial Orthopedics*, 137, 306.e1-306.e11.
148. KISHI, K., NAKAJIMA, H. & IMANISHI, N. 2007. Distally based greater saphenous venoadipofascial-sartorius muscle combined flap with venous anastomosis. *Plast Reconstr Surg*, 119, 1808-12.
149. KORIOTH, T. & VERSLUIS, A. 1997. Modeling the mechanical behavior of the jaws and their related structures by finite element (FE) analysis. *Critical Reviews in Oral Biology & Medicine*, 8, 90-104.
150. KORKHAUS, G. 1953. Discussion of report: a review of orthodontics research. *Int. Dental J.*, Ottawa, 3, 356-367.
151. KORN, E. & BAUMRIND, S. 1990. Transverse development of the human jaws between the ages of 8.5 and 15.5 years, studied longitudinally with use of implants. *Journal of dental research*, 69, 1298-1306.
152. KREBS, A. 1959. Expansion of the midpalatal suture, studied by means of metallic implants. *Acta Odontologica*, 17, 491-501.
153. KREBS, A. Midpalatal suture expansion studies by the implant method over a seven-year period. Report of the congress. *European Orthodontic Society*, 1964. 131.
154. KUROL, J., MODIN, H. & BJERKHOEL, A. 1998. Orthodontic maxillary expansion and its effect on nocturnal enuresis. *The Angle Orthodontist*, 68, 225-232.
155. LAGRAVERE, M. O. 2005. The treatment effects of Invisalign orthodontic aligners A systematic review. *The Journal of the American Dental Association*, 136, 1724-1729.

156. LAGRAVÈRE, M. O., CAREY, J., TOOGOOD, R. W. & MAJOR, P. W. 2008. Three-dimensional accuracy of measurements made with software on cone-beam computed tomography images. *American Journal of Orthodontics and Dentofacial Orthopedics*, 134, 112-116.
157. LAGRAVÈRE, M. O., HANSEN, L., HARZER, W. & MAJOR, P. W. 2006a. Plane orientation for standardization in 3-dimensional cephalometric analysis with computerized tomography imaging. *American journal of orthodontics and dentofacial orthopedics*, 129, 601-604.
158. LAGRAVÈRE, M. O., HEO, G., MAJOR, P. W. & FLORES-MIR, C. 2006b. Meta-analysis of immediate changes with rapid maxillary expansion treatment. *The Journal of the American Dental Association*, 137, 44-53.
159. LAGRAVERE, M. O., MAJOR, P. W. & FLORES-MIR, C. 2005a. Long-term dental arch changes after rapid maxillary expansion treatment: a systematic review. *The Angle orthodontist*, 75, 155-161.
160. LAGRAVERE, M. O., MAJOR, P. W. & FLORES-MIR, C. 2005b. Long-term skeletal changes with rapid maxillary expansion: a systematic review. *The Angle orthodontist*, 75, 1046-1052.
161. LAM, D. J., JAMES, K. T. & WEAVER, E. M. 2006. Comparison of anatomic, physiological, and subjective measures of the nasal airway. *American journal of rhinology*, 20, 463-470.
162. LAMPARSKI JR, D. G., RINCHUSE, D. J., CLOSE, J. M. & SCIOTE, J. J. 2003. Comparison of skeletal and dental changes between 2-point and 4-point rapid palatal expanders.

- American journal of orthodontics and dentofacial orthopedics, 123, 321-328.
163. LANE, A., ZWEIMAN, B., LANZA, D., SWIFT, D., DOTY, R., DHONG, H. & KENNEDY, D. 1996. Acoustic rhinometry in the study of the acute nasal allergic response. *The Annals of otology, rhinology, and laryngology*, 105, 811-818.
164. LANGFORD, S. & SIMS, M. 1982. Root surface resorption, repair, and periodontal attachment following rapid maxillary expansion in man. *American journal of orthodontics*, 81, 108-115.
165. LANIGAN, D. T. & MINTZ, S. M. 2002. Complications of surgically assisted rapid palatal expansion: review of the literature and report of a case. *Journal of oral and maxillofacial surgery*, 60, 104-110.
166. LAPTOOK, T. 1981. Conductive hearing loss and rapid maxillary expansion: Report of a case. *American journal of orthodontics*, 80, 325-331.
167. LARSSON, E. 1986. The effect of dummy-sucking on the occlusion: a review. *The European Journal of Orthodontics*, 8, 127-130.
168. LATHAM, R. 1971. The development, structure and growth pattern of the human mid-palatal suture. *Journal of anatomy*, 108, 31.
169. LENZA, M., LENZA, M. D. O., DALSTRA, M., MELSEN, B. & CATTANEO, P. 2010. An analysis of different approaches to the assessment of upper airway morphology: a CBCT study. *Orthodontics & craniofacial research*, 13, 96-105.

170. LEVINE, M. & ENSOM, M. H. 2001. Post hoc power analysis: an idea whose time has passed? *Pharmacotherapy*, 21, 405-9.
171. LIM, J., LASSERSON, T., FLEETHAM, J. & WRIGHT, J. 2006. Oral appliances for obstructive sleep apnoea. *Cochrane Database Syst Rev*, 1.
172. LINDER-ARONSON, S. 1970. Adenoids. Their effect on mode of breathing and nasal airflow and their relationship to characteristics of the facial skeleton and the dentition. A biometric, rhino-manometric and cephalometro-radiographic study on children with and without adenoids. *Acta otolaryngologica. Supplementum*, 265, 1.
173. LIONE, R., BALLANTI, F., FRANCHI, L., BACCETTI, T. & COZZA, P. 2008. Treatment and posttreatment skeletal effects of rapid maxillary expansion studied with low-dose computed tomography in growing subjects. *American journal of orthodontics and dentofacial orthopedics*, 134, 389-392.
174. LOWE, A. A., GIONHAKU, N., TAKEUCHI, K. & FLEETHAM, J. A. 1986. Three-dimensional CT reconstructions of tongue and airway in adult subjects with obstructive sleep apnea. *American Journal of Orthodontics and Dentofacial Orthopedics*, 90, 364-374.
175. LUDLOW, J., DAVIES-LUDLOW, L. & BROOKS, S. 2003. Dosimetry of two extraoral direct digital imaging devices: NewTom cone beam CT and Orthophos Plus DS panoramic unit. *Dentomaxillofacial Radiology*, 32, 229-234.
176. MADANI, M. & MADANI, F. 2007. The pandemic of obesity and its relationship to sleep apnea. *Atlas of the Oral and Maxillofacial Surgery Clinics*, 15, 81-88.

177. MAGLIOCCA, K. R. & HELMAN, J. I. 2005. Obstructive sleep apnea Diagnosis, medical management and dental implications. *The Journal of the American Dental Association*, 136, 1121-1129.
178. MAH, J. & HATCHER, D. 2004. Three-dimensional craniofacial imaging. *American journal of orthodontics and dentofacial orthopedics*, 126, 308-309.
179. MAH, J. K., DANFORTH, R. A., BUMANN, A. & HATCHER, D. 2003. Radiation absorbed in maxillofacial imaging with a new dental computed tomography device. *Oral Surgery, Oral Medicine, Oral Pathology, Oral Radiology, and Endodontology*, 96, 508-513.
180. MAH, P., REEVES, T. E. & MCDAVID, W. D. 2010. Deriving Hounsfield units using grey levels in cone beam computed tomography. *Dentomaxillofac Radiol*, 39, 323-35.
181. MALHOTRA, A., HUANG, Y., FOGEL, R. B., PILLAR, G., EDWARDS, J. K., KIKINIS, R., LORING, S. H. & WHITE, D. P. 2002. The male predisposition to pharyngeal collapse: importance of airway length. *American Journal of Respiratory and Critical Care Medicine*, 166, 1388-1395.
182. MCDONALD, J. P. 1995. Airway problems in children-- can the orthodontist help? *Ann Acad Med Singapore*, 24, 158-62.
183. MCNAMARA JR, J. A. 1981a. Components of Class II malocclusion in children 8-10 years of age. *The Angle Orthodontist*, 51, 177-202.
184. MCNAMARA JR, J. A. 1981b. Influence of respiratory pattern on craniofacial growth. *The Angle Orthodontist*, 51, 269-300.

185. MCNAMARA JR, J. A., BACCETTI, T., FRANCHI, L. & HERBERGER, T. A. 2003. Rapid maxillary expansion followed by fixed appliances: a long-term evaluation of changes in arch dimensions. *The Angle orthodontist*, 73, 344-353.
186. MCQUIELLEN, J. 1860. Review of the dental literature and art: Separation of the superior maxilla in the correction of irregularity of teeth. *Dental Cosmos*, 2, p. 170-173., .
187. MCROBBIE, D. W., PRITCHARD, S. & QUEST, R. A. 2003. Studies of the human oropharyngeal airspaces using magnetic resonance imaging. I. Validation of a three-dimensional MRI method for producing ex vivo virtual and physical casts of the oropharyngeal airways during inspiration. *Journal of aerosol medicine*, 16, 401-415.
188. MEHRA, P., DOWNIE, M., PITA, M. C. & WOLFORD, L. M. 2001. Pharyngeal airway space changes after counterclockwise rotation of the maxillomandibular complex. *American Journal of Orthodontics and Dentofacial Orthopedics*, 120, 154-159.
189. MELSEN, B. 1975. Palatal growth studied on human autopsy material: a histologic microradiographic study. *American journal of orthodontics*, 68, 42-54.
190. MELSEN, B. & MELSEN, F. 1982. The postnatal development of the palatomaxillary region studied on human autopsy material. *American journal of orthodontics*, 82, 329-342.
191. MEMIKOĞLU, T. & ISERI, H. 1997. Nonextraction treatment with a rigid acrylic, bonded rapid maxillary expander. *Journal of clinical orthodontics: JCO*, 31, 113.

192. MEMIKOGLU, T. U. T. & ISERI, H. 1999. Effects of a bonded rapid maxillary expansion appliance during orthodontic treatment. *The Angle Orthodontist*, 69, 251-256.
193. MEW, J. 1983. Relapse following maxillary expansion: a study of twenty-five consecutive cases. *American journal of orthodontics*, 83, 56-61.
194. MILES, D. A. 2008. *Color atlas of cone beam volumetric imaging for dental applications*, Quintessence Pub.
195. MOMMAERTS, M. 1999. Transpalatal distraction as a method of maxillary expansion. *British Journal of Oral and Maxillofacial Surgery*, 37, 268-272.
196. MOSS, M. L. 1997. The functional matrix hypothesis revisited. 1. The role of mechanotransduction. *American journal of orthodontics and dentofacial orthopedics*, 112, 8-11.
197. MOZZO, P., PROCACCI, C., TACCONI, A., MARTINI, P. T. & ANDREIS, I. B. 1998. A new volumetric CT machine for dental imaging based on the cone-beam technique: preliminary results. *European radiology*, 8, 1558-1564.
198. MURRAY, J. M. G. & CLEALL, J. F. 1971. Early tissue response to rapid maxillary expansion in the midpalatal suture of the rhesus monkey. *Journal of dental research*, 50, 1654-1660.
199. MUTINELLI, S., COZZANI, M., MANFREDI, M., BEE, M. & SICILIANI, G. 2008. Dental arch changes following rapid maxillary expansion. *The European Journal of Orthodontics*, 30, 469-476.
200. MUTO, S., YOSHII, T., SAITO, K., KAMIYAMA, Y., IDE, H. & HORIE, S. 2008. Focal therapy with high-intensity-focused ultrasound in the treatment of localized prostate cancer. *Japanese journal of clinical oncology*, 38, 192-199.

201. MUTO, T., TAKEDA, S., KANAZAWA, M., YAMAZAKI, A., FUJIWARA, Y. & MIZOGUCHI, I. 2002. The effect of head posture on the pharyngeal airway space (PAS). *International journal of oral and maxillofacial surgery*, 31, 579-583.
202. NEEDLEMAN, H. L., HOANG, C., ALLRED, E., HERTZBERG, J. & BERDE, C. 2000. Reports of pain by children undergoing rapid palatal expansion. *Pediatric Dentistry*, 22, 221-226.
203. NEELEY II, W. W., EDGIN, W. A. & GONZALES, D. A. 2007. A review of the effects of expansion of the nasal base on nasal airflow and resistance. *Journal of oral and maxillofacial surgery*, 65, 1174-1179.
204. NETTER, F. H. 2010. *Atlas of human anatomy*, Elsevier Health Sciences.
205. NEYT, N. M., MOMMAERTS, M. Y., ABELOOS, J. V., DE CLERCQ, C. A. & NEYT, L. F. 2002. Problems, obstacles and complications with transpalatal distraction in non-congenital deformities. *Journal of Cranio-Maxillofacial Surgery*, 30, 139-143.
206. NGAN, P., HÄGG, U., YIU, C., MERWIN, D. & WEI, S. H. 1996. Treatment response to maxillary expansion and protraction. *The European Journal of Orthodontics*, 18, 151-168.
207. NUMMINEN, J., DASTIDAR, P., HEINONEN, T., KARHUKETO, T. & RAUTIAINEN, M. 2003. Reliability of acoustic rhinometry. *Respiratory medicine*, 97, 421-427.
208. O'RAHILLY, R., MULLER, F., CARPENTER, S. & SWENSON, R. 1967. *Nose and paranasal sinuses*. Gardner E,

- Gray DJ, O'Rahilly R: Anatomy, 2nd ed. Philadelphia, WB Saunders Co, 924-932.
209. ODENRICK, L., KARLANDER, E. L., PIERCE, A., FRACDS, O. D. & KRETSCHMAR, U. 1991. Surface resorption following two forms of rapid maxillary expansion. *The European Journal of Orthodontics*, 13, 264-270.
210. OGAWA, T., ENCISO, R., SHINTAKU, W. H. & CLARK, G. T. 2007. Evaluation of cross-section airway configuration of obstructive sleep apnea. *Oral Surgery, Oral Medicine, Oral Pathology, Oral Radiology, and Endodontology*, 103, 102-108.
211. ONG, S., KHAMBAY, B., MCDONALD, J., CROSS, D., BROCKLEBANK, L. & JU, X. 2013. The novel use of three-dimensional surface models to quantify and visualise the immediate changes of the mid-facial skeleton following rapid maxillary expansion. *The Surgeon*.
212. PALAISA, J., NGAN, P., MARTIN, C. & RAZMUS, T. 2007. Use of conventional tomography to evaluate changes in the nasal cavity with rapid palatal expansion. *American Journal of Orthodontics and Dentofacial Orthopedics*, 132, 458-466.
213. PALOMO, J. M., KAU, C., PALOMO, L. B. & HANS, M. G. 2006. Three-dimensional cone beam computerized tomography in dentistry. *Dentistry today*, 25, 130.
214. PANGRAZIO-KULBERSH, V., WINE, P., HAUGHEY, M., PAJTAS, B. & KACZYNSKI, R. 2011. Cone beam computed tomography evaluation of changes in the naso-maxillary complex associated with two types of maxillary expanders. *The Angle Orthodontist*, 82, 448-457.

215. PERIAGO, D. R., SCARFE, W. C., MOSHIRI, M., SCHEETZ, J. P., SILVEIRA, A. M. & FARMAN, A. G. 2008. Linear accuracy and reliability of cone beam CT derived 3-dimensional images constructed using an orthodontic volumetric rendering program. *The Angle orthodontist*, 78, 387-395.
216. PERSSON, M. & THILANDER, B. 1977. Palatal suture closure in man from 15 to 35 years of age. *Am J Orthod*, 72, 42-52.
217. PETRÉN, S. & BONDEMARK, L. 2008. Correction of unilateral posterior crossbite in the mixed dentition: a randomized controlled trial. *American Journal of Orthodontics and Dentofacial Orthopedics*, 133, 790. e7-790. e13.
218. PILLAR, G., MALHOTRA, A., FOGEL, R., BEAUREGARD, J. E., SCHNALL, R. & WHITE, D. P. 2000. Airway mechanics and ventilation in response to resistive loading during sleep: influence of gender. *American journal of respiratory and critical care medicine*, 162, 1627-1632.
219. PIRELLI, P., SAPONARA, M. & GUILLEMINAULT, C. 2004. Rapid maxillary expansion in children with obstructive sleep apnea syndrome. *Sleep*, 27, 761-766.
220. PODESSER, B., WILLIAMS, S., CRISMANI, A. G. & BANTLEON, H.-P. 2007. Evaluation of the effects of rapid maxillary expansion in growing children using computer tomography scanning: a pilot study. *The European Journal of Orthodontics*, 29, 37-44.
221. PRINSELL, J. R. 2000. Maxillomandibular advancement (MMA) in a site-specific treatment approach for obstructive sleep apnea: a surgical algorithm. *Sleep and Breathing*, 4, 147-154.

222. PRITCHARD, J., SCOTT, J. & GIRGIS, F. 1956a. The structure and development of cranial and facial sutures. *Journal of anatomy*, 90, 73.
223. PRITCHARD, J., SCOTT, J. & GIRGIS, F. G. 1956b. The structure and development of cranial and facial sutures. *Journal of anatomy*, 90, 73.
224. PROFFIT, W. 2007. Contemporary orthodontic appliances. *Contemporary Orthodontics*" 4th ed, Proffit WR, Fields HW, Sarver DM ed, Mosby Co, St. Louis, 414.
225. PROFFIT, W. R. & FIELDS, H. 2000. Contemporary orthodontics Mosby. St Louis, 78, 315.
226. PROVATIDIS, C., GEORGIOPOULOS, B., KOTINAS, A. & MCDONALD, J. 2007. On the FEM modeling of craniofacial changes during rapid maxillary expansion. *Medical engineering & physics*, 29, 566-579.
227. PROVATIDIS, C., GEORGIOPOULOS, B., KOTINAS, A. & MCDONALD, J. 2008a. Evaluation of craniofacial effects during rapid maxillary expansion through combined in vivo/in vitro and finite element studies. *The European Journal of Orthodontics*, 30, 437-448.
228. PROVATIDIS, C. G., GEORGIOPOULOS, B., KOTINAS, A. & MCDONALD, J. P. 2008b. Evaluation of craniofacial effects during rapid maxillary expansion through combined in vivo/in vitro and finite element studies. *Eur J Orthod*, 30, 437-48.
229. RAVELLI, R. B., THEVENEAU, P., MCSWEENEY, S. & CAFFREY, M. 2002. Unit-cell volume change as a metric of radiation damage in crystals of macromolecules. *Journal of synchrotron radiation*, 9, 355-360.

230. RIBEIRO, A. N. C., DE PAIVA, J. B., RINO-NETO, J., ILLIPRONTI-FILHO, E., TRIVINO, T. & FANTINI, S. M. 2011. Upper airway expansion after rapid maxillary expansion evaluated with cone beam computed tomography. *The Angle Orthodontist*, 82, 458-463.
231. ROMANES, G. 1986. *Cunningham's Manual of Practical Anatomy: Volume 3: Head and Neck and Brain*, Oxford University Press.
232. RUNGCHARASSAENG, K., CARUSO, J. M., KAN, J. Y., KIM, J. & TAYLOR, G. 2007. Factors affecting buccal bone changes of maxillary posterior teeth after rapid maxillary expansion. *American Journal of Orthodontics and Dentofacial Orthopedics*, 132, 428. e1-428. e8.
233. RUSHTON, H. G. 1989. Nocturnal enuresis: epidemiology, evaluation, and currently available treatment options. *The Journal of pediatrics*, 114, 691-696.
234. SANDER, C., HÜFFMEIER, S., SANDER, F. M. & SANDER, F. G. 2006. Initial results regarding force exertion during rapid maxillary expansion in children. *Journal of Orofacial Orthopedics/Fortschritte der Kieferorthopädie*, 67, 19-26.
235. SANDIKCIOGLU, M. & HAZAR, S. 1997. Skeletal and dental changes after maxillary expansion in the mixed dentition. *Am J Orthod Dentofacial Orthop*, 111, 321-7.
236. SANDSTROM, R. A., KLAPPER, L. & PAPACONSTANTINO, S. 1988. Expansion of the lower arch concurrent with rapid maxillary expansion. *American Journal of Orthodontics and Dentofacial Orthopedics*, 94, 296-302.

237. SARDESSAI, G. & FERNANDESH, A. S. 2004. Gingival necrosis in relation to palatal expansion appliance: an unwanted sequelae. *Journal of Clinical Pediatric Dentistry*, 28, 43-45.
238. SARI, Z., UYSAL, T., USUMEZ, S. & BASCIFTCI, F. A. 2003. Rapid maxillary expansion. Is it better in the mixed or in the permanent dentition? *The Angle Orthodontist*, 73, 654-661.
239. SARVER, D. M. & JOHNSTON, M. W. 1989. Skeletal changes in vertical and anterior displacement of the maxilla with bonded rapid palatal expansion appliances. *American Journal of Orthodontics and Dentofacial Orthopedics*, 95, 462-466.
240. SAYINSU, K., ISIK, F., TRAKYALI, G. & ARUN, T. 2007. An evaluation of the errors in cephalometric measurements on scanned cephalometric images and conventional tracings. *The European Journal of Orthodontics*, 29, 105-108.
241. SCHENDEL, S. A. & HATCHER, D. 2010. Automated 3-Dimensional Airway Analysis From Cone-Beam Computed Tomography Data. *Journal of Oral and Maxillofacial Surgery*, 68, 696-701.
242. SCHNEIDMAN, E., WILSON, S. & ERKIS, R. 1990. Two-point rapid palatal expansion: an alternate approach to traditional treatment. *Pediatr Dent*, 12, 92-7.
243. SCHÜTZ-FRANSSON, U. & KUROL, J. 2008. Rapid maxillary expansion effects on nocturnal enuresis in children: A follow-up study. *The Angle Orthodontist*, 78, 201-208.

244. SHARABI, Y., DAGAN, Y. & GROSSMAN, E. 2004. Sleep apnea as a risk factor for hypertension. *Current opinion in nephrology and hypertension*, 13, 359-364.
245. SHELTON, R. L. & BOSMA, J. F. 1962. Maintenance of the pharyngeal airway. *Journal of applied physiology*, 17, 209-214.
246. SIGN 2003. Management of Obstructive Sleep
247. Apnoea/Hypopnoea Syndrome in Adults, A national clinical guideline. In: SIGN (ed.). Scotland: British Thoracic Society.
248. SILKOFF, P. E., CHAKRAVORTY, S., CHAPNIK, J., COLE, P. & ZAMEL, N. 1999. Reproducibility of acoustic rhinometry and rhinomanometry in normal subjects. *American Journal of Rhinology*, 13, 131-135.
249. SKIELLER, V. 1964. EXPANSION OF THE MIDPALATAL SUTURE BY REMOVABLE PALATES, ANALYSED BY THE IMPLANT METHOD. *Rep Congr Eur Orthod Soc*, 40, 143-58.
250. SMITH, T., GHONEIMA, A., STEWART, K., LIU, S., ECKERT, G., HALUM, S. & KULA, K. 2012. Three-dimensional computed tomography analysis of airway volume changes after rapid maxillary expansion. *American Journal of Orthodontics and Dentofacial Orthopedics*, 141, 618-626.
251. SNODELL, S. F., NANDA, R. S. & CURRIER, G. F. 1993. A longitudinal cephalometric study of transverse and vertical craniofacial growth. *American Journal of Orthodontics and Dentofacial Orthopedics*, 104, 471-483.
252. SOLOW, B. & TALLGREN, A. 1971. Natural head position in standing subjects. *Acta odontologica*, 29, 591-607.

253. SPOLYAR, J. L. 1984. The design, fabrication, and use of a full-coverage bonded rapid maxillary expansion appliance. *American journal of orthodontics*, 86, 136-145.
254. STARNBACH, H., BAYNE, D., CLEALL, J. & SUBTELNY, J. D. 1966. Facioskeletal And Dental Changes Resulting From Rapid Maxillary Expansion*. *The Angle Orthodontist*, 36, 152-164.
255. STEPOVICH, M. L. 1965. A cephalometric positional study of the hyoid bone. *American journal of orthodontics*, 51, 882-900.
256. STOCKFISCH, H. Rapid expansion of the maxilla--success and relapse. Report of the congress. *European Orthodontic Society*, 1969. 469.
257. STRATEMANN, S., HUANG, J., MAKI, K., MILLER, A. & HATCHER, D. 2008. Comparison of cone beam computed tomography imaging with physical measures. *Dentomaxillofacial Radiology*, 37, 80-93.
258. SUBTELNY, J. D. 1954. The Significance of Adenoid Tissue in Orthodontia*. *The Angle Orthodontist*, 24, 59-69.
259. TANNE, K., HIRAGA, J., KAKIUCHI, K., YAMAGATA, Y. & SAKUDA, M. 1989a. Biomechanical effect of anteriorly directed extraoral forces on the craniofacial complex: a study using the finite element method. *American Journal of Orthodontics and Dentofacial Orthopedics*, 95, 200-207.
260. TANNE, K., HIRAGA, J. & SAKUDA, M. 1989b. Effects of directions of maxillary protraction forces on biomechanical changes in craniofacial complex. *The European Journal of Orthodontics*, 11, 382-391.

261. TERHEYDEN, H., MAUNE, S., MERTENS, J. & HILBERG, O. 2000. Acoustic rhinometry: validation by three-dimensionally reconstructed computer tomographic scans. *Journal of Applied Physiology*, 89, 1013-1021.
262. THILANDER, B. & MYRBERG, N. 1973. The prevalence of malocclusion in Swedish schoolchildren. *European Journal of Oral Sciences*, 81, 12-20.
263. TIMMS, D. 1974. Some medical aspects of rapid maxillary expansion. *British journal of orthodontics*, 1, 127.
264. TIMMS, D. 1976. Long term follow-up of cases treated by rapid maxillary expansion. *Trans Eur Orthod Soc*, 52, 211-215.
265. TIMMS, D. 1986. The effect of rapid maxillary expansion on nasal airway resistance. *Journal of Orthodontics*, 13, 221-228.
266. TIMMS, D. & MOSS, J. 1971. An histological investigation into the effects of rapid maxillary expansion on the teeth and their supporting tissues. *Transactions. European Orthodontic Society*, 263.
267. TIMMS, D., PRESTON, C. & DALY, P. 1982. A computed tomographic assessment of maxillary movement induced by rapid expansion—a pilot study. *The European Journal of Orthodontics*, 4, 123-127.
268. TIMMS, D. J. 1980. A study of basal movement with rapid maxillary expansion. *American journal of orthodontics*, 77, 500-507.
269. TIMMS, D. J. 1981. *Rapid maxillary expansion*, Quintessence Publishing Company.

270. TIMMS, D. J. 1990. Rapid maxillary expansion in the treatment of nocturnal enuresis. *The Angle Orthodontist*, 60, 229-233.
271. TIMMS, D. J. 1999. The dawn of rapid maxillary expansion. *The Angle Orthodontist*, 69, 247-250.
272. TOMKINSON, A. & ECCLES, R. 1995. Errors arising in cross-sectional area estimation by acoustic rhinometry produced by breathing during measurement. *Rhinology*, 33, 138.
273. TSO, H. H., LEE, J. S., HUANG, J. C., MAKI, K., HATCHER, D. & MILLER, A. J. 2009. Evaluation of the human airway using cone-beam computerized tomography. *Oral Surgery, Oral Medicine, Oral Pathology, Oral Radiology, and Endodontology*, 108, 768-776.
274. USUMEZ, S., İSERI, H., ORHAN, M. & BASCIFTCI, F. A. 2003. Effect of rapid maxillary expansion on nocturnal enuresis. *The Angle orthodontist*, 73, 532-538.
275. VAN DE WATER, T. R. & STAECKER, H. 2006. *Otolaryngology: basic science and clinical review*, Thieme.
276. VANARSDALL, R. 1994. Periodontal/orthodontic interrelationships. _____. GRABER, T.; VANARSDAL, L R. *Orthodontics: current principles and techniques*. St. Louis: Mosby, 712-749.
277. VELÁZQUEZ, P., BENITO, E. & BRAVO, L. A. 1996. Rapid maxillary expansion. A study of the long-term effects. *American journal of orthodontics and dentofacial orthopedics*, 109, 361-367.
278. VERSTRAATEN, J., KUIJPERS-JAGTMAN, A. M., MOMMAERTS, M. Y., BERGE, S. J., NADA, R. M. & SCHOLS, J. G. 2010. A systematic review of the effects of

- bone-borne surgical assisted rapid maxillary expansion. *J Craniomaxillofac Surg*, 38, 166-74.
279. VIG, K. W. 1998. Nasal obstruction and facial growth: the strength of evidence for clinical assumptions. *American journal of orthodontics and dentofacial orthopedics*, 113, 603-611.
280. WATSON JR, R. M., WARREN, D. W. & FISCHER, N. D. 1968. Nasal resistance, skeletal classification, and mouth breathing in orthodontic patients. *American journal of orthodontics*, 54, 367-379.
281. WEISSHEIMER, A., MENEZES, L. M. D., SAMESHIMA, G. T., ENCISO, R., PHAM, J. & GRAUER, D. 2012. Imaging software accuracy for 3-dimensional analysis of the upper airway. *American Journal of Orthodontics and Dentofacial Orthopedics*, 142, 801-813.
282. WERTZ, R. & DRESKIN, M. 1977. Midpalatal suture opening: a normative study. *American journal of orthodontics*, 71, 367-381.
283. WERTZ, R. A. 1968. Changes in nasal airflow incident to rapid maxillary expansion. *The Angle Orthodontist*, 38, 1-11.
284. WERTZ, R. A. 1970. Skeletal and dental changes accompanying rapid midpalatal suture opening. *American journal of orthodontics*, 58, 41-66.
285. WHEELER, S. M. & COREY, J. P. 2008. Evaluation of upper airway obstruction—An ENT perspective. *Pulmonary pharmacology & therapeutics*, 21, 433-441.
286. WHITE, B., WOODSIDE, D. & COLE, P. 1989. The effect of rapid maxillary expansion on nasal airway resistance. *The Journal of otolaryngology*, 18, 137.

287. WIPPOLD, F. J. 2007. Head and neck imaging: the role of CT and MRI. *Journal of magnetic resonance imaging*, 25, 453-465.
288. WOODSIDE, D. G. & LINDER-ARONSON, S. 1979. The channelization of upper and lower anterior face heights compared to population standard in males between ages 6 to 20 years. *The European Journal of Orthodontics*, 1, 25-40.
289. WRIEDT, S., KUNKEL, M., ZENTNER, A. & WAHLMANN, U.-W. 2001. Surgically Assisted Rapid Palatal Expansion An Acoustic Rhinometric, Morphometric and Sonographic Investigation. *Journal of Orofacial Orthopedics/Fortschritte der Kieferorthopädie*, 62, 107-115.
290. WRIGHT, G. H. 1912a. A Group of deformities of the nasal respiratory tract, coincident with dental irregularities ii. a new instrument for comparative measurements. *Dent Cosmos*, 54, 261-9.
291. WRIGHT, G. H. 1912b. A Group of Deformities of the Nasal Respiratory Tract, Coincident with Dental Irregularities. II. A New Instrument for Comparative Measurements. *Dental Cosmos*, 54, 261-269.
292. YAMASHINA, A., TANIMOTO, K., SUTTHIPRAPAPORN, P. & HAYAKAWA, Y. 2008. The reliability of computed tomography (CT) values and dimensional measurements of the oropharyngeal region using cone beam CT: comparison with multidetector CT. *Dentomaxillofacial Radiology*, 37, 245-251.
293. YUSHKEVICH, P. A., PIVEN, J., HAZLETT, H. C., SMITH, R. G., HO, S., GEE, J. C. & GERIG, G. 2006. User-guided 3D active contour segmentation of anatomical structures:

Significantly improved efficiency and reliability. *NeuroImage*, 31, 1116-1128.

294. ZAVRAS, A., WHITE, G., RICH, A. & JACKSON, A. 1994. Acoustic rhinometry in the evaluation of children with nasal or oral respiration. *The Journal of clinical pediatric dentistry*, 18, 203.
295. ZHAO, Y., NGUYEN, M., GOHL, E., MAH, J. K., SAMESHIMA, G. & ENCISO, R. 2010. Oropharyngeal airway changes after rapid palatal expansion evaluated with cone-beam computed tomography. *American Journal of Orthodontics and Dentofacial Orthopedics*, 137, S71-S78.
296. ZHOU, Y., LONG, H., YE, N., XUE, J., YANG, X., LIAO, L. & LAI, W. 2013. The effectiveness of non-surgical maxillary expansion: a meta-analysis. *The European Journal of Orthodontics*, cjt044.
297. ZIMRING, J. F. & ISAACSON, R. J. 1965. Forces produced by rapid maxillary expansion: III. Forces present during retention. *The Angle Orthodontist*, 35, 178-186.
298. ZWEIMAN, B., GETSY, J., KALENIAN, M., LANE, A., SCHWARTZ, L. B., DOTY, R. & LANZA, D. 1997. Nasal airway changes assessed by acoustic rhinometry and mediator release during immediate and late reactions to allergen challenge. *Journal of allergy and clinical immunology*, 100, 624-631.