



You have downloaded a document from
RE-BUŚ
repository of the University of Silesia in Katowice

Title: Compression Anastomosis Clips Versus a Hand-Sewn Technique for Intestinal Anastomosis in Pigs

Author: Katarzyna Kuśnierz, Maciej Kajor, Dmytro Zaworonkow, Zdzisław Lekston, Monika Ciupińska-Kajor, Mariusz Seweryn, Paweł Lampe

Citation style: Kuśnierz Katarzyna, Kajor Maciej, Zaworonkow Dmytro, Lekston Zdzisław, Ciupińska-Kajor Monika, Seweryn Mariusz, Lampe Paweł. (2015). Compression Anastomosis Clips Versus a Hand-Sewn Technique for Intestinal Anastomosis in Pigs. "Advances in Clinical and Experimental Medicine" Nr 6 (2015), s. 1019-1029. doi: 10.17219/acem/50070



Uznanie autorstwa - Użycie niekomercyjne - Bez utworów zależnych Polska - Licencja ta zezwala na rozpowszechnianie, przedstawianie i wykonywanie utworu jedynie w celach niekomercyjnych oraz pod warunkiem zachowania go w oryginalnej postaci (nie tworzenia utworów zależnych).



UNIwersYTET ŚLĄSKI
W KATOWICACH



Biblioteka
Uniwersytetu Śląskiego



Ministerstwo Nauki
i Szkolnictwa Wyższego

KATARZYNA KUŚNIERZ^{1, A–F}, MACIEJ KAJOR^{2, C, E, F}, DMYTRO ZAWORONKOW^{3, B, C, F},
ZDZISŁAW LEKSTON^{4, B, C, F}, MONIKA CIUPIŃSKA-KAJOR^{2, B, C, F}, MARIUSZ SEWERYN^{5, C, F},
PAWEŁ LAMPE^{1, A, E, F}

Compression Anastomosis Clips Versus a Hand-Sewn Technique for Intestinal Anastomosis in Pigs^{*}

¹ Department of Gastrointestinal Surgery, Medical University of Silesia, Katowice, Poland

² Department of Pathomorphology, Medical University of Silesia, Katowice, Poland

³ Department of Gastrointestinal Surgery, Central Teaching Hospital, Katowice, Poland

⁴ Institute of Materials Science, University of Silesia, Katowice, Poland

⁵ Medical University of Silesia, Katowice, Poland

A – research concept and design; B – collection and/or assembly of data; C – data analysis and interpretation; D – writing the article; E – critical revision of the article; F – final approval of article

Abstract

Background. Anastomotic dehiscence and leaks are major problems in gastrointestinal surgery and result in increased morbidity and mortality. The ideal device to create anastomoses should ensure good serosal apposition without requiring either transgression of the bowel wall or the presence of foreign material for an extended period of time.

Objectives. The aim of this experimental study was to evaluate the safety and efficacy of a new compression anastomosis clip (CAC) for jejunojunostomies and ileocolostomies by comparing CAC anastomoses with hand-sewn (HS) anastomoses in pigs in terms of healing, breaking strength and the time to create anastomoses.

Material and Methods. The 11 pigs in the study underwent side-to-side CAC and HS jejunojunostomies and ileocolostomies, for a total of 88 anastomoses. The pigs were sacrificed on postoperative day 5 (5 pigs) or 7 (6 pigs). Macroscopic, histopathological and breaking-strength examinations were performed. The time to create the anastomoses was recorded.

Results. Neither group had anastomotic complications such as leakage or obstruction. Macroscopic examination showed no statistically significant differences between the groups. In the CAC group, the healing process was characterized by a lesser inflammatory reaction ($p < 0.05$) and very thin scar tissue at the anastomotic line (less collagen deposition and better epithelial regeneration), while the HS group had a much thicker anastomotic line. The breaking strength was significantly greater in the CAC group compared with the HS group ($p < 0.05$). The anastomosis time was shorter in the CAC group than in the HS group ($p < 0.01$).

Conclusions. Anastomosis using a CAC appears to be safe and less time-consuming than HS; it was also characterized by a good healing process with little inflammatory reaction and a high breaking strength compared with HS anastomosis (*Adv Clin Exp Med* 2015, 24, 6, 000–000).

Key words: breaking strength, healing, pig, intestinal anastomosis, compression anastomosis clip.

Anastomotic dehiscence and leaks are major problems in gastrointestinal surgery and result in increased morbidity and mortality, thus decreasing overall survival. Intestinal anastomosis healing depends on the operative technique, the underlying medical condition, medical treatment and other individual, often unknown, factors [1].

Different types of sutures, staples and sutureless anastomoses have been used to create anastomoses. The ideal device should ensure good serosal apposition without requiring either transgression of the bowel wall or the presence of foreign material for an extended period of time [2]. Healing occurs when the surgical wound is clean and sharp,

* The study was supported by a grant from the Medical University of Silesia, Katowice, Poland (KNW-1-015/N/3/0).

and when there is no infection, minimal loss of tissue and good approximation of the wound edges by suture or adhesive tape. The promotion of primary healing with anatomic apposition of all layers is believed to be important [3].

With a compression anastomosis clip (CAC) made of shape-memory materials, such as a superelastic temperature-dependent nickel-titanium alloy (NiTi) [4], the metal is shaped at a high temperature and loses its rigidity and becomes flexible when it is ice-cooled. At room temperature, it resumes its preset shape. The CAC compresses the walls of the anastomosed gastrointestinal tract together to induce necrosis and initiate the healing process, which leads to fusion of the two lumens (Fig. 1A–D, G) [5, 6]. A scar, which is the basis for a symmetrical and functional anastomosis, is formed at the periphery of the necrosis. The time before the natural expulsion of the clip from the intestine with the stool varies depending on the site of its insertion (Fig. 1E, F).

The use of CACs in humans has been reported [2, 5, 6, 7–13], including a comparison of CAC

anastomoses with stapled anastomoses in the stomach, small intestine, and colon [5–8, 13]. However, to the best of the current authors' knowledge, no comparison of healing between CAC and hand-sewn (HS) anastomoses has previously been reported.

This experimental study aimed at evaluating the safety and efficacy of a CAC for jejunojunostomies and ileocolostomies, and at understanding the basic biology of anastomotic healing. The novel endpoints of the study were early healing and the breaking strength (BS) of a CAC anastomosis, and comparison of these parameters with the same characteristics of a HS anastomosis.

Material and Methods

Study Design

The ethics committee of the Medical University of Silesia (Katowice, Poland) approved all of the animal experiments (permit number 16/2013), and the study was conducted in accordance with

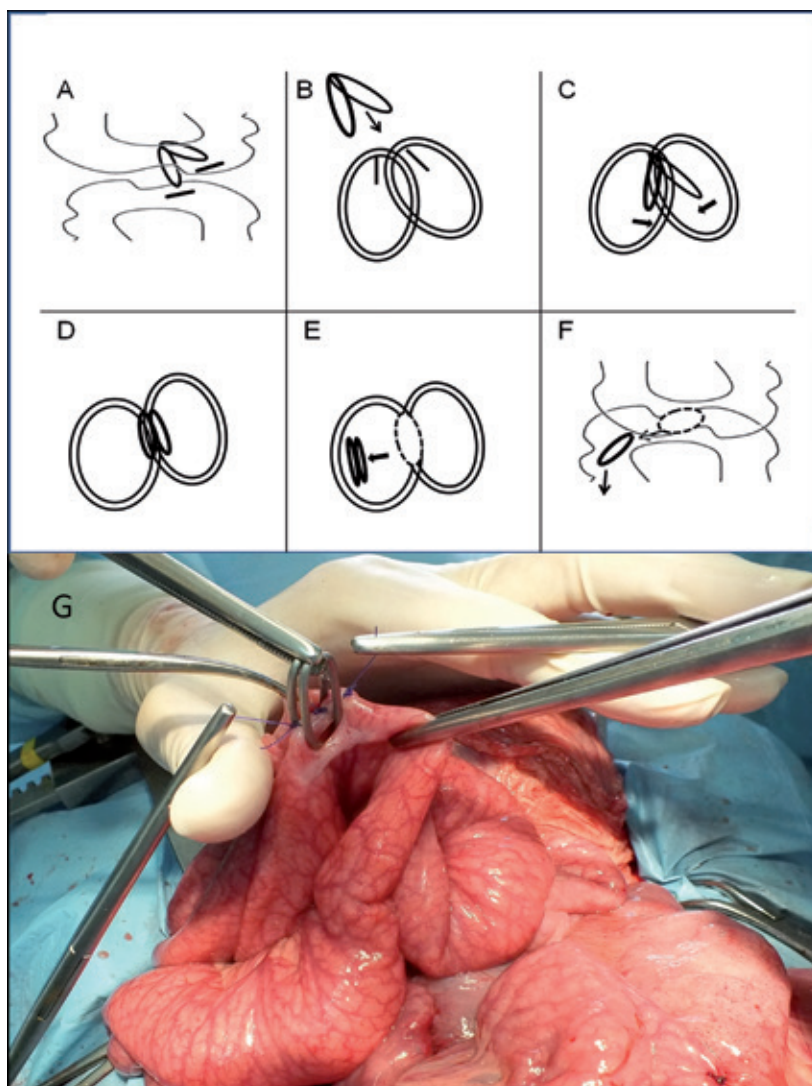


Fig. 1. Diagram (A–F) and intra-operative image (G) of the anastomosis technique using a compression anastomosis clip. CACs in open positions before insertion in the bowel lumina for anastomosis (B, G)

the Helsinki Declaration of 1975. The experiments were carried out on 11 domestic male pigs weighing 50 ± 0.5 kg. The following procedures were performed on each pig, for a total of 88 anastomoses: four side-to-side jejunojejunostomies (two HS and two CAC) and four side-to-side ileocolostomies (two HS and two CAC). Each type of anastomosis was performed on adjacent 10-cm sections of the intestine (mid-jejunum or spiral colon), which did not differ anatomically, histologically or functionally, and did not affect the result of the test [14, 15].

Preoperative care, postoperative care, and postoperative observation were performed by trained animal technicians supervised by veterinarians, who attended the animals daily and when any signs of illness appeared.

The operations were performed by the same two surgeons after the pigs underwent a 48-h fast with free access to water. After the initiation of general anesthesia using subcutaneous atropine (0.05 mg/kg), intramuscular xylazine (3 mg/kg intramuscularly), and intramuscular ketamine (10 mg/kg), all the pigs received similar general anesthesia with intravenous propofol (2–5 mg/kg), intravenous fentanyl (2.5 mg/kg), and inhaled isoflurane (at a concentration of 0.5–3%). The pigs were intubated and maintained on mechanical ventilation.

After the surgery, the animals fasted for 48 h with ad libitum access to water, and then were provided a standard diet. The pigs were monitored for five or seven days for general behavior, food intake, feces production and body temperature. The pigs were then euthanized on postoperative day 5 (5 pigs) or 7 (6 pigs) by intravenous administration of xylazine hydrochloride (6–10 mg/kg), ketamine (6–10 mg/kg) and pentobarbital (0.25 mL/kg). Postoperative days 5 and 7 were chosen to represent the first two phases of healing: the inflammatory phase (days 2–5) and the proliferation phase. The clip separates from the anastomosis after the formation of necrosis beginning on day 5 (the inflammatory phase), and the anastomotic breaking strength increases progressively from postoperative day 7 (the proliferation phase) [5, 16, 17].

Compression Anastomosis Clip

The implants were elliptical bispiral rings made of a NiTi alloy, manufactured in co-operation with the Institute of Materials Science at the University of Silesia (Katowice, Poland). The clip differed in shape and size from the clips available from NiTi Medical Technologies (Netanya, Israel), as well as from other clips used in previous studies [5, 6, 8]. Compared with the clips used in the current authors' previous clinical study, the present clip had lower Ti content (48.7% Ti) [9, 10].

The width of the anastomosis corresponded to the external diameter of the clip (longer, 28 mm; shorter, 11 mm).

Surgical Procedure in the Hand-Sewn Group

The anastomotic technique involved parallel 25–28-mm incisions in the intestinal walls. Side-to-side double layer HS anastomoses were performed using a running 3/0 polydioxanone suture (MonoPlus[®], B. Braun Surgical SA, Rubi, Spain). The anastomosis time was recorded.

Surgical Procedure in the Compression Anastomosis Clip Group

The anastomotic technique involved parallel 5-mm incisions in the intestinal walls at the predicted site of anastomosis creation (Fig. 1A). The CAC was placed in 0°C normal saline for 2 min, allowing the arms to open and form an angle of approximately 30–40° (Fig. 1B). The opened CAC was placed through the incisions into the hollow viscera previously prepared for the anastomosis, with the arms extending to separate the viscera (Fig. 1C and 1G). At body temperature, the clip returns to its original shape and presses the anastomosed surfaces together (Fig. 1D, 2A). A scalpel was then used to create a slit through the entrapped anastomosed surfaces to allow free passage of air and feces through the anastomosis until the healing process was complete. The small incisions through which the clip was inserted were closed with an interrupted polydioxanone 3/0 suture (MonoPlus[®], B. Braun Surgical SA, Rubi, Spain). The anastomosis time was recorded.

Macroscopic Examination

After the abdominal cavity was exposed, the total number of intra-abdominal adhesions was evaluated. During the examination, each anastomosis was macroscopically assessed using the van der Hamm scale, which includes the formation of adhesions, the integrity of the anastomosis and the presence of a perianastomotic abscess or peritonitis (Table 1) [18, 19]. The anastomoses were carefully dissected with 5 cm of bowel margin on each side of each anastomosis.

Histological Examination

After histological sections from each anastomosis were fixed in 10% neutral buffered

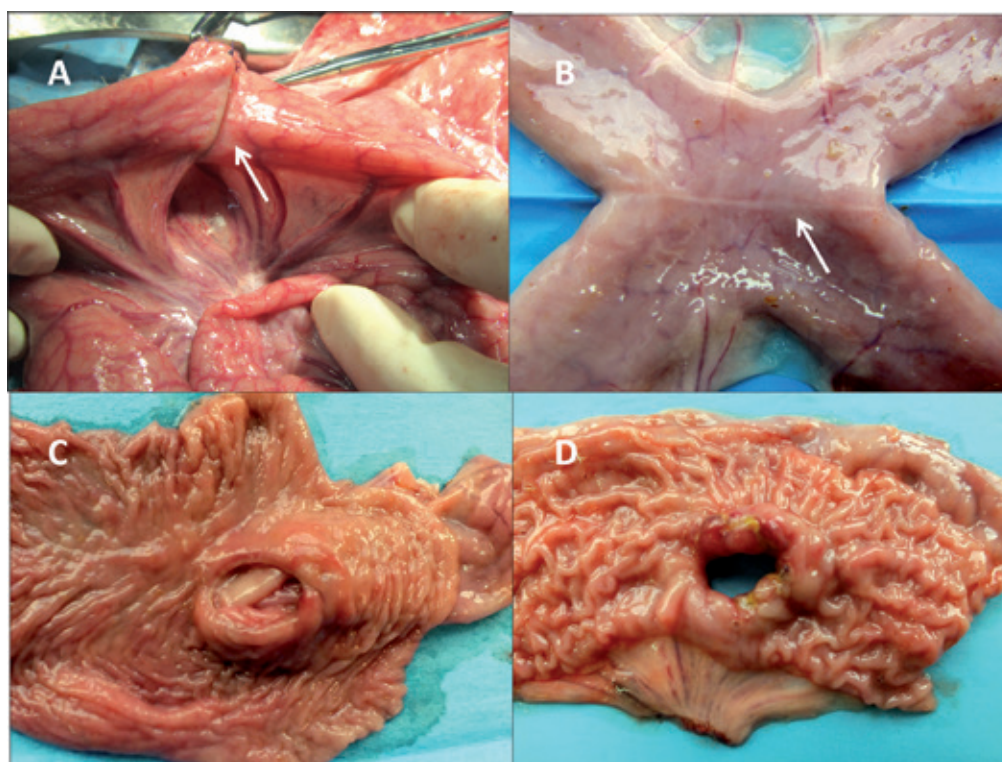


Fig. 2. A) Anastomosis is established by closure of the compression anastomosis clip (arrow), B–C) CAC anastomosis with thin scar tissue at the anastomotic line, D) much thicker and uneven line of a hand-sewn anastomosis

Table 1. Scales used to macroscopically and microscopically analyze compression anastomosis clip (CAC) and hand-sewn (HS) anastomoses

Analyzed factors		Score (points)				
Van der Hamm scale		0	1	2	3	
		no adhesions	minimal adhesions, mainly between the anastomosis and the omentum	moderate adhesions, between the omentum and the anastomosis site and between the anastomosis and the loop of the small bowel	severe and extensive adhesions, including abscess formation and peritonitis	
Ehrlich-Hunt scale		0	1	2	3	4
	inflammatory cell infiltration (WBC count) fibroblast activity neoangiogenesis collagen deposition	no evidence	occasional evidence	light scattering	abundant evidence	confluent cells or fiber
Epithelial regeneration scale		0	1	2		
		no epithelium	epithelium with partial closure	epithelium with complete closure for anastomotic healing.		
Wound healing scale score		1	2	3	4	5
		fibrinopurulent exudates	granulation tissue less than 25%	granulation tissue between 25–75%	granulation tissue more than 75% or collagen fibers less than 25%	collagen fibers more than 25%

WBC – white blood cells.

formalin and embedded in paraffin (4 μm), they sections were stained with hematoxylin-eosin and examined under a light microscope (at 20 \times , 40 \times , and 100 \times magnification). Histological parameters were graded from 0 to 4 using the Ehrlich-Hunt scale as modified by Philips et al.; the scale included inflammatory cell infiltration (white blood cell count), fibroblast activity, neo-angiogenesis, and collagen deposition (Table 1) [18–20]. Re-epithelialization was scored from 0 to 2, and the degree of wound healing at the line of the anastomosis was graded on a scale of 1 to 5 (Table 1) [17, 21, 22].

Breaking Strength

Breaking strength is typically measured using a tensiometer [23, 24] by applying increasing force in a longitudinal direction to anastomotic segments until disruption takes place [16]. In this study, the resected intestinal segments, with the sutures in place, were placed in a dynamometer (Haas-Automatyka, Bielsko-Biala, Poland) at a force of 200 newtons (N); the force was then increased at a rate of 10 mm/min. The peak force necessary to induce disruption was considered the BS σ (MPa) [23], which was calculated by dividing the maximum force by the intestinal cross-section: $F_{\text{max}} \text{ (N)}/S \text{ (mm}^2\text{)}$.

Statistical Analysis

All data are expressed as mean and standard deviation (SD). The parameters of the two anastomoses of the same type performed in each pig were compared using the chi-square test for qualitative data, Student's *t*-test for quantitative parametric data and the Mann Whitney *U* test for non-parametric data.

Comparisons between the CAC and HS anastomoses in the jejunojejunostomy and ileocolostomy groups on postoperative days 5 and 7 were conducted using Pearson's chi-square test and Yates' corrected χ^2 test for the macroscopic examination results, the Mann-Whitney *U* test for the histological results and anastomosis times, and Student's *t*-test for breaking strength. Comparisons of the histological results between days 5 and 7 for the CAC and HS anastomoses (within the jejunojejunostomy and ileocolostomy groups) and between the jejunojejunostomy and ileocolostomy groups for the CAC and HS anastomoses on days 5 and 7 were conducted using the Mann-Whitney *U* test. All the analyses were performed using STATISTICA 10.0 (StatSoft Ltd, Bedford, UK). Results were considered statistically significant at $p < 0.05$.

Results

General Results and Agreement

There were no postoperative deaths or morbidity in either the CAC group or the HS group. In addition, no anastomotic dehiscence, intra-abdominal abscess, or other infectious conditions were observed. Satisfactory agreement existed between individual parameters of the same anastomosis type in each pig (Cohen's kappa coefficient: 0.61–1.0; $p < 0.05$). Tests for differences did not result in significant findings between individual parameters of the same anastomosis type in each pig ($p > 0.05$).

Anastomosis Time

The HS anastomoses took significantly longer to form compared to the CAC anastomoses (Table 2). There were no statistically significant differences in the time to perform the CAC jejunojejunostomy compared with the CAC ileocolostomy or to perform the HS jejunojejunostomy compared with the HS ileocolostomy ($p > 0.05$).

Macroscopic Analysis

There were no statistically significant differences in adhesion development between the HS and CAC groups (Table 2). No stenoses were found in the anastomoses of the CAC or HS groups. Macroscopic examination of the CAC anastomoses showed very thin scar tissue at the anastomotic line (Fig. 2B, 2C) and a much thicker anastomotic line in the HS group (Fig. 2D).

Breaking Strength Results

In four of the 20 anastomoses formed with CACs and examined on postoperative day 5, the clip did not separate from the 4–6-mm section of the inner side of the anastomosis, and the breaking strength could not be determined. Therefore, the breaking strength was assessed on postoperative day 7, as all the clips had separated by that time. The breaking strength was higher in the CAC jejunojejunostomies and ileocolostomies than in the corresponding HS anastomoses (Table 2).

Histological Results

There were statistically significant histological differences between the jejunojejunostomies in the CAC and HS groups (Table 3). A comparison of the CAC and HS anastomoses using the Ehrlich-Hunt scale revealed significantly less inflammatory

Table 2. Comparison of the macroscopic examination, breaking strength, and anastomosis time between CAC and HS anastomoses

Analyzed factors	Jejunojejunostomy					
	postoperative day 5			postoperative day 7		
	CAC	HS	p-value	CAC	HS	p-value
Macroscopic examination: adhesions (points/n/%)	0/7/70 1/3/30 2/0/0	0/5/50 1/5/50 2/0/0	0.64810 ^c	0/7/58.3 1/4/33.3 2/1/8.3	0/2/16.7 1/9/75.0 2/1/8.3	0.09533 ^b
Breaking strength σ (MPa)	n/a			0.32 ± 0.13	0.20 ± 0.08	
Anastomosis time (min)	CAC (day 5 and day 7, n = 22)		HS (day 5 and day 7, n = 22)		p-value	
	10.00 ± 1.87		21.00 ± 4.05		0.0000001 ^d	

Analyzed factors	Ileocolostomy					
	postoperative day 5			postoperative day 7		
	CAC	HS	p-value	CAC	HS	p-value
Macroscopic examination: adhesions (points/n/%)	0/5/50 1/5/50 2/0/0	0/4/40 1/5/50 2/1/10	0.57375 ^b	0/5/41.6 1/5/41.6 2/2/16.6	0/3/25 1/2/16.6 2/7/58.3	0.10211 ^b
Breaking strength σ (MPa)	n/a			0.30 ± 0.08	0.20 ± 0.12	
Anastomosis time (min)	CAC (day 5 and day 7, n = 22)		HS (day 5 and day 7, n = 22)		p-value	
	9.09 ± 2.22		21.90 ± 5.83		0.0000001 ^d	

^a Student's *t*-test; ^b Pearson chi-square test; ^c Yates corrected chi-square test; ^d Mann-Whitney *U* test; CAC – compression anastomosis clip; HS – hand-sewn.

cell infiltration in the CAC group on postoperative days 5 and 7. A high-density active granulocytic/lymphocytic inflammatory infiltration was visible in the lamina propria of the mucosa on day 5 in both the CAC and HS groups (Fig. 3). On day 7, the density of the dominant lymphocytes of the inflammatory infiltrate had decreased, while crypt abscesses were visible in the dominant active infiltrate in the HS group (Fig. 4). On day 5, more collagen deposit was found in the HS anastomoses. On day 7, the HS anastomoses were characterized by higher fibroblast activity than the CAC anastomoses. Differences in the remaining parameters were not statistically significant (Table 3).

On postoperative days 5 and 7, statistically significant differences were detected between the CAC and HS ileocolostomies in inflammatory cell infiltration, fibroblast activity, and the degree of wound healing, with lower values in the CAC group (Table 3). On day 5, compared with the HS group, significantly less collagen deposition and significantly higher epithelial regeneration were detected in the ileocolostomies in the CAC group (Table 3). The density and other characteristics of the inflammatory infiltrate of the ileocolostomies

on postoperative days 5 and 7 were similar to those of the jejunojejunostomies (Fig. 3, 4).

The collagen deposition in the jejunojejunostomies and ileocolostomies in the HS group were significantly lower on day 7 than on day 5. The degree of wound healing was significantly lower on day 7 than day 5 in the ileocolostomies (Table 4).

The differences between jejunojejunostomy and ileocolostomy histology results for CAC and HS anastomoses on postoperative days 5 and 7 were not statistically significant (Table 5).

Discussion

In the present study, all of the CAC anastomoses resulted in smooth and intact healing with an anastomotic line that was represented by a very thin circular band of fibrosis and granulation tissue (Fig. 2B, 2C). Kopelman et al. [25] suggested that these features of CAC anastomoses are attributable to the lack of any foreign material – either suture material or metal staples – within the anastomotic site, and to the gradual compression applied to the tissue on both sides of the

Table 3. Comparison of microscopic examinations of CAC and HS anastomoses for jejunojunostomies and ileocolostomies in pigs on postoperative days 5 and 7

Analyzed factors		Jejunojunostomy					
		postoperative day 5			postoperative day 7		
		CAC	HS	p-value	CAC	HS	p-value
Ehrlich-Hunt scale	inflammatory cell infiltration (WBC count)	1.90 ± 0.57	3.20 ± 0.63	0.00149	1.67 ± 0.78	2.75 ± 0.75	0.00726
	fibroblast activity	1.50 ± 0.53	1.90 ± 0.57	0.19877	1.50 ± 0.52	2.17 ± 0.39	0.01657
	neoangiogenesis	2.40 ± 0.84	2.70 ± 0.48	0.34471	1.83 ± 0.39	2.25 ± 0.62	0.14096
	collagen deposition	0.50 ± 0.85	2.20 ± 1.23	0.00911	0.00 ± 0.00	0.50 ± 1.00	0.31232
Epithelial regeneration scale		0.50 ± 0.53	0.00 ± 0.00	0.06402	0.58 ± 0.79	0.08 ± 0.29	0.15721
Wound healing scale score		3.20 ± 0.79	3.80 ± 0.92	0.16197	2.83 ± 0.71	3.33 ± 0.65	0.12602
Ileocolostomy							
Ehrlich-Hunt scale	inflammatory cell infiltration (WBC count)	2.00 ± 0.47	3.20 ± 0.79	0.00459	2.00 ± 0.85	3.08 ± 0.67	0.00511
	fibroblast activity	1.30 ± 0.48	1.90 ± 0.32	0.02575	1.17 ± 0.39	2.17 ± 0.39	0.00038
	neoangiogenesis	2.50 ± 0.52	2.20 ± 0.63	0.36435	1.92 ± 0.51	2.33 ± 0.49	0.14096
	collagen deposition	0.70 ± 0.82	2.40 ± 0.97	0.00319	0.17 ± 0.58	0.50 ± 1.00	0.50672
Epithelial regeneration scale		0.80 ± 0.63	0.00 ± 0.00	0.00911	0.25 ± 0.45	0.08 ± 0.29	0.50672
Wound healing scale score		3.30 ± 0.67	4.10 ± 0.57	0.02837	2.75 ± 0.62	3.42 ± 0.51	0.03038

WBC – white blood cells; CAC – compression anastomosis clip; HS – hand-sewn. Values are reported as mean ± standard deviation.

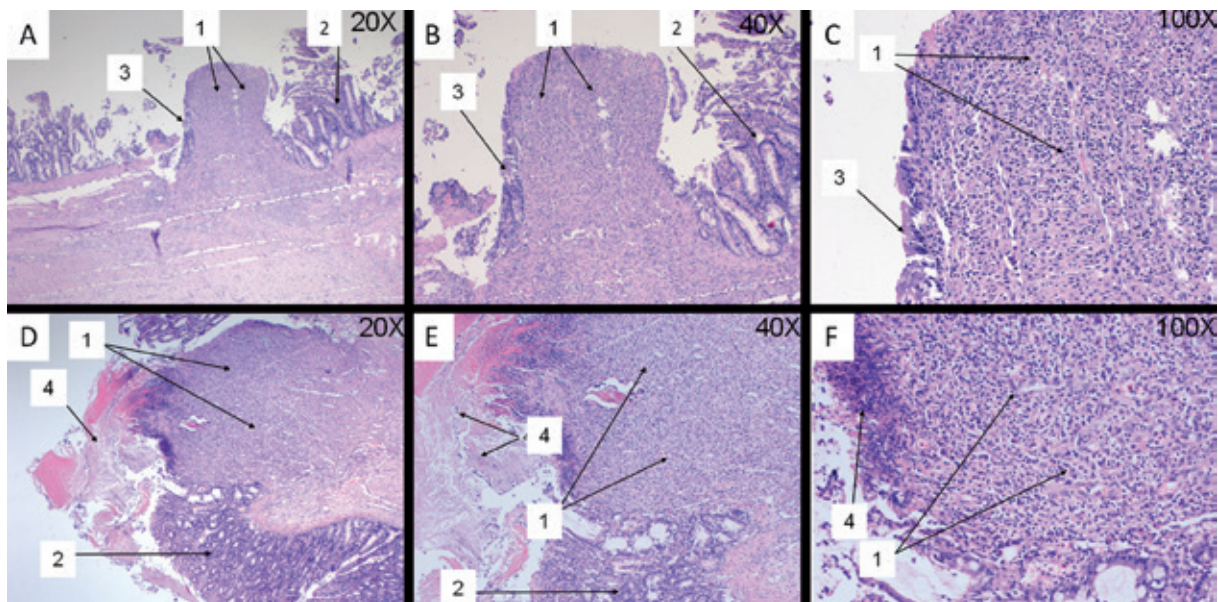


Fig. 3. Histopathological examination of a jejunojunostomy with a compression anastomosis clip (A, B, C) or hand-sewn anastomosis (D, E, F), performed on the 5th postoperative day (hematoxylin and eosin; ×20, ×40 and ×100 magnification). The arrows indicate: 1) granulation tissue; 2) mucous membrane with active inflammatory infiltration; 3) regenerating epithelium in the granulation tissue (A, B, C); and 4) necrosis (D, E, F)

anastomosed bowel. The CAC might help avoid persistent foreign material and the resultant excessive inflammatory response by the timely natural expulsion of the device [2]. The previous use

of these anastomoses in animals also resulted in appropriate mucosal healing and decreased formation of fibrous tissue [2, 26], with very little scar tissue visible at the anastomotic line under

Table 4. Comparison of microscopic examinations on postoperative days 5 and 7 for CAC and HS anastomoses in jejunojunostomies and ileocolostomies

Analyzed factors		Jejunojunostomy					
		CAC day 5	CAC day 7	p-value	HS day 5	HS day 7	p-value
Ehrlich-Hunt scale	inflammatory cell infiltration (WBC count)	1.90 ± 0.57	1.67 ± 0.78	0.40981	3.20 ± 0.63	2.75 ± 0.75	0.18725
	fibroblast activity	1.50 ± 0.53	1.50 ± 0.52	0.97369	1.90 ± 0.57	2.17 ± 0.39	0.37338
	neoangiogenesis	2.40 ± 0.84	1.83 ± 0.39	0.12125	2.70 ± 0.48	2.25 ± 0.62	0.12937
	collagen deposition	0.50 ± 0.85	0.00 ± 0.00	0.24854	2.20 ± 1.23	0.50 ± 1.00	0.01113
Epithelial regeneration scale		0.50 ± 0.53	0.58 ± 0.79	0.97369	0.00 ± 0.00	0.08 ± 0.29	0.76668
Wound healing scale score		3.20 ± 0.79	2.83 ± 0.72	0.30676	3.80 ± 0.92	3.33 ± 0.65	0.19852
Ileocolostomy							
Ehrlich-Hunt scale	inflammatory cell infiltration (WBC count)	2.00 ± 0.47	2.00 ± 0.85	0.81748	3.20 ± 0.79	3.08 ± 0.67	0.71686
	fibroblast activity	1.30 ± 0.48	1.17 ± 0.39	0.62093	1.90 ± 0.31	2.17 ± 0.39	0.33902
	neoangiogenesis	2.50 ± 0.53	1.92 ± 0.51	0.05175	2.20 ± 0.63	2.33 ± 0.49	0.71686
	collagen deposition	0.70 ± 0.82	0.17 ± 0.58	0.12937	2.40 ± 0.97	0.50 ± 1.00	0.00334
Epithelial regeneration scale		0.80 ± 0.63	0.25 ± 0.45	0.06485	0.00 ± 0.00	0.08 ± 0.29	0.76668
Wound healing scale score		3.30 ± 0.67	2.75 ± 0.62	0.09926	4.10 ± 0.57	3.42 ± 0.51	0.02718

WBC – white blood cells; CAC – compression anastomosis clip; HS – hand-sewn. Values are reported as mean ± standard deviation.

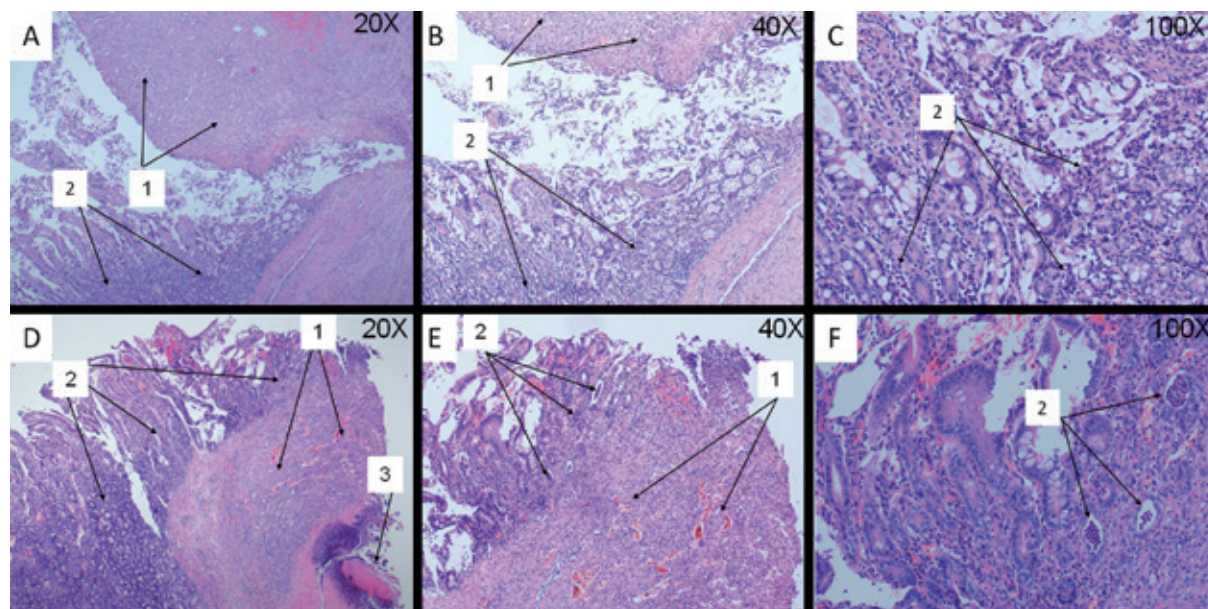


Fig. 4. Histopathological examination of a jejunojunostomy with a compression anastomosis clip (A, B, C) or hand-sewn anastomosis (D, E, F) performed on the 7th postoperative day (hematoxylin and eosin; ×20, ×40 and ×100 magnification). The arrows indicate: 1) granulation tissue; 2) mucous membrane with active inflammatory infiltration (chronic in A, B, C; active with crypt abscesses in D, E, F); and 3) necrosis (D)

microscopic examination [27]. Furthermore, the possible extent of scarring is proportional to the amount of granulation tissue that is formed [25]. In the present study, the amount of granulation tissue at the anastomotic line, as indicated by the

score on the wound healing scale, was similar in CAC and HS jejunojunostomies on both postoperative days 5 and 7. However, the HS ileocolostomies resulted in more granulation tissue on both postoperative days 5 and 7.

Table 5. Comparison of the microscopic examinations of jejunojejunostomy with ileocolostomy, in the CAC group and in the HS group on postoperative days 5 and 7

Analyzed factors		Type of anastomosis (day 5)					
		CAC			HS		
		jejunojejunostomy	ileocolostomy	p-value	jejunojejunostomy	ileocolostomy	p-value
Ehrlich-Hunt scale	inflammatory cell infiltration (WBC count)	1.90 ± 0.57	2.00 ± 0.47	0.67001	3.20 ± 0.63	3.20 ± 0.79	1.00000
	fibroblast activity	1.50 ± 0.53	1.30 ± 0.48	0.39211	1.90 ± 0.57	1.90 ± 0.32	1.00000
	neoangiogenesis	2.40 ± 0.84	2.50 ± 0.52	0.75012	2.70 ± 0.48	2.20 ± 0.63	0.06131
	collagen deposition	0.50 ± 0.85	0.70 ± 0.82	0.61801	2.20 ± 1.23	2.40 ± 0.97	0.69234
Epithelial regeneration scale		0.50 ± 0.53	0.80 ± 0.63	0.26023	0.00 ± 0.00	0.00 ± 0.00	1.00000
Wound healing scale score		3.20 ± 0.79	3.30 ± 0.67	0.76221	3.80 ± 0.92	4.10 ± 0.57	0.39721
		Type of anastomosis (day 7)					
Ehrlich-Hunt scale	inflammatory cell infiltration (WBC count)	1.67 ± 0.78	2.00 ± 0.85	0.33361	2.75 ± 0.75	3.08 ± 0.67	0.26251
	fibroblast activity	1.50 ± 0.52	1.17 ± 0.39	0.09117	2.17 ± 0.39	2.17 ± 0.39	1.00000
	neoangiogenesis	1.83 ± 0.39	1.92 ± 0.51	0.66534	2.25 ± 0.62	2.33 ± 0.49	0.72010
	collagen deposition	0.00 ± 0.00	0.17 ± 0.58	0.33182	0.50 ± 1.00	0.50 ± 1.00	1.00000
Epithelial regeneration scale		0.58 ± 0.79	0.25 ± 0.45	0.22026	0.08 ± 0.29	0.08 ± 0.29	1.00000
Wound healing scale score		2.83 ± 0.71	2.75 ± 0.62	0.76001	3.33 ± 0.65	3.42 ± 0.51	0.73170

WBC – white blood cells; CAC – compression anastomosis clip; HS – hand-sewn. Values are reported as mean ± standard deviation.

Previous studies of CAC anastomoses in humans have indicated that they are as safe and effective as stapled anastomoses [2, 5–13]. The safety of this device has also been documented in animal studies [28, 29], including a comparison between CAC and stapled jejunojejunal anastomoses in pigs, in which a histological examination of the CAC anastomoses demonstrated a complete mucosal lining with no evidence of stricture formation at two months [29]. In a dog model, macroscopic and microscopic examinations of the CAC anastomosis on postoperative day 14 showed a complete mucosal epithelial lining with re-epithelialization of the mucosa at the anastomotic site and an intact, functioning anastomosis [28]. The present study also demonstrated that CAC anastomosis is safe for both jejunojejunostomies and ileocolostomies. The macroscopic assessment showed that the clip did not increase the formation of adhesions when compared with the HS anastomoses. There was very thin scar tissue at the anastomotic line (less collagen deposition and better epithelial regeneration) in the CAC group, and a much thicker anastomotic line in the HS group. Moreover, in the early healing period, significantly less inflammatory cell infiltration occurred in the CAC group on postoperative days

5 and 7. Not only was the anastomosis time shorter in the CAC group, but the breaking strength of the CAC anastomoses was also greater.

Various methods are available to study the course of events during experimental anastomotic healing, typically involving histological studies and evaluations of breaking strength. Histological evaluation is useful to describe the course and results of the healing sequence at the tissue level as well as the successive infiltration of various cell types into the wound area. Various histological parameters of wound repair have been studied in experimental intestinal anastomoses: mucosal healing based on inflammatory cell infiltration, epithelial regeneration, the degree of necrosis, proliferation of fibroblasts, the formation of collagen fibers, neoangiogenesis and granulation tissue [18–21].

Mechanical parameters are of great importance for studying intestinal anastomoses because the mechanical strength of an anastomosis can affect leakage during the initial postoperative phase. Ikeuchi et al. [30] reported that tensile strength was a standard to evaluate the biological aspects of anastomotic healing, including suture-holding capacity. Because tensile strength measurements can only be carried out when the CAC separates

from the anastomosis, in four cases in the present study it was impossible to measure tensile strength on postoperative day 5. It might therefore be more appropriate to examine the strength of CAC anastomoses on later postoperative days, such as day 7 in the present study.

This study had certain limitations. The comparison of CAC anastomoses with HS anastomoses was based solely on two-layer HS anastomoses, which extended the time it took to create the anastomoses and might have resulted in greater inflammation caused by foreign bodies. However, the two-layer HS anastomoses increased the adherence of the anastomosed surfaces, resulting in anastomoses that were comparable to the CAC anastomoses. As indicated by the statistical agreement tests, the results were not affected by performing two CAC and two HS anastomoses in the same animal, because the anastomoses were performed on the same specific sections of the intestine, which

did not differ anatomically, histologically, or physiologically. In addition, pigs were included in the study based on the tightness of all the anastomoses performed in that pig. If even one anastomosis showed leakiness or any other complication, that would affect all of the anastomoses in that animal. Also, the study included only the early postoperative period, and a functional assessment of anastomoses requires a longer observation period because of the potential for anastomotic stenosis. Further studies are needed to evaluate anastomoses in the later postoperative period and to compare CAC anastomoses with those created using another technique, e.g., a stapler.

The authors concluded that anastomosis using a CAC appears to be safe and less time consuming than HS; it is also characterized by a good healing process with little inflammatory reaction and a high breaking strength compared with HS anastomosis.

Acknowledgements. Special thanks go to Aniela Grajoszek from the Center for Experimental Medicine, Medical University of Silesia in Katowice.

References

- [1] **Holzner PA, Kulemann B, Kuesters S, Timme S, Hoepfner J, Hopt UT, Marjanovic G:** Impact of remote ischemic preconditioning on wound healing in small bowel anastomoses. *World J Gastroenterol* 2011, 17, 1308–1316.
- [2] **Zbar AP, Nir Y, Weizman A, Rabau M, Senagore A:** Compression anastomoses in colorectal surgery: a review. *Tech Coloproctol* 2012, 16, 187–199.
- [3] **Sliker JC, Daams F, Mulder IM, Jeekel J, Lange JF:** Systematic review of the technique of colorectal anastomosis. *JAMA Surg* 2013, 148, 190–201.
- [4] **Kopelman D, Kopelman Y, Peled D, Willenz U, Zmora O, Wasserberg N:** Healing of ileocolic nitinol compression anastomosis: a novel porcine model of subtotal colectomy. *Surg Innov* 2013, 20, 570–579.
- [5] **Nudelman I, Fuko V, Wasserberg N, Niv Y, Rubin M, Szold A, Lelcuk S:** Colonic anastomosis performed with a memory-shaped device. *Am J Surg* 2005, 190, 434–438.
- [6] **Nudelman I, Fuko V, Rubin M, Lelcuk S:** A nickel-titanium memory-shape device for colonic anastomosis in laparoscopic surgery. *Surg Endosc* 2004, 18, 1085–1089.
- [7] **Liu PC, Jiang ZW, Zhu XL, Wang ZM, Diao YQ, Li N, Li JS:** Compression anastomosis clip for gastrointestinal anastomosis. *World J Gastroenterol* 2008, 14, 4938–4942.
- [8] **Nudelman I, Fuko V, Greif F, Lelcuk S:** Colonic anastomosis with the nickel-titanium temperature-dependent memory-shape device. *Am J Surg* 2002, 183, 697–701.
- [9] **Kusnierz K, Lekston Z, Zhavoronkov D, Mrowiec S, Lampe P:** A nickel-titanium memory-shape device for gastrojejunostomy: comparison of the compression anastomosis clip and a hand-sewn anastomosis. *J Surg Res* 2014, 187, 94–100.
- [10] **Kusnierz K, Morawiec H, Lekston Z, Zhavoronkov D, Lucyga M, Lampe P:** NiTi shape memory compression anastomosis clip in small- and large-bowel anastomoses: first experience. *Surg Innov* 2013, 20, 580–585.
- [11] **Hur H, Kim HH, Hyung WJ, Cho GS, Kim W, Ryo SW, Han SU:** Efficacy of NiTi Hand CAC 30 for jejunojunctionostomy in gastric cancer surgery: results from a multicenter prospective randomized trial. *Gastric Cancer* 2011, 14, 124–129.
- [12] **Lee HY, Woo JH, Park SY, Kang NW, Park KJ, Choi HJ:** Intestinal anastomosis by use of a memory-shaped compression anastomosis clip (Hand CAC 30): early clinical experience. *J Korean Soc Coloproctol* 2012, 28, 83–88.
- [13] **Hua S, Xiong L, Wen Y, Liu W, Pan K, Wang S, Chen Y:** Safety and efficacy of gastrointestinal anastomosis with nickel titanium compression anastomosis clip. *Zhong Nan Da Xue Xue Bao Yi Xue Ban* 2011, 36, 351–354.
- [14] **Frandsen RD, Wilke WL, Fails AD:** *Anatomy and Physiology of Farm Animals*. Wiley-Blackwell, Ames 2009, 7th ed., 335–374.
- [15] **Cochran PE:** *Laboratory Manual for Comparative Veterinary Anatomy and Physiology*. Thomson Delmar Learning, New York 2004, 174–204.
- [16] **Durães Lde C, Durães EF, Lobato LF, Oliveira PG, Sousa JB:** Correlation between bursting pressure and breaking strength in colonic anastomosis. *Acta Cir Bras* 2013, 28, 447–452.
- [17] **Månsson P, Zhang XW, Jeppsson B, Thorlacius H:** Anastomotic healing in the rat colon: comparison between a radiological method, breaking strength and bursting pressure. *Int J Colorectal Dis* 2002, 17, 420–425.

- [18] **Pramateftakis MG, Kanellos D, Mantzoros I, Despoudi K, Raptis D, Angelopoulos S, Koliakos G, Zaraboukas T, Lazaridis C:** Intraperitoneally administered irinotecan with 5-fluorouracil impair wound healing of colonic anastomoses in a rat model: an experimental study. *Tech Coloproctol* 2011, 15, 121–125.
- [19] **Giuratrabocchetta S, Rinaldi M, Cuccia F, Lemma M, Piscitelli D, Polidoro P, Altomare DF:** Protection of intestinal anastomosis with biological glues: an experimental randomized controlled trial. *Tech Coloproctol* 2011, 15, 153–158.
- [20] **Moran M, Ozmen MM, Duzgun AP, Gok R, Renda N, Seckin S, Coskun F:** The effect of erythropoietin on healing of obstructive vs nonobstructive left colonic anastomosis: an experimental study. *World J Emerg Surg* 2007, 2, 13.
- [21] **Cetinkaya Z, Esen K, Ozercan IH, Ustundag B, Ayten R, Aygen E:** The effect of Bosentan on healing of colonic anastomosis. *World J Emerg Surg* 2006, 1, 37.
- [22] **Arikanoglu Z, Cetinkaya Z, Akbulut S, Ilhan YS, Aygen E, Basbug M, Ayten R, Girgin M, Ilhan N, Dagli F:** The effect of different suture materials on the safety of colon anastomosis in an experimental peritonitis model. *Eur Rev Med Pharmacol Sci* 2013, 17, 2587–2593.
- [23] **Fresno L, Fondevila D, Bambo O, Chacaltana A, García F, Andaluz A:** Effects of platelet-rich plasma on intestinal wound healing in pigs. *Vet J* 2010, 185, 322–327.
- [24] **Pasternak B, Rehn M, Andersen L, Agren MS, Heegaard AM, Tengvall P, Aspenberg P:** Doxycycline-coated sutures improve mechanical strength of intestinal anastomoses. *Int J Colorectal Dis* 2008, 23, 271–276.
- [25] **Kopelman D, Lelcuk S, Sayfan J, Matter I, Willenz EP, Zaidenstein L, Hatoum OA, Kimmel B, Szold A:** End-to-end compression anastomosis of the rectum: a pig model. *World J Surg* 2007, 31, 532–537.
- [26] **Szold A:** New concepts for a compression anastomosis: superelastic clips and rings. *Minim Invasive Ther Allied Technol* 2008, 17, 168–171.
- [27] **Ho YH, Ashour MA:** Techniques for colorectal anastomosis. *World J Gastroenterol* 2010, 16, 1610–1621.
- [28] **Nudelman IL, Fuko VV, Morgenstern S, Giler S, Lelcuk S:** Gastrointestinal anastomosis with the nickel-titanium double ring. *World J Surg* 2000, 24, 874–877.
- [29] **Tucker ON, Beglaibter N, Rosenthal RJ:** Compression anastomosis for Roux-en-Y gastric bypass: observations in a large animal model. *Surg Obes Relat Dis* 2008, 4, 115–121.
- [30] **Ikeuchi D, Onodera H, Aung T, Kan S, Kawamoto K, Imamura M, Maetani S:** Correlation of tensile strength with bursting pressure in the evaluation of intestinal anastomosis. *Dig Surg* 1999, 16, 478–485.

Address for correspondence:

Katarzyna Kuśnierz
Department of Gastrointestinal Surgery
Medical University of Silesia
Medyków 14
40-752 Katowice
Poland
Tel: +48 604 873 800
E-mail: kasiachir@wp.pl

Conflict of interest: None declared

Received: 15.09.2015

Revised: 2.11.2015

Accepted: 3.11.2015