

Sygnatura: Pol J Radiol, 2007; 72(2): 75-81

Otrzymano: 2006.12.08
Zaakceptowano: 2007.02.15

Numerical segmentation image technique (NSI) in estimation of extraocular muscles volume in Graves` ophthalmopathy

Agata Majos¹, Piotr Grzelak¹, Wojciech Młynarczyk², Ludomir Stefańczyk¹

¹ Radiology Department, Medical University of Lodz, Poland

² Department of Microelectronic and Computer Science, Technical University of Lodz, Poland

Author's address: Agata Majos, Lagiewnicka 143a st., 91-863 Lodz, Poland, e-mail: egnys@poczta.onet.pl

Summary

Background:

The volume enlargement of extraocular muscles is one of the most frequent reasons of exophthalmos in Graves` ophthalmopathy. Various diameters are widely used in clinical practice for estimating muscles` size. They are not sufficient for the precise and reliable determination of their real volume. Modern computing systems enable numerical analysis of medical images including Magnetic Resonance Imaging (MRI) in an almost automatic way. The aims of this study were: The analysis of different MRI sequences routinely used in the examination of intraorbital structures and their value for NSI application. Determination of clinical value of an NSI program in estimating extraocular muscle volume and comparing the obtained results with the degree of exophthalmos.

Material/Methods:

45 patients were qualified to the study and underwent MR examinations in 1, 5 T scanner. The measurements of the degree of exophthalmos and quantity estimation of the total eye muscle volume using the NSI application were made.

Results:

The best sequence for the NSI application is SE T1. Correlation between muscle volume measurements obtained using the automatic method and after manual modification was the highest for this sequence. In all sequences the final values of volumes for each muscle after manual corrections were close what proves the repetitiveness of the NSI technique. Strong correlation between the total eye muscle volume determined by the NSI and the exophthalmos was found.

Conclusions:

T1 SE has the highest value for using NSI application for all sequences routinely used in MRI evaluation of orbital structures. The NSI technique is a clinically valuable application that provides objective volume data calculated individually for each orbit. The NSI technique allows more objective estimation of pathological processes leading to exophthalmos; it can be particularly helpful in monitoring discrete changes in muscle volume during the treatment.

Key words:

Graves` ophthalmopathy • muscles` volume • numerical analysis • segmentation

PDF file:

<http://www.polradiol.com/fulltxt.php?ICID=478117>

Background

Graves` ophthalmopathy is one of the most frequent and therefore most important causes of exophthalmos. Determination the degree of the exophthalmos and the dynamics of pathologic processes involved in this disease is of particular value because of its chronic nature and the possible serious consequences that can occur, such as visual loss.

Exophthalmos classification can be based on clinical criteria or determined by means of different imaging modalities [1, 2, 3, 4, 5, 6]. Magnetic resonance imaging (MRI) is widely considered to be a method of the highest diagnostic value, as it facilitates the precise and credible assessment of small orbital structures in any chosen plane.

Various protocols are used at present to quantitatively estimate intraorbital structures, including determination of

muscle width, which is the simplest one [7, 8]. Much more credible but at the same time more complex methods are a group of protocols based on estimating muscle volume. This is considered to be the most objective morphological index of changes in muscle size. The most common protocols in this group propose assessing muscle volume by summing up their cross section areas. These methods are effective but are also time consuming and resource and labor intensive. Therefore, they are difficult to apply in everyday clinical practice [9, 10, 11, 12].

Modern computing systems have enabled numerical analyses of medical images and greatly decreased the time required to convert numerical data into clinically useful information. Therefore, it seemed feasible to create a software application that could calculate the volume of anatomical structures on the basis of MRI imaging in an almost automatic manner. Creating a program to specifically analyse anatomical structures located within the orbital space was the goal of our work.

Therefore the aims of this study were:

1. The analysis of different MRI sequences routinely used in the examination of intraorbital structures and their value for NSI applications
2. Determination of the clinical value of an NSI program in estimating extraocular muscle volume and comparing results obtained with the degree of exophthalmos

Materials and methods

Forty-five patients (90 orbits) were qualified for this study; 6 men and 39 women aged 19-72 years (mean 55 y). All subjects were fully informed as to the nature of the study and all gave their consent in accordance with the declaration of Helsinki. The study was approved by the Local Ethical Committee of the Medical University of Lodz (decision no. KBUM/23/04).

The degree of exophthalmos was determined clinically using a Hertel exophthalmometer. Patients were not included in the study if pathological processes, posttraumatic effects or surgical interventions had disrupted the integrity of the orbit walls.

Tab I contains detailed information regarding clinical diagnosis.

The degree of exophthalmos in relation to the interzygomatic line was determined on the basis of a single MR image obtained in a horizontal section at the level of eyeball equator. This line was drawn between the most protruding points of the left and right zygomatic bones, respectively. The distance between the interzygomatic line and the corneal apex was measured perpendicularly to this line, Tab I.

MRI studies

All patients underwent MR examinations in a 1, 5 T Siemens Vision+ scanner.

The head coil was positioned in relation to the *nasion* point. Transverse sections were positioned parallel to medial and lateral muscles, coronal sections perpendicular to a path of the optic nerve which was equivalent to the long axis of the orbit.

Because of the small size of the intraorbital structures and their complex topographical relationships in the orbit, 3mm sections were used in line with standards set out in literature [8, 10, 12].

The MRI examinations without contrast medium administration lasted no longer than 35 minutes. With contrast medium and additional sequences the studies lasted 50 minutes.

The sequences routinely used for diagnostic imaging of the orbit were carried out. The protocol contained the following techniques: spin echo T1-weighted (SE T1), spin echo T1-weighted with fat tissue saturation (fat sat SE T1), spin echo T1-weighted with fat tissue saturation after contrast medium administration (fat sat SE T1 post cm) and short term inversion recovery (STIR) sequences, Tab II.

The value of these sequences for NSI applications was assessed on the basis of the first 20 examinations. Afterwards SE T1 was chosen for all further examinations.

Table 1. Clinical diagnosis and the degree of exophthalmos measured in relation to interzygomatic line in the study group; mean value for the right eye – 22,173 mm, stand. dev. 2,908, for the left eye – 24,744 mm, stand. dev. 3,041.

Diagnosis	Percentage	The measurement of the eye ball location in relation to interzygomatic line in mm			
		17,1-20,6	20,7-24,1	24,2-27,6	27,7-31,1
Without pathology inside the orbit	8 (8,9%)	4	1	-	-
Miopia	4 (4,4%)	1	1	-	-
Graves` Oftalmopathy	68 (75,5%)	2	27	31	17
Intraorbital tumor	10 (11,1%)	-	2	3	1
All	90 (100%)	7	31	34	18

Table 2. Parameters of used MRI sequences.

Sequence parameters	Sequence				
	SE T1 tra	SE T1 cor	STIR	SE T1 tra fat sat	SE T1 tra fat sat post cm
TR /ms/	390	450	5300	451	451
TE /ms/	14	14	30	12	12
TI /ms/			150		
FA /°/	90	90	180	90	90
Thickness of slices	3	3	3	3	3
Matrix	192x512	192x512	140x256	192x256	192x256
Time	5 min 2 s	4 min 22 s	3 min 38 s	4 min 23 s	4 min 23 s

NSI software

Quantitative assessment of extraocular muscles was carried out in all patients.

Contour extension NSI modification, one of the variants, was chosen to estimate muscle volume. The technique is based on detection of a precisely defined set of points.

Intraorbital structures differ in shape, homogeneity, signal intensity and the level of distinction from surrounding structures. These elements play a key role in creating the magnetic resonance image and are essential for numerical analysis. Their complexity is a genuine challenge for creating a numerical application.

Data from magnetic resonance sequences were sent to a PC computer and saved on its hard disc in DICOM format. Images used to estimate volume were characterized by 512x512x14 voxel resolution, at a single voxel size of 1x1x3 mm.

For the purpose of image processing the open source ITK library [The Insight Software Consortium, The Insight Toolkit (ITK). <http://www.itk.org/>] was used. The algorithms employed were cubic spline re sampling and Level Set segmentation. For a description of the above-mentioned algorithms we referred to the ITK library reference manual

[ITK Software Guide. Kitware, Inc.: Ibanez, Schroeder, Ng, Cates. <http://www.itk.org/ItkSoftwareGuide.pdf>].

In the first step of our procedure, a radiologist roughly marked the position of the muscle on the MRI image. This operation created a mask image that was further used as an initial condition for the Level Set segmentation algorithm. In the second step, both the MRI and the mask images were re-sampled into 1x1x1mm isotropic voxel size by cubic spline re-sampling algorithm. All further processing was done on the re-sampled MRI and mask images. In the third step, both re-sampled MRI and mask images were input into the Level Set segmentation algorithm in order to obtain a segmented image that was refined and provided a more accurate position of the muscle. The radiologist had the opportunity to control the number of iterations of the algorithm and to introduce manual corrections into the segmented image. This step essentially classified every voxel of an image into two classes - either containing the muscle or not. Lastly, the volume of muscle was estimated by multiplying the number of voxels in the area of muscle by the volume of one voxel, Fig. 1.

The muscle volume was calculated two times, the first value was obtained using only the automatic method, the second one- with manual corrections.

The total muscle volume was obtained by adding each of the separately calculated volumes for all six muscles.

Table 3. The calculated medium values of muscles` volume for all used sequences. A – in automatic way, K – with manual alterations, Z – calculated medium values for all sequences, with use of manual alterations, Y – calculated differences in percentage terms between medium value for each sequence in relation to Z value, X – the percentage relation of the volumes calculated automatically and with manual alterations.

	SE T1		SE T1 fat sat		SE T1 fat sat post cm		STIR		Medium value Z
	A	K	A	K	A	K	A	K	
Medium value of measurements /mm ³ /	3348,9	3420,8	2084,6	3363,9	1869,8	2810,3	2410,6	3762,3	3339,3
The volume differences Y /%/	100,3	102,4	62,4	100,7	55,99	84,2	72,18	112,7	100
Relation of volumes X /%/	97,8		61,2		66,5		64,0		

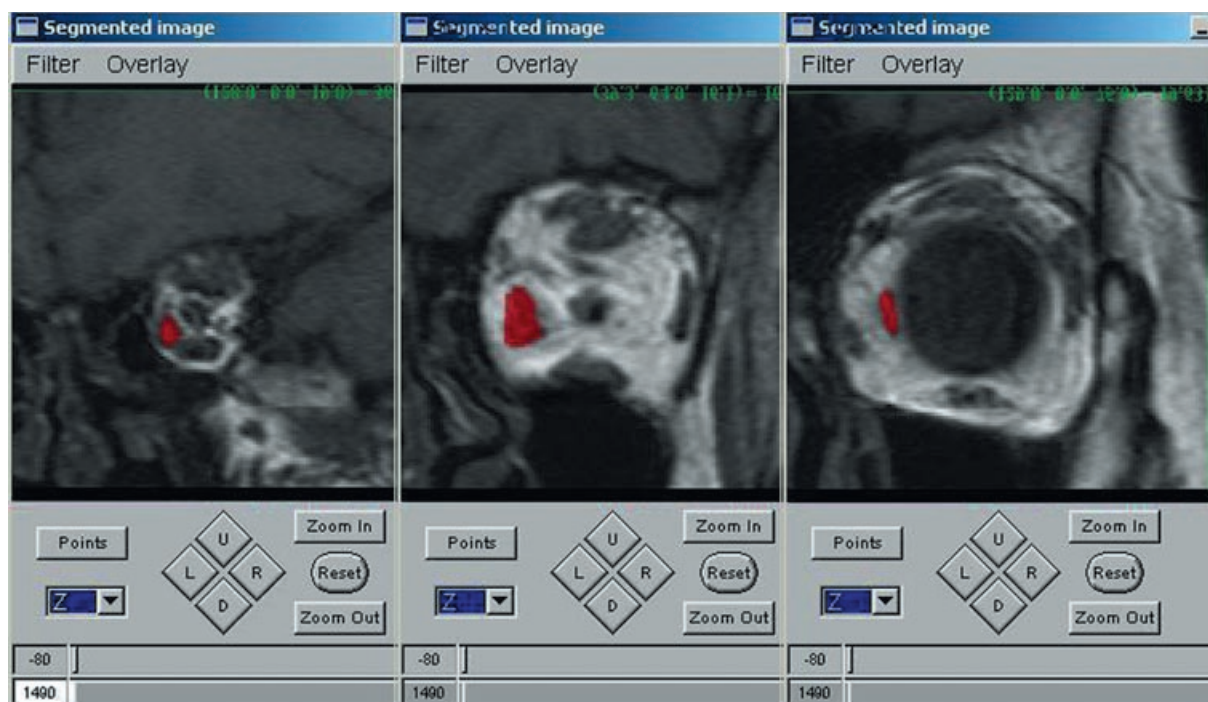


Figure 1. Muscles' volume calculation by NSI application; fitting the area inside the contour to the chosen element of MR images.

Statistical analysis

The correlations between the degree of exophthalmos /in millimetres/ measured in relation to the interzygomatic line and muscle volumes were estimated.

Parametrical methods of statistical analysis were used because of the large trial size ($n > 50$). The assessment of differences between the mean of analyzed parameters, in separate points of the examination (after confirmation of normal data distribution by Shapiro-Wilk test) with the use of a t-Student test for independent trials was carried out.

Relations between characteristics were described using Pearson linear correlation coefficient with the assessment of its significance and linear regression equations.

Results

Assessment of sequences

The numerical values of total muscle volume obtained from automatic calculation and with use of manual corrections for chosen sequences are shown in Tab III.

Muscle volumes obtained after manual modification were regarded in this study as being the most accurate values.

The results indicate that the best sequence for NSI applications is SE T1-weighted. The correlation between muscle volume values calculated using the automatic method and those obtained with manual corrections was the highest for this sequence (Fig. 2).

Significant differences in results between these two methods were observed for fat sat SE T1 and fat sat SE T1

post cm sequences. STIR sequence was characterized by the highest divergence of results.

For all sequences the final volume values for each muscle after manual corrections were very similar what proves the repetitiveness of NSI applications. Assuming the arithmetic mean after manual modification as a real value (100%), the estimated volume for SE T1 sequence was 103.4%, for fat sat SE T1 – 100.7%, for fat sat SE T1 post cm – 84.2% and for STIR sequence – 112.7%.

Extraocular muscles

A strong correlation was found between the degree of exophthalmos measured in relation to the interzygomatic line and total muscle volume calculated with use of manual corrections (linear correlation coefficient $r = 0.543$ $p = 3.13396E-08$, Spearman's correlation coefficient $R = 0.546$ $p = 2.61963E-08$), Fig. 3.

The correlation between exophthalmos in the relation to the intrzygomatic line and the total muscle volume calculated using the automatic method only was also determined (linear correlation coefficient $r = 0.511$ $p = 2.59221E-07$, Spearman's correlation coefficient $R = 0.546$ $p = 2.61963E-08$).

Discussion

SE T1 images are widely considered as a sequence of the highest diagnostic value for evaluation of intraorbital structures. High signal from fat tissue creates a natural contrast between it and the eyeball, optic nerve and muscles. Their borders can be clearly distinguished, even when there is massive muscle enlargement and the space separating these structures disappears almost completely [13].

SE T1 sequence with fat suppression

Fat tissue is characterized by a short T1 relaxation time. The presence of pathological processes can result in a signal similar to that of fat. To differentiate these, sequences with fat saturation based on chemical shift phenomenon and images weighted only on water proton resonance can be obtained [14, 15]. The disadvantage of such images, compared to standard T1 sequences, is worse signal to noise ratio [16]. On the other hand, the borders between anatomical structures in that sequence (standard T1) are indistinguishable.

SE T1 sequence with fat suppression after contrast medium administration

The effect of signal increase after contrast medium administration is characteristic for extraocular muscles and makes it possible to distinguish them from the surrounding structures. It does not improve the differentiation of other orbital structures e.g. eyeball and fat tissue [13]. It is a source of serious mistakes when using NSI application because the differences in signal intensity for different anatomical structures are essential to this application.

SE T2 sequence: STIR

T2 weighted images show lower tissue contrast in comparison with T1 images. The optic nerve and muscles have an intermediate signal. Fat tissue is characterized by high signal in this sequence and it is similar to that of structures having large water content or affected by inflammation [17, 18, 19].

T2 images, in particular STIR sequence, enable differentiation between the active and non active phases of Graves' ophthalmopathy which is of fundamental value for making decisions regarding therapy. Immunosuppressive treatment is effective only in the active phase, whilst surgery is the treatment of choice in the fibrotic stage [20, 21, 22, 23, 24].

Another feature of T2 sequences is significant sensitivity to artefacts caused by movements of the eyelids and eyeball.

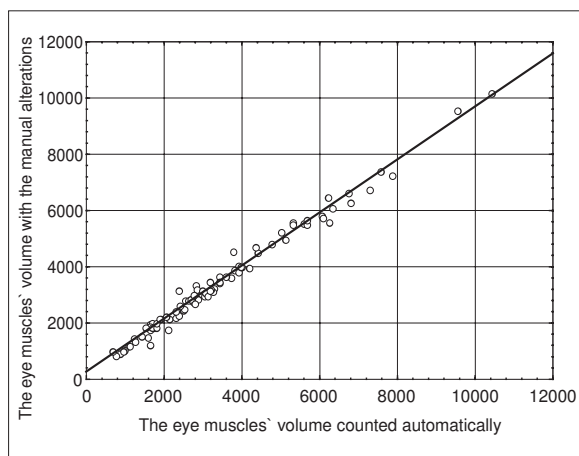


Figure 2. The correlation between the extraocular muscles' volume calculated automatically and with manual alterations obtained in the whole study group.

Bounce point artefacts can be present in form of black lines at the borders between tissues with greatly differing relaxation times. That is why images of sections are slightly blurred and the borders of intraorbital structures are not very clear. This is a significant disadvantage of these sequences when calculating muscle volumes using the NSI.

NSI technique

Well-defined borders of anatomical structures and the difference in signal intensity between them and their nearest surrounding area play a key role in NSI technique.

The contours of individual anatomical structures in sequences: fat sat SE T1, fat sat SE T1 after contrast medium administration and STIR are not very clear or easily distinguishable. The difference in signal intensity which influences the level of pixel brightness between them is also low in these sequences. The above aspects are especially important in orbital aditus and apex where spatial relationships are particularly complex and create a complicated environment for automatic numerical analysis. That is why in these regions an undesired widening of the contour far beyond the edges of anatomical structures often takes place.

The most perceptible borders and the greatest contrast in levels of brightness for all the intraorbital structures were observed in SE T1 sequence; some difficulties can be encountered only when distinguishing small, intraorbital ligaments or fibrous septa. This is due to small size of fibrotic structures rather than insufficient difference in signal intensity. However, low volume values cannot significantly influence resulting spatial relationships within the orbit and therefore the degree of exophthalmos. It is possible to incorporate them volumetrically into other structures without the risk of significant mistakes.

The results indicate that SE T1 sequence is the best for NSI application; correlation between muscle volume measurements obtained using the automatic method and after manual modification was the highest for this sequence. The degree of correlation between these two measuring methods allows us to identify this sequence as having the greatest value.

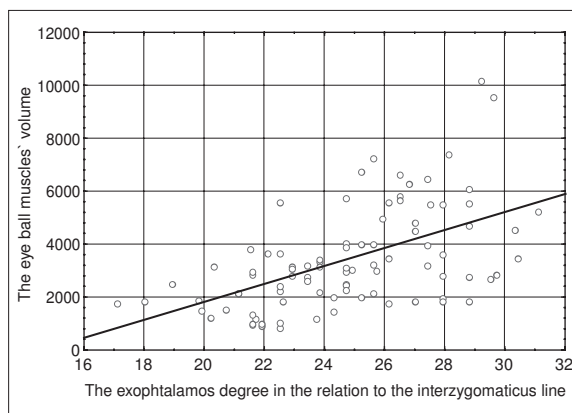


Figure 3. The correlation between the exophthalmos measured in relation to the interzygomatic line and muscles' volume.

Other sequences in descending order of value for NSI application are the following: SE T1 fat sat and SE T1 fat sat post cm. STIR sequence has the poorest value because of low tissue resolution and gives a result that clearly shows only the borders of fluid areas.

The ability to change contour toleration in the NSI application as well as the possibility of applying manual modifications greatly increases its value. This is relevant in case of muscle heterogeneity caused by fatty degeneration and fibrosis, which often takes place in the advanced stages of Graves' ophthalmopathy. Therefore, it is possible to use the NSI technique for monitoring intraorbital structures regardless of any underlying pathophysiological processes.

The methods that are most commonly used for quantitative assessment of extraocular muscle volumes, due to their simplicity, are usually based on single measurements of muscle belly [25, 26]. The most serious limitation of calculations based on single diameters, even assuming that they are very accurate, is the lack of precise criteria for carrying out these measurements. This could complicate any comparison of the obtained data, not only between different patients but also of the same patient in course of the disease. Any conclusions regarding the effectiveness of treatment made on the basis of such measurements could be controversial.

The best morphological parameter for monitoring changes in size of extraocular muscle is their volume [11, 27, 28]. The most frequent method for muscle volume estimation suggested in literature is the sum of their cross section areas [9, 10, 12, 29]. This requires manual outlining of the muscle contours by the researcher. However, individual choice of cross-sections, subjective criteria for defining the muscles borders (particularly complex in the vicinity of the orbital apex and near the muscle attachments of the eyeball) is the source of serious differences in results among authors. This limits the usefulness of this parameter in everyday radiological practice since all these methods

are labor intense and time consuming. In addition, they demand specialist computer software and specific equipment requirements for CT or MRI scanners [12].

The NSI application makes it possible to obtain credible computed results of genuine volumes, of any intraorbital structures analyzed almost automatically and in a relatively short time. The time required to calculate all six eye muscles was 3 to 6 minutes, mean value – 4 minutes 42 seconds for each orbit. The time required to calculate muscle volumes including manual marking of an area of interest required twice the above amount of time – mean value of 8 minutes 46 seconds.

Our results from the NSI application confirm a strong correlation between total extraocular muscle volume determined by NSI method and the degree of exophthalmos, as in the case published in literature [10, 11]. The correlation value was 0.559, $p=9.71279E-09$.

NSI method is objective and repeatable; it does not require outlining muscle borders manually. Muscle volume values are calculated on the basis of various sequences that differ slightly. This confirms that these values represent the genuine volume of imaged structures.

Conclusions

1. T1 SE has the highest value for using NSI application for all sequences routinely applied in MRI evaluation of orbital structures.
2. The NSI technique is a clinically valuable application that provides objective volume data calculated individually for each orbit.
3. The NSI technique allows a more objective estimation of pathological processes leading to exophthalmos; it can be particularly helpful in monitoring discrete changes in muscle volume in the course of treatment.

References:

1. DeJuan E, Hurley D, Sapira J: Racial differences in normal values of proptosis. *Arch Intern Med* 1980; 140: 1230.
2. Frueh BR, Bartley R. Graves' eye disease: Orbital compliance and other physical measurements. *Trans Am Ophthalmol Soc* 1984; 82: 539-596.
3. Nucci P, Brancato R, Bandello F et al: Normal exophthalmometric values in children. *Am J Ophthalmol* 1989; 108: 582-584.
4. So NMC, Lam WWM, Cheng G et al: Assessment of optic nerve compression in Graves' ophthalmopathy. *Acta Radiologica* 2000; 41: 559-561.
5. Wehrli FW, Kanal E. Orbital imaging: Factors determining resonance imaging appearance. *Radiol Clin North Am* 1987; 25: 419.
6. Werner SC, Coleman J, Franzen LA: Ultrasonographic evidence of a consistent orbital involvement in Graves' disease. *N Engl J Med* 1974; 290: 1447.
7. Murakami Y, Kanamoto T, Tuboi T et al: Evaluation of extraocular muscle enlargement in dysthyroid ophthalmopathy. *Jpn J Ophthalmol* 2001; 45: 622-627.
8. Ozgen A, Ariyurek M: Normative measurements of orbital structures using CT. *AJR* 1998; 170.
9. Carlow TJ, Deoer MH, Orrison WW: MR of extraocular muscles in chronic progressive external ophthalmoplegia. *AJNR* 1998; 19: 95-99.
10. Gupta MK, Perl J, Beham R et al: Effect of 131 iodine therapy on the course of Graves' ophthalmopathy: a quantitative analysis of extraocular muscle volumes using orbital magnetic resonance imaging. *Thyroid* 2001; 11: 959-965.
11. Szucs-Farkas Z, Toto J, Balazs E et al: Using morphologic parameters of extraocular muscles for diagnosis and follow-up of Graves' ophthalmopathy: diameters, areas, or values? *AJR* 2002; 179: 1005-1010.
12. Tian S, Nishida Y, Isberg B et al: MRI measurements of normal extraocular muscles and other orbital structures. *Graefes Arch Clin Exp Ophthalmol* 2000; 238: 393-404.
13. Sosnowski P: Znaczenie tomografii rezonansu magnetycznego (MR) w diagnostyce chorób oczodołu. *Rozpr habilitacyjna, Poznań* 1998.
14. De Potter PD, Flanders AE, Shields JA et al: The role of fat suppression technique and gadopentate dimeglumine in magnetic resonance imaging evaluation of intraocular tumors and simulating lesions. *Arch Ophthalmol* 1994; 112: 340-348.
15. Simon JH, Szumowski J, Toterman S et al: Fat-suppression MR imaging of the orbit. *AJNR* 1988; 9: 961-968.
16. Mukherji SK, Tart RP, Fitzsimmons J et al: Fat-suppressed MR of the orbit and cavernous sinus: comparison of fast spin-echo and conventional spin-echo. *AJNR* 1994; 15: 1707-1714.
17. Hosten N, Sander B, Cordes M et al: Graves' ophthalmopathy. MR imaging of the orbits. *Radiology* 1989; 172: 759-762.

18. Just M, Kahaly G, Higer HP et al: Graves` ophthalmopathy: Role of MR imaging in radiation therapy. *Radiology* 1991; 179: 187-190.
19. Mayer E, Herdman G, Burnett C et al: Serial STIR magnetic resonance imaging correlates with clinical score of activity in thyroid disease. *Eye* 2001; 15: 313-318.
20. Laitt RD, Hoh B, Wakeley C et al: The value of the short tau inversion recovery sequence in magnetic resonance imaging of thyroid eye disease. *BJR* 1994; 67: 244-247.
21. Ohnishi T, Noguchi S, Maurakami N et al: Extraocular muscles in Graves` ophthalmopathy - usefulness of T-relaxation measurements. *Radiology* 1994; 190: 857-862.
22. Prummel M, Gerding MN, Zonneveld FW et al: The usefulness of quantitative orbital magnetic resonance imaging in Graves` ophthalmopathy. *Clin Endocrinol* 2001; 54: 205-209.
23. Yokohama N, Nagataki S, Ashizawa K et al: Role of magnetic resonance imaging in the assessment of disease activity in thyroid-associated ophthalmopathy. *Thyroid* 2002; 12: 223-227.
24. Nagy EV, Toth J, Kaldi I et al: Graves` ophthalmopathy: eye muscle involvement in patients with diplopia. *Eur J Endocrinol* 2000; 142: 591-597.
25. Nishikawa M, Yoshimura M, Toyoda N et al: Correlation orbital muscle changes evaluated by magnetic resonance imaging and thyroid-stimulating antibody in patients with Graves` ophthalmopathy. *Acta Endocrinol* 1993; 129: 213-219.
26. Villadolid MC, Yokohama N, Izumi M et al: Untreated Graves` disease patients without clinical ophthalmopathy demonstrate a high frequency of extraocular muscle (EOM) enlargement by magnetic resonance. *J Clin Endocrinol Metab.* 1995; 80: 2830-2833.
27. Gorman CA: The measurements of change in Graves` ophthalmopathy. *Thyroid* 1998; 8: 539-543.
28. Nugent RA, Belkin RI, Neigel JM et al: Graves orbitopathy: 6. Correlation of CT and clinical findings. *Radiology* 1990; 177: 675-682.
29. Niniaris N, Hutwitz J, Chen JC et al: Correlation between computed tomography and magnetic resonance imaging in Graves` ophthalmopathy. *Can J Ophthalmol* 1994; 29: 9.