

Sygnatura: Pol J Radiol, 2007; 72(2): 36-44

Otrzymano: 2006.10.04
Zaakceptowano: 2007.02.15

Vascular rings and sling in children imaging with multislice CT

Artur Kobielski¹, Jacek Moll³, Paweł Dryżek⁴, Jerzy Stańczyk⁵, Magdalena Pierzchała⁵, Tomasz Moszura⁴, Witold D. Pietrzykowski³, Tadeusz Biegański^{1,2}¹ Department of Diagnostic Imaging, Polish Mother's Memorial Hospital, Research Institute, Lodz, Poland² Department of Pediatric Radiology, Medical University in Lodz, Poland³ Department of Cardiosurgery, Polish Mother's Memorial Hospital, Research Institute, Lodz, Poland⁴ Department of Cardiology, Polish Mother's Memorial Hospital, Research Institute, Lodz, Poland⁵ Department of Pediatric Cardiology, Medical University in Lodz, Poland**Author's address:** Artur Kobielski, Department of Diagnostic Imaging, Polish Mother's Memorial Hospital, Research Institute, 93-338 Łódź, Rzgowska 281/289 st., Poland, e-mail: arturkobielski@yahoo.com

Background:

The term „vascular ring” determines abnormal congenital arrangements of arteries that encircle trachea and esophagus. The rings may be partial or complete, composed only from the vessels or from the vessels combined with fibrous structure (usually *ligamentum arteriosum*). They are formed by derivatives of the embryonic aortic arches – most often from the IVth pairs (e.g. double aortic arches or right aortic arches) or from the VIth pairs (e.g. left pulmonary artery sling). Depending on the tightness of the ring, these abnormalities may be clinically asymptomatic, evoking repeated respiratory difficulties and/or dysphagia in children at the school age or pronounced respiratory distress in newborns. Nowadays MR or MSCT imaging is applied to visualize the vessels anomalies. **Aim:** To present the examples of MSCT appearances of the vascular rings and their effects on tracheobronchial tree and esophagus in children.

Material/Methods:

Five children, aged 1 month – 13 years, with suspicions of vascular rings underwent MSCT investigation of the chest by means of 16-row scanner (Aquillon, Toshiba), using voltage of 120 kVp, current values 40 mA – 170 mA and tube rotation time 500 ms. In all cases three dimensional reformatting was performed.

Results:

1. One-month-old girl with respiratory difficulties, cyanosis and recognized tetralogy of Fallot presented the anatomy of double aortic arch with left arch atresia. 2. Two children: 13-year-old boy with recurrent respiratory infections and stridor and 7-year-old girl treated for asthma (false positive diagnosis) – showed rings caused by right aortic arch with aberrant left subclavian artery, completed by left *ligamentum arteriosum*. 3. The left aortic arch with aberrant right subclavian artery (*arteria lusoria*) with esophageal compression was recognized in sixteen-month-old boy without clinical symptoms of dysphagia or respiratory difficulties. 4. Left pulmonary artery sling was seen in 13-month-old girl with respiratory distress; there were also: a.) concomitant common trunk for innominate artery and left common carotid artery and b.) persistent left vena cava superior. The compressions and stenoses of the tracheobronchial tree and/or esophagus were visualized in all patients. The radiation dose reduction was obtained due to the diminishing of the current values in the study protocol e.g. to 40 mA (20 mAs) in neonates and infants.

Conclusions:

MSCT, with low dose protocol, allows for accurate and comprehensive display of the vessels, trachea with main bronchi and esophagus in vascular rings in children. This visualization is significant and adequate for preoperative surgical planning.

Key words:

vascular ring • tracheal stenosis • dysphagia • children • MSCT

PDF file:

<http://www.polradiol.com/fulltxt.php?ICID=478090>

Background

Vascular rings are defects of large vessels which consist in their circular arrangement around trachea and esophagus. The rings can either be partial or full, encircling these organs completely. They can be composed only from the vessels or from the vessels combined with fibrous structure; the latter usually produces more diagnostic difficulties [1, 2]. The described abnormal vessel arrangement can result from developmental disorders in one or more of the six pairs of embryonic aortic arches [2]. Very often it is a congenital disease which concerns 4th pair of primary arches which, in normal conditions, transforms into left-sided aortic arch on the left and on the right-into brachiocephalic trunk with proximal part of right subclavian artery. Due to the disordered development, there can be a wide range of congenital lesions around the aortic arch and its branches, most often double arch or right-sided aortic arch. Less often the disorder affects the 6th pair of aortic arches which are the origin of pulmonary arteries and arterial duct, while the sling of left pulmonary artery is an example of particular developmental disorder [1, 2].

It is possible that the presence of vascular ring has no influence on anatomical image and function of adjacent organs but it often causes compression on tracheal and/or esophageal wall and leads to narrowing of lumen of these organs – hence the term of “vascular tracheo-esophageal compression syndrome” [3]. Obviously, occurrence of clinical symptoms and their intensity depend on the degree of narrowness- the degree of compression of trachea and esophagus by vessels and fibrous structures (usually *ligamentum arteriosum*). The observed symptoms, especially in infants, include cough and respiratory difficulties with associated cyanosis, caused or intensified during nursing and frequent, recurrent infections of respiratory system. Dysphagia occurs more often in older children and adult patients who were previously clinically asymptomatic [1-8].

The aim of diagnostic imaging in case of suspicion of vascular ring in view of planned surgical treatment should be [3]:

- precise presentation of anatomy of the structures around trachea and esophagus
- determination whether the clinical symptoms are caused by vascular abnormalities
- determination of lesions around trachea or esophagus, independent from vascular ring
- detection of significant disorders affecting heart (associated heart disease) and other vessels – outside the ring.

Such visualization can be provided by the MR or multislice CT technique in all the above-mentioned aspects.

This study presents images of vascular rings, trachea and esophagus obtained from 5 children by means of the latter method.

Materials and methods

From June 2003 to January 2006 five children: 3 girls and 2 boys, aged 1 month – 13 years, with suspicion of vascular ring, underwent one-step examination of the thorax using the multislice CT, after intravenous contrast medium administration.

Four patients with symptoms of dysfunctions in respiratory system were diagnosed and treated at the Clinic of Cardiology and Clinic of Cardiosurgery of Polish Mother's Memorial Hospital Research Institute and one patient (patient RT, nr 4) with abnormal esophagogram – at the Department of Pediatric Cardiology, Medical University in Lodz.

The CT examination was performed with 16-row Toshiba – Aquillon scanner at the “Kopernik” Diagnostic Centre in Lodz. Non-ionic contrast medium was applied in a dose of 1 ml/kg of body mass, with concentration of 300 mg I/ml. The technical parameters were: voltage 120 kVp, tube rotation time 500 ms and current values dependent on patient's age – range 40–170 mA. Three dimensional reconstructions of vessel images were performed in all patients, in selected patients also reconstructions of trachea and esophagus with virtual bronchoscopy.

Results

1. Double aortic arch with atresia of left arch

Patient WD, nr 1. 1-month-old girl, weight 4 kg, referred to CT exam due to respiratory difficulties, cyanosis, with suspicion of double aortic arch. Child born from pregnancy I, labor I, spontaneous, with birth weight of 2900 g, Apgar in the 1st minute -10 points, diagnosed cardiologically from the 1st day of life due to cyanosis. Echocardiography and Doppler examination of large vessels revealed congenital heart disease in form of tetralogy of Fallot and double aortic arch.

The image of thorax in a 4-week-old child showed wider shade of upper mediastinum on the right, which was described as a shadow of thymus; trachea in median line, air column in lower part of trachea - hardly visible.

CT examination was performed with the following parameters: 120 kVp, 40 mA i 500 ms.

The examination revealed double aortic arch with dominating right-sided arch and atresia of the left between left subclavian artery and descending aorta. Two arteries were branching off from the right arch: proximally- right common carotid artery and then right subclavian artery; similar order was observed in two arteries arising from the left aortic arch. Atresia of left arch concerned the section between the left subclavian artery and descending aorta (fig. 1A). We observed bilateral narrowing of tracheal lumen: on the right - by right-sided aortic arch and on the left- probably by fibrous structure (fig. 1B). Descending aorta was visible right to the spine. In 5th week of life the child underwent cardiosurgical procedure which consisted in anastomosis of left subclavian

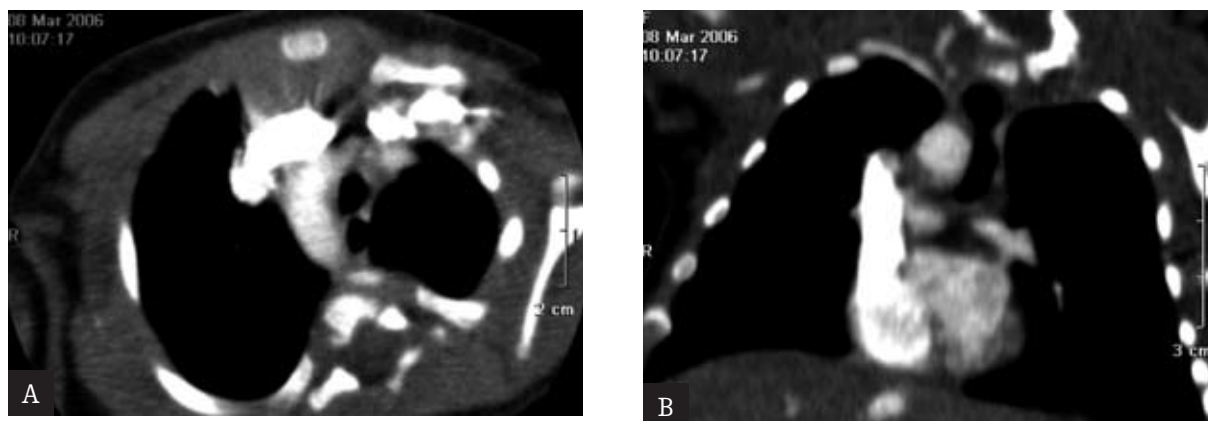


Figure 1. One-month-old girl presented with respiratory difficulties and cyanosis; double aortic arch with left arch atresia. **A.** Axial scan on the level of the left brachiocephalic vein: right-sided aortic arch with fibrous remnant of the left arch – between left subclavian artery and descending aorta. **B.** Frontal reconstructed image - bilateral tracheal narrowing: right-sided by aortic arch, on the left side due to the fibrous structure.

artery with left pulmonary artery and cutting the arterial duct located on the left side, what resulted in opening the ring.

2. Right-sided aortic arch with aberrant left subclavian artery.

Patient MS, No 2. A 13-year-old boy with recurrent infections of respiratory tract, with stridor and bad toleration of exercise was sent to the Clinic of Cardiology with suspicion of vascular ring.

The image of thorax showed right-sided aortic arch with modeling and narrowing of air column in trachea from the right side, while the trachea was slightly dislocated to the left (fig. 2A).

Echocardiographic and Doppler examination of large vessels showed no deviation from standard, neither within the aortic arch, nor its branches or location of descending aorta. Catheterization of heart with angiography of large vessels showed right-sided aortic arch with both common carotid arteries branching off from anterior part of arch; both subclavian arteries arose from the posterior part of aortic arch. Multislice tomography of thorax was carried out using 120 kVp, 170 mA and 500 ms. Right-sided aortic arch with the left common carotid artery branching off from ascending part of artery was visualized, together with (in order): right common carotid artery and right subclavian artery. The left subclavian artery (aberrant artery) arose from evident bulge of the arch- the Kommerell's diverticulum (fig. 2B). The descending aorta was on the right side. The trachea – on the right compressed by the aortic arch and in the back-by Kommerell's diverticulum (fig. 2C). The operation performed two weeks later confirmed the CT scan. The vascular ring was closed on the left side with arterial ligament, which ran from Kommerell's diverticulum. This ligament was cut opening the ring.

Patient PJ, No 3. A 7-year-old girl referred to CT exam with suspicion of vascular ring. Since infancy, the child showed recurrent infections of respiratory tract with dyspnea; hospitalized repeatedly and treated for bronchial

asthma. The diagnostics and treatment in two different pediatric academic institutes allowed diagnosing the vascular ring.

The roentgen image of the thorax, apart from interstitial opacities within the lungs – most probably with character of chronic inflammatory lesions, showed no deviation from standard, the trachea in median line with no visible signs of compression.

The echo and Doppler examination of large vessels showed right-sided aortic arch with four arterial vessels branching off.

The parameters of CT examination were as follows: 120 kVp, 100 mA and 500 ms. The examination revealed right-sided aortic arch with branches (starting from the descending aorta): left common carotid artery and then the right arteries – common carotid and subclavian artery; left subclavian artery (the aberrant artery) arising from the Kommerell's diverticulum. The latter caused impression of membranaceous trachea (fig. 3A). Also, the lumen of right main bronchus was narrowed between the descending aorta and right pulmonary artery. Descending aorta on the right (fig. 3B). The above-mentioned narrowing was also visualized with the method of virtual bronchoscopy (fig. 3C).

Elective surgical procedure carried out two months after the CT consisted in cutting the arterial ligament located on the left side. Further clinical observation presented regression of dyspnea previously evaluated as a symptom of bronchial asthma.

3. Left-sided aortic arch with aberrant right subclavian artery.

Patient RT, No 4. A 16-month-old boy with compression of esophagus at the level of Th3 revealed in radiological examination was referred to CT exam with suspicion of vascular defect. Child born from pregnancy VII, labor V, in 35th week of intrauterine life with birth weight of 2800 g and 8 points in Apgar scale in the first minute of life. Due to murmur above the heart which was observed since he was born and patent arterial duct the child was under cardiol-

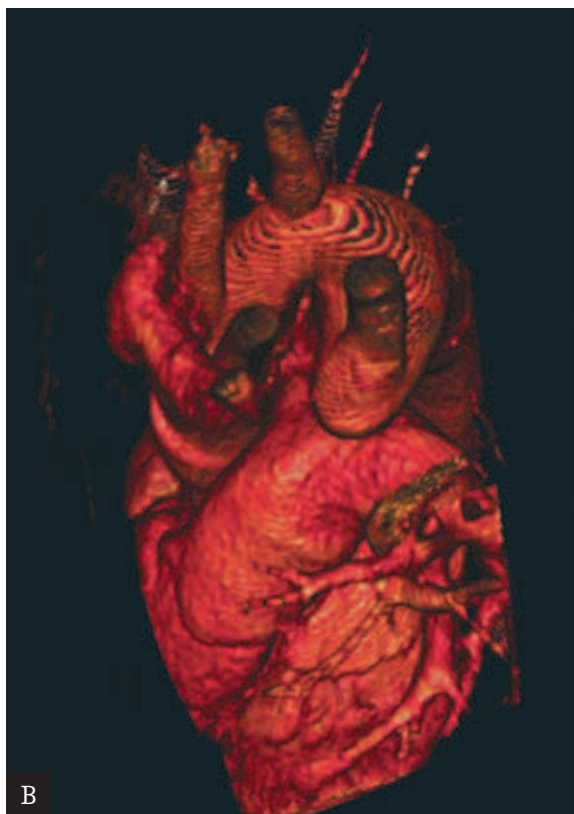
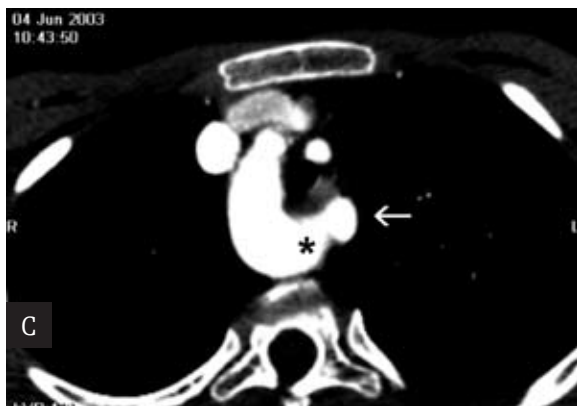
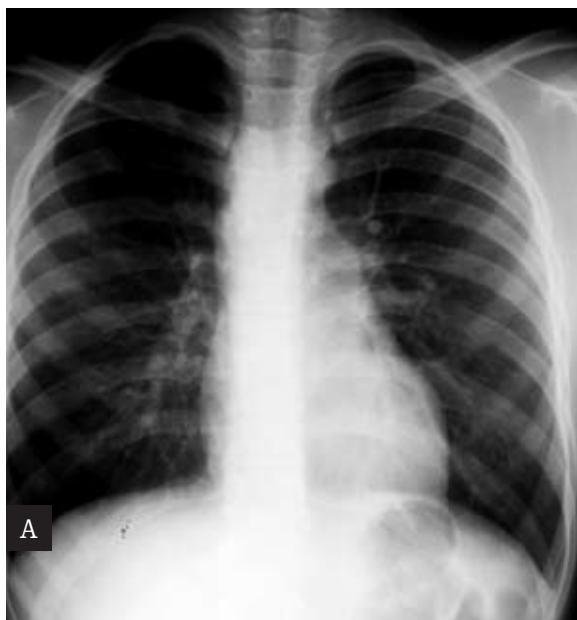

Figure 2. Boy, 13-year-old, with recurrent pneumonia and stridor; right-sided aortic arch with aberrant left subclavian artery. **A.** Chest X-ray: narrowing of the air column in trachea by right-sided arch. **B.** 3D reconstructed image: four branches of the aortic arch – left subclavian artery arising from Kommerrel’s diverticulum; vascular ring is tight. **C.** Axial scan on the level of the aortic arch: right-sided aortic arch with aberrant left subclavian artery (arrow) arising from the Kommerrel’s diverticulum (asterisk); tracheal narrowing.

gic care. In 9th month of life barium contrast image showed narrowing of esophageal lumen at the level of Th3, probably caused by a structure located prevertebrally, what led to the suspicion of abnormal course of the vessel (fig. 4A, 4B). However, the patient was generally in good condition, without dysphagia or symptoms from respiratory system. In echocardiographic examination the anatomy of heart and aortic arch were evaluated as normal. Patent arterial duct was not found. The boy was also diagnosed with nutritional allergy. Six months later another contrast roentgen examination of the child (15-month-old) confirmed the previously described compression of esophagus. Follow-up echocardiographic examination revealed a vessel with arterial flow arising from the descending part of aortic arch.

The CT of thorax was carried out with 120 kVp, 50 mA and 500 ms. We found left-sided aortic arch and branch of the right subclavian artery left to the arch, as the last branch of aortic arch (*arteria lusoria*) (fig. 4C). The artery ran behind the esophagus, narrowed its lumen causing dilatation of esophagus above and below the obstruction (fig. 4D and 4E). The image of lumen and tracheal walls was normal. The descending aorta led on the left side. A lobe of azygos vein was considered as an additional anomaly. A 2-year-old

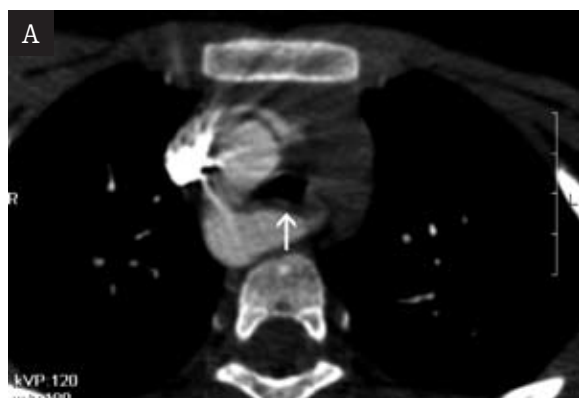
child underwent another clinical evaluation and proved to be in a good condition, respiratory and circulatory efficient, with no signs of dysphagia.

4. Sling of left pulmonary artery

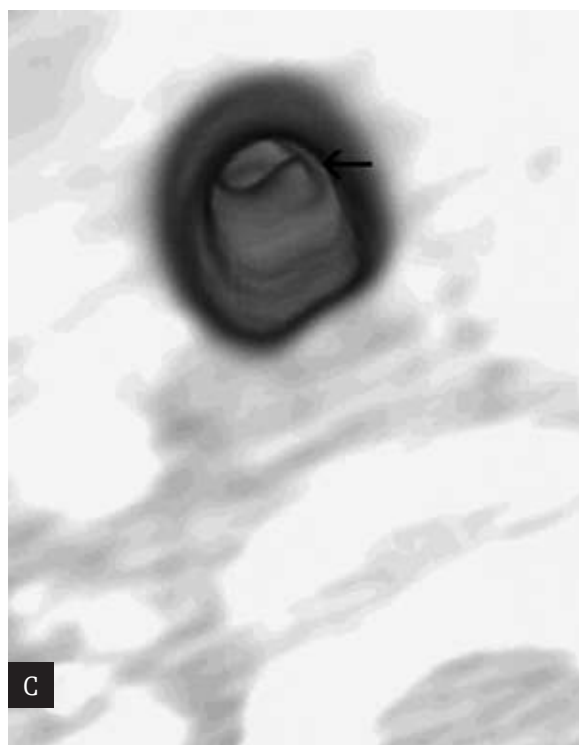
Patient AD, No 5. A 13-month-old girl with respiratory distress and congenital vascular anomaly causing compression of trachea, was admitted to the Clinic of Cardiology for evaluation of the circulatory system and qualification to defect correction.

In echo examination the heart was normal; in Doppler exam there was persistent left superior vena cava; pulmonary trunk significantly elongated, with right pulmonary artery narrowed around the bifurcation and dilatated from that point on; left pulmonary artery – long, narrow, with abnormal course.

The CT was performed with voltage of 120 kVp, current of 40 mA and time of tube rotation of 500 ms. Loop of left pulmonary artery was found – the artery led transversely at the level of Th5, initially to the right, around the right tracheal wall, causing narrowing of its lumen right above



the bifurcation, and then between trachea and esophagus-



to the left pulmonary hilus (fig. 5A). Left-sided aortic arch; descending aorta on the left. Other vascular anomalies included: a) short common trunk arising from aortic arch right before the trachea, its branches were brachiocephalic trunk and left common carotid artery; b) persistent left superior vena cava (fig. 5B). Moreover, within the tracheobronchial tree we confirmed the presence of tracheal diverticulum on its lateral wall on the right side at the level of Th3 and narrowing of the right main bronchus. The left main bronchus was also narrow (fig. 5C).

The surgical procedure carried out several days after the CT examination confirmed not only the radiological assessment of vascular anomalies but also the changes in respiratory tract. The course of left pulmonary artery was corrected. The roentgen images of thorax taken during that time clearly showed narrowed lumen of inferior part of the trachea which led in median line. Five days later, due to ventilation difficulties the narrowed segment of trachea was excised- 1 cm long, right above the bifurcation.

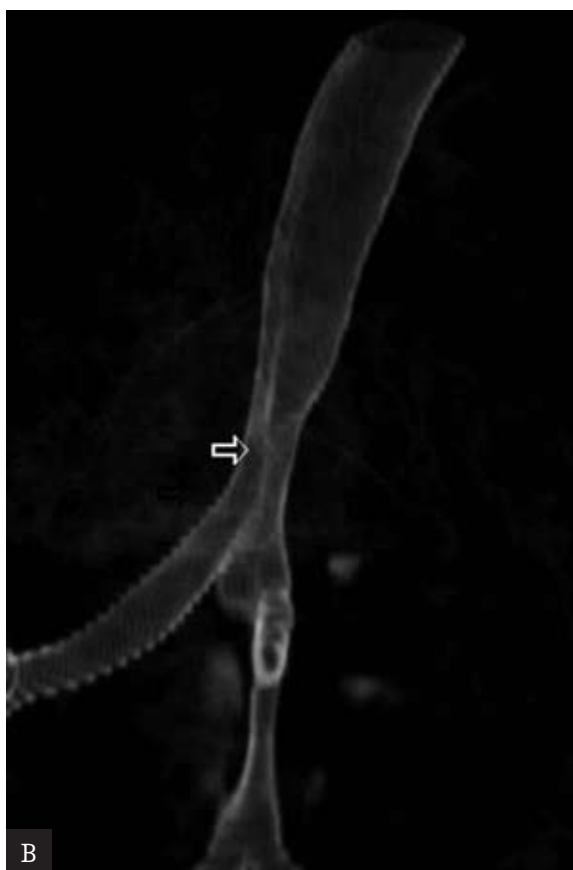


Figure 3. Girl, 7-year-old with recurrent respiratory infections and dyspnea; right-sided aortic arch with aberrant left subclavian artery. **A.** Axial scan demonstrates right-sided aortic arch with aberrant left subclavian artery, arising from Kommerell's diverticulum; membranaceous wall of the trachea is impressed (arrow). **B.** 3D reconstruction of the tracheobronchial tree presents the impressions of the posterior tracheal wall (arrow) and proximal part of the right main bronchus. **C.** Virtual bronchoscopy – stenosis of the right main bronchus (arrow).

Ventilation problems did not recede and the patient died in the postoperative period. The pathomorphologic examination of the excised tracheal sample revealed hypoplasia of the organ – the diameter of its lumen did not exceed 3 mm; the structure of tracheal wall was described as normal.

Discussion

Anatomy of vascular rings

Vascular rings show wide spectrum of developmental disorders in both – the clinical and anatomical aspect. In this group of pathologies circular arrangement of vessels can be clinically asymptomatic [1, 9], or with symptoms that occur during hemodynamic perturbances, e.g. pregnancy [5] or with very early life threatening respiratory distress.

Defect which is closest to persistent embryonic structures is the double aortic arch – on the left and right side – bilaterally patent. The disorder results from lack of involution

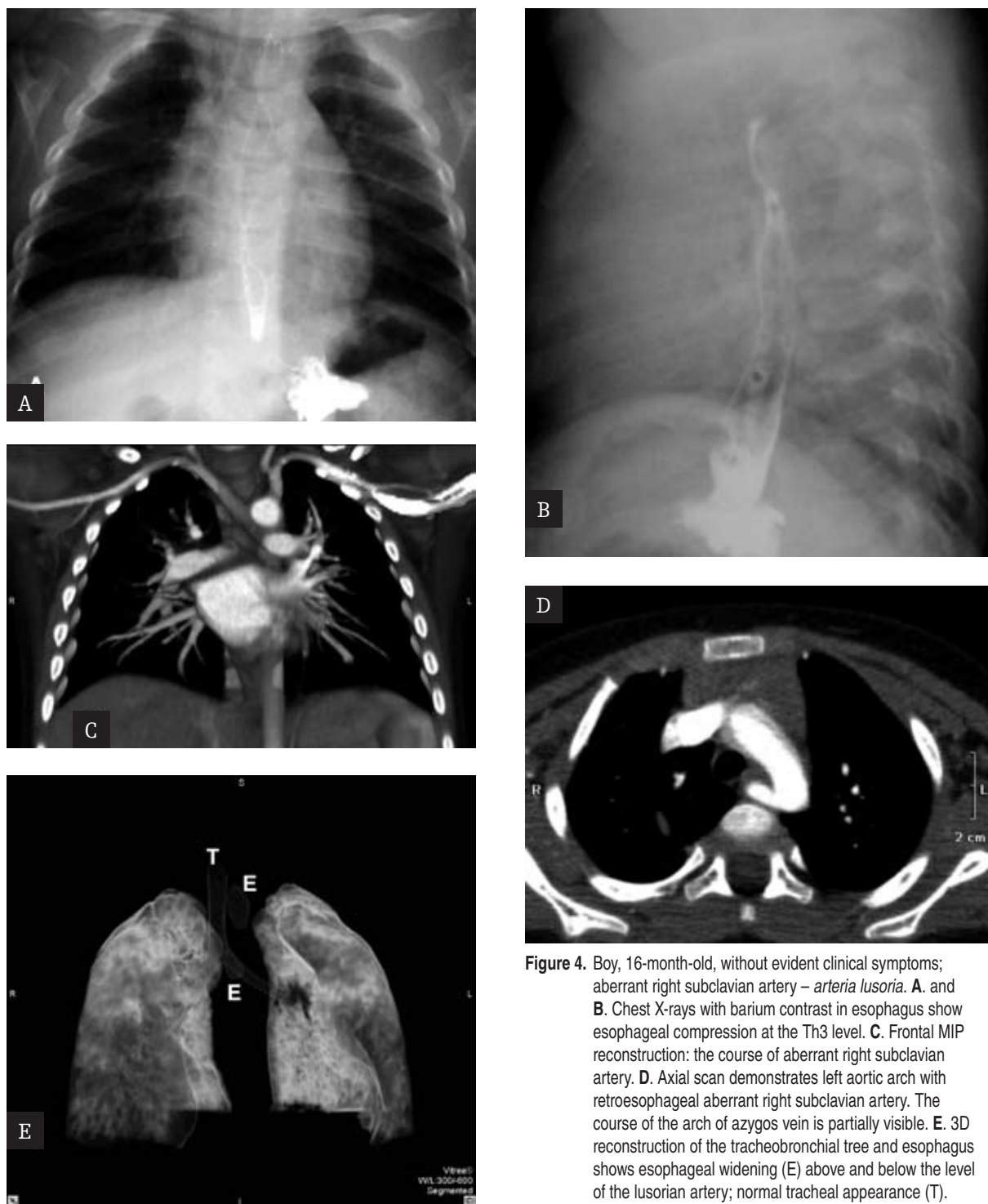


Figure 4. Boy, 16-month-old, without evident clinical symptoms; aberrant right subclavian artery – *arteria lusoria*. **A.** and **B.** Chest X-rays with barium contrast in esophagus show esophageal compression at the Th3 level. **C.** Frontal MIP reconstruction: the course of aberrant right subclavian artery. **D.** Axial scan demonstrates left aortic arch with retroesophageal aberrant right subclavian artery. The course of the arch of azygos vein is partially visible. **E.** 3D reconstruction of the tracheobronchial tree and esophagus shows esophageal widening (E) above and below the level of the lusorian artery; normal tracheal appearance (T).

of the right arch. In such case this arch is usually dominant-wider and located a bit higher (cranial) than the left. Both arches form a tight ring encircling the trachea and esophagus, thus the characteristic esophagogram image in frontal plane- in form of bilateral contrast loss with shape of the "S" letter. Patent arch on one side (most often right) with partial atresia of the arch on the opposite side is a type of bilateral aortic arch. Atresia can affect either the segment between common carotid artery and subclavian artery or between subclavian artery and descending

aorta [1]. The latter variant occurred in patient No 1. Similarly to complete patency of both arches, also in the other variant 4 singular vessels branch off from the ring and the ring itself is relatively narrow; therefore, the symptoms are early and intense- the patient we diagnosed (1 month old) was the youngest of all children in the group of vascular ring patients. In 20 % of patients with double aortic arch the defect coexists with heart diseases, often with tetralogy of Fallot [2]. It was also observed in our patient.

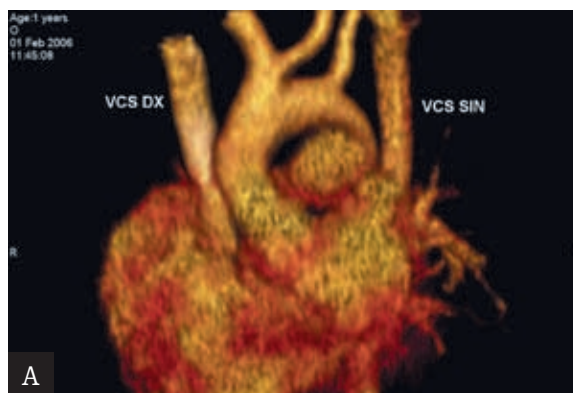
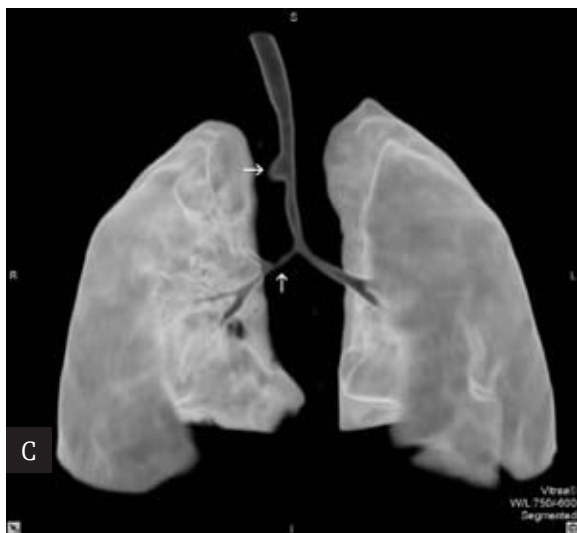
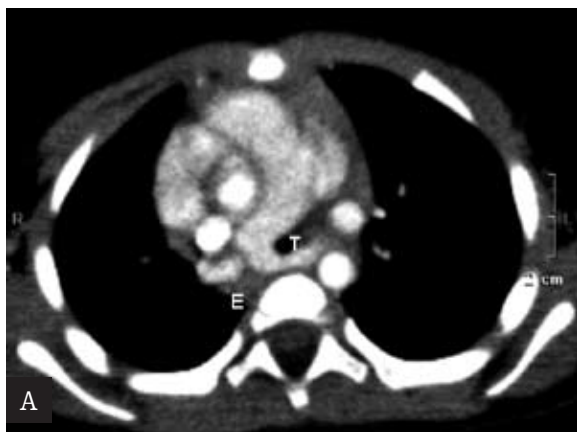
Figure 5. Girl, 13-month-old, with respiratory distress; sling of the left pulmonary artery. **A.** Axial scan at the level of the pulmonary trunk.: sling of the left pulmonary artery – between the trachea (T) and esophagus (E). **B.** 3D reconstruction of the main arteries; common trunk for innominate artery and left common carotid artery and persistent left vena cava superior (VCS SIN). **C.** 3D reconstruction of the tracheobronchial tree and lungs: right-sided tracheal diverticulum (horizontal arrow) and stenosis of the trachea and right main bronchus (vertical arrow).

The anatomic basis of vascular ring lies more often in the right-sided arch than double aortic arch. Depending on the place of involution of the left arch, it is related with aberrant left subclavian artery (most often) or less often with the so-called mirror image of the left arch (branches of the right aortic arch are, beginning from the ascending part, brachiocephalic trunk, left common carotid artery and left subclavian artery) or with aberrant left-sided brachiocephalic trunk [1, 2, 4-6, 8-13]. Considering the variant of aberrant brachiocephalic trunk or aberrant left subclavian artery, the vessels arise from the aortic diverticulum (Kommerell's d.), which is located in the posterior part of right-sided aortic arch on the left and constitutes a remnant of the left aortic arch. The diverticulum usually causes compression of the posterior esophageal wall and/or part of membranous trachea. The most frequent form of vascular ring, also referred to as Neuhauser's anomaly, connected to right-sided aortic arch, was found in 2 of our patients: MS No 2 and PJ No 3. In differentiation with double aortic arch connected with partial atresia of left arch the diagnosis was supported by right-sided course of descending aorta- typical for Neuhauser's anomaly.

Vascular ring completed with left-sided arterial ligament, as it was seen in 2 of our patients, is looser in case of right-sided arch compared to the tight ring in double aortic arch [2]. Such correlation between the type of ring

and degree of tightness in case of right-sided aortic arch is also suggested by relatively late, school age, of the diagnosed patients (7th and 13th year of age). However, in our patients we found no signs of dysphagia- symptom occurring most often in adults with this variant of ring [4-6, 8, 10], nor coexisting heart diseases – often accompanying the right-sided aortic arch with aberrant left subclavian artery [2, 14].

The anatomic image of our next patient, RT, No 4, which showed aberrant right subclavian artery that led transversely in the posterior part of esophagus, at the level of Th3, was defined at the end of XVIII century by David Bayford as *lusus naturae* (joke, freak of nature) and the term he introduced at that time- *arteria lusoria* – is still commonly used [15]. It is a frequent anomaly affecting 0.5% - 1% of population, which manifests itself in form of incomplete ring at the level of Th2-Th4 and is usually clinically asymptomatic [6, 15]. Dysphagia related to the aberrant right subclavian artery (*dysphagia lusoria*), occurs more often in adult patients and has various causes, such as aneurysms or sclerosis of this artery; however, the causes of dysphagia are sometimes difficult to define [7, 16]. Nowadays, the term *dysphagia lusoria* also includes dysphagia caused by all other forms of vascular rings [8]. In childhood, the *dysphagia lusoria* occurs with additional congenital diseases such as right-sided *ligamentum arteriosum* or common origin of the carotid arteries right before the trachea- *truncus bicaroticus* (the arteries embrace the trachea and esophagus in a bifurcated manner) or presence of the Kommerell's diverticulum [1, 4, 7, 15]. In our patient, apart from *arteria lusoria*, we found no other additional defects within the aortic arch that would close the ring of aberrant right subclavian artery. Although the compression of esophagus by transverse vessel was clearly visualized, the child had no ailments from esophagus or respiratory tract.

The developmental disorder of the 6th pair of embryonic aortic arches observed in AD girl, No 5, was the left pulmonary artery of abnormal course – between trachea and esophagus – which formed a sling and caused stenosis of trachea and right main bronchus. Today we know two types of such sling [13]. In type I the respiratory tract usually has normal structure although right-sided tracheal bronchus is also possible; compression of the inferior part of trachea and right bronchus by the surrounding pulmonary artery can cause tracheomalacia and narrowing of the lumen of this section of respiratory tract. The more common type II is associated with significant hypoplasia and stenosis of inferior part of trachea and bronchi, low course of artery forming a sling (Th6-Th7), abnormal division of respiratory tract and frequent disorders of cartilaginous rings of trachea. This type is characterised by other congenital anomalies as well, especially heart defects. The dysfunctions found in our patient suggest a transient form of the disorder.

Type I is characterized by a sling at Th5 and right-sided tracheal diverticulum at the Th3 which was most probably a rudimentary form of tracheal bronchus. On the other hand, lesions typical for type II are: considerable narrowing of trachea and bronchi, obtuse angle of tracheal bifurcation and associated vascular anomalies in form of common origin of brachiocephalic trunk and left carotid artery from aorta and persistent *vena cava superior sinistra*.

Diagnosics imaging of vascular ring

The X-ray of chest (in frontal and lateral plane) and esophagogram performed using barium also in two projections have been for 60 years the standard phase of preliminary radiological diagnostics in cases of suspected vascular ring. Diagnosis of right-sided aortic arch, often connected with the ring, can be made when: a) aortic arch – its transverse part – is visible on the right, b) trachea is located left to the spine, c) compression and modeling of the tracheal lumen on the right is visible, d) descending aorta is on the right. However, in infants the evaluation of mediastinum is usually difficult due to the presence of thymus, and the course of descending aorta is often hardly visible.

Moreover, Strife et al. studied 121 radiograms of chest (in frontal plane) from patients aged less than 2 months, with right-sided aortic arch and found the trachea on the left side only in 13% of children, modeling of the air column in trachea in 17% and visualization of descending aorta in 20% of patients. In older patients – up to 12 years old – the occurrence of these diagnostic symptoms was visibly higher reaching the values of 61%-88% [17]. Therefore, the diagnostic value of chest X-ray in diagnosing the vascular ring in youngest patients is disputable and the image of mediastinal organs described as normal does not exclude this group of pathologies [13, 17]. It should also be remembered that the presence of narrowed trachea in small children can be evaluated more precisely in lateral plane, especially if the compression affects the posterior wall of the organ [1, 2]. In our group of 5 children with vascular rings of varied anatomical background, only the thoracic image from the oldest – a 13-year-old patient with right-sided aortic arch – showed clear radiological features suggesting this type of disorder.

Until the introduction of MR and multislice CT, the esophagogram performed with the use of barium of high density was commonly considered to be indispensable in diagnostics of vascular rings. Also today, the contrast examination of esophagus provides significant information showing abnormal course of vessels. The following projections are also believed to be necessary for reliable evaluation: AP, right and left anterior oblique projection [2]. In patient RT No 4 the examination of esophagus revealed its narrowing and unequivocal characteristic impression from the backplace of *arteria lusoria* (stated later, in CT exam). However, the child showed no symptoms of dysphagia during hitherto observation.

Hernanz-Schulman believes that correct esophagogram cancels out the presence of vascular ring [2]. On the other hand, Alper et al. investigated 15 patients with *dysphagia lusoria* and obtained positive result of esophagogram only in 9 of them (60%). The visible impression of esophagus has an unspecific character and can result from enlarged lymph nodes (*lymphoma*, tuberculosis), cysts or other prevertebral tumors [6]. Therefore, the esophagogram is considered to be a useful stage of diagnostics of vascular rings when clinical symptoms are less obvious and the image of chest-equivocal [3]. Intense clinical symptoms and chest X-ray or Doppler examination suggesting vascular ring should inspire imaging with the use of multislice CT with 3D reconstruction or MR. These examinations directly indicate vascular arrangement, presence or lack of tracheal and/or esophageal compression and possibly other anatomic abnormalities of these organs. With today's technical development, the choice of imaging method between multislice CT and MR is not definite. Both methods allow precise evaluation of the investigated structures and planning the procedure. MR (including 3D MRA with gadolinium) is a relatively long examination which requires sedation or general anesthesia of the child. On the other hand, in such cases there is neither ionizing radiation nor iodine contrast agents. Multislice CT scan can be performed in a short time, without general anesthesia and the use of proper technical parameters can reduce the radiation dose.

Ultrasonography (echocardiography with Doppler examination) is a complementary diagnostic examination which enables evaluation of heart diseases accompanying vascular rings. However, the precision of assessment of vascular rings elements and topography of the remaining large vessels in both our patients and based on the data from other authors – is not sufficient for therapeutic decisions [1-3, 18].

Classical angiography, although showing directly the vascular structures of the ring and being one of the basic diagnostic examinations until recently, due to its invasiveness and lack of complete spatial visualization of vessels and adjacent organs was replaced with MR angiography and angio-CT.

In spite of the fact that the lumen of vessels which form rings is clearly visible in classical angiography, angioMR or angioCT, usually none of these imaging techniques shows directly the fibrous parts of vascular ring (arterial ligament or part of arch affected by atresia). Compression of trachea

at the level where the vessel does not have its course and location of fibrous elements is possible, prove the presence of such structures; these parts can also deform the tracheal lumen by its pulling [1, 11, 12]. In this aspect esophagography can turn out to be important and indispensable as it indirectly shows the presence of fibrous structures of the ring during contrast passage through the esophagus. It enables not only finding the ring but also differentiation of its various forms [11].

Reduction of exposure to ionizing radiation in evaluation of vascular rings by means of multislice CT

Because of relatively high exposure to ionizing radiation during CT exams in children, it is commonly advised to modify the examination protocol by conditioning the technical parameters on the age or body mass of the patient [19]. The easiest method is to reduce the value of current or product of the current value and time of tube rotation. Thus, in our youngest patients aged 1, 13 and 16 months the current values were 40 mA, 40 mA, 50 mA respectively, while the product of current and time was 20-25 mAs. It is one of the smallest values reported in literature for the so-called low-dose technique in multislice tomography used to assess the vascular rings and in virtual tracheobroncho-

scopy in infants and babies [18, 20, 21]. The values we used in older children, 7 and 13 y.o. were 120 mA i 170 mA but could well be lower with no significant loss of the quality of the image [19]. These examinations were performed as one of the first (2003), with manufacturer's protocol taken into consideration.

Additional way to reduce the dose is to limit the current voltage to 80 kVp [18, 20, 21]. The technique (80 kVp, 20-40 mAs) allows precise visualization of both- the vessels that form rings and lesions within the lumen of the tracheobronchial tree. Average effective dose calculated based on 40 such examinations in children was 1.2 ± 0.57 mSv what produces exposure comparable with 60 X-rays of thorax [18].

Conclusions

In children, the multislice CT with the low-dose protocol enables precise and complete visualization of vessels, trachea together with main bronchi and esophagus in vascular rings.

This kind of visualization has primary importance and is sufficient for planning a cardiovascular procedure.

References:

- Hernanz-Schulman M: Vascular rings: a practical approach to imaging diagnosis. *Pediatr Radiol*, 2005; 35: 961-979.
- Oddone M, Granata C, Vercellino N et al: Multi-modality evaluation of the abnormalities of the aortic arches in children: techniques and imaging spectrum with emphasis on MRI. *Pediatr Radiol*, 2005; 35: 947-960.
- Walters HL: Vascular tracheoesophageal compressive syndromes: a surgeon's view. *Pediatr Radiol*, 2005; 35: 945-946.
- Janssen M, Baggen MGA, Veen HF et al: Dysphagia lusoria: clinical aspects, manometric findings, diagnosis, and therapy. *Am J Gastroenterol*, 2000; 95: 1411-1416.
- James RCW, Murty GE: Previously undiagnosed congenital vascular ring presenting as dysphagia in a six-week post-partum female. *J Laryng Otol*, 2000; 114: 881-882.
- Alper F, Akgun M, Kantarci M et al: Demonstration of vascular abnormalities compressing esophagus by MDCT: Special focus on dysphagia lusoria. *Eur J Radiol* 2006; 59: 82-87.
- Hassan W, Omrani A AL, Neimatallah M et al.: Dysphagia lusoria caused by aberrant right subclavian artery, Kommerell's diverticulum, legamentum ring, right descending aorta, and absent left pulmonary artery: a report of a unique vascular congenital disease undetected until adulthood and a review of the literature. *Pediatr Cardiol*, 2005; 26: 851-855.
- Morris CD, Kanter KR, Miller JI et al: Late-onset dysphagia lusoria. *Ann Thorac Surg* 2000; 71: 710-712.
- Nakajima Y, Satomi G, Kawamura T et al.: Right aortic arch with aberrant retroesophageal innominate artery: a report of 2 cases and review of the literature. *Int J Cardiol*, 1993; 38: 247-251.
- Salanitri J: MR angiography of aberrant left subclavian artery arising from right-sided thoracic aortic arch. *Br J Radiol*, 2005; 78: 961-966.
- Schlesinger AE, Mendeloff E, Sharkey AM et al: MR of right aortic arch with mirror-image branching and a left ligamentum arteriosum: an unusual cause of a vascular ring. *Pediatr Radiol*, 1995; 25: 455-457.
- Midiri M, Finazzo M, Pilato M et al: Right aortic arch with aberrant left innominate artery: MR imaging findings. *Eur Radiol*, 1999; 9: 311-315.
- Newman B, Meza MP, Towbin RB et al: Left pulmonary artery sling: diagnosis and delineation of associated tracheobronchial anomalies with MR. *Pediatr Radiol*, 1996; 26: 661-668.
- Knight L, Edwards J: Right aortic arch: types and associated malformations. *Circulation* 1974; 50: 1047-1051.
- Brown DL, Chapman WC, Edward WH et al: Dysphagia lusoria: aberrant right subclavian artery with a Kommerell's diverticulum. *Am Surg*, 1993; 59: 582-586.
- Kamiya H, Knobloch K, Lotz J et al: Surgical treatment of aberrant right subclavian artery (arteria lusoria) aneurysm using three different methods. *Ann Thorac Surg* 2006; 82: 187-190.
- Strife JL, Matsumoto J, Bisset GS et al: The position of the trachea in infants and children with right aortic arch. *Pediatr Radiol*, 1989; 19: 226-229.
- Benson C, Taylor A, Rossi UG et al: Three-dimensional anatomy of the great vessels defined by 16-slice multi-detector CT angiography in neonates, infants, children and adolescents with congenital heart disease. *Pediatr Radiol*, 2005; 35 Suppl 2: S109.
- Frush DP: Review of radiation issues for computed tomography. *Semin Ultrasound CT MRI*, 2004; 25: 17-24.
- Heyer CM, Lemburg S P, Nuesslein TG et al: Low dose multidetector-CT generated virtual tracheobronchoscopy to evaluate pediatric airway abnormalities. *Pediatr Radiol*, 2006; 36 Suppl 1: 68.
- Honnef D, Wildberger JE, Das M et al: Evaluation of stridor in children with low-dose 16-multislice (MSCT) using virtual bronchoscopy and bronchography. *Pediatr Radiol*, 2005; 35 Suppl 2: S108.