

Open Access Maced J Med Sci electronic publication ahead of print,
published on June 14, 2019 as <https://doi.org/10.3889/oamjms.2019.487>

ID Design Press, Skopje, Republic of Macedonia
Open Access Macedonian Journal of Medical Sciences.
<https://doi.org/10.3889/oamjms.2019.487>
eISSN: 1857-9655
Case Report



Incomitant Exotropia After Nasal Polyp Surgery

Ni Made Ayu Surasmiasi^{*}, Ni Made Wasiastiti Budi, AAA Sukartini Djelantik, Ni Made Laksmi Utari, Putu Yuliawati, Ni Made Ari Suryathi

Ophthalmology Department, Udayana University, Faculty of Medicine, Sanglah Hospital, Denpasar, Bali, Indonesia

Abstract

Citation: Surasmiasi NMA, Budi NMW, Djelantik AAA S, Utari NML, Yuliawati P, Suryathi NMA. Incomitant Exotropia after Nasal Polyp Surgery. Open Access Maced J Med Sci. <https://doi.org/10.3889/oamjms.2019.487>

Keywords: Incomitant; Exotropia; Nasal Polyp

***Correspondence:** Ni Made Ayu Surasmiasi. Ophthalmology Department, Udayana University Faculty of Medicine Sanglah Hospital, Denpasar, Bali - Indonesia. E-mail: agrasidi01@gmail.com

Received: 21-Apr-2019; **Revised:** 25-May-2019; **Accepted:** 26-May-2019; **Online first:** 14-Jun-2019

Copyright: © 2019 Ni Made Ayu Surasmiasi, Ni Made Wasiastiti Budi, AAA Sukartini Djelantik, Ni Made Laksmi Utari, Putu Yuliawati, Ni Made Ari Suryathi. This is an open-access article distributed under the terms of the Creative Commons Attribution-NonCommercial 4.0 International License (CC BY-NC 4.0)

Funding: This research did not receive any financial support

Competing Interests: The authors have declared that no competing interests exist

BACKGROUND: Incomitant exotropia is one of ocular complication that has been reported after intranasal surgery. This case report aims to describe the causes of exotropia in a patient with a history of nasal polyp surgery.

CASE PRESENTATION: A 50-years-old male, came with the main complaint of double vision 1 month after nasal polyp surgery. He also complained his right eye turned outward. The visual acuity on the right eye was 6/7.5 with his head turn to the left. On the examination, the Hirschberg test was XT 45°, and the Krimsky test > 95 ΔBI. Duction and version test on the right eye were -4 adduction. There was no shifting on the cover-uncover test. Ishihara test was within normal limit, and there was suppression on the right eye in WFDT. On force generation test, we found limited adduction on the right eye and no restriction in force duction test. Head MRI showed atrophy of medial recti on the right eye, 2.2 mm in size. The patient underwent vertical muscle transposition procedure surgery, and it was found atrophy of medial recti without any rupture. Two months after surgery, the double vision was decreased, the result of the Hirschberg test was XT 30° and Krimsky test 65°ΔBI.

DISCUSSION: Nasal polyp surgery-related incomitant exotropia mostly caused by extraocular muscles rupture. In this case, we found no rupture. Therefore, we suspected the abnormalities of muscles vascularisation, supported by the atrophy of medial recti.

Introduction

A nasal polyp is a chronic inflammatory process in the nasal mucosa, or paranasal sinuses which characterised by edematous mass with infection is the most important factor in this process. Prevalence of polyp nasal in Indonesian was up to 4.63% of all register patient at Dr Soetomo Surabaya Hospital. In the last ten years, sinus surgery techniques that commonly used is Endoscopic, which is commonly used for intranasal ethmoidectomy. Besides the advantage, endoscopic had a risk to damage the extraocular muscle, especially at ethmoidal sinuses. The estimated rate of ocular injury after intranasal sinus surgery is up to 3%. The most common ocular complications after paranasal and intranasal polyps' surgery such as extraocular muscle rupture and extraocular muscle paralysis, vascular disorders or extraocular muscle innervation, microvascular infarction, chronic infection or inflammation, tumour mass compression. Incomitant exotropia is one of ocular complication that had been

reported after intranasal surgery [1], [2]. Incomitant exotropia is a form of strabismus which is outward deviation of the eyes with different angles of deviation in different motion field. The most common caused is due to paralysis or restriction [3], [4].

This case report aims to describe the causes of exotropia in a patient with a history of nasal polyp surgery.

Case Presentation

A 50-years old, male patient whose initial presentation was a double vision in the past one month after nasal polyp surgery, and it had been getting worse. The right eye turned outward with minimal blurry vision. History of trauma and neurological disorder was denied.

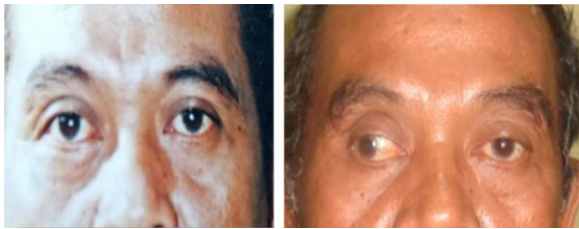

Figure 1: Physical finding before polyp surgery (left) dan after polyp surgery (right)

The visual acuity on the right eye was 6/7.5 with his head turn to the left. Position of the right eye was deviation laterally. On the examination, the Hirschberg test was XT 45°, and the Krimsky test > 95 ΔBI. Duction and version test on the right eye were -4 adduction. There was no shifting on the cover-uncover test. Ishihara test was within normal limit, but at Farnsworth D-15 test was found a red-green colour deficiency. There was suppression on the right eye in WFDT. The TNO test showed gross stereoscopies. On force generation test, we found limited adduction on the right eye and no restriction in force duction test.

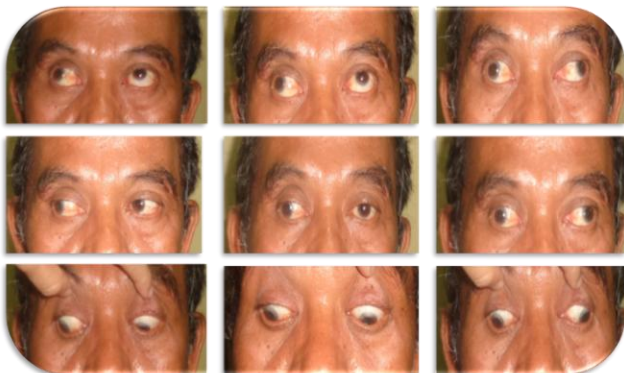

Figure 2: Ocular movements showed right exotropia

Head MRI showed right medial rectus muscle atrophy 2.2 mm in size, hypertrophy inferior nasal concha extra and sinistra, right lateral nasal cavum deformity post-surgery, chronic of right maxillary sinusitis, right and left ethmoid, and middle left frontal.

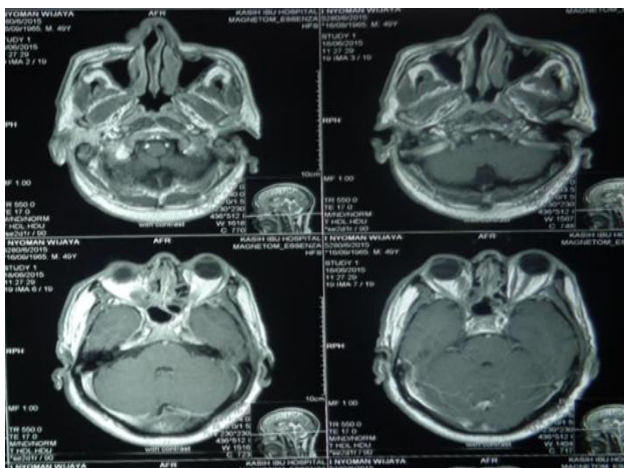


Figure 3: Head MRI showed atrophy of medial recti

We planned surgery on the right eye, with *vertical muscle transposition procedure*.

During the evaluation, there was no restriction of medial recti muscle on Forced Duction Test. Atrophy of medial recti was found during exploration right eye surgery. The medication after surgery was topical antibiotic-antiinflammation.

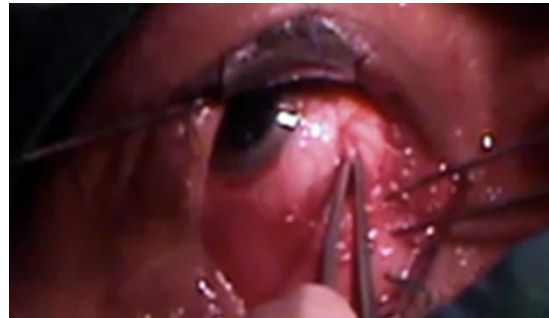

Figure 4: Atrophy of medial recti was found during exploration right eye surgery

Two months after surgery, the double vision was decreased, the result of the Hirschberg test was XT 30° and Krimsky test 65°ΔBI.

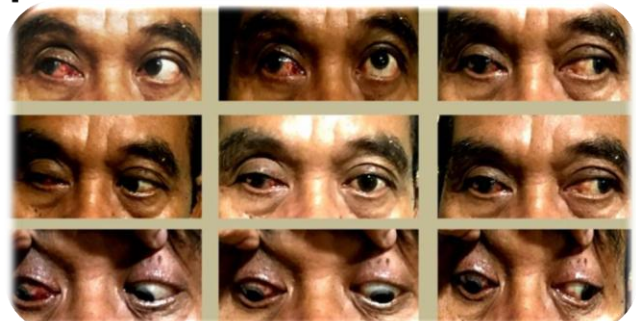

Figure 5: Ocular movements after vertical muscle transposition procedure

Discussion

A nasal polyp is a chronic inflammatory process in the nasal mucosa, or paranasal sinuses which characterised by edematous mass with infection is the most important factor in this process. Incomitant exotropia is most commonly affect ages between 30-60 years old; the prevalence of incotamitant exotropia is higher in males compared to female with ratio 2:1 to 4:1 [1].

The mechanism of ocular complications after paranasal and intranasal polyps' surgery, the most common causes due to extraocular muscle rupture and extraocular muscle paralysis, vascular disorders or extraocular muscle innervation, microvascular

infarction, chronic infection or inflammation, tumour mass compression. Complications such as enophthalmos, optic nerve atrophy, orbital cellulitis, orbital bleeding, orbital wall damage, proptosis, ptosis, strabismus [1], [5].

Incomitant exotropia is a form of strabismus which is outward deviation of the eyes with different angles of deviation in different motion field. The most common caused is due to paralysis or restriction. A subjective complaint of concomitant exotropia such as diplopia, the type of diplopia is binocular diplopia, which occurs when both eyes are open and feels better when one eye is closed. Based on its location in medial rectus atrophy, the type of diplopia is horizontal. The patient complains about the double vision that is worsening if they look far away and if they look the side to damaged muscle. When diplopia complains occur, the patient frequently closes their eyes spontaneously. Usually, patients will close the disturbance eyes. Changes in head position in patients with incomitant strabismus could reduce diplopia [3], [4].

In incomitant strabismus, due to medial rectus atrophy, there is a change of direction towards the vertical axis due to horizontal muscle disorders, which are called the anomalous head position or face turn. The examination of eyeballs position can be done by cover-uncover test, alternating cover test, prism alternating cover test (PACT), cornea light reflex test (Hirschberg test) and Krimsky test. In this case, we obtained on a cover-uncover examination and the alternating cover test but did not show shifting. In Hirschberg's examination found 45° exotropia, Krimsky > 95 Δ base in [3], [6].

Sensory status examination in strabismus patients to evaluate abnormalities of binocular vision. The most common sensory status examination that performed by ophthalmologists are worth a four-dot test (WFDT) and stereoscopic. The patient, in this case only sees 2 red dots in the WFDT exam which means there is suppression in the right eye [3].

The common binocular sensory examination is a stereoscopic examination. Stereoscopic is a technique for creating or enhancing an illusion in a depth image for binocular vision and could be evaluated by TNO test. In this test, red and green glasses are used to separate shadows in each. Patient in this case report found stereoscopic gross [3], [6].

In the last ten years, sinus surgery techniques that commonly used is Functional Endoscopic Sinus Surgery (FESS), especially for surgery for sinus obstruction. Although this procedure is stated to be relatively safe, FESS can cause tissue trauma such as orbital bleeding, optic nerve injury, nasolacrimal drainage system injury, extraocular muscle rupture. Besides that, extraocular muscle paralysis, vascularity

disorders or extraocular muscle innervation, microvascular infarction, chronic infection or inflammation, and tumour mass compression also can be caused the muscular injury. The supportive examination is the head MRI which was found atrophy in the right medial rectus muscle with a size of 2.2 mm, hypertrophy of the left and right inferior nasal concha, postoperative right lateral nasal cavity deformity, right maxillary sinusitis. This is suspected as a cause of ocular complications that happened due to vascular disorders and innervation as well as the process of chronic infection or inflammation of polyps [7].

There are so many of literature regarding exotropia management such as surgical and non-surgical, but according to Dutton's research the goal of muscle atrophy management that caused by chronic inflammation and tumour mass suppression is to overcome and reduce diplopia, restore binocular single vision and a small portion can handle cosmetics. Two-month evaluation of postoperative, the double vision was reduced, Hirschberg's examination found exotropia 30° and Krimsky 65 Δ base in.

In conclusion, incomitant exotropia is one of the reported ocular complications that can occur due to extraocular muscle atrophy which caused by vascular disorders or innervation of these muscles and can occur due to the process of chronic infection or inflammation of the surrounding tissue. The purpose/goal of surgery in such cases is to overcome and reduce the diplopia, and in small amounts can handle cosmetics.

Reference

1. Dutton J, Clarke MP, Strong NP, Tin W. Clinical Strabismus Management. 1999:319-320.
2. Eitzen JP, Elsas FJ. Strabismus following endoscopic intranasal sinus surgery. J Pediatric Ophthalmology Strabismus. 1991. 28:168. PMID : 1890576
3. American Academy of Ophthalmology Staff. Pediatric Ophthalmology and Strabismus. Basic and Clinical Science Course. Section 6. San Fransisco. 2015-2016; 87-98.
4. Eva Paul R, Whitcher, John P. Vaughan and Asbury's General Ophthalmology. 16th edition. 2004:230-248.
5. Al-Qurainy IA. Convergence Insufficiency and Failure of Accommodation Following Midfacial Trauma. BrJ Oral Maxillofac Surg. 1995. 33:71. [https://doi.org/10.1016/0266-4356\(95\)90203-1](https://doi.org/10.1016/0266-4356(95)90203-1)
6. Wright K. Pediatric Ophthalmology for Primary Care. American Academy of Pediatric 3rd edition. 2008:49-70.
7. Shin GS, Demer JL, Rosenbaum AL. High Resolution, Dynamic Magnetic Resonance Imaging in Complicated Strabismus. J Pediatric Ophthalmology Strabismus. 1996. 33:282.