

ID Design Press, Skopje, Republic of Macedonia  
Open Access Macedonian Journal of Medical Sciences. 2019 Jun 15; 7(11):1821-1824.  
<https://doi.org/10.3889/oamjms.2019.488>  
eISSN: 1857-9655  
**Case Report**



# Management of Systemic Steroid in HIV Patient with Toxoplasma Papillitis

AA Mas Putrawati Triningrat<sup>1\*</sup>, Ratna Sari Dewi<sup>1</sup>, Igam Juliari<sup>1</sup>, NK Niti Susila<sup>1</sup>, Ni Made Ayu Surasmiati<sup>1</sup>, I Ketut Agus Somia<sup>2</sup>

<sup>1</sup>Ophthalmology Department, Faculty of Medicine, Udayana University, Sanglah Hospital, Denpasar, Bali, Indonesia;  
<sup>2</sup>Internal Medicine Department, Faculty of Medicine, Udayana University, Sanglah Hospital, Denpasar, Bali, Indonesia

**Citation:** Triningrat AAMP, Dewi RS, Juliari I, Susila NKN, Surasmiati NMA, Somia IKA. Management of Systemic Steroid in HIV Patient with Toxoplasma Papillitis. Open Access Maced J Med Sci. 2019 Jun 15; 7(11):1821-1824.  
<https://doi.org/10.3889/oamjms.2019.488>

**Keywords:** Toxoplasma Papillitis; HIV; Steroid

**\*Correspondence:** AA Mas Putrawati Triningrat, Ophthalmology Department, Faculty of Medicine, Udayana University, Sanglah Hospital, Denpasar, Bali, Indonesia. E-mail: [agrasidi01@gmail.com](mailto:agrasidi01@gmail.com)

**Received:** 21-Apr-2019; **Revised:** 26-May-2019;  
**Accepted:** 27-May-2019; **Online first:** 14-June-2019

**Copyright:** © 2019 AA Mas Putrawati Triningrat, Ratna Sari Dewi, Igam Juliari, NK Niti Susila, Ni Made Ayu Surasmiati, I Ketut Agus Somia. This is an open-access article distributed under the terms of the Creative Commons Attribution-NonCommercial 4.0 International License (CC BY-NC 4.0)

**Funding:** This research did not receive any financial support

**Competing Interests:** The authors have declared that no competing interests exist

## Abstract

**BACKGROUND:** Toxoplasmosis is a zoonotic disease caused by *Toxoplasma gondii*. Ocular manifestations are seen in both congenital and acquired toxoplasmosis. These can include focal inflammation within or around the optic nerve head (papillitis). Purpose of this study is evaluating the efficacy of systemic steroid in HIV patient with toxoplasma papillitis.

**CASE PRESENTATION:** We present a case report of a male, 46 years old with a decrease of visual acuity on the right eye for three weeks before admission to the hospital. An ophthalmology examination showed visual acuity of the right eye 1/60, mild dilatation of the pupil and posterior synechiae, vitreous was hazy, and fundus examination showed optic nerve head not well demarcated and hyperaemic with the good retina and macula reflex. Laboratory examination showed reactive anti-Toxoplasma immunoglobulin G. Patient had been treated with antiretroviral and anti-Toxoplasma drugs, then he was given steroid 250 mg intravenously four times per day for three days and tapering off orally. Visual acuity on the right eye improve from 1/60 became 6/60 after use of steroid on the third day.

**DISCUSSION:** Steroid can improve visual acuity for toxoplasma papillitis in this patient. But the long term and close follow up in steroid therapy is needed.

## Introduction

Toxoplasmosis is a chronic disease caused by *Toxoplasma gondii* infection, which is an obligate intracellular parasite. The most common manifestation of Toxoplasma in HIV-infected patients is cerebral toxoplasma, whereas the most common extracerebral manifestations can be ocular and lungs diseases [1], [2], [3], [4], [5].

An ocular manifestation of toxoplasma can be in congenital or acquired. Some rare manifestations include papillitis, neuroretinitis, retrobulbar neuritis, central serous retinopathy, and scleritis. Toxoplasma papillitis mostly unilateral, and there is no predilection of gender. Clinical symptoms that appear in the form of blurry vision, red eyes, pain, and systemic symptoms such as fever and weakness [6], [7], [8],

[9], [10].

Administration of steroids in Toxoplasma papillitis expected to suppress inflammation and use with caution due to its immunosuppression effect. Although still controversial, the administration of steroids has significant benefits for the inflammatory process. Therapy with steroids is not required in ocular management of Toxoplasma, but steroids are used as adjunctive therapy in ocular toxoplasma [3], [9], [11], [12], [13], [14].

Management of Toxoplasma papillitis in HIV-infected patients is quite difficult, so it requires multidisciplinary to determine the type of therapy. The goal of this case report is to evaluate the efficacy of systemic steroid use for HIV-infected patients with Toxoplasma papillitis, so it would be better management for similar cases.

## Case Presentation

A 46-years old, bisexual, male patient came with initial presentation blurry vision on the right eye since a year ago and became worse since the last 3 weeks. It felt like a worse sensation when the eyes were moving — the history of red eyes since a year ago and recurrence. The symptoms had been treated by an ophthalmologist. The patient was diagnosed with HIV and toxoplasmosis since a year ago and undergoing treatment.

General assessment on the normal limit. Ophthalmology examination on the right eye was found visual acuity 1/60 and not improved with pinhole, palpebral was normal, hyperemic conjunctiva, mild dilatation, pupil posterior synechiae, vitreous opacities, *optic nerve head hyperemic and not well demarcated*.

The intraocular pressure was normal. The eye movement was good in all direction. There was a defect Confrontation visual field test.

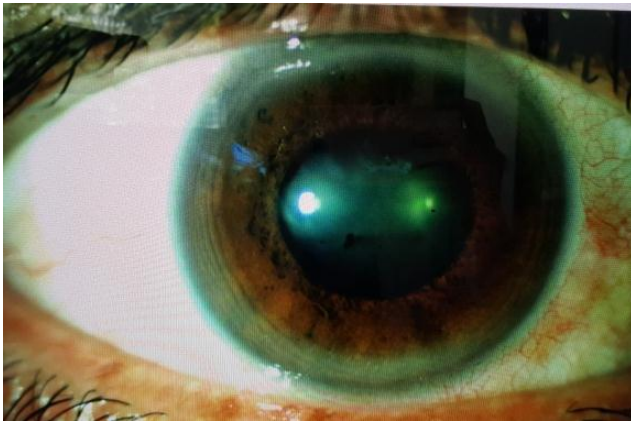


Figure 1: Anterior segment on the right eye

There was no a specific defect on the colour vision test and decreasing of contrast sensitivity (0.75). The Optical Coherence Tomography (OCT) examination showed inferior and temporal thickening, *cup-disc ratio 1.00* as result of *OCT Optic Nerve Head*.

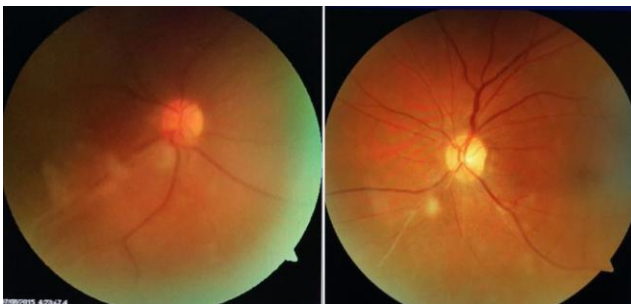

Figure 2: Fundus photography on the right eye (left) and left eye (right)

Laboratory tests showed an increase in erythrocyte sedimentation rate, decreased CD-4 levels to 201, reactive anti-toxoplasma immunoglobulin G with titers 58, reactive anti-rubella immunoglobulin G, reactive anti-HSV 1 and 2 immunoglobulin G.

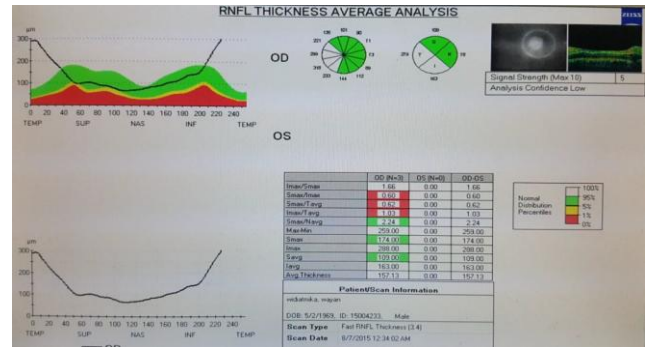


Figure 3: Optical Coherence Tomography (OCT) (RNFL) on the right eye

The patient was diagnosed with right eye Toxoplasma Papillitis and consulted to the neuro-ophthalmology and internal medicine for the plan to administer Optic Neuritis Treatment Trial (ONTT). The patient was diagnosed with stage IV HIV infection by internal medicine and given anti-toxoplasma treatment (cotrimoxazole and clindamycin), anti-retroviral and had been done the ONTT for three days by methylprednisolone 250 mg four times per day intravenously, mecobalamin 500 mg three times per day orally, and antacids three times per day orally.

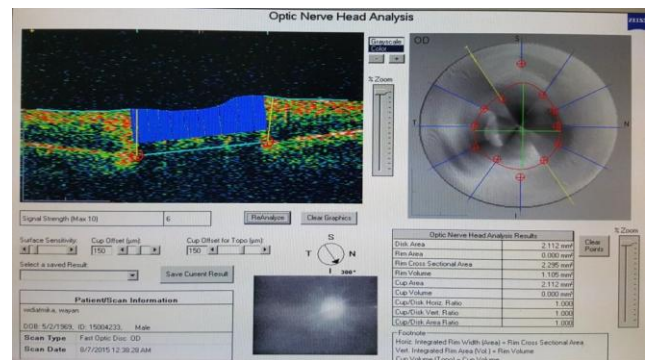


Figure 4: Optical Coherence Tomography (OCT) ONH on the right eye

Day fourth of treating with ONTT, the patient still complained of nausea and dizziness, but the vision was getting better. Visual acuity of right eye 6/60 pinhole NI, normal palpebra, normal conjunctiva, clear cornea, deep ocular anterior chamber, iris and pupil dilated, there are posterior synechiae, cloudy vitreous, fundus examination is obtained by optic nerve head indeterminate hyperemia boundary with the normal retina and positive macular reflex. Intraocular pressure was normal — eyeball movement in all directions. Confrontation test of the right eye is disturbed. The patient was diagnosed with toxoplasma

papillitis and stage IV HIV infection. Tapering off intravenous methylprednisolone have been done and then replaced with oral methylprednisolone 32 mg twice per day, mecobalamin 500 mg three times per day orally, and antacids three times per day orally, anti-toxoplasma (cotrimoxazole and clindamycin) and antiretrovirals continued. The patient was allowed to go home and suggested to control one week later, but patients do not come for treatment.

## Discussion

Toxoplasma papillitis is a rare manifestation of Toxoplasma, usually unilateral and does not have a predilection of gender. Clinical symptoms such as blurry vision, red eyes, pain, also causing systemic fever and general weakness [6], [10].

*Toxoplasma gondii* was first discovered in 1908 in the brains of South African rats and caused ocular disease for the first time in 1923. Transmission of *Toxoplasma gondii* by ingesting food containing oocysts, transplacental, through mucous membranes, after a blood transfusion or organ transplantation. Toxoplasma encephalitis is a manifestation of Toxoplasma in HIV-infected patients, but extracerebral manifestations can occur with or without encephalitis. The most common extracerebral manifestations can be ocular or pulmonary disease [3], [4], [9].

The transmission of *Toxoplasma gondii* by hematogenous and mostly affects the retinal vascular endothelial cells, so most of them manifest as retinitis with complaints of decreased visual acuity. Other manifestations can be vitreous and anterior uveitis. In severe vitreous can develop into epiretinal membrane and traction, headlight in the fog is found on fundus examination. Rare manifestations such as inflammation by Toxoplasma in the optic nerve head with hyperemia fundus images on the optic nerve head [3], [6], [9], [10].

The diagnosis of toxoplasma papillitis confirmed through fundal examination and supporting clinical features. If the clinical diagnosis cannot be confirmed through fundus examination, supporting examination such as increased detection of Toxoplasma gondii antibody titers in eye fluids or Toxoplasma gondii DNA and antibody tests in the blood [3], [6], [9], [10].

Management of Toxoplasma papillitis requires anti-parasitic combination such as pyrimethamine, sulfadiazine, clindamycin or azithromycin. These anti-parasitic therapies are effective for stopping the multiplication of parasites but cannot eliminate parasites from the human body. Administration of steroids in Toxoplasma papillitis should be adjunctive because it can suppress the immune response. A

case report stated, there are improvement visual acuity of ocular toxoplasma after prednisone 1 mg/kg. A study stated steroid administration begins within three days or a week after anti-toxoplasma therapy [6], [14], [15], [16], [17].

The use of steroids in good observation expected to suppress inflammation and reduce injury of ocular tissue, but the overall outcome is still uncertain. Steroids can cause side effects such as abdominal pain, bloating/flatulence, nausea, dizziness, joint pain, menstrual disorders, weight gain and increased appetite [18].

The visual acuity of patients after administration of steroid improved from 1/60 to 6/60, but patients complained of nausea and dizziness after administration of the steroid.

In conclusion, there have been reported cases of Toxoplasma papillitis in an HIV-infected patient who showed improvement in visual acuity after given systemic steroid therapy for three days. Further studies are needed to determine the efficacy and side effects of short-term systemic steroid use in HIV cases with Toxoplasma papillitis.

## Reference

1. Miro JM, Murray HW, Katlama C. Toxoplasmosis. In: Dolin R, ed. AIDS Therapy. 3rd ed. Philadelphia, PA: Churchill Livingstone, 2008:659-681
2. Jones JL, Kruszon-Moran D, Sanders-Lewis K, Wilson M. Toxoplasma Gondii Infection in the United States. Am J Trop Med Hyg. 2007; 77(3):405-410. <https://doi.org/10.4269/ajtmh.2007.77.405> PMID:17827351
3. Park YH, Nam HW. Clinical Feature and Treatment of Ocular Toxoplasmosis. Korean Journal of Parasitology. 2013; 51(4):393-399. <https://doi.org/10.3347/kjp.2013.51.4.393> PMID:24039281 PMID:PMC3770869
4. Jayawardene et al. Manifestation and Management of Ocular Toxoplasmosis. Indian Jr of Ophthalmol. 2008; 5(2):213-215 .
5. Luft BJ, Remington JS. Toxoplasmosis Encephalitis in AIDS. Clinical Infectious Disease. 1992; 15(2):211-222. <https://doi.org/10.1093/clinids/15.2.211> PMID:1520757
6. Alipanahi R, Sayyahmelli S. Acute Papillitis in Young Female with Toxoplasmosis. Middle East African Journal Ophthalmology. 2011; 18(3):249-251. <https://doi.org/10.4103/0974-9233.84060> PMID:21887084 PMID:PMC3162741
7. Ahmed Irma, Everett A, Chang E, Luckie A. Ophthalmic Manifestation of HIV. University of California, San Fransisco, 2006:859-873.
8. Gritz David. Toxoplasmosis. Am J Trop Med Hyg. 2014; 80(2):401-409.
9. Harvey Uy. Toxoplasma Papillitis and Neuroretinitis. Philippine Journal of Ophthalmology. 2008; 30(1):48-53.
10. Myers TD, Smith JR, Wertheim MS, et al. Use Of Corticosteroid Sparing Systemic Immunosuppression for Treatment of Corticosteroid dependant Optic Neuritis not Associated with Demyelinating Disease. Br J Ophthalmology. 2004; 17:3-8.
11. Gagliuso DJ, Teich SA, Friedman AH, Orellana J. Ocular Toxoplasmosis in AIDS Patients. Trans Am Ophthalmol Soc. 1990;

88:63-86.

12. Holland GN. Ocular Toxoplasmosis in The Immunocompromised Host. *Int Ophthalmol.* 1989; 13:399-402. <https://doi.org/10.1007/BF02306488>

13. American Academy of Ophthalmology Staff. Toxoplasma Retinochoroiditis. In: *Intraocular Inflammation and Uveitis. Basic and clinical course.* Section 9. San Fransisco:AAO, 2015-2016:308-309.

14. Jasper S, Satyanarayana S, et al. Corticosteroids for Ocular Toxoplasmosis. *National of Health Institute Public.* 2014; 4:2-16.

15. Gilbert RE, Harden M, Stanford MR. Antibiotics versus control fot Toxoplasma retinochoroiditis. *Cochrane Database of Systematic Reviews.* 2002; 1(10):218-226.

<https://doi.org/10.1002/14651858.CD002218>

16. Rush R, Sheth S. Fulminant toxoplasmic retino-choroiditis following intravitreal triamcinolone administration. *Indian journal of ophthalmology.* 2012; 60(2):141-143. <https://doi.org/10.4103/0301-4738.94059> PMID:22446913 PMCID:PMC3339077

17. Sabates R, Pruet RC, Brockhusrt RJ. Fulminant Ocular Toxoplasmosis. *American Journal of Ophthalmology.* 1981; 92(4):497-503. [https://doi.org/10.1016/0002-9394\(81\)90642-5](https://doi.org/10.1016/0002-9394(81)90642-5)

18. Aberdein J and Singer M. Clinical Review: A Systematic Review of Corticosteroid Use in Infections. *Critical Care.* 2005; 10:203-213. <https://doi.org/10.1186/cc3904> PMID:16356204 PMCID:PMC1550829