



Wglarz, P., Krejca, M., Trusz-Gluza, M., Bochenek, K., Konarska-Kuszevska, E., Szydo, K., ... Bajor, G. (2016). Neointima development in externally stented saphenous vein grafts. *Postępy w kardiologii interwencyjnej = Advances in interventional cardiology*, 12(4), 334-339. <https://doi.org/10.5114/aic.2016.63634>

Publisher's PDF, also known as Version of record

License (if available):
CC BY-NC-SA

Link to published version (if available):
[10.5114/aic.2016.63634](https://doi.org/10.5114/aic.2016.63634)

[Link to publication record in Explore Bristol Research](#)
PDF-document

This is the final published version of the article (version of record). It first appeared online via *Advances in Interventional Cardiology* at <http://doi.org/10.5114/aic.2016.63634> . Please refer to any applicable terms of use of the publisher.

University of Bristol - Explore Bristol Research

General rights

This document is made available in accordance with publisher policies. Please cite only the published version using the reference above. Full terms of use are available:
<http://www.bristol.ac.uk/pure/about/ebr-terms>

Neointima development in externally stented saphenous vein grafts

Przemysław Węglarz¹, Michał Krejca², Maria Trusz-Gluza², Krystyna Bochenek², Ewa Konarska-Kuszevska³, Krzysztof Szydło², Piotr Kuszevski¹, Christopher L. Jackson⁴, Gianni D. Angelini⁵, Grzegorz Bajor¹

¹Department of Human Anatomy, Silesian University of Medicine, Katowice, Poland

²Upper Silesian Cardiology Centre, Silesian University of Medicine, Katowice, Poland

³Freelance Cardiovascular Investigator, Katowice, Poland

⁴Freelance Cardiovascular Investigator, Yatton, United Kingdom

⁵Bristol Heart Institute, University of Bristol, Bristol, United Kingdom

Adv Interv Cardiol 2016; 12, 4 (46): 334–339

DOI: 10.5114/aic.2016.63634

Abstract

Introduction: The main limitation of coronary artery bypass grafting (CABG) is rapid neointimal hyperplasia leading to graft failure.

Aim: To assess plaque formation in saphenous vein grafts (SVG) covered by an external Dacron stent in comparison with the classical technique.

Material and methods: In the study group vein grafts covered by external stent mesh made of Dacron were implanted. An intravascular ultrasonography (IVUS) study was performed in 35 aorto-coronary SVG covered by an external Dacron stent and in 64 normal SVG during the first year after CABG. In each SVG 25 mm of good quality IVUS image, volumes of lumen, plaque (neointima), outer border of the vein graft (external SVG) and adventitia were calculated in three time periods: 0–130 days, 130–260 days and 260–390 days.

Results: Between the first and second time period, lumen volume (mm³) was reduced from 10.33 ±4.4, to 6.80 ±2.23 in the second period and 5.69 ±1.26 in the third one. This effect was much less marked in normal grafts. The corresponding lumen volume (mm³) was: 10.90 ±3.9, 9.15 ±2.94 and 8.92 ±2.93 in consecutive time periods. Plaque volume (mm³) did not change in control grafts during the course of the study, but it increased very significantly in stented grafts from 0.86 ±1.24 in the first period to 2.70 ±1.58 in the second and 3.29 ±2.66 in the third one.

Conclusions: The experimental technique of implanting SVG covered with an external elastic Dacron stent seems to be inferior to traditional ones. This is probably due to the more complicated process of vein implantation and higher micro-injury occurrence during the surgery.

Key words: coronary artery bypass grafting, intravascular ultrasonography, neointima.

Introduction

The crucial limitation of coronary artery bypass grafting (CABG), when the saphenous vein is used as a conduit, is poor long-term vein graft patency [1]. Five-year failure rates are 30–50% and have remained unchanged despite rapid development of pharmacological treatments and technologies. This has a significant effect on patient health and an important influence on the cost of treatment also. The main reason for vein graft occlusion, especially in the mid-term, is neointimal

hyperplasia (NIH) [2]. Various treatments have been investigated with a view to reducing NIH [3–5]. One such method is the use of synthetic external supports for vein grafts [6].

Several studies suggest that the application of an external stent around the grafted vein delays neointima formation and increases patency [7]. We therefore assessed the effect on saphenous vein graft patency of an external, fine network stent made of Torlen/Dacron fibres [8].

Corresponding author:

Przemysław Węglarz MD, PhD, Department of Human Anatomy, Silesian University of Medicine, 18 Medyków St, 40-762 Katowice, Poland, phone: +48 600 467 332, fax: +48 32 252 64 87, e-mail: pwęglarz@gmail.com

Received: 18.09.2015, **accepted:** 30.03.2016.

Material and methods

Patients

The study was approved by the local Ethical Committee of the Silesian University in Katowice (approval number: L.dz.NN-013-267/01). All patients provided informed consent. A total of 105 (40 in the study group and 65 in the control group) patients with stable angina were enrolled in this study. The decision whether to proceed with patient enrolment was made by the heart team (cardiologist and cardiac surgeon). Twenty-four patients refused to participate in follow-up examinations after CABG (4 from the study group, 20 from the control group) with 4 (1 from the study group, 3 from the control group) excluded because they moved away from the area. In 5 patients in the study group and 5 in the control group, intravascular ultrasonography (IVUS) was not performed because of severe graft stenosis. Thirteen patients (8 from the study group and 5 from the control group) were not included in these analyses because of time limitations. Therefore this study and analysis includes 32 patients enrolled in the control group and 22 patients in the study group.

The study inclusion criteria were: men and women, age 40–65 years, with multi-vessel coronary disease, critical stenosis in the right coronary artery (RCA), stable angina, systolic blood pressure (BP) below 160 mm Hg, blood glucose below 7.8 mmol/l. The exclusion criteria were: lack of written consent, inability to perform full arterial revascularisation, varicose veins, saphenous vein of poor quality, unstable angina, low ejection fraction (left ventricular ejection fraction (LV EF) < 30%), concomitant

valve disease, critical stenosis of the carotid arteries, Leriche syndrome, and any other condition which limited life expectancy to less than 2 years.

The primary aim of the study was to use IVUS to determine the usefulness of this modified cardio-surgery technique in clinical practice.

The secondary endpoints were the occurrence of major adverse cardiac events (MACE) or major adverse cardiac and cerebrovascular events (MACCE), and the requirement for repeat revascularisation procedures. Secondary endpoints were assessed in the first year after operation and in long-term follow-up, between 7 and 14 years after CABG.

We compared coronary and IVUS procedures in three time periods: the first was 0 to 130 days after grafting, the second was 130 to 260 days after grafting, and the third was 260 to 390 days after grafting. Patient details are given in Table I.

External Dacron stent construction

In collaboration with Tricomed S.A., Lodz, Poland, a 4 mm diameter mesh made out of polyester fibre (Torlen/Dacron) was constructed (Figure 1). This stent consists of empty rhomboidal spaces created by single interlacing of Torlen threads and provides external support to the native vein. This extravascular stent is very resistant to bending and has an ability to change its diameter depending on forces acting along its long axis.

The CABG procedure was performed with general anaesthesia, with medial sternotomy access, extracorporeal circulation and moderate hypothermia (32°C). All

Table I. Baseline characteristics of patients included in the study

Parameter	Study group (n = 40)	Control group (n = 65)	P-value
Age [years]	55.4 ±10.16	54.72 ±8.84	0.41
Ejection fraction (%)	54.64 ±6.21	54.23 ±6.2	0.72
History of MI prior to CABG	14 (35%)	22 (34%)	0.42
History of PCI prior to CABG	5 (12.5%)	11 (16.9%)	0.37
Hypertension	26 (65%)	41 (63%)	0.77
Hypercholesterolaemia	32 (80%)	49 (75.4%)	0.52
Total cholesterol [mg/dl]	209 ±38.3	207 ±46.62	0.47
LDL cholesterol [mg/dl]	130 ±40.22	127 ±76.36	0.46
HDL cholesterol [mg/dl]	43 ±8.08	44 ±11.62	0.43
Triglyceride [mg/dl]	155 ±78.04	145 ±72.58	0.16
Creatinine [mg/dl]	1.03 ±0.13	0.97 ±0.15	0.39
Current smoker	12 (30%)	19 (29.3%)	0.41
History of smoking	17 (42.5%)	26 (40%)	0.43
Non-smoker	11 (27.5%)	20 (30.7%)	0.42

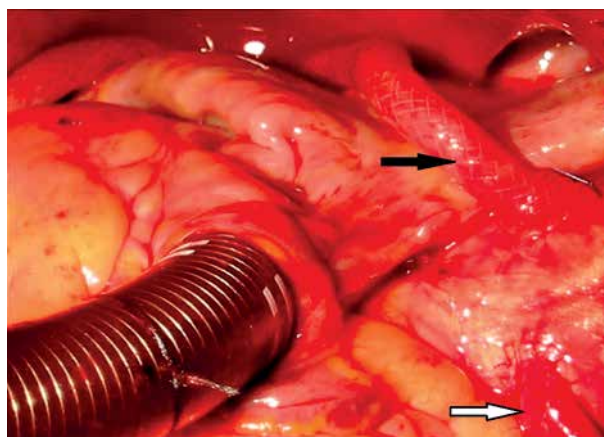



Figure 1. Stent *ex-vivo* and stented graft *in-vivo* (black arrow), regular graft (white arrow)

patients received left internal mammary artery grafts implanted into the left anterior descending artery and saphenous vein grafts to other coronary vessels. In the study group a 15 cm segment of vein graft was fed inside the Dacron stent and fused to it with tissue glue (Tissucol). The proximal and distal parts of the graft were not covered by the stent.

Coronary angiography and intravascular ultrasonography

Coronary angiography was performed after access via the femoral artery. All patients underwent angiography of the native coronary vessels and then selective angiography of the venous bypass grafts. The IVUS examinations were performed using the Volcano system, with standard 20 MHz ultrasonographic probes moved by a pull-

back device at a speed of 1 mm/s. The examination was preceded by the direct application to the grafted vein of 5000 IU of heparin and 0.2 mg of nitroglycerine. Analysis was carried out using QCU-CMS IVUS analytical software, version 4.14. A 25 mm section was analysed. The analysed data consisted of 250 single ultrasonographic images created during the examination (10 images per millimetre). Mean volumetric parameters were calculated for a 1 mm length of saphenous vein grafts (SVG).

The selection of the venous bypass graft section was made on the basis of the quality of the image, including the area of the bypass graft with the most advanced neointima formation. Sections adjacent to the proximal and distal part of the bypass graft were excluded from the analysis.

Analysis of IVUS records gave the following data: lumen volume, external elastic membrane (EEM) volume and volume of the outer border of the vein graft (external SVG). Adventitia volume was calculated as the difference between the volume of the outer border of the SVG and the EEM volume. The external elastic membrane in arterial vessels is measured as the external border of a hypoechoic zone which represents the media [9, 10]. In arteries this zone is usually easily visible. In contrast, saphenous vein grafts are much more difficult to assess. Remodelling processes, proliferation, migration of myofibroblasts and production of external extracellular substances involve the whole diameter of the bypass. Adventitia and media invasion by adipose tissue can make the EEM membrane difficult to see even under the microscope [11].

All images with an unequivocally visible echo-negative border were assumed to represent the media (Figure 2).

Data acquisition and analysis

Coronary angiographic and IVUS procedures were performed in the control group between 4 and 506 days after CABG, and in the study group between 6 and 523 days. Some patients (19 vein grafts in the control group

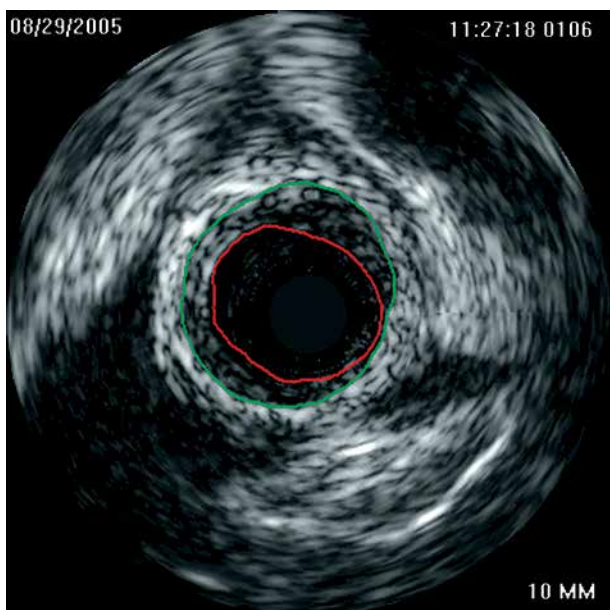


Figure 2. Delineation of the neointima (red line) and the external elastic membrane (green line) in a saphenous vein bypass graft ultrasonogram

and 13 vein grafts with external stents) had a second IVUS procedure. A total of 64 IVUS examinations in unstented vein bypass grafts, and 35 IVUS examinations in vein grafts with the external Dacron stent, were analysed in the three time periods.

Statistical analysis

Results are expressed as mean \pm standard deviation. Comparisons between groups were made using Student's unpaired two-tailed *t*-test, having checked for equivalence of variance by means of an *F* test. Differences with $p < 0.05$ were considered to be statistically significant.

Results

Patient details are given in Table I. Comparisons between patients in the two groups were made using non-parametric methods, and no statistically significant differences were found.

Table II shows data concerning the number of occluded vein grafts in each group. In analysis of selected risk factors for SVG occlusion in the control and study group, smoking was determined as a significant risk factor for saphenous vein graft occlusion.

During the first year of follow-up, no deaths, myocardial infarctions, MACE or MACCE were observed. The average hospitalization time was 7 ± 4 days in the study group and 6.4 ± 1.3 days in the control group. Because of post-operative wound infection and sternum restabilization, 1 patient from the study group left hospital after 29 days of hospitalization. One patient from the control group suffered an acute coronary event 20 days after CABG, requiring urgent percutaneous coronary intervention (PCI). In 9 others (5 from the study group, 4 from the control group) significant stenosis or SVG occlusion was noted.

Table II. Angiography characteristics of saphenous vein grafts

Vein grafts (analysed by angiography)	Control group	Study group
Number of saphenous vein grafts performed/patent (% of patent grafts):	105/95 (90.5)	47/37 (78.7)
0 to 130 days	36/34 (94.4)	26/21 (80.8)
130 to 260 days	34/29 (85.3)	11/8 (72.7)
260 to 390 days	35/32 (91.4)	10/8 (80.0)

As summarised in Table III, there were no significant differences between control and stented saphenous vein grafts in terms of the analysed parameters at the time of the first IVUS examination, 0–130 days after graft emplacement. There was a gradual and significant reduction in lumen volume in unstented grafts over the course of the study, but this effect was much more marked in grafts covered with the external stent. The control lumen volume was reduced by 18.2%, but in stented grafts it fell by 44.9% ($p < 0.05$).

Neointima (plaque) volume did not change in control grafts during the course of the study, but it increased very significantly in stented grafts. By the end of the study, neointima volumes in stented grafts were increased 3.8-fold ($p < 0.05$) (Figure 3).

There was no significant change in adventitia volume in the control group between the first and second time periods; in contrast, in the study group there was a significant reduction in adventitia volume during the same interval. Similarly, a significant reduction in adventitial volume was observed in the external stent group.

Table III. Summary of IVUS analysis

Time interval	Compartment volume	Control (mean \pm SD)	External stent (mean \pm SD)
0 to 130 days	Lumen [mm ³]	10.90 \pm 3.9	10.33 \pm 4.4
	Plaque [mm ³]	1.59 \pm 2.21	0.86 \pm 1.24
	Adventitia [mm ³]	8.61 \pm 2.26	7.98 \pm 1.89
	SVG vessel [mm ³]	21.1 \pm 5.04	19.23 \pm 5.49
130 to 260 days	Lumen [mm ³]	9.15 \pm 2.94	6.80 \pm 2.23*
	Plaque [mm ³]	1.02 \pm 2.10	2.70 \pm 1.58*
	Adventitia [mm ³]	10.36 \pm 3.62	5.50 \pm 2.02*
	SVG vessel [mm ³]	20.54 \pm 6.16	15.13 \pm 4.14*
260 to 390 days	Lumen [mm ³]	8.92 \pm 2.93	5.69 \pm 1.26*
	Plaque [mm ³]	1.36 \pm 1.73	3.29 \pm 2.66*
	Adventitia [mm ³]	9.47 \pm 2.67	6.46 \pm 2.55*
	SVG vessel [mm ³]	19.74 \pm 5.10	15.44 \pm 4.85*

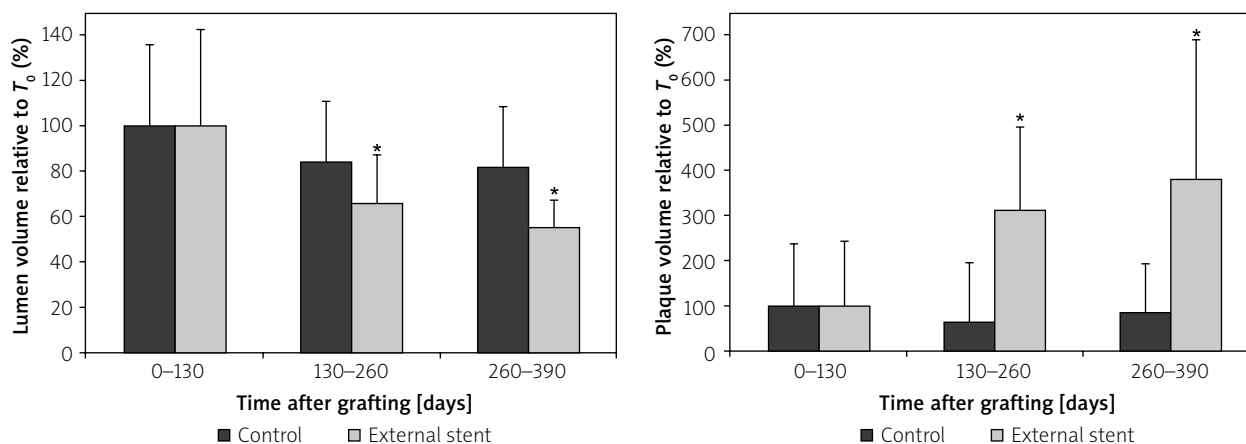


Figure 3. Lumen volume and neointima (plaque) volume as determined by IVUS in control and stented saphenous vein grafts. Values are normalised to the measurement at the earliest time point. Bars show mean values with associated standard deviations; dark bars are control grafts, light bars are externally stented grafts (* $p < 0.05$)

Discussion

Despite the limitations of CABG, as well as the continued development of interventional cardiological methods, this technique has a continuing role in the treatment of left main and multi-vessel coronary artery disease. Rapid neointimal hyperplasia, leading to graft failure, is one of the main causes of CABG failure. Potential solutions have been investigated using both pharmacological and interventional approaches [3, 4]. In 1978 the beneficial effect of an external polyester stent was described by Karayanacos *et al.* [12]. This effect is explained by three main theories: positive effects on haemodynamics [13], increased adventitial angiogenesis with the promotion of vasa vasorum around the vein graft [14, 15], and accumulation of immune and inflammatory cells within the mesh [7].

However, the clinical benefit of this technique is not known. In this study we used IVUS for precise evaluation of vein graft responses to external stenting. The IVUS is a powerful tool for investigating native and grafted vessels, allowing measurement of such parameters as lumen area, wall thickness, plaque area and so on [16]. It enables a very precise longitudinal analysis of plaque development and the adaptive mechanisms taking place in the vessel [16–19], and indeed IVUS examinations of bypass grafts show a strong correlation with histological measurements [20].

Grafts implanted in the control group showed a gradual loss of lumen over time, but neointima volume did not change significantly during the same period. This suggests that neointimal thickening is unlikely to be the causative factor for loss of lumen.

The potentially favourable reduction in adventitia volume in the stented group is completely counteracted by a very intense process of neointima formation. Consequently there was a marked reduction in lumen volume in stented vessels, possibly leading to occlusion in some of them.

Similar results to the present material were reported by Violaris *et al.* in 1993. That paper showed that a possible positive effect on the external tunica was completely compensated by very significant development of neointima in stented bypasses [21].

The reduction in adventitia volume is difficult to explain. One possible factor is the accumulation of inflammatory cells in the space between the external stent and the vascular wall [7, 22]. These cells produce a number of factors which are specific chemoattractants for adventitial fibroblasts, which could lead to migration of cells from the adventitia of the venous bypass towards the external stent.

At the same time, matrix production by adventitial fibroblasts could occur within the space between the stent and the wall. Taking into account this mechanism, which is responsible for the reduction in adventitial volume, one cannot exclude a negative effect on the stented bypass that could lead to a significant decrease in the luminal volume of the transplanted vein.

In stented bypasses the total volume of the venous bypass wall did not change significantly between time intervals I and II. It should be emphasized that during this period the stented vessel undergoes reconstruction: there is a reduction in the total volume of the vein, a statistically significant increase in neointima volume, and compensating for this a decrease in adventitial volume.

Histological examinations suggest that different segments of venous bypasses react in specific ways, related to the varying local haemodynamic conditions and the morphology of the vein [23, 24]. The development of neointima at the site of anastomosis seems to be connected with vessel narrowing and turbulent blood flow [25, 26], whereas in the middle segment the condition of the vein, previously occurring disorders and surgical technique are more important [27]. In this context it is important to note that the preparation of the vein for grafting, and in particular the process of putting the ex-

ternal Dacron stent over the graft, may have caused extra damage leading to an exaggerated response.

This study has several limitations which could potentially influence the results. There was a relatively small number of enrolled patients; vein grafts were analysed over a range of different time periods; and the IVUS analysis was limited to only 25 mm of vein graft. Furthermore, the proximal and distal parts of the graft were not covered by the stent, so we cannot predict the influence of the stent on distal and proximal anastomoses.

Conclusions

In this study we observed a significant process of neointima formation over time in stented saphenous vein grafts. This technique should not be translated into routine clinical practice at this time.

Conflict of interest

The authors declare no conflict of interest.

References

- Motwani JG, Topol EJ. Aortocoronary saphenous vein graft disease: pathogenesis, predisposition, and prevention. *Circulation* 1998; 97: 916-31.
- Davies MG, Hagen PO. Pathophysiology of vein graft failure: a review. *Eur J Vasc Endovasc Surg* 1995; 9: 7-18.
- Yamanouchi D, Banno H, Nakayama M, et al. Hydrophilic statin suppresses vein graft intimal hyperplasia via endothelial cell-tropic Rho-kinase inhibition. *J Vasc Surg* 2005; 42: 757-64.
- Trerotola SO, Carmody TJ, Timmerman RD, et al. Brachytherapy for the prevention of stenosis in a canine hemodialysis graft model: preliminary observation. *Radiology* 1999; 212: 748-54.
- Mann MJ, Whittemore AS, Donaldson MC, et al. Ex-vivo gene therapy of human vascular bypass grafts with E2F decoy: the PREVENT single-centre, randomised, controlled trial. *Lancet* 1999; 354: 1493-8.
- Parsonnet VAA, Lari AA, Shah N, et al. New stent for support of veins in arterial grafts. *Arch Surg* 1963; 87: 696-702.
- Mehta D, George SJ, Jeremy JY, et al. External stenting reduces long-term medial and neointimal thickening and platelet derived growth factor expression in a pig model of arteriovenous bypass grafting. *Nat Med* 1998; 4: 235-9.
- Krejca M, Skarysz J, Szmagała P, et al. A new outside stent: does it prevent vein graft intimal proliferation? *Eur J Cardiothorac Surg* 2002; 22: 898-903.
- Gussenhoven EJ, Essed CE, Lancée CT, et al. Arterial wall characteristics determined by intravascular ultrasound imaging: an in vitro study. *J Am Coll Cardiol* 1989; 14: 947-52.
- Nishimura RA, Edwards WD, Warnes CA, et al. Intravascular ultrasound imaging: in vitro validation and pathologic correlation. *J Am Coll Cardiol* 1990; 16: 145-54.
- Spray TL, Roberts WC. Changes in saphenous veins used as aortocoronary bypass grafts. *Am Heart J* 1977; 94: 500-16.
- Karayannacos PE, Hostetler JR, Bond MG, et al. Late failure in vein grafts: mediating factors in subendothelial fibromuscular hyperplasia. *Ann Surg* 1978; 187: 83-8.
- Dobrin PB, Littoy FN, Endean ED. Mechanical factors predisposing to intimal hyperplasia and medial thickening in autogenous vein grafts. *Surgery* 1989; 105: 393-400.
- Vijayan V, Shukla N, Johnson JL, et al. Long-term reduction of medial and intimal thickening in porcine saphenous vein grafts with a polyglactin biodegradable external sheath. *J Vasc Surg* 2004; 40: 1011-9.
- Angelini GD, Lloyd C, Bush R, et al. An external, oversized, porous polyester stent reduces vein graft neointima formation, cholesterol concentration, and vascular cell adhesion molecule 1 expression in cholesterol-fed pigs. *J Thorac Cardiovasc Surg* 2002; 124: 950-6.
- Nissen SE, Yock P. Intravascular ultrasound: novel pathophysiological insights and current clinical applications. *Circulation* 2001; 103: 604-16.
- Nase-Hueppmeier S, Uebis R, Doerr R, Hanrath P. Intravascular ultrasound to assess aortocoronary venous bypass grafts in vivo. *Am J Cardiol* 1992; 70: 455-8.
- Hozumi T, Yoshikawa J, Yoshida K, et al. Use of intravascular ultrasound for in vivo assessment of changes in intimal thickness of angiographically normal saphenous vein grafts one year after aortocoronary bypass surgery. *Heart* 1996; 76: 317-20.
- Higuchi Y, Hirayama A, Shimizu M, et al. Postoperative changes in angiographically normal saphenous vein coronary bypass grafts using intravascular ultrasound. *Heart Vessels* 2002; 17: 57-60.
- Willard JE, Netto D, Demian SE, et al. Intravascular ultrasound imaging of saphenous vein grafts in vitro: comparison with histologic and quantitative angiographic findings. *J Am Coll Cardiol* 1992; 19: 759-64.
- Violaris AG, Newby AC, Angelini GD. Effect of external stenting on wall thickening in arteriovenous bypass grafts. *Ann Thorac Surg* 1993; 55: 667-71.
- George SJ, Izzat MB, Gadsdon P. Macro-porosity is necessary for the reduction of neointimal and medial thickening by external stenting of porcine saphenous vein bypass grafts. *Atherosclerosis* 2001; 155: 329-36.
- Mills JL, Fujitani RM, Taylor SM. The characteristics and anatomic distribution of lesions that cause reversed vein graft failure: a five-year prospective study. *J Vasc Surg* 1993; 17: 195-204.
- Bassiouny HS, White S, Glagov S, et al. Anastomotic intimal hyperplasia: mechanical injury or flow induced. *J Vasc Surg* 1992; 15: 708-16.
- Sottiurai VS. Biogenesis and etiology of distal anastomotic intimal hyperplasia. *Int Angiol* 1990; 9: 59-69.
- How TV, Rowe CS, Gilling-Smith GL, Harris PL. Interposition vein cuff anastomosis alters wall shear stress distribution in the recipient artery. *J Vasc Surg* 2000; 31: 1008-17.
- Varty K, Allen KE, Bell PR, London NJ. Infringuinal vein graft stenosis. *Br J Surg* 1993; 80: 825-33.