

## Case Report

# Individualizing Unidentified Skeletal Remains: A Differential Diagnosis Combining Pathological Changes and Biomolecular Testing

**Amy Z. Mundorff**<sup>1</sup>

**Sarah Kiley**<sup>2</sup>

**Krista E. Latham**<sup>3</sup>

**Wolfgang Haak**<sup>4</sup>

**Thomas Gilson**<sup>5</sup>

**Abstract:** Collaborative work among anthropologists, pathologists, and biomolecular analysts can maximize information included in a biological profile of skeletal remains. This case study demonstrates the benefits of a multidisciplinary approach to help diagnose disease processes from skeletal remains. In this case, skeletal pathologies on unidentified human remains appeared to be a result of both ankylosing spondylitis and spinal tuberculosis. This tentative diagnosis provided a starting point for biomolecular testing to help confirm these putative findings. The extraction of *Mycobacterium tuberculosis* DNA from bone samples indicated the disease's presence in this skeleton. Molecular screening for HLA-B27 to assess ankylosing spondylitis (AS) was, however, inconclusive. This case study demonstrates how macroscopic and biomolecular analyses can be useful in assisting in the identification of disease processes of an unknown individual in a forensic context.

<sup>1</sup> Department of Anthropology, University of Tennessee, Knoxville, TN

<sup>2</sup> Department of Anthropology, University of Florida, Gainesville, FL

<sup>3</sup> Departments of Biology and Anthropology, University of Indianapolis, Indianapolis, IN

<sup>4</sup> School of Earth & Environmental Sciences, Environment Institute, The University of Adelaide, Adelaide, South Australia, Australia

<sup>5</sup> Cuyahoga County Medical Examiner, Cleveland, OH

---

Received February 25, 2013; accepted June 12, 2013

## Case Report

In 1997, utility workers in a remote area on Staten Island, New York, found a nearly complete skeleton. The remains were partially contained within a plastic trash bag and obscured by a hot water heater. In 2002, the still unidentified skeleton was re-analyzed by anthropologists at the Office of Chief Medical Examiner, New York City.

The recovered remains were those of a single individual, fully clothed, with small amounts of mummified soft tissue adherent to a few bones. The cranium, cervical vertebra 6 (C6), and several hand bones were not recovered. Dermestid detritus and pupa casings were present around the skeleton. Several bones were sun bleached where portions of clothing had been displaced. Extensive vine and root damage to the clothing and to a few bones was noted. Based on these observations, the estimation of time since death was minimally one year, but likely longer [1, 2].

A biological profile was developed using traditional physical anthropological techniques. The profile suggested a male, over the age of 45 years at the time of death, with an estimated stature of 163.5cm $\pm$  2.99 cm (5'3"-5'5") [3]. However, this individual likely appeared much shorter in life because of a dorsal kyphosis of the thoracic spine. Without a skull, ancestry could not accurately be assessed. There was no evidence of perimortem trauma indicating cause of death, however, the circumstances of recovery led to the designation of homicide for the manner of death.

### *Antemortem Pathologies*

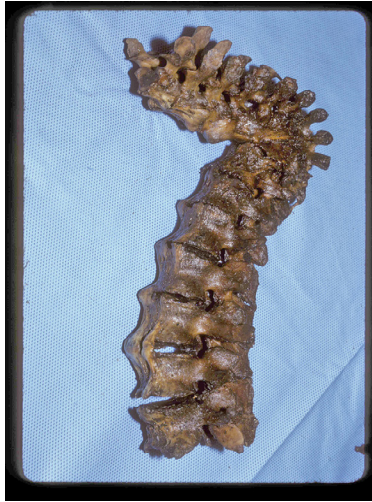The skeleton displays several, potentially overlapping, antemortem pathological conditions. Cervical vertebrae 3 (C3), 4 (C4), 5 (C5), and 7 (C7) have small and unfused syndesmophytic growths (vertical bony growths) on the anterior vertebral bodies, though the intervertebral space is maintained. Cervical vertebra 6 (C6) is missing postmortem; however, the anterior inferior margin of C5's vertebral body and the anterior superior margin of C7's vertebral body have similar thin, bony growths suggesting their presence on C6 as well.

Complete fusion of thoracic vertebrae 3 (T3) through 10 (T10) is the most prominent spinal feature, leaving little remaining intervertebral space (Figure 1). What remains of the intervertebral disc is compacted and calcified. Several of these thoracic vertebrae collapsed completely and fused further on the

anterior aspect, creating an approximately 90-degree anterior bend (kyphosis). This kyphosis would have made it impossible for this individual to walk fully upright. On the posterior aspect of the thoracic vertebrae, the interspinous and supraspinous ligaments are calcified, fusing multiple spinous processes along the median plane. On the anterior-lateral surfaces, the thoracic vertebral bodies display dense syndesmophytes, making the vertebrae difficult to differentiate because of the “bamboo-like” appearance. Several ribs show reactive activity, specifically, the visceral surface of ribs 5 through 7, right ribs 8 through 10, and the 12<sup>th</sup> left rib. Also, in the thoracic region, several right and left ribs are fused at the costovertebral joints. Interestingly, instead of being angled, the ribs are straight, an appearance more similar to the ribs of a quadruped (Figure 2). Changes in the rib’s morphology may be due, in part, to the bony changes in the vertebrae of the spine and the calcifications in the spine’s ligaments. The torso’s static anterior bend may also contribute to the rib’s deformities by causing internal organs to exert pressure on the visceral surface of the rib’s anterior aspect. This continuous pressure may cause the anterior aspect of the ribs to push out, thus straightening the normal rib angle.

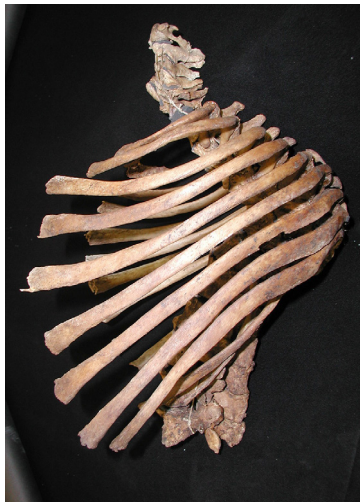The lumbar vertebrae 2 (L2) through 4 (L4) are fused by vertical enthesophytes. Enthesophytes are abnormal bony projections, calcification, and ossification commonly found at ligaments, tendons, and cartilage attachment sites. On L2 through L4, enthesophytes are located at the insertion of the anterior longitudinal spinal ligament on the anterior surface of the vertebral bodies. These vertebrae are also connected by syndesmophytes bridging adjacent vertebral bodies (Figure 3). The left aspect of L2 and L3 are fused at the diarthrodial joints (vertebral facets) on the superior and inferior zygapophyses.

The sacroiliac joint is bilaterally and symmetrically fused. Large enthesophytic activity particularly at the left anterior inferior iliac spine is present (Figure 4). There is moderate new bone formation in the right acetabulum. Entheses on the femora, patellae, scapulae, clavicularae, tibiae, fibulae, and os coxae have calcified, producing enthesophytes. The thyroid, xiphoid, and coccyx exhibit calcified cartilage. There is also extensive calcified cartilage at the sternal end of both first ribs. Arthritic lipping is present on the clavicles, vertebrae, ulnae, femora, and both scapulae. There is lytic activity and some new bone formation on the medial clavicles and corresponding manubrium. A few ribs have small osteophytic growths on the sternal ends.



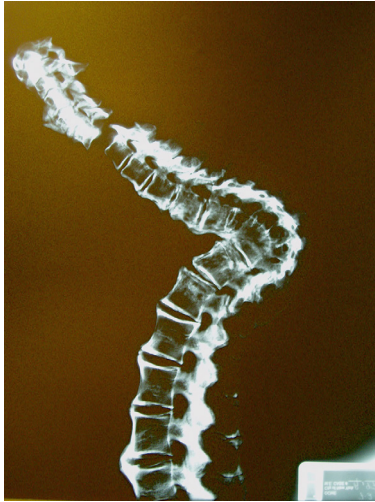
*Figure 1*

*Lateral view of spinal column illustrating fusion of vertebrae and kyphosis.*



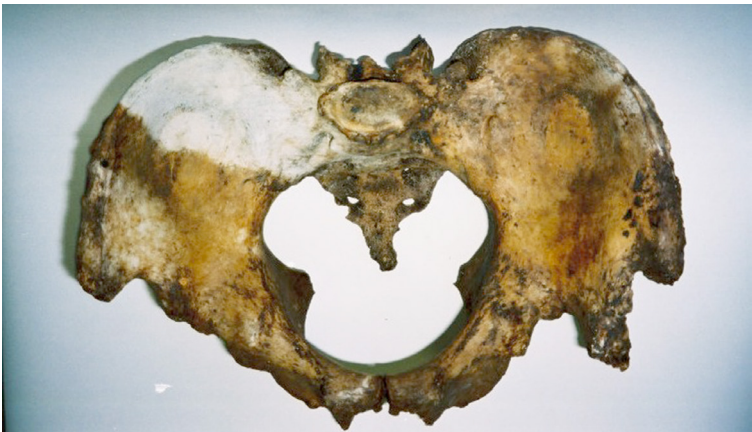*Figure 2*

*Lateral view of thoracic region illustrating straight, as opposed to curved, ribs.*



*Figure 3*

*Lateral radiograph of spinal column illustrating syndesmophytes bridging adjacent vertebral bodies.*



*Figure 4*

*Superior view of bilaterally fused os coxae also illustrating large enthesophytic activity at the left anterior inferior iliac spine.*

### *Molecular Testing*

To supplement the findings from the morphological examination, genetic analyses were conducted to screen for the presence of *M. tuberculosis* (TB) and the HLA-B\*27 allele. Bioarcheological studies have shown that *M. tuberculosis* DNA can be detected in skeletal remains long after an individual's death [4–6]. It is therefore reasonable to assume that the bacteria can be detected in more recent remains, such as those that are forensically significant. Genetic testing for HLA-B\*27 was conducted because of the strong association of this allele and ankylosing spondylitis, reported at 80 to 95% [7] and 90 to 95% [8]. Bioarchaeological studies have also shown that HLA-B27 can be detected in skeletal remains to confirm the morphological characteristics associated with AS long after an individual's death [9–10]. However, because AS can occur when the allele is not present, its absence does not eliminate the possibility that this individual suffered from this disease. The HLA-B\*27 test is not as “sensitive” as the test for the presence of TB DNA.

### **Discussion**

Based on the collective skeletal characteristics described above and a review of the literature on joint disease and spinal manifestations, three potential disorders are considered for the differential diagnosis. First, skeletal characteristics of ankylosing spondylitis (AS) and diffuse idiopathic skeletal hyperostosis (DISH) are compared to the skeleton's pathological manifestations. Second, characteristics of spinal tuberculosis, also known as Pott's disease, are considered (Table 1).

Disease	Ankylosing Spondylitis (AS)	Diffuse Idiopathic Skeletal Hyperostosis (DISH)	Pott's Disease <i>Mycobacterium tuberculosis</i>
<b>Population</b>	2–3.1 <i>males</i> to females 80%–90% carrying the antigen HLA-B27	2/3 affected are <i>male</i>  More common in European and Native American populations, rarely in Japanese or African populations  Associated with obesity and adult onset diabetes	NA
<b>Typical Onset</b>	~15–35 years	~50+ years	NA
<b>Hallmarks</b>	<i>Bilateral fusion of the sacroiliac joint</i>  <i>Calcification of anterolateral spinal ligaments with raised disc edges “bamboo-like” appearance</i>  <i>Loss of intervertebral space, may lead to kyphosis</i>  <i>Process begins in the lumbar region with progressive involvement up the spine</i>	Sacroiliac joint not significantly involved <sup>2</sup>  Calcification of anterolateral spinal ligament confined to the right side of the vertebral bodies  <i>Intervertebral space maintained</i>  Involves fewer vertebrae than AS  Process begins in the mid-thoracic region	<i>Collapse of thoracic spine into angular kyphosis</i>  <i>Anterior portion of vertebral bodies most significantly involved</i>  <i>Typically the upper lumbar and lower thoracic involved</i>  Often involves between 1–4 vertebrae, infrequently more than 4  Absence of new bone formation
<b>Axial Involvement</b>	<i>Fusion of the inter- and supra-spinous ligament and the anterior longitudinal ligament</i>  <i>Syndesmophytes symmetrical and vertically oriented on anterior vertebrae (appear thinner than DISH)</i>  Squaring of vertebral bodies in later stages <sup>1</sup>  <i>Apophyseal joint involvement, costovertebral fusion</i>  <i>Calcification of the annulus fibrosus of intervertebral discs</i>	Fusion of the anterior longitudinal ligament limited to the right side  <i>Significant enthesophytic growth</i>  <i>Intervertebral space maintained, with no vertebral end plate involvement</i>  Apophyseal joints not involved	<i>Destruction of intervertebral space, erosion of cartilage and end plate creating anterior wedging of vertebral bodies</i>  Diameter of spinal canal maintained  <i>Involvement of the posterior neural arch, spinous and transverse processes is rare but fusion can occur in the untreated individual</i>  Extra vertebral abscess found in 50–90%
<b>Appendicular Involvement</b>	<i>Involvement of other major joints in 50% of cases</i>  <i>Major joints involved typically include the hip, shoulder, knee, wrist, hand, and foot</i>  <i>New bone formation around the major joints</i>  <i>Frequency of joint involvement increases with duration of disease</i>	<i>Enthesopathies</i> typically the pubic symphysis, trochanters, patella, ischial tuberosities, iliac crests, linea aspera, Achilles tendon attachment	NA

<sup>1</sup> Squaring refers to the erosion of the anterior edge of the vertebral body visible in lateral radiographs.  
<sup>2</sup> Sacroiliac may be fused by bony bridges, not intra-articular ankylosis as displayed in AS.

Table 1

Disease characteristics of the three conditions considered during the differential diagnosis. Observed features are italicized.



### *AS, DISH, and TB Characteristics*

AS, also referred to as Marie-Strümpell disease or Bechterew's disease, is one of a number of inflammatory rheumatic disorders known collectively as spondyloarthropathies (SpA). SpAs occur in 0.5 to 1.0% of the population and primarily affect the axial skeleton and entheses [7]. AS is a degenerative inflammatory condition affecting connective tissue at ligament insertions. It is of unknown etiology, though 80 to 95% of individuals with AS also carry the antigen HLA-B27 in their blood [7–8, 11]. Screening for the presence of the HLA-B\*27 allele (a genetic test) is not recommended as a diagnostic test for AS because the disease can also occur in the absence of this allele, though if present it is thought to be diagnostic [8]. AS is known to be familial, putting siblings of affected individuals at 50 times more risk for the disease [7]. Even with the strong genetic association, it appears that environmental factors may, in part, trigger the disease. However, this relationship is not yet fully understood and more research is needed to understand the pathogenesis of AS and the complex interaction between genetic and environmental factors [8].

The onset of AS is typically between the ages of 15 to 35 years. Although it was once believed that 90% of AS-affected individuals were male, recent research shows the actual sex ratio of males to females may be closer to 66% [12–13]. The most commonly affected groups are European and Native American populations [14–15]. AS is “characterized by both reduced (osteoporosis) and increased (syndesmophytes, joint ankylosis) bone formation” [16]. This presentation is at odds with normal skeletal homeostasis, balancing deposition and resorption in unaffected adult bone tissue.

Bilateral fusion at the sacroiliac joint is the hallmark characteristic of AS [8]. From the ossa coxae, the disease then progresses cranially, up the spine, affecting the anterior longitudinal ligament insertion sites on the anterior aspect of the vertebral bodies [17]. This creates syndesmophytes that bridge the gap between the vertebral bodies and consequently fuse several vertebrae together, forming a bamboo-like appearance [18]. Calcification of the intervertebral discs occurs as the spine becomes immobile. Involvement and fusion of the zygapophyseal and costovertebral joints is typical in more severe cases. The lumbar vertebrae will have a square appearance that is due to the loss of the lateral edges of the vertebral bodies that normally appear concave [19]. In acute cases, an individual will



develop kyphosis, resulting in a permanent anterior bend in the spine [8].

AS causes erosion of the bone at the entheses (ligament insertion sites), where bone calcification replaces the connecting ligament. A new insertion is formed above the cortical bone, creating an irregular bony process [20]. About 50% of AS cases involve other major joints, such as the shoulder and knee, especially as the disease progresses [14, 21]. Diagnosis of AS is usually made through clinical presentation and radiological findings.

DISH, also known as Forestier's disease, is characterized by the production of new bone at the entheses of the spine, hands, elbows, knees, and feet (calcaneal spurs). DISH commonly affects the thoracic region of the spine, causing the progressive fusion of the spine into a thick "melted candle wax" appearance while intervertebral space is maintained. This hypertrophic bone growth typically appears on T7 through T11 and is usually confined to the anterior right aspect of the vertebral body. Diarthrodial joints and costovertebral joints are not normally affected by DISH and the sacroiliac joint is not significantly involved. Enthesopathies, particularly of the costal cartilage, are also known to occur. The disease affects older individuals, two-thirds of whom are males [22]. Factors such as obesity and adult onset diabetes often are associated with DISH. Studies found that these patients have significantly higher levels of insulin, resulting in new bone growth [20]. Diagnosis of DISH is usually made through clinical evaluation and radiological findings.

Tuberculosis, a disease that mainly affects the lungs, can also affect other areas of the body. Spinal tuberculosis, otherwise known as Pott's disease, occurs in 25 to 30% of skeletal tuberculosis cases [15]. *Mycobacterium tuberculosis* inhaled into the lungs passes through the lymphatic system to the spine where an abscess forms in the vertebral body. This leads to the destruction of the centrum and collapse of a portion of the spine into an angular kyphosis. The intervertebral joint space is not retained. Spinal tuberculosis usually affects between two and four vertebrae, often the lower thoracic and upper lumbar. It is characteristically a lytic process and bone regeneration is uncommon. The posterior neural arch, transverse processes, and spinous processes are infrequently involved but have been observed to fuse in the untreated adult [22].

### *Skeletal Characteristics Compared to Disease Characteristics*

Several pathological features on this skeleton are consistent with AS, such as the bilateral, symmetric fusion of the sacroiliac joint, which is a hallmark of the disease [22]. The progression of AS up the spine is consistent with the appearance of this skeleton. Syndesmophytic bridges fuse the lumbar vertebrae although farther up the spine the cervical vertebrae appear unfused, with smaller syndesmophytes appearing to be just developing. Although intervertebral disc space is maintained in the cervical and lumbar regions, it is collapsed and calcified in the thoracic, which has led to severe kyphosis. Lateral radiographs reveal the characteristic “bamboo” spine caused by the bony bridges fusing vertebrae together in an apparent continuous unit. Posteriorly, calcification of the interspinous and supraspinous ligaments and fusion of the zygapophyses have led to subsequent fusion of multiple spinous processes and costovertebral joints, all of which are characteristic of more advanced AS. The calcified ligaments found on the coxa, the patellae, the lesser trochanters of the femora, and other major entheses also appear consistent with a diagnosis of AS.

Although there are a few pathological features of this skeleton associated with DISH, there are significantly more characteristics that are contradictory to a DISH diagnosis. First, smaller joints that are typically affected by DISH, such as those in the hands and feet, remain unaffected in this skeleton. Second, the sacroiliac joint is bilaterally fused, a feature *specifically not* associated with DISH. Third, the thoracic vertebrae appear inconsistent with DISH. Enthesophytes that are due to DISH manifest as thick, vertically oriented growths primarily affecting the anterior right margin of the vertebral body, between T7 and T11, with intervertebral space maintained. Many of the thoracic vertebrae of this individual have bilateral syndesmophytes, showing symmetrical growth on all sides. A few thoracic vertebrae only have presentation on the left side of the vertebral body, which is opposite to the way DISH is expressed. Intervertebral disc space is maintained in the cervical and lumbar regions. However, in the thoracic region, it has compressed, ossified, and fused the vertebral bodies. Finally, this skeleton has significant involvement of the diarthrodial and costovertebral joints, again, characteristics that *do not* manifest in patients with DISH.

AS and DISH manifest similarly on a skeleton and therefore a careful macroscopic differential diagnosis must be conducted to distinguish these two diseases, if possible. In this case, only a few pathological features appear to be consistent with DISH. Therefore, based on the absence of pathological manifestations considered to be hallmarks of DISH, the authors suggest this individual does not have DISH. On the other hand, based on the pathological manifestations considered to be hallmarks of AS, such as a bilaterally fused sacroiliac joint, fused diarthrodial and costovertebral joints, and kyphosis, the authors suggest this individual most likely suffered from AS.

Further examination of the pathological features of this skeleton indicates this individual likely suffered from other comorbid conditions, specifically Pott's disease. As is characteristic of spinal tuberculosis, four thoracic vertebrae are involved and the intervertebral space is compressed. This compression led to the collapse and fusion of these vertebrae into an angular kyphosis, a deformity typical of spinal tuberculosis. The neural arch has intra- and extraspinal ligament calcification, which is occasionally found in cases of Pott's disease. Lytic activity is also present on the medial aspect of both clavicles and corresponding articulation on the manubrium. Whereas spinal tuberculosis is a disease characterized by a lytic process, this skeleton has significant bone regeneration. This apparent contradiction may be due to the bone forming attributes of AS obscuring small lesions on vertebral bodies often associated with Pott's disease. However, healing in the form of bony fusion of the vertebral bodies can also occur with TB-related kyphosis [22–23].

## **DNA Extraction and Analysis**

### *Mycobacterium Tuberculosis*

Two bone samples, from the thoracic vertebrae demonstrating pathology, were removed for genetic analysis. The DNA extraction process was conducted in a laboratory at the Corriell Institute for Medical Research (Camden, NJ) that is restricted to skeletal DNA extractions and which had never been exposed to *M. tuberculosis*. Two independent extractions were conducted adhering to strict contamination precautions. Decalcification was conducted by suspending the samples in 0.5 M EDTA, followed by solubilization using 10 mg/mL proteinase K. The DNA was isolated using an organic extraction procedure employing phenol/chloroform/isoamyl alcohol (PCI 24:24:1). Concentration

of the samples was conducted by ethanol precipitation, and the samples were stored in 1 M Tris. The samples were screened for the presence of *M. tuberculosis* DNA by polymerase chain reaction (PCR) amplification using primers targeting a repeating segment of DNA within the *M. tuberculosis* genome [24]. In each case, 25 µl PCR reactions were conducted: 2 µl DNA, 2.5 µl 10x buffer, 3 µl MgCl<sub>2</sub>, 2 µl dNTP mix, 0.3 µl Taq Gold polymerase, 0.3 µl of each 25 µM primer (forward and reverse), and 14.6 µl H<sub>2</sub>O. PCR amplification consisted of 35 cycles using an annealing temperature of 68 °C. Appropriate positive and negative controls were employed during the amplification process.

PCR amplification produced the 123 base pair fragment expected with the *M. tuberculosis* primers in two out of three amplifications for each sample. This suggests the presence of *M. tuberculosis* bacteria in the individual's thoracic vertebrae. The genetic data supports the macroscopic morphological assessment that this individual suffered from Pott's disease.

#### *HLA-B\*27*

Molecular screening for the allele was carried out in the Australian Centre for Ancient DNA at the University of Adelaide in facilities solely dedicated to work with forensic and ancient DNA. DNA was independently extracted from two samples of the os coxae, and sequence specific PCR testing was conducted for HLA-B\*27 as described previously [9]. PCR amplification utilizing the HLA-B27 primer pair was attempted several times and each failed to produce an amplicon. Appropriate HLA-B27 positive controls were added in the post-PCR laboratory to rule out PCR failure due to reagent or equipment error. DNA preservation was good, including readily amplified mitochondrial DNA fragments of up to 187 bp in length, with the resulting sequence polymorphisms unambiguously assignable to a haplogroup different from the lab personnel. Furthermore, spiking experiments with 3µl DNA extract mixed with 360 ng/µl of positive control DNA showed that the PCR was not inhibited, confirming that this individual *does not carry the HLA-B\*27 allele*. However, because the allele is not always present in individuals with AS, its absence does not eliminate the possibility that this individual had the disease.

## **Conclusion**

Differential diagnoses conducted by anthropologists and pathologists have proved useful in identifying skeletal disease

processes in forensic contexts [9–10, 25]. Many of these putative diagnoses can now be augmented by molecular techniques to potentially confirm or exclude diseases. These results may then be used to support individualization of an unidentified skeleton. Although the skeleton presented in this case study had a few characteristics associated with DISH, there were more inconsistencies with its known pathogenesis and it was not likely a condition from which this individual suffered. However, examination of the severe spinal pathologies and the genetic results indicated this individual suffered from multiple degenerative conditions. Hallmark characteristics of AS were clearly present in this skeleton. Although the genetic analysis could not confirm the presence of the HLA-B\*27 allele typically associated with AS, the predominant characteristics of AS manifested in this skeleton strongly support the diagnosis. Manifestations of spinal tuberculosis were also present although they may have been partially obscured by the severity of AS. And, the presence of *M. tuberculosis* DNA supports the conclusion that this individual had spinal tuberculosis. Careful examination of the advanced skeletal pathologies, along with supporting genetic data, has given greater support for the diagnosis of these antemortem disorders affecting this unidentified individual. Despite the added information, this individual has yet to be identified.

## Acknowledgments

The authors would like to acknowledge and thank the following individuals for their assistance and valuable contributions to this manuscript: Charles S. Hirsch, M.D., Bradley Adams, Ph.D., and Jeannette Fridie, M.A. (Office of Chief Medical Examiner, New York City); Joseph G. Lorenz, Ph.D. (Central Washington University); Dongya Yang, Ph.D. and Camilla Speller Ph.D. (Simon Fraser University); Professor Alan Cooper (Australian Research Council); Kathleen Blake, Ph.D. (State University of New York at Oswego); Marcella H. Sorg, Ph.D. (University of Maine); Stephen P. Nawrocki, Ph.D. (University of Indianapolis); Michael W. Warren, Ph.D. (University of Florida); and Dawnie Steadman, Ph.D. (University of Tennessee).

For further information, please contact:

A. Z. Mundorff  
Department of Anthropology  
University of Tennessee  
250 South Stadium Hall  
Knoxville, TN 37996  
Amundorff@utk.edu

## References

1. Haskell, N. H.; Hall, R. D.; Cervenka, V. J.; Clark, M. A. On the Body: Insects' Life Stage Presence, Their Postmortem Artifacts. In *Forensic Taphonomy: The Postmortem Fate of Human Remains*; Haglund, W. D., Sorg, M. H., Eds.; CRC Press: Boca Raton, FL, 1997; 415–448.
2. Lyman, R. L.; Fox, G. L. A Critical Evaluation of Bone Weathering as an Indication of Bone Assemblage Formation. In *Forensic Taphonomy: The Postmortem Fate of Human Remains*; Haglund, W. D., Sorg, M. H., Eds.; CRC Press: Boca Raton, FL, 1997; 223–247.
3. Trotter, M.; Gleser, G. C. A Re-evaluation of Estimation of Stature Based on Measurements of Stature Taken During Life and of Long Bones after Death. *Am. J. Phys. Anthropol.* **1958**, *16* (1), 79–123, doi: 10.1002/ajpa.1330160106.
4. Hershkovitz, I.; Donoghue, H. D.; Minnikin, D. E.; Besra, G. S.; Lee, O. Y-C.; Gernaey, A. M.; Galili, E.; Eshed, V.; Greenblatt, C. L.; Lemma, E.; Bar-Gal, G. K.; Spigelman, M. Detection and Molecular Characterization of 900-year-old Mycobacterium Tuberculosis from a Neolithic Settlement in the Eastern Mediterranean. *PLoS ONE* **2008**, *3* (10), e3426, doi:10.1371/journal.pone.0003426.
5. Donoghue, H. D.; Spigelman, M.; Greenblatt, C. L.; Lev-Maor, G.; Bar-Gal, G. K.; Matheson, C.; Vernon, K.; Nerlich, A. G.; Zink, A. R. Tuberculosis: From Prehistory to Robert Koch, as Revealed by Ancient DNA. *Lancet Infectious Disease* **2004**, *4* (9), 584–592.
6. Fletcher, H. A.; Donoghue, H. D.; Holton, J.; Pap, I.; Spigelman, M. Widespread Occurrence of Mycobacterium Tuberculosis DNA from 18th–19th Century Hungarians. *Am. J. Phys. Anthropol.* **2003**, *120* (2), 144–152, doi: 10.1002/ajpa.10114.
7. Chatzikyriakidou, A.; Voulgari, P. V.; Drosos, A. A. What is the Role of HLA-B27 in Spondyloarthropathies? *Autoimmunity Rev.* **2011**, *10* (8), 464–468, doi: 10.1016/j.autrev.2011.01.011.
8. Ehrenfeld, M. Spondyloarthropathies. *Best Practice & Res. Clin. Rheumatology* **2012**, *26* (1), 135–145, doi: 10.1016/j.berh.2012.01.002.
9. Haak, W.; Gruber, P.; Rühli, F. J.; Böni, T.; Ulrich-Bochsler, S.; Frauendorf, E.; Burger, J.; Alt, K. W. Molecular Evidence of HLA-B27 in a Historical Case of Ankylosing Spondylitis. *Arthritis & Rheumatism* **2005**, *52* (10), 3318–3319, doi: 10.1002/art.21371.

10. Leden, I.; Götherström, A.; Drenzel, L.; Svensson, B. HLA-B27 Sequences Identified in a Mediaeval Skeleton with Ankylosing Spondylitis. *Ann. Rheum. Dis.* **2009**, *68* (5), 757–758, doi: 10.1136/ard.2008.097121
11. Rogers, J.; Waldron, T. *A Field Guide to Joint Disease in Archaeology*; John Wiley and Sons: Chichester, England, 1995.
12. Gran, J. T.; Husby, G. Ankylosing Spondylitis in Women. *Seminars in Arthritis and Rheumatism* **1990**, *19* (5), 303–312.
13. Gran, J. T.; Husby, G. The Epidemiology of Ankylosing Spondylitis. *Seminars in Arthritis and Rheumatism* **1993**, *22* (5), 319–334.
14. Roberts, C.; Manchester, K. *The Archaeology of Disease*, 3rd ed.; Cornell University Press: Ithaca, New York, 2005.
15. Aufderheide, A. C.; Rodríguez-Martín, C. *The Cambridge Encyclopedia of Human Paleopathology*, 1st ed.; Cambridge University Press: Cambridge, New York, 1998.
16. Sheehan, N. J. HLA-B27: What's new? *Rheumatology* **2010**, *49* (4), 621–631, doi: 10.1093/rheumatology/kep450.
17. Resnick, D. L.; Niwayama, G. *Diagnosis of Bone and Joint Disorders*, 2nd sub ed.; WB Saunders Co.: Philadelphia, PA, 1988.
18. Eisenberg, R. L. *Skull and Spine Imaging: An Atlas of Differential Diagnosis*. Raven Press: New York, 1994.
19. Mann, R. W.; Hunt, D. R. *Photographic Regional Atlas of Bone Disease: A Guide to Pathologic and Normal Variation in the Human Skeleton*, 2nd ed.; Charles C. Thomas: Springfield, IL 2005.
20. McCarthy, E. F.; Frassica, F. J. *Pathology of Bone and Joint Disorders: With Clinical and Radiographic Correlation*. WB Saunders Company: Philadelphia, PA, 1998.
21. Rogers, J.; Waldron, T.; Dieppe, P.; Watt, I. Arthropathies in Paleopathology: the Basis of Classification According to Most Probable Cause. *J. Archeological Sci.* **1987**, *14* (2), 179–193, doi: 10.1016/0305-4403(87)90005-7.
22. Ortner, D. J. *Identification of Pathological Conditions in Human Skeletal Remains*, 2nd ed.; Academic Press: New York, 2003.
23. Ritchie, W. A. Paleopathological Evidence Suggesting Pre-Columbian Tuberculosis in New York State. *Am. J. Phys. Anthropol.* **1952**, *10* (3), 305–318.
24. Eisenach, K. D.; Cave, M. D.; Bates, J. H.; Crawford, J. T. Polymerase Chain Reaction Amplification of a Repetitive DNA Sequence Specific for Mycobacterium Tuberculosis. *J. Infect. Dis.* **1990**, *161* (5), 977–981, doi: 10.1093/infdis/161.5.977.



25. Tersigni-Tarrant, M. A.; Zachow, R. Antemortem Pathological Changes Suggestive of Reactive and Degenerative Arthritic Disorders. *Inter. J. Osteoarchaeology* **2012**, *22* (6), 718–730, doi: 10.1002/oa.1233.