

# **DEVELOPMENT OF A WEB-BASED INSTRUCTIONAL MODULE FOR INTERPRETATION OF CRANIOFACIAL CONE BEAM CT PATHOLOGY**

Wisam Al-Rawi

A thesis submitted to the faculty of the University of North Carolina at Chapel Hill in partial fulfillment of the requirements for the degree of Master of Science in the department of Dentistry.

Chapel Hill 2009

Approved by:

Dr. John Ludlow

Dr. Reinhilde Jacobs

Dr. Donald Tyndall

Dr. Enrique Platin

## **ABSTRACT**

WISAM AL-RAWI: Development of a web-based instructional module for  
interpretation of craniofacial Cone Beam CT pathology  
(Under the direction of John Ludlow)

The introduction of Cone Beam Computed Tomography (CBCT) in dental practice constitutes a paradigm shift in the way clinicians look at and interpret diagnostic information. With the rapid pace of CBCT development, and with new manufacturers and models appearing in the market each year, it is clear that this technology is assuming an increasingly important role in dental diagnosis. Because of this it will be important to provide a solid foundation on which dental students, general practitioners and specialists alike can build diagnostic skills utilizing this imaging modality. CBCT provides volumetric scans of the patient head that can be visualized in a variety of ways both in 2D and 3D. The newly developed MARCILAN website offers a highly interactive, multimedia rich, web-based, didactic module for interpretation and correlation of 3D anatomical structures as seen on CBCT. However, the current offering does not include a module to aid clinicians in the diagnosis of pathological conditions. The purpose of this study is to develop a web-based instructional module to interpret pathology as presented on cone beam CT images.

## **ACKNOWLEDGEMENTS**

Though a website can look very simple to the casual observer, however, the underlying work of this project took thousands of hard working hours and on many days I thought a project of this magnitude is simply unachievable considering the resources I had and I almost gave up.

I would like to personally thank my faculty whom without their continuous support; this project would not have started and finished. I would like to extend my thanks to my colleagues in the oral and maxillofacial radiology program, my brother Bassam Al-Rawi and my friend and colleague Bassam Hassan who were always beside me when I needed help, encouraging me and cheering me up.

I would like to thank also Prof. Paulo H. Couto Souza (School of Dentistry, Pontifical Catholic University of Paraná, Curitiba, Brazil) for his contribution of cases and help with our project.

## **DEDICATIONS**

I personally dedicate this work to the best friend and classmate I ever had Asal Mohammed Al-Quarishi who passed away in Iraq while I was working on this project. He always had the dream of coming to the United States. I will never forget you my friend and thanks for making my life a joyful experience!

I would like to dedicate this work also to my faculty and my parents for their generosity to support me and taking the burden to help covering the expenses of my study and my living.

## TABLE OF CONTENTS

### Chapter

I.	CONE BEAM COMPUTED TOMOGRAPHY.....	1
	Introduction of Cone Beam CT .....	1
	The Internet Role .....	2
	MARCILAN .....	2
	Previous Work .....	3
II.	THE EVOLVED WEB .....	4
	Web 2.0 .....	4
	The Limited HTML.....	4
	Web Design Practices.....	5
III.	WEB DEVELOPMENT .....	6
	WordPress .....	6
	Setup .....	7
	Theme .....	7
	Accessibility .....	8
	Setbacks .....	9
IV.	PATHOLOGY ON CONE BEAM CT.....	11
	Classifications .....	11
	Organization .....	11
	Cases Collection .....	12
	Reports .....	13
V.	SOFTWARE .....	14
	Image and File Editing.....	14
	From Image Reports to Multimedia Reports.....	14
	Compression.....	16
VI.	HIGHLY INTERACTIVE WEBSITE .....	17

	Home Page .....	17
	Navigation .....	17
	Text .....	19
VII.	ADVANCED WEB TECHNOLOGIES .....	20
	AJAX .....	20
	Database Backup .....	20
	Cascading Style Sheets (CSS) .....	21
	Shadowbox Galleries.....	21
	Cross-Browsers Compatibility.....	22
	Intelligent Search .....	22
	Search Engine Optimization (SEO).....	23
	Google Analytics .....	24
	User Access Control (UAC) .....	24
	Collaboration .....	24
	Upscaling .....	25
	International Support.....	26
VIII.	A WEB SOLUTION .....	27
	Alternatives .....	27
	Open-Source.....	27
	Conclusion .....	28

## LIST OF FIGURES

### Figure

1. The administrator's dashboard.....	29
2. Page editing. ....	30
3. The anatomical module integrated in MARCILAN.....	31
4. A MIP rendered QTVR 360 movie for a basal cell nevus syndrome case.....	32
5. MARCILAN home page.....	33
6. The dentigerous cyst page.....	34
7. Case reports and how to access them.....	35
8. The gallery loaded in a shadowbox window with description. ....	36
9. Cached and non-cached pages. ....	37
10. User access control. ....	38

## ABBREVIATIONS

AJAX	Asynchronous Javascript and XML
AOT	Adenomatoid Odontogenic Tumor
CBCT	Cone Beam Computed Tomography
CILE	Cone Beam CT Interactive Learning Environment
CMS	Content Management System
COC	Calcifying Odontogenic Cyst
CPU	Central Processing Unit
CSS	Cascading Style Sheets
CT	Computed Tomography
DICOM	Digital Imaging and Communications in Medicine
EPR	Electronic Patients Record
HIPPA	Health Insurance Portability and Accountability Act
HTML	HyperText Markup Language
IE	Internet Explorer
JPEG	Joint Photographic Experts Group
JS	JavaScript
MARCILAN	Maxillofacial Radiology Cone Beam CT Interactive Learning and Navigation
MIP	Maximum Intensity Projection
MPR	Multi-Planar Reformatted



QTVR	QuickTime Virtual Reality
RAM	Random Access Memory
RDC	Remote Desktop Connection
RSS	Really Simple Syndication or Rich Site Summary
SEO	Search Engine Optimization
UAC	User Access Control
VR	Virtual Reality
W3C	World Wide Web Consortium
WAMP	Windows Apache, MySQL and PHP
WCAG	Web Content Accessibility Guidelines
XML	eXtensible Markup Language

# **CHAPTER 1**

## **CONE BEAM COMPUTED TOMOGRAPHY**

### **INTRODUCTION OF CONE BEAM CT**

The introduction of Cone Beam Computed Tomography (CBCT) in dental practice constitutes a paradigm shift in the way clinicians look at patient images and interpret diagnostic information (1). CBCT provides a volumetric x-ray scan of patient head that can be visualized in a variety of ways such as multi-planar reformatted (MPR) slices, cross-sectional slices, synthetic panoramic, 3D shaded surface and volumetric rendering (2). CBCT has less cost, radiation dose, complexity, size and weight when compared to medical CT (3-9). With the rapid pace of CBCT development, and with new manufacturers and models appearing on the market each year, it is clear that this technology is assuming an increasingly important role in dental diagnosis. Thus, it is important to provide a solid foundation on which dental students general practitioners and specialists alike can build diagnostic skills utilizing this imaging modality (10).

## THE INTERNET ROLE

The Internet has transformed the globe into a small village. Access to the Internet is easy and ubiquitous as users can access it anytime, anywhere, and through multiple devices. The Internet can be used effectively as a medium to transmit information across the globe in a short amount of time. There are several web-based educational packages in different disciplines where educators write and publish content for large audiences. The Internet has clearly played a role in the development of many new applications and opportunities for radiologists (11-14). However, at the time of writing of this paper; there are not many educational resources available to the dental community addressing Cone Beam CT use in dentistry.

## MARCILAN

The newly developed Maxillofacial Radiology CBCT Interactive Learning And Navigation (MARCILAN) offers a highly interactive, multimedia rich, web-based, didactic module for interpretation and correlation of 3D anatomical structures as seen on CBCT. However, the current offering does not include a module to aid clinicians in the diagnosis of pathological conditions. The purpose of this project was to develop a web-based instructional module that teaches interpretation of pathology as presented on Cone Beam CT images. A future phase of the study will evaluate the effectiveness of the module for training dental students and helping clinicians.

## PREVIOUS WORK

In our previous study we developed and evaluated CILE (Cone Beam CT Interactive Learning Environment)(15; 16) to serve as a platform to teach basic principles of interpretation and the correlation of anatomical structures depicted on CBCT volumetric data. It also served as an assessment module to evaluate learning performance.

## **CHAPTER 2**

### **THE EVOLVED WEB**

#### **WEB 2.0**

Web 2.0 is the newly evolved version of the web (17). It allows unprecedented interaction through web-based rich user interfaces, user generated content, and it serves as a global platform for sharing of data and services (18). It empowers distant learning and serves as a medium to lower the barrier between users in the web environment (19). Examples of Web 2.0 applications where users can collaborate and share information include: wikis, blogs, instant messaging, news feeds, video sharing websites such as YouTube, and social networking websites like Facebook (18; 20).

#### **THE LIMITED HTML**

One of the major obstacles that we faced previously was that the older module was based on static HTML (Hyper Text Markup Language) pages with embedded and inline CSS (Cascading Style Sheet). This system required the opening of each page in order to change an element in a page such as font size, font style or background color globally in the website. This process was very tedious and time consuming. In addition, static HTML pages

do not support users' authentication. So there is no way to control who can or cannot be allowed to access the website. Adding additional functionalities on the platform was thus limited unless a radical change could be carried out.

## WEB DESIGN PRACTICES

We decided to adopt the best web design practices (21-23) for building the pathology module. The goal was to have an easy to use and simple layout design. It should address usability, accessibility, interactivity and compatibility. The entire website was redesigned to support web 2.0 features and at the same time maintained or improved the previous level of interactivity.

## **CHAPTER 3**

### **WEB DEVELOPMENT**

#### **WORDPRESS**

WordPress provides publishing tools that focus on aesthetics, web standards and usability. It is probably one of the most popular blogging tools on the web. It is an open source software package that provides a basic core engine and the capability to extend its level of functionality through addition of extensions (plugins). It is free and requires a basic server web technologies setup that includes Apache web server, MySQL database for storing the data and PHP scripting for executing commands; all of which are available at no cost. Since WordPress separates the content (structure) from the presentation (theme) it allows us to add content without having to worry about how our page will be rendered. It is possible to customize the look of certain elements like headers, paragraphs, ordered list ...etc across the website either globally or locally through the use of external, embedded cascading style sheets (CSS) respectively. It leverages the user experience and simplifies publishing of content. The interface is elegant, user-friendly, and has a control panel where administrators can control every aspect of the website while providing visual feedback before a change is implemented as seen in figure 1.

This is important if we want to allow non-technical users and oral and maxillofacial radiologists to collaborate on the content of the website without requiring them to understand the underlying technology so they can focus on the content as seen in figure 2. The initial setup was to do the development and testing locally and then transfer the data to a web server on the internet. This approach reduces the development time with added convenience.

## SETUP

A Lenovo R61 laptop (Lenovo Group) that is powered by an Intel Core 2 Duo processor with 2 GB of memory and 14" display was used for this project. WAMP server 2.0 (Windows Apache, MySQL and PHP) was installed on our laptop and a generic theme to serve as our framework was used for the final website look and feel. Our experience in CSS and HTML was invaluable in arriving at a final consistent theme. All the modules from the previously developed website have been migrated to the new platform. In figure 3, one of the anatomical sections integrated in the new platform can be seen. Over 3000 plugins on WordPress Extend website were reviewed and 30 were incorporated into the website.

## THEME

The previous theme of the website had a black font text against a white background. We thought the glare from a white background especially in bright monitors was not well



suited for image interpretation. The current theme has a dark background and the gallery window dims the background; thus simulating dim lights conditions on the computer screen which helps to reduce glare and improve viewing images.

## ACCESSIBILITY

W3C (World Wide Web Consortium) web content accessibility and usability 2.0 guidelines were followed while designing MARCILAN. The guidelines define how perceivable the content should be and how operable the interface elements are. The content and controls should be understandable and the content must be robust enough to work with current and future technologies (24). Great attention was paid to accessibility as it is considered to be one of the key challenges that face any web designer (25; 26). WCAG 2.0 (Web Content Accessibility Guidelines 2.0) guidelines were followed and many of the guidelines recommendations were addressed. An alt tag for almost all of the images in which you get a description text displayed relevant to the image when the image is not displayed was provided. Although it is unclear how visually impaired individuals can perform radiographic interpretation, nevertheless, alt text was provided to address them and address instances when images fail to load. The provided breadcrumbs trails which let the user be aware of the current page displayed and under which category with the added possibility to navigate levels up helps in making the pages more accessible. We tried to set the interface to be as clutter free as possible and all the pages share the same colors, background, headline, footer, fonts and layout. This should help to maintain design

consistency. Acronyms were provided globally across the website. So when a user sees MIP, QTVR, COC, AOT...etc on any page; hovering the cursor over an acronym reveals its full name. Keyboard navigation is possible not only on the website but also in Shadowbox gallery and QuickTime VR movies. The website is predictable, links have dotted underline, and hovering the cursor over them gives additional feedback. If a text in a link got cropped for esthetic reasons; hovering the cursor over the link reveals the link's full name and it uses the page title's name instead of just previous page or next page. In terms of input assistance, the website's custom 404 page not found page has Google's 404 code (from Google web masters tools) to let the user search the site using Google search engine. It displays a list of possible related pages that matches the page the user is trying to access but unable to do so.

## SETBACKS

We had our share of setbacks. Initially the development phase and design layout were laid down using Dreamweaver CS3 (Adobe Systems Inc.). After months of testing, it became apparent that it required a high level of expertise in web scripting and a dedicated team of web developers to continue the development work. That required resources that we simply could not afford. We had to look for an alternative approach. In addition, our dental school server uses Microsoft products for running its web services. With such incompatible technologies, limited storage capacity, and limited access to the server we

opted to invest in a web hosting solution to save us the headache, time for server maintenance, and administrative overhead.

## **CHAPTER 4**

### **PATHOLOGY ON CONE BEAM CT**

#### **CLASSIFICATIONS**

There was a need to follow a standard for organizing oral and maxillofacial pathology into lists. Classifications by White and Pharaoh (27) were adapted as our baseline with minor modifications as it is considered the de-facto standard book in the radiology courses given at our school and many other dental schools. With a consistent classification used across the curriculum, users will have a sense of familiarity when trying to access specific diseases or pathological conditions.

#### **ORGANIZATION**

An Excel spreadsheet was laid out which has classification of diseases in categories, number of collected cases, and patients' charts numbers associated with those cases to allow us to track and monitor our case collection progress. Having the charts' numbers allowed us to go back to the Electronic Patients Record (EPR) to verify the condition of the patient or to see if there was an update for the patient status.

## CASES COLLECTION

The patients' database record for the NewTom 3G CBCT machine from 2004-2009 was accessed and a list was prepared with patients' name, age, gender, and disease associated with that case. The list was divided based on the year of the exam to facilitate handling over 300 patient cases. Reports for older patients from 2004 and 2005 were archived in the dental school archive storage. The archives were retrieved to access the pathology report, radiology report and progress access notes of the patients in question. The reports were updated to reflect patient's progress status and treatment plans. Patient name and chart's numbers were removed upon compilation of the final cases list to comply with HIPPA (Health Insurance Portability and Accountability Act) regulations. Remote Desktop Connection (RDC) for Microsoft Windows was used to do most of the work as it allowed access to the dental school servers while working remotely so that all the files remain on the schools remote computers reducing the risk of theft. It also allowed us to work more efficiently and comfortably as we were able to access the data from anywhere even from home. RDC is installed by default on every machine running version of Microsoft Windows (XP, Vista and 7).

## REPORTS

Folders were created with the main disease categories. Subfolders for a specific disease were placed inside the main folder and within the subfolder; another subfolder was created for each case. Inside the latter, report images and text file were placed. The text file included patient information such as age at the date of exam, gender and ethnicity (if available). The report also included the type of CBCT machine used, radiographic findings and impression. We felt that it would be very helpful to include conventional images (Periapicals, panoramic and cephalometric images) beside the CBCT report images as many dental practitioners are more familiar with them and we thought it would help to bridge the gap in better understanding and appreciating CBCT images. Post treatment images were added (if available) to the reports to let the users understand the extent and results of treatment for a particular condition.

With textual descriptions from different literature sources included for every disease, individuals can use the website as an online interactive book that can be accessed from anywhere across multiple devices. It can serve as an adjunctive tool to oral radiology textbooks or as a quick reference for diseases.

Many textbooks include images of diseases to provide the reader with a picture of what a particular lesion looks like. We opted to include a full case report which includes pre and post op images and history of the case, findings and impression. In doing so, we believe it puts the disease in perspective and can give a real life scenario of how the disease affects a patient.

## **CHAPTER 5**

### **SOFTWARE**

#### **IMAGE AND FILE EDITING**

FastStone Image Viewer 3.7 (FastStone Soft) was used to mass process hundreds of reports' images. White spaces from reports' images were cropped, arrows to pinpoint a disease or condition were added, and a custom watermark was overlaid over the images. In addition, a free software called SpaceTornado Renamer (SpaceTornado) was used to batch rename file names since the images that were exported from EPR have file names with capital letters. Web servers like Apache interprets files with capitals as different files from files with small letters. Zotero (from George Mason University) which is an open source citation tool was used with Firefox 3 for collecting and managing the citations sources for the suggested reading section for each pathology category.

#### **FROM IMAGE REPORTS TO MULTIMEDIA REPORTS**

During the last phase of development, our department invested in purchasing a Mac Pro (Apple Inc.) The specifications are: 8 cores Intel Xeon 3.0 Ghz, 4 GB of memory, and GeForce 8800GT graphics card. We investigated the possibility of using this new resource in

our project. OsiriX 3.3.2 DICOM (Digital Imaging and Communications in Medicine) viewer with 64-bit extension was used to visualize patients' volumetric data set. NewTom 3G software uses proprietary file format to display and store patients' data which is not compatible with 3<sup>rd</sup> party software. All patients' data were exported to DICOM data set; a separate but similar folder structure for cases image was used to store and manages large file size DICOM files. Recording patients' charts numbers initially allowed us to go back and retrieve the DICOM files. With OsiriX at our hands, we were able to generate 360 QTVR (QuickTime Virtual Reality) interactive videos that are cross-platform and cross-browsers compatible ready to be embedded on the web.

Generating video reports have been plagued by the fact that it if takes too much time to generate therefore oral and maxillofacial radiologists will limit their reports to images only. OsiriX is a fully multi-threaded application and it fully exploits all available 8 CPU cores to render very high quality videos in very short amount of time. The 64-bit extension lets OsiriX have full access to the memory and greatly improves performance while its DICOM centralized database let us import all the DICOM data sets at once saving time and trouble when opening and closing a case.

Although we lose some information by going from 2D slices to 3D rendered movies, we do gain extra spatial information, better correlation, better appreciation of the radiographic features, and is better for patient communication. Different rendering techniques were used like MIP (Maximum intensity projection) volumetric render as it provided the best visualization for many lesions as seen in figure 4. Two sets of videos are provided: one with 100 projections that serves as our baseline and another set with 400



projections that provides smoother rotation around the patient's head which we intend to use when we upscale the website in the future.

## COMPRESSION

Images and videos were compressed to save bandwidth and improve performance. All images were saved to JPEG (Joint Photographic Experts Group) format at 75% lossy compression ratio with optimized Huffman encoding to improve compression ratio. A picture by picture comparison feature available in FastStone Image viewer was used to compare and evaluate image quality before and after the compression is applied. In many instances, it was possible to achieve a compression ratio as high as 8-10% of the original file size while maintaining an acceptable image quality. For QTVR videos, H.264 codec which is a new compression format that is network-friendly; offers excellent quality videos and good reduction in file size was used (28). Compressed versions of the JavaScripts were used on the website to further improve performance.

## **CHAPTER 6**

### **HIGHLY INTERACTIVE WEBSITE**

#### **HOME PAGE**

A highly flexible and interactive web-based CBCT pathology teaching module was created as seen in figure 5. Accessing any feature of the website is done through the top navigation bar. The current website has a blogging module integrated in it which will facilitate collaboration (29-31) and serves as a medium to update users about any new additions to the website and other announcements. The users can get the latest site updates without even visiting the website by subscribing either to RSS (Rich Site Summary) news feeds through their favorite news reader or Podcast feeds using their iPod or iPhone to access audible version of the news. Widgets can be inserted on the side bar to serve different functionalities.

#### **NAVIGATION**

Navigating the pathology module can be done in several ways. Figure 6 shows one of the pages that covers a pathological condition. Relevant diseases from the same category can be accessed from the left side bar. In the middle, the user sees the disease description

that covers: synonym, definition, clinical features, radiographic features, differential diagnosis and treatment. A table of contents allows the user to jump to any of the previously mentioned headlines. A list of all the available case reports for that disease is found at the bottom of the window. On the right side of the screen, the user sees a summary with the important features of that disease, below that a list of possible differential diagnosis. The diseases in the differential diagnosis list are linked to their respective pages. This should provide the user fast access to those diseases and let the user compare them with the current disease being studied. To provide a better sense of current location while navigating, breadcrumbs trails which can be seen on the upper left corner below the top navigation bar have been added. Clicking on any of the links moves the user one level up or more in the hierarchy. This should improve usability.

In every disease category, the user is presented with a general description about the disease and a list of all available cases accessible for that disease as seen in figure 7. Users can access different diseases in the same category from the left side bar. Clicking on a case name will slide open that case for viewing and the user can access the case text report immediately. The case reports image caption displays the CBCT machine used and a courtesy reference to the case donor. Clicking on the case image will launch a special image gallery window for the report's image gallery. Below every image there is a description for the features presented on that image as seen in figure 8.

## TEXT

Multiple oral and maxillofacial radiology literature sources were used when compiling our pathology text and at the end of each classification or category a suggested reading was provided for users who are interested to learn more about that classification or category.

## **CHAPTER 7**

### **ADVANCED WEB TECHNOLOGIES**

#### **AJAX**

The current website utilizes AJAX (Asynchronous Javascript and XML) for updating the content of the page without forcing a page refresh if the page supports it. The data is stored in an XML table as a data set. This separates the content from the presentation allowing authors to add or modify existing content by simply editing the .xml file using simple text editing programs.

#### **DATABASE BACKUP**

Pages content is stored in a MySQL database making back up of the whole website a streamlined process. Backing up files and database is crucial in case someone managed to hack the website or if the database got corrupted. WordPress Database Backup was used to backup our site's database on daily basis.

## CASCADING STYLE SHEETS (CSS)

There is only one main CSS file (main.css) that defines the look across the entire website. The file defines different properties such as font type, color, background color, borders, padding, margins... etc for different page elements like header, body, footer, sidebars, widgets, and plugins. When any modification is necessary; the CSS file can be edited using a simple text editor or through the web interface then saved. Once the page is refreshed, changes can be seen immediately and no change to the page code is necessary. So web designers can update the look of the website without worrying about affecting or breaking any page content. It is also possible to deploy multiple themes by changing certain properties like font color and background color then saving the file under a different file name. This can give the users the choice to select the theme they feel most comfortable with rather than forcing the users to use a specific theme.

## SHADOWBOX GALLERIES

A JavaScript called Shadowbox JS Media Viewer (By Michael J. Jackson) was used to load the image gallery. It dims the screen so that the user's focus is shifted towards what's inside the window as seen in figure 8. It allows the user to efficiently navigate a full size page report with a small screen size by mouse clicking and dragging the image. This should help provide immersive environment to read case reports. Although the design was done on a screen resolution of 1280x800, a minimum screen resolution of 1024x768 or higher is

required in order to display the website properly. This should help cover a wide range of users who are using older or smaller displays.

## CROSS-BROWSERS COMPATIBILITY

One of the main aims of the website was to achieve cross browsers compatibility. Although many users are shifting away from using Microsoft IE (Internet Explorer) toward other browsers like Mozilla Firefox, Apple Safari or Google Chrome. We worked hard to make sure the layout renders as uniformly as possible across those four browsers. Internet Explorer has proven to be the most problematic when it comes to CSS compatibility and adherence to web standards. Google's Chrome browser is still in beta; however, it uses the same open source WebKit render engine that Safari uses so we should expect similar compatibility as with Safari.

## INTELLIGENT SEARCH

Search is vital to any website and as web authors start adding new content and pages to their website, it becomes harder for users to find a particular piece of information or access a page. Search functionality with a search suggestions drop down list was added. As the user starts typing in the search field, the search engine will start displaying all the possible matches for what you are looking for. We thought besides convenience, this

functionality can save users some time searching. Search functionality should improve the usability of the website.

## SEARCH ENGINE OPTIMIZATION (SEO)

Exposure of the previous site (CILE) to search engines was an issue. We know that many users rely on search engines to find what they are looking for. If users cannot find a website through search engines then the site will receive far fewer hits. A sitemap XML (Extensible Markup Language) file was generated which tells the search engine what it needs to know about the structure of the website. This information was then submitted to a SEO (Search Engine Optimization) plugin which updates Google, Yahoo and Microsoft Live search engines regularly with changes to the website so that their crawlers can access the website and index it more efficiently. During the writing of this paper, major search engines now rank the website on top when searching for CBCT pathology. The file robots.txt was used to restrict the search engine web crawlers or robots from accessing certain pages and indexing them, there is no need to index lost password page or end user license page for example. In addition, during the testing period, we noticed that search engines like Google has cached our website and saved a copy of every page in their archive. Although this cache can be used for accessing the page while the website is inaccessible, however, we wanted to restrict the access to those pages and we introduced the command “*noarchive*” into our website’s header file which instructs web robots and sites like archive.org not to archive the pages in their database as seen in figure 9.



## GOOGLE ANALYTICS

Analyzing website traffic is very important because it provides information about user characteristics such as where the users are coming from, which sections they are visiting the most, what browsers they are using, and their internet connection speed. From analyzing this data the website can be optimized for future development based on those parameters. A free and powerful tool is Google Analytics <http://www.google.com/analytics> which provides extensive data tracking for different time periods and provides plot graphs for website traffic. Using Google analytics is not difficult; web developers can go to Google Analytics website and register their website for free. They will have access to the dashboard with many powerful tools to analyze their websites. More than one website can be added to the same account too; allowing multiple sites tracking.

## USER ACCESS CONTROL (UAC)

In order to let the administrators have control over who can access the website, we worked closely with WordPress plugin developers and now it is possible to enroll registered users into user access groups that define the section the users can access based on privileges levels. However, for institutions having hundreds of users registering everyone is tedious, and inefficient. Putting that into perspective, users will be able to access the website using wide IP based authentication. This should provide transparent access to students and faculty across a university campus as seen in figure 9.

## Collaboration

We wanted to give the opportunity for other people to collaborate on the content of the site. WordPress supports different levels of user access levels as part of its blogging functionality. There are 5 levels of access: subscriber level which is the lowest that allows people to comment on the site, contributor level which allows individuals to write and edit posts but unable to publish them, authors' level which allows individuals to add content to the website, editors' level which allows individuals to add content as well as have the rights to edit other people content, and lastly administrators who have access on everything and can take full control of the website. Having multiple authors can enrich the website with content from people who have an excellent experience in oral and maxillofacial radiology.

## UPSCALING

We thought about future usage of the website and we know that as time passes by; many users will have access to faster internet connection allowing them to stream or download large amounts of data in short amount of time. However, there will be many users who don't have access to fast or ultra high-speed Internet connection. We still wanted to let users with internet bandwidth at the lower end of the spectrum to access the website. In addition, our current web hosting server has a bandwidth cap limit. So we opted to offer images and videos that meet those requirements. However, High resolution pathology report images and videos were stored for future use on the website which will allow us to upscale them whenever needed.

## INTERNATIONAL SUPPORT

In the initial design phases, we planned for MARCILAN not to be restricted to a single language and we had several design challenges that needed to be met. United States English is the current website language. Future translation of the website to languages other than English is possible and is viewed as desirable for serving students of radiology in non-English speaking parts of the world.

## **CHAPTER 8**

### **A WEB SOLUTION**

#### **ALTERNATIVES**

There are other open source alternatives for WordPress which include different CMS (Content Management System) packages like Joomla and Drupal. ConeBeam.com website relies on Drupal for example to server content to their users. However, with the rapid pace of plugins developed for WordPress, it may be hard for other software packages to catch up.

#### **OPEN-SOURCE**

Open source software has been utilized as the main development tool for this project. Despite limitations in budget, and just a single developer, most of the initial design goals have been achieved in an eight months timeframe and a solid foundation was established. Several modules can utilize the underlying core technologies of the foundation to provide interactive and engaging modules. An interactive and engaging module that could help clinician to better interpret pathology with CBCT has been developed.

## CONCLUSION

We hope that the information presented serves as a reference for interested individuals and institutions to deploy Web 2.0 applications by upgrading their existing didactic websites and not miss all those interesting features. Many of the features mentioned in this paper do not require you to be a web developer guru or a professional web designer in order to improve the educational experience.

We are very interested to see how our users are going to apply our tools to advance their education and knowledge about maxillofacial radiology and Cone Beam CT. The web is evolving and so should our didactic tools in order to meet the needs of the next generation of users. More research is necessary to evaluate the effectiveness of the module. MARCILAN can be accessed by visiting <http://www.marcilan.com>

Figure 1. The administrator's dashboard.

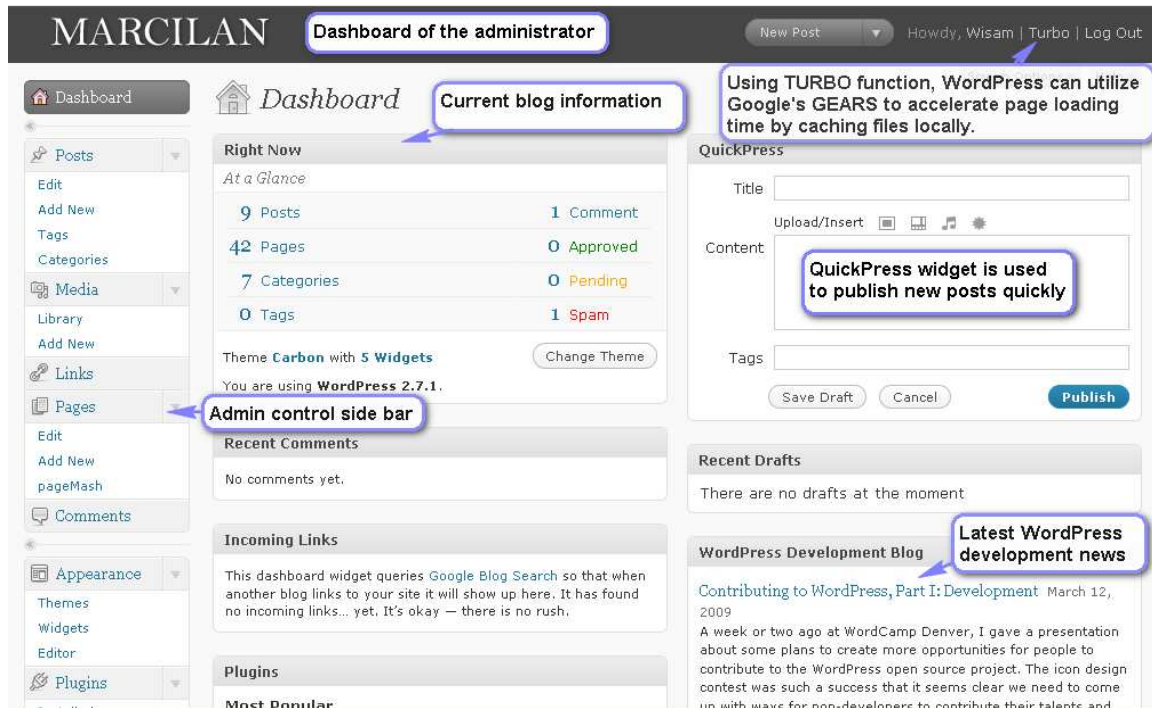


Figure 2. Page editing.

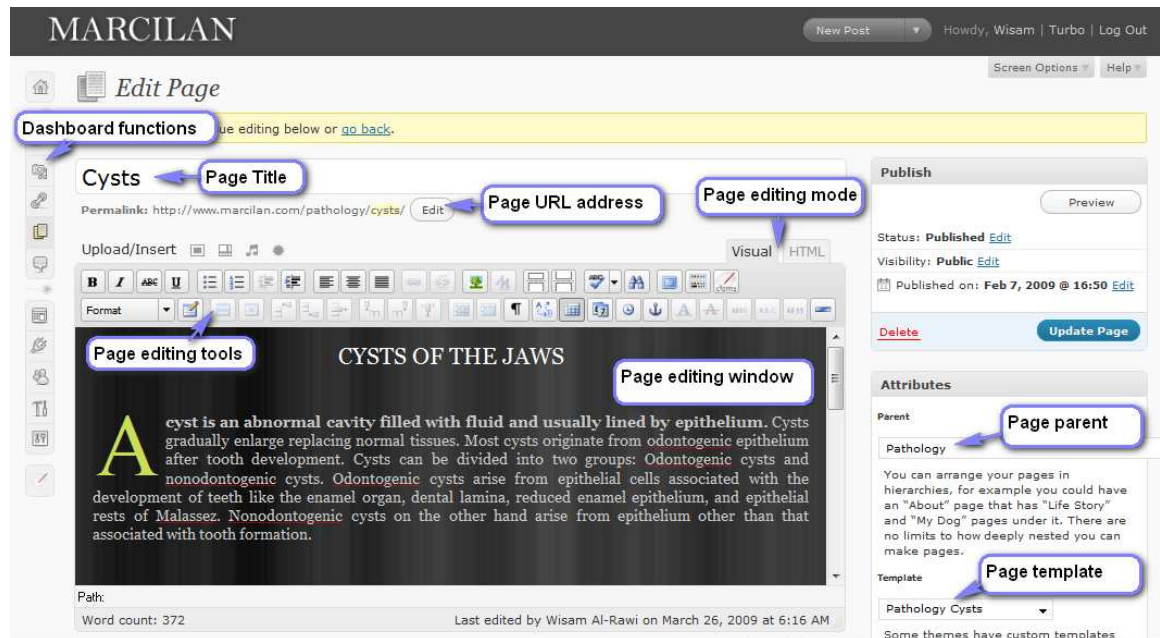


Figure 3. The anatomical module integrated in MARCILAN.

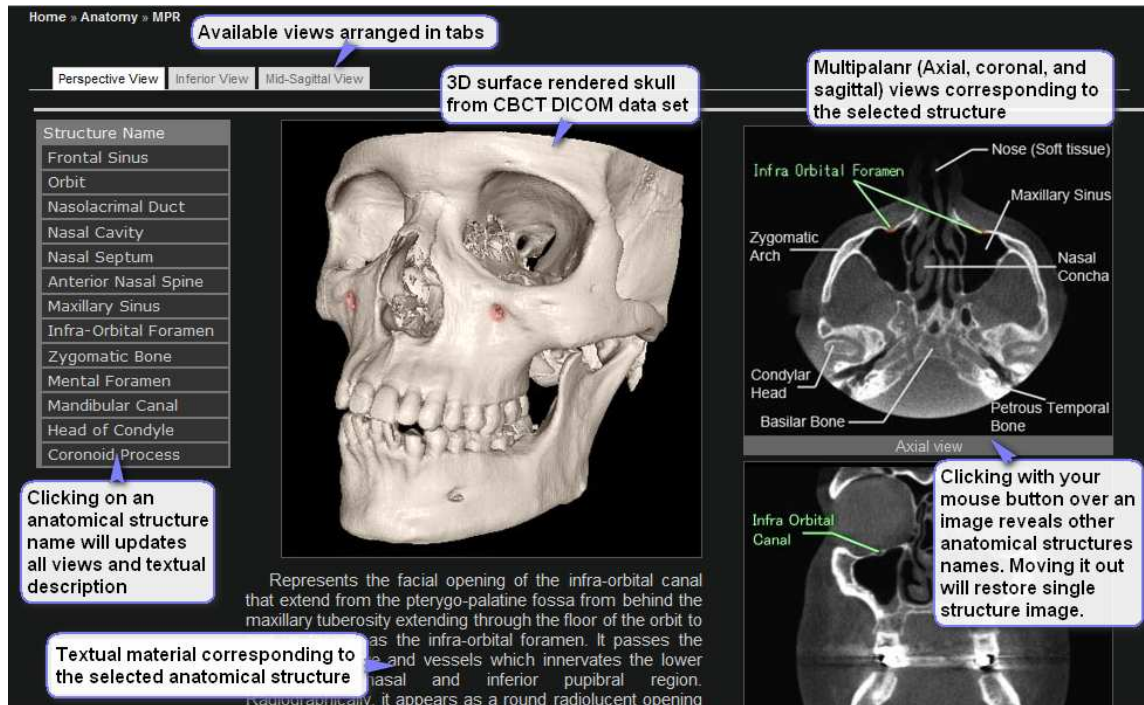




Figure 4. A MIP rendered QTVR 360 movie for a basal cell nevus syndrome case.

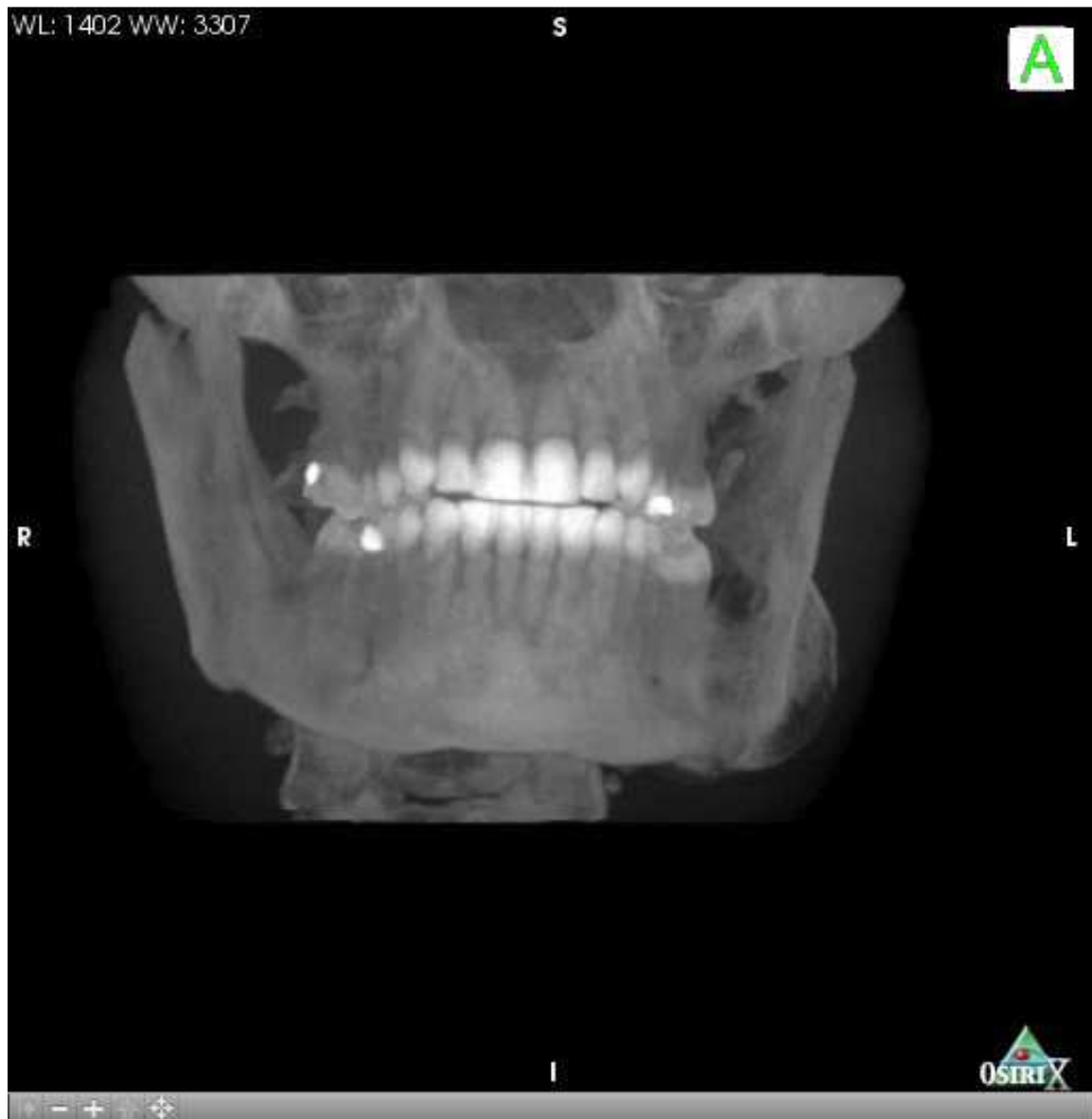

Figure 5. MARCILAN home page.

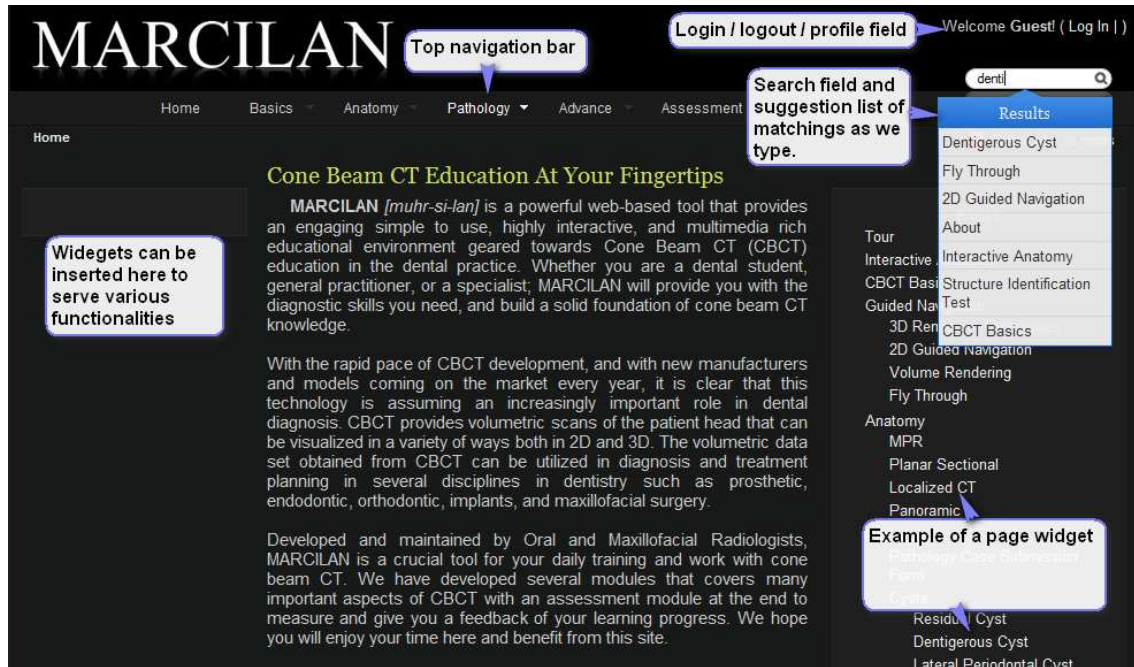


Figure 6. The dentigerous cyst page.

The screenshot shows the MARCIAN website page for "Dentigerous Cyst". The page layout includes a top navigation bar with "Home » Pathology » Cysts » Dentigerous Cyst", a search bar, and a user greeting "Welcome Guest! ( Log In | )".

Callout boxes highlight the following features:

- Current location can be seen. Clicking on a name will move you to the corresponding page.** (Points to the breadcrumb trail)
- Disease name and description** (Points to the main title "Dentigerous Cyst")
- Collapsible table of content. Clicking on a title will jump you to the corresponding section** (Points to the table of contents on the right)
- Disease summary and differential diagnosis** (Points to the "Summary" and "DDX" sections)
- List of diseases in the same category** (Points to the left sidebar menu)

The main content area is titled "Dentigerous Cyst" and includes sections for "Synonym / Acronym" (Follicular cyst), "Definition" (It is a cyst that forms from the accumulation of fluid between the reduced enamel epithelium and the crown of an unerupted tooth and attaches to the tooth neck at the cementoamel junction), "Clinical Features" (Dentigerous cysts are the second most common odontogenic cysts, next to radicular cysts. The teeth most involved are, in descending order of frequency of occurrence, the third molars, the canines, and the second premolars. Dentigerous cysts can form around supernumerary teeth most commonly found around mesiodense. Usually there are no symptoms associated with dentigerous cysts. A late noneruption could indicate the possibility of a cyst. A dentigerous cyst can expand causing facial asymmetry. As with other cysts, dentigerous cyst expands the outer cortical plate more than the lingual plate. It may involve other teeth as it expands. The term eruption cyst is used for a cyst that surrounds the crown of erupted tooth in soft tissue.), and "Radiographic Features" (Well-defined unilocular radiolucency associated with the crown of an unerupted tooth. If the cyst got infected the cortex may be absent. The cyst attaches at the cementoamel junction. It can appear round in shape or eccentric if the cyst develops from the lateral aspect of the follicle. Dentigerous cyst in mandibular third molars can expand to occupy the ramus area which represents an area of least resistance to cyst expansion. It causes displacement of the affected tooth in an apical direction and adjacent teeth in lateral direction. Inferior displacement of the inferior mandibular canal is also possible. Dentigerous cysts associated with maxillary teeth can grow into the maxillary sinus space and may not be discovered till late).

The right sidebar contains a "Summary" section with bullet points:

- Smooth well-defined unilocular often corticated.
- Uniformly radiolucent.
- Round or oval, symmetrically surrounds the crown. 5mm to several centimeters in size.
- Associated with crown of unerupted teeth usually third molars, canines, second molars, and supernumerary teeth.
- Displacement, Resorption, can cause Expansion.
- Usually teenagers, 20-40 years old. 1.6 male to female ratio

The "DDX" (Differential Diagnosis) section lists:

- Ameloblastoma
- KCOT
- AOT
- Ameloblastic fibroma

Figure 7. Case reports and how to access them.

**Treatment**

Surgical removal of the cyst alone or along with the associated tooth is carried out. If the cyst is large then marsupialization can be done before the surgical removal. Whenever a diagnosis of a dentigerous cyst is made, the possibility of being mural ameloblastoma should also be considered thus a biopsy is imperative and must always be done to confirm the final diagnosis and eliminate other diseases.

**Case Reports**

[CASE 1»](#) **Dynamic case reports (collapsed)**

[CASE 2»](#)

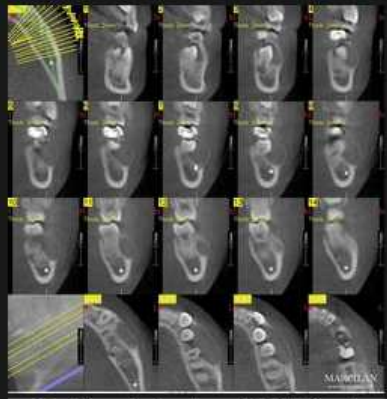
[CASE 3»](#)

Clicking on a case number will slide open the case. Case information will be displayed.

Case thumbnail and caption. Clicking on thumbnail image will launch gallery window.

**HISTORY:** A 10 years old patient was referred for tomographic evaluation of an expansile lesion in the left mandibular premolar area.

**FINDINGS:** Dental development is consistent with the patient age of 10 years. A mixed dentition is present with permanent incisors and 1st molars in occlusion. Primary molars and canine teeth with the exception tooth #m are present. A well-defined, smoothly contoured, corticated radiolucency extends from the distal aspect of the crown of unerupted #22 to the furcation area of the buccal aspect of #19. It extends from the crestal area of #19 inferiorly to the mental foramen. It has caused hydrostatic expansion and thinning of the buccal cortex and extends bucco-lingually to the lingual cortex of the follicular margin of unerupted @21. Maximum dimensions of the lesion are 27 mm L x 13 mm W x 14 mm H. The follicular spaces of unerupted #20 and 22 are contiguous and indistinguishable from the lesion. The lesion has caused lingual displacement of the roots of #20 and #21. These teeth exhibit root formation that is approximately half complete. There is no evidence of root resorption. While the lesion encroaches on the mental foramen, it does not appear to displace this structure. It is noteworthy that lingual aspect of the lesion appears to intersect the CEJ areas of both #20 and #21.



NewTom 3G. Courtesy of UNC-Chapel Hill School of Dentistry, United States

**IMPRESSIONS:** The hydrostatic character of this lesion is strongly suggestive of a cyst. The apparent association of the CEJ(s) of unerupted premolar teeth and buccal expansion are consistent with dentigerous cyst. KCOT would also be included in the differential. A benign odontogenic tumor is possible but unlikely.

Clicking on Back to Top will move you back to the top of the page.

Back to Top

Figure 8. The gallery loaded in a shadowbox window with description.

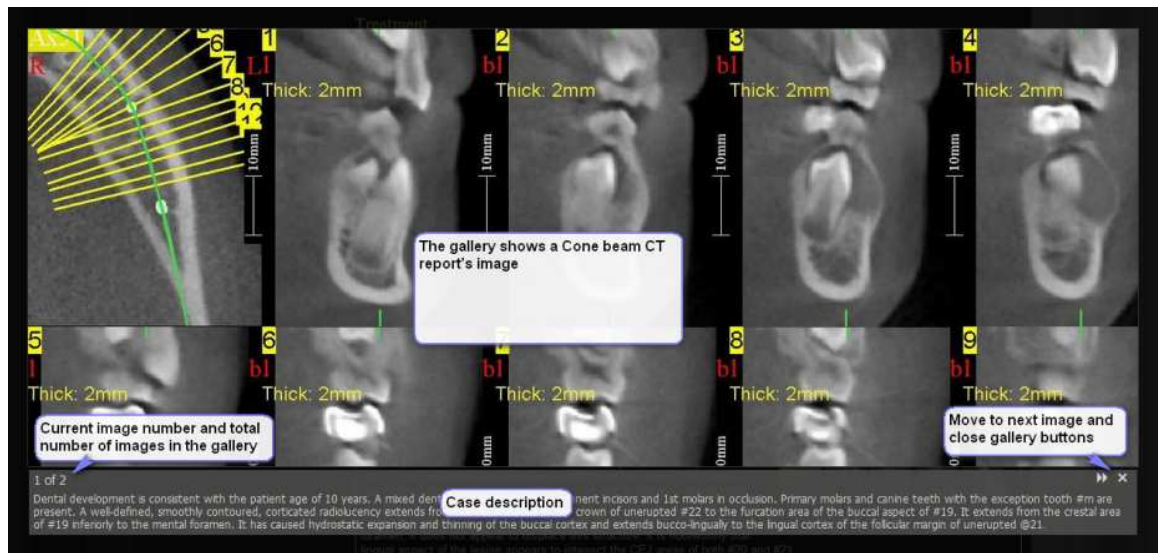






















Figure 9. Cached and non-cached pages.





[Structure Identification Test | MARCILAN | Maxillofacial Radiology ...](#)     
Home; Basics. Tour · CBCT Basics. Anatomy. Multi-Planar Correlative · Planar Sectional · Localized CT · Panoramic · Pathology ...  
[www.marcilan.com/assessment/structure-identification-test/](http://www.marcilan.com/assessment/structure-identification-test/) - [Similar pages](#) - 





[| MARCILAN](#)     
Please note that MARCILAN is not meant to be for public yet! New features are being added, modified, or deleted on daily basis. We are still experimenting ...  
[www.marcilan.com/?page\\_id=2](http://www.marcilan.com/?page_id=2) - [Similar pages](#) - 

[Cysts | MARCILAN | Maxillofacial Radiology Cone Beam CT ...](#)     
CYSTS OF THE JAWS A cyst is an abnormal cavity filled with fluid and usually lined by epithelium. Cysts gradually enlarge replacing normal tissues. Most.  
[www.marcilan.com/pathology/cysts/](http://www.marcilan.com/pathology/cysts/) - [Similar pages](#) - 

[Calcifying Odontogenic Cyst | MARCILAN](#)     
Summary Gorlin cyst. Vary from smooth well-defined and well-corticated cystic like margins to irregular margins. Uniformly radiolucent or radiolucent.  
[www.marcilan.com/pathology/benign-tumors/calcifying-odontogenic-cyst/](http://www.marcilan.com/pathology/benign-tumors/calcifying-odontogenic-cyst/) - [Similar pages](#) - 

[MARCILAN > Log In](#)     
MARCILAN. Username. Password. Login form protected by Login LockDown. Remember Me. Lost your password? ← [Back to MARCILAN.](#)  
[www.marcilan.com/wp-login.php?redirect\\_to=/](http://www.marcilan.com/wp-login.php?redirect_to=/) - 3k - [Cached](#) - [Similar pages](#) - 

[Ameloblastoma | MARCILAN](#)     
Summary Smooth and scalloped / well-defined / unilocular and Radiolucent with internal septa. Honey comb or bubble soap.  
[www.marcilan.com/pathology/benign-tumors/ameloblastoma/](http://www.marcilan.com/pathology/benign-tumors/ameloblastoma/) - 

[Central Giant Cell Granuloma | MARCILAN | Maxillofacial Radiology ...](#)     
Summary CGCG Smooth well-defined margins in the mandible to irregular ill-defined in the maxilla / unilocular and multilocular / generally not.  
[www.marcilan.com/pathology/bone-diseases/central-giant-cell-granuloma/](http://www.marcilan.com/pathology/bone-diseases/central-giant-cell-granuloma/) - 34k - [Cached](#) - [Similar pages](#) - 

Cached page in Google Index

Figure 10. User access control.

Access group name	<input type="text" value="UNC Dentistry"/> The name is used to identify the access user group.
Access group description	<input type="text" value="UNC School of Dentistry"/> The description of the group.
IP range	<input type="text" value="192.168.0.1-192.168.0.10"/> Type in the IP ranges of users which are join these groups by there IP address witho 192.168.0.1-192.168.0.10;192.168.0.20-192.168.0.30
Read access	<input type="text" value="only group users"/> The read access.
Write access	<input type="text" value="only group users"/> The write access.
Role affiliation	<input type="checkbox"/> editor <input type="checkbox"/> author <input type="checkbox"/> contributor <input type="checkbox"/> subscriber
Posts ( <a href="#">expand</a> )	<b>Contains 0 of 9 posts</b>
Pages ( <a href="#">collaps</a> )	<input type="checkbox"/> <b>Tour</b> - 2009-02-04 21:47:13 <input type="checkbox"/> <b>CBCT Basics</b> - 2009-02-04 16:21:55 <input type="checkbox"/> <b>Anatomy</b> - 2009-02-07 17:28:43 <input type="checkbox"/> <b>MPR</b> - 2009-02-05 21:31:41 <input type="checkbox"/> <b>Planar Sectional</b> - 2009-02-05 20:35:17 <input type="checkbox"/> <b>Localized CT</b> - 2009-02-05 21:03:48 <input type="checkbox"/> <b>Panoramic</b> - 2009-02-05 21:18:11 <input type="checkbox"/> <b>Pathology</b> - 2009-02-05 09:14:03 <input checked="" type="checkbox"/> <b>Cysts</b> - 2009-02-07 16:50:05 <input checked="" type="checkbox"/> <b>Residual Cyst</b> - 2009-02-12 00:02:55 <input checked="" type="checkbox"/> <b>Lateral Periodontal Cyst</b> - 2009-02-19 00:56:47 <input checked="" type="checkbox"/> <b>Simple Bone Cyst</b> - 2009-02-20 12:00:26 <input checked="" type="checkbox"/> <b>Denticulous Cyst</b> - 2009-02-07 16:50:04

## REFERENCES

1. Arnheiter C, Scarfe WC, Farman AG. Trends in maxillofacial cone-beam computed tomography usage. *Oral Radiology*. 2006 Dec 1;22(2):80-85.
2. Hatcher DC, Aboudara CL. Diagnosis goes digital. *American Journal of Orthodontics and Dentofacial Orthopedics*. 2004 Apr ;125(4):512-515.
3. Thomas SL. Application of Cone-beam CT in the Office Setting. *Dental Clinics of North America*. 2008 Oct ;52(4):753-759.
4. Araki K, Maki K, Seki K, Sakamaki K, Harata Y, Sakaino R, Okano T, Seo K. Characteristics of a newly developed dentomaxillofacial X-ray cone beam CT scanner (CB MercuRayTM): system configuration and physical properties. *Dentomaxillofac Radiol*. 2004 Jan 1;33(1):51-59.
5. Tsiklakis K, Donta C, Gavala S, Karayianni K, Kamenopoulou V, Hourdakos CJ. Dose reduction in maxillofacial imaging using low dose Cone Beam CT. *European Journal of Radiology*. 2005 Dec ;56(3):413-417.
6. White SC, Pharoah MJ. The Evolution and Application of Dental Maxillofacial Imaging Modalities. *Dental Clinics of North America*. 2008 Oct ;52(4):689-705.
7. Scarfe WC, Farman AG. What is Cone-Beam CT and How Does it Work? *Dental Clinics of North America*. 2008 Oct ;52(4):707-730.
8. Guerrero M, Jacobs R, Loubele M, Schutyser F, Suetens P, van Steenberghe D. State-of-the-art on cone beam CT imaging for preoperative planning of implant placement. *Clinical Oral Investigations*. 2006 Mar 28;10(1):1-7.
9. Loubele M, Jacobs R, Maes F, Denis K, White S, Coudyzer W, Lambrichts I, van Steenberghe D, Suetens P. Image quality vs radiation dose of four cone beam computed tomography scanners. *Dentomaxillofac Radiol*. 2008 Sep 1;37(6):309-319.



10. Howerton WB, Mora MA. Advancements in Digital Imaging: What Is New and on the Horizon? J Am Dent Assoc. 2008 Jun 1;139(suppl\_3):20S-24.
11. Wunderbaldinger P, Schima W, Turetschek K, Helbich TH, Bankier AA, Herold CJ. World Wide Web and Internet: applications for radiologists. European Radiology. 1999 Jul 15;9(6):1170-1182.
12. Achenbach S. Intranet and radiology: a critical appraisal of radiological applications of Intranet technology. European Radiology. 2002 Feb 18;12(2):485-490.
13. Willing SJ, Berland LL. A Radiology Department Intranet: Development and Applications. Radiographics. 1999 Jan 1;19(1):169-182.
14. Scarsbrook A, Graham R, Perriss R. The scope of educational resources for radiologists on the internet. Clinical Radiology. 2005 May ;60(5):524-530.
15. Hassan B, Jacobs R, Scarfe W, Al-Rawi W. A web-based instruction module for interpretation of craniofacial cone beam CT anatomy. Dentomaxillofac Radiol. 2007 Sep 1;36(6):348-355.
16. Al-Rawi W, Jacobs R, Hassan B, Sanderink G, Scarfe W. Evaluation of web-based instruction for anatomical interpretation in maxillofacial cone beam computed tomography. Dentomaxillofac Radiol. 2007 Dec 1;36(8):459-464.
17. Oreilly T. What is Web 2.0: Design patterns and business models for the next generation of software.
18. Feeney L, Reynolds PA, Eaton KA, Harper J. A description of the new technologies used in transforming dental education. Br Dent J. 2008 Jan 12;204(1):19-28.

19. Xiao N. Web 2.0 as Catalyst [Internet]. Web 2.0 as Catalyst: Virtually Reaching Out to Users and Connecting Them to Library Resources and Services. 2008 Fall ;[cited 2009 Feb 12 ] Available from: <http://www.istl.org/08-fall/article2.html>
20. Sethi S. Blog/web log - a new easy and interactive website building tool for a non-net savvy radiologist. J Thorac Imaging. 2007 May ;22(2):119, 115.
21. Lynch PJ, Horton S. Web style guide: Basic design principles for creating Web sites. Yale University Press; 2009.
22. Spool JM. Web site usability: a designer's guide. Morgan Kaufmann; 1999.
23. Burdman J. Collaborative Web development: strategies and best practices for Web teams. Addison-Wesley Professional; 1999.
24. Caldwell B, Cooper M, Reid L, Vanderheiden G. Web Content Accessibility Guidelines (WCAG) 2.0 [Internet]. Web Content Accessibility Guidelines (WCAG) 2.0 W3C Recommendation 11 December 2008. 2008 Dec 11;[cited 2009 Feb 12 ] Available from: <http://www.w3.org/TR/WCAG20/>
25. Abascal J, Arrue M, Fajardo I, Garay N, Tomás J. The use of guidelines to automatically verify Web accessibility. Universal Access in the Information Society. 2004 Mar 1;3(1):71-79.
26. Foley A, Regan B. Web design for accessibility: Policies and practice. Educational Technology Review. 2002 ;10(1):
27. White SC, Pharoah MJ. Oral Radiology: Principles and Interpretation. 5th ed. Mosby; 2003.

28. Wiegand T, Sullivan G, Bjontegaard G, Luthra A. Overview of the H.264/AVC video coding standard. *Circuits and Systems for Video Technology, IEEE Transactions on*. 2003 ;13(7):560-576.
29. Kerawalla L, Minocha S, Kirkup G, Conole G. An empirically grounded framework to guide blogging in higher education. *Journal of Computer Assisted Learning*. 2009 ;25(1):31-42.
30. Hong Chen, Ikeuchi N, Qun Jin. Implementation of Ubiquitous Personal Study Using Web 2.0 Mash-up and OSS Technologies. 2008. p. 1573-1578.
31. El Tantawi MM. Evaluation of a Blog Used in a Dental Terminology Course for First-Year Dental Students. *J Dent Educ*. 2008 Jun 1;72(6):725-735.