

**THE EFFECTIVENESS OF ORTHODONTISTS AND ORAL RADIOLOGISTS IN
THE DIAGNOSIS OF IMPACTED MAXILLARY CANINES**

Jason Thomas Herring, DDS

A thesis submitted to the faculty of the University of North Carolina at Chapel Hill in partial fulfillment of the requirements for the degree of Master of Science in the School of Dentistry (Orthodontics).

Chapel Hill
2006

Approved by

Advisor: Carroll-Ann Trotman, BDS, MS

Reader: H. Garland Hershey, Jr., DDS, MS

Reader: Andre Mol, DDS, PhD, MS

ABSTRACT

JASON THOMAS HERRING: The effectiveness of orthodontists and oral radiologists in the diagnosis of impacted maxillary canines (Under the direction of Dr. Carroll-Ann Trotman)

This study was designed to evaluate clinicians' ability to accurately diagnose maxillary canine impactions. Simulated cases of maxillary canine impaction were constructed using a human skull. Traditional radiographs and NewTom scans were obtained for each simulated case. Orthodontists and radiologists viewed and diagnosed the cases using both the traditional and NewTom images. The following diagnoses were assessed for each case: 1) Buccopalatal location of the canine, 2) Canine proximity to the lateral incisor, and 3) Presence of lateral incisor root resorption. Comparisons of diagnostic accuracy were made between the orthodontists and radiologists and between the two imaging modalities. For canine localization, radiologists outperformed orthodontists using the traditional images, but orthodontists' improved dramatically using the NewTom. For proximity and resorption, both groups of clinicians were inaccurate using the traditional images, but were significantly more accurate using the NewTom. NewTom imaging outperformed traditional radiography for all diagnostic questions.

TABLE OF CONTENTS

	Page
LIST OF TABLES.....	iv
LIST OF FIGURES.....	v
LIST OF ABBREVIATIONS.....	vi
SECTION	
I. INTRODUCTION.....	1
II. LITERATURE REVIEW.....	3
Epidemiology of Impacted Maxillary Canines.....	3
Normal Canine Development and Etiology of Canine Impaction.....	4
Sequelae and Diagnosis of Maxillary Canine Impaction.....	12
Radiographic Evaluation of Impacted Maxillary Canines.....	15
Traditional Radiographic Techniques for Impacted Canine Diagnosis.....	16
Accuracy of Canine Localization Using Traditional Radiographic Techniques.....	20
Computed Tomography Imaging of Impacted Maxillary Canines.....	24
Diagnosis of Root Resorption.....	27
Cone Beam Computed Tomography in Impacted Canine Imaging.....	34
II. MATERIALS AND METHODS.....	39
Case Simulations.....	39

Radiographic Imaging.....	43
Case Presentations.....	47
Examiners and Their Task.....	51
Protocols for Case Diagnosis.....	52
Diagnostic Questionnaire.....	55
Data Analysis.....	56
III. RESULTS.....	58
Localization Diagnosis: <i>canine crown buccal or palatal to central incisor</i>	58
Localization Diagnosis: <i>canine crown buccal or palatal to lateral incisor</i>	59
Proximity Diagnosis: <i>canine crown touching or not touching lateral incisor</i>	64
Resorption Diagnosis:	
<i>canine has resorbed or has not resorbed lateral incisor</i>	68
Traditional Imaging: Orthodontists versus Radiologists.....	68
Orthodontists: Traditional Imaging versus NewTom Imaging.....	71
Radiologists: Traditional Imaging versus NewTom Imaging.....	73
Intra-examiner Reliability.....	75
IV. DISCUSSION.....	76
Localization Diagnosis.....	76
Proximity Diagnosis.....	83
Resorption Diagnosis.....	90
V. LIMITATIONS.....	98
VI. CONCLUSIONS.....	100
VII. REFERENCES.....	101

LIST OF TABLES

Table	Page
1. Methods Table 1: Anatomical Arrangements of Case Simulations.....	42
2. Methods Table 2: Questionnaire Format.....	55
3. Results Table 1: Buccopalatal Localization Relative to Central Incisor.....	59
4. Results Table 2: Buccopalatal Localization by Orthodontic Examiner.....	61
5. Results Table 3: Buccopalatal Localization by Radiologic Examiner.....	62
6. Results Table 4: Proximity Assessment by Orthodontic Examiner.....	66
7. Results Table 5: Proximity Assessment by Radiologic Examiner.....	66
8. Results Table 6: Accuracy of Resorption Diagnosis: Traditional Imaging Modality: Orthodontists versus Radiologists.....	69
9. Results Table 7: Accuracy of Resorption Diagnosis: Orthodontist Judge Group: Traditional versus NewTom Modality.....	72
10. Results Table 8: Resorption Assessment by Orthodontic Examiner.....	73
11. Results Table 9: Accuracy of Resorption Diagnosis: Radiologist Judge Group: Traditional versus NewTom Modality.....	74
12. Results Table 10: Resorption Assessment by Radiologic Examiner.....	75
13. Discussion Table 1: Accuracy Rates of Various Localization Methods.....	81
14. Discussion Table 2: Accuracy of Root Resorption Diagnosis for Different Imaging Modalities.....	95

LIST OF FIGURES

Figure	Page
1. Methods Figure 1: Skull and Materials.....	40
2. Methods Figure 2: Mid-root Resorption.....	40
3. Methods Figure 3: Repositioning Teeth.....	41
4. Methods Figure 4: Cortical Bone Overlay.....	41
5. Methods Figure 5: Traditional Imaging Setup.....	43
6. Methods Figure 6: Example Panoramic Radiograph.....	44
7. Methods Figure 7: Example Periapical Radiographs.....	45
8. Methods Figure 8: Example Occlusal Radiographs.....	45
9. Methods Figure 9: Immersion Box.....	46
10. Methods Figure 10: Example NewTom Images.....	47
11. Methods Figure 11: Presentation Slide Example—Panoramic Image.....	48
12. Methods Figure 12: Presentation Slide Example—Periapical Images.....	48
13. Methods Figure 13: Presentation Slide Example—Occlusal Images.....	49
14. Methods Figure 14: Presentation Slide Example—NewTom 1.....	50
15. Methods Figure 15: Presentation Slide Example—NewTom 2.....	50
16. Results Graph 1: Accuracy of Buccopalatal Localization of Canine Relative to Lateral Incisor.....	60
17. Results Graph 2: Buccopalatal Localization Performance.....	63
18. Results Graph 3: Accuracy of Diagnosis of Proximity of Canine Relative to Lateral Incisor.....	64
19. Results Graph 4: Proximity Assessment Performance.....	67

20. Results Graph 5: Accuracy of Diagnosis of Root Resorption of the Lateral Incisor.....	70
21. Results Graph 6: Resorption Assessment Performance.....	70
22. Discussion Figure 1: Sample NewTom Views for Case Nine.....	87

LIST OF ABBREVIATIONS

Description	Abbreviation
Buccal.....	B
Buccal Object Rule.....	BOR
Compact Disc.....	CD
Computed Tomography.....	CT
Cone Beam Computed Tomography.....	CBCT
Digital Volume Tomography.....	DVT
Female.....	F
Field of View.....	FOV
Kilovolts.....	kVp
Male.....	M
Milliamperes.....	mA
Not Resorbed.....	NR
Not Touching.....	NT
Palatal.....	P
Quantitative Radiology.....	QR
Receiver Operating Characteristic.....	ROC
Resorbed.....	R
Same Lingual Opposite Buccal.....	SLOB
Seconds.....	sec
Thermoluminescent Dosemeter.....	TLD

Three Dimensional.....	3D
Third Generation.....	3G
Touching.....	T
University of North Carolina.....	UNC

I. INTRODUCTION

Ectopic eruption and impaction of the permanent maxillary canines is a significant problem of dental development, affecting an estimated 1-3% of the general population or more than 50,000 orthodontic patients in the United States each year.¹ Radiographic examination plays an important role in the planning of surgical and orthodontic treatment to resolve canine impactions. Radiographic information is used to determine the relative buccopalatal positions of impacted canines and adjacent incisors, as well as the proximity of the teeth to one another. Accurate knowledge of these spatial relationships is needed to assess the feasibility of reducing the impaction and to plan the surgical approach and orthodontic mechanics to minimize risks of iatrogenic injury and maximize the efficiency of tooth movement. In addition, radiographic examination should detect pathologic conditions, including incisor root resorption, because such findings may influence the treatment plan.

Orthodontists have a responsibility to ensure that the radiographic techniques they employ provide accurate and reliable information, especially when that information is used to plan a combined surgical and orthodontic intervention.² Traditionally, panoramic radiographs and parallax series of intraoral films have been used to diagnose impacted maxillary canines, but research has shown that the use of these traditional views can be problematic with regard to accuracy of buccopalatal localization and detection of incisor root resorption. Evidence suggests that even the best traditional methods of buccopalatal localization result in a misdiagnosis of canine position once in every six to twelve cases. In addition, researchers have found that traditional radiographic diagnosis may grossly

underestimate the prevalence and severity of incisor root resorption in association with impacted canines. Modern computed tomography (CT) imaging modalities provide accurate, three-dimensional anatomical detail and have been shown to hold diagnostic advantages over traditional radiographs for impacted canine diagnosis. However, the high costs and high radiation doses associated with conventional CT have ruled out its routine use for impacted canine imaging. At this time, the scientific literature supporting the use of new, lower dose, cone beam CT applications for impacted canine imaging remains relatively underdeveloped.

This study was designed to evaluate the ability of orthodontists and oral radiologists to accurately diagnose simulated cases of maxillary canine impaction using a series of traditional radiographic images and a series of cone beam CT images. Ten, anatomically different case simulations of maxillary canine impaction were constructed by rearranging teeth within a dry human skull. Each case was imaged with a panoramic radiograph, tube-shift pairs of periapical and occlusal radiographs, and a NewTom 3G scan. Eleven orthodontists and six oral and maxillofacial radiologists were recruited to diagnose the cases, first from the traditional radiographs and then from NewTom 3G images. Identical questionnaires were used to record the clinicians' diagnoses of the following: buccopalatal location of canines relative to adjacent incisors; the presence of contact between the canine and lateral incisor; and the presence of root resorption of the lateral incisor for the two imaging modalities. The accuracy of the observers' diagnostic impressions was evaluated by comparing their responses to the known actual anatomy of the dry skull simulations, and inter-group and inter-modality comparisons were made.

II. LITERATURE REVIEW

Epidemiology of Impacted Maxillary Canines

Ectopic eruption and impaction of the permanent maxillary canines during dental development is a significant clinical problem in orthodontics. A tooth is considered impacted when its eruption is delayed and it is not expected to erupt completely based on clinical and radiographic findings.^{3,4} Maxillary canines are the most frequently impacted teeth after the third molars. Epidemiological studies place the prevalence of maxillary canine impaction in the range of 1-3%, depending on the population studied.^{5,6,7,8,9} In classic studies, Dachi and Howell reported an incidence of maxillary canine impaction in 0.92% of a sample of almost 3900 radiographic series, and Ericson and Kurol found incidence rates of 1.7% and 1.5% of ectopically erupting maxillary canines in two separate populations of 500 and 3000 Scandinavian children, respectively.^{5,6,7} Recent studies report similar findings. For example, Thilander et al. found impaction of the maxillary canine in 1.7% of a population of over 4700 Columbian children, and an incidence of 3.3% was found by Aydin et al. in a sample of 4500 consecutive panoramic radiographs from a Turkish population.^{8,9} Translated into real numbers, these incidence rates suggest that there are about 50,000 new cases of maxillary canine impaction per year in the United States.¹

The literature also suggests that impacted maxillary canines affect females twice as much as males. Aydin et al. found a sex ratio of canine impaction incidence of M1:F1.64 in a Turkish study population of 4500 consecutive panoramic radiographs.⁸ Becker et al. found that, of 88 patients with palatally impacted canines in an Israeli sample, the number of

females was approximately 2.5 times that of males.¹⁰ Approximately 8% of cases were bilateral impactions.⁵

The position of impacted maxillary canines in the dental arch is variable, as the teeth may become impacted in the alveolus buccally, palatally, or in line with the dental arch. Palatal impaction is far more common than buccal or mid-alveolus impaction.^{7, 11} Ericson and Kuroi found 125 impacted canines in a sample of 3000 Scandinavian children and localized 55% in a palatal position, 26% in a distal position, and 19% in a buccal position relative to the root of the lateral incisor.⁷ Stellzig et al. found 84.5% palatal and 15.5% buccal canines in a study of 84 impacted canines.¹¹ Due to differences in the clinical presentations of cases with buccal versus palatal canine impaction, many researchers consider buccal and palatal canine impactions to be separate entities with distinct etiologies.^{12, 13, 14}

Normal Canine Development and Etiology of Canine Impaction

The developmental path of the permanent maxillary canine has been studied with great interest since the advent of cephalometric radiography. Broadbent studied the development of the permanent dentition in his examination of the Bolton Study records and focused on the eruption of the permanent maxillary canines and their interaction with the roots of the incisors during the “ugly duckling stage.”¹⁵ Dewel was similarly intrigued by canine development. In 1949, he wrote “No tooth is more interesting from a developmental point of view than the upper cuspid. Of all teeth it has the longest period of development, the deepest area of development, and the most devious course to travel from its point of origin to full occlusion.” In light of this difficult eruption path, he mused “with so many opportunities

in time and position for deflection from a normal course, it is surprising that the cuspid so often finds its way into a reasonably normal occlusion.”¹⁵

Investigators in recent studies have re-examined radiographs from historical longitudinal data sets to characterize and measure the normal eruption pathway of the permanent maxillary canine as well as the pathway of ectopic eruption. Coulter and Richardson tracked the yearly changes in canine position on lateral and posteroanterior cephalograms of 30 patients with normal canine eruption from ages five to fifteen years.¹⁶ The authors found that normally erupting maxillary canines follow a wavering, indirect path from their position at age five years until they reach full occlusion, consistently demonstrating a general path of vertical eruption with variations in the anteroposterior and buccopalatal directions. Eruptive movements of the canines were always downward in the vertical plane, with significant movement towards the oral cavity during every year between ages five to twelve years. In the lateral plane, movement was palatally directed prior to nine years of age, but after nine, a subsequent buccal eruptive movement brought the canines into their normal position in the arch. There was an average difference of five millimeters between the most palatal and most buccal positions of the canine tip. In the three planes of space, the canines were found to travel almost 22 millimeters from their position at five years of age to their position at 15 years of age, verifying and quantifying the long eruption path described in earlier works.¹⁶

Ectopic eruption of the permanent maxillary canines generally results in their displacement to either the buccal, or more commonly, the palatal side of the dental arch. Due to differences between the presentation of cases with buccal versus palatal canine impaction, many researchers have considered the two problems as separate entities with distinct

etiologies.^{12, 13, 14} Jacoby was among the first to suggest that buccally ectopic canines might result from an altogether different process than palatal ones.¹³ Jacoby noted that buccally positioned canines appeared to result from an arch length discrepancy in which the canines were crowded out of the dental arch and observed that many buccal canines erupted spontaneously if allowed enough time. In contrast to buccal canines, Jacoby observed that palatally ectopic canines seldom erupted spontaneously. His experience led him to dispute the idea that palatally displaced canines were caused by inadequate arch space.

In a study of 46 unerupted maxillary canines (40 palatal, 6 buccal), Jacoby examined the relationship between arch length and canine impaction by separating the palatal from the buccal canines.¹³ Jacoby found that 85% of the palatally impacted canines had sufficient space for eruption while only 1 in 6 of the buccally unerupted canines had sufficient space. He concluded that buccal ectopic eruption of the maxillary canine can be considered the result of crowding in the maxillary arch, whereas palatally impacted canines do not show the same arch length discrepancy and may even be etiologically related to excessive space in the maxillary bone.¹³ The findings of Stellzig et al. support those of Jacoby, demonstrating an arch length deficiency in only 18% of cases with palatally impacted canines in comparison with 46% of cases with buccally impacted canines.¹¹ Presently, it is generally accepted that buccal displacement of the maxillary canines is usually due to inadequate arch space and eventually results in eruption in most cases as the canines move along a path of least resistance.¹⁴

In contrast to the accepted etiology of buccally ectopic canines, controversy surrounds the etiology of palatal canine displacement. Two competing theories, the guidance theory and the genetics theory, have arisen from a growing body of evidence that palatally

impacted maxillary canines occur in association with other dental anomalies, many of which are genetically mediated.

Becker et al. recognized that lateral incisors adjacent to palatally impacted canines were often congenitally missing or of smaller than normal size.¹⁰ In a study of 88 patients with 128 palatally impacted canines, the lateral incisor associated with palatally displaced canines was absent in 5.5% of subjects, peg-shaped in 17.2% of subjects, and small in 25% of subjects. In only half of the cases was the lateral incisor adjacent to the impacted canine found to have a mesiodistal diameter larger than that of the ipsilateral lower lateral incisor. From this evidence, the Becker group concluded that missing or undersized lateral incisors adjacent to the canines create a local environment in which the canine is deprived of its usual guidance by the root of a normal lateral incisor, and the excess space opens a new course for a downward path on the palatal side.¹⁰ This concept of the etiologic process of palatal canine displacement and impaction has been termed the “guidance” theory, and the Becker group has remained its leading proponent.

Palatal canine impaction has been statistically associated with many anomalies of dental development, in addition to small and missing lateral incisors. Researchers have demonstrated significant relationships between palatally impacted canines and the following anomalies: congenital absence of teeth, including maxillary lateral incisors,^{10, 17} mandibular second premolars,^{18, 19, 20} and third molars;^{17, 19, 20} small teeth, including microform maxillary lateral incisors,^{10, 17, 18, 19} and generalized tooth size reduction;^{21, 22} delayed dental age;^{22, 23} infraocclusion of primary molars;¹⁸ and enamel hypoplasia.¹⁸ Pedigree studies have shown that palatal canine displacement and dental anomalies are heritable family traits.^{17, 24} Many authors have concluded that the evidence of these related, heritable anomalies of dental

development suggests a common genetic origin for the conditions.^{14, 17, 18, 25} A recent report of two cases of bilateral palatal canine displacement in a pair of monozygotic twin girls lends a further measure of support to a genetic etiology of palatal canine impaction.²⁶

This “genetics” theory of palatal canine etiology asserts that the reason that palatally displaced canines are frequently seen in association with dental anomalies is that the canines and the dental anomalies have a common genetic origin. Peck et al. published a review of the literature in support of genetic factors as the primary origin of most palatal displacements and subsequent impactions of maxillary canines.¹⁴ The evidence that palatal canine displacement was a genetically controlled positional anomaly was presented in five categories. First, the concomitant occurrence of palatal canine displacement with other dental anomalies was used to show that palatal canine displacement was not an isolated phenomenon. Associated anomalies included tooth agenesis, tooth size reduction, supernumerary teeth, other ectopic teeth, delayed dental development, tooth transpositions, and others, many of which have been shown to be genetically interrelated. For their second and third lines of evidence, the authors described similarities in the epidemiological characteristics of palatal canine displacement and certain dental anomalies known to be under genetic control. The prevalence rate of bilateral palatal canine impaction was shown to be similar to the bilateralism rates of hypodontia and maxillary canine-first premolar transposition. Sex differences in prevalence rates with a predominance of female occurrence were shown to be a shared characteristic of the three developmental problems. Pedigree studies that found elevated rates of palatal canine displacement and other dental anomalies among family members of patients with palatally impacted canines were presented as a fourth level of evidence of a genetic mechanism. Lastly, the authors argued that racial

differences in prevalence rates of palatal canine displacement among world populations supported the involvement of genetics in the etiology of the anomaly.¹⁴ The authors criticized earlier hypotheses of palatal canine displacement etiology and concluded that mechanical theories such as the guidance theory appeared simplistic and inadequate, offering instead a complex genetic mechanism as the explanation that fit the evidence best.

The etiology of palatal canine displacement remains controversial because neither the advocates for guidance nor those for genetics can present definitive evidence to support their theories. In response to Peck's genetics argument, Becker defended the guidance theory, stating that the same evidence presented in support of a purely genetic etiology may be used with equal effectiveness to argue the case for the guidance theory.²⁷ He wrote, "it is equally reasonable to expect certain hereditary factors, such as missing lateral incisors or late-developing roots of a small or peg-shaped lateral incisor, to deprive the relatively early arrival of the canine of...guidance, while the presence of excessive space permits it to move palatally."²⁷ While defending the guidance theory, Becker admitted that the issue remained undecided and that guidance did not explain the whole story, since palatal canine impaction was not seen to occur every time there was a missing or anomalous lateral incisor. He supposed that one of two premises was at work: either the existence of genetically determined anomalies had brought about an environmentally generated alteration in the eruption pattern of the canine or that the palatally displaced canine was genetically determined.²⁷

Subsequent research by Becker's group continued to support a local guidance mechanism in palatal canine displacement. Becker hypothesized that a common genetic origin between lateral incisor anomalies and palatal canine impaction would mean that

impactions should occur with equal frequency on either side in patients with a missing lateral incisor on one side and a microform lateral incisor on the other. Nineteen cases affected by lateral incisor agenesis on one side, a small or peg-shaped lateral incisor on the other side, and a palatally displaced canine were found in a population of approximately 12,000 consecutively treated Israeli patients, and a study was designed to test the left/right distribution of palatally impacted canines in the sample. The results showed that the canine impactions occurred far more frequently on the side of the diminutive lateral incisor than on the side of the missing lateral incisor, leading the authors to conclude that an environmental factor related to tooth size was involved in the palatal displacement of maxillary canines.¹²

Meanwhile, other researchers have produced additional lines of evidence of the involvement of a genetic mechanism in palatal canine impaction. McSherry and Richardson²⁸ repeated the study of Coulter and Richardson¹⁶ to characterize the eruption path of palatally ectopic canines. Using records from the same longitudinal growth study population, the authors identified 15 cases in which one or both maxillary canines remained unerupted in study models at 15 years of age. In all, 20 palatally impacted canines were found, and serial lateral and posteroanterior cephalograms were traced to demonstrate yearly changes between the ages of five to fifteen years old.²⁸ The annual changes from the palatal ectopic eruption sample were compared with those observed for the normally erupting canines from the previous study. In the vertical plane, the occlusally directed eruption of the ectopic canines was found to be less than normal, accounting for the high position of the canines impacted in the palate. The most remarkable findings of the study were seen in the lateral plane. The serial tracings revealed that the average palatally ectopic canine always moved in a palatal direction, never showing the buccally directed movement seen in normally erupting canines

between the ages of ten and twelve years old. Palatal impaction of the ectopic canines was judged to be the result of a continual and consistent eruptive movement in a palatal direction and a lack of the late buccal eruptive movement seen in normal canines.²⁸ The authors noted that differences between normal and ectopic canines in the lateral plane of space were present from as early as five to six years of age and continued throughout the growth period. They concluded that this finding may indicate a genetic origin for palatally ectopic canines because the positional abnormality existed at a stage of dental development before any mechanical guidance from the developing incisor roots would be expected.²⁸ No mention was made by the authors of the size or presence of lateral incisors adjacent to the palatally impacted canines in the study.

Thus, the literature is inconclusive about the etiology of palatal ectopic eruption and impaction of the maxillary canines. Generous amounts of data have been offered in support of both the guidance theory and the genetics theory, and, while the evidence pointing to the involvement of a genetic mechanism in palatal canine displacement appears compelling, one may not dismiss the possibility that the genetically mediated dental anomalies commonly seen in cases of palatal impaction create a local environment that encourages or facilitates an ectopic path of eruption. The evidence supports the conclusion that both mechanisms probably play an etiologic role in palatal canine displacement at some level and suggests that a combined theory, encompassing genetic and guidance mechanisms together, may represent the most comprehensive explanation of palatal ectopic eruption of maxillary canines.

Sequelae and Diagnosis of Maxillary Canine Impaction

Dentists consider the permanent maxillary canines to be the cornerstones of the dental arch due to their great functional and esthetic importance to the occlusion and the smile. As a result of their high functional and esthetic value, malpositioning and noneruption of the canines represent significant sequelae of their ectopic eruption and impaction.^{29, 30} Patients with impacted canines are perceived by orthodontists to be more difficult to treat than average patients and have been shown to require a longer time in treatment than controls, with unilateral impacted canines adding three months to the average duration of treatment and bilateral impacted canines adding ten months.³¹ In addition, ectopic eruption of the canines may cause damage to the roots of neighboring teeth. External resorption of incisor roots in association with impacted canines has been demonstrated with alarming frequency and severity.^{7, 32, 33, 34, 35, 36, 37} More rarely, premolars have been affected by canine-induced external root resorption.^{37, 38} Internal resorption of the canine, cystic degeneration of the canine follicle, infection and referred pain have also been reported as consequences of canine impaction.³⁰ On the other hand, the presence of an impacted maxillary canine may cause no complications to an individual over the course of their lifetime.³⁰

The potential complications involved with ectopic canine eruption mandate that erupting maxillary canines be monitored from an early age to diagnose any deviations from a normal eruptive course as soon as possible. Early diagnosis of ectopic eruption is advantageous because early treatment, such as extraction of the primary canine, may stimulate a spontaneous correction in the eruption path of the permanent canine.^{39, 40, 41} Various authors have reported that periodic examination, including visual inspection and intraoral palpation of the canine region, should be performed for patients beginning around 8-

10 years of age, with individual variations depending upon the degree of dental development.^{1, 42, 43} Individual variations in dental development may be significant, with as much as 5-6 years difference in eruption timing between a precocious girl and a late developing boy.^{1, 44} The following clinical signs have been suggested as possible indicators of canine impaction: delayed eruption of the permanent canine or prolonged retention of the deciduous canine; absence of a normal buccal canine bulge; presence of a palatal bulge; and delayed eruption, distal tipping or a splaying migration of the lateral incisor.³⁰

The bulge of the erupting canine is normally palpable high in the buccal vestibule about 18 months before oral eruption, and the presence of such a palpable canine bulge has been found to signify a favorable eruption position.^{1, 42, 44} Palpation should be done bimanually, with the index fingers of both hands simultaneously palpating both the buccal and palatal aspects of the alveolus above the primary canine root.⁴² The absence of a palpable canine bulge at the age of 9-10 years old, and especially an asymmetry in palpation findings, should raise suspicion of an eruption disturbance of the permanent canine, and the presence and position of the canine should be confirmed with radiographs.^{6, 42, 44}

The likelihood of a nonpalpable buccal canine bulge decreases between ten and twelve years of age, however, the probability that the lack of a canine bulge signifies an eruption disturbance increases with age. In a study of 505 longitudinally studied Swedish children, Ericson and Kurol found that 29% of ten year-old children had non-palpable canines bilaterally, while the corresponding figure in eleven year-old children was five percent, and the prevalence of nonpalpable canines in the age group 11-15 years was three percent. These results showed that younger children with a potential for ectopic eruption may later produce a correct eruption path,⁴⁴ which is in agreement Coulter and Richardson's

findings of a late buccal movement in normal canine eruption.¹⁶ Ericson and Kurol concluded that the lack of a palpable buccal canine bulge was not necessarily problematic up to age ten years, but in children eleven and older, an inability to palpate the canine strongly indicated a disturbance of eruption. In addition, they found that a right/left difference in palpation was a strong indication of aberrant eruption in children older than ten years of age.^{6, 44}

Radiographic evaluation of the erupting canine is indicated when clinical findings suggest a potential eruption disturbance. Ericson and Kurol advised radiographic examination if: 1) asymmetry on palpation or a pronounced difference in eruption of canines was present between the left and right side, 2) the canines could not be palpated in the normal positions and occlusal development was advanced, warranting suspicion of an abnormal path of eruption, or 3) the lateral incisor was late in eruption or showed a pronounced displacement.^{6, 7} The goals of radiographic examination should be to determine the three-dimensional position of the unerupted canines and their relationship to adjacent teeth, to assess the health of the neighboring roots and to consider the prognosis and the best mode of treatment for resolution of the situation.³ Diagnosis of an ectopic position early in the canine's eruptive path allows interceptive treatment at a time when it is most likely to be effective and the possibility of damage to adjacent roots caused by the canine is minimized. For established impacted canines that are diagnosed too late for interceptive treatment, radiographic assessment plays an essential role in determining the following: 1) the feasibility of orthodontic alignment and the proper vector for application of orthodontic forces, 2) the proper access for a surgical approach to the canine and the likely difficulty of exposure or extraction, and 3) the extent of root resorption of neighboring teeth.^{30, 45}

Radiographic Evaluation of Impacted Maxillary Canines

Radiographic imaging protocols for viewing unerupted maxillary canines have varied greatly since the advent of dental radiography. The protocols have changed as a result of expanded definitions of the diagnostic requirements of radiographic images for impacted canine cases, as well as improved capabilities of imaging modalities available to the clinician. Historically, assessment of the presence and location of unerupted canines has been the primary goal of radiographic examination, and this remains so today. Many methods for canine localization using traditional dental radiographs have been described in the literature, including tube-shift intraoral radiographs,^{46, 47, 48} two extraoral projections at right angles,³⁹ and magnification in panoramic radiographs.^{49, 50, 51, 52} These traditional methods have been shown to be accurate for localization of canines in most cases, but limitations have been found in their ability to clearly depict the complex anatomy of some impactions.^{2, 7, 51, 52, 53} In addition, recent studies using three-dimensional imaging modalities have shown that traditional radiographs may fail to reveal root resorption in incisors adjacent to impacted canines in an alarming number of cases.^{7, 32, 34, 37}

As a result of growing concerns about incisor root resorption, the scope of information required for diagnosing impacted canines has broadened considerably to encompass far more than canine localization. In a recent article, Chaushu et al. proposed that, for an orthodontist to be in a position to recommend the best line of treatment for an impacted tooth, the following information is required: 1) the exact positions of the crown and root apex of the impacted tooth and the three-dimensional orientation of its long axis, 2) the proximity of the impacted tooth to the roots of adjacent teeth, 3) the presence of any pathologic entities in association with the impacted tooth and their spatial relationship with

the impacted tooth, 4) the presence of adverse conditions affecting the adjacent teeth, including root resorption, and 5) the three-dimensional anatomy of the crown and root of the impacted tooth.⁵⁴ Interest in the use of computed tomography (CT) modalities for canine imaging has increased as clinicians have perceived a greater need for three-dimensional anatomical information, and clinical studies have shown that CT imaging offers advantages over plain film radiography in the diagnosis of canine location,⁵⁵ canine root and crown anatomy,^{45, 56, 57} canine proximity to adjacent teeth,^{55, 56, 58} and root resorption of adjacent teeth.^{34, 37, 55, 58, 59} The diagnostic benefits of CT imaging come with an increased burden to the patient of higher radiation risk and monetary cost. Therefore, considerations of effectiveness and efficiency play a major role in an orthodontist's decision of which radiographic imaging modality to prescribe for patients.^{55, 56} Clinicians must weigh the quality and benefit of the diagnostic information provided by the imaging modality against the costs of the exposures in terms of money and radiation risk.

Traditional Radiographic Techniques for Impacted Canine Diagnosis

A series of radiographs that includes a panoramic view and a pair of intraoral views for parallax localization represents the traditional or standard approach for the diagnosis of impacted maxillary canines. Southall and Gravely surveyed 312 British orthodontists and oral surgeons to assess their habits in prescribing radiographs for patients with impacted maxillary canines.⁶⁰ Sixty-eight percent of the clinicians responded to the survey describing a wide range of radiographic prescriptions. The authors found that one panoramic radiograph was commonly taken for a general view and to estimate the height of the canine, and two additional intraoral views were obtained for parallax localization of the canine's buccopalatal

position.⁶⁰ Panoramic radiographs provide a fast, qualitative overview of the teeth and jaws and are often used as a screening tool in orthodontic consultations to determine the need for additional radiographic views.⁶¹ Intraoral radiographs such as periapical and occlusal views provide greater anatomical detail than panoramic radiographs, and a “tube-shift” pair or series of intraoral radiographs taken at different beam angulations can be used to localize unerupted canines using the principle of parallax.^{48, 61} Panoramic radiographs may also be useful for localization of ectopic canines because the beam geometry of panoramic imaging causes malposed teeth to appear distorted in size and position relative to well-aligned teeth, giving an indication of their buccopalatal position in the dental arch.^{48, 51}

Parallax localization methods using a series of “tube-shift” intraoral radiographs were described as early as 1909 and are still advocated today.^{46, 47, 48} Parallax is the apparent change in the position or direction of an object when it is observed from two different points of view.(Merriam Webster) Radiographic localization using parallax involves comparing two or more radiographic projections of the same anatomy made at different angulations of the X-ray beam. Changes in the radiographic position of imaged objects between the different projections are evaluated to determine the true position of the objects in relation to one another and to the X-ray source.⁴⁸ The rules of parallax localization state that the image of the tooth that is nearer to the X-ray source, which is the buccal tooth for all intraoral views, moves in the same direction as the change in the beam angulation, and the image of the tooth that is farther from the source, i.e. palatal, moves in the opposite direction as the change in beam angulation. This is called the Buccal Object Rule, because the buccal object moves in the same direction as the change in beam angulation.⁴⁷ Written another way, objects farther from the X-ray source, i.e. palatal objects for intraoral views, will be seen to

move in the same direction as the movement of the X-ray tube head while objects nearer to the source, or buccal, move in the opposite direction as the tube. This is known as the S.L.O.B Rule—Same Lingual, Opposite Buccal. These two “rules” describe the same parallax effect, because the change in beam angulation is always opposite in direction to the movement of the X-ray tube head.

Tube-shift parallax localization is usually applied in the horizontal dimension by viewing the changes between a pair or series of periapical images made with the x-ray tube head moving horizontally around the dental arch.^{62, 63} The method may also be applied by observing changes in the vertical positions of objects in periapical, occlusal, and even panoramic images.⁴⁷ The periapical and occlusal radiographs used for parallax localization are readily available in dental clinics and low in cost and radiation risk to patients.⁶³ Tube-shift methods are familiar to dentists and have been shown to be reasonably accurate in buccopalatal localization of unerupted canines.^{2, 53} The key disadvantage of parallax localization is that the method does not clearly demonstrate the proximity of imaged objects to one another. Although the method allows clinicians to determine if the canine is buccal or palatal to a reference tooth, it does not indicate how close together the teeth are.⁶³

Panoramic radiographs are the primary diagnostic images in orthodontics, routinely prescribed as part of a patient’s initial evaluation to screen for pathology and to assess dental development. It would be advantageous to clinicians and patients alike if this single film could reliably be used for accurate buccopalatal localization of unerupted teeth.⁵¹

Buccopalatal localization using image magnification in panoramic radiographs is possible based on the radiographic principle that objects which are closer to the film cast a smaller shadow than objects farther from the film.⁵¹ Due to the imaging geometry of panoramic

machines, in which the film cassette is positioned extraorally and the x-ray beam is projected from behind and below the anatomy of interest, image acquisition in dental panoramic tomography results in relative magnification of objects located palatal to the focal trough and relative shrinkage of objects buccal to it.⁵⁰ In theory, then, a palatally positioned unerupted tooth should appear larger in a panoramic projection than its well-aligned contralateral mate, while a buccally positioned unerupted tooth should appear smaller.⁵¹ Parallax effects of the beam geometry in panoramic radiography also may provide clues to the buccopalatal location of unerupted teeth. According to the rules of parallax localization, the sweeping movement and postero-inferior position of the x-ray source should project palatally positioned objects superiorly and distally relative to objects in line with the arch because palatal objects are nearer to the source. Conversely, the beam geometry should project buccally positioned objects inferiorly and medially due to their being farther from the source.⁵¹

Gavel et al. constructed an in vitro simulation to test the effect of tooth position on the image of unerupted canines in panoramic radiographs.⁶⁴ In the study, a positioning jig was used to vary the buccopalatal location and inclination of one canine in the maxillary arch of a dry skull with well-aligned teeth. Panoramic radiographs of the simulation were made at different canine locations and measurements were made from the radiographs to compare the size and position the of the malposed canines to that of well-aligned canines in the images.⁶⁴ The results showed that, in comparison to well-aligned contralateral canines, buccally positioned canines appeared shorter in length but the same width and were shifted toward the midline and at the same vertical position. Palatally displaced canines appeared the same length but wider than contralateral canines and were shifted away from the midline and vertically higher above the occlusal plane.⁶⁴

Clinical studies that have tested the reliability of localizing impacted canines on the basis of one panoramic radiograph have found results ranging from poor to promising.^{7, 49, 50, 51, 53} The main disadvantages of using panoramic magnification for localization of unerupted maxillary canines are that poor patient positioning and dental malalignment can lead to incorrect interpretation of the position of the canine from the images.⁴⁸ Also, similar to parallax methods of localization, assessment of how far to the buccal or palatal an impacted canine is positioned relative to neighboring teeth is difficult to determine with the panoramic magnification technique.

Accuracy of Canine Localization Using Traditional Radiographic Techniques

Studies of the accuracy of maxillary canine localization using tube-shift and panoramic magnification techniques have yielded a range of results, with some authors reporting reasonably good success with the techniques and others reporting poor performance. In their study of 125 ectopically erupting canines, Ericson and Kurol compared the accuracy of assessment of canine position among three radiographic methods—conventional periapical X-ray films, axial vertex X-ray films, and orthopantograms.⁷ Localization diagnoses were made from each of the three modalities separately, and the “gold standard” true position of the canines for the study was established by combining the information from all of the radiographic methods. The authors found that the positions of the canines relative to the adjacent incisors could be assessed accurately in 92% of the cases using periapical X-rays, in 72% of the cases using axial vertex occlusal X-rays, and in only 29% of the cases using panoramic radiographs.⁷ Thus, periapical radiographs were found to

be quite accurate in diagnosing canine position, while panoramic radiographs were found to be unreliable.⁷

Mason et al. compared the accuracy of two methods of impacted canine localization in a sample of 133 impacted canines (87 palatal, 38 buccal) in 100 patients.⁵³ Six examiners from different dental specialties diagnosed canine position, first using a vertical parallax technique between a panoramic radiograph and an anterior maxillary occlusal radiograph and then using the panoramic radiograph alone. The gold standard for canine location was the true position of the canine found during exposure surgery as recorded in the operative notes. The results of the study showed a wide variation in agreement between the true and predicted canine position from both localization techniques. No significant difference was found in the performance of the two modalities, but neither modality was particularly successful in localizing canines. Seventy-six percent of impacted canines were successfully localized using vertical parallax and 66% using panoramic magnification.⁵³ Buccally impacted canines were difficult to localize using either technique. Both parallax and magnification accurately located almost 90% of the palatally impacted canines, but buccal canines were correctly localized only 46% of the time using vertical parallax and 11% of the time using magnification. The authors concluded that both techniques were unsatisfactory in the localization of buccal canines.⁵³

Armstrong et al. compared the diagnostic accuracy of two parallax techniques for localizing unerupted maxillary canines.² Thirty-nine subjects with 43 impacted maxillary canines (34 palatal, 9 buccal) received a panoramic radiograph, an anterior occlusal radiograph, and a periapical radiograph of each canine. The panoramic and occlusal radiographs were used as a vertical parallax pair, and the occlusal and periapical radiographs

were used as a horizontal parallax pair. Six experienced orthodontists evaluated the impacted canines using both radiographic techniques and classified the position of as buccal, palatal, in line with the arch, or unsure. The true position of the canine upon surgical exposure was used as the gold standard for comparison. The results of the study showed horizontal parallax to be superior to vertical parallax for localizing impacted canines. A significant difference was found between the techniques in the mean proportion of correct diagnoses, with 83% correct using horizontal parallax and 68% correct using vertical parallax.² Horizontal parallax was significantly more successful than vertical parallax for localizing palatal canines, that is, for palatal canines, the sensitivity of horizontal parallax was 88% while the sensitivity of vertical parallax was 69%. The two techniques performed equally poorly for localizing buccal canines, with identical sensitivity scores of 63%. The authors expressed concern that more than one-third of buccally ectopic maxillary canines would be misdiagnosed with either technique, reinforcing the findings of Mason et al. that localization of buccal canines with traditional radiographic techniques represents a considerable diagnostic challenge.²

Fox et al. studied the validity of using magnification effects in a single panoramic radiograph for locating palatally ectopic maxillary canines.⁵⁰ The sample included 139 ectopic canines from 100 patients. The authors used a vertex occlusal radiographic view as the gold standard for comparison, which they admitted was not as good as the use of surgical evidence. However, the authors argued that the strict selection criteria used in the study helped to ensure that the vertex occlusal view provided clear information about the relationship of the unerupted tooth to the dental arch. The study found a sensitivity of 82% for accurately predicting a palatal location of the canine crown, meaning that 82% of palatal

canines showed an enlarged image on the panoramic radiograph. The specificity was found to be 78%, meaning that 78% of normal canines showed a normal image on the panoramic radiograph. The authors concluded that approximately four out of five palatal canines can be detected from the panoramic radiograph, and at best, magnification of the images of unerupted canine crowns on panoramic radiographs could be used as an imperfect guide to position.⁵⁰

Chaushu et al. developed an improved method of localizing displaced maxillary canines from a single panoramic film by accounting for the vertical position of canines in panoramic images when using magnification effects to determine buccopalatal position.⁵¹ The authors measured the mesiodistal widths of impacted canines, ipsilateral central incisors, and contralateral canines in panoramic radiographs of 113 subjects with 160 displaced maxillary canines. Ratios of canine to incisor and canine to canine widths were constructed. The vertical position of the impacted canines was classified based on which zone of the lateral incisor root, apical, middle, or coronal, the canine crown overlapped. The true position of the impacted canines was defined according to findings upon surgical exposure. Then, the distribution of the palatally and buccally displaced canines was analyzed to determine which combinations of vertical position and width ratios were associated with palatal and buccal canine position in order to construct a diagnostic algorithm. The authors determined cutoff values for the width ratios that indicated whether a tooth at a given vertical position was buccal or palatal. Using these cutoff values, they found that accurate diagnosis of canine location was possible in 87.5% of all of the cases in the sample. The technique was 100% accurate for localizing canines in the coronal and middle vertical zones, but the anatomy of the anterior maxilla made localization of teeth in the apical zone unreliable. The

authors concluded that a single panoramic radiograph was adequate for determining the buccopalatal location of an impacted maxillary canine in approximately 88% of cases, and that additional radiographic views were required for accurate localization of canines seen to overlap the apical third of adjacent incisor roots in panoramic radiographs.⁵¹

In summary, the scientific literature demonstrated that traditional methods of radiographic localization were somewhat effective for diagnosing the buccopalatal position of impacted maxillary canines, but the accuracy of the traditional methods left considerable room for improvement. Horizontal parallax techniques with periapical and occlusal radiographs outperformed other traditional localization methods but still resulted in misdiagnosis of canine position once in every six² to twelve⁷ cases. Vertical parallax methods using panoramic and occlusal radiographs were found to be less accurate, with a misdiagnosis in one in three² to one in four⁵³ cases. A wide range of accuracy rates were reported for using a single panoramic radiograph to localize canines, with misdiagnosis rates ranging from approximately seven in ten⁷ to one in nine⁵¹ cases. Parallax and panoramic localization techniques both performed poorly for localizing buccally positioned canines.^{2, 53}

Computed Tomography Imaging of Impacted Maxillary Canines

Recently, the use of computed tomography (CT) scanning has been proposed as a new modality for defining the exact position of an impacted tooth.^{54, 61} Multiplanar and three-dimensional (3D) reconstruction of the scanned anatomy can accurately demonstrate the relationship of the impacted tooth to adjacent teeth and structures in three planes of space, showing the position of the crown and apex of the impacted tooth, as well as the inclination of its long axis.^{54, 58, 61} CT eliminates the superimposition of structures that often obscures

visualization of overlapped objects in two-dimensional (2D) plain film radiography and provides anatomical detail in sufficient clarity to allow accurate assessment of the proximity of impacted teeth to adjacent roots, even showing contact between the structures.^{37, 54, 55, 56, 58} Furthermore, CT imaging has been shown to demonstrate resorption of incisor roots adjacent to impacted canines better than traditional radiographs.^{34, 37, 54, 55, 58, 59} Initial forays into the use of computed tomography imaging for impacted canine diagnosis were made using conventional, fan beam, helical CT units, which were originally developed for medical, not dental, diagnostic use.⁶⁵ The problems in adapting helical CT scans for dental use include high cost, large space requirement, long scanning time and, most notably, high radiation exposure.⁶⁵ The high monetary and radiation dose costs of helical CT have led many authors to conclude that, despite its excellent diagnostic yield, the modality is seldom justified for impacted canine patients and should be reserved for complex cases in which conventional radiography fails to describe adequately the anatomical situation.^{55, 56, 61}

The advent of cone beam computed tomography (CBCT) technology and the development of digital volume tomography machines for dedicated dental use have produced an innovative diagnostic modality that provides 3D imaging information at a much lower cost and radiation dose than conventional, helical CT.^{66, 67} Conventional CT uses a narrow, fan-shaped X-ray beam to acquire volumetric data through a series of rotational scans around the patient, losing efficiency on every axial slice where the edges of the beam exceed the boundaries of the detector.⁶⁸ In contrast, CBCT makes efficient use of a cone-shaped X-ray beam to generate volumetric data in a single, rapid, 360 degree scan of the patient.^{67, 68} The volumetric data acquired by the scan is reformatted through a series of algorithmic reconstructions on a personal computer. Clinicians may use the software to generate axial,

coronal, and cross-sectional slices of the scanned anatomy, as well as pseudopanoramic and 3D views.^{67, 68} Research has demonstrated that reconstructed images from CBCT scans are free of geometric distortion and highly accurate for linear measurements between dentofacial anatomical sites in all three planes of space.^{67, 69, 70} The main drawbacks of the cone beam technique are increased noise from scatter radiation and a resultant loss of contrast resolution relative to conventional CT.⁶⁸

Dosimetry studies have demonstrated that the effective dose of radiation absorbed during a cone beam CT examination compares favorably with conventional CT examination and is in the range of radiation doses routinely observed in dentistry. Ludlow, et al. measured the radiation dose absorbed in thermoluminescent dosimeter (TLD) chips placed at 20 sites in a tissue-equivalent phantom during a full field of view scan using a NewTom QR-DVT 9000 cone beam unit and an Orthophos Plus DS panoramic unit. The effective dose of the combined maxillomandibular NewTom scan was found to be 39.6 microseiverts $E_{(ICRP 1990)}$, a value equivalent to approximately one percent, or three and one-half days, of the annual per capita background radiation dose of 3600 microseiverts in the United States.⁶⁸ Comparisons were made between the effective dose findings of the study and those from other published dosimetry studies in the literature. The results showed that a NewTom CBCT scan appears to have three to seven times the radiation risk of a panoramic examination, depending on the area examined, the degree of collimation and the acquisition software version.⁶⁸ In a similar study which also used TLD chips in a tissue-equivalent phantom, Mah, et al. found that the total effective dose of a full field of view NewTom scan equaled 50.3 microseiverts $E_{(ICRP 1990)}$.⁷¹ The authors compared their findings of tissue absorbed doses in NewTom examination to those published by other dosimetry studies and

noted that, in certain tissues, the absorbed doses from a full-mouth series with D-speed film can approach and exceed those generated during a NewTom CBCT examination.⁷¹

A very recent dosimetry study by Ludlow et al. found that the NewTom 3G device yielded the lowest effective dose for a full field of view (FOV) scan among three commercially available large (9-12”) FOV CBCT units.⁷² The effective dose for the NewTom 3G scan was found to be 44.7 microseiverts $E_{(ICRP\ 1990)}$ and 58.9 microseiverts $E_{(ICRP\ 2005)}$. The effective dose for the i-CAT was found to be 1.5 to 1.8 times greater than the NewTom 3G at 69.4 microseiverts $E_{(ICRP\ 1990)}$ and 104.5 microseiverts $E_{(ICRP\ 2005)}$, and the CB Mercuray was found to yield 9.7 to 11 times the dose of the NewTom at 487.1 microseiverts $E_{(ICRP\ 1990)}$ and 568.8 microseiverts $E_{(ICRP\ 2005)}$. The full FOV doses from the dental CBCT units in the study were 2% to 23% of the dose of comparable conventional CT examinations reported in the literature. The authors placed the NewTom dose in perspective by stating that the most common full mouth radiographic examination in dentistry, using D speed film and round collimation, utilized a dose of 150 microseiverts, about three times greater than the dose of the NewTom 3G exam. Smaller FOV examinations were associated with significant dose reductions, which may apply to impacted canine imaging since a single jaw can readily be imaged by a 6” FOV scan.⁷²

Diagnosis of Root Resorption

One of the areas of impacted canine diagnosis in which computed tomographic imaging has proven especially useful is in the assessment of resorptive damage to incisor roots caused by ectopic canine eruption. Traditional panoramic and intraoral radiographs, as planar, two-dimensional imaging modalities, are inherently limited in their illustration of

three-dimensional anatomy. One such limitation is that overlapped anatomical structures appear superimposed in traditional, planar projections. In the diagnosis of ectopic canines, overlapping of the canine crown and incisor roots makes it exceedingly difficult to determine their proximity to one another and obscures detection of incisor root resorption.

Ericson and Kurol were among the first researchers to study the consequences of this limitation of traditional radiography with regard to ectopic canines.⁷ From a sample of almost 3000 Scandinavian children, the authors identified 84 children with radiographic signs of ectopic eruption of 125 maxillary canines, and a stepwise radiographic protocol was used to evaluate the position of the canines and identify the number, location and extent of incisor resorptions. To overcome the problem of superimposed anatomy in panoramic and intraoral radiographs, the authors prescribed a series of conventional tomograms for cases in which intraoral techniques failed to project the lateral incisor free from overlap with the canine. The series of tomograms was found to be necessary in 45% of all cases and in 63% of cases with truly ectopic canines, meaning that panoramic and intraoral radiographs failed to rule out incisor root resorption in almost half of all cases and nearly two-thirds of cases with ectopic canines. Thus, overlapping of the canine with the lateral incisor was found to be a common problem with intraoral radiography.⁷ The study showed that the series of conventional tomograms reproduced root resorptions more fully than panoramic and intraoral projections and also revealed new lesions that were unseen in the other radiographs. Use of the tomographic series doubled the number of teeth with diagnosed resorptions and gave a more reliable indication of the extent of the lesions compared to intraoral films and panoramic radiographs. In all, 12.5% of ectopic canines were found to have caused some

degree of resorption of adjacent incisors. This figure was considerably higher than previous estimates of the frequency of incisor resorption due to ectopic canine eruption.⁷

Ericson and Kurol followed up their first conventional tomography study of ectopic canines with a second study that aimed to analyze the location and extent of incisor root resorptions associated with ectopic canines.³² From their first study, they had learned that the radiographic modality used for visualization of ectopic canines played a significant role in what was diagnosed, especially with regard to resorption of incisors. For the next investigation, the authors studied a sample of 41 consecutive cases with radiographic evidence of resorptions in 47 teeth—six central incisors, 40 laterals, and one bicuspid. The stepwise radiographic protocol from the first study was repeated, and the series of conventional tomograms was necessary in 36% of the cases. The results of the study showed that 82% of the resorptions were in the middle vertical third of the incisor roots, and buccal and palatal resorptions were commonplace. The buccal and palatal mid-root location of the lesions was proposed as an explanation of why so many resorptions escaped detection with routine radiographic techniques.³² One third of the resorbed laterals in the sample had a normal appearance on periapical radiographs, and the extent of resorption could only be assessed adequately with the tomographic series in 40% of the sample. Of particular concern was the finding that over half of the resorbed teeth—19 of 40 lateral incisors and five of six central incisors—showed advanced resorption, in which the resorption cavities extended into the pulps of the teeth.³²

As a result of the conventional tomography studies, Ericson and Kurol concluded that resorption on the roots of the maxillary incisors was difficult to diagnose on intraoral and panoramic radiographs, especially when the dentin loss was located buccally or palatally.³⁴

The overlapping of anatomical structures and the extent of resorption cavities relative to the thickness of roots were found to contribute to a situation in which even resorptions into the pulp of incisors were overlooked on intraoral films.³⁴ Though the series of conventional tomograms was shown to be superior to panoramic and intraoral radiography for demonstrating root resorption, the authors noted deficiencies in conventional tomographic images that led them to suspect that underestimation of incisor resorptions was likely even with the use of tomograms. Conventional tomographic images lacked sharpness and failed to blur out all overlapping structures, making it difficult to be certain of resorption diagnosis, especially when resorptions were small.³⁴ Since computed tomography (CT) eliminated the blurring problem of conventional tomography and increased the perceptibility of root resorption, the authors designed a CT study to investigate the positions of ectopic maxillary canines and to determine the prevalence and extent of incisor root resorption occurring during the eruption of the canines.

One hundred seven children with 156 ectopic canines that were difficult to assess on panoramic and intraoral films due to overlapping were selected for CT imaging of the maxillary dentition and alveolar bones.³⁴ Scans were made on a helical, fan-beam CT unit, and reconstructed images of the scanned anatomy were analyzed by the authors to document the positions of the canines and the presence and severity of resorption defects on the incisors. Relative to the roots of the maxillary incisors, the position of the main cusp of the canine was found to be buccal in 21% of cases, distobuccal in 18% of cases, palatal in 27% of cases, distopalatal in 23% of cases, apical to the lateral in 4%, apical to the central in 1%, and between the central and lateral incisors in 6% of cases. Ninety-three percent of the 156

ectopically erupting canines were in contact with the lateral incisor and 19% were in contact with the central incisor.³⁴

With regard to incisor resorption, 58 of the 152 maxillary lateral incisors (38%) and 14 of the 156 maxillary central incisors (9%) adjacent to ectopic canines showed resorptions on the roots close to the crowns of the erupting canines.³⁴ In all, 51 of the 107 subjects (48%) experienced resorption of incisors, suggesting that the injury may occur with far greater frequency than previously reported. Resorptions were most common at the age of 11 and 12 years old, but severe resorptions with pulp involvement were found as early as 9 years of age. The location and extent of the resorptions varied greatly, with mainly severe, deep resorptions. The majority of the resorptions were located in the middle and apical thirds of the incisor roots, and resorptions were found as often on the buccal as on the palatal surfaces of the incisors. Sixty percent of the resorptions on the lateral incisors and 43% of the resorptions on centrals had pulpal involvement. Highly significant correlations were shown between ectopic eruption and resorption on the adjacent incisor and between crown-root contact and resorption.³⁴

As part of the study, Ericson and Kurol examined the differences between the conventional intraoral radiographs and the CT scans when those modalities were used to diagnose root resorption on incisors adjacent to ectopically erupting maxillary canines.³⁴ All maxillary incisors adjacent to an ectopic canine with good quality images for the two modalities were grouped into categories as “resorbed” or “not resorbed.” This grouping included 180 lateral and 186 central incisors.

The results of the comparison showed that CT scans demonstrated the number and severity of incisor root resorptions more effectively than the intraoral films. Using CT

findings as the gold standard for root resorption, calculations of sensitivity and specificity values from the results showed that the sensitivity and specificity of intraoral films for demonstrating resorption of lateral incisor roots were 0.46 and 0.95 respectively. For central incisors, the sensitivity of intraoral films was 0.38 and the specificity was 0.99. Combining the lateral incisor and central incisor groups, the overall values for sensitivity and specificity of intraoral radiographs for diagnosing incisor root resorption were 0.45 and 0.98, respectively. These results suggested that intraoral radiographs may fail to demonstrate resorption when it is present more than half of the time, since in this sample the films yielded a positive test in only 45% of the cases in which root resorption had occurred. The comparison showed that the severity of the resorptions was also demonstrated better by CT than by intraoral radiographs. Of the 34 lateral incisors graded with severe, into-the-pulp resorptions on CT, only 12 (35%) were given the same grading when assessed by intraoral films, and ten (30%) severe resorptions detected by CT scanning were not discovered at all in the conventional images.³⁴

In a separate investigation, Ericson and Kurol evaluated the accuracy of CT scans for assessing root resorption by comparing the morphological appearance of extracted lateral incisors with CT images of the incisors obtained prior to extraction.³⁵ The sample included 17 maxillary lateral incisors associated with impacted canines that were extracted after CT scanning because of resorption or for other reasons associated with the orthodontic treatment plan. The severity of resorption defects on the incisor roots was graded radiographically from the CT images and clinically with direct measurements of the extracted teeth. Comparison of the scores from of the clinical and radiographic examinations showed a high level of agreement between the two methods concerning the extent and grading of resorption.

The sensitivity of CT scanning for diagnosing the severity of resorption was calculated as 1 and the specificity as 0.875. The authors concluded that the investigation showed CT scanning to be a reliable method of revealing resorptions on maxillary incisor roots caused by ectopic eruption of maxillary canines. The results showed that the clinical findings from extracted teeth matched the radiographic findings of CT scans both in the depth of resorption and in pulpal involvement, relieving concerns that resorptions seen in CT scans were merely artifacts.³⁵ The results of their two computed tomography studies led Ericson and to support the use of CT scans as the gold standard for diagnosis of incisor root resorption in association with ectopic maxillary canines.³⁴

Other investigators have reported evidence of the inadequacy of traditional radiographic methods and the superiority of fan-beam CT for demonstrating incisor root resorptions caused by impacted canines. Freisfeld et al.⁵⁹ asked ten orthodontists to diagnose upper canine impactions and incisor root resorptions from panoramic radiographs and CT images of 30 patients. The orthodontists' diagnoses from the panoramic radiographs were compared with those from the CT images, and CT imaging was found to reveal more than twice as many incisor root resorptions as panoramic radiography. Relative to the gold standard of CT findings, the sensitivity of panoramic radiographs for diagnosis of root resorption was reported to be 45.6%, and the specificity was 88.9%.⁵⁹ Preda et al.⁵⁵ compared CT with conventional radiographs for diagnosis of contact between impacted canines and adjacent incisors and resorption of incisor roots. Nineteen subjects with 29 impacted canines were examined with panoramic and lateral cephalometric radiographs and spiral CT scans. No intraoral radiographs were included in the examination. The results of the comparison showed that CT imaging demonstrated contact between the canine and

incisors and resorption of the incisor roots better than the conventional images, especially when the root resorption was mild and located on the palatal and buccal surfaces of the incisors.⁵⁵

In summary, clinical studies have demonstrated that conventional CT imaging is superior to traditional radiography in the information it provides for impacted maxillary canine diagnosis. CT has been found particularly advantageous for demonstrating the proximity of impacted canines to other structures and for revealing resorptive damage to the roots of incisors adjacent to impacted canines. Despite these documented advantages, conventional CT has not been accepted as a routine imaging modality for impacted canine diagnosis due to the high monetary costs and radiation doses associated with the technique.

Cone Beam Computed Tomography in Impacted Canine Imaging

The recent emergence of cone beam CT (CBCT) devices for dentomaxillofacial imaging has provided a means of obtaining three-dimensional radiographic information at a fraction of the cost and risk of a conventional CT examination. Early studies suggest that CBCT may offer many of the same advantages as conventional CT in the diagnosis of impacted maxillary canines, but the literature is relatively underdeveloped at this time.

Walker et al.³⁷ studied the ability of a CBCT device to demonstrate and quantify the spatial relationships of impacted maxillary canines with regard to canine location and inclination, proximity to adjacent structures, resorption of incisors, alveolar width, and follicle size. Nineteen consecutive patients with 27 ectopically erupted maxillary canines were scanned with a NewTom QR-DVT 9000 unit, and secondary reconstructions were made using NewTom software to produce transaxial, panoramic, and three-dimensional views of

the anatomy. Ninety-three percent of the canines in the study were located palatally, and the remaining seven percent were buccal. The accuracy of the NewTom localization findings was not assessed, as the study lacked a gold standard for comparison.

Root resorption of the lateral incisor was found in association with 18 of the 27 (66.7%) impacted canines, and central incisor resorption with 3 of 27 (11.1%). All of the central incisor resorption cases also had lateral incisor resorption, and in one impaction case, a first premolar root was resorbed. The severity of the resorption defects was not graded in the study. The results of the proximity assessment revealed that 63% of the canines were in contact with adjacent lateral incisors and 18.5% were in contact with central incisors. A correlation was reported between canine-incisor contact and incisor root resorption. Linear and angular measurements were made to define follicle size, cusp tip to occlusal plane and cusp tip to midline distances, and the canines' axial inclinations. The study demonstrated that a wide range of useful information about the anatomical relationships of impacted maxillary canines could be obtained from cone beam CT imaging. The authors proposed that this information may enable clinicians to better understand and treat impacted canine cases surgically and orthodontically.³⁷

Chaushu et al. reported on the use of CBCT imaging in the diagnosis of 23 impacted maxillary teeth. The study evaluated the ability of the technique to reveal the exact positions of the crowns and root apices of the teeth and their spatial relationships with adjacent structures, including the roots of neighboring incisors, premolars, and supernumerary teeth.⁵⁴ In addition, the adjacent teeth were evaluated for root resorption, and the crown and root morphology of the impacted teeth was assessed. The results of the study showed that the NewTom views revealed important features of the spatial relationships of the impactions that

were undiagnosed in panoramic and tube-shift periapical views. In one case, the CBCT images confirmed the buccal position of an impacted canine crown relative to the incisors as seen in plain film radiographs, but the CT views revealed the additional finding that the root apex of the canine was on the palatal side of the first premolar, which was unseen in the traditional views. The authors stated that such knowledge of the position of the root apex was highly important for the orthodontist in determining the feasibility of resolution of the impaction, and assessed the prognosis for retrieval of this particular canine to be poor.⁵⁴

Another case was presented to demonstrate the advantage of CBCT imaging in depicting the proximity of the crown of the impacted tooth to the crown and root of adjacent teeth. The authors explained that knowledge of the proximity of the impacted tooth crown to the roots of adjacent teeth was important to the surgeon in planning the exposure of the tooth so that the risk of iatrogenic damage could be assessed and minimized. This information was also judged to be valuable to the orthodontist in planning the mechanics of tooth movement to avoid nearby structures and result in efficient tooth eruption. A case report of an impacted maxillary incisor showed that CBCT views revealed intimate contact between the impacted tooth and the root of an adjacent incisor, while the overlapping of structures in plain film radiographs obscured the assessment of proximity.⁵⁴

Overlapped structures in plain film radiographs were also seen to obscure the view of root resorption caused by impacted teeth, while CBCT provided clear images to document the presence and severity of resorption defects. The authors presented a case of an impacted canine in which panoramic and periapical radiographs were suggestive of apical resorption of the central incisor but the lateral incisor root outline appeared normal. The crown of the impacted canine was superimposed over the lateral incisor root in the images, obscuring a

portion of the root. CBCT views confirmed shortening of the root of the central incisor, but also revealed severe, oblique resorption of the buccal surface of the lateral incisor root. The authors explained that plain film radiographs reveal oblique root resorption only when it has gone far enough to affect the mesiodistal outline of the root in the images, meaning that significant buccopalatal resorption may easily be missed. This was considered to be a significant shortcoming of plain film images because oblique buccopalatal root resorption has been shown to be the most likely type of resorption associated with impacted maxillary canines.⁵⁴

Chaushu et al. concluded from their clinical cases that CBCT imaging of impacted teeth provided valuable and accurate information for diagnosis and treatment planning. Taking into consideration the acceptable monetary cost and radiation dose of cone beam CT and the clarity with which CBCT images provided a three-dimensional picture of impacted teeth, the authors recommended the routine use of CBCT imaging for diagnosis of impactions as a superior alternative to plain film radiography and a less expensive and less risky alternative to conventional CT.⁵⁴

Thus, the existing scientific literature advocates the use of cone beam CT as a routine imaging modality for impacted canine diagnosis, because it offers similar diagnostic information to conventional CT at a much lower cost and risk to the patient. Specifically, cone beam CT has been shown to be effective for diagnosing the three dimensional location and orientation of impacted canines, their proximity to adjacent structures, and the presence and severity of incisor root resorptions associated with impacted canines. No controlled comparisons of the differences between cone beam CT and traditional radiography for

impacted canine diagnosis exist in the current literature, however, so the relative benefits of CBCT imaging over traditional techniques have yet to be defined.

The purpose of the present study was to compare the effectiveness of orthodontists and oral radiologists in diagnosing simulated cases of maxillary canine impaction using traditional radiographic images and images generated from a NewTom 3G cone beam CT scan. The comparison considered diagnoses of the canines' buccopalatal location, their proximity to neighboring lateral incisors, and resorption of the roots of lateral incisors. The null hypotheses for the comparisons were that no differences would be seen in diagnostic accuracy between the examiner groups or imaging modalities for localization, proximity, and resorption assessment.

MATERIALS AND METHODS

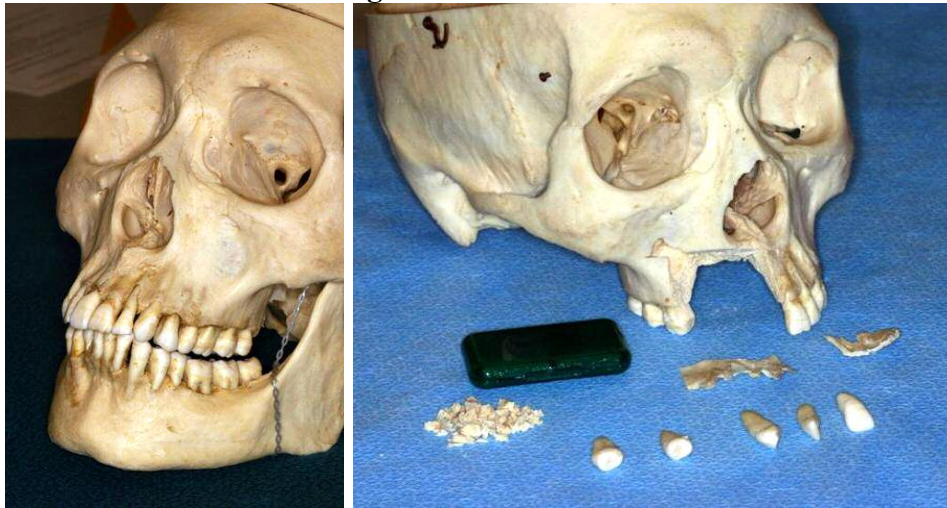Case Simulations

A dry human skull with an intact adult dentition, removable calvarium, and spring-articulated mandible was purchased from Skulls Unlimited, International (Oklahoma City, OK). A segment of the right maxillary dentoalveolus, encompassing the second premolar, first premolar, canine, lateral incisor, and central incisor, was sectioned with an air-driven laboratory handpiece and a serrated diamond disc. Specifically, vertical interdental cuts were made between the first molar and second premolar and between the central incisors, first from the facial and then from the palatal. Next, horizontal cuts were made to connect the vertical cuts at a level high enough to ensure that the root apices of the teeth were not damaged by the disc. Once the cuts were made, a laboratory knife was used to pry the segment away from the maxilla by fracturing the remaining trabecular bone connections internal to the section lines. The segment fractured cleanly, leaving the floor of the nasal sinus intact.

After the segment was sectioned from the maxilla, the teeth in the segment were extracted with finger pressure. The diamond disc then was used to cut the trabecular bone away from the cortical bone, leaving the buccal and palatal cortical plates intact as much as possible. The remaining trabecular bone was removed and ground into small particles by wrapping it in cloth and crushing the bone against a hard countertop with a hammer. The trabecular bone particles were mixed into a matrix of silicone orthodontic wax (OrthoSil, Dentsply Glenroe, Bradenton, FL) to create a bone-radiodensity, moldable composite, as

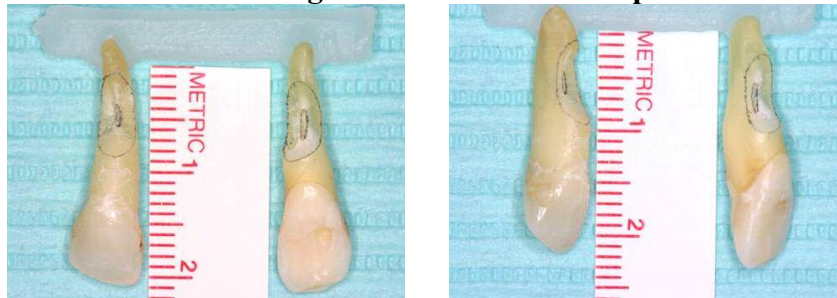described by Huh-Mol.⁷³ In addition to the teeth extracted from the maxillary segment, extra maxillary right premolars, canines, and incisors were obtained from the supply of extracted teeth kept by the UNC Department of Operative Dentistry. The extra teeth were selected for good quality roots to be used in the case simulations and for simulated resorption defects on different locations of the roots of the lateral incisors.

Methods Figure 1: Skull and Materials



Resorptive lacunae on the roots of lateral incisors were simulated by excavation of root dentin with a high speed dental handpiece and a football-shaped diamond bur. Two lateral incisors were prepared with resorption craters in the middle third of the root, one with resorption on the buccal surface, and one with resorption on the palatal surface. The buccal and palatal resorption craters were ovoid in shape, approximately eight millimeters long by four millimeters wide, and extended into the pulp space of the teeth.

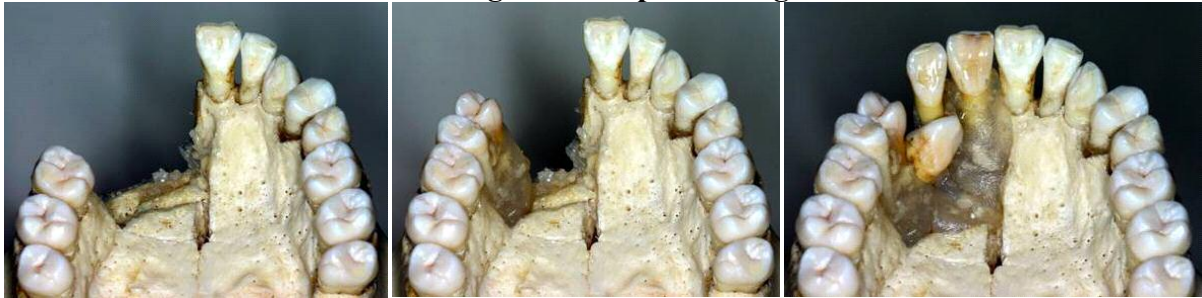
Methods Figure 2: Mid-root Resorption



A third lateral incisor was prepared with resorption in the apical third of the root. Apical resorption was simulated by removal of the apical third of the root in an oblique direction such that more of the palatal root surface was lost and more of the buccal root surface was preserved.

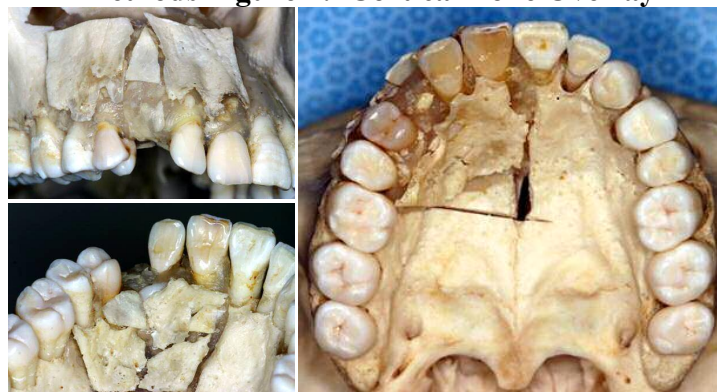To create the case simulations, the maxillary right dentoalveolus segment was reconstructed by adding teeth back to the dental arch one by one, using the composite of silicone wax and trabecular bone as a matrix to hold the teeth in position. The premolars were positioned first, then the central incisor, and the canine and lateral incisor were added last to simulate various anatomical arrangements of maxillary canine impaction.

Methods Figure 3: Repositioning Teeth



Once the teeth were in position, the cortical bone was overlaid on top of the silicone wax to reconstruct the buccal and palatal cortical plates. The cortical bone adhered to the silicone wax without any additional adhesive agent.

Methods Figure 4: Cortical Bone Overlay



The proximity of the canine crown to the lateral incisor root was controlled by the presence or absence of a Styrofoam shim, approximately 2.5 millimeters thick, interposed between the teeth. When contact between the teeth was desired, the lateral incisor and canine were squeezed together until they touched. When space between the teeth was desired, the shim was placed between them

Ten distinct arrangements of the teeth were constructed. The canine was positioned buccal to the lateral incisor in five cases and palatal to the lateral incisor in the other five. In one of the cases in which the canine was buccal to the lateral incisor, the canine was positioned mesially enough that its tip was palatal to the central incisor. The canine was touching the lateral incisor root in six cases, and in the other four, the Styrofoam shim was used to keep the teeth apart. Resorption of the lateral incisor root was simulated on five of the ten cases. Four cases had resorption in the middle third of the root, and one case had resorption of the apical tip. The anatomical arrangements of the cases are described in Methods Table 1.

Methods Table 1: Anatomical Arrangements of Case Simulations

Anatomical Arrangements of Case Simulations				
Case Number	Canine Location Relative to Incisor		Canine Proximity to Lateral Incisor Root	Resorption of Lateral Incisor Root
	B = buccal P = palatal vs Central	vs Lateral		
2		P	T	NR
3		P	NT	NR
6		P	T	R (palatal)
10		P	NT	R (palatal)
4		B	T	NR
1		B	NT	NR
7		B	T	R (buccal)
9		B	NT	R (buccal)
8		P	T	R (apical)
5	P	B	T	NR

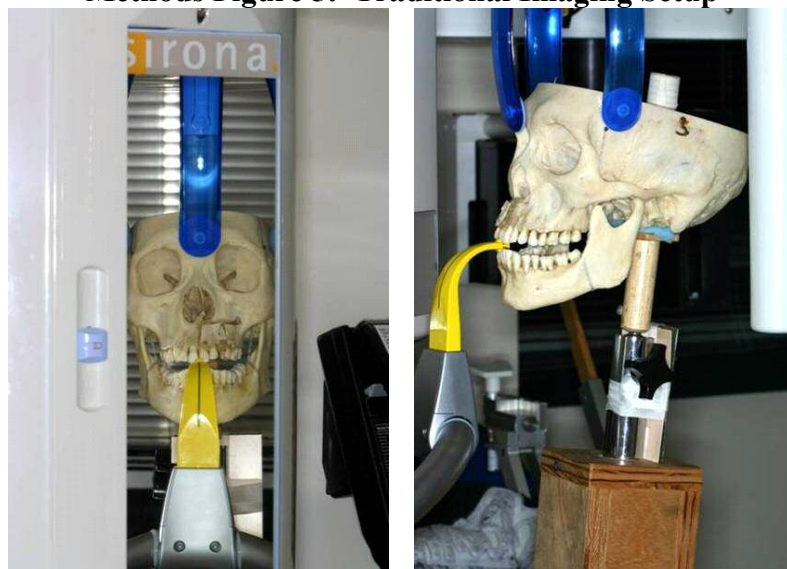
Radiographic Imaging

For each of the ten simulated cases of maxillary canine impaction, a traditional radiographic series and a cone beam CT study were obtained. All radiographic images were made in the Oral and Maxillofacial Radiology Clinic of the UNC School of Dentistry. Prior to imaging, the metal springs that articulated the mandible to the skull were removed and replaced with elastic chain (Ormco, Sybron Dental Specialties, Orange CA) to eliminate a source of radiopaque artifacts in the exposures.

• Traditional Radiography

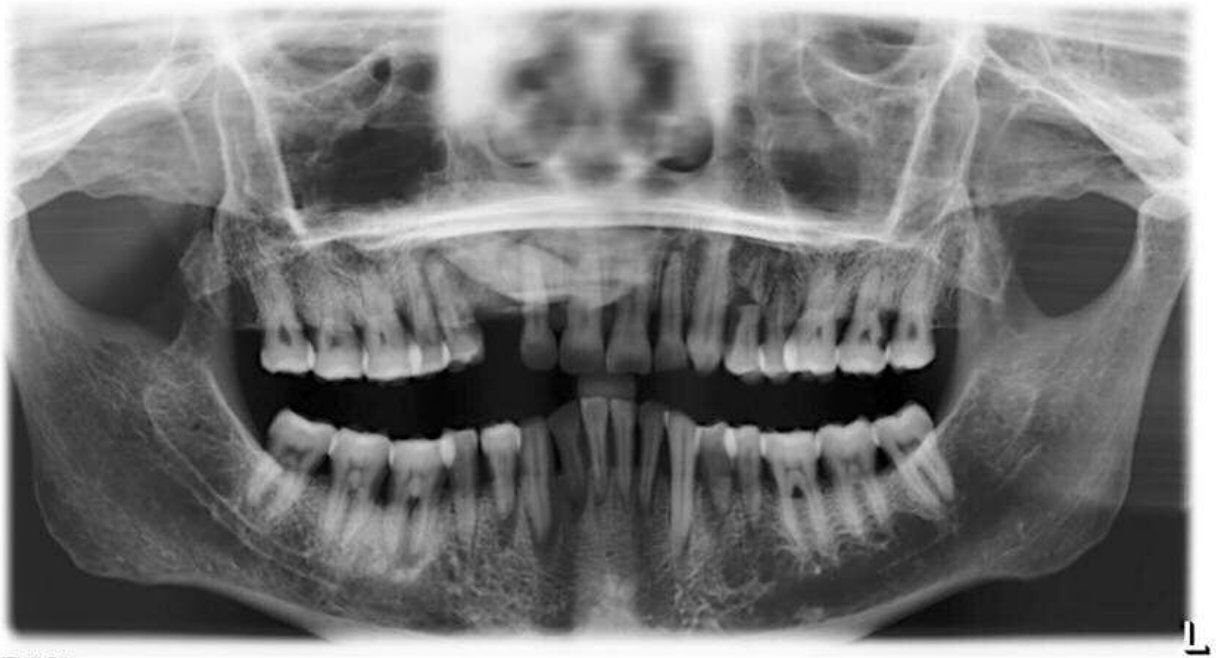A series of traditional radiographs, including a panoramic view, a tube-shift pair of periapical views, and a tube-shift pair of occlusal views, was obtained for each case simulation. A custom-made mounting apparatus was used to secure the dry skull on a photographic tripod for panoramic and intraoral exposures. The critical element of the mounting jig was a wooden dowel rod that extended through the foramen magnum to hold the skull in place. The wooden dowel rod allowed panoramic radiographs to be made without a metallic “spine” artifact in the midline of the images.

Methods Figure 5: Traditional Imaging Setup



Panoramic radiographs were made using one direct digital Sirona Orthophos XG Plus panoramic unit. The panoramic scan was performed at the preset exposure variables for a patient of small stature (62 kilovolts, 8 milliamperes, 14.1 seconds). The x-ray beam was attenuated by a rectangular piece of paper card stock taped over the tube head. Optimal positioning for the panoramic exposures was achieved by carefully orienting the Frankfort Horizontal plane parallel to the floor and aligning the midsagittal plane according to the laser guidelines of the panoramic machine.

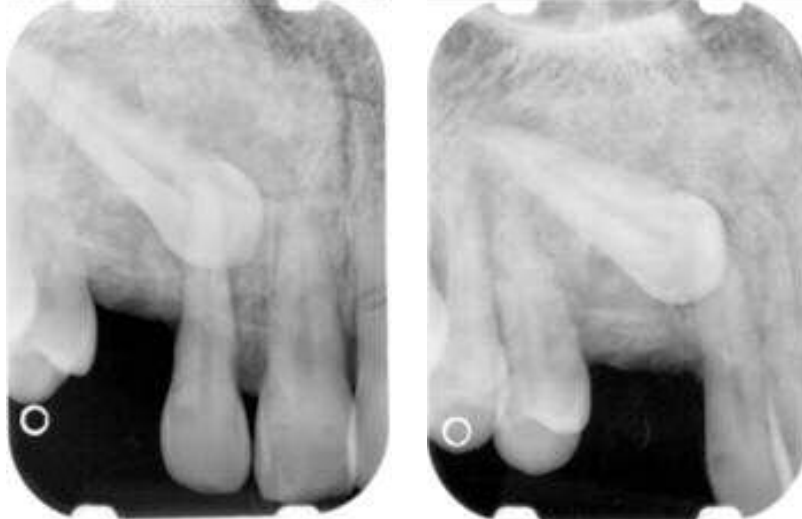
Methods Figure 6: Example Panoramic Radiograph



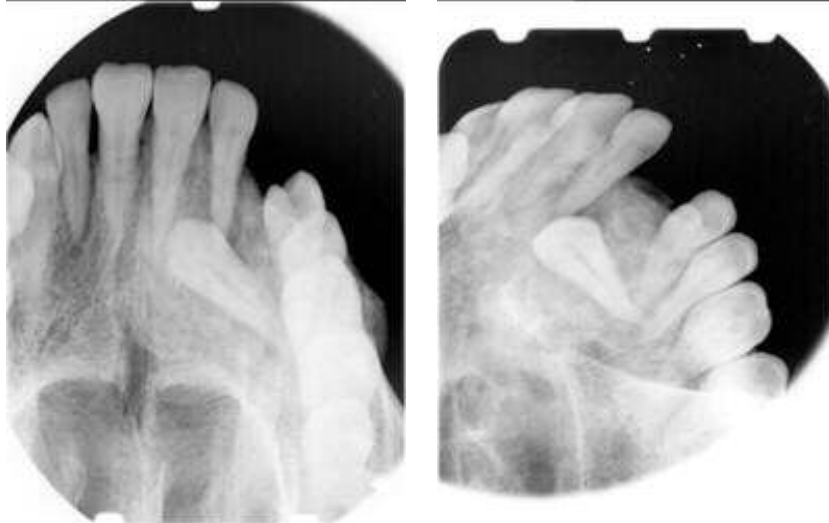Intraoral periapical and occlusal radiographs were made using one Planmecca Prostyle Intra dental X-ray source, Gendex indirect digital photostimulable phosphor receptor plates, and Gendex DenOptix scanners. Exposure settings for the intraoral exposures were 70 kVp and 8 mA for 0.12 sec. Tube shift pairs of intraoral radiographs were obtained by making two periapical and two occlusal exposures for each simulated case and changing the beam angulation between the first and second exposures. For both film formats, an anterior

projection was made first, in which the central ray of the x-ray beam split the central and lateral incisors. Then, the tube head was moved distally around the arch to make a second projection in which the central beam was aimed at the first premolar. Retakes were made as necessary to eliminate cone cuts and projection errors.

Methods Figure 7: Example Periapical Radiographs



Methods Figure 8: Example Occlusal Radiographs



A Styrofoam bite stabe was used to hold the receptor plate in place for periapical exposures, with the receptor positioned parallel to the long axes of the teeth. The tube head was aligned perpendicularly to the receptor plate for periapical exposures. Occlusal

exposures were made with the receptor plate placed between the upper and lower teeth of the skull and the tube head at a sixty degree vertical angulation to the receptor plate. The elastomeric chain used to articulate the mandible to the skull provided enough bite-closing force to hold the bite staves and receptor plates in place for imaging. The traditional radiographic images were stored on the UNC School of Dentistry's Electronic Patient Record and viewed on VixWin (Gendex Dental Systems, Lake Zurich, IL) imaging software.

- **Cone Beam Computed Tomography**

Cone beam CT studies were made using one NewTom 3G scanner (QR, Verona, Italy). The dry skull was immersed under water in a watertight Lexan box for CBCT scanning. The water in the immersion box was used to simulate soft tissue in order to attain images of appropriate contrast. The skull and immersion box were positioned within the gantry of the NewTom unit, and the laser guide beams were used to align the midsagittal plane of the skull and orient the anatomy of interest in the center of the scan field.

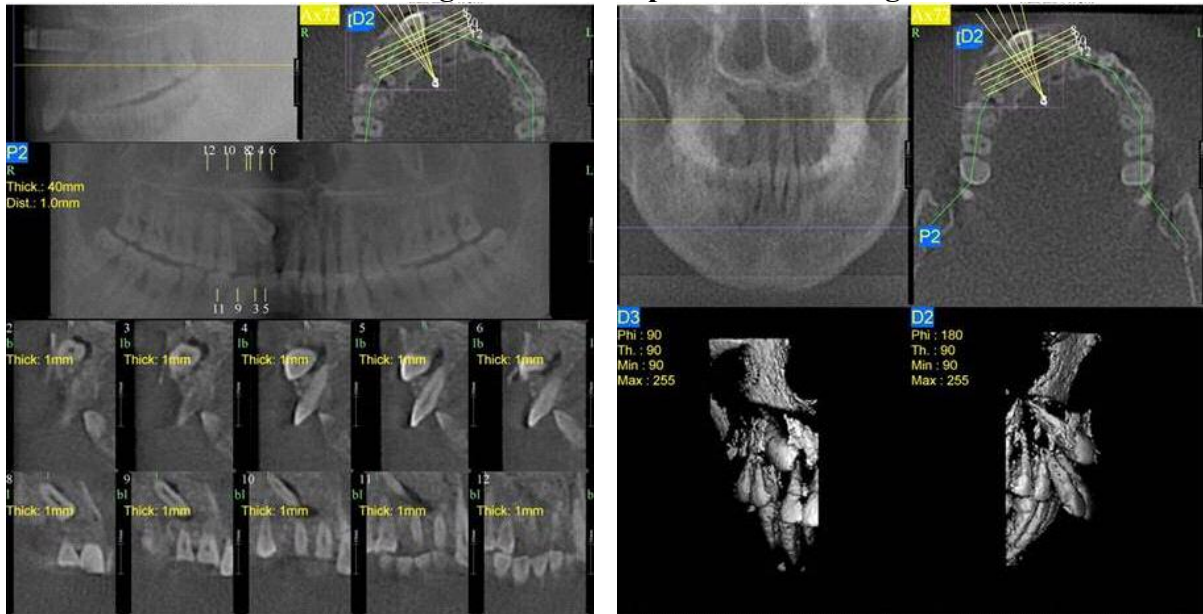
Methods Figure 9: Immersion Box



The large, twelve-inch, field of view was used for all NewTom scans. Primary reconstructions of the CT studies were performed using NewTom software (NNT, QR,

Verona, Italy). “Highest quality” settings and 0.5 millimeter slice thicknesses were used for all reconstructions. Imaging files were stored on a research-dedicated computer in the Department of Radiology.

Methods Figure 10: Example NewTom Images



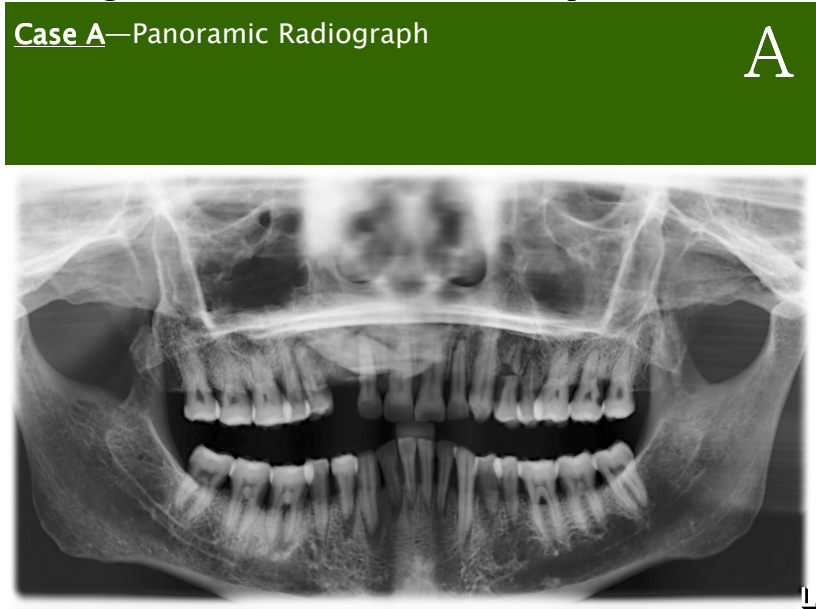Case Presentations

Slideshow presentations of the diagnostic images for each case simulation were prepared using PowerPoint software (Microsoft, Redmond, WA). Two PowerPoint presentations of case images were made: one to display the traditional radiography images, and a second to display the NewTom 3G images. Each presentation included all ten of the anatomically distinct case arrangements previously described, as well as four repeated cases for assessment of examiner reliability. The order of the case displays was randomized for both presentations.

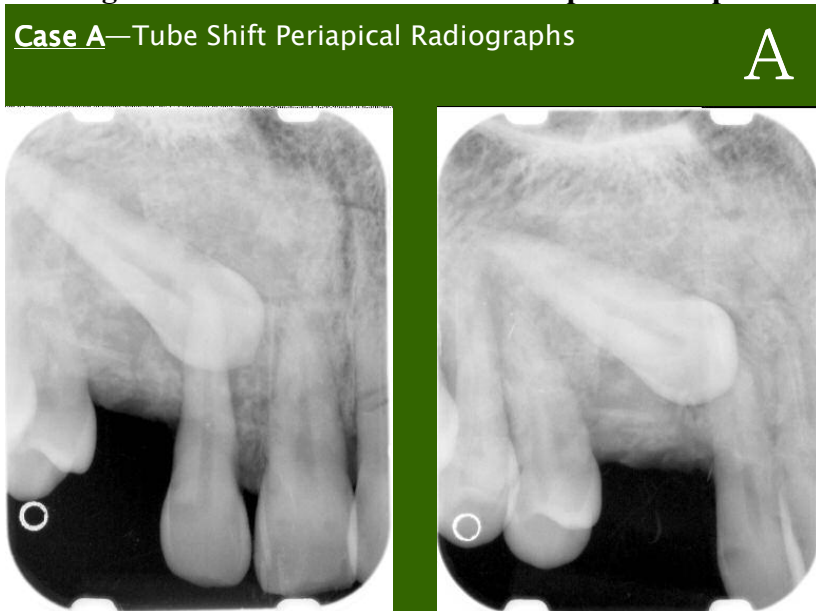
The “traditional imaging” presentation showed three slides of traditional radiographic images for each case. The first slide displayed the panoramic image centered on the screen

in a consistent, large format. The second slide showed the tube-shift periapical images side by side. The third slide showed the tube-shift occlusal images side by side. The periapical and occlusal images were displayed in a consistent size, format, and order. The slides were laid out so that the more anterior projection was always on the left and the more posterior projection was always on the right.

Methods Figure 11: Presentation Slide Example—Panoramic Image



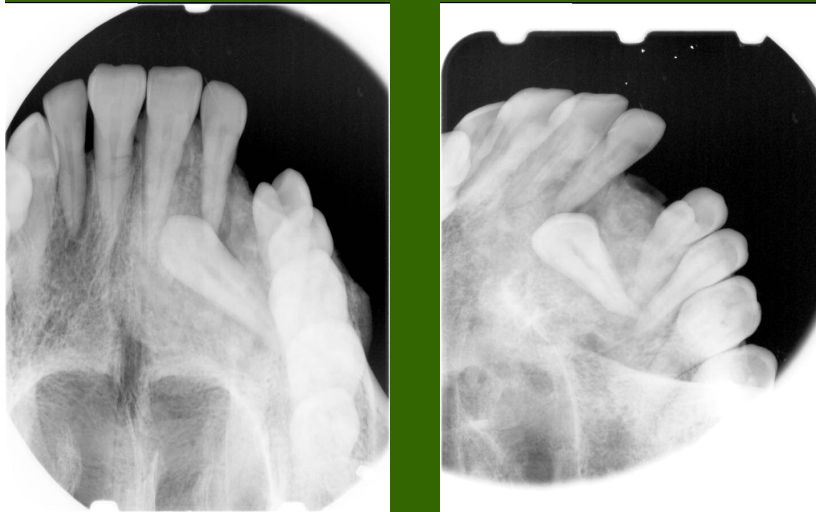
Methods Figure 12: Presentation Slide Example—Periapical Images



Methods Figure 13: Presentation Slide Example—Occlusal Images

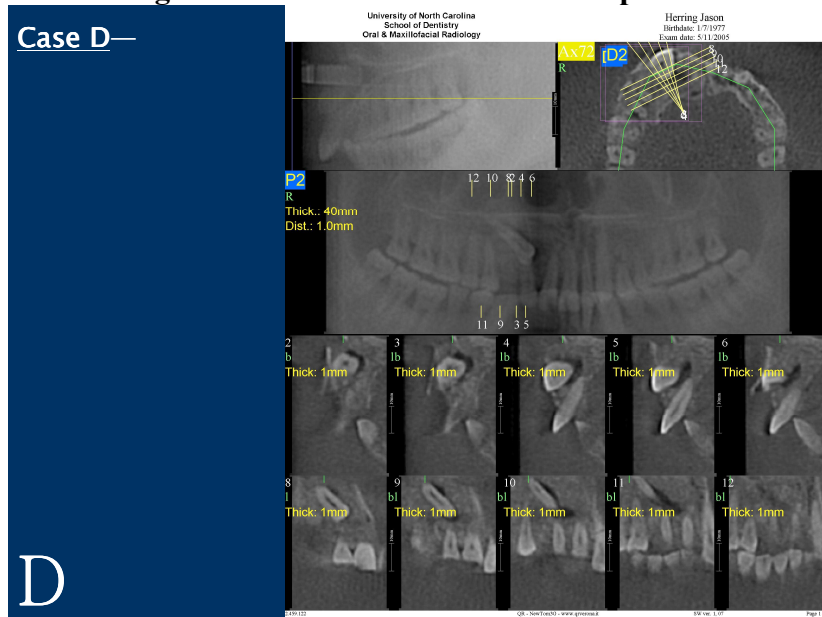
Case A—Tube Shift Occlusal Radiographs

A

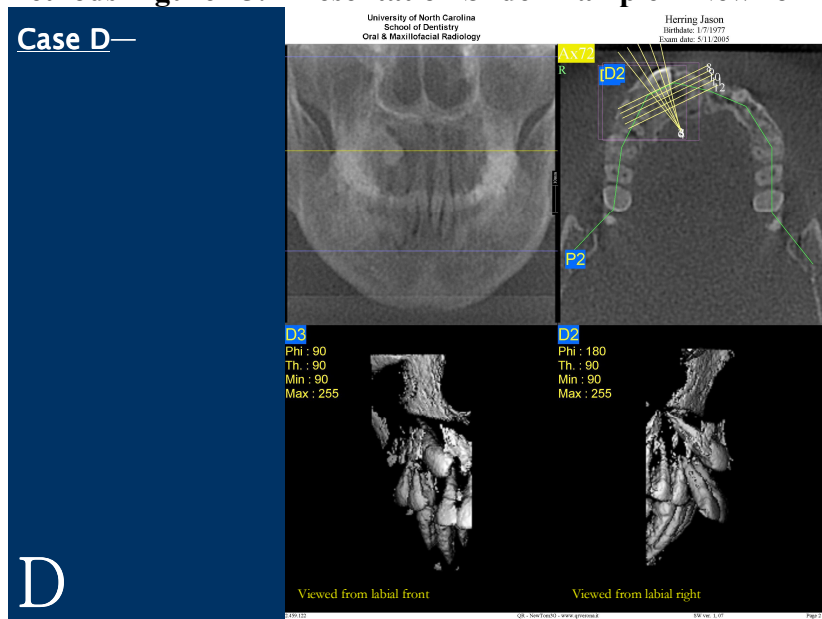


The “NewTom imaging” presentation showed two slides of NewTom 3G images for each case. The first slide displayed the following views: a lateral “scout” view, an axial view of the maxillary arch at the level of the middle of the impacted canine crown, a pseudopanoramic view, five representative orthogonal slices of the canine-incisor region, and five representative coronal slices of the canine-incisor region. A line on the lateral scout view defined the image layer of the axial view, and a series of lines on the axial view defined the image layers of the panoramic view and the orthogonal and coronal slices. The second slide displayed the following views: an anteroposterior “scout” view, the same axial slice of the maxillary arch in the first slide, and two three-dimensional reconstructions, one as seen from a labial point of view and another as seen from a lingual point of view. A line on the anteroposterior scout view defined the image layer of the axial view, and a box on the axial view defined the volume for the three-dimensional reconstructions. The primary investigator used NewTom software to generate all of the NewTom 3G images in the PowerPoint presentation and selected representative views for inclusion in the slideshow.

Methods Figure 14: Presentation Slide Example—NewTom 1



Methods Figure 15: Presentation Slide Example—NewTom 2



Since the images were similar in appearance for all cases, features were incorporated into the slide presentations to help examiners keep track of which case they were viewing. Cases were identified by letter in the upper right-hand corner of each slide. The background color of the slides alternated from dark green to dark blue to signify a change in case. For example, in the “traditional” presentation, the three slides for Case A were shown on a green

background, and the three slides for Case B were shown on a blue background, followed by the three slides for Case C on green, and so on. Thus, examiners had two visual cues of the transition from one case to another in the presentation—the change in the letter in the upper right corner of the slide and the change in the background color of the slide.

Examiners and Their Task

Eleven specialists in Orthodontics and six specialists in Oral and Maxillofacial Radiology were recruited to serve as examiners in the study. A consent process approved by the UNC Biomedical Institutional Review Board was followed in recruiting the examiners. Orthodontists were recruited from the faculty of the UNC School of Dentistry Department of Orthodontics, and eight full-time faculty orthodontists and three part-time faculty orthodontists agreed to participate. Radiologists were recruited from the UNC School of Dentistry Department of Oral and Maxillofacial Radiology. Three full-time faculty members in oral radiology, one PhD candidate, one third-year Master's program resident, and one second-year Master's program resident agreed to participate in the study.

The examiners who agreed to participate in the study were given a packet that included a cover letter explaining the study, a consent document, a self-test on the Buccal Object Rule for localization, two diagnostic questionnaires, and a compact disc (CD). Orthodontists and radiologists were given slightly different CDs. Orthodontist examiners received a CD that contained a Word document file (Microsoft, Redmond, WA) of the answer key to the Buccal Object Rule self-test and two PowerPoint files of the “Traditional Imaging” and “NewTom Imaging” case presentations. The radiologists' CD also contained the answer key to the Buccal Object Rule self-test, but it held only the “Traditional Imaging”

PowerPoint case presentation. This discrepancy was made because the protocol for viewing the NewTom 3G case images was different for the two specialist groups, as explained in the following section.

Prior to viewing any of the case presentation images, examiners in the study were asked to complete a self-test on the Buccal Object Rule. The self-test was administered in order to allow the examiners to assess for themselves their level of competency with the localization method before continuing with the study. The answer key to the self-test was included on the CDs for all examiners. Examiners were instructed to complete and grade the self-test and decide for themselves whether or not they required additional instruction on the localization technique. For those examiners who did desire additional instruction, a web address to an online learning module on the Buccal Object Rule was included in the cover letter. The learning module, adapted from the work of A.G. Richards,⁴⁷ was hosted on the UNC School of Dentistry website as part of the instructional materials for the DENT 125 *Introduction to Radiology* course in the first-year DDS curriculum. The questions on the self-test were taken from example problems in the learning module. No effort was made by the primary investigator to grade the self-tests or otherwise assess the examiners' proficiency in use of the Buccal Object Rule. The goal of the self-test procedure was to allow the examiners to proceed with the study when they considered themselves ready to do so.

Protocols for Case Diagnosis

After completing the Buccal Object Rule self test procedure, the examiners were ready to view the diagnostic images and complete the questionnaires. Orthodontist examiners were instructed to review the images on the “Traditional” and “NewTom”

PowerPoint presentations and record their diagnostic impressions of the cases on the questionnaire that corresponded to the imaging modality. In order to guard against reading order bias created by the order of viewing the two imaging modalities, six of the eleven orthodontists were instructed to complete the traditional imaging diagnosis before proceeding to the NewTom imaging diagnosis, while the other five orthodontists were instructed to complete the NewTom imaging diagnosis first and then the traditional imaging diagnosis.

The orthodontist examiners were not required to finish all fourteen cases in a presentation in one sitting, but they were required to finish the cases for one modality before continuing to the next. No washout period between imaging modalities was used for the orthodontist examiners. This decision was made primarily for convenience, so that the orthodontist examiners could diagnose the cases from both modalities in one day if they desired to do so. This concession was especially important to enable the participation of part-time orthodontic faculty members in the study. Since the traditional images differed considerably in appearance from the NewTom 3G images, and the order of the case presentations was different for the different imaging modalities, it was judged unlikely that examiners would be able to identify and recall cases between the two modalities to confound the data.

The radiologists' protocol for viewing the case images and completing the diagnostic questionnaires was somewhat different from that of the orthodontists. Like the orthodontists, the radiologist examiners reviewed the panoramic and intraoral images on the "Traditional Imaging" PowerPoint presentation to complete the traditional diagnosis of the simulated cases. Unlike the orthodontists, all of the radiologists were required to complete the traditional diagnosis before continuing to the NewTom diagnosis, and a washout period of

two weeks between finishing the traditional diagnosis and starting the NewTom diagnosis was required for the radiologists.

The protocols for viewing the NewTom 3G images were different because the orthodontists and radiologists had widely different levels of expertise in using NewTom software (NNT, QR, Verona, Italy) to manipulate and interpret the NewTom 3G scans. All but one of the orthodontists had no experience with the software, while all but one of the radiologists were very familiar with its use. Since the orthodontists were not trained to manipulate the software on their own, they viewed the sample of images on the “NewTom Imaging” PowerPoint presentation to diagnose the case simulations. The radiologist examiners were trained to use the NewTom software, and they were allowed to perform reconstructions on their own to create whatever slices and views they desired for diagnosis of the impacted canine cases. A goal of the study was to allow the radiologists to use the information provided in the NewTom scans to its fullest potential, and limiting the radiologists to the sample of images provided in the “NewTom Imaging” PowerPoint presentation was decided to be counterproductive to that goal.

As a precaution against reading order bias, the radiologist examiners were required to wait a minimum of two weeks after finishing the traditional diagnosis to begin the NewTom diagnosis. The examiners were given a brief orientation to help them locate the series of cases in the file directory, and they were instructed not to save any of the cross-sectional slices or three dimensional reconstructions that they generated during their session. The radiologist examiners diagnosed all ten of the anatomically distinct case simulations in randomized order, but no cases were repeated for reliability in this part of the study. The radiologists’ “NewTom Imaging” diagnoses were expected to approximate the gold standard

in accuracy, and in the context of this expectation, repeated cases, which would require a second washout period, were deemed unnecessary.

Diagnostic Questionnaire

A questionnaire was developed to allow examiners to record their diagnostic impressions of the images displayed in the case presentations. The examiners were asked to diagnose the buccopalatal location of the canine relative to the incisors, the proximity of the canine to the root of the lateral incisor, and the presence or absence of root resorption of the lateral incisor. The questionnaire required that examiners choose a value from a five point ordinal scale to express their agreement with objectively true or false diagnostic statements. The questionnaire format is provided in Methods Table 2 below:

Methods Table 2: Questionnaire Format

<p><u>CASE A</u> Please note your agreement/disagreement with the following statements using the scale below: (1)Definitely True (2)Probably True (3)Unsure (4)Probably Not True (5)Definitely Not True</p> <p>Location The impacted canine is buccal to the central incisor. _____ The impacted canine is buccal to the lateral incisor. _____</p> <p>Proximity The impacted canine is touching the root of the lateral incisor. _____</p> <p>Root resorption The impacted canine has caused resorption of the root of the lateral incisor. _____</p>
--

The “Traditional Imaging” questionnaire for both the orthodontists and radiologists had fourteen cases, lettered A through M. The “NewTom Imaging” questionnaire for the orthodontists also had fourteen cases. The “NewTom Imaging” questionnaire for the radiologists had ten cases, lettered A through J.

Data Analysis

Questionnaires were collected at the end of each viewing session and completion of all questions was verified. Any unanswered questions were brought to the examiner's attention, and the examiner revisited the case images to complete the omitted questions.

Data were initially entered using Excel software (Microsoft, Redmond, WA), and data analysis was performed using SAS software (SAS, Cary, NC). The accuracy of the orthodontist and radiologist examiners' diagnoses was evaluated by comparing their scores against the known anatomy of the case simulation setups. Since the viewing protocol for the NewTom Imaging modality for the orthodontists and radiologists differed, a factorial analysis was not appropriate. The following pairwise comparisons of the accuracy of the responses were performed: 1) Traditional Imaging Modality—Orthodontists versus Radiologists, 2) Orthodontist Examiners—Traditional Imaging versus NewTom Imaging, and 3) Radiologist Examiners—Traditional Imaging versus NewTom Imaging.

The original strategy for data analysis involved a Receiver Operating Characteristic (ROC) analysis so that the certainty, as well as the accuracy, of diagnoses could be assessed. The ordinal scale response format of the questionnaires used in the study reflected the ROC analysis plan. ROC analysis was abandoned after the data set yielded degenerate results using ROCKIT and LABMRMC software (University of Chicago, Chicago, IL).

The definitely and probably categories were combined yielding true, not true, and unsure categories for each question. Accuracy was classified as "incorrect" if the response was unsure or did not match the case simulation. The pairwise comparisons were performed using an extended Mantel-Haenszel general association test with stratification to control for the influence of skull on the responses. The Breslow-Day Test of Homogeneity was used to

assess whether the relationship between accuracy and group or modality was similar for all of the dry skull simulations. The alpha level for statistical significance was set at 0.05.

Examiners' responses were also analyzed by constructing probability ratios as analogues of sensitivity, specificity, positive predictive value, and negative predictive values in order to provide further description of the quality of the two imaging modalities as diagnostic tests. "Unsure" responses were again considered as incorrect diagnoses. The term "Buccal Sensitivity" was defined as the chance of a correct "buccal" localization diagnosis for the case setups in which the canines were actually buccal. This probability was calculated by the ratio (Correct Buccal/True Buccal) from the two by two table example above. "Palatal Sensitivity" was defined as the chance of a correct "palatal" localization diagnosis for the case setups in which the canines were actually palatal and was calculated by the ratio (Correct Palatal/True Palatal). "Buccal Predictive Value" was defined as the chance that a diagnosis of "buccal" was actually correct and was calculated (Correct Buccal/Test Buccal). "Palatal Predictive Value" was defined as the chance that a diagnosis of "palatal" was actually correct and was calculated (Correct Palatal/Test Palatal). Similar probability ratios were calculated for the "Touching/Not Touching" and "Resorbed/Not Resorbed" diagnoses.

RESULTS

Localization Diagnosis: *canine crown buccal or palatal to central incisor*

The buccopalatal location of the canine relative to the central incisor was diagnosed by the examiners for every case, but many examiners reported confusion with the question. In only one of the ten case simulations was the canine purposefully positioned to overlap the central incisor. In all of the other case setups, the canine was positioned distally to the central incisor, and this led to confusion because examiners did not know how to respond to the statement, “The canine is buccal to the central incisor.” Examiners were unclear whether to score the question as “Definitely Not True” because the canine’s distal position was definitely not buccal to the central incisor or whether to use the canine’s position relative to the lateral incisor as a guide to score the question.

As a result of this confusion, the accuracy of the canine-to-central incisor localization responses was evaluated only for the one case in which the canine was positioned palatally to the central incisor in the case setup. There were eleven orthodontist observations and six radiologist observations of the case for each imaging modality. Results are shown in Results Table 1.

Results Table 1

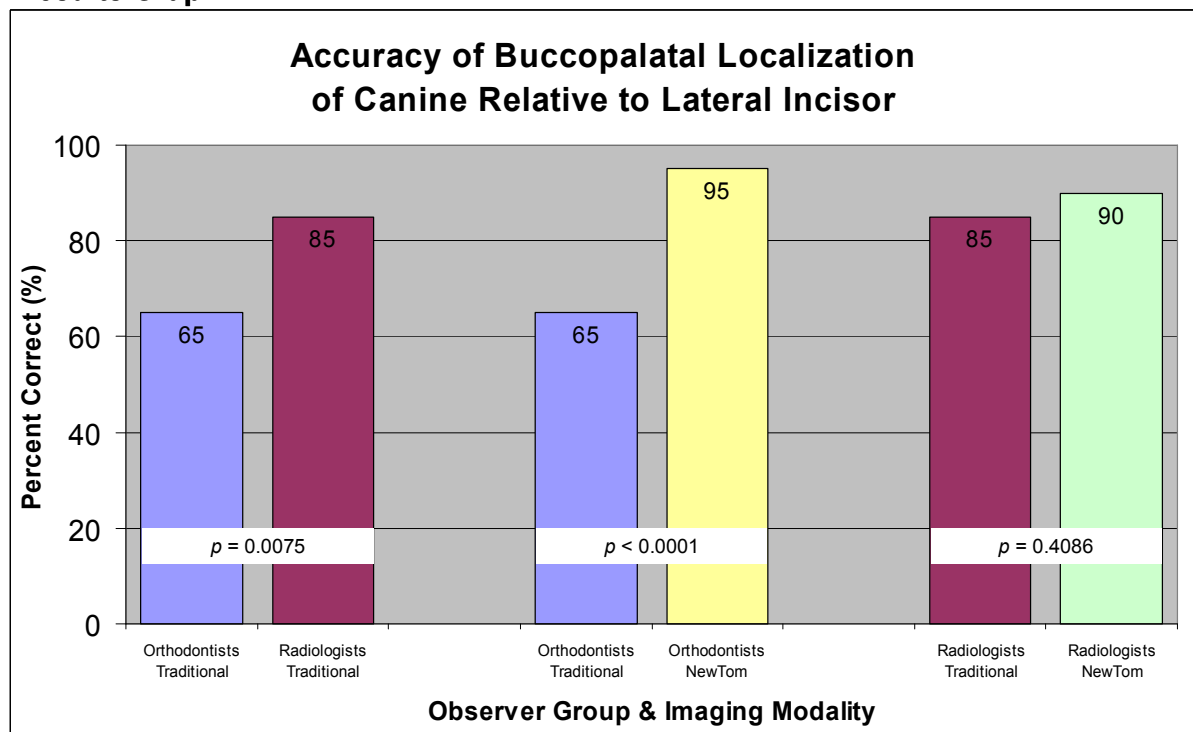
Buccopalatal Localization Relative to Central Incisor					
Observer Group	Modality	correct		incorrect	
		N	%	N	%
Orthodontist	Traditional	6	54.55	5	45.45
	NewTom	6	54.55	5	45.45
Radiologist	Traditional	4	66.67	2	33.33
	NewTom	3	50	3	50

Using the “Traditional Imaging” modality, the orthodontists correctly diagnosed the canine’s palatal position 55% of the time and the radiologists correctly diagnosed the canine’s palatal position 50% of the time. Using the “NewTom Imaging” modality, the orthodontists correctly diagnosed the canine’s position 55% of the time, and the radiologists correctly diagnosed the canine’s position 67% of the time. The differences in accuracy were not analyzed for statistical significance due to the small number of examiner observations.

Localization Diagnosis: *canine crown buccal or palatal to lateral incisor*

The analysis of the examiners’ accuracy in buccopalatal localization of the canine relative to the lateral incisor included observations for all ten cases. In total, there were 110 orthodontist observations and 60 radiologist observations for each imaging modality. For all pairwise comparisons, the Breslow-Day test was not statistically significant ($p = 0.6573$), indicating that the relationship between accuracy and group or modality was the same for all dry skull case simulations. Thus, it was not necessary to consider the case simulations separately. Results are shown in Results Graph 1.

Results Graph 1



For the “Traditional Imaging” modality, there was statistically significant evidence (Mantel-Haenszel p -value = 0.0075) that the radiology group had higher accuracy rates (85% correct) than the orthodontic group (65% correct) for buccopalatal localization of the canines relative to the lateral incisors. In the comparison of imaging modalities within observer groups, there was statistically significant evidence (Mantel-Haenszel p -value < 0.0001) that the orthodontists were much more accurate in their localization diagnoses from the NewTom images (95% correct) than they were from the traditional images (65% correct). There was no statistically significant evidence (Mantel-Haenszel p -value = 0.4086) that the radiologists’ accuracy rates differed between the “Traditional Imaging” diagnoses (85% correct) and the “NewTom Imaging” diagnoses (90% correct) with regard to canine localization relative to the lateral incisor.

Localization accuracy rates for the individual orthodontic and radiologic examiners are shown in Results Table 2 and Results Table 3. The orthodontists' accuracy rates for "Traditional Imaging" localization ranged from zero percent correct to 100% correct. Five of the eleven orthodontists were perfectly accurate, correctly localizing the canines in all ten of the case simulations. Another two orthodontists were 90% accurate, misdiagnosing only one case each. At the other end of the spectrum were two orthodontists who misdiagnosed all ten cases, along with two others who were correct in only 10% and 30% of their diagnoses. The radiologists' accuracy rates for traditional localization ranged from 40% correct to 100% correct. Four of the six radiologists were perfectly accurate, and the other two had accuracy rates of 40% and 70%.

Results Table 2

Buccopalatal Localization by Orthodontic Examiner							
Orthodontist	Traditional Imaging			Orthodontist	NewTom Imaging		
	% Correct Buccal	% Correct Palatal	% Correct Total		% Correct Buccal	% Correct Palatal	% Correct Total
1	100	100	100	1	100	100	100
3	100	100	100	2	100	100	100
8	100	100	100	6	100	100	100
9	100	100	100	7	100	100	100
11	100	100	100	8	100	100	100
4	80	100	90	9	100	100	100
6	80	100	90	10	100	100	100
10	20	40	30	11	100	100	100
5	0	20	10	3	60	100	80
2	0	0	0	4	60	100	80
7	0	0	0	5	100	60	80
Average	61.8	69.1	65.5	Average	92.7	96.4	94.5

Results Table 3

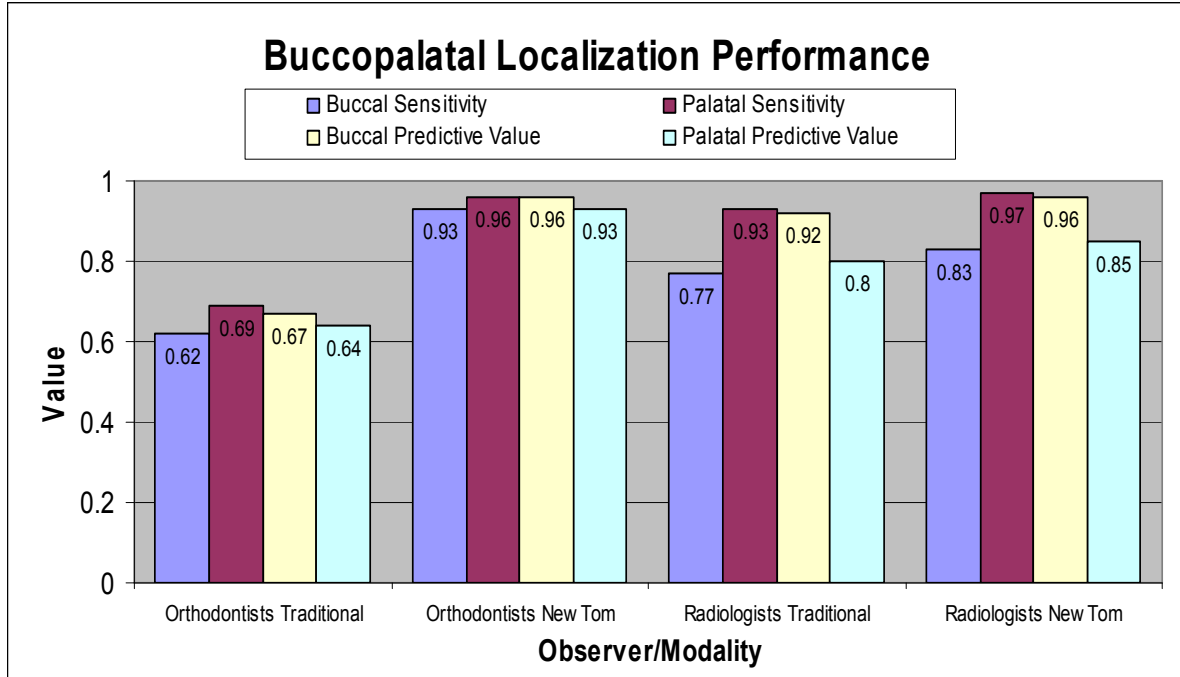
Buccopalatal Localization by Radiologic Examiner							
Radiologist	Traditional Imaging			Radiologist	NewTom Imaging		
	% Correct Buccal	% Correct Palatal	% Correct Total		% Correct Buccal	% Correct Palatal	% Correct Total
1	100	100	100	2	100	100	100
2	100	100	100	6	100	100	100
4	100	100	100	1	80	100	90
6	100	100	100	5	100	80	90
3	40	100	70	3	60	100	80
5	20	60	40	4	60	100	80
Average	76.7	93.3	85.0	Average	83.3	96.7	90.0

The examiners' accuracy rates for buccopalatal localization generally improved for the "NewTom Imaging" modality. Eight of the eleven orthodontic examiners were perfectly accurate with the NewTom modality, and the other three were 80% accurate, missing two cases each. Only two of the orthodontists were less accurate with the NewTom images than the traditional images. The radiologists' accuracy rates for NewTom localization ranged from 80% to 100% accurate. Two radiologists were perfectly accurate, two misdiagnosed one case, and two misdiagnosed two cases with the NewTom 3G images.

Sensitivity ratios revealed that orthodontic examiners were equally successful at diagnosing the location of buccal versus palatal canines while radiologic examiners were somewhat more successful at diagnosing the location of palatal canines versus buccal ones. Results are shown in Results Graph 2. Using the "Traditional Imaging" modality, orthodontists correctly localized 62% of the buccal canines they examined and 69% of the palatal canines they examined. Radiologists correctly localized 77% of the buccal canines and 93% of the palatal canines. The patterns seen for the traditional imaging modality held true for both observer groups with the "NewTom Imaging" modality, as the orthodontists

performed similarly for buccal and palatal canines while the radiologists were somewhat better with palatal canines than buccal.

Results Graph 2



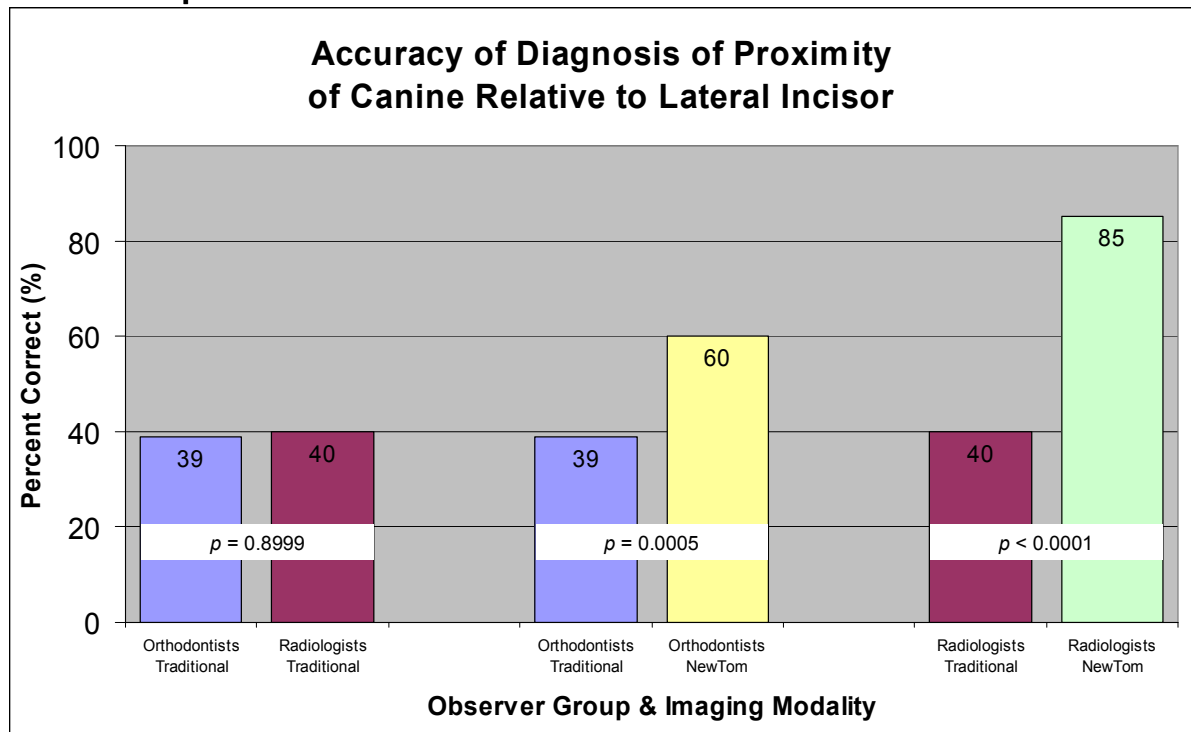
Predictive values (Results Graph 2) showed that the likelihood that a diagnosis of “buccal” or “palatal” was actually correct. The orthodontists were correct about the same percentage of the time for their “buccal” diagnoses as their “palatal” diagnoses for both modalities. Using the “Traditional Imaging” modality, 67% of the orthodontists’ diagnoses of “buccal” were correct while 64% of their “palatal” diagnoses were correct. Using the “NewTom Imaging” modality, 96% of the orthodontists’ “buccal” diagnoses were correct, and 93% of their “palatal” diagnoses were correct. Radiologists were more likely to be correct in a diagnosis of “buccal” than a diagnosis of “palatal” for both modalities. Using the “Traditional Imaging” modality, radiologists’ diagnoses of “buccal” were correct 92% of the time, in comparison to 80% of their “palatal” diagnoses. Using the “NewTom Imaging”

modality, 96% of the radiologists' diagnoses of "buccal" were correct, and 85% of their "palatal" diagnoses were correct.

Proximity Diagnosis: *canine crown touching or not touching lateral incisor*

The analysis of the examiners' accuracy in diagnosing the presence or absence of contact between the canine and lateral incisor included observations for all ten cases. In total, there were 110 orthodontist observations and 60 radiologist observations for each imaging modality. For all pairwise comparisons, the Breslow-Day test was not statistically significant ($p = 0.3355$), indicating that the relationship between accuracy and group or modality was the same for all dry skull case simulations. Thus, it was not necessary to consider the case simulations separately. Results are shown in Results Graph 3.

Results Graph 3



Orthodontists and radiologists were similarly inaccurate at diagnosing contact between the canine and lateral incisor using the “Traditional Imaging” modality, with accuracy rates of 39% and 40% respectively. There was no statistically significant evidence of a difference between the groups in their “Traditional Imaging” diagnosis of proximity (Mantel-Haenszel p -value = 0.8999). In the comparison of imaging modalities within observer groups, there was statistically significant evidence (Mantel-Haenszel p -value = 0.0005) that the orthodontists were more accurate in diagnosing proximity with the “NewTom Imaging” modality (60% correct) than they were with the “Traditional Imaging” modality (39% correct). There also was statistically significant evidence (Mantel-Haenszel p -value < 0.0001) that the radiologists were much more accurate in diagnosing proximity with the “NewTom Imaging” modality (85% correct) than they were with the “Traditional Imaging” modality (40% correct).

Accuracy rates of the individual examiners for the diagnosis of canine to incisor proximity are shown in Results Table 4 and Results Table 5. Orthodontists’ accuracy rates for “Traditional Imaging” proximity diagnosis ranged from 10% to 60% correct. Only two of the eleven orthodontists were more than 50% accurate using the traditional images. Radiologists’ accuracy rates for “Traditional Imaging” proximity diagnosis ranged from 20%-70% accurate. One of the radiologists was more than 50% accurate. Using the “NewTom Imaging” modality, orthodontists’ accuracy rates for proximity diagnosis ranged from 10%-80%. Seven of the eleven orthodontists were more than 50% accurate with the NewTom images. The radiologists’ accuracy rates with the “NewTom Imaging” modality ranged from 70%-90%. Four of the radiologists were 90% accurate, misdiagnosing only one case each.

Results Table 4

Proximity Assessment by Orthodontic Examiner							
Orthodontist	Traditional Imaging			Orthodontist	NewTom Imaging		
	% Correct Touch	% Correct No Touch	% Correct Total		% Correct Touch	% Correct No Touch	% Correct Total
9	100	0	60	3	83.3	75	80
10	83.3	25	60	5	83.3	75	80
4	33.3	75	50	6	100	50	80
8	66.7	25	50	9	100	50	80
11	33.3	75	50	1	83.3	50	70
3	50	25	40	7	50	75	60
5	16.7	50	30	8	50	75	60
6	16.7	50	30	10	83.3	0	50
7	33.3	25	30	11	50	50	50
1	16.7	25	20	2	33.3	50	40
2	16.7	0	10	4	16.7	0	10
Average	42.4	34.1	39.1	Average	66.7	50.0	60.0

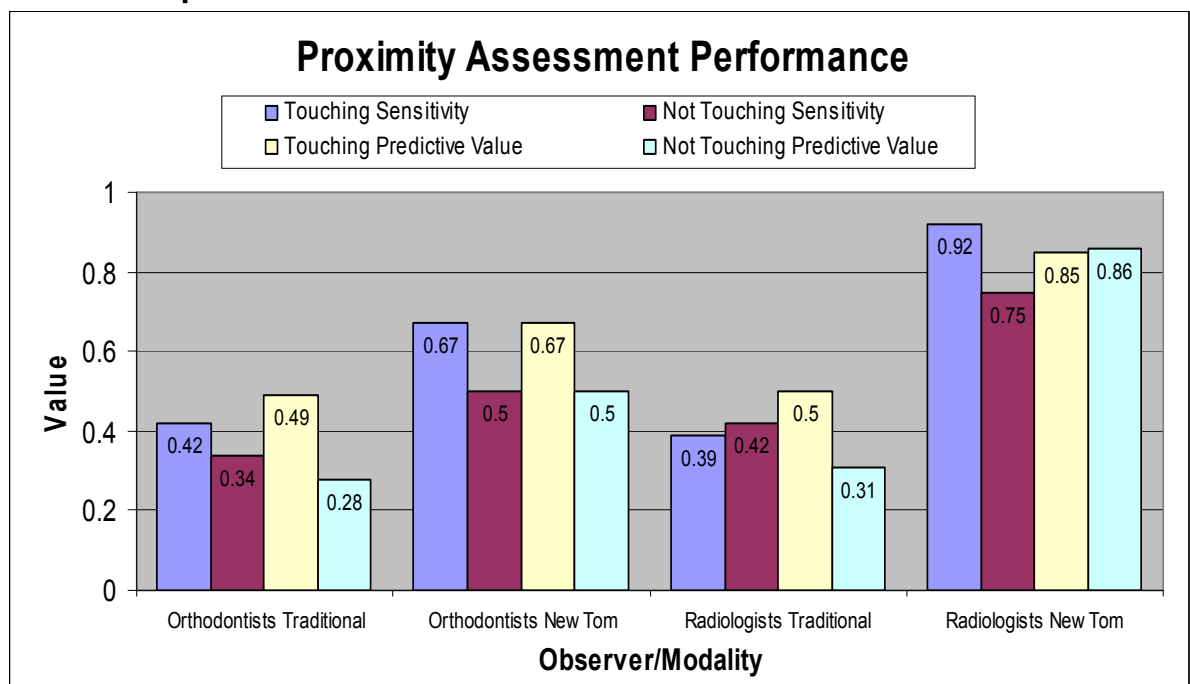
Results Table 5

Proximity Assessment by Radiologic Examiner							
Radiologist	Traditional Imaging			Radiologist	NewTom Imaging		
	% Correct Touch	% Correct No Touch	% Correct Total		% Correct Touch	% Correct No Touch	% Correct Total
2	66.7	75	70	1	100	75	90
1	16.7	100	50	2	100	75	90
3	33.3	50	40	5	83.3	100	90
4	50	0	30	6	100	75	90
5	33.3	25	30	4	83.3	75	80
6	33.3	0	20	3	83.3	50	70
Average	38.9	41.7	40.0	Average	91.7	75.0	85.0

Sensitivity ratios and predictive values showed that both groups of observers performed poorly in their “Traditional Imaging” diagnosis of canine to incisor proximity. Results are shown in Results Graph 4. Using the “Traditional Imaging” modality, orthodontists correctly diagnosed contact in 42% of the touching cases that they examined, and they correctly diagnosed no contact in 34% of the cases that were not touching.

Radiologists correctly diagnosed contact in 39% of the touching cases and correctly diagnosed no contact in 42% of the cases that were not touching. Forty-nine percent of the orthodontists’ “Traditional Imaging” diagnoses of “touching” were correct and 28% of their diagnoses of “not touching” were correct. The radiologists were correct in 50% of their “touching” diagnoses and 31% of their “not touching” diagnoses using the “Traditional Imaging” modality.

Results Graph 4



The orthodontists’ performance in diagnosing canine to incisor proximity improved modestly with the use of NewTom 3G imaging, and the radiologists’ performance improved dramatically. Using the “NewTom Imaging” modality, the orthodontists correctly diagnosed contact in 67% of the touching cases that they examined, and they correctly diagnosed no contact in 50% of the cases that were not touching. Radiologists correctly diagnosed contact in 92% of the touching cases using the NewTom 3G images, and they correctly diagnosed no contact in 75% of the cases that were not touching. Sixty-seven percent of the orthodontists’

diagnoses of “touching” were correct using the “NewTom Imaging” modality, and 50% of their diagnoses of “not touching” were correct. The radiologists were correct in 85% of their “touching” diagnoses and 86% of their “not touching” diagnoses using the NewTom images.

Resorption Diagnosis: *canine has resorbed/has not resorbed lateral incisor*

All ten cases were included in the analysis of the examiners’ accuracy in diagnosing the presence or absence of resorption of the lateral incisor root. In total, there were 110 orthodontist observations and 60 radiologist observations for each imaging modality. For all pairwise comparisons, the Breslow-Day test was statistically significant ($p = 0.0030$), indicating that the relationship between accuracy and group or modality was not the same for all dry skull case simulations. For this reason, each case was considered separately, making the effective number of observations per case eleven for the orthodontists and six for the radiologists.

Traditional Imaging: Orthodontists versus Radiologists

In the comparison of the orthodontists’ and radiologists’ diagnoses of root resorption from the “Traditional Imaging” modality, there was marginally piece-wise statistically significant evidence that the orthodontist group and the radiology group differed in accuracy rates. The case by case results are shown in Results Table 6. A statistically significant inter-group difference in accuracy of resorption diagnoses was found for only two case simulations. In Case 1, which did not have resorption, the radiology group had a higher accuracy rate (Fisher’s exact test p -value = 0.0427). In Case 3, which also did not have resorption, the orthodontic group had a higher accuracy rate (Fisher’s exact test p -value = 0.0276). For all other cases, there were no statistically significant differences between the

two groups. The pattern of which observer group had a higher accuracy rate was not consistent for this question.

Results Table 6

Accuracy of Resorption Diagnosis				
Traditional Imaging Modality: Orthodontists versus Radiologists				
Case Number	Truth	Percent Correct (%)		p-value
		Ortho (n=11)	Rad (n=6)	
1	NR	45	100	0.0427
2	NR	55	83	0.3334
3	NR	91	33	0.0276
4	NR	45	83	0.3043
5	NR	55	100	0.1023
6	R palatal	18	0	0.5147
7	R buccal	0	0	1
8	R apical	82	100	0.5147
9	R buccal	18	0	0.5147
10	R palatal	73	50	0.6

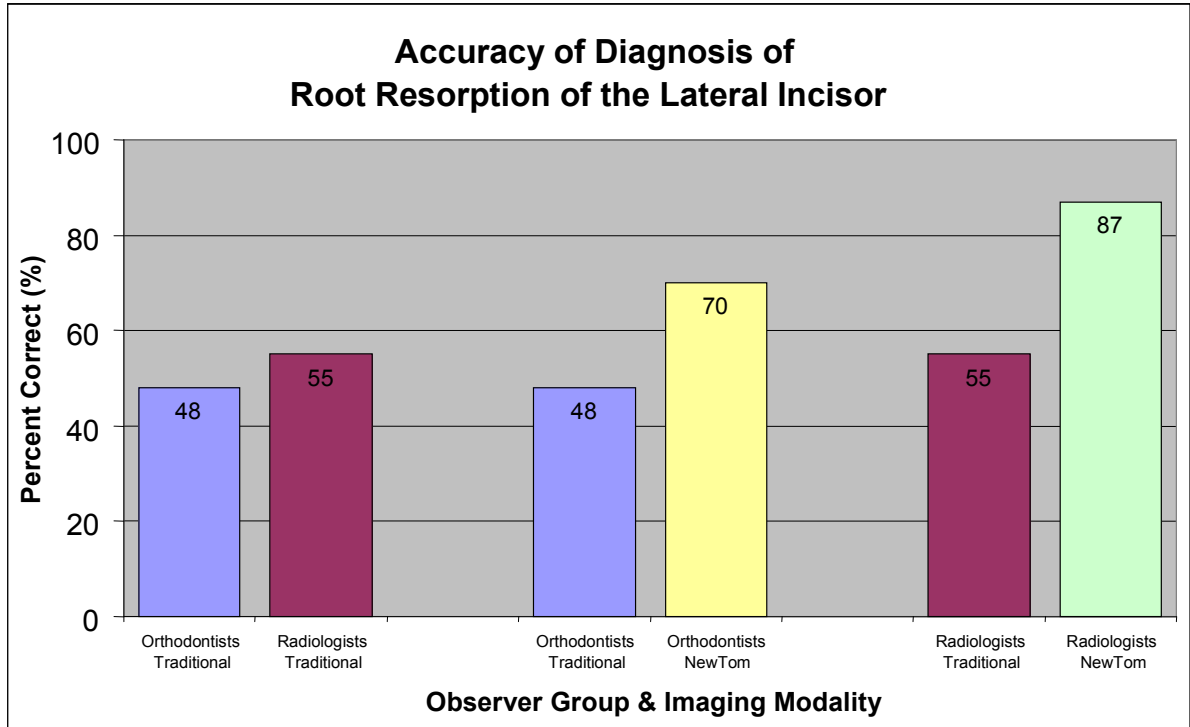
NR = not resorbed

R = resorbed (location)

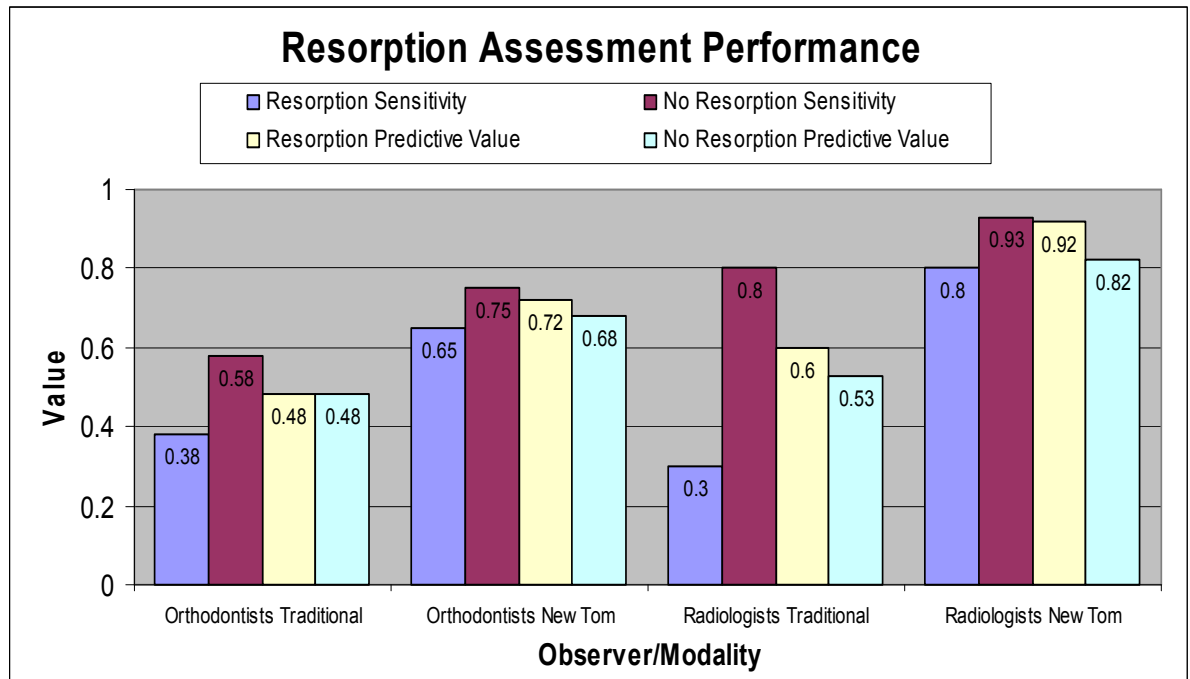
Overall accuracy rates, sensitivity ratios and predictive values showed that both groups of examiners performed poorly in their “Traditional Imaging” diagnosis of lateral incisor root resorption. Results are shown in Results Graphs 5 and 6. Using the traditional images, the orthodontists’ overall accuracy rate for resorption diagnoses was 48%, and the radiologists’ overall accuracy rate was 55%. Orthodontists correctly diagnosed 38% of the resorbed cases and 58% of the not resorbed cases that they examined, and radiologists correctly diagnosed 30% of the resorbed cases and 80% of the not resorbed cases that they examined. The orthodontists’ “resorbed” diagnoses were correct 48% of the time, and their “not resorbed” diagnoses were correct 48% of the time. The radiologists’ “resorbed”

diagnoses were correct 60% of the time, and their “not resorbed” diagnoses were correct 53% of the time.

Results Graph 5



Results Graph 6



The case by case results for the “Traditional Imaging” modality (Results Table 6) showed that both groups of examiners had difficulty detecting root resorption when it was present in the case simulations, especially when the resorption cavities were on a midroot surface. The lateral incisors of Cases 6, 7, 8, 9, and 10 had resorption defects. The resorption cavities were on buccal or palatal surfaces of the middle third of the incisor root for Cases 6, 7, 9, and 10. In three of those four midroot resorption cases, examiners were highly inaccurate in their traditional imaging diagnoses. For Case 6, two orthodontists and zero radiologists were correct using the traditional images. The same was true for Case 9. For Case 7, all observers were inaccurate. Added together, only four of 33 orthodontist diagnoses and zero of 18 radiologist diagnoses were correct for Cases 6, 7, and 9 using the traditional images. The examiners were more accurate with the fourth midroot resorption case, Case 10, with 73% of the orthodontists and 50% of the radiologists diagnosing the case correctly. Resorption was simulated in the apical third of the incisor root for Case 8, and both groups of examiners were highly accurate in their “Traditional Imaging” diagnoses of this case.

Orthodontists: Traditional Imaging versus NewTom Imaging

In the comparison of the orthodontists’ use of the two different imaging modalities for root resorption diagnosis, there was marginally piece-wise statistically significant evidence that the accuracy rate was higher with the NewTom scans than with the traditional images. The case by case results are shown in Results Table 7. In Cases 6, 7, and 9, the NewTom diagnoses had higher accuracy rates (Fisher’s exact test p-values 0.0300, <0.0001, and 0.0300, respectively). For all other cases, there was no statistically significant difference

between the two modalities. The pattern of which modality had a higher accuracy rate was not consistent for this question.

Results Table 7

Accuracy of Resorption Diagnosis				
Orthodontist Judge Group: Traditional versus NewTom Modality				
Case Number	Truth	Percent Correct (%)		p-value
		Trad (n=11)	NewTom (n=11)	
1	NR	45	91	0.0635
2	NR	55	55	1
3	NR	91	91	1
4	NR	45	73	0.387
5	NR	55	64	1
6	R palatal	18	73	0.03
7	R buccal	0	91	0.000034
8	R apical	82	36	0.0805
9	R buccal	18	73	0.03
10	R palatal	73	55	0.6594

NR = not resorbed

R = resorbed (location)

The orthodontists were considerably more accurate at diagnosing root resorption from the NewTom 3G images than they were using the traditional image series. Using the traditional images, the orthodontists correctly diagnosed 38% of the resorbed cases and 58% of the not resorbed cases that they examined. Using the NewTom images, the orthodontists correctly diagnosed 65% of the resorbed cases and 75% of the not resorbed cases.

Accuracy rates of individual examiners for diagnosis of lateral incisor root resorption are shown in Results Table 8. Orthodontists' accuracy rates for "Traditional Imaging" resorption diagnosis ranged from 20% to 80%, with six of the eleven orthodontist examiners scoring at or below 40% accurate. Using the "NewTom Imaging" modality, the

orthodontists' accuracy rates for resorption diagnosis ranged from 20% to 100%, and only one of the orthodontists was less than 60% accurate.

Results Table 8

Resorption Assessment by Orthodontic Examiner							
Orthodontist	Traditional Imaging			Orthodontist	NewTom Imaging		
	% Correct Resorbed	% Correct Not Resorbed	% Correct Total		% Correct Resorbed	% Correct Not Resorbed	% Correct Total
8	60	100	80	11	100	100	100
11	60	100	80	5	80	100	90
1	40	80	60	1	100	60	80
7	20	100	60	3	60	100	80
10	20	100	60	8	60	100	80
3	60	20	40	6	100	40	70
5	40	40	40	7	40	100	70
6	20	60	40	2	40	80	60
2	40	20	30	9	80	40	60
4	20	20	20	10	20	100	60
9	40	0	20	4	40	0	20
Average	38.2	58.2	48.2	Average	65.5	74.5	70.0

Radiologists: Traditional Imaging versus NewTom Imaging

In the comparison of the radiologists' use of the two different imaging modalities for root resorption diagnosis, there was marginally piece-wise statistically significant evidence that the accuracy rate was higher with the NewTom scans than with the traditional images. The case by case results are shown in Results Table 9. In case 1, both imaging modalities were associated with all correct answers. In cases 6, 7, and 9, the "NewTom Imaging" diagnoses had higher accuracy rates (Fisher's exact test p -value = 0.0152, 0.0152, and 0.0152, respectively). For all other cases, there was no statistically significant difference between the two modalities. The pattern of which modality had a higher accuracy rate was not consistent for this question.

Results Table 9

Accuracy of Resorption Diagnosis				
Radiologist Judge Group: Traditional versus NewTom Modality				
Case Number	Truth	Percent Correct (%)		p-value
		Trad (n=6)	NewTom (n=6)	
1	NR	100	100	1
2	NR	83	100	1
3	NR	33	100	0.0606
4	NR	83	83	1
5	NR	100	83	1
6	R palatal	0	83	0.0152
7	R buccal	0	83	0.0152
8	R apical	100	83	1
9	R buccal	0	83	0.0152
10	R palatal	50	67	1

NR = not resorbed

R = resorbed (location)

The radiologists were considerably more accurate at diagnosing root resorption from the NewTom 3G images than they were using the traditional image series. Using the traditional images, the radiologists correctly diagnosed 30% of the resorbed cases and 80% of the not resorbed cases that they examined. Using the NewTom modality, the radiologists correctly diagnosed 80% of the resorbed cases and 93% of the not resorbed cases. Accuracy rates of individual examiners for diagnosis of lateral incisor root resorption are shown in Results Table 10. Radiologists' accuracy rates for "Traditional Imaging" resorption diagnosis ranged from 40% to 70%. With the "NewTom Imaging" modality, the radiologists' accuracy rates for resorption diagnosis ranged from 60% to 100%, with three of the six radiologists scoring 100% accuracy.

Results Table 10

Resorption Assessment by Radiologic Examiner							
Radiologists	Traditional Imaging			Radiologist	NewTom Imaging		
	% Correct Resorbed	% Correct Not Resorbed	% Correct Total		% Correct Resorbed	% Correct Not Resorbed	% Correct Total
3	40	100	70	1	100	100	100
1	20	100	60	2	100	100	100
6	40	80	60	6	100	100	100
4	20	80	50	3	80	100	90
5	20	80	50	5	40	100	70
2	40	40	40	4	60	60	60
Average	30.0	80.0	55.0	Average	80.0	93.3	86.7

Intra-examiner Reliability

Analysis of repeated cases for intra-examiner reliability showed 100% agreement regardless of group or modality.

DISCUSSION

Localization Diagnosis

Comparison of the accuracy results for buccopalatal localization of impacted canines revealed that traditional radiographic methods were effective when used expertly, but that NewTom imaging took some of the confusion out of localization diagnosis. Analysis of the canine-to-lateral incisor localization data revealed that the radiologists used the traditional images more effectively than the orthodontists, scoring an overall accuracy rate of 85% correct diagnoses, compared to 65% for orthodontists ($p = 0.0075$). The orthodontists diagnosed buccopalatal location more effectively from the NewTom images than the traditional images, improving to 95% accuracy with the NewTom modality ($p < 0.0001$). The radiologists improved to 90% accuracy with the NewTom images, but the difference in accuracy rates between imaging modalities for the radiologists was not statistically significant.

It was expected that the radiologists would outperform the orthodontists at traditional radiographic localization due to their specialty training and greater familiarity with parallax techniques. The radiologists performed well, with four of the six examiners scoring perfect scores for traditional localization accuracy, while the other two scored 70% and 40%, respectively. The overall success of the radiologists demonstrated that sufficient information was provided by the traditional images to make accurate localization possible. However, their results showed that even well-trained examiners were prone to errors in diagnosing canine location using traditional methods. Additionally, the failure of the orthodontists to

perform at the same level as the radiologists demonstrated that traditional localization methods are subject to confusion and misinterpretation.

The orthodontists' traditional localization performance was interesting because most of the orthodontists were highly accurate in their localization diagnoses while others were highly inaccurate. Seven out of eleven orthodontists were more than 90% accurate at buccopalatal localization from traditional radiographs, reinforcing the evidence that traditional methods could be used successfully to locate impacted canines. The success of those orthodontists was offset, however, by two orthodontists who were perfectly inaccurate, misdiagnosing all ten cases, along with two others who were accurate in only 10% and 30% of their diagnoses.

The dichotomous character of the orthodontists' localization results suggested that most of the orthodontists possessed a good understanding of the principles of parallax localization while a few of them were confused. The remarkable inaccuracy of the three orthodontists who scored 0%, 0%, and 10% suggests one of two possibilities. Either the examiners misunderstood the rules of parallax localization, reading the changes in the images correctly but interpreting them to mean the wrong thing, or they were confused by the ordinal scale of the diagnostic questionnaire and systematically recorded the opposite diagnosis to the one they intended. It is unlikely that the diagnostic questionnaire was to blame for the poor performance, because the orthodontists did not repeat their poor localization performances with the NewTom modality. In fact, three of them were perfectly accurate, and the fourth scored 80% correct.

Thus, the evidence points to confusion about the rules of parallax localization as the factor that confounded the orthodontists' effectiveness at traditional radiographic

localization. This confusion may result from the two different “rules” that explain the principles of parallax localization, the SLOB rule and the Buccal Object Rule. Though the two rules describe the same phenomenon, the Same Lingual Opposite Buccal rule relates changes in imaged objects to movements of the X-ray tube head, while the Buccal Object Rule relates changes in imaged objects to changes in the angulation of the X-ray beam. Since the change in beam angulation is always opposite to the movement of the X-ray tube head, the two rules actually explain the same thing. However, if one misuses Buccal Object Rule principles to interpret changes due to movement of the X-ray tube head, their diagnoses of location will be perfectly backward. The same is true if one uses SLOB rule principles to interpret changes due to different angulations of the X-ray beam.

For the study, examiners were instructed on parallax localization in the language of the Buccal Object Rule, and a self-test was provided to allow examiners to assess their competency with parallax localization for themselves. Examiners who desired additional instruction on the Buccal Object Rule were directed to a computer-based learning module on the subject. The goal of this protocol was to allow the examiners to proceed with the study when they judged themselves ready to go forward. It was hoped that this procedure would provide “real world” results, since practicing clinicians would have access to instructional materials if they desired them, but would not be subject to an external test prior to diagnosing impacted canines. The procedure may have created confusion, however, if the orthodontic examiners understood parallax localization in the verbiage of the SLOB rule and failed to recognize the differences of the Buccal Object Rule.

In contrast to the results for “Traditional Imaging” localization, there was no evidence of confusion in the localization results for the “NewTom Imaging” modality. Using the

NewTom images, 95% of the orthodontists' localization diagnoses were correct, with eight of the eleven orthodontists demonstrating perfect accuracy and all orthodontists scoring at least 80%. Similarly, the radiologists were highly effective at canine localization from the NewTom images, scoring an overall accuracy rate of 90%, with all radiologists scoring at or above 80% accuracy.

The only surprising finding with the “NewTom Imaging” localization results was that the radiologists did not perform better than they did. The radiologists were familiar with the NewTom imaging modality, and they were allowed to use NewTom software to make whatever views and slices they needed to diagnose the cases from the NewTom 3G scans. As a result, it was expected that the radiologists would be nearly 100% accurate for buccopalatal localization using the NewTom images. While the radiologists were highly effective at NewTom localization, scoring an overall accuracy of 90%, they did not approach 100% accuracy as a group. In fact, only two of the six radiologists were 100% accurate. The radiologists did not seem to benefit greatly from the ability to manipulate the NewTom software on their own. They had six NewTom misdiagnoses of canine location in all, the same number of localization misdiagnoses that the eleven orthodontists had from their sample of images from the NewTom scans.

Perspective

Buccopalatal localization is the primary diagnostic task of radiographic examination of impacted maxillary canines, and evidence suggests that traditional methods of canine localization have shortcomings that affect diagnostic accuracy. Modern, three-dimensional imaging modalities may enable clinicians to make more accurate diagnoses of canine location. The purpose of the study was to evaluate the effectiveness of orthodontists and

radiologists at diagnosing the buccopalatal location of simulated impacted canines from a traditional radiographic series and a series of images obtained from a NewTom 3G cone beam CT scan.

The radiographic information provided to the examiners in the traditional image series was probably greater in quantity and quality than what is customary in a clinical setting. The traditional series of one panoramic, two periapical, and two occlusal views for each case included more views that one would expect to obtain clinically for localization of an impacted maxillary canine. A typical clinical localization series would probably include a parallax series of either periapical views or occlusal views, but not both. As a result, the amount of information provided to the examiners in the study may have been greater than what is customary in a clinical setting. In addition, in the study, retake exposures of panoramic and intraoral radiographs were made until good quality images were obtained for each case. Images were retaken to eliminate cone cuts and ensure that the anatomy of interest was well-demonstrated in the image field of view. In the clinical setting, radiation hygiene principles may discourage clinicians from retaking exposures and encourage them to settle for images of less-than-ideal diagnostic quality.

Providing examiners with more and higher quality radiographic information about the case simulations than is customary for clinical diagnosis would be expected to allow the examiners to perform at a higher level of localization accuracy than they would achieve in a clinical setting. That five orthodontists and four radiologists were perfectly accurate in their traditional localization diagnoses may suggest that such a scenario played out. However, the overall accuracy rates of the examiner groups in our study did not surpass the published

accuracy rates reported in the literature for traditional radiographic localization of impacted maxillary canines.

Accuracy rates for various methods of canine localization as reported in the literature are listed in Discussion Table 1. The highest accuracy rate for canine localization reported in the literature was found by Ericson and Kurol in their use of a horizontal parallax localization series ⁷. The horizontal parallax accuracy rate reported in that study of 92% may have been inflated, however, by the authors' choice of their gold standard for canine location. The authors combined the information provided by panoramic, axial vertex, and periapical radiographs to determine the gold standard position of the canines, and since the periapical radiographs were found to provide the best assessment of canine location, it is logical to assume that the periapical findings may have exerted an undue influence on the definition of the gold standard. As a result, a sort of self-fulfilling prophecy may have been at work, in which the periapical radiographs were highly accurate, in part, because they strongly influenced the gold standard.

Discussion Table 1

Accuracy Rates of Various Localization Methods										
Author(s)	Year	# Cases	# Buccal	# Palatal	Number of Observers	Localization Method	Gold Standard	Overall Accuracy Rate	Buccal Sensitivity	Palatal Sensitivity
Ericson & Kurol	1987	125	NR	NR	NR	Panoramic*	Combination	29%	NR	NR
Ericson & Kurol	1987	125	NR	NR	NR	Axial Vertex*	Combination	72%	NR	NR
Ericson & Kurol	1987	125	NR	NR	NR	Horizontal parallax--Periapical**	Combination	92%	NR	NR
Mason et al.	2001	133	38	87	6	Vertical Parallax--Panoramic* & Occlusal*	Surgical note	76%	46%	89%
Mason et al.	2001	133	38	87	6	Panoramic*	Surgical note	66%	11%	89%
Armstrong et al.	2003	43	9	34	6	Vertical Parallax--Panoramic* & Occlusal*	Surgical note	68%	63%	69%
Armstrong et al.	2003	43	9	34	6	Horizontal Parallax--Occlusal* & Periapical*	Surgical note	83%	63%	88%
Fox et al.	1995	139	NR	NR	NR	Panoramic*	Vertex Occlusal*	NR	NR	82%
Chaushu et al.	1999	160	NR	NR	NR	Panoramic*	Surgical note	88%	NR	NR
Herring	2006	10***	5	5	11 (ortho)	Panoramic*, Periapical**, Occlusal**	Case setup	65%	62%	69%
Herring	2006	10***	5	5	6 (rad)	Panoramic*, Periapical**, Occlusal**	Case setup	85%	77%	93%
Herring	2006	10***	5	5	11 (ortho)	NewTom 3G--selected images	Case setup	95%	93%	96%
Herring	2006	10***	5	5	6 (rad)	NewTom 3G--using NewTom software	Case setup	90%	83%	97%

NR = Not Reported
 * = single film
 ** = two or more films
 *** = dry skull case simulations

The findings of Mason et al.⁵³ and Armstrong et al.² place the diagnostic accuracy of vertical and horizontal parallax localization methods in the range of 68-83%. Similarly, Mason et al.⁵³ and Chaushu et al.⁵¹ found localization from panoramic radiographs alone to be 66-88% accurate. All of these studies used the operative notes from canine exposure as their gold standard for canine location. Surgical findings may be considered an excellent and unbiased gold standard, comparable to the case setup gold standard used in the present study. In the present study, orthodontists were 65% accurate overall for traditional localization and radiologists were 85% accurate overall. Thus, it is evident that they performed at a level comparable to the accuracy rates reported in clinical studies, but they did not outperform the clinical studies, despite having a superior series of diagnostic images.

Two authors of localization studies have reported that traditional localization is more difficult for buccally impacted canines than palatally impacted canines^{2, 53}. The present study also found that examiners had greater difficulty in diagnosing buccal canines versus palatal ones. The fact that buccal canines are more difficult to localize than palatal ones may make direct comparison of the overall accuracy findings of the present study to published clinical studies impossible. Since palatal impaction is far more common than buccal impaction, palatal canines greatly outnumbered buccal canines in the published clinical studies. In the present study, however, there were an equal number of buccal and palatal canine case simulations. The greater proportion of buccal canines in the present study relative to the clinical studies may have deflated the overall accuracy rates for traditional localization in our study relative to the others. It is likely that the accuracy rates of the clinical studies would have been lower if the number of buccal canines were equal to the number of palatal ones,

just as it is likely that the accuracy rates of the present study would be higher if palatal canines outnumbered buccal canines.

The accuracy rates for localization of impacted canines from NewTom 3G images were generally higher than the accuracy rates for traditional localization published in the literature. The orthodontist and radiologist examiners in the study were 95 and 90% accurate in their NewTom diagnoses of canine location, respectively. The only report in the literature of a traditional localization method performing to that level of accuracy was the 92% accuracy rate shown by Ericson and Kurol for horizontal parallax using periapical radiographs, but the gold standard for that study may have been compromised.⁷ Armstrong et al.² found horizontal parallax localization using one occlusal and one periapical to be 83% accurate, and Chaushu et al.⁵¹ showed 88% accuracy for their method of localization from a single panoramic radiograph, but these two studies were the only ones in which traditional localization resulted in accuracy rates that approached those found in the present study for NewTom localization. No reports of the accuracy of impacted canine localization using Cone Beam CT imaging modalities were discovered in the literature review, so direct comparisons of our results with other Cone Beam CT studies may not be made.

Proximity Diagnosis

Results for the proximity question showed that the “NewTom Imaging” modality was clearly superior to the “Traditional Imaging” modality for diagnosing contact between impacted canines and the roots of lateral incisors in the case simulations. Examiners were unable to diagnose proximity effectively using the traditional image series, but their diagnostic accuracy improved significantly with the “NewTom Imaging” modality.

It was expected that examiners would have difficulty diagnosing contact between impacted canines and lateral incisor roots from traditional radiographs due to overlapping of structures in the two-dimensional images, and the results of the study confirmed this expectation. Overall accuracy rates for “Traditional Imaging” diagnosis of proximity were around 40% for both examiner groups, meaning that the examiners were wrong more often than they were right and less effective than chance at diagnosing whether or not the teeth were actually touching in the case simulations. Sensitivity values showed that examiners were no more successful at detecting contact when teeth were touching than they were at detecting space between the teeth when they were apart. Predictive values showed that both examiner groups had around a 50% chance that a diagnosis of “touching” was correct and around a 30% chance that a diagnosis of “not touching” was correct. These results suggested that the examiners tended to diagnose cases as “not touching” too often and failed to see contact between the teeth in the traditional images in cases in which the canine and lateral incisor were touching.

The orthodontic and radiologic examiner groups performed equally poorly at diagnosing proximity from the traditional images, indicating that specialty training in radiographic interpretation did not improve accuracy outcomes. This finding suggested that the traditional modality itself was inadequate for the diagnostic task and to blame for the examiners’ ineffectiveness at proximity assessment. Whereas the localization data showed some examiners to be highly accurate in their “Traditional Imaging” diagnoses of canine location, none of the examiners were particularly effective at diagnosing proximity from the traditional images. Only two of the orthodontists and one of the radiologists performed better than chance in their diagnoses of proximity from the traditional images. These

findings reinforced the evidence that traditional radiographic images may not hold the potential for highly accurate diagnosis of canine to incisor proximity.

Examiners' accuracy for diagnosing proximity improved substantially with the use of the "NewTom Imaging" modality. The orthodontic examiners' proximity diagnoses were correct one and one-half times more often with the NewTom images than they were with the traditional images. The radiologists improved to an even greater degree as their accuracy more than doubled using the NewTom modality. Whereas only two orthodontists performed better than chance at diagnosing proximity from the traditional images, seven of the eleven orthodontists exceeded 50% accuracy with the NewTom images, and four of the eleven had accuracy rates of 80% correct. Similarly, only one radiologist beat chance using the traditional modality, but all six were at least 70% accurate in their NewTom diagnoses of proximity. Four of the radiologists had accuracy rates of 90% with the NewTom images, misdiagnosing only one case each.

The orthodontists and radiologists followed different protocols for reviewing the NewTom images of the case simulations, so no direct comparisons may be made between the performances of the two groups for the NewTom modality. That said, the radiologists were able to achieve a higher level of diagnostic accuracy for proximity assessment using the NewTom modality than were the orthodontists. The high level of accuracy seen in the radiologists' results demonstrated that the NewTom imaging modality provided highly diagnostic information about the presence or absence of tooth-to-tooth contact in the case simulations. In addition, evidence suggests that the results may have underestimated the examiners' performance with the NewTom modality due to a problem with the setup of one case simulation, as discussed below.

Limitations

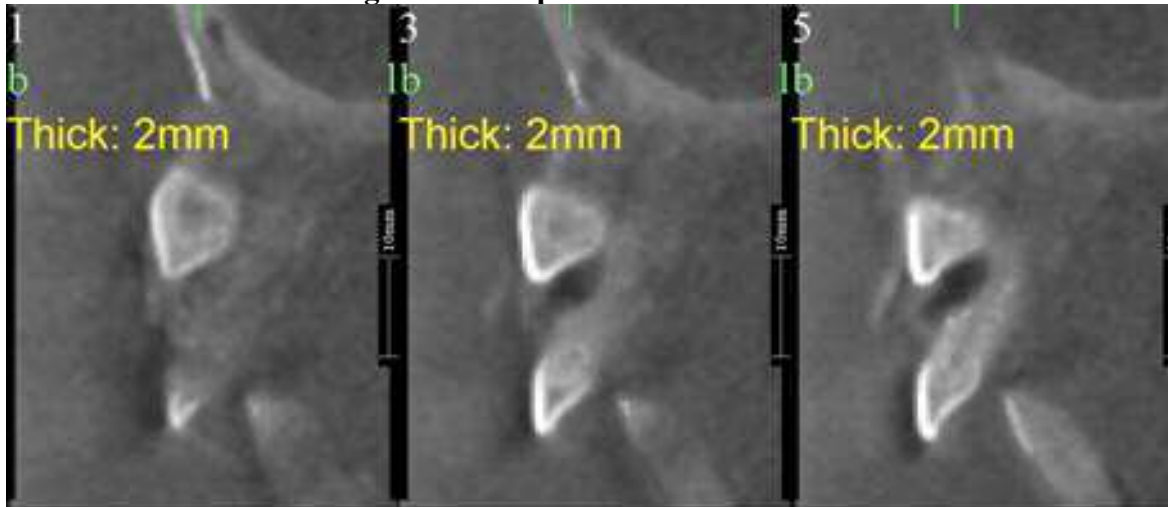
The gold standard for canine to lateral incisor proximity may have been compromised for at least one of the case simulations. For the localization and resorption parts of the study, the gold standards were definitive because the canines were definitely either buccal or palatal to the lateral incisor, and the lateral incisors were definitely either resorbed or not resorbed. For the proximity part of the study, the gold standard was less definitive, because the canine and incisor approximated each other internally in the simulations, and it was impossible to be certain that the case setup achieved its proximity objective.

In setting up the case simulations, the proximity of the impacted canines to the lateral incisors was controlled by the presence or absence of a Styrofoam shim placed between the canine crown and incisor root. For “touching” cases, the shim was not used, and the canine and incisor were squeezed together into contact. For “non touching” cases, the shim was placed in between the teeth at the level of the canine crown, but it may have been possible for the teeth to be unintentionally in contact at a level apical to the shim. Cases were considered to be not touching if the shim was used, but the presence of the shim did not actually rule out the possibility of contact between the teeth. Thus, the gold standard for proximity was not as definitive as those for the localization and resorption parts of the study.

Evidence from the NewTom images suggests that one of the case simulations that was setup with a shim and considered to be not touching may have actually had contact between the canine and the lateral incisor root. Discussion Figure 1 shows some of the NewTom images provided to the orthodontic examiners of Case #9, in which the canine was buccally positioned, the lateral incisor was resorbed, and there was supposed to be no contact

between the canine and incisor. The cross-sectional slices appear to show that the canine and incisor actually do touch at a level apical to the resorption defect on the incisor.

Discussion Figure 1: Sample NewTom Views for Case Nine



Using the NewTom images, Case #9 was diagnosed as “touching” by five of the six radiologists and nine of the eleven orthodontists, and these diagnoses were counted as incorrect in the data analysis. If those “touching” diagnoses had been counted as correct, the orthodontists’ accuracy for NewTom proximity assessment would have been 66%, and the radiologists’ accuracy for NewTom proximity assessment would have been 92%. In addition, if the “touching” diagnoses for Case #9 had not been counted as incorrect, the values for Not Touching Sensitivity and Touching Predictive Value would have been higher for both observer groups.

Perspective

Studies using CT imaging modalities have shown that contact between ectopically erupting maxillary canines and the roots of adjacent incisors is a common occurrence. Using conventional CT, Ericson and Kurol found that most erupting maxillary canines were in contact with the roots of adjacent incisors at some level. In their examination of 107 children with 156 ectopic canines, they found that 49% of normally erupting canines were in contact

with the roots of the lateral incisor and that ectopically erupting canines were in contact with lateral incisors 93% of time and central incisors 19% of the time.³⁴ Using cone beam CT, Walker et al. discovered that 17 of the 27 (63%) ectopic canines examined in their study were in contact with the roots of adjacent lateral incisors.³⁷

Effective diagnosis of the proximity of impacted canines to incisor roots should be important to orthodontists because close contact between the teeth may complicate treatment mechanics and has been found to be related to root resorption. If orthodontic eruption is to be attempted for resolution of an impacted canine, accurate knowledge of the canine's proximity to other structures would enable the orthodontist to select a path of eruption that minimizes the risk of iatrogenic damage and maximizes the efficiency of tooth movement. Diagnosis of close contact between the teeth should elevate suspicion of incisor root resorption, because evidence suggests that resorption associated with ectopic canines is probably caused by the pressure of physical contact between the erupting canine and the incisor root.⁷⁴ Ericson and Kurol found that resorbed incisor roots were more frequently seen when the canine crown was in contact with the incisor root than when there was no contact between the canine and incisor.³⁵ Of the 61 lateral incisors with some type of resorption reported in their study, 59 were in contact with the crowns of ectopic canines. Similarly, twelve of fourteen resorbed central incisors were in contact with the canine crowns.³⁵ Walker et al. also reported a correlation between the proximity of the impacted canine to the incisors and resorption of the incisor roots.³⁷

Several authors have reported anecdotal evidence of the superiority of CT imaging modalities over traditional plain-film radiography for assessing the proximity of impacted canines to adjacent incisor roots.^{37, 54, 55, 56, 58} However, no data on the accuracy of different

imaging modalities for diagnosing the proximity of impacted canines to incisor roots were found in the literature review. The findings of the current study demonstrated that traditional radiographic images were inadequate for effective diagnosis of proximity and quantified the diagnostic advantage offered by the NewTom 3G cone beam CT imaging modality. The results confirmed that NewTom imaging allowed visualization of contact between impacted canines and incisor roots, and when used by well-trained examiners, was highly accurate for the diagnosis of canine to incisor proximity.

Resorption Diagnosis

The results of the resorption assessment component of the study revealed that orthodontic and radiologic examiners were generally ineffective at diagnosing incisor root resorption in the case simulations from traditional radiographic images. The two groups of examiners were both around 50% accurate at diagnosing the presence or absence of lateral incisor root resorption from traditional images. Their accuracy was found to be statistically different for only two cases, both of which had intact, non-resorbed lateral incisors. The orthodontists outperformed the radiologists on one case, while the radiologists outperformed the orthodontists on the other. No differences were found for the other eight case simulations, which included all five of the cases with resorbed incisors.

The data suggested that the traditional imaging modality, and not examiner skill, was responsible for the poor diagnostic efficacy seen in the results. If the traditional imaging modality possessed the potential for high accuracy in resorption diagnosis, the experts in radiographic interpretation would have been expected to outperform the orthodontists in their diagnostic effectiveness. Not only did the radiologists not outperform the orthodontists, but few individual examiners demonstrated high accuracy rates at resorption diagnosis from the traditional images. Only two orthodontists and one radiologist had accuracy rates greater than 60% using the traditional modality. The “Traditional Imaging” modality was clearly inadequate for resorption assessment. Overall, for a true/false diagnostic question, the chances that either group of examiners were correct about a diagnosis of “resorbed” or “not resorbed” were about as good as a coin flip.

Using traditional images, examiners were especially ineffective at detecting resorption when it was present, with the orthodontists correctly diagnosing 38% of the

resorbed cases and the radiologists correctly diagnosing only 30%. Interestingly, these low accuracy scores for the resorbed cases may over-represent the effectiveness of traditional imaging for resorption detection because of the success the examiners had with two of the five resorbed cases. First, the orthodontic and radiologic examiners were highly accurate in diagnosing the one case in which resorption was simulated in the apical third of the lateral incisor. The examiners success with that case boosted their overall sensitivity for resorbed cases. Diagnoses of the apical resorption case accounted for 43% of the orthodontists' and 67% of the radiologists' correct diagnoses of resorption. If the apical resorption case were excluded from the data set, the sensitivity scores for detecting resorption in the four cases with damage to the middle third of the incisor roots would have been would have been 27% for the orthodontists and 12.5% for the radiologists.

Thus, the results showed that examiners had great difficulty at detecting resorption on buccal and palatal midroot surfaces of lateral incisors using traditional images. The examiners demonstrated very poor accuracy at diagnosing resorption in three of the four midroot resorption case simulations, Cases 6, 7, and 9. For these cases, the orthodontists made four correct diagnoses in 33 observations (12%), and the radiologists made zero correct diagnoses in 18 observations (0%). The examiners were more accurate for the fourth midroot resorption case, Case 10, in which the lateral incisor had resorption on the palatal surface of the root and was not in contact with the canine. Eight out of eleven orthodontists (73%) and three out of six (50%) radiologists correctly diagnosed resorption in the case. Examination of the traditional radiographic images for Case 10 revealed that the occlusal projection separated the root of the incisor from the canine and gave the suggestion of resorption in the density of the incisor root.

In the comparison of imaging modalities for orthodontic examiners, the NewTom modality was found to provide advantages to the orthodontists for diagnosing resorption of lateral incisor roots. Overall, the orthodontists improved from 48% accurate with the traditional images to 70% accurate with the NewTom images for resorption diagnosis, but this finding required further scrutiny since the pattern between accuracy rate and modality was not consistent for all case simulations. The orthodontic examiners were more accurate with the NewTom images than the traditional images for six of the ten case simulations. Their accuracy rates with the two modalities were equal for two cases, and they were more accurate with the traditional images for two cases.

Only three case simulations showed differences in diagnostic accuracy that were statistically significant between the traditional and NewTom imaging modalities, and those were the three midroot resorption cases that were so difficult to diagnose with the traditional images. This finding revealed that the overall gains in accuracy seen for the NewTom modality were mostly due to the orthodontists' greater effectiveness at detecting midroot resorption from the NewTom versus the traditional images. The orthodontists' accuracy rates for Cases 6, 7, and 9 improved more than sixfold, from 12% (four correct diagnoses out of 33 observations) with the traditional images to 79% (26 correct diagnoses out of 33 observations) with the NewTom images. The results demonstrated clearly the superiority of NewTom imaging for visualization of resorption on buccal and palatal surfaces of the middle third of incisor roots.

One surprising finding in the orthodontists' intermodality comparison was that the orthodontic examiners were more accurate in diagnosing the case simulation with apical resorption of the lateral incisor from the traditional modality than they were with the

NewTom scan. The difference was not statistically significant at our established alpha level, but it was close ($p = 0.0805$). This finding may be explained by the orthodontists' familiarity with using panoramic radiographs to detect apical resorption, which occasionally occurs as a byproduct of orthodontic tooth movement. Alternatively, the finding may be explained by an inadequacy of the sample of NewTom images provided to the orthodontists. The sample may not have included enough views that allowed a comparison of the length of the resorbed lateral incisor with that of its contralateral, or the orthodontists may not have known where to look for those views in the in the PowerPoint slides. The "NewTom Imaging" case presentations included thirteen views on one slide and four views on a second slide for each case. The orthodontists may have found it difficult to process all of the information in so many slices and reconstructions.

The comparison of imaging modalities for the radiologist examiners revealed that the radiologists were also more accurate at diagnosing resorption from the NewTom scans than they were from the traditional images. Overall, their accuracy rates improved from 55% to 87% between the traditional and NewTom modalities. Like the orthodontists, the pattern between accuracy rate and modality was not consistent for all case simulations, so the results bore further examination. The radiologists were more accurate with the NewTom modality than they were with the traditional modality for six of the ten case simulations. Their accuracy rates were the same for the two modalities for two cases, and they were better with the traditional modality for two cases. Also like the orthodontists, the only statistically significant differences between the modalities were seen for the difficult midroot resorption cases, Cases 6, 7, and 9.

The radiologists were perfectly inaccurate in their traditional imaging diagnoses of resorption for Cases 6, 7, and 9, with zero correct diagnoses in 18 observations of the cases. Using the NewTom modality, their accuracy improved to 83% correct for all three cases. Thus, the results suggested that the radiologists' gains in overall accuracy for the NewTom modality over the traditional modality were also heavily weighted by the midroot resorption cases.

In summary, the results of the comparison of the two imaging modalities for diagnosis of resorption were consistent for both the orthodontic and radiologic examiners. Overall, the most pertinent finding of the resorption assessment part of the present investigation may have been the evidence that both groups of examiners were terribly ineffective at detecting midroot resorption from traditional images and that both improved dramatically using NewTom images. It was expected that overlapped anatomical structures in traditional images would obscure the view of resorption on buccal and palatal midroot surfaces, but the degree of the examiners' failure was alarming. In the end, the data supported the conclusion that, if detection of midroot resorption in association with impacted canines was important to clinicians, that traditional images were inadequate for the task, and NewTom imaging offered a successful alternative modality.

Perspective

Studies that have examined impacted maxillary canines using three-dimensional computed tomography imaging modalities have found that incisor root resorption in association with ectopic canine eruption may occur with far greater frequency and severity than previously reported. In a large sample, Ericson and Kuroi found that 51 out of 107 subjects (48%) with impacted canines had incisor resorption.³⁴ Using conventional CT, they

found that the resorption defects varied greatly in location and extent, with the majority of the resorptions being located in the middle and apical thirds of the incisor roots and involving the pulp in severity.³⁴ A recent cone beam CT study by Walker et al. found resorption of the lateral incisor in association with 18 of 27 impacted canines (67%) in the sample.

Traditional radiographic examinations of impacted maxillary canines may fail to demonstrate resorption of adjacent incisor roots due to overlapping anatomy in the images. Previous studies in the literature have demonstrated that panoramic, periapical, and occlusal images are lacking in sensitivity for detection of root resorption when it is present. Discussion Table 2 compares the results of two different clinical studies for accuracy of resorption diagnosis to the results of the present investigation. The two clinical studies used the findings of a conventional CT scan as their gold standard for resorption diagnoses. The conventional CT findings may be viewed as a good gold standard, however, the resolution of conventional CT may have been inadequate for detection of minor resorptions in the studies.

Discussion Table 2

Accuracy of Root Resorption Diagnosis for Different Imaging Modalities									
Author(s)	Year	Imaging Modality	Gold Standard	# Adjacent Incisors	Accuracy Rate (Overall)	Resorbed Sensitivity	Not Resorbed Sensitivity	Resorbed Predictive Value	Not Resorbed Predictive Value
Ericson & Kurol	2000	Panoramic*, Periapical**, Occlusal*	Conventional CT	186 (central)	95%	38%	99%	83%	96%
Ericson & Kurol	2000	Panoramic*, Periapical**, Occlusal*	Conventional CT	180 (lateral)	80%	46%	95%	81%	80%
Ericson & Kurol	2000	Panoramic*, Periapical**, Occlusal*	Conventional CT	366 (total)	88%	45%	98%	82%	88%
Freisfeld	1999	Panoramic*	Conventional CT	1200	83%	46%	89%	39%	91%
Herring (ortho)	2006	Panoramic*, Periapical**, Occlusal**	Case setup***	110	48%	38%	58%	48%	48%
Herring (rad)	2006	Panoramic*, Periapical**, Occlusal**	Case setup***	60	55%	30%	80%	60%	53%
Herring (all)	2006	Panoramic*, Periapical**, Occlusal**	Case setup***	170	51%	35%	66%	51%	50%
Herring (ortho)	2006	NewTom 3G--selected images	Case setup***	110	70%	65%	75%	72%	68%
Herring (rad)	2006	NewTom 3G--using NewTom software	Case setup***	60	87%	80%	93%	92%	82%

* = single film
 ** = two or more films
 *** = dry skull case simulations

Ericson and Kurol found a traditional series of radiographs including one panoramic view, two periapical views, and one occlusal view to be 88% accurate overall for diagnosis of resorption in the roots of 366 central and lateral incisors adjacent to ectopic canines.³⁴

Closer examination of the data revealed that the traditional series was only 45% accurate for revealing resorption when it was present, however, because the clinical sample included a large number of intact incisors that were diagnosed accurately 98% of the time.³⁴ Freisfeld et al. found one panoramic radiograph to be 83% accurate for resorption diagnosis in a sample of 1200 incisors adjacent to ectopic canines.⁵⁹ Again, the sensitivity of the panoramic radiograph for detecting root resorption when it was present was low at 46%, but the overall accuracy scores were buoyed by a large number of not-resorbed incisors that were correctly diagnosed.

The results of the present in vitro study complement those of the clinical studies nicely. The gold standard in the study was excellent. The presence or absence of resorption in the case simulations was a known factor, not subject to error like the proximity setup. The simulated resorption cavities that were excavated in the incisor roots were likely different in shape and contour from natural resorptions, but they were large in size and extended into the pulp chamber, making a significant defect for the examiners to attempt to detect in the radiographs.

In our investigation, the overall accuracy rate for all examiners at resorption diagnosis from the traditional radiographic series was 51%. The sensitivity of the examiners at detecting resorption when it was present was 35%. The lower overall accuracy rate seen in the present study in comparison to the clinical studies may be explained by the equal number of resorbed and not resorbed cases in the present study. The low accuracy for resorbed cases was not balanced by a large number of correctly diagnosed not resorbed cases in our study, so the overall accuracy rate was lower than the clinical studies.

The low accuracy for resorbed cases seen in our study may also reflect the high ratio of midroot resorption cases to apical tip resorption cases in the sample. Four case simulations in the study had resorption of the middle third of the incisor roots while only one had resorption of the apical tip. The data demonstrated clearly that both groups of examiners had very poor accuracy for diagnosis of the midroot resorption cases, which was responsible for the low overall accuracy rate for traditional resorption diagnosis. Ericson and Kurol reported the location of root resorptions on lateral incisors in their study, and apical tip resorption was seen in 31% of their 58 cases while the rest of the incisors were resorbed on apical third (12%), middle third (43%), and cervical third (5%) midroot surfaces. Thus, a greater percentage of apical tip resorption cases in their sample may have contributed to their higher sensitivity for resorbed cases.

LIMITATIONS

The present study used dry skull simulations to represent cases of maxillary canine impaction, and the findings of the study were generalizable to clinical practice only inasmuch as the simulated cases, and the radiographic and CBCT images made of the cases, accurately reflected what is commonplace in the diagnosis of clinical patients. Only ten different arrangements of maxillary canine impaction were simulated, and the full spectrum of impacted canine anatomy was not represented in the sample of cases. The findings of the study may not apply to clinical cases with a different or more complicated anatomy than what is included in the sample. The simulated cases were true to life in that they were constructed of human teeth and bones, but they were devoid of soft tissue, and additional materials such as silicone wax and Styrofoam were used in their construction. It is unlikely that the materials used in the simulations either added or detracted from the examiners' ability to accurately diagnose the cases.

The traditional radiographic series included more images than would be customary for clinical diagnosis, with two parallax series for each case simulation. This factor may have inflated the accuracy of traditional diagnosis in the study over what may be expected clinically. The lack of soft tissues in the skull simulations probably lowered the clarity and resolution of the NewTom 3G images below what is achievable for clinical patients. This factor may have reduced the accuracy of NewTom diagnosis in the study compared to what would be possible for human subjects.

The findings of the study were generalizable if the examiners in the study were representative of practicing clinicians in the private sector. Eight of the eleven orthodontists in the sample were full time faculty members in a university setting. University orthodontists may have had less experience with diagnosing impacted canines than privately practicing orthodontists, due to having fewer patients in their faculty practices, as well as having access to experts in oral radiology for referral of difficult cases. With regard to the radiologic examiners in the study, the three graduate students in the sample may be expected to have less expertise in impacted canine diagnosis than practicing oral radiologists. These factors may have contributed to an overall reduction of diagnostic accuracy in the study for both imaging modalities in comparison to what may be possible for experienced clinicians.

Overall, the combination of a small number of cases and a small number of examiners meant that only large differences in diagnostic accuracy achieved statistical significance. This was especially true for the root resorption component of the study, in which each case needed to be analyzed separately, leaving only eleven orthodontist observations and six radiologist observations per case. If characterization of smaller differences between the imaging modalities were desired, a future study should include a greater number of case simulations and a greater number of examiners.

CONCLUSIONS

In conclusion, the results of the study found that examiners were more effective at diagnosing impacted maxillary canines using NewTom 3G images than they were using traditional radiographic images. For buccopalatal localization of canines, many examiners were highly accurate using traditional radiographs, but some examiners were obviously confused about how to interpret parallax effects to localize canines. NewTom imaging was superior for localization because it eliminated the confusion, with all examiners performing at a high level of accuracy. For diagnosis of proximity, excellent accuracy was not possible with traditional radiographs, but NewTom imaging significantly improved accuracy rates for both examiner groups. For detection of resorption, the results demonstrated that resorption on buccal or palatal mid-root surfaces was not detectable using traditional radiographs, whereas NewTom imaging dramatically increased resorption detection.

The results confirmed and quantified the advantages of cone beam CT imaging over traditional radiography purported in the literature for impacted maxillary canine diagnosis. In light of these advantages, cone beam CT imaging may be viewed as the imaging modality of choice for diagnosis of impacted maxillary canines.

REFERENCES

1. Kurol J. Early treatment of tooth-eruption disturbances. *Am J Orthod Dentofacial Orthop* 2002; 121(6): 588-591.
2. Armstrong C, Johnston C, Burden D, Stevenson M. Localizing ectopic maxillary canines--horizontal or vertical parallax? *Eur J Orthod* 2003; 25(6): 585-589.
3. Richardson G, Russell KA. A review of impacted permanent maxillary cuspids--diagnosis and prevention. *J Can Dent Assoc* 2000; 66(9): 497-501.
4. Thilander B, Jakobsson SO. Local factors in impaction of maxillary canines. *Acta Odontol Scand* 1968; 26(2): 145-168.
5. DACHI SF, HOWELL FV. A survey of 3, 874 routine full-month radiographs. II. A study of impacted teeth. *Oral Surg Oral Med Oral Pathol* 1961; 14: 1165-1169.
6. Ericson S, Kurol J. Radiographic assessment of maxillary canine eruption in children with clinical signs of eruption disturbance. *Eur J Orthod* 1986; 8(3): 133-140.
7. Ericson S, Kurol J. Radiographic examination of ectopically erupting maxillary canines. *Am J Orthod Dentofacial Orthop* 1987; 91(6): 483-492.
8. Aydin U, Yilmaz HH, Yildirim D. Incidence of canine impaction and transmigration in a patient population. *Dentomaxillofac Radiol* 2004; 33(3): 164-169.

9. Thilander B, Pena L, Infante C, Parada SS, de Mayorga C. Prevalence of malocclusion and orthodontic treatment need in children and adolescents in Bogota, Colombia. An epidemiological study related to different stages of dental development. *Eur J Orthod* 2001; 23(2): 153-167.
10. Becker A, Smith P, Behar R. The incidence of anomalous maxillary lateral incisors in relation to palatally-displaced cuspids. *Angle Orthod* 1981; 51(1): 24-29.
11. Stellzig A, Basdra EK, Komposch G. The etiology of canine tooth impaction--a space analysis. *Fortschr Kieferorthop* 1994; 55(3): 97-103.
12. Becker A, Gillis I, Shpack N. The etiology of palatal displacement of maxillary canines. *Clin Orthod Res* 1999; 2(2): 62-66.
13. Jacoby H. The etiology of maxillary canine impactions. *Am J Orthod* 1983; 84(2): 125-132.
14. Peck S, Peck L, Kataja M. The palatally displaced canine as a dental anomaly of genetic origin. *Angle Orthod* 1994; 64(4): 249-256.
15. Dewel BF. The Upper Cuspid: Its Development and Impaction. *The Angle Orthodontist* 1949; 19(2): 79-79-90.
16. Coulter J, Richardson A. Normal eruption of the maxillary canine quantified in three dimensions. *Eur J Orthod* 1997; 19(2): 171-183.
17. Pirinen S, Arte S, Apajalahti S. Palatal displacement of canine is genetic and related to congenital absence of teeth. *J Dent Res* 1996; 75(10): 1742-1746.

18. Baccetti T. A controlled study of associated dental anomalies. *Angle Orthod* 1998; 68(3): 267-274.
19. Peck S, Peck L, Kataja M. Prevalence of tooth agenesis and peg-shaped maxillary lateral incisor associated with palatally displaced canine (PDC) anomaly. *Am J Orthod Dentofacial Orthop* 1996; 110(4): 441-443.
20. Peck S, Peck L, Kataja M. Site-specificity of tooth agenesis in subjects with maxillary canine malpositions. *Angle Orthod* 1996; 66(6): 473-476.
21. Langberg BJ, Peck S. Tooth-size reduction associated with occurrence of palatal displacement of canines. *Angle Orthod* 2000; 70(2): 126-128.
22. Chaushu S, Sharabi S, Becker A. Dental morphologic characteristics of normal versus delayed developing dentitions with palatally displaced canines. *Am J Orthod Dentofacial Orthop* 2002; 121(4): 339-346.
23. Becker A, Chaushu S. Dental age in maxillary canine ectopia. *Am J Orthod Dentofacial Orthop* 2000; 117(6): 657-662.
24. Peck S, Peck L. Palatal displacement of canine is genetic and related to congenital absence of teeth. *J Dent Res* 1997; 76(3): 728-729.
25. Baccetti T. A clinical and statistical study of etiologic aspects related to associated tooth anomalies in number, size, and position. *Minerva Stomatol* 1998; 47(12): 655-663.
26. Leonardi R, Peck S, Caltabiano M, Barbato E. Palatally displaced canine anomaly in monozygotic twins. *Angle Orthod* 2003; 73(4): 466-470.

27. Becker A. In defense of the guidance theory of palatal canine displacement. *Angle Orthod* 1995; 65(2): 95-98.
28. McSherry P, Richardson A. Ectopic eruption of the maxillary canine quantified in three dimensions on cephalometric radiographs between the ages of 5 and 15 years. *Eur J Orthod* 1999; 21(1): 41-48.
29. Taylor RW. Eruptive abnormalities in orthodontic treatment. *Semin Orthod* 1998; 4(2): 79-86.
30. Bishara SE. Clinical management of impacted maxillary canines. *Semin Orthod* 1998; 4(2): 87-98.
31. Stewart JA, Heo G, Glover KE, Williamson PC, Lam EW, Major PW. Factors that relate to treatment duration for patients with palatally impacted maxillary canines. *Am J Orthod Dentofacial Orthop* 2001; 119(3): 216-225.
32. Ericson S, Kurol J. Incisor resorption caused by maxillary cuspids. A radiographic study. *Angle Orthod* 1987; 57(4): 332-346.
33. Ericson S, Kurol J. Resorption of maxillary lateral incisors caused by ectopic eruption of the canines. A clinical and radiographic analysis of predisposing factors. *Am J Orthod Dentofacial Orthop* 1988; 94(6): 503-513.
34. Ericson S, Kurol PJ. Resorption of incisors after ectopic eruption of maxillary canines: a CT study. *Angle Orthod* 2000; 70(6): 415-423.

35. Ericson S, Kurol J. Incisor root resorptions due to ectopic maxillary canines imaged by computerized tomography: a comparative study in extracted teeth. *Angle Orthod* 2000; 70(4): 276-283.
36. Rimes RJ, Mitchell CN, Willmot DR. Maxillary incisor root resorption in relation to the ectopic canine: a review of 26 patients. *Eur J Orthod* 1997; 19(1): 79-84.
37. Walker L, Enciso R, Mah J. Three-dimensional localization of maxillary canines with cone-beam computed tomography. *Am J Orthod Dentofacial Orthop* 2005; 128(4): 418-423.
38. Postlethwaite KM. Resorption of premolar roots by ectopic canines. *Br Dent J* 1989; 167(11): 397-398.
39. Newcomb M. Recognition and Interception of Aberrant Canine Eruption. *The Angle Orthodontist* 1959; 29(3): 161-161-168.
40. Ericson S, Kurol J. Early treatment of palatally erupting maxillary canines by extraction of the primary canines. *Eur J Orthod* 1988; 10(4): 283-295.
41. Power SM, Short MB. An investigation into the response of palatally displaced canines to the removal of deciduous canines and an assessment of factors contributing to favourable eruption. *Br J Orthod* 1993; 20(3): 215-223.
42. Shapira Y, Kuffinec MM. Early diagnosis and interception of potential maxillary canine impaction. *J Am Dent Assoc* 1998; 129(10): 1450-1454.

43. Ngan P, Hornbrook R, Weaver B. Early Timely Management of Ectopically Erupting Maxillary Canines. *Seminars in Orthodontics* 2005; 11: 152-152-163.
44. Ericson S, Kurol J. Longitudinal study and analysis of clinical supervision of maxillary canine eruption. *Community Dent Oral Epidemiol* 1986; 14(3): 172-176.
45. Sawamura T, Minowa K, Nakamura M. Impacted teeth in the maxilla: usefulness of 3D Dental-CT for preoperative evaluation. *Eur J Radiol* 2003; 47(3): 221-226.
46. Clark CA. A method of ascertaining the position of unerupted teeth by means of film radiographs. *Proc Royal Soc Med (Odontological section)* 1909; 3: 87-87-90.
47. Richards AG. The buccal object rule. *Dent Radiogr Photogr* 1980; 53(3): 37-56.
48. Jacobs SG. Localization of the unerupted maxillary canine: how to and when to. *Am J Orthod Dentofacial Orthop* 1999; 115(3): 314-322.
49. Wolf JE, Mattila K. Localization of impacted maxillary canines by panoramic tomography. *Dentomaxillofac Radiol* 1979; 8(2): 85-91.
50. Fox NA, Fletcher GA, Horner K. Localising maxillary canines using dental panoramic tomography. *Br Dent J* 1995; 179(11-12): 416-420.
51. Chaushu S, Chaushu G, Becker A. The use of panoramic radiographs to localize displaced maxillary canines. *Oral Surg Oral Med Oral Pathol Oral Radiol Endod* 1999; 88(4): 511-516.

52. Chaushu S, Chaushu G, Becker A. Reliability of a method for the localization of displaced maxillary canines using a single panoramic radiograph. *Clin Orthod Res* 1999; 2(4): 194-199.
53. Mason C, Papadakou P, Roberts GJ. The radiographic localization of impacted maxillary canines: a comparison of methods. *Eur J Orthod* 2001; 23(1): 25-34.
54. Chaushu S, Chaushu G, Becker A. The role of digital volume tomography in the imaging of impacted teeth. *World J Orthod* 2004; 5(2): 120-132.
55. Preda L, La Fianza A, Di Maggio EM, Dore R, Schifino MR, Campani R, Segu C, Sfondrini MF. The use of spiral computed tomography in the localization of impacted maxillary canines. *Dentomaxillofac Radiol* 1997; 26(4): 236-241.
56. Bodner L, Sarnat H, Bar-Ziv J, Kaffe I. Computed tomography in the management of impacted teeth in children. *ASDC J Dent Child* 1994; 61(5-6): 370-377.
57. Cernochova P, Kanovska K, Krupa P. Morphology and position of the root apex in impacted maxillary canines. *Scripta Medica* 2003; 76(1): 9-9-20.
58. Schmuth GP, Freisfeld M, Koster O, Schuller H. The application of computerized tomography (CT) in cases of impacted maxillary canines. *Eur J Orthod* 1992; 14(4): 296-301.
59. Freisfeld M, Dahl IA, Jager A, Drescher D, Schuller H. X-ray diagnosis of impacted upper canines in panoramic radiographs and computed tomographs. *J Orofac Orthop* 1999; 60(3): 177-184.

60. Southall PJ, Gravely JF. Radiographic localization of unerupted teeth in the anterior part of the maxilla: a survey of methods currently employed. *Br J Orthod* 1987; 14(4): 235-242.
61. Becker A. *The Orthodontic Treatment of Impacted Teeth*. St Louis, MO: Mosby, 1998.
62. Goaz PW, White SC. *Oral Radiology: Principles and Interpretation*. 3rd, St. Louis, MO: Mosby, 1994.
63. Friedland B. Clinical radiological issues in orthodontic practice. *Semin Orthod* 1998; 4(2): 64-78.
64. Gavel V, Dermaut L. The effect of tooth position on the image of unerupted canines on panoramic radiographs. *Eur J Orthod* 1999; 21(5): 551-560.
65. Nakajima A, Nakajima A. Two- and Three- dimensional Orthodontic Imaging Using Limited Cone Beam Computed Tomography. *The Angle Orthodontist* 2005; 75: 895-895-903.
66. Arai Y, Tammissalo E, Iwai K, Hashimoto K, Shinoda K. Development of a compact computed tomographic apparatus for dental use. *Dentomaxillofac Radiol* 1999; 28(4): 245-248.
67. Mozzo P, Procacci C, Tacconi A, Martini PT, Andreis IA. A new volumetric CT machine for dental imaging based on the cone-beam technique: preliminary results. *Eur Radiol* 1998; 8(9): 1558-1564.

68. Ludlow JB, Davies-Ludlow LE, Brooks SL. Dosimetry of two extraoral direct digital imaging devices: NewTom cone beam CT and Orthophos Plus DS panoramic unit. *Dentomaxillofac Radiol* 2003; 32(4): 229-234.
69. Marmulla R, Wortche R, Muhling J, Hassfeld S. Geometric accuracy of the NewTom 9000 Cone Beam CT. *Dentomaxillofac Radiol* 2005; 34(1): 28-31.
70. Lascala CA, Panella J, Marques MM. Analysis of the accuracy of linear measurements obtained by cone beam computed tomography (CBCT-NewTom). *Dentomaxillofac Radiol* 2004; 33(5): 291-294.
71. Mah JK, Danforth RA, Bumann A, Hatcher D. Radiation absorbed in maxillofacial imaging with a new dental computed tomography device. *Oral Surg Oral Med Oral Pathol Oral Radiol Endod* 2003; 96(4): 508-513.
72. Ludlow JB, Davies-Ludlow LE, Brooks SL, Howerton B. Dosimetry of 3 CBCT Devices for Oral and Maxillofacial Radiology: CB Mercuray, NewTom 3G, and i-CAT. *Dentomaxillofacial Radiology* 2006; in press.
73. Huh Mol J (2002) Early Detection and Quantitative Assessment of Apical Root Resorption Using Tuned Aperture Computed Tomography (TACT) (dissertation). Chapel Hill, NC: University of North Carolina at Chapel Hill.
74. Ericson S, Bjerklin K, Falahat B. Does the canine dental follicle cause resorption of permanent incisor roots? A computed tomographic study of erupting maxillary canines. *Angle Orthod* 2002; 72(2): 95-104