



CASE REPORT

Thromboembolic Disaster after Atrial Ablation:

Use of Novel Anticoagulation

Mahmoud Farhoud, M.D.¹

Valerie S. Cagle, M.D.²

Wassim Shaheen, M.D.^{3,4}

¹University of Central Florida

College of Medicine, Orlando, FL

²Tulane University School of Medicine,
New Orleans, LA

³Heartland Cardiology, P.A., Wichita, KS

⁴University of Kansas
School of Medicine-Wichita, KS

Introduction

Atrial fibrillation (AF) may result in thromboembolism often from a thrombus in the left atrium or atrial appendage accounting for nearly 15% of all strokes in the US,¹ with an annual incidence of stroke of up to 6% or higher in some patients.² Atrial fibrillation ablation, if successful over the long-term, may reduce the risk of future stroke. New anticoagulants, such as dabigatran, rivaroxaban, and apixaban, have been shown to be superior to warfarin to reduce the risk of stroke in non-valvular atrial fibrillation (NVAF), but no solid data are available to show if they are appropriate to utilize as an alternative to warfarin in patients undergoing catheter ablation procedures. Our case illustrated that such therapy may not be efficient.

Case Report

A fifty-year-old male underwent catheter ablation for symptomatic paroxysmal atrial fibrillation. He is known to have dyslipidemia, hypertension, and coronary artery disease. He was diagnosed with paroxysmal NVAF and despite the use of several antiarrhythmic medications, including dronedarone and propafenone, normal sinus rhythm could not be maintained. Hence, he underwent atrial ablation with a pre-

procedural transesophageal echocardiogram that did not reveal any intracardiac thrombus. Prior to the ablation procedure, he had been anticoagulated with warfarin for more than four weeks with an international normalized ratio (INR) documented above two. He was discharged on warfarin and sotalol with a one-week follow-up.

At the follow-up visit, the patient's post-ablation anticoagulation regimen was changed from warfarin to apixaban per the patient's request not to take warfarin anymore. Approximately two weeks later, the patient presented to the emergency department due to the sudden onset of weakness and dizziness. He also had a fever of more than 101°F and cough.

A chest x-ray revealed a left lower lobe infiltrate. His electrocardiogram showed normal sinus rhythm. Other laboratory values were unremarkable except for leukocytosis and elevated troponin at 7.91 ng/ml (normal range less than 0.05 ng/ml). A CT scan of the brain showed a small subarachnoid hemorrhage in the right upper precentral sulcus. A transthoracic echocardiogram showed a 3 cm mobile thrombus in the left atrium.

His initial blood culture results were suggestive of gram positive cocci in a

streptococcal arrangement. Vancomycin and cefepime were started. Later, the final culture results were positive for streptococcus mitis and oralis.

A transesophageal echo on the following day showed an ejection fraction of 30% and a 3.7 cm long mobile thrombus attached to the roof of the left atrium (Figure 1). He also had recurrent episodes of atrial fibrillation during his hospital course.

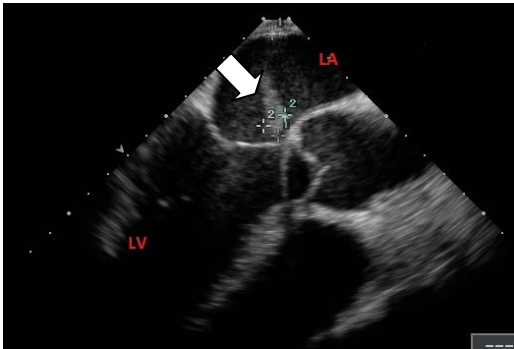

Figure 1. A transesophageal echo showed a 3.7 cm long mobile thrombus attached to the roof of the left atrium (arrow), LA: left atrium, LV: left ventricle.

Unfortunately, his neurological status deteriorated and he became unresponsive with a fixed and dilated left pupil. A repeat CT of the brain revealed thromboembolic lesion of disastrous proportions, “every area of the brain was involved with too many new lesions to report” (Figure 2). The CT scan also was significant for air bubbles over the top of the left parietal lobe. The patient was provided comfort care and subsequently expired immediately after extubation.

Discussion

Several complications are associated with catheter ablation in the left atrium. Our patient developed a post-procedure thrombus in the left atrium which we strongly feel became infected with secondary septic thromboembolism. This likely caused a mycotic aneurysm and hence the initial

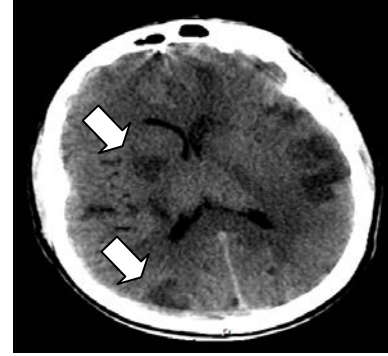


Figure 2. A CT of the head revealed multiple thromboembolic lesions (arrows).

small subarachnoid hemorrhage was seen on the first CT scan of the brain. There also was fistula, a known but rare complication of ablation. There is also the suggestion of a developing atriopharyngeal fistula, a known but rare complication of ablation. While this diagnosis could not be confirmed, as the patient was unstable to have any additional tests, the blood cultures showing streptococcus viridans and the air seen over the left parietal lobe on the final CT scan strongly supported our suspicion.^{3,4}

NVAF patients are at increased short-term risk of thromboembolism after their ablation.⁵ Several factors are implicated: the trans-septal sheath placement can precipitate thrombus formation on the catheter or sheath during the procedure or in the left atrial appendage,^{6,7} delivery of radiofrequency energy during the ablation disrupts the endocardium activating the clotting cascade,⁸ “char” (hard coagulum) from tissue heating and denaturation and aggregation of plasma proteins⁹ may form and systemically embolize,⁶ and the atrial tissue may be stunned post-procedure leading to impairment of normal contraction.¹⁰

To minimize this risk, anticoagulation is initiated as part of the ablation procedure. Current practice involves pre-ablation anticoagulation with warfarin, then anticoagulation with heparin during the procedure without discontinuation of

warfarin, followed by post-procedural anticoagulation, usually with warfarin for three to six months.^{11,12}

Our patient, anticoagulated with apixaban, developed a thrombus nearly four centimeters in length on the roof of the left atrium that resulted in fatal neurologic complications. Apixaban is an oral direct factor Xa inhibitor. The initial studies for apixaban have been promising, both in the context of NVAF as well as anticoagulation for cardioversion, with none of the over 300 patients on apixaban undergoing cardioversion in the ARISTOTLE trial having stroke over the next 30 days.¹³

Winkle et al.¹⁴ demonstrated dabigatran as safe and well tolerated after AF ablation. On the other hand, a larger multicenter study¹⁵ reported that peri-procedural dabigatran use significantly increases the risk of complications compared with

uninterrupted warfarin therapy. Due to the novelty of the oral anticoagulants, the studies are limited and there are likely many factors in the equation not yet recognized or explored. Our case is the first reported case that shows using apixaban following ablation may not be appropriate.

Conclusion

Despite the recent studies that showed apixaban to be a safe and effective anticoagulant in the prevention of stroke in a patient with NVAF compared to warfarin, physicians should be careful in extrapolating these data to a patient undergoing NVAF ablation. One can only speculate on how the use of apixaban, instead of warfarin, affected our patient's outcome. Our case illustrated the need for caution and further studies on the use of the new factor Xa inhibitors in such patient populations.

References

- ¹ Risk factors for stroke and efficacy of antithrombotic therapy in atrial fibrillation. Analysis of pooled data from five randomized controlled trials. *Arch Intern Med* 1994; 154(13):1449-1457. PMID: 8018000.
- ² Bornstein N, Corea F, Gallai V, Parnetti L. Heart-brain relationship: Atrial fibrillation and stroke. *Clin Exp Hypertens* 2002; 24(7-8):493-499. PMID: 12450224.
- ³ Finsterer J, Stollberger C, Pulgram T. Neurological manifestations of atrio-esophageal fistulas from left atrial ablation. *Eur J Neurol* 2011; 18(10):1212-1219. PMID: 21426444.
- ⁴ Stollberger C, Pulgram T, Finsterer J. Neurological consequences of atrio-esophageal fistula after radiofrequency ablation in atrial fibrillation. *Arch Neurol* 2009; 66(7):884-887. PMID: 19597091.
- ⁵ Scherr D, Sharma K, Dalal D, et al. Incidence and predictors of periprocedural cerebrovascular accident in patients undergoing catheter ablation of atrial fibrillation. *J Cardiovasc Electrophysiol* 2009; 20(12):1357-1363. PMID: 19572951.
- ⁶ Wazni OM, Rossillo A, Marrouche NF, et al. Embolic events and char formation during pulmonary vein isolation in patients with atrial fibrillation: Impact of different anticoagulation regimens and importance of intracardiac echo imaging. *J Cardiovasc Electrophysiol* 2005; 16(6):576-581. PMID: 15946352.
- ⁷ Ren JF, Marchlinski FE, Callans DJ. Left atrial thrombus associated with ablation for atrial fibrillation: Identification with intracardiac echocardiography. *J Am Coll Cardiol* 2004; 43(10):1861-1867. PMID: 15145112.
- ⁸ Luther T, Mackman N. Tissue factor in the heart. Multiple roles in hemostasis, thrombosis, and inflammation. *Trends Cardiovasc Med* 2001; 11(8):307-312. PMID: 11728878.

- ⁹ Demolin JM, Eick OJ, Münch K, Koullick E, Nakagawa H, Wittkamp FH. Soft thrombus formation in radiofrequency catheter ablation. *Pacing Clin Electrophysiol* 2002; 25(8):1219-1222. PMID: 12358173.
- ¹⁰ Sparks PB, Jayaprakash S, Vohra JK, et al. Left atrial "stunning" following radiofrequency catheter ablation of chronic atrial flutter. *J Am Coll Cardiol* 1998; 32(2):468-475. PMID: 9708477.
- ¹¹ Wazni OM, Beheiry S, Fahmy T, et al. Atrial fibrillation ablation in patients with therapeutic international normalized ratio: Comparison of strategies of anti-coagulation management in the peri-procedural period. *Circulation* 2007; 116(22):2531-2534. PMID: 17998456.
- ¹² Page SP, Siddiqui MS, Finlay M, et al. Catheter ablation for atrial fibrillation on uninterrupted warfarin: Can it be done without echo guidance. *J Cardiovasc Electrophysiol* 2011; 22(3):265-270. PMID: 21040095.
- ¹³ Easton JD, Lopes R, Bahit MC, et al. Apixaban compared with warfarin in patients with atrial fibrillation and previous stroke or transient ischaemic attack: A subgroup analysis of the ARISTOTLE trial. *Lancet Neurol* 2012; 11(12):503-511. PMID: 22572202.
- ¹⁴ Winkle RA, Mead RH, Engel G, Kong MH, Patrawala RA. The use of dabigatran immediately after atrial fibrillation ablation. *J Cardiovasc Electrophysiol* 2012; 23(3):264-268. PMID: 21955008.
- ¹⁵ Lakkireddy D, Reddy YM, Biase LD, et al. Feasibility and safety of dabigatran versus warfarin for periprocedural anti-coagulation in patients undergoing radiofrequency ablation for atrial fibrillation: Results from a multicenter prospective registry. *J Am Coll Cardiol* 2012; 59(13):1168-1174. PMID: 22305113.

Keywords: thromboembolism, atrial fibrillation, ablation techniques, apixaban