



CASE REPORT

Esophagitis Dissecans as a Cause of Upper GI Bleeding

Patrick Ters, M.D.,
William J Salyers, M.D., M.P.H.
University of Kansas
School of Medicine-Wichita
Department of Internal Medicine

Introduction

Esophagitis Dissecans Superficialis (EDS) is a rare benign condition of the esophagus, which results in sloughing of large fragments of esophageal mucosal epithelium.¹ The esophageal mucosal tear may be horizontal or vertical with cracks, and the sloughed fragments may be within or tethered, easily detachable from the mucosa, and can be coughed up or vomited.¹ Although an association has been made with medications,¹⁻³ skin conditions,⁴⁻⁵ heavy smoking,⁴ and physical trauma (hot beverages, nasogastric tube, chemical irritants, and large meals),^{3,5,6} EDS rarely has been reported as a cause of upper gastrointestinal (GI) bleeding.

Case Report

A 90-year-old white male presented to the emergency department with multiple episodes of coffee-ground emesis. He had no melena. He lived in a nursing home. He had a history of expressive aphasia, therefore, history-taking was limited. Previous records revealed a history of gastroesophageal reflux disease, esophagitis, and hiatal hernia. Medications included aspirin, ferrous sulfate, potassium chloride, and acetaminophen.

The patient's vital signs on admission included a temperature of 97.8°F, pulse of 120 bpm, blood pressure of 137/70 mmHg, respiratory rate of 18 bpm, and oxygen saturation of 99%. On physical exam, there were no skin lesions, blisters, or bullous

lesions. Epigastric tenderness was noted on the abdominal exam.

Laboratory results showed hemoglobin of 14.4 g/dL, white blood count of 12.7 g/dL, blood urea nitrogen between 20-33 mg/dL, and creatinine between 1.4-1.7 mg/dL. Other results included thyroid stimulating hormone of 1.93 mU/L, aspartate aminotransferase of 23 U/L, alanine aminotransferase of 24 U/L, alkaline phosphatase of 77 U/L, total bilirubin of 0.5 mg/dL, serum albumin of 3.3 g/dL, and calcium of 8.9 mg/dL. Electrolytes were within normal limits and troponins were negative.

The patient was treated with pantoprazole, 80 mg IV bolus and 8 mg/hr for 72 hours, made hemodynamically stable, and transferred to the medical intensive care unit for monitoring. He underwent esophagogastroduodenoscopy the next day revealing esophagitis dissecans with sloughing of the superficial mucosa from the proximal esophagus to gastroesophageal junction (Figure 1) and a medium-sized hiatal hernia. His stomach was otherwise normal; the duodenal bulb and the second portion of the duodenum were within normal limits. Following endoscopy, the patient had no further bleeding. Proton pump inhibitors (PPI) were switched from IV to oral twice daily for eight weeks.

The pathology report noted an intact esophageal squamous mucosa, non-specific reactive epithelial changes, focal surface

mucosal exfoliation, and degenerative changes associated with focal bacterial colonization. No intestinal metaplasia or

dysplasia was identified. *Helicobacter pylori* antigen testing was negative. These findings were consistent with EDS (Figure 2).

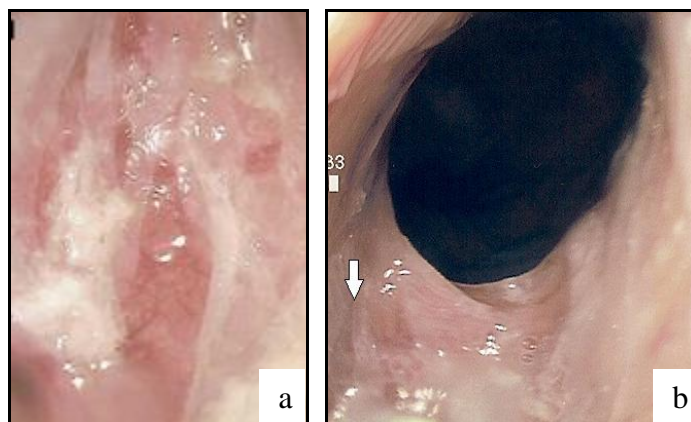


Figure 1. Endoscopic view of esophagitis dissecans superficialis: (a) diffuse sloughing of the lower esophagus mucosa and (b) vertical sloughing at the lower gastro-esophageal junction (see arrow).

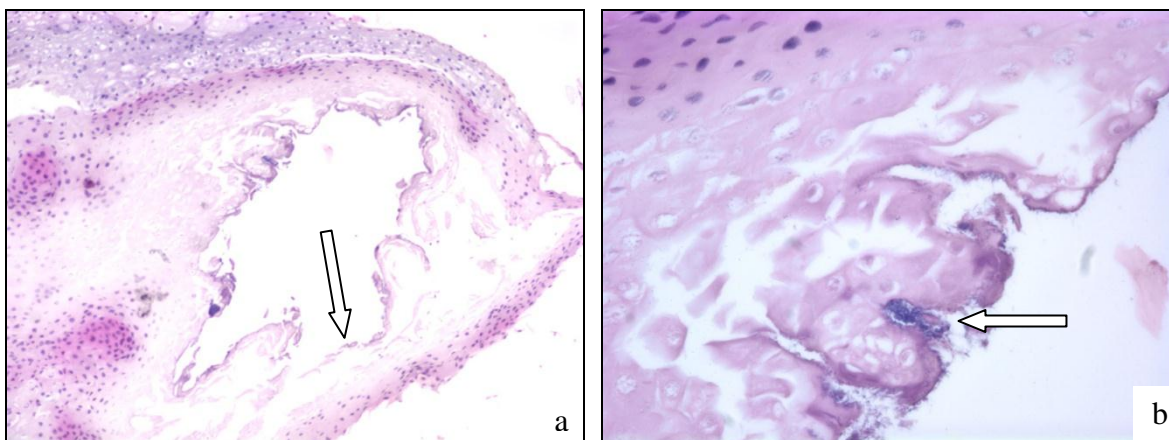


Figure 2. Histological examination of the mucosa showed (a) focal bacterial colonization (arrow) and (b) detached squamous epithelium (arrow).

Discussion

Upper GI bleeding is one of the most commonly seen medical emergencies with high morbidity and mortality in some age groups.² The annual incidence of acute upper GI bleeding is 102/100,000. GI bleed can be caused by a wide range of causes, but it rarely has been reported with EDS.

EDS is a rare endoscopic finding.¹ Its usual symptoms include dysphagia, odynophagia, and heartburn.^{1,7} It can be caused by

non-steroidal anti-inflammatory drugs,¹ bisphosphonates,³ potassium chloride,³ hot beverages,³ collagen disease,⁴ autoimmune bullous dermatoses,⁴ and celiac disease.⁸ Our patient had no bullous lesions or skin rash. He had never been on bisphosphonates. His history did not reveal any physical trauma. He had been on potassium chloride and aspirin which may have contributed to the development of EDS.

Endoscopy did not reveal any other potential sources of his GI bleeding. A rare lesion, such as a Dieulafoy's lesion, which was not actively bleeding at the time of endoscopy, cannot be ruled out completely. The mild decrease in his hemoglobin and lack of melena suggests against such a lesion. Endoscopy did not reveal any gastric or duodenal ulcers, masses, or any lesions suggesting hemorrhage which makes EDS a highly likely cause for his upper GI bleeding.

Conclusion

EDS, a very benign chronic condition of the esophagus, can be a cause of upper GI

bleeding. It occurs with many iatrogenic, avoidable, and reversible conditions. EDS is an entity that we should be aware of, especially when prescribing bisphosphonates, potassium chloride, or during nasogastric tube placement. The physical exam should be of value as presence of skin lesions with upper GI bleed may point toward EDS. Endoscopy should be manipulated with experienced endoscopists due to the very fragile consistency of the mucosa.

Acknowledgment

We thank Dr. William Palko for his assistance and help.

References

- ¹ Carmack SW, Vemulapalli R, Spechler SJ, Genta RM. Esophagitis dissecans superficialis ("sloughing esophagitis"): A clinicopathologic study of 12 cases. *Am J Surg Pathol* 2009; 33(12):1789-1794. PMID: 19809273.
- ² Longstreth GF. Epidemiology of hospitalization for acute upper gastrointestinal hemorrhage: A population-based study. *Am J Gastroenterol* 1995; 90(2): 206-210. PMID: 7847286.
- ³ Hokama A, Ihama Y, Nakamoto M, Kinjo N, Kinjo F, Fujita J. Esophagitis dissecans superficialis associated with bisphosphonates. *Endoscopy* 2007; 39(Suppl 1): E91. PMID: 17440869.
- ⁴ Hokama A, Yamamoto Y, Taira K, et al. Esophagitis dissecans superficialis and auto immune bullous dermatoses: A review. *World J Gastrointest Endosc* 2010; 2(7) 252-256. PMID: 21160615.
- ⁵ Kaplan RP, Touloukian J, Ahmed AR, Newcomer VD. Esophagitis dissecans superficialis associated with pemphigus vulgaris. *J Am Acad Dermatol* 1981; 4(6):682-687. PMID: 7016940.
- ⁶ Patterson TC. A simple superficial esophageal cast. *J Pathol* 1935; 40:559-69.
- ⁷ Patel NK, Salathé C, Vu C, Anderson SH. Esophagitis dissecans: A rare cause of odynophagia. *Endoscopy* 2007; 39(Suppl 1):E127. PMID: 17440858.
- ⁸ Hage-Nassar G, Rotterdam H, Frank D, Green PH. Esophagitis dissecans superficialis associated with celiac disease. *Gastrointest Endosc* 2003; 57(1): 140-141. PMID: 12518158.

Keywords: esophagitis, gastrointestinal hemorrhage, upper gastrointestinal tract