

CASE REPORT

CMV Colitis in an HIV Positive Patient with CD4 greater than 200

Mahmoud Farhoud, M.D.,
Furqan Siddiqi, M.D., William J. Salyers, M.D.,
Donna Sweet, M.D.
University of Kansas
School of Medicine-Wichita
Department of Internal Medicine

Introduction

Cytomegalovirus (CMV) disease typically occurs in immunocompromised individuals including HIV-positive patients with CD4 counts less than 50 cells/ μ L to 100 cells/ μ L.¹ Few cases of CMV gastrointestinal disease have been reported in patients with CD4 counts greater than 200 cells/ μ L.²⁻⁴

Case Report

A 28-year-old male known to have HIV was admitted with a one-week history of worsening fatigue, nausea, vomiting, 2 kg weight loss, and constipation. Blood pressure was 110/70 mmHg. Heart rate was 105 bpm and body temperature was 37.2 C.

On physical examination, the patient looked dehydrated. His abdomen was tender to palpation without guarding. Bowel sounds were normal. Initial lab work showed sodium at 130 mEq/l, albumin at 2.2 g/dl, and white blood count at 15.9 K/cmm with normal differentials. Blood cultures were negative.

On admission, his CD4 count was 223 cells/ml and viral load was 5350 copies per ml. Three months prior, his CD4 count was 666 cells/ml with 1960 HIV RNA copies per ml. A kidney, ureter, and bladder (KUB) x-ray study showed small bowel obstruction. A nasogastric tube was inserted. Computed tomography (CT) of the abdomen showed multiple air and fluid filled loops of small bowel with marked edema of distal small

bowel. Colonoscopy revealed congested and erythematous mucosa with skip areas within the proximal, middle, and distal transverse colon and congestive mucosa within the terminal ileum with prominent Peyer's patches. Serum cytomegalovirus (CMV) PCR was 3250 IU/mL.

Histological findings in colonic biopsies revealed active inflammation with ulceration (Figure 1) and characteristic large cells (Figure 2). CMV infection could be confirmed immunohistochemically (Figure 3). The patient was started on IV ganciclovir. Highly active anti-retroviral therapy (HAART) was initiated with efavirenz, emtricitabine, and tenofovir.

The patient improved. He was discharged on ganciclovir 450 PO BID and HAART. Three weeks later, the patient was seen at primary care physician's office with clinical improvement and repeat serum CMV PCR was negative.

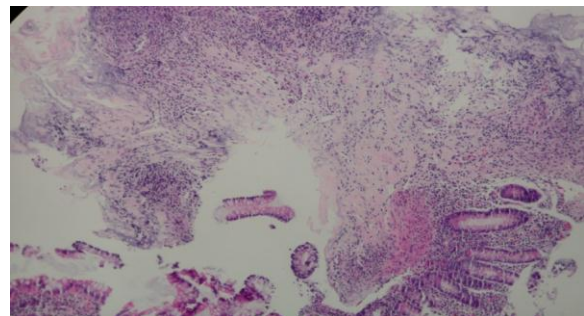


Figure 1. H&E stained section of mucosa with ulceration and inflammation.

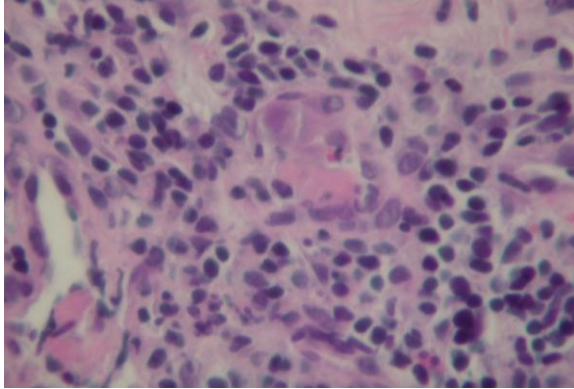


Figure 2. H&E stained section showing 3 large cells with large nucleus, eosinophilic nucleolus, and stippled appearance of cytoplasm admixed with mostly small lymphocytes and a few eosinophils.

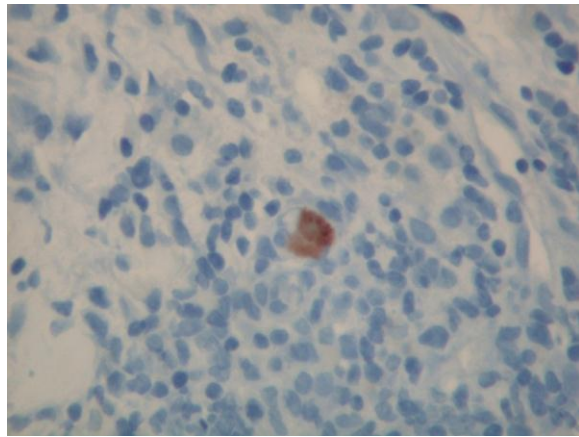


Figure 3. CMV immunohistochemical stain of biopsy.

Discussion

CMV colitis can occur in up to 7.3% of persons with AIDS.⁵ CMV colitis occurs late in the course of HIV infection.⁶ The risk of opportunistic infections in patients with HIV has been known to be dependent on the degree of immunodeficiency as measured by CD4 T cells. Ulcers caused in the gastrointestinal tract by CMV infection are observed usually when the number of CD4

decreases to less than 50 cells/ μ L to 100 cells/ μ L. For example, Wilcox et al.⁷ reported CMV colitis in 56 HIV patients, most with severe immunodeficiency and a median CD4 count of 15 cells/ μ L.

Few cases of CMV colitis in HIV positive patients with CD4 count more than 200 cells/ μ L have been reported. Yotsumoto and colleagues² reported cytomegalovirus esophagitis and colitis, esophageal candidiasis and colon amebiasis in an HIV patient with CD4 count more than 200 cells/ μ L. Wolf and colleagues³ reported a case of severe CMV colitis in an HIV positive woman with relatively preserved CD4 count. Smith and colleagues⁴ reported a case of a patient with CMV colitis and a CD4 count of 800.

Explanations of acquiring CMV colitis with relatively higher CD4 counts include poor nutritional status or alcohol consumption.⁸ Our patient denied alcohol abuse. Surawicz et al.⁹ reported CMV colitis in immunocompetent individuals as a consequence of receptive anal intercourse. Our patient was a man who had sex with men, so there was possibility of an anal mucosa tear. Another possibility is dysfunction of T cells secondary to HIV virus, although it is difficult to prove.²

Conclusion

Although gastrointestinal manifestations of CMV in patients with advanced HIV disease are well described, this case highlighted that CMV colitis also can occur in patients with CD4 counts greater than 200. CMV colitis should be included in the differential diagnosis of any HIV-positive patient presenting with lower gastrointestinal symptoms, regardless of their CD4 counts.

References

- ¹ Springer KL, Weinberg A. Cytomegalovirus infection in the era of HAART: Fewer reactivations and more immunity. *J Antimicrob Chemother* 2004; 54(3):582-586. PMID: 15282241.
- ² Yotsumoto M, Nakamura N, Kitano K, et al. Cytomegalovirus esophagitis and colitis, esophageal candidiasis and colon amebiasis in an HIV patient with more than 200/ μ L CD4 positive lymphocytes. *J AIDS Res* 2002; 5:537-537.
- ³ Wolf T, Bickel M, Faust D, Fellbaum C, Brodt HR. A case of severe CMV-colitis in an HIV positive patient despite moderate immunodeficiency. *Scand J Infect Dis* 2003; 35(11-12):904-906. PMID: 14723380.
- ⁴ Smith PR, Glynn M, Sheaff M, Aitken C. CMV colitis in early HIV infection. *Int J STD AIDS* 2000; 11(11):748-750. PMID: 11089790.
- ⁵ Gallant JE, Moore RD, Richman DD, Keruly J, Chaisson RE. Incidence and natural history of cytomegalovirus disease in patients with advanced human immunodeficiency virus treated with zidovudine. The Zidovudine Epidemiology Study Group. *J Infect Dis* 1992; 166(6):1223-1227. PMID: 1358986.
- ⁶ Mentec H, Leport C, Leport J, Marche C, Harzic M, Vildé JL. Cytomegalovirus colitis in HIV-1-infected patients: A prospective research in 55 patients. *AIDS* 1994; 8(4):461-467. PMID: 8011249.
- ⁷ Wilcox CM, Chalasani N, Lazenby A, Schwartz DA. Cytomegalovirus colitis in acquired immunodeficiency syndrome: A clinical and endoscopic study. *Gastrointest Endosc* 1998; 48(1):39-43. PMID: 9684662.
- ⁸ Latif O, Peterson JD, Waltenbaugh C. Alcohol-mediated polarization of type 1 and type 2 immune responses. *Front Biosci* 2002; 7:a135-a147. PMID: 12133821.
- ⁹ Surawicz CM, Myerson D. Self-limited cytomegalovirus colitis in immunocompetent individuals. *Gastroenterology* 1988; 94(1):194-199. PMID: 2826283.

Keywords: cytomegalovirus infections, colitis, HIV, CD4-positive T-lymphocytes