



CASE REPORT

Be aware of B19
David J. Lerner, MS3
Sylvia Orozco-Do, M.D.
University of Kansas
School of Medicine – Wichita
Department of Internal Medicine

Introduction

Sickle cell parvovirus B19 transient aplastic crisis is a relatively common occurrence that can require hospitalization with a multi-modality treatment plan including a complete exchange transfusion. We report a case of sickle cell parvovirus B19 transient aplastic crisis that required multiple complete exchange transfusions.

Case Report

A 31-year-old, African-American woman presented to the emergency department after a two-week history of increasing generalized pain, with particular emphasis in the legs bilaterally, left arm, and chest. The pain was aggravated by increased movement, but continued while at rest. She had been vaccinated against tetanus, and against streptococcus *pneumonia* with Pneumococcal Vaccine Polyvalent (Pneumovax®), but not for meningitis.

A review of systems was positive for dehydration, decreased appetite, and subjective fevers for three days. Her past medical history included sickle cell hemoglobinopathy, thrombosis secondary to a peripherally inserted central catheter line, laparoscopic cholecystectomy, and a caesarean section. She had a history of smoking and drinking alcohol. She was taking acetaminophen/oxycodone and folic acid.

The patient was mildly obese. She was well-nourished and well-developed, but was in distress from her pain. She was tearful.

Her vital signs were abnormal for respirations of 24 breaths per minute and a blood pressure of 146/86 mmHg. She had dry mucous membranes of the oral and conjunctival mucosa. A midline caesarean scar had no evidence of erythema or dehiscence. There was no evidence of hepatosplenomegally. She had eczema of the right calf. Her sternum was tender to palpation. Initial laboratory data showed a white blood cell count of 35.2×10^3 cells/mm³ with no left shift, a hemoglobin of 6.9 gm/dl, a mean corpuscular volume of 98.6 fL, with platelets of 1337×10^3 /mm³. A blood smear showed target cells, schistocytes, and ovalocytes. Additional labs showed a reticulocyte count of 2.5%.

A chest x-ray revealed patchy infiltrates in both lower lobes. A two-dimensional echocardiogram revealed a pulmonary arterial pressure of 50-55 mmHg. A brain natriuretic peptide showed results of 1185 pgmol/liter. Liver function tests revealed a maximum alanine aminotransferase of 1736 units/liter and a maximum aspartate aminotransferase of 2184 units/liter. Lactate dehydrogenase tests reached a maximum of 4273 units/liter. Direct Coombs test and cold agglutinins tests were negative. A

hemoglobin electrophoresis yielded hemoglobin S 53.7% and hemoglobin C 46.3%. Blood cultures were negative. A streptococcus pneumonia urine antigen was negative.

A titer for parvovirus B-19 revealed an IgM of 10.40 mg/dl and an IgG of 4.75 mg/dl. Sickle cell SC aplastic crises with parvovirus B-19 Infection was diagnosed.

The patient was placed on three liters of oxygen. She was given packed red blood cells, but they did not normalize her anemia. She initially was given IV antibiotics, fluids, and pain medications. Antibiotics were discontinued after a 10-day regimen. She

was given one complete exchange transfusion to remove the sickled cells, then received a hemoglobin electrophoresis which revealed that her erythrocytes were still sickling (see Figure 1a). Another complete exchange transfusion was performed and another hemoglobin electrophoresis which then indicated resolution (see Figure 1b). Supportive therapy was given. During her hospital stay, she developed acute renal failure which resolved. She was discharged on pain medications with plans to improve hydration habits.

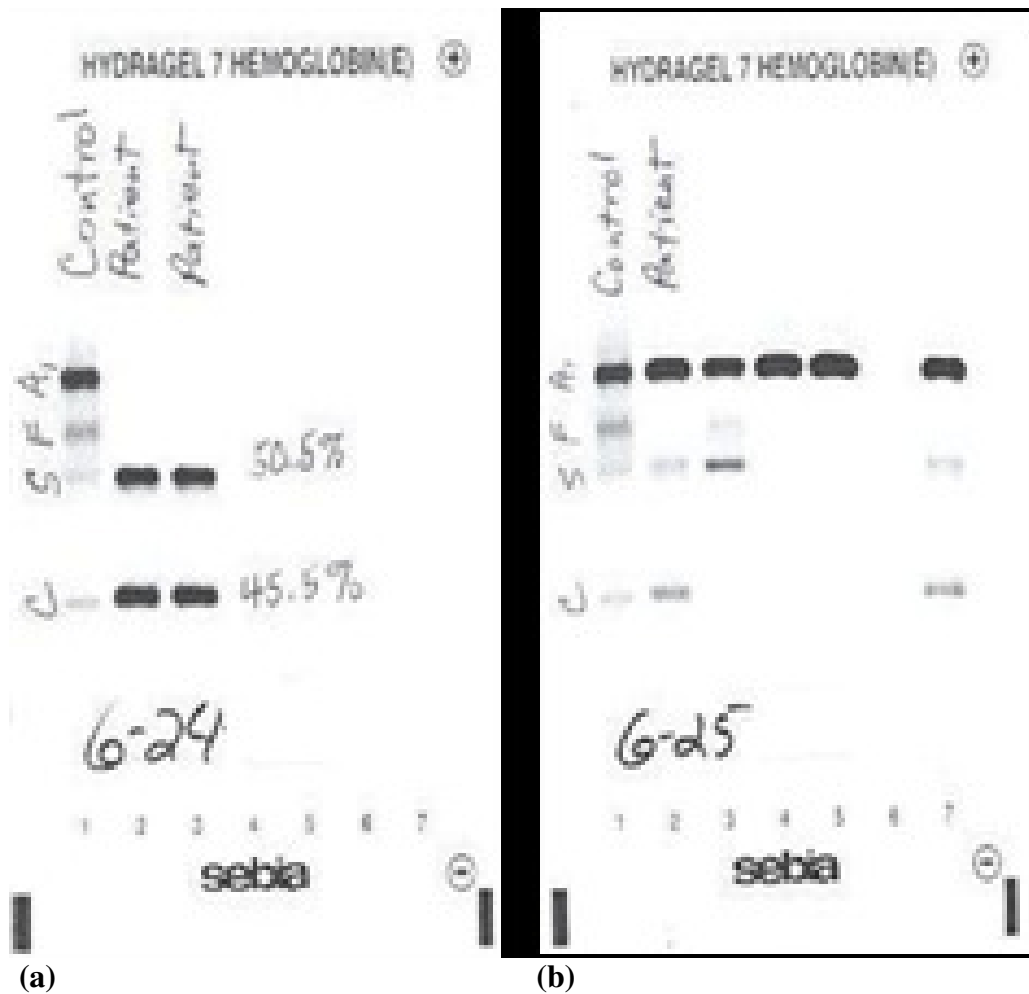


Figure 1. (a) The first hemoglobin electrophoresis illustrates that anemia was not treated adequately with the exchange transfusion, most likely due to the parvovirus. (b) Another exchange transfusion was necessary for resolution.

Discussion

Sickle cell SC is a disorder of hemoglobin that leads to polymerization of hemoglobin S in erythrocytes causing cell sickling.¹ The hemoglobin C gene is one-fourth as common as the hemoglobin S gene, which is around 8% of the African-American population.^{2,3}

Parvovirus B-19 is a virus that is directly toxic to human erythroid precursor cells. More than seventy percent of adults have measurable parvovirus B-19-specific IgG antibodies.⁴ Sickle cell anemia commonly presents as recurrent painful crises. Intermittent bouts of sickling will cause vasoocclusion in connective and musculo-skeletal tissue causing a painful ischemia.

Most painful crises will present with acute pain, tenderness, fever, tachycardia, and anxiety. When these infarctions occur in the pulmonary vasculature, it can cause acute chest syndrome, which is a medical emergency. It can lead to pulmonary hypertension which causes a secondary right sided heart failure.⁵

Sickle cell anemia aplastic crises can occur when a parvovirus B19 strain infects the host. The sickle cell anemia in crises is exacerbated by a loss in erythropoiesis due to the B19 toxicity to erythroid precursors. Labs will show abrupt decreases in hemoglobin without a compensatory reticulocytosis. Definitive diagnosis of Sickle cell SC hemoglobinopathy is determined by hemoglobin electrophoresis.

Sickle cell hemoglobinopathies are suspected in a history of hemolytic anemia, as well as a characteristic sickling seen on a blood smear.⁵ The practical choice for diagnosing immunocompetent individuals with acute parvovirus B-19 infections is serum IgM and IgG antibodies or PCR. Additionally, decreased or lower than expected reticulocyte counts might be noted.⁶

Treatment of a sickle cell aplastic crisis focuses on supportive care, identifying the problem, and treating the patient's acute problems in a timely manner. The main treatments include giving blood transfusions until the patient's immune system has cleared the virus, and reticulocytes and red blood cell function have returned. In severe and chronic cases, IgG infusions might be needed.

In a longitudinal study of 308 patients with hemoglobin SS, 91 out of 114 (80%) who were infected with B19 developed a transient aplastic crisis.⁷ Another study in 633 children with sickle cell disease indicated that 68 parvovirus B19 aplastic crises occurred over a five-year period.⁸

Prevention of parvovirus B19 infection is best achieved by using good infection control practices. A vaccine given to 24 seronegative adults in a series of three doses over six months was highly immunogenic.^{7,9} Prevention of sickle cell crisis involves lifestyle changes and planning ahead. Hydration is important to maintain erythrocytic volume. Staying away from hot or cold environments or stressful situations also can prevent recurrence.

Antibiotic prophylaxis in splenectomized patients prior to procedures or dental work also might prevent recurrence as well as pneumococcal and meningitis vaccines. Hydroxurea also will help by inducing hemoglobin F production and decrease the amount of time that hemoglobin is in the deoxygenated form (tense) form.⁵

The need for two complete exchange transfusions is unusual in that one complete exchange transfusion typically replaces the sickling erythrocytes and resolves such a crisis. Although there have been cases of multiple partial exchange transfusions,¹⁰ no other case reports are known describing the

need for more than one complete exchange transfusion in a sickling crisis with acute chest syndrome. Therefore, our case indicates that multiple complete exchange transfusions can be warranted in such cases of sickle cell crisis.

Conclusion

Because sickle cell disease is a common condition in certain populations in the US and the very high existence of parvovirus B19 exposures in the general population, one must always carry a high suspicion for sickle cell disease parvovirus B19 aplastic anemia in sickle cell patients presenting with a crisis. The acute treatment usually is hospitalization with hydration, symptom management, and in serious cases, the possibility of more than one complete exchange transfusion.

References

- ¹ Bunn HF, Noguchi CT, Hofrichter J, Schechter GP, Schechter AN, Eaton WA. Molecular and cellular pathogenesis of hemoglobin SC disease. *Proc Natl Acad Sci USA* 1982; 79:7527-7531.
- ² Motulsky AG. Frequency of sickling disorders in U.S. blacks. *N Engl J Med* 1973; 288:31-33.
- ³ Hemphill RR. Hereditary Hemolytic Anemias. In: Tintinalli JE, Kelen GD, Stapczynski JS, Ma OJ, Cline DM (Eds), *Tintinalli's Emergency Medicine: A Comprehensive Study Guide*, 6th Edition. 2004. Accessed at: <http://www.accessmedicine.com/content.aspx?aID=606858>.
- ⁴ Cohen BJ, Buckley MM. The prevalence of antibody to human parvovirus B19 in England and Wales. *J Med Microbiol* 1988; 25:151-153.
- ⁵ Benz EJ. Hemoglobinopathies. In: Kasper DL, Fauci AS, Longo DL, Braunwald E, Hauser SL, Jameson JL (Eds), *Harrison's Principles of Internal Medicine*. 16th Edition. New York: McGraw-Hill Professional, 2005, pp. 593-597.
- ⁶ Erdman DD, Usher MJ, Tsou C, et al. Human parvovirus B19 specific IgG, IgA, and IgM antibodies and DNA in serum specimens from persons with erythema infectiosum. *J Med Virology* 1991; 35:110-115.
- ⁷ Jordan JA. Treatment and prevention of Parvovirus B19 infection. January, 2009. Accessed at: <http://www.uptodate.com>.
- ⁸ Smith-Whitley K, Zhao H, Hodinka RL, et al. Epidemiology of human parvovirus B19 in children with sickle cell disease. *Blood* 2004; 103:422-427.
- ⁹ Ballou WR, Reed JL, Noble W, Young NS, Koenig S. Safety and immunogenicity of a recombinant parvovirus B19 vaccine formulated with MF59C.1. *J Infect Dis* 2003; 187:675-678.
- ¹⁰ Lanzkowsky P, Shende A, Karayalcin G, Kim YJ, Aballi AJ. Partial exchange transfusion in sickle cell anemia. Use in children with serious complications. *Am J Dis Child* 1978; 132:1206-1208.

Keywords: parvovirus B19, sickle cell anemia, aplastic anemia, electrophoresis, exchange transfusion