



CASE REPORT

Recurrent Epidural Abscess Caused by *Propionibacterium Acnes*

Zartash Z. Khan, M.D.¹, Maha Assi, M.D.,
M.P.H.^{2,3}, Thomas A. Moore, M.D.^{2,3}

¹University of Oklahoma Health Sciences Center,
Department of Internal Medicine, Infectious
Diseases Section, Oklahoma City, OK

²Infectious Disease Consultants, Wichita, KS

³University of Kansas

School of Medicine-Wichita,
Department of Internal Medicine

Introduction

Epidural abscess is a suppurative fluid collection in the epidural space that, if not treated promptly, may result in severe consequences. It is caused most commonly by *Staphylococcus aureus* followed by Gram negative bacilli, streptococcus species, and coagulase negative staphylococci.^{1,2} A rare case of recurrent epidural abscess caused by an unusual pathogen, *Propionibacterium acnes*, is presented.

Case Report

A 60-year-old Caucasian male presented with a two-day history of excruciating low back pain radiating to his left lower extremity. He received a trigger point steroid injection in the outpatient setting at the onset of his symptoms and had been using high potency non-steroidal anti-inflammatory agents with no relief. He then developed numbness and weakness of his affected limb.

The past medical history was significant for chronic back pain and an L4-L5 diskectomy for bulging disc and sciatica about five months prior to this event. He also received periodic trigger point steroid injections for his back pain. The patient had a history of systemic lupus erythematosus and was maintained on prednisone (10mg daily), methotrexate (15mg weekly), and hydroxychloroquine (200mg daily). He had no history of illicit drug use.

The review of systems revealed no bowel or bladder incontinence, no fever or chills, and no urinary symptoms. There was tenderness to palpation over the lumbar spine and the straight leg raising test was positive on the left side. The motor exam was limited due to considerable pain. Sensation to light touch on the left lower leg was impaired. Reflexes and rectal tone were normal.

The lab work showed leucocytes at 18,000 cells per mL, 78% neutrophils, erythrocyte sedimentation rate at 57 mm/hr, and C reactive protein at 17.9 mg/L. Blood cultures were negative.

Magnetic Resonance Imaging (MRI) obtained upon admission revealed an epidural abscess at L4-L5 (Figure 1). Intravenous (IV) vancomycin (1gm twice daily) was initiated and abscess drainage and evacuation with microdiskectomy was performed. High dose steroids were used to decrease post-operative inflammation and swelling.

The surgical tissue gram stain revealed gram positive coccobacilli and rare gram positive cocci in pairs. The culture grew a moderate amount of *Propionibacterium acnes* within ten days. Intravenous vancomycin was continued.

Eight days after the surgery, the patient had recurrence of acute onset of left leg pain, numbness, and weakness. A repeat

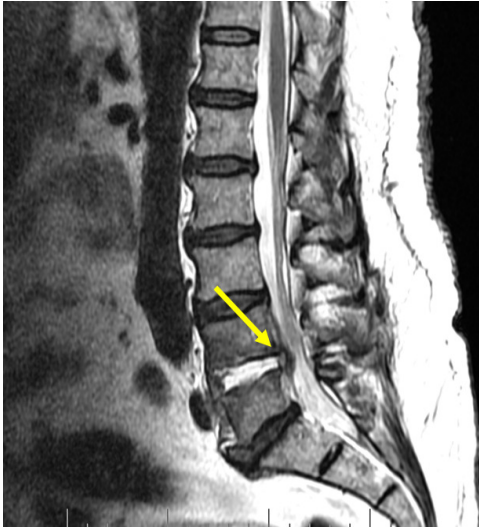


Figure 1. An epidural abscess and discitis at the L4-L5 level upon admission.

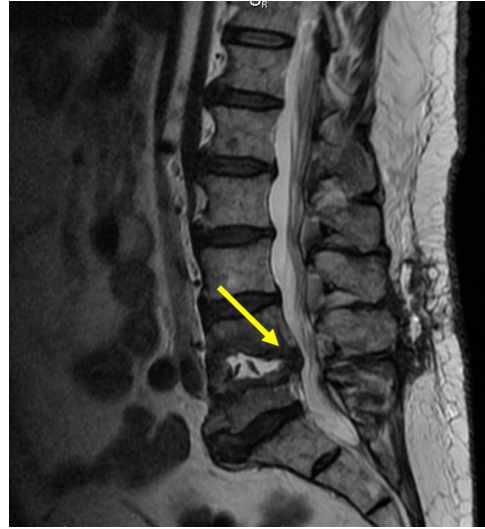


Figure 2. Evidence of osteomyelitis and recurrent epidural abscess.

MRI (Figure 2) showed a new fluid collection and evidence of osteomyelitis at L4-L5 level. The patient underwent evacuation and drainage of the abscess with good clinical results. The drainage catheter was removed three days later and he was dismissed with continued vancomycin treatment.

Twelve days after dismissal, the patient again presented with similar symptoms. Recurrence of the abscess was confirmed with MRI (Figure 3). This time, two catheters were placed intraoperatively, one for continuous vancomycin instillation for 24 hours and another for drainage. The patient showed great improvement post-operatively. He received IV vancomycin for a total of four weeks and was kept, thereafter, on suppressive treatment with oral minocycline 100mg twice daily for six months. He remained asymptomatic.

Discussion

The epidural space lies over the dura mater which is the outermost sub-osteal layer surrounding the brain and the spinal cord. Fat tissue is abundant in the lumbosacral region providing a favorable substrate for microorganisms. Collection of

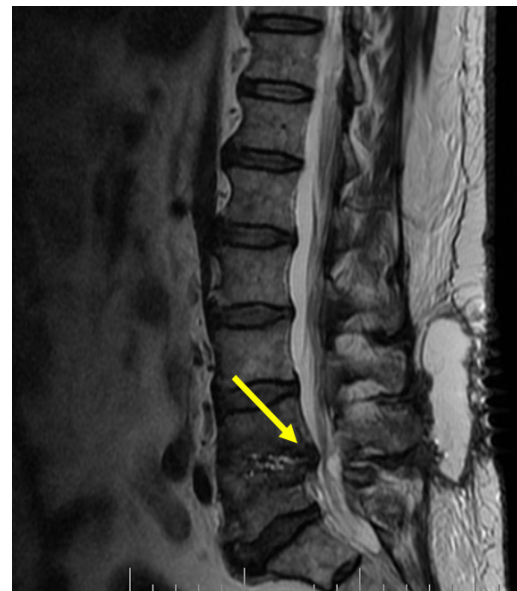


Figure 3. Recurrence of the abscess after the second surgery.

pus in the epidural space is referred to as an epidural abscess.² Clinical features include fever, back pain, and neurological deficits.²⁻⁵

Diagnosis is based on clinical features and MRI findings. MRI is the preferred diagnostic modality,⁴⁻⁷ while computed

tomography (CT) with contrast and myelography are acceptable alternatives.^{2,4,7-9}

Epidural abscess requires early recognition and treatment. The main determinant of outcome for patients with spinal epidural abscess is the neurological status at the time of diagnosis. Mortality rates for adults remains high (up to 14%) despite advances in diagnosis and treatment.^{3,10}

Staphylococcus aureus accounts for about two-thirds of cases caused by pyogenic bacteria, followed by *Streptococcus pneumoniae* at 7.7%, *Staphylococcus epidermidis* at 5.2%, and a small percent of cases reported with viridans strep, *Escherichia coli*, citrobacter, serratia, and clostridium.⁷ Propionibacterium is an extremely rare cause of epidural abscess and osteomyelitis. There are only four cases of discitis and/or osteomyelitis published in the English literature.¹¹⁻¹⁴

Propionibacterium acnes colonize the skin and reside in the lipid rich microenvironment of hair follicles. They produce inflammatory mediators (lipase, neuraminidase, phosphatase, and protease) which cause papules or pustules or nodulocystic skin lesion characteristic of inflammatory acne. These are slow growing, non-sporulating, Gram-positive, anaerobic bacilli. The species requires culture for at least 7 to 10 days to ensure its isolation.^{8,15}

Propionibacterium has been identified as a rare cause of brain abscess, subdural empyema, dental infections, endocarditis, conjunctivitis, vision threatening keratitis, peritonitis in association with peritoneal dialysis catheters, arthritis in association with prosthetic joints, and osteomyelitis.⁵ Any causative organism of epidural abscess may spread from adjacent soft tissue or skin infection, via contaminated syringes, as a complication of invasive surgical procedure, or epidural catheters that remain for longer periods.^{4,5,7,16,17} Only 26% of cases occur by

hematogenous seeding following bacteremia.^{3,18} In the illustrative case above, it is likely that the trigger point steroid injections that he received introduced this organism from the skin into the sterile epidural space.

Conditions which may perpetuate or make patients prone to developing an epidural abscess are diabetes, immunosuppression, steroids, alcohol, chronic renal failure, trauma, intravenous drug use, bacteremia, spinal injections, and catheterization or other forms of instrumentation.^{3,4,6,7} Human Immunodeficiency Virus also is associated with epidural abscess.⁸ The patient discussed above had several risk factors including immunosuppression with methotrexate, chronic steroids, and spinal injections. It is unknown whether the same risk factors contributed to his disease recurrence despite adequate therapy.

Standard treatment guidelines dictate medical management if the abscess is small and there is no neurological deficit. If there is neurological deterioration, management should include prompt surgical evacuation and drainage.⁴ Patients usually are started on high dose steroids as soon as possible to decrease the swelling and reduce any developing neurological deficit. Steroids also provide some analgesia benefit.¹⁹ CT guided drainage or drainage under fluoroscopy are options in uncomplicated cases.^{10,18} With evidence of osteomyelitis, surgical debridement is required in addition to IV antibiotics for six to eight weeks guided by the microbiologic diagnosis.⁷

Based on these guidelines, our patient was treated appropriately with surgical evacuation and debridement and proper IV antibiotics. However, his epidural abscess recurred twice despite therapy. There were no significant data on direct instillation of antibiotics into the epidural space, though it might be considered in addition to systemic

antibiotics in refractory cases where standard treatments had failed.

References

- ¹ Kaufman DM, Kaplan JG, Litman N. Infectious agents in spinal epidural abscesses. *Neurology* 1980; 30:844-850.
- ² Huff JF. Spinal epidural abscess. January 17, 2007. Accessed at: <http://emedicine.medscape.com/article/1165840-overview>.
- ³ Mackenzie AR, Laing RB, Smith CC, Kaar GF, Smith FW. Spinal epidural abscess: The importance of early diagnosis and treatment. *J Neurol Neurosurg Psychiatry* 1998; 65:209-212.
- ⁴ Danner RL, Hartman BJ. Update of spinal epidural abscess: 35 cases and review of the literature. *Rev Infect Dis* 1987; 9:265-274.
- ⁵ Royakkers AA, Willigers H, van der Ven AJ, Wilmink J, Durieux M, van Kleef M. Catheter-related epidural abscesses: Don't wait for neurological deficits. *Acta Anaesthesiol Scand* 2002; 46:611-615.
- ⁶ Nussbaum ES, Rigamonti D, Standiford H, Numaguchi Y, Wolf AL, Robinson WL. Spinal epidural abscess: A report of 40 cases and review. *Surg Neurol* 1992; 38:225-231.
- ⁷ Hlavín ML, Kaminski HJ, Ross JS, Ganz E. Spinal epidural abscess: A ten-year perspective. *Neurosurgery* 1990; 27:177-184.
- ⁸ Del Curling O Jr, Gower DJ, McWhorter JM. Changing concepts in spinal epidural abscess: A report of 29 cases. *Neurosurgery* 1990; 27:185-192.
- ⁹ Baker AS, Ojemann RG, Swartz MN, Richardson EP Jr. Spinal epidural abscess. *New Engl J Med* 1975; 293:463-468.
- ¹⁰ Lyu RK, Chen CJ, Tang LM, Chen ST. Spinal epidural abscess successfully treated with percutaneous, computed tomography-guided, needle aspiration and parenteral antibiotic therapy: Case report and review of the literature. *Neurosurgery* 2002; 51:509-512.
- ¹¹ Harris AE, Hennicke C, Byers K, Welch WC. Postoperative discitis due to *Propionibacterium acnes*: A case report and review of the literature. *Surg Neurol* 2005; 63:538-541.
- ¹² Chia JK, Nakata MN. Intervertebral diskitis caused by *Propionibacterium acnes*: A report of four cases. *Clin Infect Dis* 1996; 23:643-644.
- ¹³ Crouzet J, Claudepierre P, Aribi EH, et al. Two cases of discitis due to *Propionibacterium acnes*. *Rev Rhum Engl Ed* 1998; 65:68-71.
- ¹⁴ Noble RC, Overman SB. *Propionibacterium acnes* osteomyelitis: Case report and review of the literature. *J Clin Microbiol* 1987; 25: 251-254.
- ¹⁵ Handa S. *Propionibacterium* infections. April 27, 2006. Accessed at: <http://emedicine.medscape.com/article/226337-overview>.
- ¹⁶ Sarubbi FA, Vasquez JE. Spinal epidural abscess associated with the use of temporary epidural catheters: Report of two cases and review. *Clin Infect Dis* 1997; 25:1155-1158.
- ¹⁷ Talu GK, Erdine S. Complications of epidural neuroplasty: A retrospective evaluation. *Neuromodulation* 2003; 6:237-247.
- ¹⁸ Brook I. Brain abscess. December 15, 2006. Accessed at: <http://emedicine.medscape.com/article/212946-overview>.
- ¹⁹ Diken B, Taspınar V, Karakelle N, et al. Dexamethasone: Can it be an analgesic after lumbar laminectomy? *Pain Clinic-Utrecht* 2005; 17:297-302.

Keywords: epidural abscess, *propionibacterium acnes*, case report