

Université de Montréal

**L'infestation palpébrale et faciale au**  
***Demodex folliculorum***

par  
Sarah Aumond

École d'Optométrie  
Faculté des études supérieures

Mémoire présenté à la Faculté des études supérieures  
en vue de l'obtention du grade de  
Maîtrise en Sciences de la Vision  
option Sciences fondamentales et appliquées

octobre 2018

© Sarah Aumond, 2018

## Résumé

Le *Demodex folliculorum* [*D. folliculorum*] est l'ectoparasite le plus fréquent dans les follicules des cils et de la peau. Son rôle précis dans la microflore n'est pas encore déterminé, mais il semble agir comme un commensal. Par contre, lorsque sa quantité dépasse un certain seuil, il devient pathogène. Son infestation est associée à une blépharite antérieure et/ou postérieure, une sécheresse oculaire et plusieurs types d'affectation du visage tels que l'acné rosacée. Comme il peut se retrouver autant dans les paupières que la peau du visage, cela suggère qu'une infestation palpébrale pourrait être associée à une plus grande densité faciale dudit parasite. Pour vérifier cette hypothèse, des participants ayant diverses sévérités de blépharite antérieure à *D. folliculorum* ont été recrutés. Une épilation de cils infestés a été effectuée, permettant un décompte des parasites. D'un autre côté, l'infestation faciale a été évaluée par une biopsie superficielle standardisée de la peau du front, prélevant ainsi quelques couches de l'épiderme superficiel et le contenu des follicules pileux. L'analyse des résultats révèle que la présence d'une blépharite à *D. folliculorum* est associée à une densité faciale du parasite au-delà du seuil de normalité. De plus, le degré d'érythème facial augmente avec la sévérité de l'infestation des paupières et du visage. Certains signes et symptômes oculaires sont aussi affectés par la présence de la blépharite. Par exemple, on retrouve une réduction de la hauteur du ménisque lacrymal et une augmentation des yeux larmoyants lors d'une infestation légère à modérée, de même qu'une augmentation de la sensation de picotement à la bordure des paupières en présence d'une infestation sévère.

En conclusion, comme les infestations faciale et palpébrale sont concomitantes, autant les professionnels de la vue que les dermatologistes doivent être impliqués dans le diagnostic et la prise en charge de cette condition. Une approche multidisciplinaire serait certainement bénéfique pour les individus atteints.

**Mots-clés :** *Demodex folliculorum*, blépharite, pathophysiologie du cil, démodécie, follicule, biopsie superficielle faciale

## **Abstract**

*Demodex folliculorum* [*D. folliculorum*] is the most common ectoparasite in the eyelash and skin follicles. Its precise role in the microflora is not yet determined, but it seems to act as a commensal. However, when its quantity exceeds a certain threshold, it becomes pathogenic. Its infestation is associated with anterior and/or posterior blepharitis, dry eye disease and several types of facial conditions such as rosacea. Since *D. folliculorum* can be found as much in the lids as in the facial skin, this suggests that a palpebral infestation may be associated with a higher facial mite density. To verify this hypothesis, participants with various severities of *D. folliculorum* blepharitis were recruited. The epilation of infested lashes was performed, to assess mite counts. The facial infestation was quantified by a standardized skin-surface biopsy of the forehead, thus extracting a few layers of the superficial epidermis and the content of the hair follicles. The results revealed that the presence of *Demodex* blepharitis is associated with a facial mite density beyond the normal threshold. In addition, the degree of facial erythema increases with the severity of palpebral and facial infestations. Some ocular signs and symptoms are also affected by the presence of *Demodex* blepharitis. For example, a mild to moderate infestation is associated with a tear meniscus height reduction as well as more watery eyes, and a severe infestation with increased itching along the lids.

In conclusion, since facial and palpebral infestations are concomitant, both eye care professionals and dermatologists should be involved in the diagnosis and management of this common parasite. In addition, a multidisciplinary approach would ultimately benefit the affected individuals.

### **Keywords :**

*Demodex folliculorum*, blepharitis, eyelash pathophysiology, demodicosis, follicle, skin-surface biopsy

# Table des matières

Résumé.....	i
Abstract.....	ii
Table des matières.....	iii
Liste des tableaux.....	iv
Liste des figures.....	v
Liste des sigles.....	vi
Liste des abréviations.....	vii
Remerciements.....	viii
1. Introduction.....	1
1.1 L'ectoparasite <i>Demodex folliculorum</i> .....	1
1.2 L'infestation palpébrale au <i>Demodex folliculorum</i> .....	2
1.2.1 Article 1: The eyelash follicle features and anomalies, a review.....	4
1.2.2 Prise en charge de l'infestation palpébrale.....	33
1.3 L'infestation faciale au <i>Demodex folliculorum</i> .....	34
1.3.1 Prise en charge de l'infestation faciale.....	37
1.4 Le lien entre l'infestation palpébrale et faciale.....	38
2. Méthodologie.....	39
2.1 Objectifs.....	39
2.2 Raisonnement.....	39
2.3 Hypothèses.....	40
3. Résultats.....	41
3.1 Article 2: Palpebral and facial skin infestation by <i>Demodex folliculorum</i> .....	42
4. Discussion.....	73
5. Conclusion.....	77
6. Bibliographie.....	78

## Liste des tableaux

### Article 1

Tableau 1. Hair anomalies and their associated pathologies.....	14
Tableau 2. Etiologies and management of lash conditions.....	15

### Article 2

Tableau 1. Exclusion criteria.....	46
Tableau 2. Clinician Erythema Assessment (CEA).....	51
Tableau 3. Facial skin conditions reported with an effect or not on facial mite density.....	51
Tableau 4. Demographics of each severity group of <i>Demodex</i> blepharitis.....	53
Tableau 5. Percentage (%) of each dermatological condition per severity group.....	55
Tableau 6. Ocular and lid variables.....	57
Tableau 7. Mean mite count for each lid.....	57
Tableau 8. Ocular Surface Disease Index, Non-Invasive Break Up Time and Tear Meniscus Height for each <i>Demodex</i> blepharitis severity.....	58

# Liste des figures

## Article 1

Figure 1. The general morphology of the eyelash and its surrounding skin.....	6
Figure 2. The anatomy of the eyelash.....	7
Figure 3. The life cycle of the eyelash.....	10
Figure 4. Eyelash debris assessment by eyecare professionals.....	22

## Article 2

Figure 1. <i>Demodex folliculorum</i> ( <i>D.f</i> ) from the lashes under 40-400x magnification.....	50
Figure 2. <i>Demodex folliculorum</i> ( <i>D.f</i> ) from the forehead skin under 40-400x magnification...50	
Figure 3. Forehead <i>Demodex</i> densities (mite count/cm <sup>2</sup> ) expressed as marginal mean ± standard error (SE).....	54
Figure 4. Scatterplot of the degree of facial erythema and the forehead <i>Demodex</i> density [mite count/cm <sup>2</sup> ].....	55
Figure 5. Lash mite count expressed as mean ± standard error (SE) for each severity group...56	
Figure 6. Percentage (%) of participants with different symptoms (itching along the lid margin, ocular itching and watery eyes) for each severity group.....	59

## **Liste des sigles**

ANCOVA: A one-way analysis of covariance

ANOVA: A one-way analysis of variance

ROSCO: global ROSacea COnsensus

TFOS-DEWS: Tear Film & Ocular Surface Society Dry Eye WorkShop

## Liste des abréviations

CD: cylindrical dandruff

CEA: clinician erythema assessment

*D. brevis*: *Demodex brevis*

DED: dry eye disease

*D. folliculorum*: *Demodex folliculorum*

ECP: eye care professional

EGFR: epidermal growth factor receptor

IVCM: *in vivo* confocal microscopy, microscopie confocale *in vivo*

MG: meibomian gland; glandes de Meibomius

MGD: meibomian gland dysfunction

NIBUT: non-invasive break-up time

OSDI: ocular surface disease index

SSSB: standardized skin-surface biopsy

TBUT: tear breakup time

TLR: receptors toll-like

TMH: tear meniscus height



## Remerciements

Si quelqu'un m'avait dit lors de ma graduation en 2011 que j'allais revenir à l'école d'optométrie pour me lancer dans une maîtrise en Sciences de la vision, je ne l'aurais pas cru. Pourtant, me voilà à discuter avec mon amie Audrey d'un possible retour à l'école, lors d'une randonnée de ski de fond entre Noël et le jour de l'an 2016. Merci Audrey de m'avoir mis cette idée en tête et de m'avoir convaincu de contacter Etty Bitton, afin qu'elle soit ma directrice de maîtrise. Merci Etty pour ta confiance, ton support et toutes les heures que tu as passées à me relire... En plus, tu m'as aidé à obtenir des bourses d'études, ce qui m'a permis de me concentrer à 100% sur mon projet de recherche. Je n'aurais pas pu avoir une meilleure personne pour me guider durant ces deux dernières années. C'est stimulant de côtoyer quelqu'un qui s'investit autant dans tout ce qu'elle fait, et qui réussit à te transmettre sa passion. Grâce à toi Etty, j'aime lire des articles scientifiques et faire de la recherche!

J'aimerais aussi remercier le personnel et les professeurs de l'école d'optométrie, qui m'ont encouragé dans mon parcours académique, et merci tout spécialement à Walter Wittich, qui m'a fait aimer les statistiques, ce qui n'est pas une mince affaire. Merci à Julie, Anton, Vanessa et Diane, aussi étudiants au cycle supérieur, pour votre motivation et surtout, pour m'avoir diverti!

Je dois remercier mon amoureux des 17 dernières années, qui m'a supporté dans cette aventure, autant financièrement qu'émotionnellement. Lorsque j'avais des doutes, il était toujours là pour m'écouter, me rassurer, me pousser à continuer... et m'offrir un soutien informatique, et ce, jour et nuit ! Merci d'avoir été si compréhensif... Et finalement, un merci tout spécial à Mathéo, qui m'a accompagné 24h sur 24 durant les neuf derniers mois de mon projet de recherche, et qui me laisse un peu de temps chaque jour, pouvant varier de quelques minutes à quelques heures, pour finaliser mon mémoire.

D'autres beaux projets s'en viennent grâce à cette maîtrise.... Restez à l'affût !!

# 1. Introduction

## 1.1 L'ectoparasite *Demodex folliculorum*

Les êtres humains ont une flore qui leur est propre et qui leur permet de réguler et maintenir l'homéostasie. La microflore cutanée peut contenir entre autres deux ectoparasites spécifiques aux humains, soient le *Demodex folliculorum* [*D. folliculorum*] et le *Demodex brevis* [*D. brevis*] (Nicholls et al., 2017). Les deux espèces sont des arthropodes qui ont une portion antérieure composée d'une tête et de quatre paires de pattes, ainsi qu'une région postérieure composée d'un long opisthosoma sans anus. Leur cycle de vie est d'une durée de 15 à 18 jours, de l'éclosion des œufs pondus par les femelles jusqu'à leur pleine maturité (Rufli et al., 1981). Les parasites sembleraient se transférer d'une personne à l'autre par contact direct avec des articles domestiques, tels que la literie et les serviettes, de même que la poussière (Tarkowski et al., 2015). Bien que leur rôle précis dans la microflore n'est pas complètement établi, ils agiraient comme des parasites commensaux (Lacey et al., 2011). Le *D. Brevis* se loge profondément dans les follicules ciliaires et pileux, ainsi que dans les glandes de Meibomius (Nicholls et al., 2017). L'espèce la plus prévalente est le *D. folliculorum*, retrouvé surtout dans les couches superficielles de la peau du visage et des paupières, ainsi que dans les follicules qui lui sont rattachés, soient les follicules pileux et ciliaires (Lacey et al., 2011; Nicholls et al., 2017). Il a été établi que sa fréquence augmente avec l'âge et qu'il serait même présent chez 100 % des gens âgés de plus de 70 ans (Post et al., 1963). Une association avec l'âge n'a pas été démontrée quant au *D. Brevis*. Ce projet de recherche se concentrera sur le *D. folliculorum*. Une description détaillée des différentes couches de la peau ainsi que des follicules pileux et ciliaires est de mise afin de mieux comprendre l'interaction du *D. folliculorum* avec son milieu. Une revue de littérature a donc été réalisée et publiée à ce sujet. La base de données Ovid MEDLINE a été utilisée pour rechercher les mots-clés « eyelash physiopathology /abnormalities/pathologies » et quelques articles complémentaires ont été dénichés sur Embase. Cette revue de littérature non-systématique, aussi appelée « scoping review », est donc présentée à la sous-section 1.2.1.

Bien que le *D. folliculorum* fait partie de la microflore normale, il devient pathogénique lorsqu'il se retrouve en quantité excessive (Lacey et al., 2011). Il y a alors une infestation du tissu sous-jacent, que ce soit les paupières ou la peau du visage. Les infestations palpébrale et faciale à *D. folliculorum* sont décrites aux sections 1.2 et 1.3, respectivement.

## **1.2 L'infestation palpébrale au *Demodex folliculorum***

Une infestation des paupières par le *D. folliculorum* se traduit entre autres par une blépharite antérieure [cils] et postérieure [glandes de Meibomius] (Bhandari et al., 2014; Chen et al., 2017; Lopez-Ponce et al., 2017). Des analyses avec microscopie confocale *in vivo* [IVCM] démontrent que le parasite est surtout présent à plusieurs niveaux du follicule ciliaire et parfois, à l'extérieur du follicule entre les cils (Randon et al., 2015). De plus, les cils ayant des follicules ciliaires colonisés par une grande quantité de *D. folliculorum* sont entourés à la base seulement par des gaines gélatineuses appelées « cylindrical dandruff [CD] » (Gao et al., 2005). Les mêmes chercheurs ont établi que les CD sont un signe pathognomonique d'une quantité excessive de *Demodex*. Une infestation à *D. folliculorum* peut donc être l'étiologie d'une blépharite antérieure. Plusieurs autres types de blépharite antérieure existent, dont la séborrhéique (Paulino, 2017; Wolf et al., 2014) ou la bactérienne [surtout par les staphylocoques] (Bernardes et al., 2010). Moins fréquemment, elle peut être causée par un autre parasite, le *Phthiriasis palpebrarum* (Turgut et al., 2009).

D'un autre côté, il n'a pas été démontré que le *D. folliculorum* serait l'une des causes de la blépharite postérieure. En effet, le *D. folliculorum* n'est pas retrouvé à l'intérieur des glandes de Meibomius, contrairement à *D. brevis* (Randon 2015). La prévalence du *D. brevis* augmente en présence d'une dystrophie des glandes de Meibomius et/ou de chalazion (Liang et al., 2014; Liang et al., 2018). Il est tout de même possible de diagnostiquer une blépharite antérieure à *D. folliculorum* concomitante à une blépharite postérieure. De même, une blépharite à *Demodex* peut déséquilibrer le film lacrymal, causant ainsi une sécheresse oculaire. Des concentrations plus élevées de cytokines dans les larmes, surtout IL-17, sembleraient expliquer l'inconfort oculaire ressenti et les télangiectasies fréquemment retrouvées lors d'une infestation palpébrale (Kim et al., 2011).

La blépharite à *Demodex* peut être asymptomatique ou associée à des signes et symptômes non spécifiques tels qu'un picotement, une rougeur sur les paupières, des yeux larmoyants ou une sensation de sécheresse oculaire (Sedzikowska et al., 2016). De plus, comme tous les autres types de blépharite antérieure, elle peut avoir à long terme des répercussions négatives sur les cils telles que des changements de pigmentation, de direction, de position ou de croissance. Ces anomalies sont associées à des pathologies des cils telles que la poliose [perte de pigmentation], la trichiase [mauvaise direction] et le milphosis [perte des cils] (Ferreira et al., 2010; Kumar et al., 2012; Vij et al., 2015). Ces anomalies peuvent aussi être associées à l'application de produits cosmétiques sur les cils. Plusieurs recommandations ont donc été émises afin de réduire l'impact des cosmétiques sur les cils et sur la surface oculaire (O'Dell et al., 2017). La description de plusieurs pathologies ciliaires, leurs étiologies, les facteurs iatrogéniques qui affectent les cils tels que les cosmétiques de même que l'implication du *D. folliculorum* sur l'homéostasie des paupières font partie d'une revue de littérature. Cette dernière met aussi en évidence que les recherches sur le cil et son follicule ont un retard considérable par rapport à celles sur les cheveux. Les cils ont longtemps été considérés comme un simple poil sans rôle particulier. De ce fait, peu d'intérêt leur était porté par la communauté scientifique. De plus, le prélèvement d'un follicule ciliaire humain est très complexe, étant donné qu'une portion de la paupière doit être retirée. Ce sont surtout les modèles animaux qui ont permis de démontrer les caractéristiques spécifiques des follicules ciliaires et ainsi, en faire des entités distinctes. Dans les dernières années, de plus en plus de recherches s'orientent sur le cil et son follicule, ce qui comble graduellement l'écart avec la recherche sur les cheveux (Paus et al., 2016; Thibaut et al., 2010). La revue de littérature se retrouve à la section suivante (1.2.1).

## **1.2.1 Article 1: The eyelash follicle features and anomalies, a review**

*[publié dans Journal of Optometry (2018), 11, 211-222]*

Sarah Aumond<sup>1</sup>, Ety Bitton<sup>1</sup>

<sup>1</sup>École d'optométrie, Université de Montréal, CP 6128 succursale centre-ville, Montréal, Qc, Canada

### **Abstract**

The primary role of eyelashes is to protect and maintain the health of the lid margin. However, the mechanisms to fulfill this role are not fully understood. Unravelling these mechanisms will stand to greatly improve the efficiency of eye care professionals' interventions in anomalies of the eyelashes. The aim of this article is to provide a review on eyelashes including highlights and new avenues for research; the biology of both the lash and its follicle; the pathophysiology and management of lash anomalies by eye care professionals; and the effect of iatrogenic factors on lashes. Using the database of Ovid MEDLINE, we reviewed studies specifically directed on human/mammalian eyelashes and key articles on current trends in scalp hair methodologies that can be applicable to lash research. The eyelash morphology, pigmentation and growth rate have been documented using techniques ranging from lash imaging to follicle immunohistochemistry. Furthermore, studies have demonstrated that the lash follicle is sensitive to many factors of the external environment, a variety of systemic/topical medications and cosmetics. Recently, aerodynamic studies using a mammalian eye model confirmed that an optimal lash length was needed so that eyelashes serve a protective role in reducing the number of particles that can reach the eye. Despite recent advances in lash research, studies are still scarce, due to the limited availability of the human lid for sampling. This review brings awareness that further research is needed with respect to eyelashes and will hopefully reduce the gap with scalp hair research.

### **Keywords**

Eyelash, follicle, hair, eyelash pathophysiology, lid margin

## **Introduction**

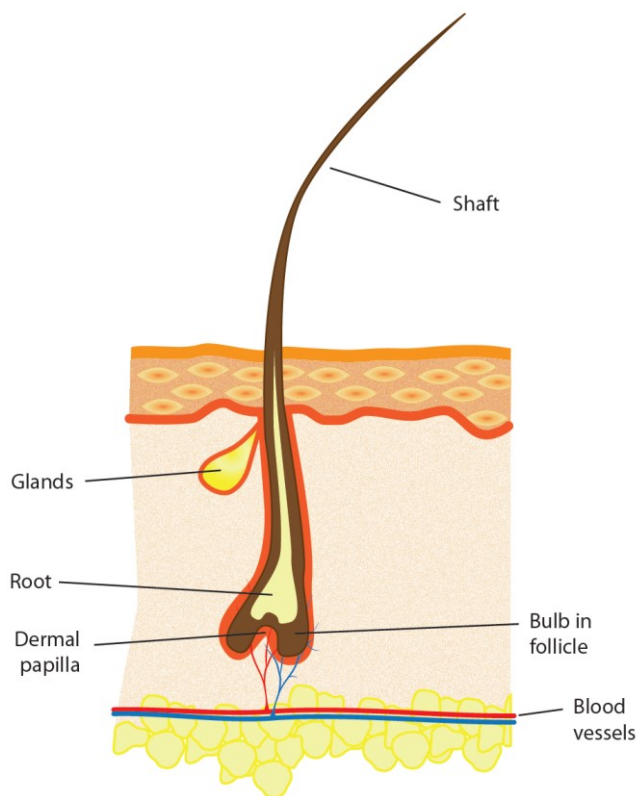
Little research has been done on the human eyelash on account that most of the attention has been directed to research on hair for people suffering from scalp hair loss. However, recent discoveries on the role of eyelashes and its distinctive characteristics have led to an increased scientific interest. Moreover, eyelashes are now considered an important aspect of the facial aesthetic and are the object of various beauty treatments to enhance them (Draelos, 1991; Jones, 2011). Since eyelashes form a barrier between the external and internal environment of the eye, they are extremely sensitive to a variety of threats and irritants and are highly innervated to perform that function (Montagna et al., 1969). Eyelashes are an integral part of the lid margin anatomy, much like the Meibomian glands, eyelid skin and biofilm, each contributing to the overall homeostasis of the ocular surface. As such, it is important to maintain their integrity. As a whole, the lid margin is responsible for the production of the tear film lipid layer and the protection of the eye from external trauma. Via the blink, it distributes the tears towards the nasolacrimal puncta found in the inner portion of the lid margin (Willcox et al., 2017). If any part of the lid margin is inflamed, it can induce a tear film disturbance or instability which can, in turn, affect the ocular surface (Craig et al., 2017). Left untreated, this inflammatory cascade can develop into dry eye disease (Craig et al., 2017). Therefore, studying the eyelash and its pathophysiology is valuable for researchers and eye care professionals [ECPs] alike, to maintain ocular surface homeostasis.

An Ovid MEDLINE search for eyelash physiopathology/abnormalities/pathologies has led to 419 human and 59 non-human publications. The articles that were selected for this non-systematic review concentrated on the general biology of the human lash, the prevailing methods in lash research, lash anomalies and the resulting pathologies with their associated clinical management by an ECP. Also, we reviewed relevant articles on current trends in scalp hair research that can be applicable to eyelashes, and the iatrogenic factors that can affect the lashes, such as cosmetics.

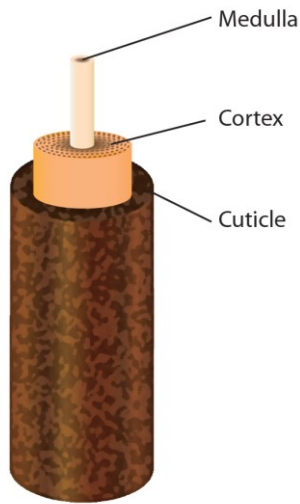
### **The general biology of the human lash**

The human lower lid contains 75-80 lashes dispersed in three to four rows, whereas the upper lid has 90-160 lashes scattered on five to six rows (Liotet et al., 1977; Montagna et al., 1969; Na et al., 2006). The anatomy of the lash and hair has some similar characteristics (Marieb, 2005). Both have a hair shaft [the visible part] that extends outside the skin, a root that is under the skin and a bulb, which is the enlarged terminal portion [Figure 1]. The inferior portion of the bulb is in direct contact with the dermal papilla, which brings key mesenchymal-epithelial interactions in follicle cycling.

The lash itself is made up of three structures that fit into one another [Figure 2] (Liotet et al., 1977). The innermost structure, the medulla, consists of loose cells. A thicker cortex surrounds the medulla to ensure its strength and stability. The pigmentation of either the lash or hair is the result of the melanin contained in the cortex. Finally, the cuticle, composed of several cell layers, forms the outermost portion, offering protection to the internal structures by its impermeability.



**Figure 1.** The general morphology of the eyelash and its surrounding skin



**Figure 2.** The anatomy of the eyelash

The anatomy and physiology of the lash follicle are distinctive from other hair follicles. Consequently, the lash follicle is worthy of a detailed study and appreciation of its specific characteristics and surrounding skin; its influence on the lash life cycle, curvature, and pigmentation; and the age-related changes of the lashes.

### **The surrounding skin of the follicle and its features**

To appreciate the main characteristics of the lash follicle and its surrounding skin, it is imperative to compare these structures to that of the scalp hair, which have been studied extensively. The scalp skin contains three layers: the epidermis [external], the dermis [middle] and the hypodermis [internal] (Marieb, 2005) whereas the skin of the lids has two layers: a thinner epidermis and a dermis (Thibaut et al., 2010). All follicles on the human body are rooted in their deepest skin layer, notably the hypodermis for the scalp and the dermis for the lid. Consequently, the lash follicle is shorter than the scalp hair follicle (Thibaut et al., 2010). Another major characteristic that distinguishes lash follicles from scalp hair follicles is that they have no arrector pili muscles, which are responsible for straightening the hair in response to cold or intense emotions (Marieb, 2005), producing what is commonly referred to as ‘goose bumps’. Therefore, lashes do not require individual mobility (Montagna et al., 1969).



Lash follicles are connected with two types of secretory glands: Zeiss and Moll. They produce different substances released through channels that flow into the follicle. The Zeiss glands use a holocrine mechanism of action, thus liberating their complete cell content, which is a sebum (Smith et al., 2008). It has antimicrobial and lubrication properties, just as it allows the transport of antioxidants, although the exact function of the sebum is unknown (Smith et al., 2008). The Moll glands, only found in the lids and active from birth, are apocrine glands that produce secretions by fragmentation from one side of their cells (Stoeckelhuber et al., 2003). Their secretions, which contain a variety of sugar components, might play a critical role in the defense against microorganisms (Stoeckelhuber et al., 2003).

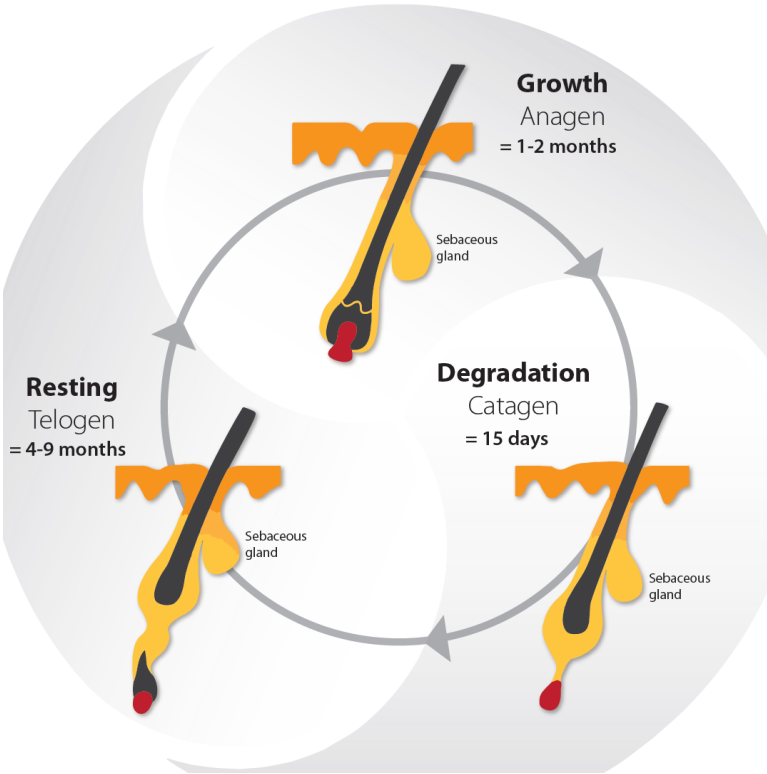
### **The life cycle, curvature and pigmentation**

Lashes have a life cycle consisting of three phases : the growth phase [anagen], the degradation phase [catagen] and the resting phase [telogen] (Kloepper et al., 2010). Following the telogen phase, the lash falls out and the life cycle begins again with a new lash in the anagen phase [Figure 3] (Kloepper et al., 2010). The daily growth rate of a lash is 0.12 mm to 0.14 mm (Na et al., 2006; Thibaut et al., 2010). The anagen phase duration varies from four to ten weeks and the complete life cycle is from four to eleven months (Na et al., 2006; Paus et al., 2016; Thibaut et al., 2010). The lash length rarely exceeds 12 mm, as the growth rate and anagen phase duration are shorter than the ones observed in scalp hair research (Thibaut et al., 2010). The lash growth rate is influenced by several factors, including the topical prostaglandin analogs used to reduce the intraocular pressure in glaucoma patients (Paus et al., 2016). Nesher et al. (2015) demonstrated that the prostaglandin analog F2 $\alpha$  receptors were expressed in several layers of the lash follicle during its anagen phase. Further studies are needed to confirm the expression of the prostaglandin analog F2 $\alpha$  receptors with the use of prostaglandin analogs eyedrops.

The morphology of the eyelashes is such that they are curved in all individuals, regardless of ethnicity. This curvature is initiated at the bulb of the lash and continues until the tip of the shaft (Thibaut et al., 2005). Thibaut et al. (2010) have shown that several cell types of the lash follicle alongside the bulb location are asymmetric [i.e. certain sheaths along the concave side of the

bulb are thicker than the ones on the convex side]. While studying the biology of curly hair *in vitro*, the same phenomenon of asymmetry has been observed (Thibaut et al., 2005). Curly hair's markers are also found in the cuticle and cortex of the lash itself (Thibaut et al., 2007; Thibaut et al., 2010). These studies offer possible explanations of the mechanisms involved in lash curvature. Nevertheless, the amplitude of the curvature can vary among individuals. Ethnic studies have identified a difference in the degree of lash curvature [or curl] revealing that the lift-up and curl-up angles are more pronounced among Caucasians as compared to Asians (Na et al., 2006).

The skin and all hair on the human body acquire their pigmentation mostly by melanogenesis, which is the synthesis of different types of melanin by the melanocytes (Commo et al., 2004), these cells being under the influence of several enzymes, including *tyrosinase-related protein 2* [TRP-2] (Schallreuter et al., 1998). When it comes to lashes, their degree of pigmentation is defined by the quantity of melanocytes in the lash follicle structure (Thibaut et al., 2010). The lash becomes greyish at a very advanced age and rarely whitens (Liotet et al., 1977). The maintenance of the lash pigmentation may be explained by a sustained expression of TRP-2 (Thibaut et al., 2010). Further studies are needed to confirm if this association is a direct cause-effect relationship. In contrast, many studies have shown that scalp hair will progressively lose its pigmentation due to a gradual depletion of melanocytes (Commo et al., 2004). Several mechanisms have been demonstrated to explain this phenomenon: melanocyte apoptosis, oxidative stress and a reduced expression of certain enzymes, such as TRP-2 (Arck et al., 2006; Commo, Gaillard, Thibaut, et al., 2004; Tobin, 2008).



**Figure 3.** The life cycle of the eyelash

**Age-related changes**

There are limited studies about age-related changes on eyelashes. Procianoy et al. (2015) have studied women’s lower lid lashes and found that the curvature of the lashes on the medial and central eyelid portion increased with age, while those of the lateral portion remained in the same direction. Glaser et al. (2014) reported that there was a reduction of length, thickness and pigmentation of the lashes with age.

**Research methods**

Compared to scalp hair, little research has been dedicated to the study of eyelashes, namely due to the limitation inherent to the *in vivo* access of the lash follicle. This section explores the techniques employed in lash research and their challenges.

### **Sampling and organ culture of the lash follicle**

There are only a few studies on human lash follicle sampling because it is limited to cadaveric studies and eyelid surgeries, such as ectropion repairs (Montagna et al., 1969; Nesher et al., 2015; Thibaut et al., 2010). It was in 1969 that the first research on the histology and cytochemistry of human lids and lashes was published (Montagna et al., 1969). The function and microscopic anatomy of the follicle cells were studied post mortem following sudden accidental deaths. Other studies that have succeeded in preserving a portion of the human lid have used immunohistochemistry to perform analysis (Nesher et al., 2015; Thibaut et al., 2010). This technique consists of detecting certain antigens [proteins] in the cells of the tissue, using antibodies that bind to them specifically. This technique allowed researchers to describe the morphology, curvature and pigmentation of the lash follicles (Thibaut et al., 2010), and the presence and characteristics of some prostaglandin receptors in the follicles (Nesher et al., 2015).

As sampling on human lash follicles is limited, it is even more complex for scientists to perform lash follicle cultures, hence existing publications on that topic are limited to animal studies. Yet, human scalp hair cultures are common and have been successfully achieved for the past several decades, whereby tissues are obtained during face-lift procedures (Harries et al., 2013; Kloepper et al., 2010; Philpott et al., 1990). A research guide has been proposed to standardize the scalp hair follicle culture, which is of interest to researchers in different fields: experimental dermatology, genetics, developmental biology and endocrinology (Langan et al., 2015). It is even possible to observe human hair follicles *in vivo* with xenotransplantation [the follicles in their anagen phase or full-thickness skin portions are removed from the human scalp and transplanted on the back of mice] (Gilhar et al., 2013; Hashimoto et al., 2000; Oh et al., 2016). All of these studies highlight how hair research has progressed as compared to eyelash research. To overcome this gap, other mammals had to be considered. In the past, primate tissues have been used due to their resemblance with respect to anatomy and physiology. However, animal protection laws have evolved and primates have a restricted accessibility (Weatherall et al., 2007). Previous hair studies have demonstrated that both human and porcine hair follicles are anatomically close (Debeer et al., 2013; Mangelsdorf et al., 2014). Consequently, preliminary

trials on cultivated porcine lash follicles were performed as recently as 2016, whereby follicles from pigs intended for human consumption were used for organ culture assays (Paus et al., 2016). An elongation of the follicles was obtained within a few days. Hopefully, this study and future ones will enhance our knowledge on the lash and help to reduce the gap between studies on lashes and hair.

### **Imaging of lashes**

Imaging is a minimally invasive technique to quantify various parameters of human lashes. Observational studies with different age categories demonstrated that lashes change with age (Glaser et al., 2014; Procianoy et al., 2015). Characteristics such as the orientation, length, thickness and pigmentation were measured from photographs of the lower and upper lids (Glaser et al., 2014; Procianoy et al., 2015). Human and mouse eyelash life cycle phases have been estimated with photographs in several studies (Na et al., 2006; Paus et al., 2016; Tauchi et al., 2010; Thibaut et al., 2010). However, the measures were variable from one study to another due to non-standardized methodologies. To improve accuracy, Thibaut et al. (2010) observed preselected lashes over a nine-month period by measuring their length each week. Once again, while imaging of lashes estimates the parameters of the life cycle, more advanced techniques described above, such as xenotransplantation and follicle cultures, are routinely used to measure the same parameters for hair (Oh et al., 2016).

Imaging techniques have also been utilized for ethnic differences between the lashes of Caucasian and Asian women (Na et al., 2006). Digital photographs were used to calculate the lift-up and curl-up angles of the upper lashes and phototrichogram [allows *in vivo* study of the growth cycle] (Dhurat, 2006) for the number, length and thickness of lashes (Na et al., 2006). Smaller lash details such as the cuticle textures and layer density were observed *ex-vivo* with electron microscopy (Na et al., 2006).

### **Study on aerodynamics**

No *in vivo* studies of human lash aerodynamics exist to date in the literature. Only one *in vitro* study exists using a model of a mammalian eye to study the aerodynamics of particles around

eyelashes (Amador et al., 2015). The biophysics research team designed a wind tunnel in which air flow, that could affect the ocular surface, was recreated. The model had dimensions of an adult human eye, with a depth of 4 mm and a diameter of 20 mm, and was made with an aluminum dish. Water filled in the dish was used to mimic the tear film and a mesh was chosen to represent the lashes, after obtaining the same results with commercially available lashes made with human hair. Measurements of water evaporation on the ocular surface and calculation of particle deposition on the lashes were obtained using various mesh lengths. Optimal lash lengths that decreased evaporation and particle deposition were determined. Using fluid mechanic principles, the flow on the model eye's surface, as well as around and through lashes, were calculated. The optimal lash length determined was compared with other mammalian eyelash lengths, obtained by photographs from phylogenetically diverse preserved mammalian heads. They established that the optimal lash length was one third of the width of the eye. Aerodynamic analysis confirmed that this was the optimal length, because it reduced tear evaporation and deposition of particles on lashes by half. Short lashes created a zone of airflow stagnation above the ocular surface, while long lashes pushed the airflow towards the ocular surface. These aerodynamic studies highlighted the important role of lashes in the protection of the eye. *In vivo* studies should be carried out to validate these results on humans, but the wind tunnel effect would most undoubtedly induce an increased frequency of reflex blinking to protect the ocular surface. Based on this study, any alterations of lash length, be it with certain pharmaceuticals or cosmetic procedures [ie. lash extensions], would have an impact on the protective effect of the ocular surface. Further studies will be needed to validate this impact. Although the study provided an interesting insight into the role that lashes play in the aerodynamics at the front surface of the eye, there remained limitations. Some examples of those include the plane surface used in the model, instead of a convex surface, and water as the chosen composition to represent the tear film, which is more complex in mammals. Studying the protective role of lashes was unexplored before this study, and the authors have paved the way for future investigations in the aerodynamic role of *in vivo* human lashes.

## Pathophysiology of the lashes and their management

### Definitions of lash anomalies

During an evaluation of the anterior segment of the eye, ECPs need to assess the normalcy of several structures including eyelashes. There are several terms in the literature that define anomalies of hair anywhere on the body, however some are specific for eyelashes. Table 1 summarizes the different types of hair anomalies and their associated pathologies.

**Table 1.** Hair anomalies and their associated pathologies

Anomaly	Pathological condition	Lashes only	Description
Pigmentation	Poliosis		Decreased/absence of pigmentation in hair from any area of the body (Sleiman et al., 2013), by decreased/absence of melanin and/or hair follicle melanocytes (Meyer et al., 2009)
Direction and position	Trichiasis Distichiasis	X X	Primary trichiasis: misdirected lash, by misdirection of the hair shaft (Dutton et al., 2000) Secondary trichiasis: secondary to entropion, normal orientation of the hair shaft (Dutton et al., 2000) Abnormal row of lashes near or in the Meibomian glands; rare condition (Ferreira et al., 2010)
Growth	Hypotrichosis Milphosis Madarosis	X	Reduced hair density in any area of the body (Law, 2010) Lash loss (Vij et al., 2015) Lash and/or eyebrow loss (Vij et al., 2015)
Mixed	Hypertrichosis Trichomegaly		An increased of hair in any area of the body, beyond the normal variation for age, sex or race (Wendelin et al., 2003) Increased lash [ $>12$ mm] and/or eyebrow length, curl, stiffness, pigmentation and thickness (Almagro et al.,

			2003; Paul et al., 2012; Santmyire-Rosenberger et al., 2005)
--	--	--	--

There is a consensus on most definitions on eyelash anomalies with the exception of hypertrichosis and trichomegaly. The term hypertrichosis is commonly misinterpreted as a synonym for trichomegaly, even though they have distinct definitions. Hypertrichosis is defined as an increase in hair in any part of the body, whereas trichomegaly is specific for eyelashes and eyebrows (Almagro et al., 2003; Paul et al., 2012; Santmyire-Rosenberger et al., 2005). The definitions of hypertrichosis and trichomegaly adopted for this review reflect the ones used in recent publications (Almagro et al., 2003; Paul et al., 2012; Santmyire-Rosenberger et al., 2005). Also, the terms madarosis and milphosis are often confounded. In a clinical setting, the term madarosis is used to describe lash loss, however milphosis is the more appropriate term.

**Management of lash anomalies**

The etiology and management of poliosis, trichiasis, milphosis and trichomegaly have been summarized from the written literature, mainly from case reports [Table 2]. Depending on the etiology, a single pathology or several lash pathologies may be present simultaneously. As a result of the lack of substantive clinical trials on lash pathologies, Table 2 emphasizes the most frequently reported management strategies, and as such, is non-exhaustive.

**Table 2.** Etiologies and management of lash conditions

Pathological condition	Etiology	Management
Poliosis	Congenital syndromes (Dessinioti et al., 2009)  <b>Acquired conditions</b> (Kumar et al., 2016; Moorthy et al., 1995; Sleiman et al., 2013; Tabbara, 2012): melanocytic	No medication approved to restore lash pigmentation  <b>If ophthalmic-related:</b> treat underlying etiology (Jalalat et al., 2014) with results varying from no change to full recovery



	<p>lesions, inflammatory systemic disorders, blepharitis and vernal keratoconjunctivitis (VKC)</p> <p><b>Less common:</b> systemic/ophthalmic drug-induced (side effect of all topical prostaglandin analogues) (Chen et al., 2004; Nakakura et al., 2015; Ozyurt et al., 2015; Waheed et al., 2001)</p>	<p>of the pigmentation (Chen et al., 2004; Tabbara, 2012; Waheed et al., 2001)</p> <p><b>If systemic implication</b> (Jalalat et al., 2014): referred to the patient's primary care doctor</p>
Trichiasis	<p><b>Ophthalmic</b> (Ferreira et al., 2010): lid margin scars from trauma/surgery; lid margin inflammation; conjunctival diseases; conjunctival burns</p> <p>Various skin diseases (Ferreira et al., 2010)</p>	<p><b>Initial episode:</b> epilation of the affected lash(es) and soft contact lenses for short-term relief of induced conjunctival or corneal irritation (Chiou et al., 1998)</p> <p><b>Recurrent episode:</b> refer to an ophthalmologist for an ablation procedure [depends on the severity]: laser argon ablation (Basar et al., 2000; Yung et al., 1994), electrolysis (Benson, 1882), trephination (McCracken et al., 2006), direct internal lash bulb extirpation (Dutton et al., 2000), folliclectomy (Tirakunwichcha et al., 2006), cryotherapy (Elder et al., 1994), entropion surgery (Ballen, 1964)</p> <p><b>If skin disease suspected:</b> refer to a dermatologist</p>
	<p><b>Ophthalmic</b> (Vij et al., 2015); lid infestation [<i>staphylococcal spp.</i>, <i>Demodex folliculorum</i>, trachoma] and/or lid inflammation [posterior</p>	<p><b>Reversible follicle damage</b> (Khong et al., 2006): lash(es) regrowth possible; consider pharmaceutical approach to increase the regrowth rate [bimatoprost</p>

<p>Milphosis (loss of lashes)</p>	<p>blepharitis, ocular rosacea, seborrheic blepharitis]</p> <p><b>Associated with eyebrow madarosis</b> (Kumar et al., 2012): several dermatological diseases and inherited conditions</p> <p><b>Associated with eyebrow and hair madarosis</b> (Kumar et al., 2012): Extensive list of systemic and drug-induced conditions</p>	<p>ophthalmic solution 0.03% is the only approved drug in patients with healthy lashes and hypotrichosis] (Barron-Hernandez et al., 2017; Fagien, 2010; Smith et al., 2012; Zaleski-Larsen et al., 2017)</p> <p><b>Irreversible follicle damage:</b> no lash regrowth</p> <p><b>Severe irreversible milphosis:</b> refer to an oculoplastic surgeon for lash grafting consideration (Kumar et al., 2012)</p>
<p>Trichomegaly</p>	<p><b>Congenital syndromes</b> (Kaur et al., 2015): Oliver-McFarlane and Cornelia de Lange</p> <p><b>Familial</b></p> <p><b>Acquired</b> (Paul et al., 2012): Allergic rhinitis, atopic dermatitis, HIV infection, uveitis and VKC</p> <p><b>Drug-induced</b> (Paul et al., 2012): Topical prostaglandin analogues and epidermal growth factor receptor [EGFR] inhibitors used in oncology</p>	<p>Trimming of the affected lashes if visual disturbance or smudging with inner surface of eyeglass lens (Dueland et al., 2003; Lacouture et al., 2006; Robert et al., 2005)</p> <p>With concomitant trichiasis (Chiou et al., 1998): refer to trichiasis management [above]</p>

It is essential for ECPs to first determine the etiology of the lash pathology to select the appropriate management. In the particular case of milphosis without a clear etiology, ECPs must consider a psychiatric disorder called trichotillomania as a possible causal factor, regardless of

the concomitance of eyebrow and/or hair madarosis. Trichotillomania is characterized by an uncontrollable urge to pull out hair from any part of the body (Christenson et al., 1991) and a referral for a psychological evaluation should be considered. This condition can be managed by investigating the cause of the behaviour and, in some cases, pharmacotherapy is recommended (Johnson et al., 2016).

The etiology of the lash pathology also affects the appearance of the lashes, which may affect the patient's esthetic appearance. For example, common causes of trichomegaly, such as HIV infection and allergic rhinitis, will induce the regrowth of long and smooth lashes, while epidermal growth factor receptor [EGFR] inhibitors make them rougher and more dispersed (Paul et al., 2012). The appearance of eyelashes also has a major impact on the quality of life, as hair loss can cause various degrees of psychological distress (Phillips et al., 2017). Dunnill et al. (2017) have demonstrated that the most distressing side effect of chemotherapy is the loss of hair. Other systemic diseases that induce hair loss can be stressful for the affected person, such as alopecia areata, which is characterized by a patchy loss of scalp hair. This disease can progress to other parts of the body, including eyelashes (Liu et al., 2016). Although the exact pathophysiological mechanism is not established yet, it is thought to be caused by an autoimmune attack on hair follicles (Dainichi et al., 2017). Patients with alopecia areata have poor health-related quality life scores similar to what is established in other chronic skin diseases, as demonstrated in two systematic studies (Liu et al., 2016; Rencz et al., 2016).

As seen in Table 2, the management of lash pathologies will be influenced by their causal agent. When the lash pathology severity ranges from mild to moderate, this can be managed by an ECP in most cases. To date, there is only one pharmaceutical option approved for eyelash loss [lash hypotrichosis], consisting of a topical application of bimatoprost ophthalmic solution 0.03% [Latisse, Allergan] along the superior lash base. It's mode of action is to prolong the anagen phase of the lash life cycle (Barron-Hernandez et al., 2017), hence resulting in an increased lash length, thickness and pigmentation (Barron-Hernandez et al., 2017; Fagien, 2010; Smith et al., 2012; Zaleski-Larsen et al., 2017). Before using this product, patients should always seek the advice of an ECP. If adverse events occur, such as discomfort and skin pigmentation, discontinuation of the product will typically reverse the effects. Some cases of poliosis have

been reported following prostaglandin analogues use (Chen et al., 2004). To date, there is no medication approved to restore the pigmentation of lashes.

Severe lash pathologies must be referred to specialists for an ablation procedure (Basar et al., 2000; Benson, 1882; McCracken et al., 2006; Tirakunwichcha et al., 2006), eyelash grafts (Kumar et al., 2012), lid reconstruction (Choo, 2002; Khafagy et al., 2012) or systemic therapies (Dainichi et al., 2017). Promising therapies are emerging for hair loss, which can lead to the discovery of new treatments for eyelashes specifically. Dainichi and Kabashima (2017) have reviewed all current therapies and treatments that have an effect on hair regrowth in alopecia areata and universalis [subtype of alopecia that also affect the lashes]. In alopecia universalis, hair regrowth has been observed with medications such as topical immunotherapy and corticosteroids (Dainichi et al., 2017). However, these studies focused on scalp hair regrowth and did not collect data on the regrowth rate of lashes. Data from scalp hair studies may guide future therapies for eyelashes.

### **Lid margin microflora**

The inherent microflora of the lid margin also plays a vital role in maintaining the lashes free of anomalies. The lid margin typically contains a microflora composed of commensal bacteria and parasites. A disruption of the balance of this microflora can lead to various types of blepharitis (Nicholls et al., 2017). Lee et al. (2012) have demonstrated that the most common bacteria found in lash samples were *Propionibacterium*, *Staphylococcus*, *Streptophyta*, *Corynebacterium* and *Enhydrobacter*. The variety of the lash microflora is unique to each individual. The study further highlighted that when blepharitis was diagnosed, *Staphylococcus*, *Streptophyta*, *Corynebacterium*, and *Enhydrobacter* were increased whereas *Propionibacterium* was decreased. Due to the constant contact of the lids with the ambient air, the lid microflora is particularly influenced by environmental factors, such as pollen, dust, and soil particles. Furthermore, touching our lids with our fingers can inoculate other varieties of the microflora, contributing to the dynamic nature of the lid margin microflora.

Bacterial overpopulation can be observed clinically with the presence of debris on the lashes. *Acute Staphylococcal* blepharitis is identified with collarettes, which are hard crusts on lashes, and with other non-specific signs [squame/scale, telangiectasia vessels, Meibomian gland dysfunction] (Bernardes et al., 2010). Chronic signs are madarosis, trichiasis, poliosis, tylosis or scars on the lid margin (Bernardes et al., 2010; Nicholls et al., 2017). Blepharitis can also be caused by other micro-organisms, such as parasites. Three types of parasites, all arthropods, can inhabit the lid margin: *Demodex folliculorum*, *Demodex brevis* and *Phthirus pubis* (Padhi et al., 2017). *Demodex* parasites are part of the natural eye microflora (Nicholls et al., 2017) and their number increases with age, so much so that one study has reported 100% prevalence in people over 70 years old (Roth, 1979). *D. folliculorum* is mostly found in the lash follicle and other parts of the body such as eyebrows, scalp, nose and ears. *D. Brevis* is found mainly in the Meibomian glands and other sebaceous glands, such as the face (Liu et al., 2010). The anatomy of the *Demodex* parasite consists of a head with four pairs of legs on either side and an elongated body/tail that contains the digestive system. The parasite has no anus, hence all the ingested material remains in the gut, along with its own microflora of *Streptococcus spp.*, *Staphylococcus spp.* and *Bacillus oleronius* (Szkardkiewicz et al., 2012). At the end of its life cycle, approximately 15-18 days in length, the parasite bursts and releases its content, which can provoke an inflammatory response (Liu et al., 2010; Szkardkiewicz et al., 2012). An overpopulation of the parasite is called a demodicosis, and on the lids, this would be termed blepharitis secondary to *Demodex*. Since *Demodex* has the potential to affect both the anterior [lashes] and posterior [Meibomian glands] portion of the lid margin, some (Duncan et al., 2015) have proposed the term marginal blepharitis to describe a demodicosis of the lid margin. Clinical signs of demodicosis include follicular hypertrophy (Liu et al., 2010), gelatinous debris surrounding the base of the lashes termed cylindrical dandruff (Gao et al., 2005), and non-specific blepharitis signs as stated above. Cylindrical dandruff is a pathognomonic sign for *Demodex* (Gao et al., 2005). On the other hand, the parasite *Phthirus pubis* is not found in the normal lid microflora, as it originates in pubic hair. It can be transmitted by sexual contact and less often through linens and bedding (Anane et al., 2013). Transfer of the parasite from the infested region to the hand can reach any hair on the body, including the eyelashes (Turgut et al., 2009). The resulting blepharitis is termed *Phthiriasis palpebrarum* and its clinical presentation, in one or both eyes, includes the translucent parasite's body firmly attached to

lashes, brown scales corresponding to the parasite's feces, and multiple nits (unhatched parasites) fixed on the lashes and the lid margin (Anane et al., 2013; Turgut et al., 2009). Symptoms include itchiness and irritation of the lid margin (Anane et al., 2013).

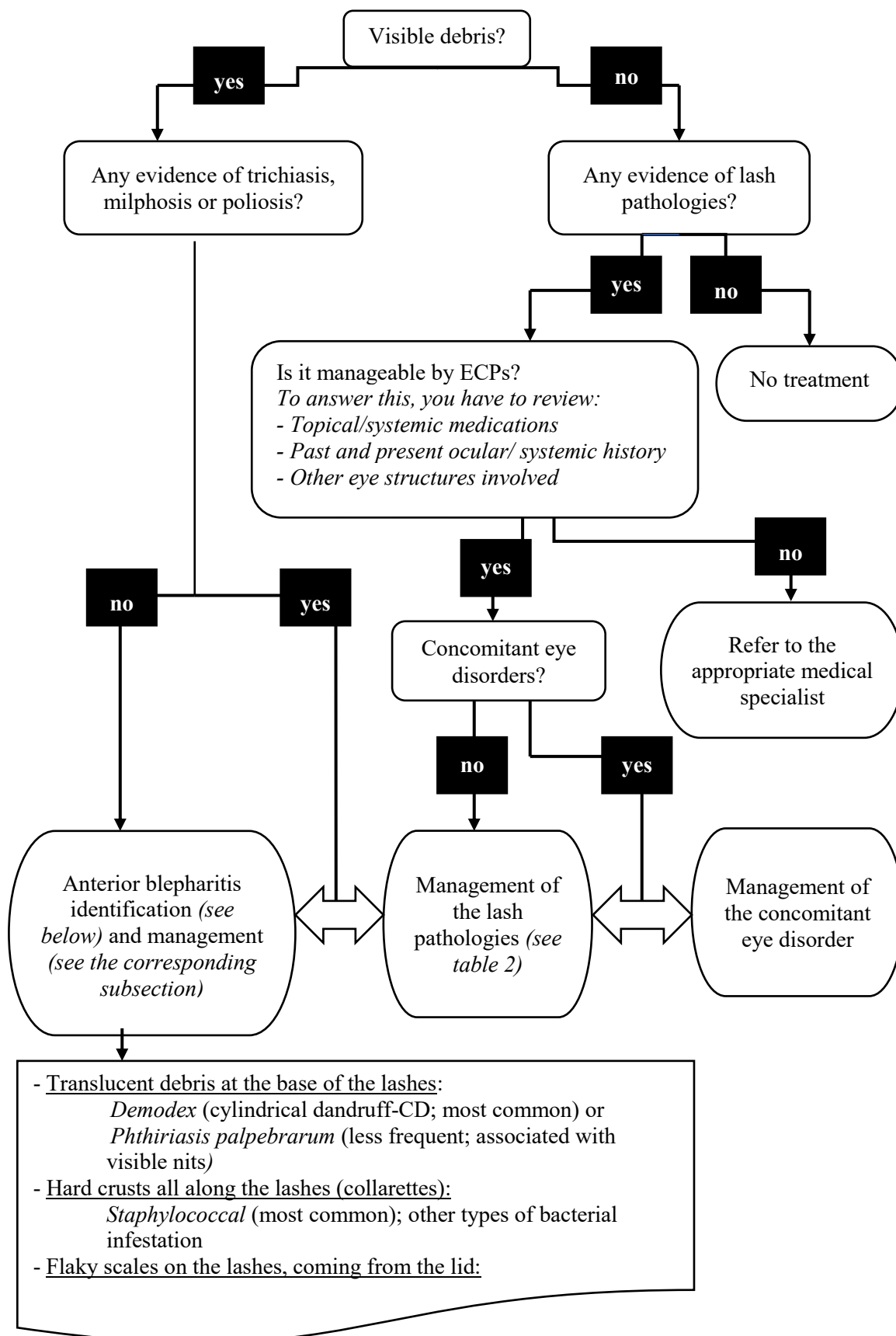
Finally, blepharitis can be the result of seborrheic dermatitis, a dermatological condition affecting the skin and, in some cases, the lid margin. Many etiologies have been proposed and researchers are still looking for the exact mechanism (Paulino, 2017). An imbalance in the skin micro-organisms might be the cause (Paulino, 2017). Other than the non-specific signs of blepharitis detailed above, ECPs can observe some flaky scales on the lids that can fall on the lashes (Wolf et al., 2014). When the condition affects the anterior portion of the lid, it is called seborrheic blepharitis.

### **Management of anterior blepharitis**

The aim in blepharitis management is to restore the normal microflora (Nicholls et al., 2016). A complete eradication of *Phthiriasis palpebrarum* is desired and can be achieved by mechanical removal of the parasites and nits (Dagdelen et al., 2013; Padhi et al., 2017). Blepharitis secondary to the imbalance of the microflora are chronic conditions. Hence, they are not expected to be completely eradicated. First line therapies of blepharitis include warm compresses to soften the debris and eyelid hygiene to manually dislodge them (Lindsley et al., 2012). Targeted lid margin therapies should be adopted by ECPs, including antibacterial for *Staphylococcal* infestation (Liu et al., 2010) and anti-parasitic formulations for *Demodex* parasites (Gao et al., 2005; Ngo et al., 2017), in order to limit lid margin anomalies that come with chronic blepharitis. To target properly seborrheic blepharitis, a reference to dermatology is required to establish the diagnosis of seborrheic dermatitis and treat the affected skin with the appropriate pharmaceutical (Paulino, 2017).

### **ECP assessment of lashes**

Figure 4 summarizes in a flowchart the management of debris on eyelashes. This tool can be used when teaching students or residents to identify and localize debris on lashes and select the appropriate management.



## **Figure 4: Eyelash debris assessment by eyecare professionals**

### **Iatrogenic factors**

The appearance of eyelashes is an increasingly growing preoccupation in many people who are seeking an aesthetic enhancement. Cosmetics have been used since biblical times to improve the aesthetic of the eye and the thickness, length and color of eyelashes (Draelos, 2001). Lash tints and extensions are newer and popular, surpassing expectations in the cosmetic marketplace. Over \$55 million in 2014 were dedicated to eyelash extension and adhesives alone in the US (Statista). Synthetic lashes are glued individually on the natural lashes with different adhesives, which have been linked to ocular problems such as keratoconjunctivitis (Amano et al., 2012). In most cases, the glue and removing agents have induced inflammation on the eye, by direct contact with the ocular surface. Furthermore, the vapors associated with the application, or the dissolving, of the glue afterwards have been reported as ocular irritants. Lash tinting is done with dyes that contain *p*-phenylenediamine, a sensitizer that can provoke an allergic reaction and contact dermatitis (Ali et al., 2017; Teixeira et al., 2006). Water-based mascara is made of several waxes, types of pigment and resins dissolved in water, whereas solvent-based mascara, known as waterproof, has its pigments and waxes added in petroleum distillates (Draelos, 2001). Fukami et al. (2014) found a positive correlation between the frequency of mascara use and the degree of cracking in the lash cuticles. Also, long-term use of mascara led to milphosis, possibly due to the rubbing, with fingers and water only, by the users (Kadri et al., 2013). Needless to say, eye cosmetics in general can have an impact on the lids, lashes, tear film and ocular surface (Ng et al., 2016). Consequently, patients need to be educated appropriately about the application, removal, shelf life and associated precautions of cosmetic use.

### **Conclusion**

This review brings a deeper awareness on the eyelashes and their follicles. The current literature has numerous cases of how lashes are affected by systemic/eye diseases, pharmaceuticals and cosmetics, and how they change the lash morphology. In addition, an imbalance of the lash microenvironment can lead to a variety of blepharitis and impact negatively the adjoining lid margin. Many studies have demonstrated that lashes do not serve only a cosmetic function, but



also a protective role on the lid margin and the ocular surface. The lash follicle structures are mostly studied with *ex vivo* techniques, which are limited by the poor availability of the human lid sampling. This review further highlights the challenges when studying the lash follicle and the need to develop newer techniques. Increasing lash research will certainly improve the efficiency of ECP's interventions in lash anomalies.

## **Acknowledgements**

A special thanks to Micheline Gloin for her graphic assistance.

## **Funding**

This research did not receive any specific grant from funding agencies in the public, commercial, or not-for-profit sectors.

## **Conflict of interest**

SA has received honorarium for conferences/consulting from Allergan and Shire. EB has received funding from Alcon, Allergan, Canadian Optometric Trust Fund, I-Med Pharma Inc, Shire and honorarium for conferences/consulting from Akorn, Alcon, Allergan, American Academy of Optometry, Canadian Association of Optometry, CooperVision, Labtician, Jobson Publishing, Novartis, Santen, Shire.

## **References**

- Ali, L., Foulds, J. S. et Abdul Ghaffar, S. (2017). Severe eyelid allergic contact dermatitis secondary to eyelash tint: two case reports. *Contact Dermatitis*, 77(1), 59-60.
- Almagro, M., del Pozo, J., Garcia-Silva, J., Martinez, W., Castro, A., et al. (2003). Eyelash length in HIV-infected patients. *AIDS*, 17(11), 1695-1696.
- Amador, G. J., Mao, W., DeMercurio, P., Montero, C., Clewis, J., et al. (2015). Eyelashes divert airflow to protect the eye *J R Soc Interface* (Vol. 12).
- Amano, Y., Sugimoto, Y. et Sugita, M. (2012). Ocular disorders due to eyelash extensions. *Cornea*, 31(2), 121-125.

- Anane, S., Malek, I., Kamoun, R. et Chtourou, O. (2013). Phthiriasis palpebrarum: diagnosis and treatment. *Journal Français d'Ophtalmologie*, 36(10), 815-819.
- Arck, P. C., Overall, R., Spatz, K., Liezman, C., Handjiski, B., et al. (2006). Towards a "free radical theory of graying": melanocyte apoptosis in the aging human hair follicle is an indicator of oxidative stress induced tissue damage. *FASEB Journal*, 20(9), 1567-1569.
- Ballen, P. H. (1964). A Simple Procedure for the Relief of Trichiasis and Entropion of the Upper Lid. *Archives of Ophthalmology*, 72, 239-240.
- Barron-Hernandez, Y. L. et Tosti, A. (2017). Bimatoprost for the treatment of eyelash, eyebrow and scalp alopecia. *Expert Opin Investig Drugs*, 26(4), 515-522.
- Basar, E., Ozdemir, H., Ozkan, S., Cicik, E. et Mirzatas, C. (2000). Treatment of trichiasis with argon laser. *European Journal of Ophthalmology*, 10(4), 273-275.
- Benson, A. (1882). On the Treatment of Partial Trichiasis by Electrolysis. *British Medical Journal*, 2(1146), 1203-1204.
- Bernardes, T. F. et Bonfioli, A. A. (2010). Blepharitis. *Seminars in Ophthalmology*, 25(3), 79-83.
- Chen, C. S., Wells, J. et Craig, J. E. (2004). Topical prostaglandin F(2alpha) analog induced poliosis. *American Journal of Ophthalmology*, 137(5), 965-966.
- Chiou, A. G. Y., Florakis, G. J. et Kazim, M. (1998). Management of Conjunctival Cicatrizing Diseases and Severe Ocular Surface Dysfunction. *Survey of Ophthalmology*, 43(1), 19-46.
- Choo, P. H. (2002). Distichiasis, trichiasis, and entropion: advances in management. *International Ophthalmology Clinics*, 42(2), 75-87.
- Christenson, G. A., Popkin, M. K., Mackenzie, T. B. et Realmuto, G. M. (1991). Lithium treatment of chronic hair pulling. *Journal of Clinical Psychiatry*, 52(3), 116-120.
- Commo, S., Gaillard, O. et Bernard, B. A. (2004). Human hair greying is linked to a specific depletion of hair follicle melanocytes affecting both the bulb and the outer root sheath. *British Journal of Dermatology*, 150(3), 435-443.
- Commo, S., Gaillard, O., Thibaut, S. et Bernard, B. A. (2004). Absence of TRP-2 in melanogenic melanocytes of human hair. *Pigment Cell Research*, 17(5), 488-497.
- Craig, J. P., Nichols, K. K., Akpek, E. K., Caffery, B., Dua, H. S., et al. (2017). TFOS DEWS II Definition and Classification Report. *Ocul Surf*, 15(3), 276-283.

- Dagdelen, S., Aykan, U. et Cetinkaya, K. (2013). Phthriasis palpebrarum can resemble tick larva infestation in an eyelid. *Journal of AAPOS*, 17(4), 440-442.
- Dainichi, T. et Kabashima, K. (2017). Alopecia areata: What's new in epidemiology, pathogenesis, diagnosis, and therapeutic options? *Journal of Dermatological Science*, 86(1), 3-12.
- Debeer, S., Le Luduec, J. B., Kaiserlian, D., Laurent, P., Nicolas, J. F., et al. (2013). Comparative histology and immunohistochemistry of porcine versus human skin. *European Journal of Dermatology*, 23(4), 456-466.
- Dessinioti, C., Stratigos, A. J., Rigopoulos, D. et Katsambas, A. D. (2009). A review of genetic disorders of hypopigmentation: lessons learned from the biology of melanocytes. *Experimental Dermatology*, 18(9), 741-749.
- Dhurat, R. (2006). Phototrichogram. *Indian Journal of Dermatology, Venereology and Leprology*, 72(3), 242-244.
- Draelos, Z. D. (2001). Special considerations in eye cosmetics. *Clinics in Dermatology*, 19(4), 424-430.
- Draelos, Z. K. (1991). Eye cosmetics. *Dermatologic Clinics*, 9(1), 1-7.
- Dueland, S., Sauer, T., Lund-Johansen, F., Ostenstad, B. et Tveit, K. M. (2003). Epidermal growth factor receptor inhibition induces trichomegaly. *Acta Oncologica*, 42(4), 345-346.
- Duncan, K. et Jeng, B. H. (2015). Medical management of blepharitis. *Current Opinion in Ophthalmology*, 26(4), 289-294.
- Dunnill, C. J., Al-Tameemi, W., Collett, A., Haslam, I. S. et Georgopoulos, N. T. (2017). A Clinical and Biological Guide for Understanding Chemotherapy-Induced Alopecia and Its Prevention. *Oncologist*.
- Dutton, J. J., Tawfik, H. A., DeBacker, C. M. et Lipham, W. J. (2000). Direct internal eyelash bulb extirpation for trichiasis. *Ophthalmic Plastic and Reconstructive Surgery*, 16(2), 142-145.
- Elder, M. J. et Bernauer, W. (1994). Cryotherapy for trichiasis in ocular cicatricial pemphigoid. *British Journal of Ophthalmology*, 78(10), 769-771.
- Fagien, S. (2010). Management of hypotrichosis of the eyelashes: Focus on bimatoprost. *Clinical, Cosmetic and Investigational Dermatology*, 3, 39-48.

- Ferreira, I. S., Bernardes, T. F. et Bonfioli, A. A. (2010). Trichiasis. *Seminars in Ophthalmology*, 25(3), 66-71.
- Fukami, K., Inoue, T., Kawai, T., Takeuchi, A., Uesugi, K., et al. (2014). Internal structure changes of eyelash induced by eye makeup. *J Cosmet Sci*, 65(4), 217-224.
- Gao, Y. Y., Di Pascuale, M. A., Li, W., Baradaran-Rafii, A., Elizondo, A., et al. (2005). In vitro and in vivo killing of ocular Demodex by tea tree oil. *British Journal of Ophthalmology*, 89(11), 1468-1473.
- Gao, Y. Y., Di Pascuale, M. A., Li, W., Liu, D. T., Baradaran-Rafii, A., et al. (2005). High prevalence of Demodex in eyelashes with cylindrical dandruff. *Investigative Ophthalmology and Visual Science*, 46(9), 3089-3094.
- Gilhar, A., Keren, A. et Paus, R. (2013). A new humanized mouse model for alopecia areata. *Journal of Investigative Dermatology. Symposium Proceedings*, 16(1), S37-38.
- Glaser, D. A., Jones, D., Carruthers, J., Campo, A., Moench, S., et al. (2014). Epidemiologic analysis of change in eyelash characteristics with increasing age in a population of healthy women. *Dermatologic Surgery*, 40(11), 1208-1213.
- Harries, M. J., Meyer, K., Chaudhry, I., J, E. K., Poblet, E., et al. (2013). Lichen planopilaris is characterized by immune privilege collapse of the hair follicle's epithelial stem cell niche. *Journal of Pathology*, 231(2), 236-247.
- Hashimoto, T., Kazama, T., Ito, M., Urano, K., Katakai, Y., et al. (2000). Histologic and cell kinetic studies of hair loss and subsequent recovery process of human scalp hair follicles grafted onto severe combined immunodeficient mice. *Journal of Investigative Dermatology*, 115(2), 200-206.
- Jalalat, S. Z., Kelsoe, J. R. et Cohen, P. R. (2014). Alopecia areata with white hair regrowth: case report and review of poliosis. *Dermatology Online Journal*, 20(9).
- Johnson, J. et El-Alfy, A. T. (2016). Review of available studies of the neurobiology and pharmacotherapeutic management of trichotillomania. *J Adv Res*, 7(2), 169-184.
- Jones, D. (2011). Enhanced eyelashes: prescription and over-the-counter options. *Aesthetic Plastic Surgery*, 35(1), 116-121.
- Kadri, R., Achar, A., Tantry, T. P., Parameshwar, D., Kudva, A., et al. (2013). Mascara induced milphosis, an etiological evaluation. *Int J Trichology*, 5(3), 144-147.

- Kaur, S. et Mahajan, B. B. (2015). Eyelash Trichomegaly. *Indian Journal of Dermatology*, 60(4), 378-380.
- Khafagy, A., Mostafa, M. M. et Fooshan, F. (2012). Management of trichiasis with lid margin split and cryotherapy. *Clinical Ophthalmology (Auckland, N.Z.)*, 6, 1815-1817.
- Khong, J. J., Casson, R. J., Huilgol, S. C. et Selva, D. (2006). Madarosis. *Survey of Ophthalmology*, 51(6), 550-560.
- Kloepper, J. E., Sugawara, K., Al-Nuaimi, Y., Gaspar, E., van Beek, N., et al. (2010). Methods in hair research: how to objectively distinguish between anagen and catagen in human hair follicle organ culture. *Experimental Dermatology*, 19(3), 305-312.
- Kumar, A. et Karthikeyan, K. (2012). Madarosis: a marker of many maladies. *Int J Trichology*, 4(1), 3-18.
- Kumar, S. et Al Khars, W. (2016). Vitiligo in association with vernal keratoconjunctivitis. *Saudi J Ophthalmol*, 30(2), 128-129.
- Lacouture, M. E., Boerner, S. A. et Lorusso, P. M. (2006). Non-rash skin toxicities associated with novel targeted therapies. *Clinical Lung Cancer*, 8 Suppl 1, S36-42.
- Langan, E. A., Philpott, M. P., Kloepper, J. E. et Paus, R. (2015). Human hair follicle organ culture: theory, application and perspectives. *Experimental Dermatology*, 24(12), 903-911.
- Law, S. K. (2010). Bimatoprost in the treatment of eyelash hypotrichosis. *Clinical Ophthalmology (Auckland, N.Z.)*, 4, 349-358.
- Lee, S. H., Oh, D. H., Jung, J. Y., Kim, J. C. et Jeon, C. O. (2012). Comparative ocular microbial communities in humans with and without blepharitis. *Investigative Ophthalmology and Visual Science*, 53(9), 5585-5593.
- Lindsley, K., Matsumura, S., Hatf, E. et Akpek, E. K. (2012). Interventions for chronic blepharitis. *Cochrane Database Syst Rev*(5), CD005556.
- Liotet, S., Riera, M. et Nguyen, H. (1977). Les cils. Physiologie, structure, pathologie. *Archives d'Ophthalmologie*, 37(11), 697-708.
- Liu, J., Sheha, H. et Tseng, S. C. (2010). Pathogenic role of Demodex mites in blepharitis. *Current Opinion in Allergy and Clinical Immunology*, 10(5), 505-510.

- Liu, L. Y., King, B. A. et Craiglow, B. G. (2016). Health-related quality of life (HRQoL) among patients with alopecia areata (AA): A systematic review. *Journal of the American Academy of Dermatology*, 75(4), 806-812 e803.
- Mangelsdorf, S., Vergou, T., Sterry, W., Lademann, J. et Patzelt, A. (2014). Comparative study of hair follicle morphology in eight mammalian species and humans. *Skin Research and Technology*, 20(2), 147-154.
- Marieb, E. (2005). Le système tégumentaire (Traduit par R. Lachaine). Dans ERPi (dir.), *Anatomie et physiologie humaines* (3<sup>e</sup> éd., p. 156-208).
- McCracken, M. S., Kikkawa, D. O. et Vasani, S. N. (2006). Treatment of trichiasis and distichiasis by eyelash trephination. *Ophthalmic Plastic and Reconstructive Surgery*, 22(5), 349-351.
- Meyer, K. C., Brzoska, T., Abels, C. et Paus, R. (2009). The alpha-melanocyte stimulating hormone-related tripeptide K(D)PT stimulates human hair follicle pigmentation in situ under proinflammatory conditions. *British Journal of Dermatology*, 160(2), 433-437.
- Montagna, W. et Ford, D. M. (1969). Histology and cytochemistry of human skin. 3. The eyelid. *Archives of Dermatology*, 100(3), 328-335.
- Moorthy, R. S., Inomata, H. et Rao, N. A. (1995). Vogt-Koyanagi-Harada syndrome. *Survey of Ophthalmology*, 39(4), 265-292.
- Na, J. I., Kwon, O. S., Kim, B. J., Park, W. S., Oh, J. K., et al. (2006). Ethnic characteristics of eyelashes: a comparative analysis in Asian and Caucasian females. *British Journal of Dermatology*, 155(6), 1170-1176.
- Nakakura, S., Yamamoto, M., Terao, E., Nagatomi, N., Matsuo, N., et al. (2015). Prostaglandin-associated periorbitopathy in latanoprost users. *Clinical Ophthalmology (Auckland, N.Z.)*, 9, 51-56.
- Nesher, R., Mimouni, M., Elnaddaf, H., Nemet, A. et Kidron, D. (2015). Characterization of prostaglandin F2alpha receptors in human eyelids. *European Journal of Ophthalmology*, 25(2), 81-84.
- Ng, A., Evans, K., North, R. V., Jones, L. et Purslow, C. (2016). Impact of Eye Cosmetics on the Eye, Adnexa, and Ocular Surface. *Eye Contact Lens*, 42(4), 211-220.
- Ngo, W., Jones, L. et Bitton, E. (2017). Short-Term Comfort Responses Associated With the Use of Eyelid Cleansing Products to Manage Demodex folliculorum. *Eye Contact Lens*.

- Nicholls, S. G., Oakley, C. L., Tan, A. et Vote, B. J. (2016). Demodex species in human ocular disease: new clinicopathological aspects. *International Ophthalmology*.
- Nicholls, S. G., Oakley, C. L., Tan, A. et Vote, B. J. (2017). Demodex species in human ocular disease: new clinicopathological aspects. *International Ophthalmology*, 37(1), 303-312.
- Oh, J. W., Kloepper, J., Langan, E. A., Kim, Y., Yeo, J., et al. (2016). A Guide to Studying Human Hair Follicle Cycling In Vivo. *Journal of Investigative Dermatology*, 136(1), 34-44.
- Ozyurt, S. et Cetinkaya, G. S. (2015). Hypertrichosis of the malar areas and poliosis of the eyelashes caused by latanoprost. *Actas Dermo-Sifiliograficas*, 106(1), 74-75.
- Padhi, T. R., Das, S., Sharma, S., Rath, S., Rath, S., et al. (2017). Ocular parasitoses: A comprehensive review. *Survey of Ophthalmology*, 62(2), 161-189.
- Paul, L. J., Cohen, P. R. et Kurzrock, R. (2012). Eyelash trichomegaly: review of congenital, acquired, and drug-associated etiologies for elongation of the eyelashes. *International Journal of Dermatology*, 51(6), 631-646; 643-634, 646.
- Paulino, L. C. (2017). New perspectives on dandruff and seborrheic dermatitis: lessons we learned from bacterial and fungal skin microbiota. *European Journal of Dermatology*, 27(S1), 4-7.
- Paus, R., Burgoa, I., Platt, C. I., Griffiths, T., Poblet, E., et al. (2016). Biology of the eyelash hair follicle: an enigma in plain sight. *British Journal of Dermatology*, 174(4), 741-752.
- Phillips, T. G., Slomiany, W. P. et Allison, R. (2017). Hair Loss: Common Causes and Treatment. *American Family Physician*, 96(6), 371-378.
- Philpott, M. P., Green, M. R. et Kealey, T. (1990). Human hair growth in vitro. *Journal of Cell Science*, 97 ( Pt 3), 463-471.
- Procianoy, F., Mendonca, T. B., Bins, C. A. et Lang, M. P. (2015). Characterization of Normal Mediolateral Angular Direction of Lower Eyelid Eyelashes in Different Age Groups. *Ophthalmic Plastic and Reconstructive Surgery*, 31(4), 332-333.
- Rencz, F., Gulacsi, L., Pentek, M., Wikonkal, N., Baji, P., et al. (2016). Alopecia areata and health-related quality of life: a systematic review and meta-analysis. *British Journal of Dermatology*, 175(3), 561-571.
- Robert, C., Soria, J. C., Spatz, A., Le Cesne, A., Malka, D., et al. (2005). Cutaneous side-effects of kinase inhibitors and blocking antibodies. *Lancet Oncology*, 6(7), 491-500.

- Roth, A. M. (1979). Demodex folliculorum in hair follicles of eyelid skin. *Annals of Ophthalmology*, 11(1), 37-40.
- Santmyre-Rosenberger, B. R. et Albert, M. (2005). Acquired trichomegaly with topiramate. *Journal of the American Academy of Dermatology*, 53(2), 362-363.
- Schallreuter, K., Slominski, A., Pawelek, J. M., Jimbow, K. et Gilchrest, B. A. (1998). What controls melanogenesis? *Experimental Dermatology*, 7(4), 143-150.
- Sleiman, R., Kurban, M., Succaria, F. et Abbas, O. (2013). Poliosis circumscripta: overview and underlying causes. *Journal of the American Academy of Dermatology*, 69(4), 625-633.
- Smith, K. R. et Thiboutot, D. M. (2008). Thematic review series: skin lipids. Sebaceous gland lipids: friend or foe? *Journal of Lipid Research*, 49(2), 271-281.
- Smith, S., Fagien, S., Whitcup, S. M., Ledon, F., Somogyi, C., et al. (2012). Eyelash growth in subjects treated with bimatoprost: a multicenter, randomized, double-masked, vehicle-controlled, parallel-group study. *Journal of the American Academy of Dermatology*, 66(5), 801-806.
- Statista. (2017). Annual sales of the leading false eyelashes and adhesives in the United States in 2014 (in million U.S. dollars). Repéré le October 2017 à <https://www.statista.com/statistics/323101/sales-of-false-eyelashes-and-adhesives-in-the-us>
- Stoeckelhuber, M., Stoeckelhuber, B. M. et Welsch, U. (2003). Human glands of Moll: histochemical and ultrastructural characterization of the glands of Moll in the human eyelid. *Journal of Investigative Dermatology*, 121(1), 28-36.
- Szkaradkiewicz, A., Chudzicka-Strugala, I., Karpinski, T. M., Goslinska-Pawlowska, O., Tulecka, T., et al. (2012). Bacillus oleronius and Demodex mite infestation in patients with chronic blepharitis. *Clinical Microbiology and Infection*, 18(10), 1020-1025.
- Tabbara, K. F. (2012). Reversal of poliosis and vitiligo following Vogt-Koyanagi-Harada disease. *Archives of Ophthalmology*, 130(3), 394-396.
- Tauchi, M., Fuchs, T. A., Kellenberger, A. J., Woodward, D. F., Paus, R., et al. (2010). Characterization of an in vivo model for the study of eyelash biology and trichomegaly: mouse eyelash morphology, development, growth cycle, and anagen prolongation by bimatoprost. *British Journal of Dermatology*, 162(6), 1186-1197.



- Teixeira, M., de Wachter, L., Ronsyn, E. et Goossens, A. (2006). Contact allergy to para-phenylenediamine in a permanent eyelash dye. *Contact Dermatitis*, 55(2), 92-94.
- Thibaut, S., Barbarat, P., Leroy, F. et Bernard, B. A. (2007). Human hair keratin network and curvature. *International Journal of Dermatology*, 46 7-10.
- Thibaut, S., De Becker, E., Caisey, L., Baras, D., Karatas, S., et al. (2010). Human eyelash characterization. *British Journal of Dermatology*, 162(2), 304-310.
- Thibaut, S., Gaillard, O., Bouhanna, P., Cannell, D. W. et Bernard, B. A. (2005). Human hair shape is programmed from the bulb. *British Journal of Dermatology*, 152(4), 632-638.
- Tirakunwichcha, S., Tinnangwattana, U., Hiranwiwatkul, P. et Rohitopakarn, S. (2006). Folliculectomy: management in segmental trichiasis and distichiasis. *Journal of the Medical Association of Thailand*, 89(1), 90-93.
- Tobin, D. J. (2008). Human hair pigmentation--biological aspects. *International Journal of Cosmetic Science*, 30(4), 233-257.
- Turgut, B., Kurt, J., Catak, O. et Demir, T. (2009). Phthriasis palpebrarum mimicking lid eczema and blepharitis. *J Ophthalmol*, 2009, 803951.
- Vij, A. et Bergfeld, W. F. (2015). Madarosis, milphosis, eyelash trichomegaly, and dermatochalasis. *Clinics in Dermatology*, 33(2), 217-226.
- Waheed, K. et Laganowski, H. (2001). Bilateral poliosis and granulomatous anterior uveitis associated with latanoprost use and apparent hypotrichosis on its withdrawal. *Eye (London, England)*, 15(Pt 3), 347-349.
- Weatherall, D. et Munn, H. (2007). Moving the primate debate forward. *Science*, 316(5822), 173.
- Wendelin, D. S., Pope, D. N. et Mallory, S. B. (2003). Hypertrichosis. *Journal of the American Academy of Dermatology*, 48(2), 161-182.
- Willcox, M. D. P., Argueso, P., Georgiev, G. A., Holopainen, J. M., Laurie, G. W., et al. (2017). TFOS DEWS II Tear Film Report. *Ocul Surf*, 15(3), 366-403.
- Wolf, R., Orion, E. et Tuzun, Y. (2014). Periorbital (eyelid) dermatides. *Clinics in Dermatology*, 32(1), 131-140.
- Yung, C. W., Massicotte, S. J. et Kuwabara, T. (1994). Argon laser treatment of trichiasis: a clinical and histopathologic evaluation. *Ophthalmic Plastic and Reconstructive Surgery*, 10(2), 130-136.

Zaleski-Larsen, L. A., Ruth, N. H. et Fabi, S. G. (2017). Retrospective Evaluation of Topical Bimatoprost and Iris Pigmentation Change. *Dermatologic Surgery*.

### 1.2.2 Prise en charge de l'infestation palpébrale

Comme la blépharite antérieure à *D. folliculorum* est causée par une trop grande quantité de *Demodex*, le traitement n'est pas d'éradiquer complètement le parasite, mais plutôt de réduire sa quantité afin de rééquilibrer la flore (Nicholls et al., 2017). De cette façon, le parasite peut reprendre son rôle de commensal. Cliniquement, l'efficacité d'une thérapie peut être évaluée par deux facteurs : l'observation à la lampe à fente d'une réduction du nombre de CDs à la base des cils et l'amélioration des symptômes oculaires rapportés par les individus atteints. À ce jour, plusieurs traitements sont prescrits contre l'infestation palpébrale à *D. folliculorum*. En première ligne se retrouvent les thérapies utilisées pour tout type de blépharite antérieure, soit les compresses chaudes pour ramollir les débris dans les cils et le frottement des cils pour y déloger les débris (Lindsley et al., 2012). Le clinicien peut manuellement déloger les débris à la base des cils en utilisant une petite tige métallique avec un embout courbé qui agit comme un grattoir, tel qu'un « golf spud » (Korb et al., 2013). Ensuite, des thérapies qui ciblent directement le *Demodex* peuvent être utilisées avec le traitement de première ligne. Il a été démontré que le terpinen-4-ol, un ingrédient présent dans l'huile essentielle de *Melaleuca* [provenant d'arbre à théier], réduit substantiellement la quantité de *Demodex* lorsqu'il est appliqué localement sur les paupières pour plusieurs semaines (Tighe et al., 2013). De même, une diminution de l'inflammation palpébrale et le soulagement des symptômes oculaires ont été notés (Gao et al., 2007). Suite à cette étude, des formulations à base de terpinen-4-ol ou d'huile essentielle de *Melaleuca* ont vu le jour, sous forme de mousse ou de lingettes préimbibées (Gao et al., 2007; Ngo et al., 2017).

D'autres thérapies plus récentes permettent aussi de s'attaquer au *Demodex*, telles que le 1, 2-Octanediol, un ingrédient nouvellement intégré dans des lingettes préimbibées, et la microblépharoexfoliation, qui se fait avec un instrument pour débrider et exfolier le bord palpébral (Murphy et al., 2018a). L'ivermectine orale, un antiparasitaire à large spectre, a aussi

démontré son efficacité chez une série d'individus atteints de blépharite réfractaire associée à une infestation à *Demodex* (Holzchuh et al., 2011). Deux doses [200 ug/kg] prises à 7 jours d'intervalle ont réduit la quantité de *Demodex* dans les prélèvements des cils, et ont amélioré la stabilité et la quantité de larmes. Cet usage n'était pas conforme à l'indication reconnue [off label]. L'ivermectine est habituellement prescrite pour la strongyloïdose et l'onchocercose (Holzchuh et al., 2011). Il est de plus en plus utilisé contre des infestations aux arthropodes telles que les poux et les acariens (Chosidow et al., 2018).

Finalement, comme l'infestation au *D. folliculorum* peut être concomitante à une blépharite postérieure, qui peut à son tour créer une sécheresse oculaire, une prise en charge de la déficience des glandes de Meibomius est de mise (Geerling et al., 2011).

### **1.3 L'infestation faciale au *Demodex folliculorum***

Comme la microflore palpébrale, la microflore cutanée est composée de plusieurs micro-organismes qui cohabitent. De même, certains micro-organismes cutanés, dont le *D. folliculorum*, déséquilibreraient la microflore sous-jacente lorsqu'ils sont présents en trop grande quantité (Two et al., 2015). Plusieurs manifestations cliniques faciales sont présentes en réaction à une infestation cutanée, telles qu'un picotement sur la peau, un érythème localisé, des squames blanchâtres, des lésions circonscrites et surélevées, avec et sans exsudats liquidiens [papulo-pustules] et des élevures exsudatives et inflammatoires associées aux follicules pileux [pustules folliculaires] (Chen et al., 2014; Forton et al., 2005; Hsu et al., 2009; Karıncaoglu et al., 2004). Plusieurs pathologies dermatologiques sont donc associées à ces manifestations cliniques, et du même coup, à une infestation au *D. folliculorum*. La pathologie la plus fréquemment diagnostiquée est la rosacée, une maladie chronique inflammatoire de la peau. Les mécanismes d'action qui expliquent l'apparition des manifestations cliniques de la rosacée sont encore débattus ainsi que le rôle du *D. folliculorum* dans cette pathologie (Forton, 2012; Moran et al., 2017; Two et al., 2015). Plusieurs facteurs, dont les rayons ultraviolets, les épices, la chaleur, le stress, l'exercice, ainsi que certains micro-organismes [*Staphylococcus epidermidis*, *D. folliculorum*] peuvent déclencher une cascade inflammatoire, provoquant ainsi une réaction

de la peau de type IV [hypersensibilité], qui se manifeste sous forme de papules et de pustules (Yamasaki et al., 2007). Le *D. folliculorum*, de même que d'autres bactéries, déclencherait la cascade inflammatoire par une dépression du système immunitaire (Forton, 2012; Moran et al., 2017). Le *D. folliculorum* promouvrait activement l'immunosuppression, en produisant des substances qui augmenteraient la déficience en cellules T chez des individus déjà prédisposés (Akilov et al., 2004). Cela lui permettait de proliférer, tout en supprimant la réponse immunitaire de l'hôte, ce qui éviterait son expulsion. On parle alors d'une immunosuppression primaire (Moran et al., 2017). D'un autre côté, lorsque d'autres facteurs ou d'autres maladies affectent le système immunitaire de l'hôte, le *D. folliculorum* serait opportuniste et en profiterait pour accroître sa population. Du même coup, l'immunosuppression locale serait accompagnée d'une immunosuppression primaire, ce qui augmenterait significativement la densité faciale de *D. folliculorum* (Moran et al., 2017).

Le débalancement de la microflore par le *Demodex* contribuerait à la pathogenèse de la rosacée de plusieurs façons. Le surplus de parasites bloquerait les follicules pileux et les glandes sébacées, causant ainsi un bris dans la barrière cutanée (Moran et al., 2017). Par conséquent, il y a une augmentation de l'expression des « toll-like » récepteurs [TLR] sur les macrophages et les cellules dendritiques, ce qui active la réponse immunitaire. L'exosquelette des parasites, de même que la dégradation des parasites lorsqu'ils meurent, libérant ainsi plusieurs bactéries, enzymes et fèces, pourraient aussi déclencher une réponse immunitaire (Forton, 2012; Yamasaki et al., 2007). À partir d'une certaine densité faciale, l'effet immunosuppressif changerait pour un effet pro-inflammatoire (Moran et al., 2017). D'un autre côté, il a été démontré que le *D. folliculorum* contient une flore qui lui est propre, hébergeant des bactéries pathogéniques, dont le *Bacillus oleronius* (Lacey et al., 2007). Ce dernier contient des antigènes qui ont le potentiel de stimuler une réaction inflammatoire locale, créant ainsi des papulo-pustules. Un ou plusieurs de ces mécanismes pourraient expliquer les manifestations cliniques observées en présence de rosacées.

Il n'existe pas de consensus quant à la manière de définir la rosacée. Deux façons différentes ont été proposées afin de standardiser les appellations. Two et al., 2015 a divisé la rosacée en quatre sous-catégories [I : érythémato-télangiectasique, II : papulo-pustuleuse, III : phymateuse,

IV : oculaire]. Chacune d'entre elles a des caractéristiques qui doivent être visibles sur la peau [primaires] et d'autres qui peuvent ou non l'être [secondaires]. Les sous-catégories peuvent aussi être concomitantes (Asai et al., 2016; Schaller et al., 2016). Celles qui ont été associées au *D. folliculorum* sont les sous-catégories I, II et IV (el-Shazly et al., 2001; Forton et al., 2017; Karıncaoglu et al., 2004). D'un autre côté, le ROSacea COnsensus [ROSCO] panel, composé de dix-sept dermatologues et trois ophtalmologues, a plutôt défini la rosacée par des présentations cliniques, et a rattaché à chacune les thérapies disponibles sur le marché (Schaller et al., 2016). Cette démarche permet de catégoriser la rosacée par des phénotypes plutôt que par des sous-catégories préétablies qui regroupent plusieurs phénotypes. Les phénotypes qui permettent de décrire la rosacée sont donc l'érythème transitoire, l'érythème persistant, des papules/pustules [légères, modérées, sévères], des télangiectasies, un nodule [phyma] cliniquement inflammé et la fibrose d'un nodule. Les phénotypes les plus fréquemment associés au *D. folliculorum* sont les suivants : érythème persistant, papules/pustules et télangiectasie (el-Shazly et al., 2001; Forton et al., 2017; Karıncaoglu et al., 2004).

D'autres pathologies sont aussi associées au *D. folliculorum*, telles que le *pityriasis folliculorum* et la folliculite (Forton, 2012; Karıncaoglu et al., 2004). Le *pityriasis folliculorum* est caractérisé par de petites squames folliculaires, discrètes et dispersées de façon régulière (Ayres et al., 1961). Malgré que cette condition soit la plus fréquente des infestations à *Demodex*, elle est très peu connue et ainsi, sous-diagnostiquée (Forton et al., 2005). Chez les individus atteints, on retrouve une plus grande densité de *D. folliculorum* par cm<sup>2</sup> que chez ceux ayant la rosacée papulo-pustuleuse (Forton et al., 2005). Pourtant, les individus diagnostiqués avec le *pityriasis folliculorum* ont peu ou pas d'inflammation de la peau (Ayres et al., 1961). Forton et al., 2012 a suggéré que le *pityriasis folliculorum* pourrait être la condition qui précède l'apparition de la rosacée, soit une phase latente de cette dernière. Selon la même théorie, lorsque la quantité de *Demodex* atteindrait un certain niveau, il y aurait alors une réaction pro-inflammatoire, engendrant ainsi les papulo-pustules. Celles-ci réduiraient la densité de *Demodex*, mais ne permettraient pas d'éliminer complètement l'infestation. Cela expliquerait qu'une quantité significative du parasite est tout de même retrouvée dans la peau des individus atteints de rosacée, mais moindre que chez ceux ayant le *pityriasis folliculorum*.

Finalement, l'infestation à *D. folliculorum* peut se manifester par des lésions faciales atypiques (Karincaoglu et al., 2004). Les chercheurs de cette étude suggèrent que des lésions non classiques et ne répondant pas aux thérapies conventionnelles devraient faire l'objet de prélèvement facial pour y chercher un excès de *D. folliculorum*.

### 1.3.1 Prise en charge de l'infestation faciale

En recherche, plusieurs techniques permettent d'évaluer la densité faciale de *D. folliculorum*. La biopsie superficielle faciale est celle qui est la plus fréquemment utilisée (Forton et al., 2005; Lacey et al., 2016), prélevant ainsi le contenu des follicules pileux. Les individus ayant des manifestations cutanées associées au *D. folliculorum* vont rencontrer un dermatologue afin d'améliorer l'apparence de leur peau. Dans un contexte clinique, la densité faciale de *D. folliculorum* ne sera pas évaluée. Le dermatologue va plutôt diagnostiquer et traiter la pathologie sous-jacente au *D. folliculorum*. L'efficacité de la thérapie sélectionnée sera donc jugée non pas par la réduction de la densité de *Demodex*, mais plutôt par la diminution des manifestations cutanées telles que l'érythème facial, les squames blanchâtres, les papulo-pustules ou les pustules folliculaires. Malgré que ces manifestations cutanées puissent être accompagnées d'un picotement de la peau, c'est surtout pour l'esthétisme de la peau que les individus atteints vont consulter.

Dans la littérature, plusieurs agents pharmaceutiques et traitements contre une infestation faciale à *D. folliculorum* ont fait l'objet de rapport de cas (Gilaberte et al., 2009; Lacey et al., 2016; Schaller et al., 2016). Par exemple, Gilaberte et al., 2009 ont démontré une réduction de la densité faciale avec la thérapie photodynamique chez un patient avec une folliculite sévère secondaire au *Demodex*. Karincaoglu et al., 2004 ont quant à eux démontré une diminution de la densité faciale sur des lésions non spécifiques de toute sorte, à l'aide d'un insecticide, la perméthrine topique 5 %. Il y a par contre beaucoup plus d'études qui portent sur les traitements du *Demodex* en lien avec la prise en charge de la rosacée. L'ivermectine topique 1% fait partie de l'algorithme de traitement lorsque des papules/pustules légères, modérées ou sévères sont détectées (Schaller et al., 2016). Des études cliniques ont ainsi

démontré qu'il réduit la quantité de papules/pustules et l'inflammation associée à la rosacée (Stein et al., 2014; Taieb et al., 2015). Pour ce faire, il s'attaque spécifiquement au *D. folliculorum* et en réduit la quantité (Moran et al., 2017; Sahni et al., 2018). Aussi, une seule session de traitement à la lumière pulsée a permis de diminuer significativement la densité faciale de *Demodex* chez des individus atteints de rosacée (Ertas et al., 2018). En infligeant des dommages à l'exosquelette des parasites (Prieto et al., 2002), la lumière pulsée est donc une autre avenue de traitement. D'un autre côté, les médicaments tels que le métronidazole topique, la brimonidine gel et la doxycycline orale sont efficaces pour traiter les autres phénotypes de la rosacée (Schaller et al., 2016). Par contre, l'effet de chacun de ces traitements sur le *Demodex* n'a pas encore fait l'objet de publications scientifiques.

## **1.4 Le lien entre l'infestation palpébrale et faciale**

Le *D. folliculorum* a longtemps été considéré comme un ectoparasite inoffensif, et ainsi, peu d'importance lui était accordée. Ces dernières années, plusieurs publications scientifiques ont démontré que le *D. folliculorum* est impliqué dans la pathophysiologie de la rosacée et de la blépharite antérieure (Forton et al., 2017; Kabatas et al., 2017; Moran et al., 2017; Murphy et al., 2018a; Sahni et al., 2018; Two et al., 2015), accroissant ainsi l'intérêt des chercheurs pour ledit parasite. Par contre, peu d'articles se sont penchés sur l'infestation à la fois des paupières et du visage (Gonzalez-Hinojosa et al., 2018; Liang et al., 2016). Cela peut s'expliquer entre autres par la ségrégation des disciplines de l'optométrie/ophtalmologie et de la dermatologie. Comme il n'y a pas de corridor de collaboration entre les deux disciplines du côté clinique, cela se reflète dans la recherche scientifique. De plus, la formation des optométristes/ophtalmologistes met peu d'emphase sur les affectations cutanées telles que la rosacée. Ainsi, les professionnels de la vue ne questionnent pas systématiquement leurs patients sur leurs antécédents dermatologiques, et ne regardent pas attentivement le visage de leurs patients à la recherche d'anomalies. Le même phénomène est observé chez les dermatologistes, qui n'ont pas la formation et l'équipement, tel qu'une lampe à fente, pour bien comprendre les pathologies des paupières. L'infestation palpébrale et faciale

à *D. folliculorum* demeure donc une problématique peu explorée jusqu'à présent dans les recherches scientifiques.

## 2. Méthodologie

### 2.1 Objectifs

L'objectif principal de mon projet de recherche était d'évaluer s'il existe un lien entre la sévérité d'une blépharite antérieure à *D. folliculorum* et une infestation faciale. Les objectifs secondaires étaient d'évaluer plusieurs paramètres dermatologiques et oculaires en fonction de la sévérité de la blépharite antérieure à *D. folliculorum*. Pour ce faire, une étude transversale à double insu a été effectuée, incluant cinquante-huit participants divisés en trois groupes de sévérité de la blépharite [contrôle, légère/modérée, sévère].

### 2.2 Raisonnement

Comme démontré précédemment dans l'introduction, le follicule du cil contient une microflore qui lui permet de bien réguler son fonctionnement. Un déséquilibre de la flore provoque aussi de l'inflammation des paupières, qui peut causer à son tour des pathologies ciliaires. Chez l'humain, le parasite *D. folliculorum* s'intègre à la microflore des paupières et de la peau du visage au cours de la vie (Lacey et al., 2011). Lorsqu'une trop grande quantité le rend pathogène, un traitement doit être entrepris par des thérapies topiques ciblées aux structures atteintes, ce qui se fait par les professionnels de la vue pour les paupières et par les dermatologues pour la peau du visage. Actuellement, l'infestation palpébrale et faciale est prise en charge séparément. Cependant, on pourrait penser que les deux infestations pourraient être présentes en même temps. Afin de répondre à ce questionnement, ce projet de recherche s'est donc orienté sur le lien possible entre une infestation palpébrale et faciale au *D. folliculorum*. De plus, plusieurs signes et symptômes oculaires mesurés lors d'une évaluation de la sécheresse oculaire d'un patient sont associés à la présence d'une blépharite antérieure à *Demodex*. Pour ce projet de recherche, nous avons retenu les paramètres oculaires qui semblaient les plus affectés chez nos patients atteints de sécheresse oculaire, certains ayant déjà été démontrés dans la



littérature (Jalbert et al., 2015; Kabatas et al., 2017; Lee et al., 2010; Murphy et al., 2018b) et d'autres non. Plusieurs paramètres dermatologiques sont aussi affectés par le *D. folliculorum*, ce qui a été démontré par quelques études (Karincaoglu et al., 2004; Moran et al., 2017; Two et al., 2015). Comme un dermatologue a décidé de collaborer à cette recherche, nous avons aussi ajouté des paramètres dermatologiques au projet, qui pouvaient être jaugés à l'aide de photographies du visage.

## 2.3 Hypothèses

La sévérité de la blépharite à *D. folliculorum* devrait influencer toutes les variables principales et secondaires de ce projet.

### Variable principale

Une **augmentation** du degré de sévérité de la blépharite serait associée à une **augmentation** de la densité faciale de *Demodex*.

### Variabes secondaires

Une **augmentation** du degré de sévérité de la blépharite serait associée à une **augmentation**

- du degré de sévérité de l'érythème facial;
- de la quantité de *D. folliculorum* dans les follicules ciliaires, mesurée dans les prélèvements des cils;
- de la sévérité des symptômes de sécheresse oculaire, donc une valeur plus élevée au questionnaire « Ocular Surface Disease Index » ;
- de la sévérité des symptômes de larmoiement, de picotement des yeux et de picotement au bord de la paupière.

De plus, une **augmentation** du degré de sévérité de la blépharite serait associée à une **diminution**

- de la stabilité des larmes, mesurée par le temps de bris des larmes;
- de la quantité de larmes, mesurée par la hauteur du ménisque lacrymal.

### 3. Résultats

Les résultats de ce mémoire sont présentés sous la forme d'un article qui est en préparation et qui sera soumis au journal « Contact Lens and Anterior Eye ». Cet article a été réalisé suite à une étude transversale à double insu portant sur l'infestation palpébrale et faciale au *D. folliculorum*. Une optométriste a exécuté l'expérimentation complète avec les participants, récoltant ainsi tous les prélèvements des cils et du visage, et quantifiant toutes les variables oculaires. Une seconde optométriste a dénombré le *D. folliculorum* dans tous les prélèvements des cils et du visage, et ce, sans indication de la provenance des prélèvements. Finalement, une dermatologue a analysé toutes les photographies faciales des participants sans savoir de quel groupe provenaient les participants. Elle devait déterminer la sévérité de l'érythème facial et déceler les pathologies dermatologiques pouvant avoir une influence sur la densité faciale de *D. folliculorum*. L'article « Palpebral and facial skin infestation by *Demodex folliculorum* » est présenté à la sous-section 3.2. La contribution de la dermatologue se limite à l'analyse des photographies du visage. Elle n'a pas participé à la rédaction de l'article qui sera soumis pour publication, ce qui explique qu'elle ne fasse pas partie des coauteurs.

### 3.1 Article 2: Palpebral and facial skin infestation by *Demodex folliculorum*

[article en préparation]

Sarah Aumond<sup>1</sup>, Etty Bitton<sup>1</sup>

<sup>1</sup>École d'optométrie, Université de Montréal, CP 6128 succursale centre-ville, Montréal, Qc, Canada

#### Abstract

**Purpose:** To evaluate facial *Demodex* densities in participants with varying severities of blepharitis secondary to *Demodex folliculorum* determined by the highest number of cylindrical dandruffs per lid.

**Methods:** This double masked cross-sectional study included 58 participants [19 control, 21 mild/moderate and 18 severe *Demodex* blepharitis] who underwent a standardized skin-surface biopsy and a lash epilation for each lid to obtain the forehead *Demodex* densities and the overall lash mite count, respectively. Also, facial photographs were taken to evaluate facial erythema and dermatological conditions. The Ocular Surface Disease Index [OSDI], non-invasive break-up time [NIBUT], tear meniscus height [TMH], bulbar conjunctival redness as well as additional questions on watery eyes, ocular itching and itching along the lids were assessed.

**Results:** Both mild/moderate and severe *Demodex* blepharitis groups were over the cut-off value [ $\geq 5$  mites/cm<sup>2</sup>] that confirms a facial demodicosis (mild/moderate:  $4.8 \pm 0.6$ ; severe:  $5.5 \pm 0.7$ ) while the control group was below it ( $2.4 \pm 0.6$ ). Group comparisons showed that an increased severity of *Demodex* blepharitis was associated with higher forehead mite densities ( $p = 0.002$ ) and increased lash mite count ( $p < 0.001$ ). The degree of facial erythema was also positively correlated with forehead mite densities ( $r_s = 0.31$ ,  $p = 0.02$ ). When compared to the controls, the mild/moderate group had more watery eyes ( $X^2 = 6.54$ ,  $p = 0.02$ ), a lower TMH ( $U = 100.5$ ,  $p = 0.006$ ) and the severe group had more itching along the lids ( $X^2 = 4.94$ ,  $p = 0.04$ ). The other ocular signs and symptoms [NIBUT, bulbar conjunctival redness, OSDI] were not affected by the severity of *Demodex* blepharitis ( $p > 0.05$ ).

**Conclusion:** Palpebral and facial *Demodex* infestation can co-exist, as the presence of blepharitis secondary to *Demodex* is associated with increased facial mite densities.

## Keywords

*Demodex folliculorum*, blepharitis, lash epilation, demodicosis, skin-surface biopsy

## Introduction

*Demodex* ectoparasites [*D. folliculorum* and *D. Brevis*] are part of the human's microflora, as residents of the pilosebaceous units of the facial skin, lash follicles and meibomian glands of the lids (Nicholls et al., 2017). *D. folliculorum* is usually found in the superficial structures of the follicles and glands, while *D. Brevis* is anchored deeper in the glands. The mites' anatomy, physiology and life cycle are well documented (Nicholls et al., 2017). Nevertheless, their precise role in normal skin conditions is still uncertain. It is hypothesized that they could have a symbiotic relationship with humans as commensals, feeding from the human sebum without harming their host (Lacey et al., 2011). However, when their population exceeds a critical point, they become pathogenic, commonly referred to as demodicosis (Lacey et al., 2011), which can affect the facial skin and eyelids. It remains to be determined if a mite infestation can affect nearby tissues, generating a widespread demodicosis.

Facial demodicosis has been associated to both obvious skin conditions, like papulopustular and granulomatous rosacea, as well as to underdiagnosed and less noticeable affectations, such as pityriasis *folliculorum* and folliculitis (el-Shazly et al., 2001; Forton et al., 2017; Karıncaoglu et al., 2004). Facial manifestations of demodicosis are various and non-specific: itching of the skin, erythema, whitish scale, some papulopustules and follicular pustules (Chen et al., 2014; Forton et al., 2005; Hsu et al., 2009; Karıncaoglu et al., 2004). To quantify *Demodex* densities in the skin, various techniques have been reported, such as direct microscopic examination and standardized skin-surface biopsy [SSSB] (Askin et al., 2010). The direct microscopic examination allows better visualization of deeper skin layers and higher detection rate of *D. Brevis* than SSSB, which collects only the outermost layer of the epidermis and the hair follicle's content (Yun et al., 2017). Nevertheless, SSSB remains the most widespread technique, being minimally invasive, well tolerated and conducive in a clinical setting (Forton et al., 2005; Lacey et al., 2016). With SSSB, the presence of five mites or more per cm<sup>2</sup> [ $\geq 5/\text{cm}^2$ ] confirms an infestation by *Demodex* mites (Forton et al., 1993).

Eyelid demodicosis may take a variety of forms and severity, depending on whether *D. Brevis* or *D. folliculorum* is the main causative agent. The overpopulation of *D. Brevis* is generally found in the meibomian glands of people suffering from meibomian gland dysfunction [MGD] and chalazion (Gao et al., 2007; Tarkowski et al., 2015). In contrast, *D. folliculorum* is present in 90% of anterior blepharitis (Bhandari et al., 2014) and 60 to 88% of MGD (Bhandari et al., 2014; Chen et al., 2017; Lopez-Ponce et al., 2017). Although people affected by demodicosis may be asymptomatic, most will experience non-specific symptoms, such as itchiness, redness of the lids, watery eyes and dry eye sensation (Bhandari et al., 2014; Sedzikowska et al., 2016). In a clinical setting, practitioners can see pathognomonic signs of lash demodicosis, which are gelatinous debris at the base of the lashes, known as cylindrical dandruff [CD] (Gao et al., 2005). They can also observe the mites by using tweezers to rotate an eyelash that possesses CD to disturb the mite so that its tail emerges from the follicle opening (Mastrota, 2013). Although this technique is non-invasive and can be easily performed in a clinical setting, it remains qualitative and not well suited for research purposes whereby mite counts are needed. Unlike the assessment of facial demodicosis, there is no standardized mite count technique for the lids. Despite the lack of standardization, two techniques are commonly used, notably lash epilation and *in vivo* confocal microscopy [IVCM]. Lash epilation consists of visually selecting a lash with CD and, using forceps, holding it and pulling the lash out of its follicle in a brisk movement. Subsequently, the epilated lash is placed on a microscope slide, so that the follicle's content and the lash itself can be observed. Selecting an eyelash with CD will significantly increase the mite count (Gao et al., 2005). Unfortunately, epilation techniques among studies are highly variable (Bhandari et al., 2014; Gao et al., 2005; Jalbert et al., 2015; Lopez-Ponce et al., 2017; Murphy et al., 2018a, 2018b), which makes the mite count' comparison between studies challenging. IVCM allows the visualization of the complete content of the lash follicles and meibomian glands, which increases the detection rate of *Demodex* larvae and *D. Brevis* (Randon et al., 2015). Randon et al. (2015) demonstrated that lash epilation and IVCM had similar mite detection rates, while Jalbert and Rejab (2015) found a higher prevalence of mites with IVCM. Since the observation of *Demodex* mites by IVCM is more recent and less accessible than lash epilation, the most widespread technique is still lash epilation (Wolffsohn et al., 2017). Other

than the skin, demodicosis can also impact other structures. Not only are *Demodex* infestations associated with lid pathologies but, in addition, are comorbidities of dry eye disease [DED]; can exacerbate a pre-existing DED; and are more prevalent in cases of pterygium (Bron et al., 2017; Tarkowski et al., 2017).

Various treatments have an anti-parasitic effect on *Demodex* mites and can improve the underlying skin or lid affectations (Gilaberte et al., 2009; Lacey et al., 2016; Murphy et al., 2018a; Schaller et al., 2017; Tighe et al., 2013). A reduction in the facial mite count has been demonstrated with photodynamic therapy (Gilaberte et al., 2009) and, for the lids, with micro-blepharoexfoliation (Murphy et al., 2018a). Effective pharmaceuticals include ivermectin 1%, an anti-parasitic cream also approved for the treatment of rosacea (Schaller et al., 2017), and tea tree oil [especially the active ingredient *terpinen-4-ol*] (Tighe et al., 2013), which has been introduced into several lid wipes and foam eyelid cleansing formulations.

Despite the large number of studies on *Demodex* mites in the lids and facial skin, few studies have examined the relationship between the two issues (Gonzalez-Hinojosa et al., 2018; Liang et al., 2016). Using the IVCN technique, Liang et al. (2016) found a strong positive correlation between *Demodex* mites in the meibomian glands/lash follicles and the cheeks of patients with confirmed rosacea. On the other hand, Gonzalez-Hinojosa et al. (2018) found that the presence of *Demodex* in epilated lashes was more frequent in patients diagnosed with cutaneous rosacea than those without rosacea. The concomitance of facial and palpebral *Demodex* infestation is increasingly likely in patients with rosacea but has yet to be demonstrated in patients with regular skin conditions. Therefore, the objective of this study was to evaluate facial mite densities in participants with varying severities of blepharitis secondary to *Demodex folliculorum*.

## **Methods**

### Participants

This research project was conducted in agreement with the tenets of the Declaration of Helsinki and was approved by the ethic committee of the *Université de Montréal* [*Comité d'Éthique de la Recherche En Santé*]. Informed consent was obtained from all the participants, who were over 18 years of age and enrolled from November 2017 to April 2018. Inclusion criteria involved discontinuation of any products for lid hygiene management [lid wipe/mousse/shampoo] 24 hours prior to the study visit. In addition, discontinuation of any products used in or around the eyes [artificial tears, topical ointment or gel, make-up such as eyeliner/mascara, facial cleansers/moisturizer/foundation/soap] for the day of the study visit. Participants were excluded if they had any factors [Table 1] that have an evidence-based impact on facial and palpebral *Demodex* counts or that might play a role in the reduction/increase of the mite count. Furthermore, factors that have an impact on the tear film quality, stability, and quantity and that were not tested/monitored in the experimentation were also part of the exclusion criteria. A complete list is available in Table 1.

Table 1. Exclusion criteria

<b>Criteria</b>	<b>Detailed description</b>
Evidence-based impact on mite count (Forton et al., 2005; Gerber et al., 2011; Kulac et al., 2008; Lacey et al., 2016; Roth, 1979; Yamashita et al., 2011)	Any lid hygiene products containing tea tree oil or <i>terpinen-4-ol</i> [last six weeks]
	Diagnosis of cutaneous rosacea by a dermatologist; diagnosis of proliferative diabetic retinopathy; patients receiving phototherapy or inhibitors of the epidermal growth factor receptor [EGFR]
	Any facial skin medications or preparations containing topical tretinoin, gamma benzene hexachloride lotion, 1% permethrin cream rinse, 10% povidone–iodine, 75% and 100% alcohol, 50% baby shampoo, 4% pilocarpine, 100% tea tree oil, 100% caraway oil and 100% dill weed oil, crotamiton 10% cream or ivermectin [within the past month]
Possible effect on mite count	Any of these oral antibiotics: doxycycline, tetracycline, minocycline [within the past month]
	Eyelash extensions [in the past six months]

Anything that has an impact on the tear film [not monitored in the study] (Novack et al., 2017)	Any surgery in/on the eye [in the past twelve months]
	Any of these prescribed eyedrops: for glaucoma, anti-inflammatory/steroids, topical cyclosporine or lifitegrast [in the past six months]
	Any active ocular infection or significant eyelid anomalies
	Currently a smoker

Masking

A single investigator [SA] was responsible for the recruitment and data collection. The eyelash samples and skin swabs were coded and evaluated by a separate investigator [EB]. A dermatologist received the coded pictures of the participants. Both the evaluator of the slides and the dermatologist were masked from the participants and from each other.

Procedures

Where applicable, all procedures were performed on both eyes.

**Assessment of Specific Health/Ocular History, Daily Skin Care and Ocular Symptoms.**

The investigator asked the participants whether or not they had a chronic inflammatory disease, diabetes, thyroid disorders, and whether they were contact lens wearers. Participants were questioned about their daily skin routine: how many times they cleaned their face and if they used soap or a facial moisturizer. Then, the Ocular Surface Disease Index [OSDI] (Schiffman et al., 2000) was administered to assess the severity of dry eye symptoms and their score between 0 and 100 was recorded, with higher scores representative of higher degrees of dry eye symptom severity. In addition, participants were asked to identify if they felt the following symptoms in the past week (ocular itching, itching along the lids and watery eyes), as reported in other studies (Kabatas et al., 2017; Murphy et al., 2018b; Sedzikowska et al., 2016). The severity scale that has been selected is the one used in the OSDI questionnaire (Schiffman et al., 2000).



**Standardized Skin-Surface Biopsy [SSSB].** SSSB is achieved with cyanoacrylate adhesives on a microscope slide that is pressed to the designated facial site, with both slide and skin precleaned with ether or alcohol (Aydingoz et al., 2000; Aytekin et al., 2016; Forton et al., 1993; Forton et al., 2017; Gerber et al., 2011; Kulac et al., 2008; Lacey et al., 2016). We selected the cyanoacrylate adhesive Loctite Super Glue LOC1364076, which had been previously tested among four other Loctite glues available in Canada and gave the best quality of sampling and the least localized skin irritation. Additionally, recent studies have shown that a second sampling on the same site, called a consecutive SSSB, collected the mites that were anchored deeper into the hair follicles (Forton et al., 2017) and that a specific location on the forehead [2 cm up from the bridge of the nose and then 2 cm to the right or left] allowed the SSSB technique to be further standardized (Lacey et al., 2016). Thereby, we adopted the consecutive SSSB and the standardized forehead site for this study.

In our study, the following order of procedures was performed for each sampling. The glue was dispersed on the microscope slide for five seconds, and then the slide was pressed on the right forehead location. After one minute forty seconds, the adhesion of the slide to the forehead was tested. If the glue was dried, the slide was removed from the skin. If the glue was still unsettled, the slide was held on the skin for an extra 10 to 20 seconds. The procedure was repeated on the same site to obtain the consecutive SSSB. The procedure was repeated for the left forehead location.

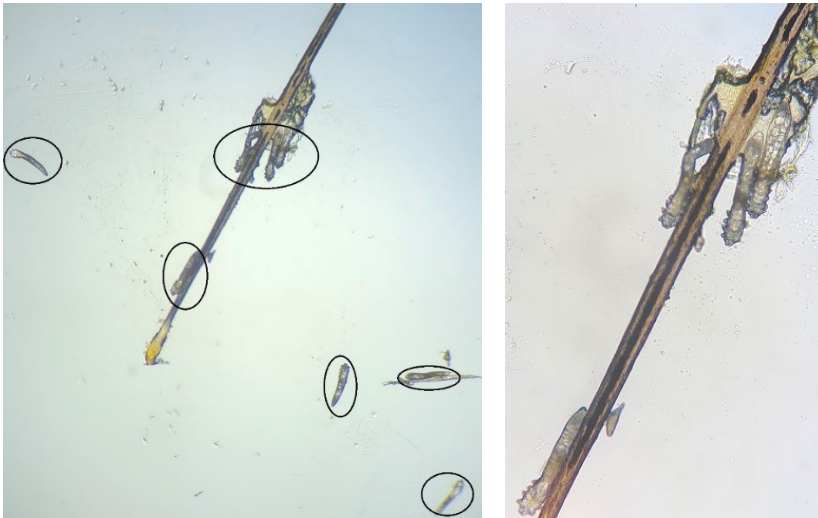
**Tear Meniscus Height [TMH] and Bulbar Conjunctival Redness.** Tear volume and bulbar conjunctival redness were evaluated using the Keratograph 5M [Oculus, Arlington, WA, USA], using respectively the inherent TMH and R-Scan options. The TMH was taken centrally of the inferior lid and recorded in millimeters. If a minor deformation [ $< 0.5$  mm] of the lid margin was present, the investigator shifted the measurement of the TMH slightly towards the temporal side. The R-Scan recorded the bulbar and limbal redness using a range from 0 [no redness] to 4 [severe redness] for both the nasal and temporal sides.

**Non-Invasive Break-Up Time [NIBUT].** NIBUT was calculated in seconds using the Medmont E300 Corneal Topographer [Nunawading, Victoria, Australia] and a timer from a computer. Participants were instructed to blink normally and then keep their eyes open for as long as they could. This was repeated three times per eye and averaged.


**Assessment of the Lashes.** A digital camera [Nikon D100] coupled to a biomicroscope [Topcon SL-D7] was used to take several photographs of the outer, inner and central portion of each lid, with a digital capturing system [ImageNet, Topcon]. These photographs were assessed for the CD count of both the inferior and superior lid. As described by Schachter (2014), the lid with the highest CD count was used to establish the severity of *Demodex* blepharitis [control: free of CDs, mild: 1 to 4 CDs, moderate: 5 to 9 CDs, severe:  $\geq 10$  CDs]. To facilitate the recruitment of participants, the mild and moderate severities were combined in one category [mild/moderate: 1 to 9 CDs]. The presence of trichiasis and poliosis on each lid was also recorded. Subsequently, one lash with CD per lid (for a total of 4 lashes) was epilated using tweezers [Stephens S5-1895, Lexington, KY]. The lash was held while rotating it clockwise three times, pulled gently and placed on a pre-coded microscope slide and gently covered with a cover slip. A drop of fluorescein was dispersed between the slide and the cover slip, to increase the visibility of the mites (Kheirkhah et al., 2007). For the control group [without CD], the same technique was used, but the epilated lash was randomly selected in the central portion of each lid.

**Microscopic Examination of the *Demodex* Mites.** The epilated lashes were examined using a microscope [OMAX 40X-2000X Binocular Compound LED Microscope] under 40-400X magnification to observe the presence of adult *D. folliculorum* [Figure 1]. The examiner simply counted the visible mites and recorded the result onto an excel spreadsheet under the coded number of the slide. The examiner was masked as to the participant, the lid or the eye that the lash came from. The slides with SSSB were examined using the same instrumentation. Due to the three-dimensional nature of the sample, focusing up and down was needed to identify the tip of facial hair and progress down to the base of the shaft. The slide was examined first at 40X to scan the sample and magnification was subsequently increased to examine details of *D.*

*folliculorum* for confirmation of movement or to see a part of its anatomy [Figure 2]. All slides were examined within 12 hours after sampling.



**Figure 1.** *Demodex folliculorum* (*D.f*) from the lashes under 40-400x magnification. **Left:** Epilated eyelash with 8 *D.f* at 40X **Right:** Increased magnification (400X) of the eyelash, with 4 *D.f*



**Figure 2.** *Demodex folliculorum* (*D.f*) from the forehead skin under 40-400x magnification. **Left:** General view (40X) of the hair follicle's contents with 2 visible *D.f* **Right:** Increased magnification (400X) of one visible *D.f*

**Assessment of the Facial Erythema and Facial Skin Conditions.** A smartphone [LG G6] was used by the investigator to take several photographs at various magnifications of the frontal and the right/left profile of the face. These photographs were then coded and sent to the dermatologist. The facial erythema was quantified from 0 to 4, using the validated Clinician Erythema Assessment [CEA] scale illustrated in Table 2 (Tan et al., 2014).

Table 2. Clinician Erythema Assessment [CEA] (Tan et al., 2014)

<b>CEA</b>	<b>Definition</b>
0 = Clear	Clear skin with no signs of erythema
1 = Almost clear	Almost clear; slight redness
2 = Mild	Mild erythema, definite redness
3 = Moderate	Moderate erythema; marked redness
4 = Severe	Severe erythema; fiery redness

Also, the dermatologist defined whether the participants presented certain facial skin conditions reported in the literature that have an effect or not on the facial mite density [Table 3] (Forton et al., 2017).

Table 3. Facial skin conditions reported with an effect or not on facial mite density (Forton et al., 2017)

<b>Reported effect on facial mite density</b>	Rosacea with persistent erythema [typical PPR]
	Granulomatous rosacea
	Telangiectasia
<b>No effect reported on facial mite density</b>	Acne vulgaris
	Seborrheic dermatitis
	Dry skin [+ eczematides]
	Hyperpigmentation
	Folliculitis
	Atopic /contact/ irritation dermatitis
	Chronic lupus erythematosus

### Outcome variables

The primary outcome variables are the forehead *Demodex* densities [mite count/cm<sup>2</sup>] for the first SSSB [SSSB1], and the sum of the first and second SSSB [SSSB1 + SSSB2].

Secondary outcome variables are the facial erythema, facial skin conditions, overall mite count in lashes, symptom severity, tear film stability and quantity, bulbar conjunctival redness and lash anomalies.

### Statistical analyzes

Statistical analysis was performed using SPSS IBM [vers. 25.0] and JASP [vers. 0.8.6.0]. A Repeated Measures one-way analysis of covariance [ANCOVA] between groups was used to analyze the primary outcome variables, with age as a covariate and a Tukey post hoc analysis. The relationship among secondary outcome variables were analyzed with the appropriate non-parametric statistical tests: Spearman's correlation coefficient [rs] for continuous and ordinal variables and Chi-square [ $X^2$ ] for categorical variables. To analyze the effect of each severity group on the secondary outcome variables, parametric and non-parametric tests were used, based on Levene's homogeneity results. For parametric distributions, a one-way analysis of variance [ANOVA] or Repeated Measures ANOVA between groups was performed, and if it was statistically significant, an ANCOVA between groups with age as a covariate was subsequently tested, as well as Tukey's post hoc analysis when required. For non-parametric distributions, a Kruskal Wallis' analysis was performed and if statistically significant, a Mann-Whitney test for between-group comparisons.

## **Results**

Fifty-eight participants were included in this double masked cross-sectional study and divided into three severity groups [Table 4] of *Demodex* blepharitis. All participants completed the

experimental visit and no adverse effects were reported. There was no statistically significant difference in demographics between the three groups ( $p > 0.05$ ) [Table 4].

Table 4. Demographics of each severity group of *Demodex* blepharitis

Demographics		Groups (n=58)						p value	
		Control (free of CDs) n = 19		Mild/moderate (1 to 9 CDs) n = 21		Severe (≥10 CDs) n = 18			
Gender (% female)		52.6		61.9		50.0		0.59	
Ethnicity (% caucasian)		73.7		80.1		88.9		0.54	
Age	Years±SD	38±19		37±16		49±18		0.06	
	Min-Max	19-84		18-75		19-80			
Contact lens wearers <sup>1</sup> (%)		5.3		4.8		5.5		0.97	
Chronic inflammatory diseases <sup>2</sup> (%)		5.3		9.5		0.0		0.34	
Daily face cleaning with water (%) /soap (%)		94.7	68.4	90.5	76.2	100	44.4	0.41	0.11
Daily moisturizer use (%)		52.6		38.1		27.7		0.30	

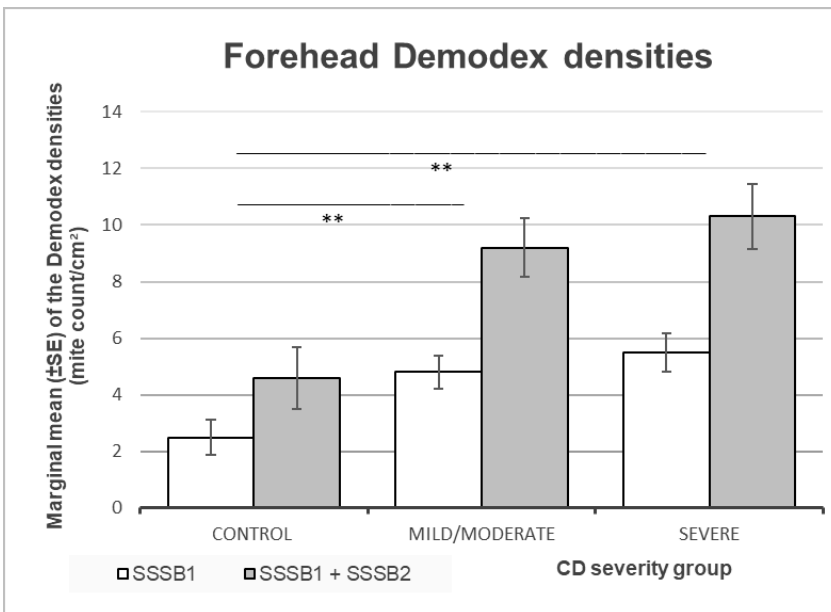
<sup>1</sup> Contact lens wear was defined as: > 4 days/week regardless of the number of hours per day or > 2 days/week with a minimum of 4 hours/day.

<sup>2</sup> Chronic inflammatory diseases were defined as rheumatoid arthritis, Lupus, Crohn, Sjogren, etc.

### Primary Outcome Variables

A Repeated Measures ANCOVA was performed to analyze facial *Demodex* densities [SSSB] between the three groups of severities. Controlling for age, there were significant differences for both SSSB1 [Wilks' Lambda = 0.98,  $F_{1(2,54)} = 6.04$ ,  $p = 0.004$ ,  $\eta^2 = 0.17$ ,  $\omega^2 = 0.14$ ] and SSSB1 + SSSB2 [Wilks' Lambda = 0.97,  $F_{1+2(2,54)} = 7.35$ ,  $p = 0.002$ ,  $\eta^2 = 0.20$ ,  $\omega^2 = 0.17$ ] [Figure 3]. Post hoc tests showed a significant difference for SSSB1 and SSSB1 + SSSB2

respectively, between the control and mild/moderate group [ $t_1 = -2.72, p = 0.02; t_{1+2} = -3.06, p = 0.009$ ]; the control and severe group [ $t_1 = -3.20, p = 0.007; t_{1+2} = -3.49, p = 0.003$ ], but no difference between the mild/moderate and severe group [ $t_1 = -0.70, p = 0.77; t_{1+2} = -0.67, p = 0.78$ ]. For the covariate [age], there was a significant difference between the groups for the SSSB1 + SSSB2 only [ $F_{1+2} (1,54) = 4.51, p = 0.04, \eta^2 = 0.06, \omega^2 = 0.05$ ].

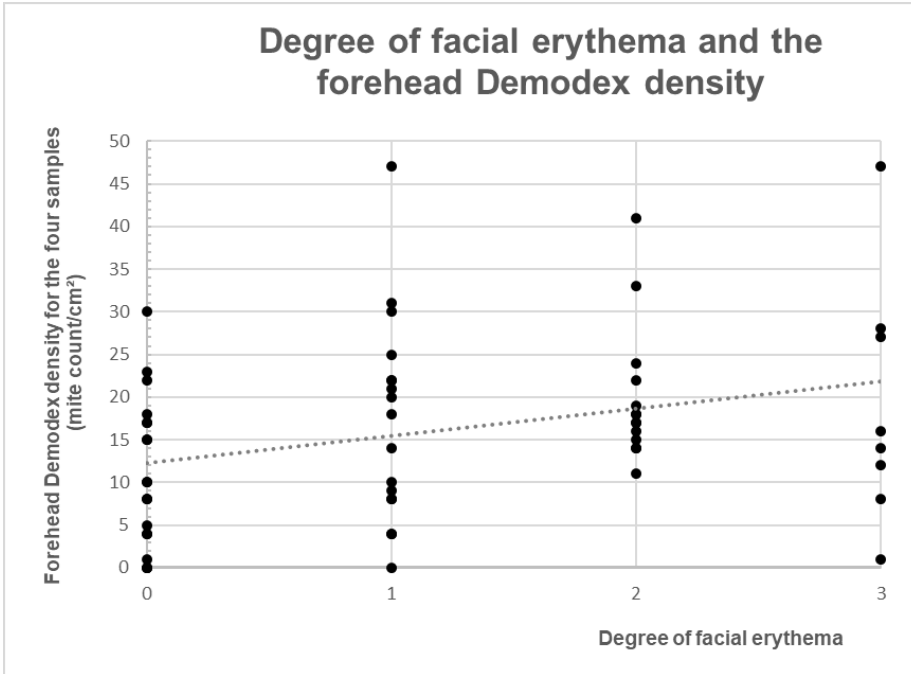


**Figure 3.** Forehead *Demodex* densities [mite count/cm<sup>2</sup>] expressed as marginal mean  $\pm$  standard error [SE]. SSSB = Standardized Skin-Surface Biopsy. CD = cylindrical dandruff. Asterisks illustrate significant differences between groups at  $**p < 0.01$ .

### Secondary Outcome Variables

**Dermatological evaluations.** The age of participants showed no correlation with the facial erythema [ $r_s = 0.21, p = 0.52$ ] and facial skin conditions [ $r_s = 0.01, p = 0.23$ ], hence was not included in further analyzes. A moderate positive correlation was found between the degree of facial erythema [ $r_s = 0.31, p = 0.02$  -Figure 4] and the overall forehead mite density (total of the four samples). Also, higher severities of blepharitis were associated with a higher degree of facial erythema [ $X^2 (6, N = 58) = 13.81, p = 0.03$ ]. No relationship was found between the groups and facial skin conditions diagnosed by the dermatologist [ $X^2 (2, N = 58) = 3.84, p = 0.74$ ]. Also, when the dermatological conditions were divided in two groups [effect/no effect on the

facial mite density-Table 5], no correlation was found between the severity groups [ $X^2(2, N = 58) = 2.30, p = 0.34$ ].



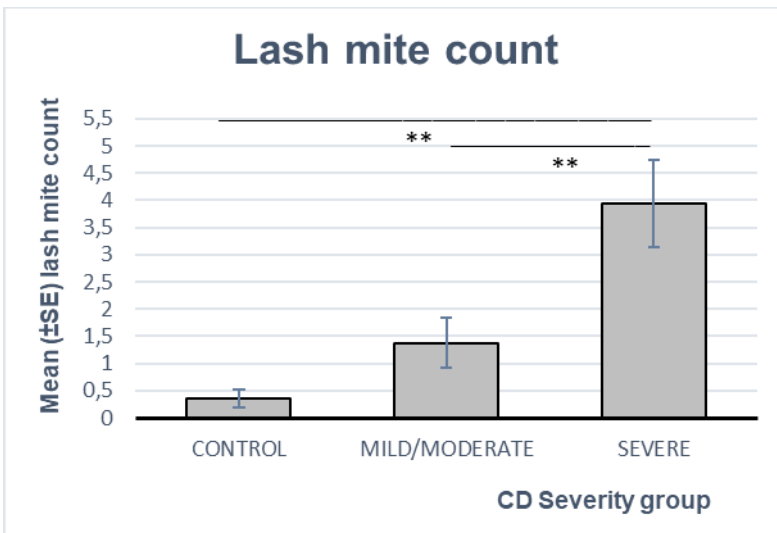
**Figure 4.** Scatterplot of the degree of facial erythema and the forehead *Demodex* density [mite count/cm<sup>2</sup>]

Table 5. Percentage (%) of each dermatological condition per severity group

	FACIAL SKIN CONDITIONS	GROUPS			P VALUE
		Control	Mild/moderate	Severe	
NO EFFECT REPORTED ON FACIAL MITE DENSITY	None	68.4%	71.4%	61.1%	0.34
	Acne vulgaris	5.3	14.3	5.5	
	Seborrheic dermatitis	10.5	4.8	5.5	
EFFECT REPORTED ON FACIAL MITE DENSITY	Telangectasias and/or papulopapules	15.8	9.5	27.7	
		100%	100%	100%	



**Lash Mite Count.** The overall lash mite count from the four lids of each participant was recorded. For the control, mild/moderate and severe groups, the mean was  $0.36 \pm 0.17$ ,  $1.38 \pm 0.45$  and  $3.94 \pm 0.80$  mites [Figure 5] and the median [min-max] was 0 [0-3], 0 [0-3] and 3 [1-14] mites, respectively. A significant increase in the mean lash mite count was observed between the three groups ( $p < 0.001$ ). The severe group had significantly higher mite count than both the controls ( $p < 0.001$ ) and mild/moderate group ( $p = 0.001$ ) [Table 6]. A correlation between age and the lash mite count was assessed, to make sure that age was not a confounding factor, and no relationship was found [ $r_s = 0.19$ ,  $p = 0.08$ ].



**Figure 5.** Lash mite count expressed as mean  $\pm$  standard error [SE] for each severity group. CD = cylindrical dandruff. Asterisks illustrate significant differences between groups at  $**p < 0.01$ .

To further evaluate the lash mite count, we compared the mean mite count for each lid. Participants came from both mild/moderate and severe groups [mild/moderate: 42.8%, severe: 100%]. These analyzes revealed no significant differences between each combination ( $p > 0.05$ ) [Table 7].

Table 6. Ocular and lid variables

Variables	Among the groups of severity (C, M, S)		Between-group comparisons
	Statistical test	p value	p value
Lash mite count	Kruskal-Wallis	< 0.001**	C-S: < 0.001**, r = 0.80; M-S: 0.001**, r = 0.51 C-M: 0.20;(Mann-Whitney U test)
TMH	Kruskal-Wallis	0.03*	C-M: 0.006**, r = -0.43; C-S: 0.34; M-S: 0.13 (Mann-Whitney U test)
OSDI	ANOVA	0.52	N/A
NIBUT	Repeated measures ANOVA	0.45	
Conjunctival bulbar redness	ANCOVA <sup>1</sup>	0.10	
Total of lash anomalies (trichiasis + poliosis)	ANCOVA <sup>1</sup>	0.34	

C = control; M = mild/moderate; S = severe;

OSDI = Ocular Surface Disease Index; NIBUT = Non-Invasive Break Up Time, TMH = Tear Meniscus Height

<sup>1</sup> Controlling for age

Asterisks illustrate statistical significance (\*p < 0.05, \*\*p < 0.01)

Table 7. Mite count for each lid

	Right eye			Left eye			p value
	Mean±SE	Median	Min-Max	Mean±SE	Median	Min-Max	
<b>Upper lid</b>	1.04±0.37	0	0-7	0.73±0.26	0	0-6	0.27
<b>Lower lid</b>	1.12±0.26	1	0-4	0.58±0.11	0	0-3	0.06
<b>p value</b>	0.87			0.64			

**Other Ocular Parameters.** Mean (±SE) TMH, NIBUT and OSDI are presented in Table 8. Since TMH values were not following a Gaussian distribution, the median for each group is also presented. There was a strong positive correlation between eyes for TMH [rs = 0.69, p < 0.001].

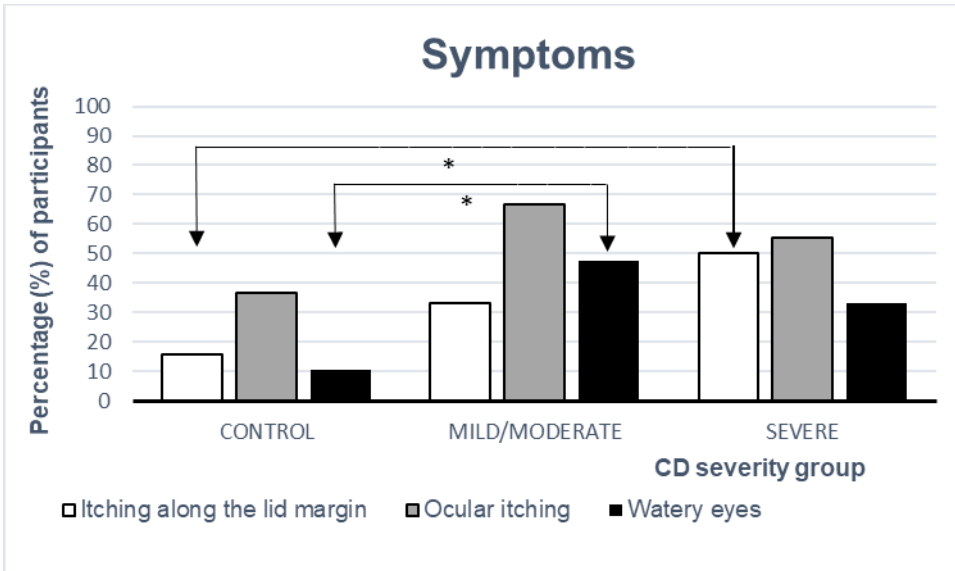
Hence, OD and OS values were averaged for the next analysis. Age was not a confounding factor, as the correlation between age and TMH was not statistically significant [ $r_s = 0.15$ ,  $p = 0.25$ ]. Non-parametric analysis revealed a statistically significant difference between the control and mild/moderate groups for TMH measurements [Table 6]. Parametric statistics were performed on OSDI, NIBUT, lash anomalies and conjunctival redness. However, none were statistically significant ( $p > 0.05$ ) [Table 6].

Table 8. Ocular Surface Disease Index, Non-Invasive Break Up Time and Tear Meniscus Height for each *Demodex* blepharitis severity

		Groups					
		Control		Mild/moderate		Severe	
		Right eye	Left eye	Right eye	Left eye	Right eye	Left eye
TMH	Mean±SE	0.27 ±0.06	0.28 ±0.06	0.18 ±0.04	0.20 ±0.04	0.23 ±0.05	0.23 ±0.05
	Median	0.23	0.24	0.19	0.20	0.20	0.20
NIBUT (Mean±SE)		7.5 ±1.7	7.8 ±1.8	8.0 ±1.7	8.2 ±1.8	7.6 ±1.8	6.5 ±1.4
OSDI (Mean±SE)		12.5±2.9		16.6±3.6		18.3±4.3	

OSDI = Ocular Surface Disease Index; NIBUT = Non-Invasive Break Up Time, TMH = Tear Meniscus Height

**Ocular Symptoms.** Participants were asked about itching along the lid margin, ocular itching and watery eyes specifically. For each symptom, responses were grouped into either symptomatic [some/most/all of the time] or asymptomatic [none of the time]. Inter-group comparisons were made for each group [Figure 6]. For itching along the lid margin, a relationship was found between the control and severe groups [ $X^2(1, N = 37) = 4.94$ ,  $p = 0.04$ ; Cramer's  $V = 0.37$ ]. For watery eyes, a relationship was found between the control and mild/moderate groups [ $X^2(1, N = 40) = 6.54$ ,  $p = 0.02$ ; Cramer's  $V = 0.40$ ]. For all of the other combinations, no statistically differences were found.



**Figure 6.** Percentage (%) of participants with different symptoms [itching along the lid margin, ocular itching and watery eyes] for each severity group. CD = cylindrical dandruff. Asterisks illustrate significant differences between groups at  $*p < 0.05$ .

Finally, all of the participants (100%) with *Demodex* blepharitis had at least one CD on each upper lid compared with 64.2% for each lower lid.

## Discussion

*Demodex* mites are normally present in the facial skin and the eyelids. However, their precise role in the microflora remains to be determined. It has been shown that the presence of *Demodex* is associated with several types of rosacea and blepharitis (Forton et al., 2017; Gao et al., 2005; Jalbert et al., 2015; Karıncaoglu et al., 2004; Lacey et al., 2016; Murphy et al., 2018b; Randon et al., 2015; Yun et al., 2017). As such, studies on *Demodex* mites have long been focused on whether the mite density in the facial skin or the mite count in the lids (Forton et al., 2017; Gao et al., 2005; Jalbert et al., 2015; Karıncaoglu et al., 2004; Lacey et al., 2016; Murphy et al., 2018b; Randon et al., 2015; Yun et al., 2017). Fortunately, some recent studies have analyzed and assessed both issues together with patients diagnosed with rosacea (Gonzalez-Hinojosa et al., 2018; Liang et al., 2016). From these studies came two conclusions: the presence of *Demodex* mites in the lids is associated with their occurrence in the cheeks (Liang et al., 2016),

and the mites are more frequent in the lash follicles of patients diagnosed with cutaneous rosacea (Gonzalez-Hinojosa et al., 2018).

Our study demonstrates that there is indeed a relationship between the palpebral and facial skin *Demodex* mites [Figure 2]. An increased facial mite density was found when participants were diagnosed with blepharitis secondary to *Demodex*. Both mild/moderate and severe groups were over the cut-off value [ $\geq 5$  mites/cm<sup>2</sup>] that confirms a facial demodicosis (Forton et al., 1993; Forton et al., 2017) [mild/moderate:  $4.8 \pm 0.6$ ; severe:  $5.5 \pm 0.7$ ] while the control group was below it [ $2.4 \pm 0.6$ ]. Although the severe group had a higher facial density than the mild/moderate group, the difference was not statistically significant. Unlike the study of Forton et al. (2017) that had a higher facial mite density in SSSB2 than SSSB1, we did not find any differences between SSSB1 and SSSB2. The variability in methodologies could explain this dissimilarity, as the sampling site in our study was always the same forehead location, while that of Forton et. al was the facial location with the cutaneous lesions.

The expertise of a dermatologist was highly beneficial in this study to identify facial skin anomalies in a standardized approach. Despite the exclusion of participants with evident acne rosacea, the dermatologist still identified several criteria [telangiectasia and/or papulopustules] of acne rosacea in 17% of our participants. This would have been missed by an eye care professional [ECP] alone. These skin analyzes were crucial, as they could have interfered as a confounding factor on the final mite density. Fortunately, the distribution of each skin condition diagnosed by the dermatologist, including participants with rosacea, was similar between each severity group [Table 5]. Therefore, we can conclude that the relationship we found between palpebral and facial *Demodex* mites is primarily explained by the mite itself. Moreover, our study shows that higher severities of facial erythema are associated with higher severities of *Demodex* infestation. Centrofacial erythema, as reported in the Canadian Clinical Practice Guidelines for Rosacea, is involved in several skin conditions: rosacea, photodamage, systemic lupus erythematosus, facial dermatitis, seborrheic dermatitis, psoriasis, and keratosis rubra pilaris faciei (Asai et al., 2016). From all of these conditions, only rosacea has been associated with *Demodex* mites. The pathogenesis of rosacea is complex and not yet fully understood. Two

mechanisms implicating *D. folliculorum* are the activation and involvement of the innate immune system and the overgrowth of commensal skin organisms (Two et al., 2015). It is demonstrated that *D. folliculorum* is one micro-organism among others that can prompt the immune system (Two et al., 2015). An immune system response typically involves vascular dilation in order to bring the necessary components closer to the involved tissue (Two et al., 2015). Although the exact steps between *Demodex* involvement and facial erythema is not yet elucidated in the literature, the present study shows that the degree of facial erythema is correlated with *Demodex* blepharitis severity ( $p = 0.001$ ) and increasing forehead mite density ( $p = 0.02$ ).

The SSSB technique and skin evaluations have some limitations. It is well demonstrated that the sampling location for the SSSB [i.e. cheeks, forehead, chin, and nose] influences facial mite densities (Forton et al., 2005; Yun et al., 2017). Yun et al. (2017) demonstrated that the facial mite density was higher in the T-zone [forehead, nose] of the face as compared to the U-zone [cheeks] using the SSSB technique. We selected the forehead [along the T-zone] for the following reasons: its physical characteristics of a flat, robust surface which had the least potential to have adverse effects related to the glue with the SSSB technique; and for better inter-study comparisons as demonstrated by Lacey et al. (2016). The SSSB technique has a learning curve to establish a standard protocol. For example, in some instances, the glue remained stuck on the skin after the microscope slide was removed. To preserve the sampling, the glue was removed gently using tweezers and was subsequently placed on the slide [Fabienne Forton, personal communication, September 20, 2017]. With practice this was less encountered, so training prior to the protocol is recommended. Despite this, some skin types were more conducive to the adhesion of the glue. However, the identification of the skin types was beyond the scope of this study. Another limitation is inherent to the CEA scale used in this study to establish the severity of the facial erythema (Tan et al., 2014). It is a reliable and validated tool that uses only descriptive terms for each severity of erythema. However, it has been criticized for its lack of photographs depicting the different severities (Tan et al., 2014). In our study, between 10 and 20 photographs per participant were taken to provide the dermatologist with a variety of views and address any issues with lighting. Using a single dermatologist reduced

potential inter-examiner bias. In a multi-examiner situation, sample photographs for each category could be useful.

The secondary objectives of our study were to assess the impact of the groups on several lid and ocular variables. The first variable was the lash mite count, which was significantly higher in the severe group [10 or more CDs] compared to the other groups [less than 10 CDs]. Also, it was higher in the mild/moderate group [1 to 9 CDs] compared to the controls [free of CDs], but the difference was not significant. It is well established that the presence of CDs is pathognomonic to *Demodex* (Gao et al., 2005). Our results confirm that not only are lashes with CDs more likely to have *Demodex* mites, which has already been demonstrated (Gao et al., 2005), but having more CDs per lid increases the mite count per eyelash. This suggests that when ECPs observe 10 or more CDs per lid, they could be reassured clinically that a *Demodex* infestation is present. Therefore, they may not need to perform lash epilation to confirm a demodicosis. However, when there is less than 10 CDs per lid, microscopic confirmation after epilation is appropriate. That being said, if the purpose is to evaluate the efficacy of a particular treatment, whether in clinic or in a research setting, then epilation followed by a microscopic confirmation of mite counts is required. We also evaluated the mean mite count of the four lashes that were epilated from participants that had at least 1 CD per lid. There were no significant differences in the mean mite count between eyes or between lids [Table 7]. This suggests that the origin of the epilated lash with CDs has no influence on the mite count.

To categorize the severity of *Demodex* blepharitis, the scale adopted for this study using the highest number of CDs per lid was the only one found in the literature (Schachter, 2014). We recognize that it is not yet validated and, as such, could create limitations in the division of the severity groups. In terms of the mite count, we have found that the scale is less effective to differentiate the lids with less than 10 CDs from the lids that are free of CDs. Despite some attempts at categorizing the levels of *Demodex* infestation in the literature (Liang et al., 2016; Randon et al., 2015; Schachter, 2014), there is no known validated scale for either the severity of *Demodex* blepharitis or the mite count in lash follicles. Additional investigations on this issue would be of great interest for future study comparisons. Based on our study, a severity scale using the CD count should consider primarily the upper lids, as 100% of our blepharitis

participants had at least one CD on each upper lid, compared to 64.2% for each lower lid. Furthermore, it is easier to have a person look down and scan the upper lashes as there are more lashes than in the lower lids.

Some limitations are associated with the lash epilation technique used in our study. As noted by Murphy et al. (2018), this technique does not always remove the complete content of the lash follicles. This is even more relevant in severe infestations where the eyelashes are poorly attached to the follicle (Murphy et al., 2018a). In these cases, the IVCN technique would have offered a more reliable estimation of the mites buried in the lash follicles because it is an undisturbed *in vivo* view. Furthermore, an epilation technique for the purposes of mite count has not yet been standardized. In our study, the epilation technique was uniform throughout the three groups, notably rotating the lash three times clockwise and pulling gently afterwards. The results obtained in this study for the mite count may not be directly comparable with others that have used a different technique (Gao et al., 2005; Murphy et al., 2018a, 2018b) or that did not specify the technique (Gao et al., 2012; Kheirhah et al., 2007; Koo et al., 2012). Also, other studies cited above collected at least two lashes per lid, compared with one lash per lid in our study. This choice in methodology is justified by our pilot project, in order to reduce the participants' level of stress and fatigue. The lash epilation was the last step in the experimentation and had the potential to increase the anxiety of the participant. Consequently, it was felt that epilating one lash per lid was an acceptable balance in the methodology, especially after all the tests that were performed on each participant. The decision had no impact on the primary outcome variables, since the blepharitis severity groups were divided based on the number of CDs. However, more lashes could have been beneficial in the analyzes of the secondary outcome variables.

Other secondary outcome variables were the OSDI, NIBUT, conjunctival bulbar redness and lash anomalies. None of them had any differences between the groups of CD severity. Many reasons may explain these observations. Firstly, for the three groups, the OSDI score was all between 13 and 23 [Table 8], considered as mild symptomatic dry eye. These findings confirm that the OSDI, validated for DED, is not appropriate with patients that are presenting with *Demodex* blepharitis, and this has been raised by others (Lee et al., 2010; Murphy et al., 2018b).



A modified OSDI version proposed by Murphy et al. (2018) better targets *Demodex* blepharitis patients but was not known at the time of this study. Secondly, when assessing tear film stability using the tear break up time [TBUT], Lee et al. (2010) and Kabatas et al. (2017) found a reduced TBUT with an increased mite presence. This is in contrast to our results and those of Jalbert and Rejab (2015). In our study, we measured NIBUT, as recommended for DED studies in the TFOS-DEWS II report (Novack et al., 2017), as opposed to the fluorescein TBUT measured in other studies (Jalbert et al., 2015; Kabatas et al., 2017; Lee et al., 2010). This difference in methodology makes comparisons between studies challenging. Thirdly, conjunctival bulbar redness and lash anomalies were not associated with blepharitis secondary to *Demodex* and were rather correlated with an increase in the age of the participants. We can hence conclude that the OSDI, NIBUT, conjunctival bulbar redness and lash anomalies are not specifically affected by blepharitis secondary to *Demodex*.

The last outcome variable was the specific ocular symptoms reported by the participants [watery eyes, ocular itching, itching along the lids]. The percentage of symptomatic participants with “watery eyes” was different in each group [control: 10.5%; mild/moderate: 47.6%; severe: 33.3%- Figure 6]. The mild/moderate group had significantly more watery eyes than the controls, but not significant with the severe group. As a result, we expected that the TMH would be higher in the group that reported more ‘watery eyes’ [i.e. mild/moderate group]. In contrast, the TMH measurement was significantly lower for the mild/moderate group compared to the controls [Table 8]. As TMH and “watery eyes” differed only between the control and mild/moderate group, a posteriori analysis between both variables was performed, but showed no correlation ( $p > 0.05$ ). A potential hypothesis to explain why the mild/moderate group had more watery eyes and a lower TMH may perhaps be in response to the recent onset of *Demodex* blepharitis, which results in inflammation of the lid margin and the ocular surface by an increased level of tear cytokine IL-17 (Kim et al., 2011). As the eye attempts to remove inflammatory markers by increased lacrimation, this in turn can blur the vision and subsequently induce an increase of the blinking reflex, resulting in a reduced TMH. Unfortunately, blinking was not assessed as part of the study, so this remains a potential hypothesis which needs to be validated with future investigations. The symptoms “itching along the lids” and “ocular itching” were also compared within the groups. The percentage of participants with “itching along the

lids” was significantly higher in the severe group compared to the controls [control: 15.8%; mild/moderate: 33.3%; severe: 50.0%]. Interestingly, it was the only symptom that was also correlated with the lash mite count. In contrast, participants with “ocular itching” were not significantly different between the groups [control: 36.8%; mild/moderate: 66.6%; severe: 55.5%] and this symptom was not correlated with the lash mite count, unlike other studies (Kabatas et al., 2017; Murphy et al., 2018b; Sedzikowska et al., 2016). To distinguish between “ocular itching” and “itching along the lid margin”, the principal investigator in our study was the only person to conduct the questions, so as to be consistent and clear about the anatomic distinction. This distinction was not made in previous studies (Kabatas et al., 2017; Murphy et al., 2018b; Sedzikowska et al., 2016). “Ocular itching” may have included participants exhibiting ocular allergies, of which ocular itching is a hallmark (Ackerman et al., 2016), whereas “itching along the lids” may be more specific to *Demodex* blepharitis, as demonstrated in our study. Therefore, ECPs should make a clear distinction between the two symptoms in their case history, which will more effectively target patients at risk of blepharitis secondary to *Demodex*.

Our study demonstrates that there is a connection between a palpebral and facial demodicosis. Although we did not evaluate the effectiveness of therapies on both ocular and facial mites. Topical ivermectin showed to be a promising therapy to reduce facial demodicosis (Schaller et al., 2017). Perhaps future formulations can be beneficial for both ocular and facial skin. Future studies should focus on the diagnosis and management of facial and palpebral demodicosis together, and whether systemic therapies, such as oral ivermectin (Brown et al., 2014), could play a role in normalizing *Demodex* mite count both in the lids and the facial skin. The results of this study provide evidence to ECPs that patients with *Demodex* mites in the lids may also have a concomitant facial infestation. Conversely, observation of a certain level of facial erythema by dermatologists should prompt them to consider *Demodex* infestation as part of the differential diagnosis, and a timely referral should be addressed to an ECP to rule out ocular demodicosis. Interprofessional management by both ECPs and dermatologists was also suggested by the global ROSacea Consensus [ROSCO] panel in 2016 for ocular and cutaneous rosacea (Schaller et al., 2016). They made several recommendations for the optimization of patient care in the treatment of rosacea. Since rosacea is strongly associated with MGD (Asai et

al., 2016) and in turn MGD is associated with Demodex infestation (Lopez-Ponce et al., 2017), it follows that facial rosacea patients should be referred to an ECP for evaporative dry eye related issues. This collaborative model would ultimately benefit the patient.

## **Conclusion**

Blepharitis secondary to *Demodex* is correlated with the degree of facial erythema, some ocular symptoms [watery eyes, itching along the lid margin] and a variation in the TMH. Finally, the presence of *Demodex* blepharitis is associated with increased facial mite densities, thus validating that palpebral and facial *Demodex* infestation can co-exist and a co-management approach between ECPs and dermatologists should be encouraged.

## **Acknowledgments**

The authors thank Dr. Sandra Davar, MD, Clinical lecturer, Department of Dermatology, *Université de Montréal*, for her facial skin analyzes and dermatological expertise, and the Canadian Optometric Education Trust Fund [COETF] for partial funding for this study. SA received financial support for her graduate degree from Allergan Canada, Shire Canada, School of Optometry and the Faculty of Graduate Studies [*École d'Optométrie et Faculté des études supérieures et postdoctorales- ÉOUM; FESP*], *Université de Montréal*.

## **References**

- Ackerman, S., Smith, L. M. et Gomes, P. J. (2016). Ocular itch associated with allergic conjunctivitis: latest evidence and clinical management. *Therapeutic Advances in Chronic Disease*, 7(1), 52-67.
- Asai, Y., Tan, J., Baibergenova, A., Barankin, B., Cochrane, C. L., et al. (2016). Canadian Clinical Practice Guidelines for Rosacea. *Journal of Cutaneous Medicine and Surgery*, 20(5), 432-445.

- Askin, U. et Seckin, D. (2010). Comparison of the two techniques for measurement of the density of *Demodex folliculorum*: standardized skin surface biopsy and direct microscopic examination. *British Journal of Dermatology*, 162(5), 1124-1126.
- Aydingoz, I. E., Dervent, B. et Guney, O. (2000). *Demodex folliculorum* in pregnancy. *International Journal of Dermatology*, 39(10), 743-745.
- Aytekin, S., Goktay, F., Yasar, S. et Gizlenti, S. (2016). Tips and tricks on *Demodex* density examination by standardized skin surface biopsy. *Journal of the European Academy of Dermatology and Venereology*, 30(11), e126-e128.
- Bhandari, V. et Reddy, J. K. (2014). Blepharitis: always remember demodex. *Middle East Afr J Ophthalmol*, 21(4), 317-320.
- Bron, A. J., de Paiva, C. S., Chauhan, S. K., Bonini, S., Gabison, E. E., et al. (2017). TFOS DEWS II pathophysiology report. *Ocul Surf*, 15(3), 438-510.
- Brown, M., Hernandez-Martin, A., Clement, A., Colmenero, I. et Torrelo, A. (2014). Severe demodexfolliculorum-associated oculocutaneous rosacea in a girl successfully treated with ivermectin. *JAMA Dermatol*, 150(1), 61-63.
- Chen, D., Li, R., Liu, X. W. et Li, Y. (2017). [Prevalence and treatment effects of *Demodex* species in eyelash follicles in patients with meibomian gland dysfunction]. *Zhonghua Yan Ke Za Zhi*, 53(3), 193-197.
- Chen, W. et Plewig, G. (2014). Human demodicosis: revisit and a proposed classification. *British Journal of Dermatology*, 170(6), 1219-1225.
- el-Shazly, A. M., Ghaneum, B. M., Morsy, T. A. et Aaty, H. E. (2001). The pathogenesis of *Demodex folliculorum* (hair follicular mites) in females with and without rosacea. *Journal of the Egyptian Society of Parasitology*, 31(3), 867-875.
- Forton, F., Germaux, M. A., Brasseur, T., De Liever, A., Laporte, M., et al. (2005). Demodicosis and rosacea: epidemiology and significance in daily dermatologic practice. *Journal of the American Academy of Dermatology*, 52(1), 74-87.

- Forton, F. et Seys, B. (1993). Density of Demodex folliculorum in rosacea: a case-control study using standardized skin-surface biopsy. *British Journal of Dermatology*, 128(6), 650-659.
- Forton, F. M. et De Maertelaer, V. (2017). Two Consecutive Standardized Skin Surface Biopsies: An Improved Sampling Method to Evaluate Demodex Density as a Diagnostic Tool for Rosacea and Demodicosis. *Acta Dermato-Venereologica*, 97(2), 242-248.
- Gao, Y. Y., Di Pascuale, M. A., Elizondo, A. et Tseng, S. C. (2007). Clinical treatment of ocular demodicosis by lid scrub with tea tree oil. *Cornea*, 26(2), 136-143.
- Gao, Y. Y., Di Pascuale, M. A., Li, W., Baradaran-Rafii, A., Elizondo, A., et al. (2005). In vitro and in vivo killing of ocular Demodex by tea tree oil. *British Journal of Ophthalmology*, 89(11), 1468-1473.
- Gao, Y. Y., Di Pascuale, M. A., Li, W., Liu, D. T., Baradaran-Rafii, A., et al. (2005). High prevalence of Demodex in eyelashes with cylindrical dandruff. *Investigative Ophthalmology and Visual Science*, 46(9), 3089-3094.
- Gao, Y. Y., Xu, D. L., Huang J., Wang, R. et Tseng, S. C. (2012). Treatment of ocular itching associated with ocular demodicosis by 5% tea tree oil ointment. *Cornea*, 31(1), 14-17.
- Gerber, P. A., Kukova, G., Buhren, B. A. et Homey, B. (2011). Density of Demodex folliculorum in patients receiving epidermal growth factor receptor inhibitors. *Dermatology*, 222(2), 144-147.
- Gilaberte, Y., Frias, M. P., Rezusta, A. et Vera-Alvarez, J. (2009). Photodynamic therapy with methyl aminolevulinate for resistant scalp folliculitis secondary to Demodex infestation. *Journal of the European Academy of Dermatology and Venereology*, 23(6), 718-719.
- Gonzalez-Hinojosa, D., Jaime-Villalonga, A., Aguilar-Montes, G. et Lammoglia-Ordiales, L. (2018). Demodex and rosacea: Is there a relationship? *Indian Journal of Ophthalmology*, 66(1), 36-38.
- Hsu, C. K., Hsu, M. M. et Lee, J. Y. (2009). Demodicosis: a clinicopathological study. *Journal of the American Academy of Dermatology*, 60(3), 453-462.

- Jalbert, I. et Rejab, S. (2015). Increased numbers of Demodex in contact lens wearers. *Optometry and Vision Science*, 92(6), 671-678.
- Kabatas, N., Dogan, A. S., Kabatas, E. U., Acar, M., Bicer, T., et al. (2017). The Effect of Demodex Infestation on Blepharitis and the Ocular Symptoms. *Eye Contact Lens*, 43(1), 64-67.
- Karinaoglu, Y., Bayram, N., Ayca, O. et Esrefoglu, M. (2004). The clinical importance of demodex folliculorum presenting with nonspecific facial signs and symptoms. *Journal of Dermatology*, 31(8), 618-626.
- Kheirkhah, A., Blanco, G., Casas, V. et Tseng, S. C. (2007). Fluorescein dye improves microscopic evaluation and counting of demodex in blepharitis with cylindrical dandruff. *Cornea*, 26(6), 697-700.
- Kim, J. T., Lee, S. H., Chun, Y. S. et Kim, J. C. (2011). Tear cytokines and chemokines in patients with Demodex blepharitis. *Cytokine*, 53(1), 94-99.
- Koo, H., Kim, T. H., Kim, K. W., Wee, S. W., Chun, Y. S., et al. (2012). Ocular surface discomfort and Demodex: effect of tea tree oil eyelid scrub in Demodex blepharitis. *Journal of Korean Medical Science*, 27(12), 1574-1579.
- Kulac, M., Ciftci, I. H., Karaca, S. et Cetinkaya, Z. (2008). Clinical importance of Demodex folliculorum in patients receiving phototherapy. *International Journal of Dermatology*, 47(1), 72-77.
- Lacey, N., Ni Raghallaigh, S. et Powell, F. C. (2011). Demodex mites--commensals, parasites or mutualistic organisms? *Dermatology*, 222(2), 128-130.
- Lacey, N., Russell-Hallinan, A. et Powell, F. C. (2016). Study of Demodex mites: Challenges and Solutions. *Journal of the European Academy of Dermatology and Venereology*, 30(5), 764-775.
- Lee, S. H., Chun, Y. S., Kim, J. H., Kim, E. S. et Kim, J. C. (2010). The relationship between demodex and ocular discomfort. *Investigative Ophthalmology and Visual Science*, 51(6), 2906-2911.

- Liang, H., Randon, M., Michee, S., Tahiri, R., Labbe, A., et al. (2016). In vivo confocal microscopy evaluation of ocular and cutaneous alterations in patients with rosacea. *British Journal of Ophthalmology*.
- Lopez-Ponce, D., Zuazo, F., Cartes, C., Salinas-Toro, D., Perez-Valenzuela, C., et al. (2017). High prevalence of Demodex spp. infestation among patients with posterior blepharitis: correlation with age and cylindrical dandruff. *Arch Soc Esp Oftalmol*.
- Mastrota, K. M. (2013). Method to identify Demodex in the eyelash follicle without epilation. *Optometry and Vision Science*, 90(6), 172-174.
- Murphy, O., O'Dwyer, V. et Lloyd-McKernan, A. (2018a). The efficacy of tea tree face wash, 1, 2-Octanediol and microblepharoexfoliation in treating Demodex folliculorum blepharitis. *Cont Lens Anterior Eye*, 41(1), 77-82.
- Murphy, O., O'Dwyer, V. et Lloyd-McKernan, A. (2018b). Ocular Demodex folliculorum: prevalence and associated symptoms in an Irish population. *International Ophthalmology*.
- Nicholls, S. G., Oakley, C. L., Tan, A. et Vote, B. J. (2017). Demodex species in human ocular disease: new clinicopathological aspects. *International Ophthalmology*, 37(1), 303-312.
- Novack, G. D., Asbell, P., Barabino, S., Bergamini, M. V. W., Ciolino, J. B., et al. (2017). TFOS DEWS II Clinical Trial Design Report. *Ocul Surf*, 15(3), 629-649.
- Randon, M., Liang, H., El Hamdaoui, M., Tahiri, R., Batellier, L., et al. (2015). In vivo confocal microscopy as a novel and reliable tool for the diagnosis of Demodex eyelid infestation. *British Journal of Ophthalmology*, 99(3), 336-341.
- Roth, A. M. (1979). Demodex folliculorum in hair follicles of eyelid skin. *Annals of Ophthalmology*, 11(1), 37-40.
- Schachter, S. (2014, 04-01-2014). A different approach to treating Demodex blepharitis. Repéré à <http://optometrytimes.modernmedicine.com/optometrytimes/content/tags/blephex/different-approach-treating-demodex-blepharitis?page=0,1>

- Schaller, M., Almeida, L. M., Bewley, A., Cribier, B., Dlova, N. C., et al. (2016). Rosacea treatment update: recommendations from the global ROSacea COnsensus (ROSCO) panel. *British Journal of Dermatology*.
- Schaller, M., Gonser, L., Belge, K., Braunsdorf, C., Nordin, R., et al. (2017). Dual anti-inflammatory and anti-parasitic action of topical ivermectin 1% in papulopustular rosacea. *Journal of the European Academy of Dermatology and Venereology*, 31(11), 1907-1911.
- Schiffman, R. M., Christianson, M. D., Jacobsen, G., Hirsch, J. D. et Reis, B. L. (2000). Reliability and validity of the Ocular Surface Disease Index. *Archives of Ophthalmology*, 118(5), 615-621.
- Sedzikowska, A., Oseka, M. et Grytner-Ziecina, B. (2016). Ocular symptoms reported by patients infested with Demodex mites. *Acta Parasitol*, 61(4), 808-814.
- Tan, J., Liu, H., Leyden, J. J. et Leoni, M. J. (2014). Reliability of Clinician Erythema Assessment grading scale. *Journal of the American Academy of Dermatology*, 71(4), 760-763.
- Tarkowski, W., Moneta-Wielgos, J. et Mlocicki, D. (2017). Do Demodex mites play a role in pterygium development? *Medical Hypotheses*, 98, 6-10.
- Tarkowski, W., Owczynska, M., Blaszczyk-Tyszka, A. et Mlocicki, D. (2015). Demodex mites as potential etiological factor in chalazion - a study in Poland. *Acta Parasitol*, 60(4), 777-783.
- Tighe, S., Gao, Y. Y. et Tseng, S. C. (2013). Terpinen-4-ol is the Most Active Ingredient of Tea Tree Oil to Kill Demodex Mites. *Transl Vis Sci Technol*, 2(7), 2.
- Two, A. M., Wu, W., Gallo, R. L. et Hata, T. R. (2015). Rosacea: part I. Introduction, categorization, histology, pathogenesis, and risk factors. *Journal of the American Academy of Dermatology*, 72(5), 749-758; quiz 759-760.
- Wolffsohn, J. S., Arita, R., Chalmers, R., Djalilian, A., Dogru, M., et al. (2017). TFOS DEWS II Diagnostic Methodology report. *Ocul Surf*, 15(3), 539-574.



- Yamashita, L. S., Cariello, A. J., Geha, N. M., Yu, M. C. et Hofling-Lima, A. L. (2011). Demodex folliculorum on the eyelash follicle of diabetic patients. *Arquivos Brasileiros de Oftalmologia*, 74(6), 422-424.
- Yun, C. H., Yun, J. H., Baek, J. O., Roh, J. Y. et Lee, J. R. (2017). Demodex Mite Density Determinations by Standardized Skin Surface Biopsy and Direct Microscopic Examination and Their Relations with Clinical Types and Distribution Patterns. *Ann Dermatol*, 29(2), 137-142.

## 4. Discussion

La revue de littérature sur les caractéristiques et anomalies des cils permet de saisir les particularités du follicule ciliaire, de la microflore des paupières, ainsi que l'impact que peut avoir une blépharite antérieure sur les cils. De plus, tous les types de blépharite antérieure, dont celle à *Demodex*, sont explicités. La blépharite à *Demodex* fait partie intégrante du projet de recherche et est le sujet principal du second article « Palpebral and facial skin infestation by *Demodex folliculorum* ». Cet article se concentre sur l'infestation à *D. folliculorum* dans les paupières et dans la peau du visage. Il répond à la question suivante : la sévérité de l'infestation des paupières est-elle corrélée avec la densité dudit parasite dans la peau du visage ? Les résultats démontrent qu'il existe effectivement une association entre la présence d'une blépharite antérieure à *D. folliculorum* et le degré d'infestation faciale. Par ailleurs, plus l'infestation faciale est sévère, plus le degré d'érythème facial l'est aussi. D'autre part, une blépharite antérieure à *D. folliculorum*, de grade léger à modéré, est associée à une réduction de volume de larmes (mesuré à l'aide de la hauteur du ménisque lacrymal) et à une augmentation des yeux larmoyants. Une de type sévère est associée à une augmentation de la sensation de picotement à la bordure des paupières.

Tel que décrit dans le premier article, la blépharite antérieure à *Demodex* peut avoir des répercussions négatives sur les cils. Lorsqu'elle n'est pas traitée, elle peut causer des anomalies de direction, de pigmentation et de croissance des cils. C'est pourquoi certaines anomalies des cils avaient été mesurées dans ce projet de recherche. La trichiase et la poliose avaient été sélectionnées pour leur facilité d'observation sur des photographies et le fait qu'elles soient quantifiables. Ces pathologies ont fait l'objet d'une description complète dans le premier article. Les résultats de ce projet de recherche ne démontrent pas que la trichiase et la poliose sont plus fréquentes en présence d'une blépharite à *D. folliculorum*. Par contre, c'est seulement lorsqu'une blépharite antérieure devient chronique qu'elle va créer des anomalies telles que la trichiase et la poliose. Le diagnostic de la blépharite à *D. folliculorum* peut donc être posé plusieurs mois après l'apparition des signes et symptômes oculaires, ce qui rend l'évaluation de sa durée une simple estimation. Le fait que le facteur « durée de la blépharite » n'était pas

considéré dans l'analyse statistique pourrait expliquer pourquoi il n'y avait pas une augmentation significative de la trichiasis et de la poliose en présence d'une blépharite. Seule une étude prospective permettrait d'obtenir une durée précise de la blépharite, et ce, en suivant des centaines de participants sur plusieurs décennies. Une telle étude n'est pas réaliste. D'un autre côté, il aurait été pertinent de mesurer d'autres anomalies des cils, tels que le milphosis. En présence d'une blépharite à *Demodex*, une perte de plusieurs cils est facilement observable à la lampe à fente. Par contre, le milphosis est difficilement quantifiable. En effet, il faudrait avoir une mesure de base du nombre de cils de chaque participant sans la blépharite, car la quantité de cils varie d'une paupière à l'autre et d'un individu à l'autre. Comme il n'y a pas de façon de quantifier le milphosis, cette anomalie n'avait pas été incluse dans ce projet de recherche.

Les résultats de ce projet de recherche ont aussi une retombée sur la pratique clinique de l'optométrie, l'ophtalmologie et la dermatologie. Les professionnels de la vue peuvent évaluer rapidement les cils à la lampe à fente et détecter la présence de gaines gélatineuses (connues dans la littérature sous le nom « cylindrical dandruff-CD ») pathognomoniques au *Demodex*. Une certaine expertise est requise afin de bien identifier ce type de débris et l'épilation de quelques cils ainsi que l'observation microscopique peut confirmer le diagnostic en cas de doute. Lorsqu'un diagnostic de blépharite à *D. folliculorum* est posé, une évaluation du visage devrait être faite afin de déterminer si une infestation faciale est aussi présente. L'évaluation faciale est plus fastidieuse que l'évaluation palpébrale, l'extraction du contenu des follicules pileux se faisant par plusieurs techniques invasives se prêtant difficilement à un contexte clinique. Cette difficulté limite grandement l'évaluation de la densité faciale de *D. folliculorum*.

Ce projet de recherche a aussi démontré que le degré d'érythème facial est corrélé à la sévérité d'une blépharite à *D. folliculorum*. Ainsi, une évaluation de la rougeur faciale pourrait être faite par les professionnels de la vue lorsqu'ils diagnostiquent une blépharite à *Demodex*. Cela pourrait être fait en utilisant des photographies typiques ou une échelle descriptive des divers degrés d'érythème facial (Hopkinson et al., 2015; Tan et al., 2014). Basés sur cette évaluation,

les professionnels de la vue feraient donc un tri des patients qui requièrent l'expertise d'un dermatologiste. D'un autre côté, les dermatologistes qui traitent une condition faciale reliée au *Demodex* pourraient aussi questionner davantage leurs patients sur leurs symptômes oculaires et les informer d'une possible infestation palpébrale. Ils devraient aussi diriger les patients qui se plaignent d'une sensation de picotement à la bordure des paupières, ce symptôme étant plus fréquent en présence d'une infestation palpébrale sévère à *D. folliculorum*, tel que démontré dans ce projet de recherche. La collaboration entre les deux professions est donc primordiale si une prise en charge globale de la problématique est souhaitée. Pour y arriver, il faudra sensibiliser les optométristes/ophtalmologistes et les dermatologistes aux effets du *D. folliculorum* sur le visage et sur les paupières. Des conférences multidisciplinaires devraient être envisagées.

Malgré que ce projet de recherche ait démontré une association entre l'infestation à *D. folliculorum* dans les paupières et dans la peau du visage, il ne permet pas d'établir s'il y a une relation de cause à effet entre les deux infestations. Est-ce que les parasites qui infestent le visage migrent vers les paupières ou vice-versa ? Cette hypothèse est crédible, mais les résultats de Rojas et al., 2012 ne semblent pas pointer dans cette direction. Les chercheurs ont démontré que les *D. folliculorum* retrouvés dans les cils et dans la peau du visage ont des différences morpho-biométriques (de Rojas et al., 2012). En effet, le *D. folliculorum* prélevé dans les cils a un opisthosoma de forme différente et est plus long que celui prélevé dans la peau du visage. De plus, il y a des différences dans leurs séquences génétiques. Le *D. folliculorum* a donc des caractéristiques « régionales », ce qui suggère qu'il infeste seulement son environnement immédiat. L'hypothèse la plus probable pour expliquer les deux infestations concomitantes serait que la quantité de parasites des paupières et de la peau du visage augmenterait progressivement dans leurs environnements respectifs. Par conséquent, un déséquilibre se produirait autant dans la microflore cutanée que dans celle palpébrale, et une infestation plus globale surviendrait. Il n'y aurait donc pas de migration des parasites d'une région à l'autre. Cette hypothèse devrait donc être validée dans de futures recherches.

Comme ce projet de recherche démontre que les infestations faciale et palpébrale peuvent être concomitantes, une prise en charge des deux structures atteintes serait de mise. Cela pourrait être fait par des thérapies topiques ou systémiques déjà existantes. Les agents topiques qui ont fait leurs preuves contre le *Demodex* pourraient faire l'objet d'études cliniques qui vérifient leur efficacité sur l'infestation palpébrale et faciale, de même que l'innocuité sur les deux structures atteintes. Ainsi, les préparations contenant du terpinen-4-ol ou de l'ivermectine topique pourraient être appliquées autant sur les paupières que sur la peau du visage. Si les résultats s'avèrent concluants, un seul produit pourrait donc être utilisé sur l'ensemble du visage. Aussi, des études cliniques pourraient être faites avec l'ivermectine sous forme orale. Son efficacité a été démontrée dans un rapport de cas chez une patiente ayant une infestation oculo-cutanée sévère et étant récalcitrante à d'autres thérapies systémiques (Brown et al., 2014). Une seule dose d'ivermectine orale avait été nécessaire pour diminuer les manifestations cliniques cutanées. Deux doses d'ivermectine sous forme orale avaient aussi diminué l'infestation palpébrale à *D. folliculorum* et amélioré la stabilité et quantité des larmes (Holzchuh et al., 2011). Finalement, la brimonidine topique et la lumière pulsée, deux thérapies qui sont recommandées par le ROSCO panel pour soulager l'érythème facial persistant secondaire à la rosacée, devraient être testées sur l'infestation palpébrale et faciale (Schaller et al., 2016). Bien que la brimonidine topique soit efficace dans la réduction de la rougeur faciale, il n'y a pas encore de publications sur l'effet qu'elle pourrait avoir sur le *Demodex*. La lumière pulsée a quant à elle fait ses preuves tout récemment sur l'infestation faciale (Ertas et al., 2018).

## 5. Conclusion

La présence d'une blépharite antérieure à *D. folliculorum* est associée à une augmentation de la densité faciale dudit parasite. De plus, la sévérité de la blépharite antérieure à *D. folliculorum* est corrélée avec le degré d'érythème facial, les symptômes oculaires des yeux larmoyants et de picotement du bord palpébral ainsi qu'avec une variation de la hauteur du ménisque lacrymal. Ces résultats démontrent que l'infestation palpébrale et l'infestation faciale coexistent, et qu'une approche multidisciplinaire entre les professionnels de la vue et les dermatologistes serait bénéfique pour les patients atteints

## 6. Bibliographie

- Akilov, O. E. et Mumcuoglu, K. Y. (2004). Immune response in demodicosis. *Journal of the European Academy of Dermatology and Venereology*, 18(4), 440-444.
- Asai, Y., Tan, J., Baibergenova, A., Barankin, B., Cochrane, C. L., et al. (2016). Canadian Clinical Practice Guidelines for Rosacea. *Journal of Cutaneous Medicine and Surgery*, 20(5), 432-445.
- Ayres, S., Jr. et Ayres, S., 3rd. (1961). Demodectic eruptions (demodicidosis) in the human. 30 years' experience with 2 commonly unrecognized entities: pityriasis folliculorum (Demodex) and acne rosacea (Demodex type). *Archives of Dermatology*, 83, 816-827.
- Bernardes, T. F. et Bonfioli, A. A. (2010). Blepharitis. *Seminars in Ophthalmology*, 25(3), 79-83.
- Bhandari, V. et Reddy, J. K. (2014). Blepharitis: always remember demodex. *Middle East Afr J Ophthalmol*, 21(4), 317-320.
- Brown, M., Hernandez-Martin, A., Clement, A., Colmenero, I. et Torrelo, A. (2014). Severe demodexfolliculorum-associated oculocutaneous rosacea in a girl successfully treated with ivermectin. *JAMA Dermatol*, 150(1), 61-63.
- Chen, D., Li, R., Liu, X. W. et Li, Y. (2017). [Prevalence and treatment effects of Demodex species in eyelash follicles in patients with meibomian gland dysfunction]. *Zhonghua Yan Ke Za Zhi*, 53(3), 193-197.
- Chen, W. et Plewig, G. (2014). Human demodicosis: revisit and a proposed classification. *British Journal of Dermatology*, 170(6), 1219-1225.
- Chosidow, O., Bernigaud, C. et Do-Pham, G. (2018). High-dose ivermectin in malaria and other parasitic diseases: a new step in the development of a neglected drug. *Parasite*, 25, 33.
- de Rojas, M., Riazzo, C., Callejon, R., Guevara, D. et Cutillas, C. (2012). Morphobiometrical and molecular study of two populations of Demodex folliculorum from humans. *Parasitology Research*, 110(1), 227-233.
- el-Shazly, A. M., Ghaneum, B. M., Morsy, T. A. et Aaty, H. E. (2001). The pathogenesis of Demodex folliculorum (hair follicular mites) in females with and without rosacea. *Journal of the Egyptian Society of Parasitology*, 31(3), 867-875.

- Ertas, R., Yaman, O., Akkus, M. R., Ozlu, E., Avci, A., et al. (2018). The rapid effect of pulsed dye laser on demodex density of facial skin. *Journal of Cosmetic and Laser Therapy*, 1-4.
- Ferreira, I. S., Bernardes, T. F. et Bonfioli, A. A. (2010). Trichiasis. *Seminars in Ophthalmology*, 25(3), 66-71.
- Forton, F., Germaux, M. A., Brasseur, T., De Liever, A., Laporte, M., et al. (2005). Demodicosis and rosacea: epidemiology and significance in daily dermatologic practice. *Journal of the American Academy of Dermatology*, 52(1), 74-87.
- Forton, F. M. (2012). Papulopustular rosacea, skin immunity and Demodex: pityriasis folliculorum as a missing link. *Journal of the European Academy of Dermatology and Venereology*, 26(1), 19-28.
- Forton, F. M. et De Maertelaer, V. (2017). Two Consecutive Standardized Skin Surface Biopsies: An Improved Sampling Method to Evaluate Demodex Density as a Diagnostic Tool for Rosacea and Demodicosis. *Acta Dermato-Venereologica*, 97(2), 242-248.
- Gao, Y. Y., Di Pascuale, M. A., Elizondo, A. et Tseng, S. C. (2007). Clinical treatment of ocular demodecosis by lid scrub with tea tree oil. *Cornea*, 26(2), 136-143.
- Gao, Y. Y., Di Pascuale, M. A., Li, W., Liu, D. T., Baradaran-Rafii, A., et al. (2005). High prevalence of Demodex in eyelashes with cylindrical dandruff. *Investigative Ophthalmology and Visual Science*, 46(9), 3089-3094.
- Geerling, G., Tauber, J., Baudouin, C., Goto, E., Matsumoto, Y., et al. (2011). The international workshop on meibomian gland dysfunction: report of the subcommittee on management and treatment of meibomian gland dysfunction. *Investigative Ophthalmology and Visual Science*, 52(4), 2050-2064.
- Gilaberte, Y., Frias, M. P., Rezusta, A. et Vera-Alvarez, J. (2009). Photodynamic therapy with methyl aminolevulinate for resistant scalp folliculitis secondary to Demodex infestation. *Journal of the European Academy of Dermatology and Venereology*, 23(6), 718-719.
- Gonzalez-Hinojosa, D., Jaime-Villalonga, A., Aguilar-Montes, G. et Lammoglia-Ordiales, L. (2018). Demodex and rosacea: Is there a relationship? *Indian Journal of Ophthalmology*, 66(1), 36-38.



- Holzchuh, F. G., Hida, R. Y., Moscovici, B. K., Villa Albers, M. B., Santo, R. M., et al. (2011). Clinical treatment of ocular Demodex folliculorum by systemic ivermectin. *American Journal of Ophthalmology*, 151(6), 1030-1034.
- Hopkinson, D., Moradi Tuchayi, S., Alinia, H. et Feldman, S. R. (2015). Assessment of rosacea severity: A review of evaluation methods used in clinical trials. *Journal of the American Academy of Dermatology*, 73(1), 138-143
- Hsu, C. K., Hsu, M. M. et Lee, J. Y. (2009). Demodicosis: a clinicopathological study. *Journal of the American Academy of Dermatology*, 60(3), 453-462.
- Jalbert, I. et Rejab, S. (2015). Increased numbers of Demodex in contact lens wearers. *Optometry and Vision Science*, 92(6), 671-678.
- Kabatas, N., Dogan, A. S., Kabatas, E. U., Acar, M., Bicer, T., et al. (2017). The Effect of Demodex Infestation on Blepharitis and the Ocular Symptoms. *Eye Contact Lens*, 43(1), 64-67.
- Karıncaoglu, Y., Bayram, N., Aycan, O. et Esrefoglu, M. (2004). The clinical importance of demodex folliculorum presenting with nonspecific facial signs and symptoms. *Journal of Dermatology*, 31(8), 618-626.
- Kim, J. T., Lee, S. H., Chun, Y. S. et Kim, J. C. (2011). Tear cytokines and chemokines in patients with Demodex blepharitis. *Cytokine*, 53(1), 94-99.
- Korb, D. R. et Blackie, C. A. (2013). Debridement-scaling: a new procedure that increases Meibomian gland function and reduces dry eye symptoms. *Cornea*, 32(12), 1554-1557.
- Kumar, A. et Karthikeyan, K. (2012). Madarosis: a marker of many maladies. *Int J Trichology*, 4(1), 3-18.
- Lacey, N., Delaney, S., Kavanagh, K. et Powell, F. C. (2007). Mite-related bacterial antigens stimulate inflammatory cells in rosacea. *British Journal of Dermatology*, 157(3), 474-481.
- Lacey, N., Ni Raghallaigh, S. et Powell, F. C. (2011). Demodex mites--commensals, parasites or mutualistic organisms? *Dermatology*, 222(2), 128-130.
- Lacey, N., Russell-Hallinan, A. et Powell, F. C. (2016). Study of Demodex mites: Challenges and Solutions. *Journal of the European Academy of Dermatology and Venereology*, 30(5), 764-775.

- Lee, S. H., Chun, Y. S., Kim, J. H., Kim, E. S. et Kim, J. C. (2010). The relationship between demodex and ocular discomfort. *Investigative Ophthalmology and Visual Science*, 51(6), 2906-2911.
- Liang, H., Randon, M., Michee, S., Tahiri, R., Labbe, A., et al. (2016). In vivo confocal microscopy evaluation of ocular and cutaneous alterations in patients with rosacea. *British Journal of Ophthalmology*.
- Liang, L., Ding, X. et Tseng, S. C. (2014). High prevalence of demodex brevis infestation in chalazia. *American Journal of Ophthalmology*, 157(2), 342-348 e341.
- Liang, L., Liu, Y., Ding, X., Ke, H., Chen, C., et al. (2018). Significant correlation between meibomian gland dysfunction and keratitis in young patients with Demodex brevis infestation. *British Journal of Ophthalmology*, 102(8), 1098-1102.
- Lindsley, K., Matsumura, S., Hatef, E. et Akpek, E. K. (2012). Interventions for chronic blepharitis. *Cochrane Database Syst Rev*(5), CD005556.
- Lopez-Ponce, D., Zuazo, F., Cartes, C., Salinas-Toro, D., Perez-Valenzuela, C., et al. (2017). High prevalence of Demodex spp. infestation among patients with posterior blepharitis: correlation with age and cylindrical dandruff. *Arch Soc Esp Oftalmol*.
- Moran, E. M., Foley, R. et Powell, F. C. (2017). Demodex and rosacea revisited. *Clinics in Dermatology*, 35(2), 195-200.
- Murphy, O., O'Dwyer, V. et Lloyd-McKernan, A. (2018a). The efficacy of tea tree face wash, 1, 2-Octanediol and microblepharoexfoliation in treating Demodex folliculorum blepharitis. *Cont Lens Anterior Eye*, 41(1), 77-82.
- Murphy, O., O'Dwyer, V. et Lloyd-McKernan, A. (2018b). Ocular Demodex folliculorum: prevalence and associated symptoms in an Irish population. *International Ophthalmology*.
- Ngo, W., Jones, L. et Bitton, E. (2017). Short-Term Comfort Responses Associated With the Use of Eyelid Cleansing Products to Manage Demodex folliculorum. *Eye Contact Lens*.
- Nicholls, S. G., Oakley, C. L., Tan, A. et Vote, B. J. (2017). Demodex species in human ocular disease: new clinicopathological aspects. *International Ophthalmology*, 37(1), 303-312.

- O'Dell, L., Gallant Sullivan, A. et Perlmanm, L. (2017). When beauty talk turns ugly. *Advanced Ocular Care*, 8(1), 16-20.
- Paulino, L. C. (2017). New perspectives on dandruff and seborrheic dermatitis: lessons we learned from bacterial and fungal skin microbiota. *European Journal of Dermatology*, 27(S1), 4-7.
- Paus, R., Burgoa, I., Platt, C. I., Griffiths, T., Poblet, E., et al. (2016). Biology of the eyelash hair follicle: an enigma in plain sight. *British Journal of Dermatology*, 174(4), 741-752.
- Post, C. F. et Juhlin, E. (1963). Demodex Folliculorum and Blepharitis. *Archives of Dermatology*, 88, 298-302.
- Prieto, V. G., Sadick, N. S., Lloreta, J., Nicholson, J. et Shea, C. R. (2002). Effects of intense pulsed light on sun-damaged human skin, routine, and ultrastructural analysis. *Lasers in Surgery and Medicine*, 30(2), 82-85.
- Randon, M., Liang, H., El Hamdaoui, M., Tahiri, R., Batellier, L., et al. (2015). In vivo confocal microscopy as a novel and reliable tool for the diagnosis of Demodex eyelid infestation. *British Journal of Ophthalmology*, 99(3), 336-341.
- Rufli, T. et Mumcuoglu, Y. (1981). The hair follicle mites Demodex folliculorum and Demodex brevis: biology and medical importance. A review. *Dermatologica*, 162(1), 1-11.
- Sahni, D. R., Feldman, S. R. et Taylor, S. L. (2018). Ivermectin 1% (CD5024) for the treatment of rosacea. *Expert Opinion on Pharmacotherapy*, 19(5), 511-516.
- Schaller, M., Almeida, L. M., Bewley, A., Cribier, B., Dlova, N. C., et al. (2016). Rosacea treatment update: recommendations from the global ROSacea COnsensus (ROSCO) panel. *British Journal of Dermatology*.
- Sedzikowska, A., Oseka, M. et Grytner-Ziecina, B. (2016). Ocular symptoms reported by patients infested with Demodex mites. *Acta Parasitol*, 61(4), 808-814.
- Stein, L., Kircik, L., Fowler, J., Tan, J., Draelos, Z., et al. (2014). Efficacy and safety of ivermectin 1% cream in treatment of papulopustular rosacea: results of two randomized, double-blind, vehicle-controlled pivotal studies. *J Drugs Dermatol*, 13(3), 316-323.

- Taieb, A., Ortonne, J. P., Ruzicka, T., Roszkiewicz, J., Berth-Jones, J., et al. (2015). Superiority of ivermectin 1% cream over metronidazole 0.75% cream in treating inflammatory lesions of rosacea: a randomized, investigator-blinded trial. *British Journal of Dermatology*, 172(4), 1103-1110.
- Tan, J., Liu, H., Leyden, J. J. et Leoni, M. J. (2014). Reliability of Clinician Erythema Assessment grading scale. *Journal of the American Academy of Dermatology*, 71(4), 760-763.
- Tarkowski, W., Owczynska, M., Blaszczyk-Tyszka, A. et Mlocicki, D. (2015). Demodex mites as potential etiological factor in chalazion - a study in Poland. *Acta Parasitol*, 60(4), 777-783.
- Thibaut, S., De Becker, E., Caisey, L., Baras, D., Karatas, S., et al. (2010). Human eyelash characterization. *British Journal of Dermatology*, 162(2), 304-310.
- Tighe, S., Gao, Y. Y. et Tseng, S. C. (2013). Terpinen-4-ol is the Most Active Ingredient of Tea Tree Oil to Kill Demodex Mites. *Transl Vis Sci Technol*, 2(7), 2.
- Turgut, B., Kurt, J., Catak, O. et Demir, T. (2009). Phthriasis palpebrarum mimicking lid eczema and blepharitis. *J Ophthalmol*, 2009, 803951.
- Two, A. M., Wu, W., Gallo, R. L. et Hata, T. R. (2015). Rosacea: part I. Introduction, categorization, histology, pathogenesis, and risk factors. *Journal of the American Academy of Dermatology*, 72(5), 749-758; quiz 759-760.
- Vij, A. et Bergfeld, W. F. (2015). Madarosis, milphosis, eyelash trichomegaly, and dermatochalasis. *Clinics in Dermatology*, 33(2), 217-226.
- Wolf, R., Orion, E. et Tuzun, Y. (2014). Periorbital (eyelid) dermatides. *Clinics in Dermatology*, 32(1), 131-140.
- Yamasaki, K., Di Nardo, A., Bardan, A., Murakami, M., Ohtake, T., et al. (2007). Increased serine protease activity and cathelicidin promotes skin inflammation in rosacea. *Nature Medicine*, 13(8), 975-980.