



## UvA-DARE (Digital Academic Repository)

### Effect of CO2 milliwatt laser on peripheral nerves: part I. A dose-response study

Menovsky, T.; van den Bergh Weerman, M.; Beek, J.F.

**DOI**

[10.1002/\(SICI\)1098-2752\(1996\)17:10<562::AID-MICR6>3.0.CO;2-S](https://doi.org/10.1002/(SICI)1098-2752(1996)17:10<562::AID-MICR6>3.0.CO;2-S)

**Publication date**

1997

**Published in**

Microsurgery

[Link to publication](#)

**Citation for published version (APA):**

Menovsky, T., van den Bergh Weerman, M., & Beek, J. F. (1997). Effect of CO2 milliwatt laser on peripheral nerves: part I. A dose-response study. *Microsurgery*, 17, 562-567. [https://doi.org/10.1002/\(SICI\)1098-2752\(1996\)17:10<562::AID-MICR6>3.0.CO;2-S](https://doi.org/10.1002/(SICI)1098-2752(1996)17:10<562::AID-MICR6>3.0.CO;2-S)

**General rights**

It is not permitted to download or to forward/distribute the text or part of it without the consent of the author(s) and/or copyright holder(s), other than for strictly personal, individual use, unless the work is under an open content license (like Creative Commons).

**Disclaimer/Complaints regulations**

If you believe that digital publication of certain material infringes any of your rights or (privacy) interests, please let the Library know, stating your reasons. In case of a legitimate complaint, the Library will make the material inaccessible and/or remove it from the website. Please Ask the Library: <https://uba.uva.nl/en/contact>, or a letter to: Library of the University of Amsterdam, Secretariat, Singel 425, 1012 WP Amsterdam, The Netherlands. You will be contacted as soon as possible.

# EFFECT OF CO<sub>2</sub> MILLIWATT LASER ON PERIPHERAL NERVES: PART I. A DOSE-RESPONSE STUDY

THOMAS MENOVSKY, M.D.,\*

MARIUS VAN DEN BERGH WEERMAN, and

JOHAN F. BEEK, M.D., Ph.D.

In order to explore further the role of laser for microneural repair, the effect of CO<sub>2</sub> laser irradiation on intact rat sciatic nerves was investigated. In total 40 rat sciatic nerves were exposed to 12 different combinations of laser power (50, 100, and 150 mW) and pulse duration (0.1 to 3 s) normally used for CO<sub>2</sub> laser-assisted nerve repair. The results were evaluated 24 hr after surgery with functional toe-spreading test and light microscopy. Irradiations of 50 and 100 mW for up to 1 s exposure time per pulse resulted in almost no deficit in motor function, while 100 mW power with prolonged exposure times and 150 mW power resulted in a significant decrease in motor function. Light microscopy showed signifi-

cant focal injury to the epi/perineurium and the subepineurial nerve fibres proportional to the laser energy applied to the nerve, consisting of Wallerian degeneration and thrombosis of blood vessels. In conclusion, a power of 50–100 mW in combination with a pulse duration of 0.1–1 s produced no or minimal thermal damage with no or a negligible loss of motor function. Therefore, combinations of power and pulse duration above these thresholds are considered less suitable for CO<sub>2</sub> laser nerve repair.

© 1997 Wiley-Liss, Inc.

MICROSURGERY 17:562–567 1996

The CO<sub>2</sub> milliwatt laser has been used experimentally, and occasionally clinically, for repair of transected peripheral and cranial nerves for a decade.<sup>1,2</sup> Although very promising, laser-assisted nerve repair (LANR) still needs to be optimised to be effectively and safely used in clinical practice. Many factors influence the results of LANR, the most important being the total energy of laser irradiation applied to the nerve.

Not much information could be gained from the literature on the exact action of laser on peripheral nerve tissue. Unlike the brain, in which the action of laser irradiation has been studied extensively,<sup>3–7</sup> there are almost no data on the extent of damage of peripheral nerves after laser irradiation. In a previous study, we have determined the CO<sub>2</sub> laser settings that produce the greatest bonding strength.<sup>8</sup> In order to further explore the role of CO<sub>2</sub> milliwatt laser for repair of peripheral nerves, this study was designed to investigate the thermal damage of rat sciatic nerve irradiated by a CO<sub>2</sub> mW laser at different powers and exposure times. The results were evaluated 24 hr after irradiation by means of the functional toe spreading test and light microscopy.

## MATERIALS AND METHODS

A total of 40 female Wistar rats were used in the experiments. The rats (weighing 200–300 g) were housed a maximum of six to a cage and were kept during the experiment under conventional laboratory conditions. General anaesthesia was achieved using an intraperitoneal injection of ketamine, xylazine, and atropine mixture (9:5:1) in a dosage of 0.15 ml/100 g.

In each rat, the right sciatic nerve was exposed by a modified dorsolateral incision.<sup>9</sup> Under an operating microscope, the nerve was prepared free and isolated from the surrounding tissue by a plastic sheet. The diameter of the sciatic nerve ranged between 0.9 and 1.1 mm (average 1 mm). Circumferential irradiation of the nerve with the CO<sub>2</sub> laser was performed at various laser settings as summarised in Table 1. For each setting (*n* = 4) the total number of pulses applied to each nerve was between 8 to 10. These laser settings have been previously evaluated for their bonding strength in an *in vitro* study.<sup>8</sup> For 50 mW power, exposure times were limited to 2 and 3 s, as below these exposure times no bonding of the nerves could be achieved. The untreated left nerve was sham operated and served as a control. After the procedure, the fascia of the hamstring muscles was closed with 6-0 Dexon sutures and the skin was closed with 4-0 Dexon sutures. The same person carried out all surgical procedures.

The CO<sub>2</sub> laser was used in conjunction with an operating microscope and a joystick micromanipulator. The laser was operated in a continuous wave mode using an electrical

Laser Centre and Department of Pathology, Academic Medical Centre, Amsterdam, and Department of Neurosurgery, University Hospital Nijmegen St. Radboud, Nijmegen, The Netherlands

Contract grant sponsor: Matty Brand Stichting, The Netherlands.

\*Correspondence to: Thomas Menovsky, M.D., Laser Center, Academic Medical Center, Meibergdreef 9, 1105AZ Amsterdam, The Netherlands.

**Table 1.** Experimental Protocol of Laser Parameters and Summary of the Macroscopic Observations<sup>a</sup>

Power (mW)	Exposure time per pulse (s)			
	0.5	1.0	2.0	3.0
50	x	x	1-2	2-3
100	2-3	3-4	4	4-5
150	3-4	5	5-6	6

<sup>a</sup>0 = no observable effect; 1 = drying; 2 = shrinkage; 3 = whitening; 4 = caramelization (slightly browning); 5 = carbonization; 6 = vaporization. x = not performed.

shutter and a foot-switch to control the pulse duration. A spot size of 320  $\mu\text{m}$  was used.

The motor function of the nerves was examined 24 hr after surgery using a modified version of the "toe-spreading test" as described by others.<sup>10-12</sup> In short, the toe-spreading, defined as the distance from the first to the fifth digit, from both hind legs was measured from walking tracts. The relative toe-spreading of the right foot was calculated with the untreated left foot as a control. A 100% motor function loss will result in a relative toe-spreading of 30%, whilst no motor function loss will result in a relative toe-spreading of 100%. For each measurement, at least four footsteps were recorded.

The rats were sacrificed 24 hr after surgery by an overdose of intraperitoneal Nembutal and the nerves were carefully dissected. The nerves were fixed in Karnovsky's fixative, post-fixed in osmium tetroxide 1%, stained with uranyl acetate, dehydrated in acidified 2,2-dimethoxypropane, and embedded in Epon. After hardening, semi-thin cross-sections were cut (1.25  $\mu\text{m}$ ) and stained with Toluidine blue.

## RESULTS

### Macroscopic Changes

Observation of the nerve during irradiation showed gradual changes in appearance of the tissue, which are summarised in Table 1. Little macroscopic effect was elicited from the 50-mW power groups at 2-s exposure time. In contrast, vaporisation, ablation, and perforation of the epi/perineurium were observed in the 150-mW power groups at irradiations with 2.0 and 3.0 s. The 100-mW power groups showed brown discoloration and some degree of shrinkage of the irradiated area (approximately proportional to the irradiation time).

### Toe-Spreading Test

The results of the toe-spreading test are presented in Figure 1. Irradiations of 50 and 100 mW for up to 1-s exposure time per pulse resulted in negligible or no deficit in motor function of the nerves. Irradiations with 100 mW with prolonged exposure timer (>2 s pulse duration) and

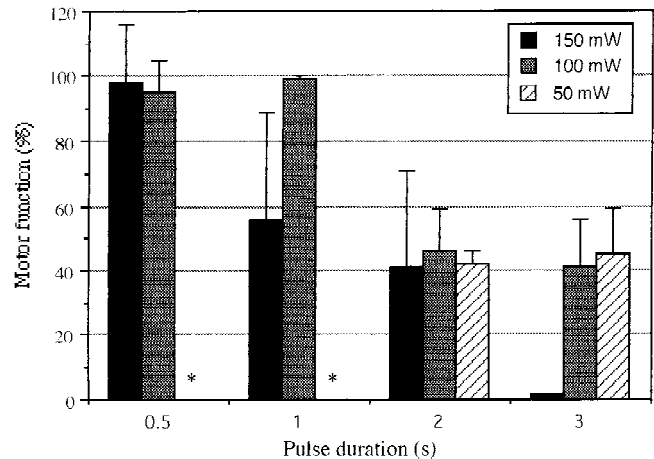


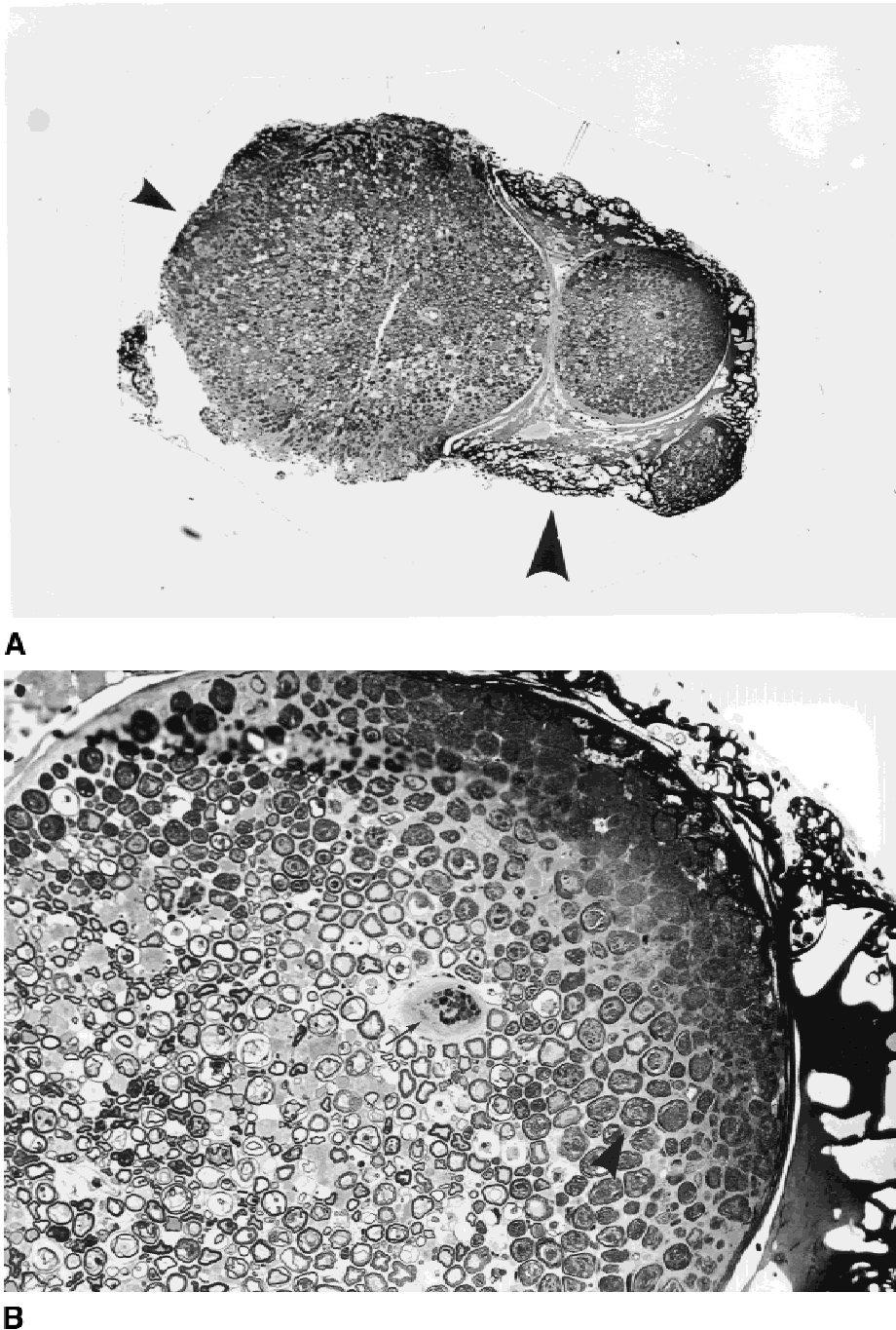
Figure 1. Motor function based on the toe-spreading of the hind legs of rats after irradiation with the CO<sub>2</sub> laser at different laser settings.

irradiations with 150 mW power resulted in significant decrease in motor function.

### Light Microscopic Changes

Several pathological reactions ranging from total destruction of a part of the nerve to minimal changes were observed, strongly related to the used level of power and exposure duration. The most severe reaction, occurring at 150 mW for 2- and 3-s exposure time, consisted of ablation and perforation of the epi- and perineurium and carbonised and coagulated tissue in which the cells and the tissue structure were not recognisable. More towards the centre of the nerve, massive Wallerian degeneration with endoneurial oedema was observed (Fig. 2). In this region, the blood vessels were thrombosed and the injured axons were retracted away from their myelin sheaths and Schwann cells. No inflammatory cells were seen. Only in the central part of the nerve, a few normal axons and myelin sheaths were observed together with intact blood vessels. The extent of the thermal damage was approximately 500  $\mu\text{m}$  including the thickness of epi/perineurium.

At lower powers (50 mW for 3.0 s and 100 mW for 0.5 and 1 s), the thermal damage was much more confined to the sub-epineurial axons (Fig. 3). The pathological changes consisted of two relatively thin layers. In the outer zone ( $\pm 120 \mu\text{m}$ ), located directly sub-perineurially, the nerve tissue was oedematous and the nerve fibres had darkly stained cytoplasm. The second zone ( $\pm 150 \mu\text{m}$ ), located more towards the centre, was also oedematous but the myelin sheaths were thin and separate layers of the myelin sheaths were intruding into the axoplasm. Moreover, enlarged and empty endoneurial tubules were seen. Both the inner and outer zones were undergoing Wallerian degeneration, but inflammatory changes were not found. The vessels were



**Figure 2.** Severe thermal damage of nerve tissue at 150 mW for 3-s laser exposure. **A:** Total (small arrowhead) and subtotal (large arrowhead) vaporization of epi- and perineurium with carbonisation. Only in the very center of the nerve are normal axons present (Toluidine blue  $\times 45$ ). **B:** Two different zones of thermal damage. Edematous nerve fibers with darkly stained axoplasm (arrowhead) and nerve fibres in which myelin sheaths are thin and retracted in the axoplasm. Note also the thrombosed vessels (small arrow) (Toluidine blue,  $\times 125$ ).

thrombosed and the perivascular space was enlarged. The epineurium was oedematous and fibroblasts showed dark pyknotic nuclei. The thickness of the total thermal damage was approximately 300  $\mu\text{m}$ , including the epineurium. The central part of the nerve was undamaged.

At 50 mW for 2.0 s and 100 mW for 0.5 s, the thermal

damage was slightly less than in the 100-mW group for 0.5 and 1 s, despite the absence of macroscopical changes during the laser irradiation. The thickness of the thermal damage was approximately 120  $\mu\text{m}$ . The pathological changes were the same as described at 50 mW for 3.0 s and 100 mW for 0.5 and 1 s but less pronounced (Fig. 4).




Figure 3. Subepineurial zone of thermal damage at 100 mW for 1 s laser exposure. Note Wallerian degeneration in the nerve 24 hr after irradiation (large arrow). In the outer zone, there is swelling of affected fibers with darkly stained axoplasm and attenuated myelin sheaths (large arrow). In the inner zone some empty endoneurial tubules (small arrows) are seen together with disintegrating myelin sheaths (Toluidine blue,  $\times 501$ ).

In all groups, morphological changes proximal from the irradiated area were not seen. In the distal nerve, Wallerian degeneration was not yet seen. Sham-operated nerves showed no pathological changes and were identical to unoperated nerves.

## DISCUSSION

In microsurgery, optimal results are only achieved when techniques are constantly refined and developed. In a previous study, we investigated the *in vitro* tensile strength of laser-assisted nerve repair using the CO<sub>2</sub> mW laser without addressing the damage to nerve and nerve functions. In the present study, we have investigated the thermal damage and nerve function of peripheral nerves irradiated with a CO<sub>2</sub> mW laser at settings that were found to give the highest tensile strength *in vitro*. A survival time of 24 h was chosen because thermal damage to biological tissue is assumed to be complete.<sup>13</sup> After 24 hr only further re-organisation is expected to take place. Since this study focussed on thermal damage, the nerves were not transected prior to laser irradiation. Reactions resulting from the traumatic division only would have hampered the assessment of the tissue reaction caused by laser irradiation. No reaction resulting from only exploration and mobilisation was found in the sham-operated sides, as was expected.<sup>14</sup>

Due to its desirable properties of low tissue penetration, the CO<sub>2</sub> laser ( $\lambda = 10.6 \mu\text{m}$ ) is at this moment the most

frequently used system for microsurgical laser-assisted nerve repair. As the CO<sub>2</sub> laser energy is mostly absorbed at the tissue surface, at short pulse duration it is expected to cause minimal damage within the substance of the nerve. There are only two previous studies on the effects of CO<sub>2</sub> laser irradiation on intact peripheral nerves. Richmond reports no histological, behavioural, or neurological deficit following CO<sub>2</sub> laser irradiation of intact rat sciatic nerves at a power of 70–80 mW and a pulse duration of several microseconds.<sup>15</sup> Myers et al. did find thermal damage in rat sciatic nerve irradiated with a CO<sub>2</sub> laser at relatively high power for tissue welding of 5 W for 0.25 and 0.5 s, using a relatively large spot size of 2 mm (energy densities of 0.4 and 0.8 J/m<sup>2</sup> at 0.25 and 0.5 s pulse duration, respectively).<sup>16</sup> Wallerian degeneration and perivascular and subperineurial oedema marked the nerve injury 2 days after irradiation.

In this study, the pathological changes of the nerve tissue consisted of specific alterations, dependent on the energy delivered. At high powers, there was total destruction of the nerve with only a small centre in which healthy nerve fibres could be observed. At lower powers, a small zone of sub-epineurial Wallerian degeneration with oedema, swelling of vascular structures, damaged endothelial cells, and vascular occlusion was seen. The central part of the nerve was undamaged. Minimal damage was seen at a power of 100 mW and pulse duration of 1 s (at a spot size of 320  $\mu\text{m}$ , resulting in an energy density of 3.5 J/m<sup>2</sup> per pulse). This

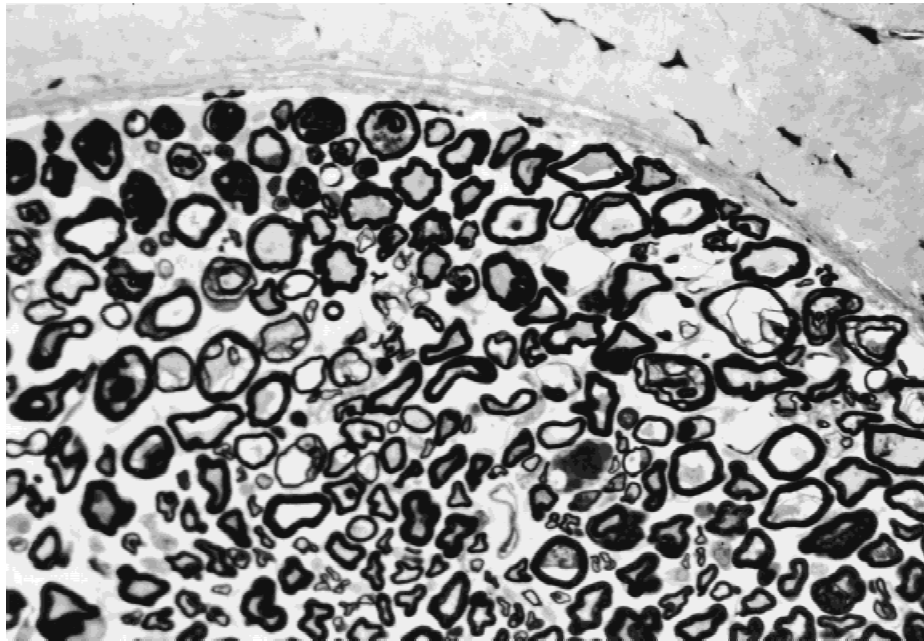


Figure 4. Degeneration of axons after CO<sub>2</sub> laser irradiation at 50 mW. Despite absence of macroscopic changes during irradiation, the nerve shows minimal sub-epineurial degeneration (Toluidine blue, x500).

result compares favourably to the results of Myers et al.<sup>16</sup> who found extensive damage at lower energy densities.

Several aspects of this study are of importance. First, the absence of macroscopic changes during laser irradiation does not necessarily mean that the nerve is uninjured. For example, at 50 mW power, where only slight macroscopic changes were observed, there is still an area of damaged nerve fibres noted on histological sections. On the other hand, significant changes during laser irradiation such as at 100 mW for 1 s (Table 1) did not result in extensive histological damage to the nerve nor in severe functional deficit. Second, at powers with short exposure times the relative amount of nerve tissue injured is minimal and irradiation at these powers leads to hardly any neurological dysfunction. In other words, segmental demyelination does not necessarily lead to the development of severe nerve function loss. Finally, at 100 mW for 1 s (which are the laser settings which produced the greatest tensile strength in vitro<sup>8</sup>) only sub-epineurial damage was present with normal preservation of the nerve structure, including the vasculature in the middle of the nerve. Consequently, these laser settings are very suitable for future experiments on laser-assisted nerve repair. Further experiments are warranted.

#### ACKNOWLEDGMENTS

The authors thank Dr. Olga L. Kubista, M.D., for her help with the experiments and Marja Ramkema and Dora Zeehandelaar for their help with the histology. This study

was supported by a grant from "Matty Brand Stichting," The Netherlands.

#### REFERENCES

1. Krishnamurthy S, Powers SK: Lasers in neurosurgery. *Lasers Surg Med* 15:126-167, 1994.
2. Menovsky T, Beek JF, Thomsen SL: Laser(-assisted) nerve repair: a review. *Neurosurg Rev* 18:225-235, 1995.
3. Gamache FJ, Morgello S: The histopathological effects of the CO<sub>2</sub> versus the KTP laser on the brain and spinal cord: A canine model. *Neurosurgery* 32:100-104, 1993.
4. Martiniuk R, Bauer JA, McKean JD, Tulip J, Mielke BW: New long-wavelength Nd:YAG laser at 1.44 micron: effect on brain. *J Neurosurgery* 70:249-256, 1989.
5. Roux FX, Mordon S, Fallet BC, Merienne L, Devaux BC, Chodkiewicz JP: Effects of 1.32-micron Nd:YAG laser on brain thermal and histological experimental data. *Surg Neurol* 34:402-407, 1990.
6. Wharen RJ, Anderson RE, Scheithauer B, Sundt TJ: The Nd:YAG laser in neurosurgery. Part 1. Laboratory investigations: dose-related biological response of neural tissue. *J Neurosurg* 60:531-539, 1984.
7. Wharen RJ, Anderson RE, Sundt TJ: The Nd:YAG laser in neurosurgery. Part 2. Clinical studies: an adjunctive measure for hemostasis in resection of arteriovenous malformations. *J Neurosurg* 60:540-547, 1984.
8. Menovsky T, Beek JF, van Gemert MJ: CO<sub>2</sub> laser nerve welding: optimal laser parameters and the use of solders in vitro. *Microsurgery* 15:44-51, 1994.
9. Menovsky T: Modified surgical approach of the rat sciatic nerve. *Microsurgery* 16:510-511, 1995.
10. DeMedinacelli L, Feed WJ, Wyatt RJ: An index of the functional condition of rat sciatic nerve based on measurements made from walking tracts. *Exp Neurol* 77:634-643, 1982.
11. Terzis JK, Smith KJ: Repair of severed peripheral nerves: comparison

- of the "de Medinaceli" and standard microsuture methods. *Exp Neurol* 96:672-680, 1987.
12. Wondergem J, Haveman J, Rusman V, Sminia P, van Dijk JDP: Effects of local hyperthermia on the motor function of the rat sciatic nerve. *Int J Radiat Biol* 3:429-438, 1988.
  13. Thomsen S: Pathologic analysis of photothermal and photochemical effects of laser-tissue interactions. *Photochem Photobiol* 53:825-835, 1991.
  14. Edshage S: Peripheral nerve suture. *Acta Chirurgico Scand* 331:32-55, 1964.
  15. Richmond IL: The use of lasers in nerve repair, in Fasano VA (ed): *Advanced intraoperative technologies in neurosurgery*. Wien, Springer-Verlag, 1986, pp. 175-183.
  16. Myers RR, James HE, Powell HC: Laser injury of peripheral nerve: a model for focal endoneurial damage. *J Neurol Neurosurg Psychiatry* 48:1265-1268, 1985.