

PDF hosted at the Radboud Repository of the Radboud University Nijmegen

The following full text is a publisher's version.

For additional information about this publication click this link.

<http://hdl.handle.net/2066/22678>

Please be advised that this information was generated on 2021-09-30 and may be subject to change.

Palatal Mucoperiosteal Expansion as an Adjunct to Palatal Fistula Repair: Case Report and Review of the Literature

PHILIP A. VAN DAMME, M.D., D.M.D.
HANS PETER M. FREIHOFFER, M.D., D.M.D., PH.D.

Case report of conventional palatal soft-tissue expansion in an attempt at cleft palate fistula closure with a standard tissue expander. This technique may be an alternative to a tongue flap to promote closure of persistent oronasal fistula.

KEY WORDS: *alternative to tongue flap, cleft palate, fistula closure, standard tissue expander, soft-tissue expansion*

Intraoral soft-tissue expansion for augmentation of the alveolar process in preprosthetic surgery has been established (Lew et al., 1986). Palatal mucoperiosteal expansion with non-custom-made tissue expanders, however, has never been reported. Indeed, conventional or rapid palatal soft-tissue expansion was recently judged to be impossible (Abramo et al., 1993; Van Damme, 1994). In clinical reports, the use of Foley catheters and custom-made tissue expanders has been reported (De Mey et al., 1990, Abramo et al., 1993). In an animal experiment, custom-made tissue expanders were successfully utilized for subperiosteal palatal soft-tissue expansion (Van Damme et al., 1991, 1993).

The purpose of this report is to suggest that palatal soft-tissue expansion with standard expanders can be helpful, although not necessarily completely successful, in closing residual palatal defects of cleft palate patients under unfavorable circumstances.

CASE REPORT

A 37-year-old male patient was referred to the Nijmegen Center for cleft lip and palate management. He presented with an operated right-sided cleft lip and palate (UCLP), with a persistent oronasal fistula. He had had eight previous operations at other centers including, at the age of 24 years, closure of the palatal oronasal communication with a costal bone graft. Because of sequestration of part of the graft, a fistula had developed. Initially, there were no functional problems. However, in time, the patient complained of liquid leakage into the nose and requested closure of the fistula. A late secondary closure techni-

que was indicated with nasal and oral mucoperiosteal-layer closure and interposition of an autogenous chinbone graft for reconstruction of the alveolar process (Freihofer et al., 1993). The operation and immediate postoperative period were uneventful. However, in spite of adjustment of a protection device, palatal dehiscence with exposure of the transplant occurred, which finally led to necrosis of the graft and a residual palatal defect (Fig. 1). Since the patient had a fixed dental bridge, a buccovestibular-flap technique to close the defect was considered undesirable.

The feasibility for conventional palatal soft-tissue expansion with standard tissue expanders was studied on a cast model (Fig. 2). A spherical Intravent tissue expander (CUI-IOS-01, CUI Corporation, Carpinteria, CA), with an expansion volume of 1 mL and a diameter of 12 mm, with a remote filling tube was chosen. This was inserted after tunneling the palatal mucoperiosteum on the left side via a small incision in the front of the vestibulum and another near the second molar. Initially, it was filled with 0.4 mL of physiologic salt solution. Healing was undisturbed. Two weeks postoperatively, serial inflation was started twice a week until, after eight sessions, a volume of 1.8 mL was reached (Fig. 3). The tissue expander was removed along the lateral incision line (Fig. 4), and a

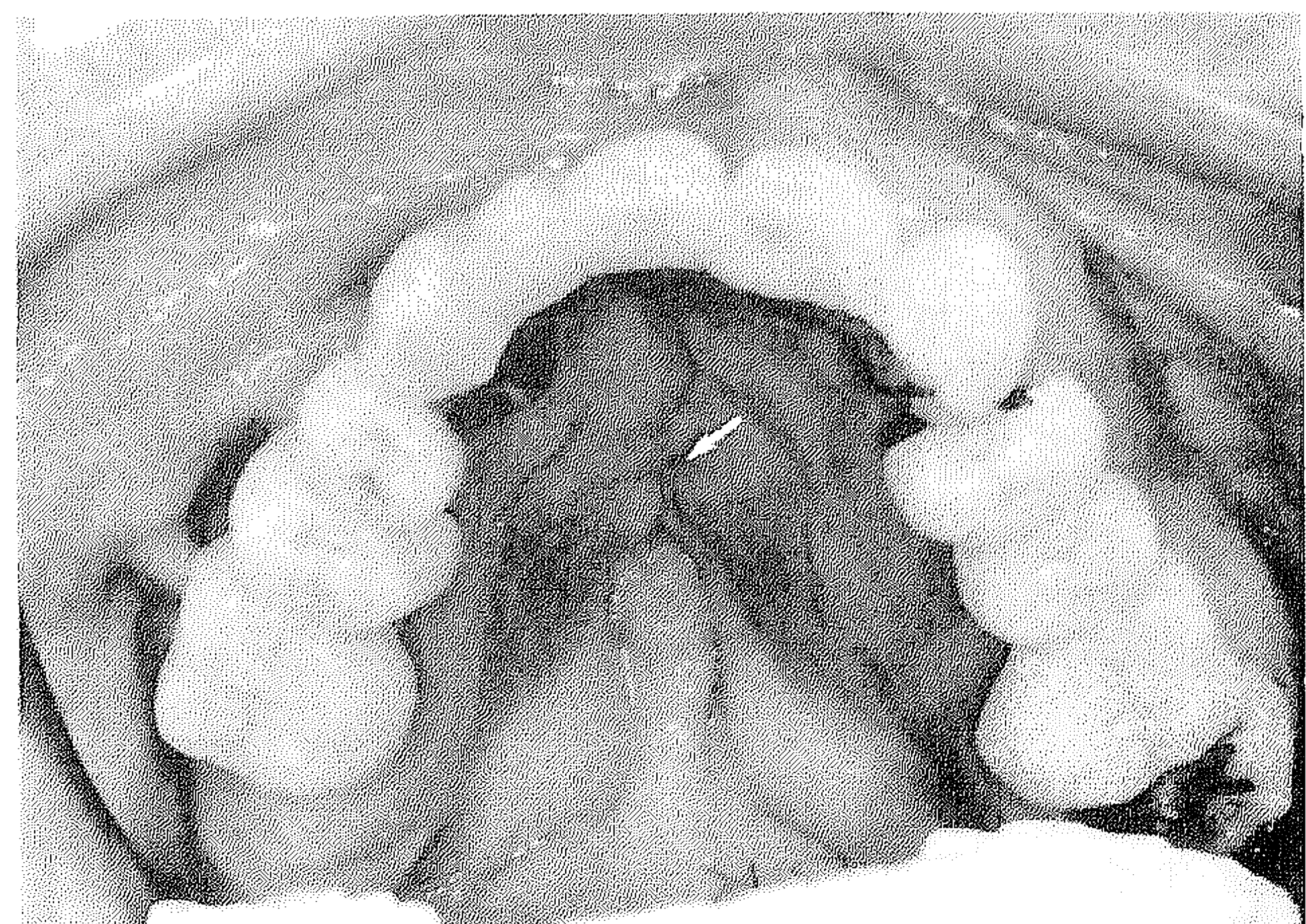


FIGURE 1 Palatal oronasal fistula (arrow) in 37-year-old male patient with right-sided UCLP after multiple operations before tissue expansion.

Dr. Philip A. Van Damme is Consultant maxillofacial surgeon and Lecturer at the Department of Cranio-Maxillo-Facial Surgery, University of Nijmegen, The Netherlands. Dr. Freihofer is Professor and Head of the Department of Cranio-Maxillo-Facial Surgery, member of the Nijmegen Cleft Palate-Craniofacial team at the University of Nijmegen, The Netherlands.

Submitted October 1994; Accepted December 1995.

Reprint requests: Dr. P. A. Van Damme, Department of Cranio-Maxillo-Facial Surgery, University of Nijmegen, St. Radboud, P.O. Box 9101, 6500 HB Nijmegen, The Netherlands.

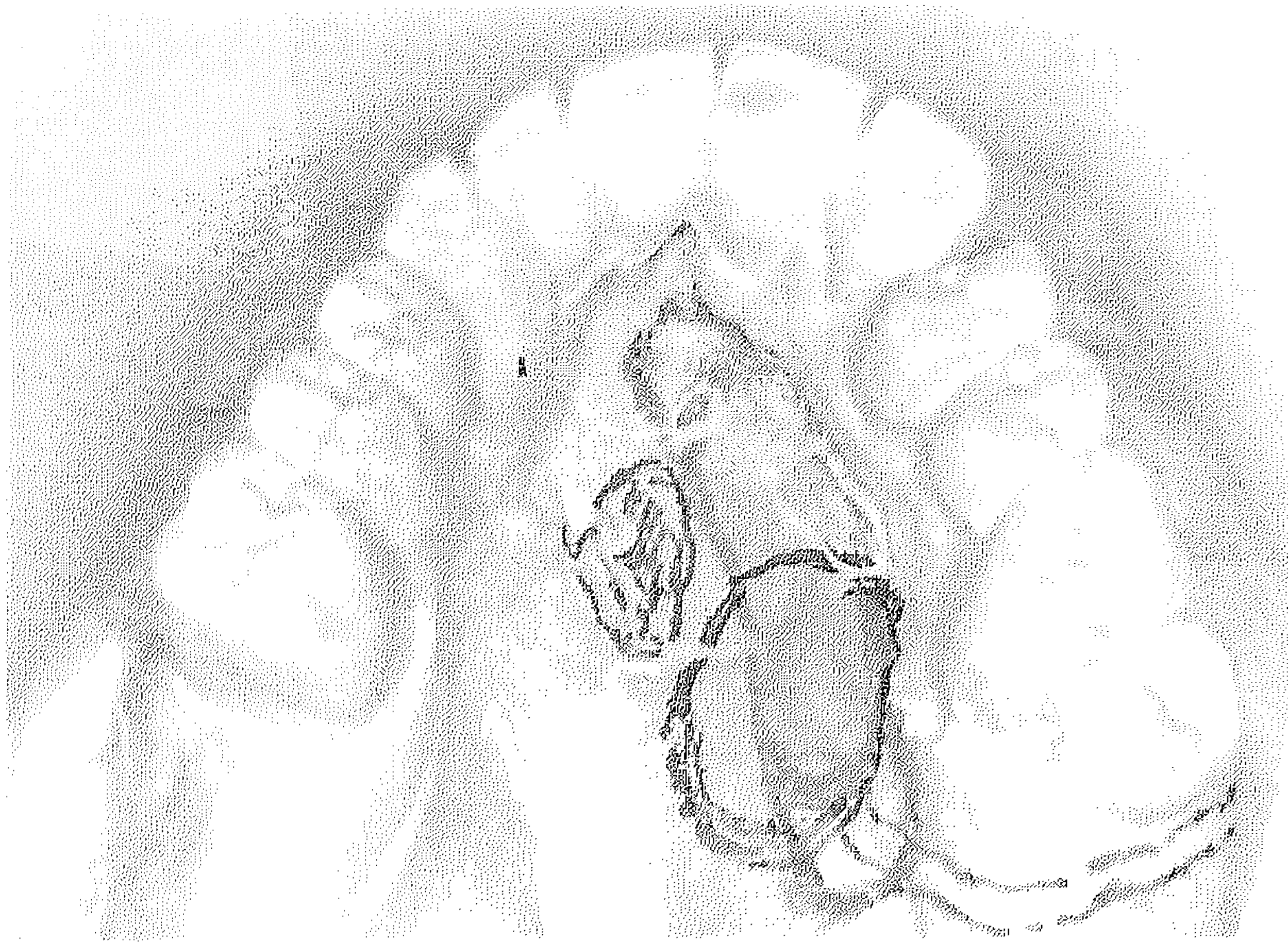


FIGURE 2 Study of tissue expansion feasibility with various standard tissue expanders on cast model. Different models and sizes were considered. The round (spherical) model was chosen with external filling tube.

unilateral Veau soft-tissue flap was created and fixed in place with Vicryl® 4-0 sutures after excision of the wound edges in the acceptor area. A gauze pack, impregnated with iodoform/Vaseline was used as a protective covering. Six days later, it was removed and the flap was vital, with no sign of dehiscence (Fig. 5).

Unfortunately, a small oronasal fistula developed 12 days after removal of the expander along the acceptor margin of the canine tooth. The patient noticed fluid in the nose after mouth rinsing, but he declined further surgical intervention. His general dental practitioner is making a palatal sealing plate/frame to correct this problem.

DISCUSSION

Several techniques have been used to close residual palatal oronasal fistula (Millard, 1980; Voorsmit and Fennis, 1992). The initial success rate varies from 36% to 69% and diminishes

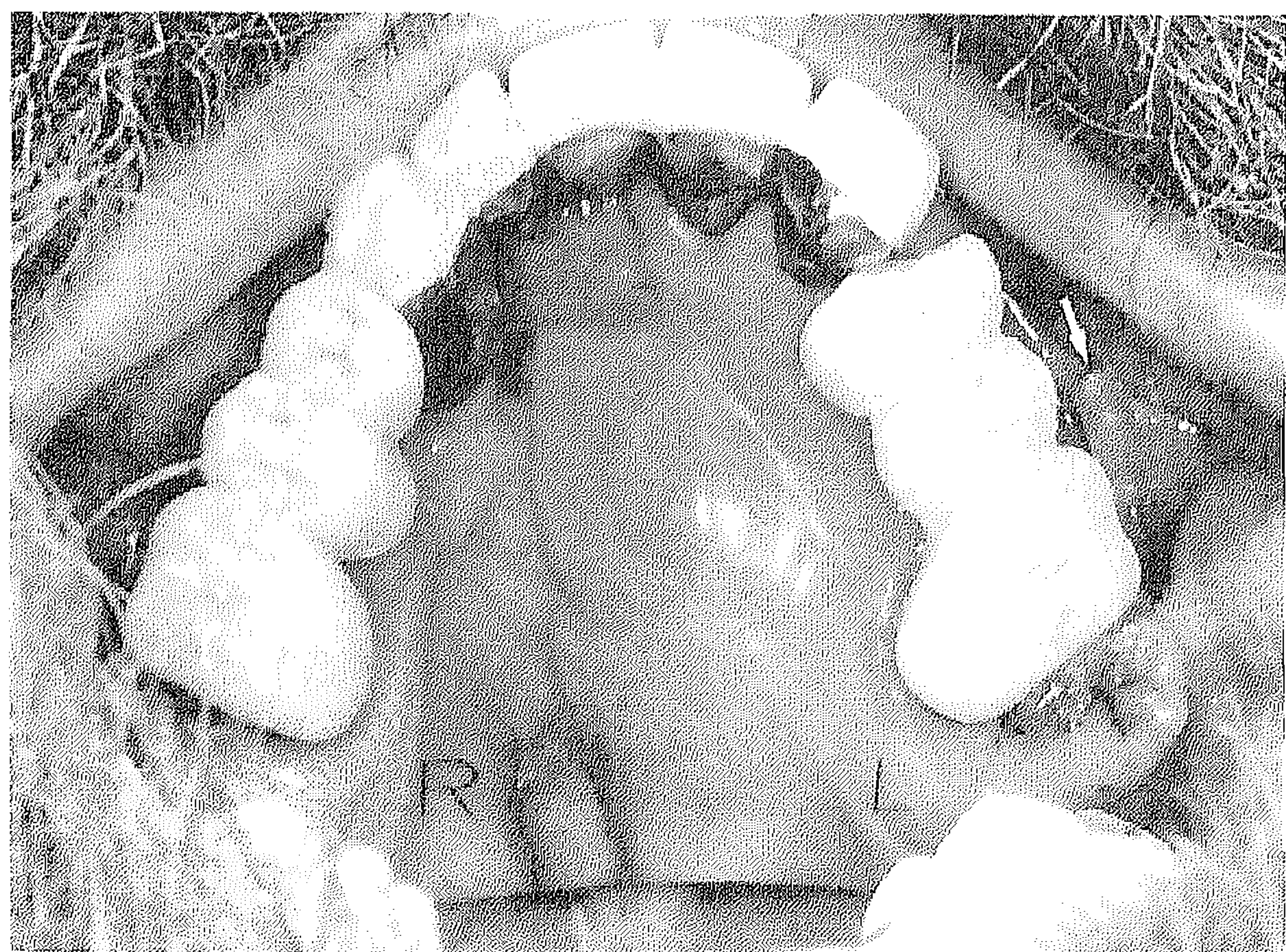


FIGURE 3 Palatal situation after eight inflations to a volume of 1.8 mL, just before removal of the expander. Note the remote filling tube at the buccal aspect of the molar teeth (arrow).

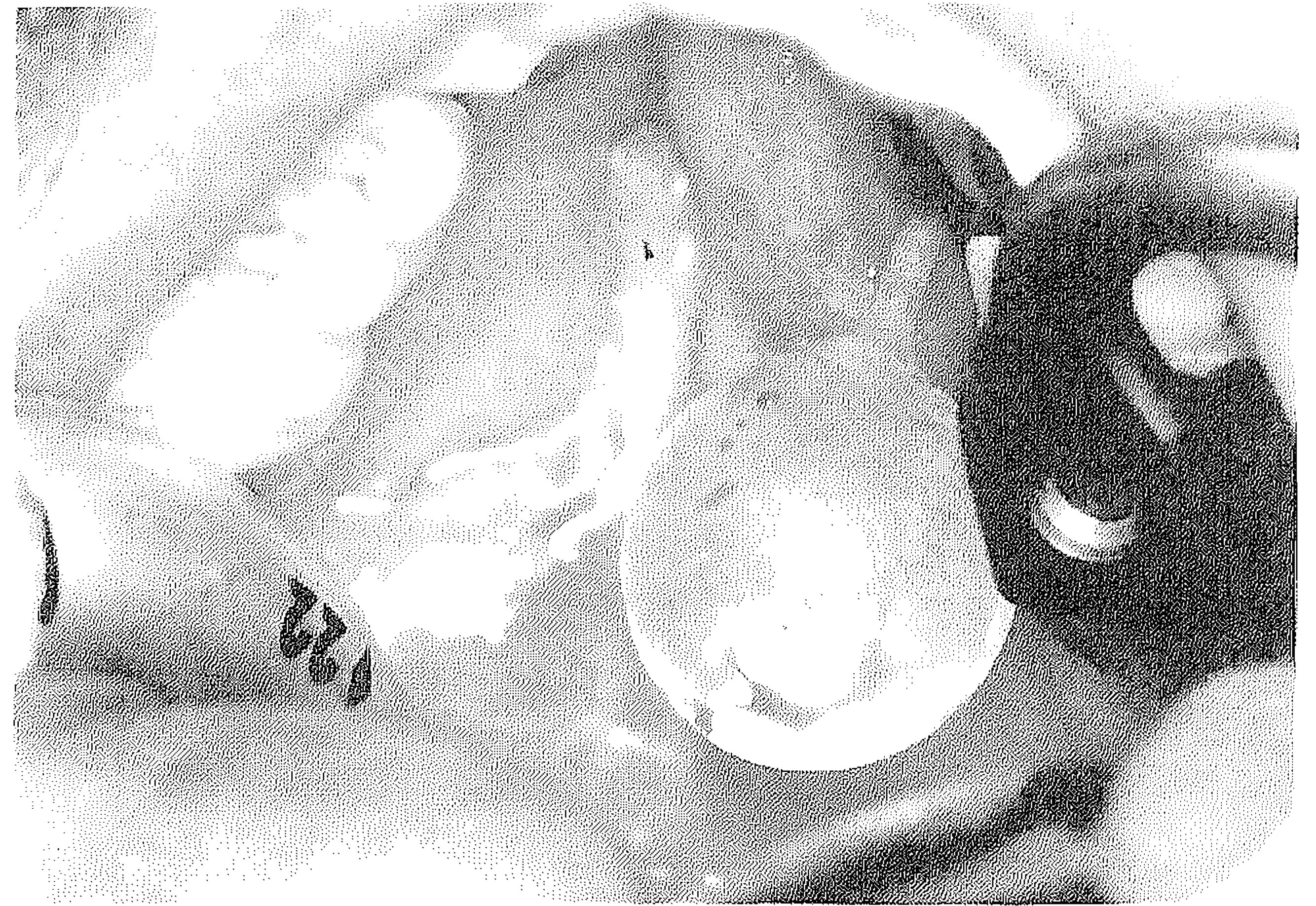

FIGURE 4 Removal of the inflated tissue expander via a lateral paramarginal incision and preparing of the unilateral Veau flap.

with the second, third, or further attempts. Whenever a two-stage procedure is chosen (e.g., a tongue-flap, Guerrerosantos and Altamirano, 1966), conventional palatal soft-tissue expansion should be considered as a realistic alternative.

However, this is a multistage procedure with serial inflations and two operations, with insertion and removal of the tissue expander and with mobilization and fixation of the flap. This is compensated by the fact that tongue movements are unrestricted, and taste and sensation of the tongue are not compromised.

In this case, the surgery and inflations were well tolerated, with little patient discomfort. There was also no pain during inflation or thereafter, and no mechanical hindrance to eating, despite the increasing volume of the expander. The overlying soft tissues became shiny and appeared to become thinner. After removal of the tissue expander, a fibrous capsule was seen. This seemed to restrict the mobility and pliability of the expanded tissue. Clinically, the vascularity of the expanded

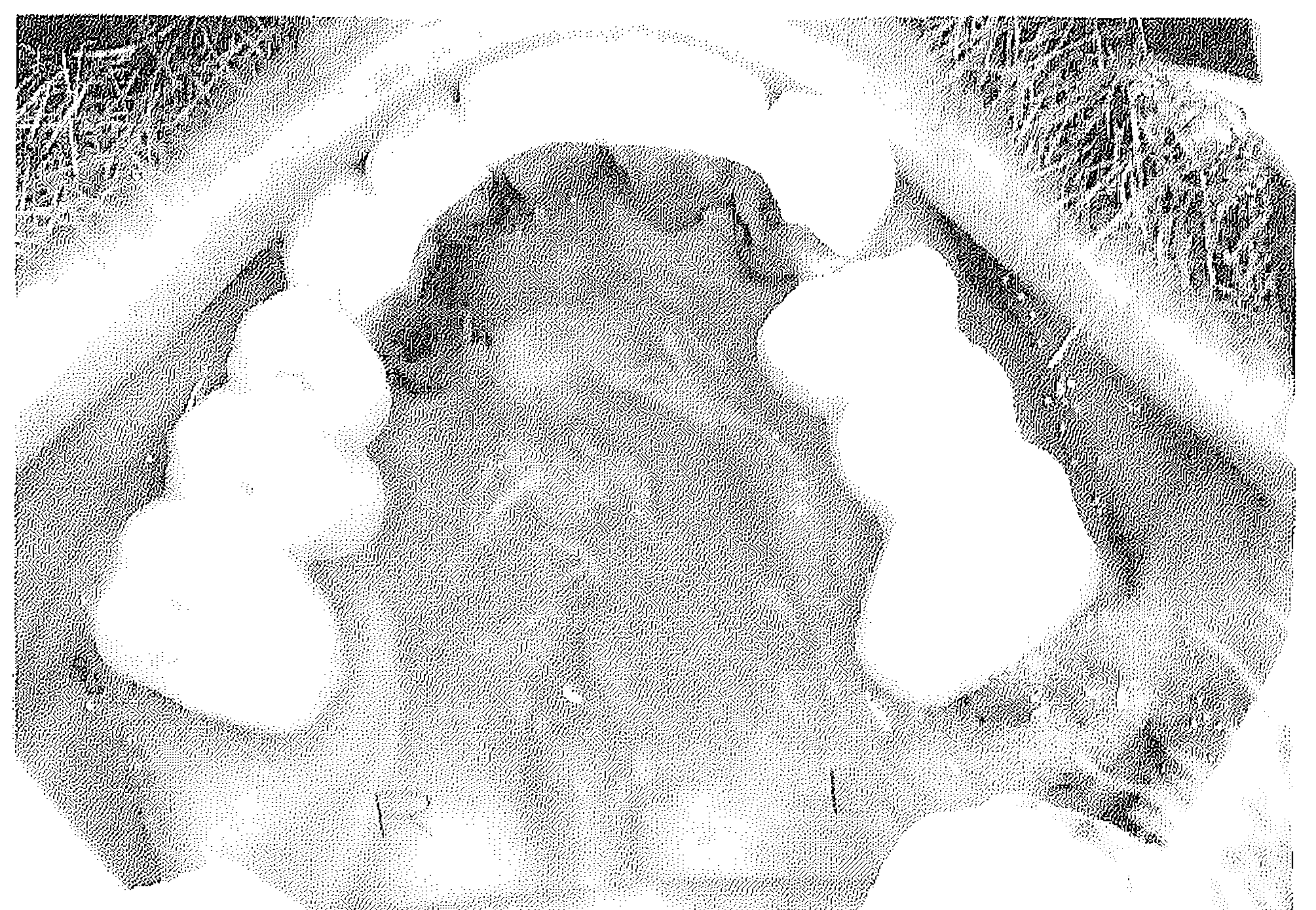

FIGURE 5 Palatal situation 6 days after expander removal and rotation of the unilateral Veau flap, just after withdrawal of the protective covering.

tissue was not compromised, in contrast to the recipient palatal site near the right canine tooth. The recurrent fistula developed in the area of the recipient wound edge, apparently, not to be considered so much a failure of the tissue expansion procedure, but rather caused mainly by the poor vascular condition of the recipient area. A more extended resection of the wound edges of the mucosa surrounding the defect might have avoided this complication. The patient's smoking (15 cigarettes per day), however, and the scarring from previous surgery may have reduced the chances of success.

In conclusion, conventional palatal mucoperiosteal soft-tissue expansion with standard expanders is a realistic option as an adjunct to recurrent cleft palate oronasal fistula closure. However, it does not guarantee independence of the quality and vascularity of the adjacent tissue at the recipient site.

Acknowledgments. We are indebted to Dr. P.C.M. de Wilde (Institute of Pathology) for the histologic analysis, Drs. A.E. Loewenthal and E.N. Robertson (Institute of Anesthesiology) for reviewing the English text, and our secretary, Petra van Veelen, for typing the manuscript.

REFERENCES

- ABRAMO AC, VIOLA JC, ANGELO AJ. Intraoperative rapid expansion in cleft palate repair. *Plast Reconstr Surg* 1993;91:441-445.
- DE MEY A, MALEVEZ C, LEJOUR M. Treatment of palatal fistula by expansion. *Br J Plast Surg* 1990;43:362-364.
- FREIHOFFER HPM, BORSTLAP WA, KUIJPERS-JAGTMAN AM, VOORSMIT RACA, VAN DAMME PA, HEIDBÜCHEL KLWM, BORSTLAD-ENGELS VMF. Timing and transplant materials for closure of alveolar clefts. *J Cranio-Maxillo Fac Surg* 1993;21:143-148.
- GUERREROSANTOS J, ALTAMIRANO JT. The use of lingual flaps in repair of fistulas of the hard palate. *Plast Reconstr Surg* 1966;38:123-128.
- LEW D, CLARK R, SHAHBAZIAN T. Use of a soft tissue expander in alveolar ridge augmentation: a preliminary report. *J Oral Maxillofac Surg* 1986;44:516-519.
- MILLARD DR JR. Cleft craft. The evolution of its surgery. III. Alveolar and palatal deformities. Boston: Little, Brown, 1980:809-865.
- VAN DAMME PA. Soft-tissue expansion in cleft palate surgery: an animal study. III International Tissue Expansion Symposium, October 1991, Sapporo, Japan.
- VAN DAMME PA. Palatal expansion: experimental and clinical. IV International Tissue Expansion Symposium, October 1993, Sao Paulo, Brazil.
- VAN DAMME PA. Soft-tissue expansion in cleft palate repair. *Plast Reconstr Surg* 1994;93:1307-1308.
- VOORSMIT RACA, FENNIS JPM. The buccal fat pad for closure of oro-nasal communications in cleft patients. *J Craniomaxillofac Surg* 1992;20(suppl 1):71.