

Clinical Study

Ultrasound Biomicroscopy Comparison of *Ab Interno* and *Ab Externo* Intraocular Lens Scleral Fixation

Lie Horiguchi,¹ Patricia Novita Garcia,^{1,2} Gustavo Ricci Malavazzi,^{1,2}
Norma Allemann,² and Rachel L. R. Gomes^{2,3}

¹Department of Ophthalmology, Irmandade da Santa Casa de Misericórdia de São Paulo, São Paulo, SP, Brazil

²Department of Ophthalmology, Federal University of São Paulo, São Paulo, SP, Brazil

³Hospital de Olhos Paulista, Rua Abílio Soares 218, 04005-000 São Paulo, SP, Brazil

Correspondence should be addressed to Rachel L. R. Gomes; rachelgomes@novais.md

Received 22 March 2016; Revised 1 May 2016; Accepted 4 May 2016

Academic Editor: Sang Beom Han

Copyright © 2016 Lie Horiguchi et al. This is an open access article distributed under the Creative Commons Attribution License, which permits unrestricted use, distribution, and reproduction in any medium, provided the original work is properly cited.

Purpose. To compare *ab interno* and *ab externo* scleral fixation of posterior chamber intraocular lenses (PCIOL) using ultrasound biomicroscopy (UBM). **Methods.** Randomized patients underwent *ab externo* or *ab interno* scleral fixation of a PCIOL. Ultrasound biomicroscopy was performed 3 to 6 months postoperatively, to determine PCIOL centration, IOL distance to the iris at 12, 3, 6, and 9 hours, and haptics placement in relation to the ciliary sulcus. **Results.** Fifteen patients were enrolled in the study. The *ab externo* technique was used in 7 eyes (46.6%) and the *ab interno* in 8 eyes (53.3%). In the *ab externo* technique, 14 haptics were located: 4 (28.57%) in the ciliary sulcus; 2 (14.28%) anterior to the sulcus; and 8 (57.14%) posterior to the sulcus, 6 in the ciliary body and 2 posterior to the ciliary body. In the *ab interno* group, 4 haptics (25.0%) were in the ciliary sulcus, 2 (12.50%) anterior to the sulcus, and 10 (75.0%) posterior to the sulcus, 4 in the ciliary body and 6 posterior to the ciliary body. **Conclusions.** *Ab externo* and *ab interno* scleral fixation techniques presented similar results in haptic placement. *Ab externo* technique presented higher vertical tilt when compared to the *ab interno*.

1. Introduction

Capsular bag is the standard of care for posterior chamber intraocular lens (IOL) placement. However, if the capsular support is absent, many techniques can be used to fixate the lens. *Ab interno* and *ab externo* are trans scleral suture techniques described to fixate a posterior chamber intraocular lens (PCIOL) [1–3]. Nevertheless, other techniques to fixate an IOL have been described, such as the no-suture technique that places the IOL haptic inside a scleral tunnel [4–6]. The aim of fixation is to position the haptics in the ciliary sulcus; however, these procedures are performed without direct visualization of the path of the needle.

Direct view techniques, guided by endoscopic probe, have greater rate of success in lens centration and correct haptic position [7, 8]. This technique is considered the gold standard; however, it requires particular equipment and specific training.

Ultrasound biomicroscopy (UBM) is an effective method to study the anterior segment and haptics placement behind the iris [9]. In this study we compared *ab interno* and *ab externo* techniques to evaluate both haptics position in relation to ciliary sulcus and the IOL distance from iris plane determining vertical and horizontal tilt using UBM.

2. Methods

This study was approved by the Santa Casa de São Paulo Ethics Committee. Patients scheduled for IOL implantation were randomly assigned to participate in one of the groups. Scleral fixation was performed after a complete ophthalmic examination. Surgery was scheduled according to patient's intraocular inflammation status. Patients with any sign of active inflammation or best-corrected visual acuity worse than 20/40 during the recruitment timeframe were excluded from this study. In one group, the IOL was fixated using

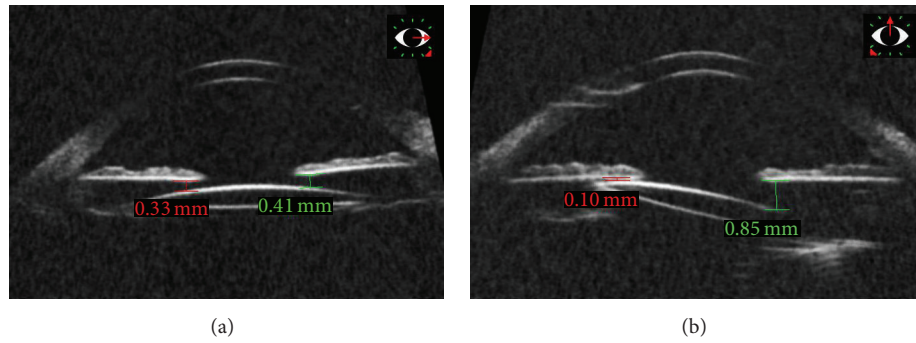


FIGURE 1: Ultrasound biomicroscopy of the left eye submitted to intraocular lens fixation using *ab externo* technique. (a) Horizontal plane showing good lens positioning; (b) vertical tilt of the IOL, lens placed more posteriorly in the superior meridian compared to the inferior meridian.

ab interno technique and in the other group, it was fixated using *ab externo*. All patients did not present adequate capsule support and were candidates for scleral IOL fixation surgery. Block randomization method was used to allocate patients in the treatment groups. All surgeries were performed by the same surgeon (RLRG).

In the *ab externo* surgical technique, two triangular scleral flaps were created at the 2 and 8 o'clock positions in the right eyes and at 4 and 10 o'clock positions in the left eyes. Next, a 26-gauge needle was used to penetrate the bed of the scleral flap at 2 or 4 o'clock position perpendicular to the sclera and 1.5 mm posterior to the limbus. At the same time, a straight needle attached to a 10-0 polypropylene suture was used to penetrate the bed of the opposite scleral flap perpendicular to the sclera. The suture was threaded into the barrel of a 26-gauge needle. An uninterrupted intersulcus suture was placed, extending across the posterior chamber. The anterior chamber was then opened and filled with 2% methylcellulose solution. The suture was pulled outside the eye, divided, and tied to the haptics of a single-piece (polymethylmethacrylate) IOL. The IOL was then placed in the posterior chamber.

In the *ab interno* technique, 2 scleral flaps were created using the same criteria as in the *ab externo* technique, and 2 straight needles with 10-0 polypropylene sutures were passed through a scleral incision parallel to the undersurface of the iris. Further steps were as in the *ab externo* technique.

Ultrasound biomicroscopy (UBM Vumax II, Sonomed Inc., NY, USA) was performed by the same examiner (PNG) under immersion technique (anesthetic drop instillation prior to the insertion of an immersion cup between the eyelids, filled with 10 mL saline solution) from 3 to 6 months postoperatively to detect the position of both haptics in relation to the ciliary sulcus and the position of the optics in relation to the iris, in different positions: 3, 6, 9, and 12 o'clock hours.

Statistical analysis was performed using Stata 14 software (StataCorp 2015, Stata Statistical Software, Version 23, College Station, Texas, USA). IOL tilt in vertical and horizontal planes was compared using variance analysis. IOL tilt was defined as the difference in millimeters in the position between measurements obtained in the vertical plane (12 and 6 hours) and the horizontal plane (3 and 9 hours). Null

represented a centered IOL. Positive values represented an anterior displacement of the IOL portion in relation to the perfect position, and negative values represented a posterior displacement of the IOL portion in relation to the null position. A p value less than 0.05 was considered statistically significant.

3. Results

A total of nineteen eyes of 19 patients were included in the study. Four patients were excluded for lost follow-up. Surgery was performed in 8 right eyes (OD) and 7 left eyes (OS). The mean age was 63.53 ± 20.8 years.

The *ab externo* technique was used in 7 eyes (57.8 ± 28.4 years, 3 females) and the *ab interno* in 8 eyes (68.5 ± 10.7 years, 5 females). Sixteen eyes were aphakic, 2 had subluxated lens, and 1 had dislocated IOL. Patient demographics and aphakia etiology are listed in Table 1. Figures 1 and 2 demonstrate the UBM images.

In the *ab externo* technique, 14 haptics were located using UBM: 4 (28.57%) in the ciliary sulcus, 2 (14.28%) anterior to the sulcus, and 8 (57.14%) posterior to the sulcus (6 were in the ciliary body and 2 were posterior to the ciliary body). In the *ab interno* group, 16 haptics were located using UBM: 4 (25.0%) in the ciliary sulcus, 2 (12.50%) anterior to the sulcus, and 10 (75.0%) posterior to the sulcus (4 were in the ciliary body and 6 were posterior to the ciliary body). Table 1 summarizes the demographics of the sample and the position of the haptics after the surgical intervention in each group (*ab externo* and *ab interno*) based on information from ultrasound biomicroscopy evaluation.

Tables 2 and 3 compare the findings of intraocular lens position ("tilt") considering each surgical technique, utilizing ultrasound biomicroscopy.

4. Discussion

The aim of scleral fixation techniques is to place the IOL haptics in the sulcus. The results of our study demonstrate that the *ab interno* technique is similar to the *ab externo* to assure the ciliary sulcus placement of the haptics. Four (28.57%) haptics of the *ab externo* technique patients were

TABLE 1: Demographics of the sample and cause and technique used for intraocular lens fixation and postoperative IOL positioning evaluated using ultrasound biomicroscopy.

Age (yrs)	Gender	Cause of inadequate capsular support	IOL fixation surgical technique	Postoperative UBM haptics position in relation to sulcus
77	F	After Phaco aphakia	<i>Ab interno</i>	(1) Posterior-pars plana (2) Sulcus
80	M	Decentered IOL	<i>Ab interno</i>	(1) Posterior-pars plana (2) Anterior
58	M	Unknown aphakia	<i>Ab interno</i>	(1) Posterior-ciliary body (2) Anterior
55	F	After Phaco aphakia	<i>Ab interno</i>	(1) Posterior-pars plana (2) Sulcus
82	F	After ICE aphakia	<i>Ab interno</i>	(1) Posterior-ciliary body (2) Posterior-ciliary body
73	F	After Phaco aphakia	<i>Ab interno</i>	(1) Posterior-pars plana (2) Posterior-pars plana
60	F	After Phaco aphakia	<i>Ab interno</i>	(1) Posterior-pars plana (2) Sulcus
63	M	Subluxated cataract	<i>Ab interno</i>	(1) Sulcus (2) Posterior-ciliary body
18	M	Subluxated cataract	<i>Ab externo</i>	(1) Posterior-ciliary body (2) Anterior
43	F	Subluxated cataract	<i>Ab externo</i>	(1) Sulcus (2) Sulcus
69	M	After ECE aphakia	<i>Ab externo</i>	(1) Sulcus (2) Posterior-ciliary body
82	F	After Phaco aphakia	<i>Ab externo</i>	(1) Sulcus (2) Posterior-pars plana
93	M	After Phaco aphakia	<i>Ab externo</i>	(1) Posterior-ciliary body (2) Posterior-ciliary body
72	M	After Phaco aphakia	<i>Ab externo</i>	(1) Posterior-ciliary Body (2) Anterior
28	F	Unknown aphakia	<i>Ab externo</i>	(1) Posterior-ciliary body (2) Posterior-pars plana

F: female; M: male; IOL: intraocular lens; ECE: extracapsular extraction; Phaco: phacoemulsification; ICE: intracapsular extraction; (1): haptic 1; (2): haptic 2.

TABLE 2: Intraocular lens position in relation to the iris (IOL tilt) in the horizontal plane (3 and 9 h), considering UBM findings.

	N	Mean (mm)	SD	95% confidence interval	
				Inferior	Superior
<i>Ab externo</i>	7	-0.12	0.1603	-0.4356	0.927
<i>Ab interno</i>	8	-0.04	0.1138	-0.2668	0.1793
Total	15	-0.08	0.0933	-0.2628	0.1028

SD: standard deviation; IOL: intraocular lens.

TABLE 3: Intraocular lens position in relation to the iris (IOL tilt) in the vertical plane (12 and 6 h), considering UBM findings.

	N	Mean (mm)	SD	95% confidence interval	
				Inferior	Superior
<i>Ab externo</i>	7	-0.36	0.1261	-0.6058	-0.1113
<i>Ab interno</i>	8	-0.2	0.1059	-0.4101	0.0051
Total	15	-0.28	0.0813	-0.4347	-0.116

SD: standard deviation; IOL: intraocular lens.

in the sulcus, compared to 4 haptics (25%) in the *ab interno* group. Using UBM, Kamal et al. reported that 29% of the haptics were in the ciliary sulcus with the *ab interno* technique and 31% with the *ab externo*, with no statistical significance [2].

The results may vary between studies. Pavlin et al. [10] found 38.24% of the haptics in the sulcus, 38.24% anterior to the sulcus, and 23.53% posterior to the sulcus after *ab externo* scleral fixation. Steiner et al. [11] reported 33%, 17%,

and 50%, respectively, versus 55%, 27.5%, and 17.5% reported by Sewelam et al. [12]. de Camargo Vianna Filho et al. [13] observed that there was a tendency of the haptics to be placed out of the sulcus in the *ab externo* technique (75%), and this was more evident at one side of the fixation. The current study presented similar results. In the *ab externo* group, 75.0% of the haptics were out of sulcus, and in the *ab interno* group, 71.42% of the haptics were out of sulcus.

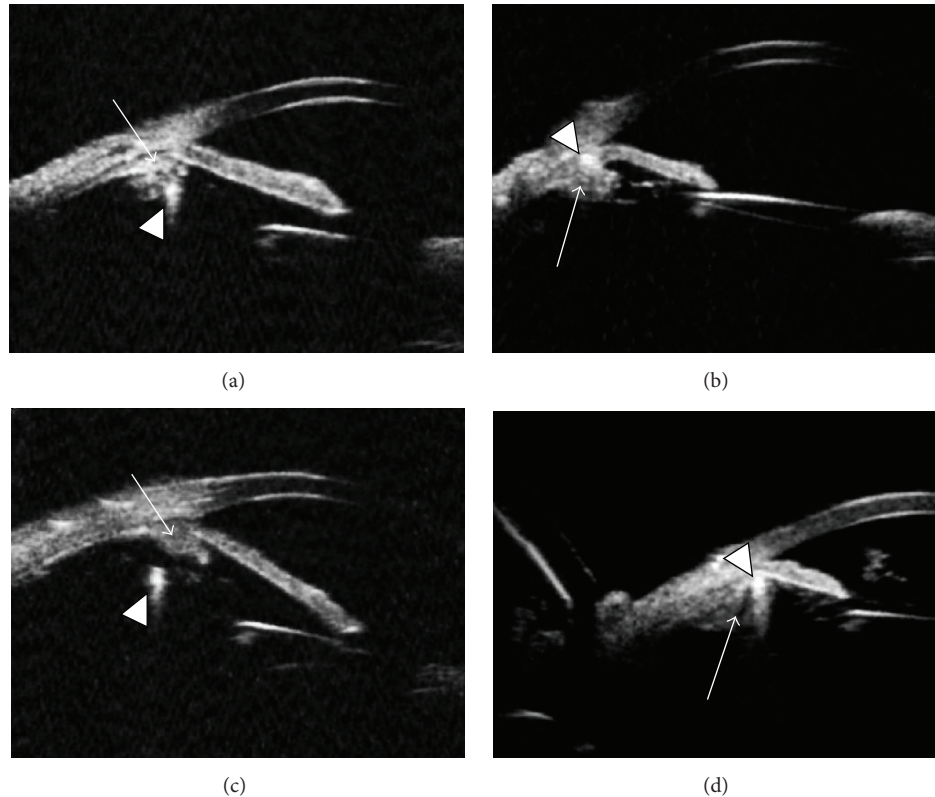


FIGURE 2: Ultrasound biomicroscopy of eyes submitted to intraocular lens fixation using UBM images. Arrows show the ciliary body, and arrow heads show the haptic. (a) *Ab externo*, haptic placed in the ciliary body; (b) *ab interno*, haptic in the sulcus; (c) *ab interno*, haptic posterior to the ciliary body; (d) haptic in the sulcus.

Ultrasound biomicroscopy was performed from 3 to 6 months postoperatively. After surgery, all cases had a centered and stable IOL positioned with no IOL-related iris complication. The IOL remained stable during the study follow-up period. In the literature, it is observed that the haptic position after a sutured scleral fixation does not change over time unless suture breakage occurs. The polypropylene suture showed stability for more than 4 years in the long-term evaluation [14, 15]. Price et al. observed late postoperative dislocation of PCIOL, 7 to 14 years after fixation. More studies will be important to determine the long-term results [16].

The variability of the results and haptic placement may be related to the surgeon personal technique and specific anatomic difficulties of each operated eye. We observed more surgical difficulties in the aphakic patients after phacoemulsification. Probably, the anatomy and the orbital conformation could have compromised the result of the primary surgery and might also have influenced the secondary IOL implantation.

Rau et al. [17] evaluated the PCIOL tilt in reference to the iris plane using UBM. They observed 18.1% tilted PCIOL intentionally implanted in the ciliary sulcus. The evaluation of IOL tilt was different in studies. Vasavada et al. [18] and Loya et al. [19] also studied tilt with the same imaging method. We observed that there was a significant vertical tilt in the *ab externo* group and there was no horizontal tilt in our sample.

Hayashi et al. observed significantly greater tilt in the eyes that underwent suture scleral fixation when compared to other techniques [20].

Ab externo and *ab interno* scleral fixation techniques presented similar results in haptic placement in the group examined. *Ab externo* technique resulted in a higher vertical IOL tilt when compared to the *ab interno* technique.

Disclosure

This research was done in Santa Casa de São Paulo and Federal University of São Paulo.

Competing Interests

Rachel L. R. Gomes is a researcher supported by the CAPES Foundation, Ministry of Health, Brazil. The other authors did not receive any grant or funding support for this work.

References

- [1] E. Can, M. Reşat Başaran, and A. Gül, "Scleral fixation of a single-piece multifocal intraocular lens," *European Journal of Ophthalmology*, vol. 23, no. 2, pp. 249–251, 2013.
- [2] A. M. Kamal, M. Hanafy, A. Ehsan, and R. H. Tomerak, "Ultrasound biomicroscopy comparison of *ab interno* and *ab externo* scleral fixation of posterior chamber intraocular lenses,"

- Journal of Cataract and Refractive Surgery*, vol. 35, no. 5, pp. 881–884, 2009.
- [3] M. Seki, S. Yamamoto, H. Abe, and T. Fukuchi, “Modified ab externo method for introducing 2 polypropylene loops for scleral suture fixation of intraocular lenses,” *Journal of Cataract and Refractive Surgery*, vol. 39, no. 9, pp. 1291–1296, 2013.
 - [4] Y.-W. Cho, I.-Y. Chung, J.-M. Yoo, and S.-J. Kim, “Sutureless intrascleral pocket technique of transscleral fixation of intraocular lens in previous vitrectomized eyes,” *Korean Journal of Ophthalmology*, vol. 28, no. 2, pp. 181–185, 2014.
 - [5] A. I. Moawad and A. A. Ghanem, “One-haptic fixation of posterior chamber intraocular lenses without scleral flaps,” *Journal of Ophthalmology*, vol. 2012, Article ID 891839, 5 pages, 2012.
 - [6] J. Nadal, B. Kudsieh, and R. P. Casaroli-Marano, “Scleral fixation of posteriorly dislocated intraocular lenses by 23-gauge vitrectomy without anterior segment approach,” *Journal of Ophthalmology*, vol. 2015, Article ID 391619, 6 pages, 2015.
 - [7] C. Althaus and R. Sundmacher, “Endoscopically controlled improvement of transscleral suture fixation of posterior chamber intraocular lenses in the ciliary sulcus,” *Ophthalmologie*, vol. 90, no. 4, pp. 317–324, 1993.
 - [8] T. W. Olsen and J. T. Pribila, “Pars plana vitrectomy with endoscope-guided sutured posterior chamber intraocular lens implantation in children and adults,” *American Journal of Ophthalmology*, vol. 151, no. 2, pp. 287–296.e2, 2011.
 - [9] S. Gao, T. Qin, S. Wang, and Y. Lu, “Sulcus fixation of foldable intraocular lenses guided by ultrasound biomicroscopy,” *Journal of Ophthalmology*, vol. 2015, Article ID 520418, 4 pages, 2015.
 - [10] C. J. Pavlin, D. Rootman, S. Arshinoff, K. Harasiewicz, and F. S. Foster, “Determination of haptic position of transsclerally fixated posterior chamber intraocular lenses by ultrasound biomicroscopy,” *Journal of Cataract and Refractive Surgery*, vol. 19, no. 5, pp. 573–577, 1993.
 - [11] A. Steiner, U. H. Steinhorst, M. Steiner, M. Theischen, and R. Winter, “Ultrasound biomicroscopy (UBM) for the localization of artificial lens haptics after transscleral suture fixation,” *Der Ophthalmologe*, vol. 94, no. 1, pp. 41–44, 1997.
 - [12] A. Sewelam, A. M. Ismail, and H. El Serogy, “Ultrasound biomicroscopy of haptic position after transscleral fixation of posterior chamber intraocular lenses,” *Journal of Cataract and Refractive Surgery*, vol. 27, no. 9, pp. 1418–1422, 2001.
 - [13] R. de Camargo Vianna Filho, L. De Freitas, N. Allemann, and A. L. H. de Lima, “Biomicroscopia ultra-sônica na avaliação da posição das lentes intra-oculares em uma técnica de fixação escleral,” *Arquivos Brasileiros de Oftalmologia*, vol. 63, no. 5, p. 349, 2000.
 - [14] R. Asadi and A. Kheirkhah, “Long-term results of scleral fixation of posterior chamber intraocular lenses in children,” *Ophthalmology*, vol. 115, no. 1, pp. 67–72, 2008.
 - [15] B. J. Vote, P. Tranos, C. Bunce, D. G. Charteris, and L. Da Cruz, “Long-term outcome of combined pars plana vitrectomy and scleral fixated sutured posterior chamber intraocular lens implantation,” *American Journal of Ophthalmology*, vol. 141, no. 2, pp. 308–312.e1, 2006.
 - [16] M. O. Price, F. W. Price Jr., L. Werner, C. Berlie, and N. Mamalis, “Late dislocation of scleral-sutured posterior chamber intraocular lenses,” *Journal of Cataract and Refractive Surgery*, vol. 31, no. 7, pp. 1320–1326, 2005.
 - [17] R. Rau, C. R. Santana, A. A. G. Martinez, A. L. D. F. Silva, and N. Allemann, “Positioning of intraocular lens haptics intentionally implanted in the ciliary sulcus by ultrasound biomicroscopy,” *Arquivos Brasileiros de Oftalmologia*, vol. 76, no. 3, pp. 147–151, 2013.
 - [18] A. R. Vasavada, S. M. Raj, S. Karve, V. Vasavada, V. Vasavada, and P. Theoulakis, “Retrospective ultrasound biomicroscopic analysis of single-piece sulcus-fixated acrylic intraocular lenses,” *Journal of Cataract and Refractive Surgery*, vol. 36, no. 5, pp. 771–777, 2010.
 - [19] N. Loya, H. Lichter, D. Barash, N. Goldenberg-Cohen, E. Strassmann, and D. Weinberger, “Posterior chamber intraocular lens implantation after capsular tear: ultrasound biomicroscopy evaluation,” *Journal of Cataract and Refractive Surgery*, vol. 27, no. 9, pp. 1423–1427, 2001.
 - [20] K. Hayashi, H. Hayashi, F. Nakao, and F. Hayashi, “Intraocular lens tilt and decentration, anterior chamber depth, and refractive error after trans-scleral suture fixation surgery,” *Ophthalmology*, vol. 106, no. 5, pp. 878–882, 1999.



Hindawi
Submit your manuscripts at
<http://www.hindawi.com>

