

**DESCRIPTION OF DENTAL CARIES AND EFFECTS OF FOODS  
ON TOOTH DESTRUCTION IN SKULLS OF PAWON MAN**  
*Deskripsi Karies Gigi dan Pengaruh Makanan pada Kerusakan Gigi  
pada Kerangka Manusia Pawon*

**Amalina Ahmad<sup>1</sup>, Dudi Aripin<sup>2</sup>, Lutfi Yondri<sup>3</sup>, Warta Dewi<sup>4</sup>, Fahmi Oscandar<sup>5</sup>**

<sup>1</sup>Fakultas Kedokteran Gigi, Universitas Padjadjaran  
E-mail: [amalinaahmad6161fans@gmail.com](mailto:amalinaahmad6161fans@gmail.com)

<sup>2</sup>Departemen Konservasi Gigi, Fakultas Kedokteran Gigi Universitas Padjadjaran  
E-mail: [dudi\\_fkg2006@yahoo.com](mailto:dudi_fkg2006@yahoo.com),

<sup>3</sup> Balai Arkeologi Bandung  
E-mail: [yondrilutfi@gmail.com](mailto:yondrilutfi@gmail.com)

<sup>4</sup>Departemen Oral Biologi, Fakultas Kedokteran Gigi Universitas Padjadjaran  
E-mail: [warta.dewi@fkg.unpad.ac.id](mailto:warta.dewi@fkg.unpad.ac.id),

<sup>5</sup>Departemen Oral Radiologi, Fakultas Kedokteran Gigi Universitas Padjadjaran  
E-mail: [fahmi.oscandar@fkg.unpad.ac.id](mailto:fahmi.oscandar@fkg.unpad.ac.id)

Naskah diterima 14 Juli 2017 — Revisi terakhir 2 November 2017

Disetujui terbit 28 November 2017 — Tersedia secara *online* 30 November 2017

**Abstrak**

Kerangka Manusia Pawon yang hidup di zaman Mesolitik berusia 5,660±170 BP - 9,500±200 BP telah digunakan sebagai objek penelitian Forensik Odontologi. Namun, belum ada penelitian pada karies gigi Manusia Pawon. Tujuan dari penelitian ini adalah untuk menggambarkan karies gigi pada tengkorak Manusia Pawon. Jenis penelitian adalah deskriptif ditujukan untuk mengungkap permasalahan terkait dampak makanan terhadap kerusakan gigi pada Manusia Pawon. Pengambilan sampel menggunakan metode purposive sampling. Sampel adalah gigi geligi dari empat kerangka Manusia Pawon. Penelitian ini dilakukan dengan menggunakan metode pemeriksaan klinis. Hasil dari pemeriksaan klinis menunjukkan bahwa 12.5% dari sampel 32 gigi tengkorak Manusia Pawon I, III, IV dan V mengalami karies gigi. Pemeriksaan klinis menunjukkan adanya karies gigi dalam sampel Manusia Pawon III gigi molar tiga permanen mandibula dari regio 4(48) di daerah lingual dan lesi bukal pada gigi permanen molar tiga dari region 3 (38). Pada Manusia Pawon IV, ada lesi lingual pada gigi permanen bawah molar kedua (37) dan permanen kiri bawah molar ketiga (38). Semua lesi yang terdeteksi adalah hanya dalam enamel yang kode 1 menurut kode ICDAS. Kesimpulannya, karies gigi ditemukan hanya sedikit di tengkorak manusia Pawon karena diet mereka yang rendah gula, dari buah-buahan dan tanaman yang kaya gula (gula fruktosa). Konsumsi makanan keras dan bukti keberadaan gigi binatang dan moluska telah memberikan kontribusi terhadap persentase atrisi gigi yang lebih tinggi dibandingkan karies gigi.

**Kata kunci:** karies gigi, klinis, manusia Pawon

### **Abstract**

*The skeleton of Pawon Man's that lived in Mesolithic era aged 5,660±170 BP - 9,500± 200 BP (Before Present) years before Christ (BC) has been used for forensic odontology research. However, there has not been any research on dental caries of Pawon Man. The aim of this research was to describe the dental caries in skulls of Pawon Man. The type of the research was descriptive by using purposive sampling. The samples were from four Pawon Man skulls and their teeth. The research was conducted by using clinical examination. All aspects were recorded, collected and presented in tabular form. The result shows that 12.5% of the samples from 32 teeth of skulls of Pawon Man I, III, IV and V had experienced dental caries. Clinical examination shows presence of dental caries in samples of Pawon Man III of permanent mandibular third molar tooth of region 4(48) in lingual area and buccal lesion of lower left third molar (38). In Pawon IV, lingual lesion of lower left permanent second molar (37) and in lower left permanent third molar (38). All lesions are only in enamel which is code 1 according to ICDAS code. In conclusion, the dental caries in skulls of Pawon Man was low due to their low sugar diets from fruits and sugar-rich plants (fructose sugars). Consumption of hard foods and evidence of presence of animal teeth and mollusks had contributed to the higher percentage of dental attrition compared to dental caries.*

**Keywords:** dental caries, clinical, Pawon man

### **INTRODUCTION**

From ancient age till now, dental caries has been the most major public health problem in adults and children. Dental caries is a pathological process of demineralization and localized destruction of the teeth which is produced by plaque microorganisms (*Streptococcus mutans*, *Lactobacillus spp.* and *Actinomyces spp.*) as they metabolized dietary sucrose (glucose and fructose) into lactic acids (Trinkaus, E. Hillson, S W, Franciscus, R G, Holiday, 2006). Initial process of tooth enamel demineralization will be followed by remineralization, and teeth cavitation start to occur when the former process overtakes the latter. The infection will progress to dentine, with the pulp becoming inflamed and then become necrotic (Bagramanian, Robert A. Garcia-Gody, Franklin. Anthony, 2009).

Forensic dentistry (or forensic odontology) is the study and practice of aspects of dentistry that are relevant to legal

problems (Trinkaus, 1995). It comprises of major areas of interest in identification and description of found human remains (skulls or fossils), identification in mass fatalities, assessment of bite mark injuries, assessment of cases of abuse (such as child, spouse or elder abuse), civil cases involving dental malpractice and negligence and age estimation (Lebel, S. Trinkaus, 2001).

Pawon Cave had been inhabited by Pawon Man and based on the shape of skulls found, Pawon Man is believed originated from Mongoloid race. Since 2003 until 2004, the Bandung Archaeological Center has conducted six archaeological excavations and among discoveries are four skeletons of Pawon Man located at different stratigraphic layers, with chronologically ranges from 5600 to 9500 years Before Christ (Yondri, 2005). The results of the discovery shows the Pawon prehistoric cave had various equipments in the form of stone tools, bone tools, molluscs, obsidian stone

and remaining of human skeletons also animal bones in the past. Then the digging continued and they found human skeletons of Pawon who were much older than the age of the human skeleton's Pawon which had been found previously 5,660±170 BP - 9,500± 200 BP. These skeletons were found in the deeper layers of stratigraphy (Yondri, 2005).

This research aims to know about the description of dental caries in skulls of Pawon Man as well as to correlate the diet patterns and socio-cultural of Pawon Man.

The methodology for this preliminary research is descriptive research with purposive sampling method and samples were taken from four remaining skulls collected from Pawon Cave, which is located in the village of Mount Masigit, Cipatat District, West Bandung regency. Samples are taken by purposive sampling from four skulls of Pawon Man, from three mandibular samples (Pawon 1, Pawon 3 and Pawon 4) and two maxillary samples (Pawon 3, and Pawon 5).








Occlusal Protocol ***							
ICDAS code	0	1	2	3	4	5	6
							
Definitions	Sound tooth surface; no caries change after air drying (5 sec); or hypoplasia, wear, erosion, and other noncaries phenomena	First visual change in enamel; seen only after air drying or colored change "thin" limited to the confines of the pit and fissure area	Distinct visual change in enamel; seen when wet, white or colored, "wider" than the fissure/fossa	Localized enamel breakdown with no visible dentin or underlying shadow; discontinuity of surface enamel, widening of fissure	Underlying dark shadow from dentin, with or without localized enamel breakdown	Distinct cavity with visible dentin; frank cavitation involving less than half of a tooth surface	Extensive distinct cavity with dentin; cavity is deep and wide involving more than half of the tooth
Histologic depth		Lesion depth in P/F was 90% in the outer enamel with only 10% into dentin	Lesion depth in P/F was 50% inner enamel and 50% into the outer 1/3 dentin	Lesion depth in P/F with 77% in dentin	Lesion depth in P/F with 88% into dentin	Lesion depth in P/F with 100% in dentin	Lesion depth in P/F 100% reaching inner 1/3 dentin
Sealant/restoration Recommendation for low risk	Sealant optional DIAGNOdent may be helpful	Sealant optional DIAGNOdent may be helpful	Sealant optional or caries biopsy if DIAGNOdent is 20-30	Sealant or minimally invasive restoration needed	Minimally invasive restoration	Minimally invasive restoration	Minimally invasive restoration
Sealant/restoration Recommendation for moderate risk	Sealant optional DIAGNOdent may be helpful	Sealant recommended DIAGNOdent may be helpful	Sealant optional or caries biopsy if DIAGNOdent is 20-30	Sealant or minimally invasive restoration needed	Minimally invasive restoration	Minimally invasive restoration	Minimally invasive restoration
Sealant/restoration Recommendation for high risk *	Sealant recommended DIAGNOdent may be helpful	Sealant recommended DIAGNOdent may be helpful	Sealant optional or caries biopsy if DIAGNOdent is 20-30	Sealant or minimally invasive restoration needed	Minimally invasive restoration	Minimally invasive restoration	Minimally invasive restoration
Sealant/restoration Recommendation for extreme risk **	Sealant recommended DIAGNOdent may be helpful	Sealant recommended DIAGNOdent may be helpful	Sealant optional or caries biopsy if DIAGNOdent is 20-30	Sealant or minimally invasive restoration needed	Minimally invasive restoration	Minimally invasive restoration	Minimally invasive restoration
* Patients with one (or more) cavitated lesion(s) are high-risk patients. ** Patients with one (or more) cavitated lesion(s) and xerostomia are extreme-risk patients.							
*** All sealants and restorations to be done with a minimally invasive philosophy in mind. Sealants are defined as confined to enamel. Restoration is defined as in dentin. A two-surface restoration is defined as a preparation that has one part of the preparation in dentin and the preparation extends to a second surface (note: the second surface does not have to be in dentin). A sealant can be either resin-based or glass ionomer. Resin-based sealants should have the most conservatively prepared fissures for proper bonding. Glass ionomer should be considered where the enamel is immature, or where fissure preparation is not desired, or where rubber dam isolation is not possible. Patients should be given a choice in material selection.							

Figure 1. The International Caries Detection and Assessment System (ICDAS) showing visual caries detection (Heymann, 2012)

Dental caries can be described from colour changes, tooth surface texture and tactile sensation when an explorer is used judiciously to detect surface roughness by gently stroking across the tooth surface. The occlusal surface of dental caries appears chalkiness or cavitation, forming the fissure or pit, is seen brown-gray discoloration. These visual techniques of examining teeth are then translated into codes used in the International Codes Detection and Assessment System (ICDAS) (Rickne, C Scheid. Gabriela, 2011).

According to figure 1, the International Caries Detection and Assessment System (ICDAS) detection codes for coronal caries range from 0 to 6 depending on the severity of the lesion. There are minor variations between the visual signs associated with each code depending on a number of factors, including the surface characteristics; whether there are adjacent teeth present and also whether or not the caries are associated with a restoration or sealant. Therefore, the teeth of the skeletons of Pawon Man were examined by using ICDAS code for pits and fissures and smooth surfaces (mesial or distal).

## RESULTS BASED ON ASPECTS

### Pits and Fissure Caries

- **Code 0:** *Sound tooth surface:* There should be no evidence of caries. Surfaces with developmental defects such as enamel hyperplasia, fluorosis, tooth wear (attrition, abrasion, and erosion), and extrinsic or intrinsic stains will be recorded as sound. The examiner should also score as sound, a surface with multiple stained fissures if such a condition is seen in other pits and fissures.

- **Code 1:** *First visual change in enamel:*

When seen wet there is no evidence of any change in color attributable to carious activity, but after prolonged air drying, a carious opacity or discoloration (white or brown lesion) is visible, which is not consistent with the clinical appearance of sound enamel, or when there is a change of color due to caries it is not consistent with the clinical appearance of sound enamel and is limited to the confines of the pit and fissure area (whether seen wet or dry). The appearance of these carious areas is not consistent with that of stained pits and fissures as defined in code 0.

- **Code 2:** *Distinct visual change in enamel:*

The tooth must be viewed wet. When wet there is a carious opacity (white spot lesion) and/or brown carious discoloration that is wider than the natural fissure/fossa, which is not consistent with the clinical appearance of sound enamel.

- **Code 3:** *Localized enamel breakdown due to caries with no visible dentin or underlying shadow:*

The tooth viewed wet may have a clear carious opacity (white spot lesion) and/or brown carious discoloration that is wider than the natural fissure/fossa, which is not consistent with the clinical appearance of sound enamel. Once dried, there is carious loss of tooth structure at the entrance to, or within the pit or fissure/fossa. This will be seen visually as evidence of demineralization at the entrance to or within the fissure or pit, and although the pit or fissure may appear

substantially and unnaturally wider than normal, the dentin is not visible in the walls or base of the cavity/discontinuity.

If in doubt, or to confirm the visual assessment, the WHO/CPI/PSR probe can be used gently across the tooth surface, to confirm the presence of a cavity apparently confined to the enamel. This is achieved by sliding the ball end along the suspect pit or fissure and a limited discontinuity is detected if the ball drops into the surface of the enamel cavity/discontinuity.

- **Code 4:** *An underlying dark shadow from dentin with or without localized enamel breakdown:*

This lesion appears as a shadow of discolored dentin visible through an apparently intact enamel surface, which may or may not show signs of localized breakdown. The shadow appearance is often seen more easily when the tooth is wet. The darkened area is an intrinsic shadow that may appear gray, blue or brown. The shadow must clearly represent caries that started on the tooth surface being evaluated. If in the opinion of the examiner, the carious lesion started on an adjacent surface and there was no evidence of any caries on the surface being scored, then the surface should be coded "0". Codes 3 and 4, histologically may vary in depth with one being deeper than the other and vice versa.

- **Code 5:** *Distinct cavity with visible dentin:*

Cavitation in opaque or discolored enamel, exposing the dentin beneath. The tooth viewed wet may have

darkening of the dentin visible through the enamel. Once dried, there is visual evidence of loss of tooth structure at the entrance to or within the pit or fissure - frank cavitation. There is visual evidence of demineralization (opaque (white), brown or dark brown walls) at the entrance to or within the pit or fissure and in the examiner's judgment, the dentin is exposed.

- **Code 6:** *Extensive distinct cavity with visible dentin:*

There is obvious loss of tooth structure, the cavity is both deep and wide, and the dentin is clearly visible on the walls and at the base. An extensive cavity involves at least half of a tooth surface or possibly reaches the pulp.

### Smooth Surface Caries

This requires visual inspection from the occlusal, buccal, and lingual directions.

- **Code 0:** *Sound tooth surface:*

There should be no evidence of caries. Surfaces with developmental defects such as enamel hyperplasia, fluorosis, tooth wear (attrition, abrasion and erosion), and extrinsic or intrinsic stains will be recorded as sound.

- **Code 1:** *First visual change in enamel:*

When seen wet there is no evidence of any change in color attributable to carious activity, but after prolonged air drying a carious opacity (white or brown lesion) is visible that is not consistent with the clinical appearance of sound enamel. This will be seen from the buccal or lingual surface.

- **Code 2:** *Distinct visual change in enamel when viewed wet:*

There is a carious opacity or discoloration (white or brown lesion) that is not consistent with the clinical appearance of sound enamel. This lesion may be seen directly when viewed from the buccal or lingual direction. In addition, when viewed from the occlusal direction, this opacity or discoloration may be seen as a shadow confined to enamel, seen through the marginal ridge.

- **Code 3:** *Initial breakdown in enamel due to caries with no visible dentin:*

Once dried for approximately five seconds there is distinct loss of enamel integrity, viewed from the buccal or lingual direction.

- **Code 4:** *Underlying dark shadow from dentin with or without localized enamel breakdown:*

This lesion appears as a shadow of discolored dentin visible through an apparently intact marginal ridge, buccal or lingual walls of enamel. This appearance is often seen more easily when the tooth is wet. The darkened area is an intrinsic shadow which may appear as gray, blue or brown.

- **Code 5:** *Distinct cavity with visible dentin:*

Cavitation in opaque or discolored enamel (white or brown) with exposed dentin in the examiner’s judgment. I

- **Code 6:** *Extensive distinct cavity with visible dentin:*

Obvious loss of tooth structure, the extensive cavity may be deep or wide and dentin is clearly visible on both the walls and at the base. The marginal ridge may or may not be present. An extensive cavity involves at least half of a tooth surface or possibly reaching the pulp.

**DISCUSSION**

The results from the clinical examinations of maxilla and mandible of Pawon Man showed data as follows:

**Pawon Man III**

- 1) Presence of dental caries in Pawon Man III of lower right permanent mandibular third molar (48) in lingual area and buccal lesion of lower left permanent third molar tooth (38) were all within codes 1, there were visual change in enamel seen as white spots in the pits or fissures of the teeth.

**Table 1.** Percentage of Dental Caries Using ICDAS Codes from Pawon 3 Mandibular Posterior According to Tooth Surfaces.

Pawon 3 Mandibula Posterior	0	1	2	3	4	5	6
<b>38/48</b>							
• Mesial surface							
• Occlusal surface	✓						
• Distal surface	✓						
• Buccal surface		✓					
• Lingual surface		✓					
<b>Total</b>	0	2	0	0	0	0	0



**Figure 2.** Dental caries in Pawon Man III of lower right permanent mandibular third molar (48) in lingual area and buccal lesion of lower left permanent third molar tooth (38) (Ahmad, 2016).



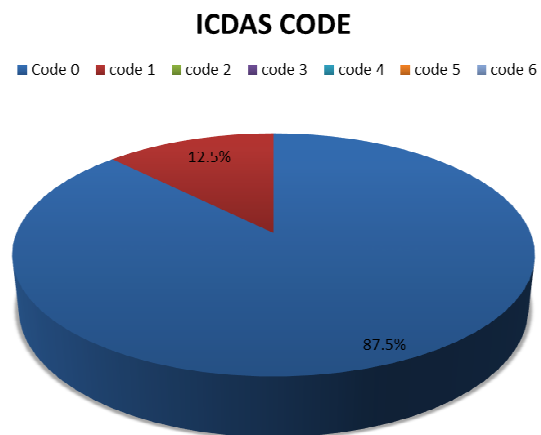
**Figure 4:** Dental caries in lingual lesion of lower left permanent second molar tooth (37) in Pawon 4 (Ahmad, 2016)

**Pawon IV**

2) In Pawon IV, lingual lesion of lower left permanent second molar tooth (37) and in lower left permanent third molar tooth (38). All lesions detected are only in enamel area with codes 1 according to The International Caries Detection and Assessment System (ICDAS).



**Figure 3.** Dental caries in Pawon IV lingual lesion in lower left permanent third molar tooth (38) (Ahmad, 2016)



**Graphic 1:** The Dental Caries in Pawon 1, 3, 4 and 5 by International Caries Detection and Assessment System (ICDAS) (Ahmad, 2016)

**Table 2.** Percentage of Dental Caries Using ICDAS Codes from Pawon 4 Mandibular Posterior According to Tooth Surfaces.

<b>Pawon 4 Mandibula Posterior</b>	<b>0</b>	<b>ICDAS 1</b>	<b>Codes 2</b>	<b>3</b>	<b>4</b>	<b>5</b>	<b>6</b>
<b>37/47</b>							
Mesial surface							
Occlusal surface							
Distal surface							
Buccal surface							
<b>Lingual surface</b>		✓					
<b>38/48</b>							
Mesial surface							
Occlusal surface							
Distal surface							
Buccal surface							
<b>Lingual surface</b>		✓					
Total	0	2	0	0	0	0	0

According to Graphic 1, for each Pawon Man 1, 3, 4 and 5 teeth samples had been purposively selected which give total of 32 teeth from all Pawon Man. The number of the dental caries presence in the Pawon Man was very low of which 12.5% (represented by red bar) detected with code 1 of ICDAS. The code 1 represent first visual changes in enamel after air-drying which is confine only in the pit and fissure area. Code 0 is the code for sound tooth surfaces and no caries change after air drying or presence of tooth wear detected in the teeth samples. This 0 code represent by blue bar having 87.5% of all Pawon Man teeth.

The reason for the low prevalence of dental caries in Pawon Man is because of Pawon Man’s low sugar diets that mostly from fruits and plants. Those sugars are categorized as fructose sugars which are often bonded to glucose to form the

disaccharide sucrose. It is one of the three dietary monosaccharides, along with glucose and galactose that are absorbed directly into the bloodstream during digestion (Trinkaus, E. Smith, R J. Lebel, 2002).

However, this fructose sugars in the fruits and plants that have been consumed by Pawon Man alongside other non-cariogenic sugars do not cause any production of extracellular polysaccharides in the oral cavity thus lesser chance for the growth of oral plaque biofilm that can contribute to dental caries. Also the cariogenicity is lesser compared to the sucrose sugars. Sugar alcohols such as sorbitol and xylitol play an important role to reduce dental caries. This is due to most of the microorganisms that dominate dental plaque cannot utilized these sugars (Trinkaus, E. Panila, 2009).



Most common sugars that contribute to higher prevalence of dental caries are sucrose which in turn becomes acids such as lactic acid through a glycolytic process called fermentation. If lactic acid contact with the tooth, these acids may cause demineralization. If demineralization continues over time, enough mineral content may be lost so that the soft organic material left behind disintegrates, forming a cavity or hole. The impact such sugars have on the progress of dental caries is called cariogenicity. *S.mutans* adheres to the biofilm on the tooth by converting sucrose into an extremely adhesive substance called dextran polysaccharide (Heymann, 2012).

Another reason for low prevalence of dental caries in Pawon Man is because most of the teeth examined either by using clinical examination is because most of the enamel surface of the teeth in Pawon Man have already wear off. Thus more existence of dental attrition compared to the dental caries in Pawon Man samples of teeth. Based on the attrition pattern on the teeth Pawon Man, such as in the first molars, second molars and third molars, can be estimated that human that lived in the Pawon Cave and being buried there were averagely 21 to 35 yrs old (Yondri, 2005). This also explained why all the teeth found in Pawon Man are all permanent teeth.

Third reason for evidence of existence of dental caries in Pawon Man even it has been demonstrated low is because they have poor oral hygiene during that period. Based on the findings of socio-cultural remain of Pawon Man such as tool flakes and obsidian stone, jewelries, bone tools, bone fragments and mollusks can be concluded that Pawon Cave has been utilized by Pawon Man as their home and their burial area also place for

them to collect and store foods. There are no evidence of Pawon Man utilized any tools in the Pawon Cave, that can be used as their toothbrush or to remove dental plaque dated back to 9525-5660 years Before Christ (Yondri, 2005).

Fourth reason for presence of dental caries in the Pawon Man 3 sample of buccal area of 38, third permanent mandibular molar, and lingual area of Pawon Man 4 samples of permanent mandibular second molar (37) and third molar (38) and Pawon Man 3 sample of permanent mandibular third molar (48) is because of the morphologic features of the teeth that can predispose Pawon Man to the development of dental caries. The buccal and lingual pits tend to trap foods, bacteria and debris and this can be more susceptible to dental caries development. However, in the teeth of Pawon Man there are more dental attrition, thus inclined planes of the teeth become flattened, providing less opportunity for entrapment of foods in the fissures, and the predisposition towards dental caries had diminished.

## CONCLUSION

The dental caries in skulls of Pawon Man is indicated as low, 12.5% of the 32 teeth samples and this is due to their diet patterns and their socio-cultural lifestyle. The presence of dental caries in Pawon Man was due to their bad oral hygiene.

Low percentage of dental caries in Pawon Man was due to their low sugar diets from fruits and sugar-rich plants. Further research need to be carried out since this is a preliminary research and perhaps in the future to know the difference of dental caries in Pawon Man and dental caries in local communities that live nearby to the Pawon Cave.

## REFERENCES

- Ahmad, A. (2016). *Laporan Hasil Pengukuran Kerusakan Gigi Akibat Pengaruh Makanan Pada Manusia Pawon*. Bandung.
- Bagramanian, Robert A. Garcia-Gody, Franklin. Anthony, R. (2009). The Global Increase in Dental Caries. A Pending Public Health Crisis. *American Journal of Dentistry*, 22(1), 3–8.
- Heymann, H. O. (2012). *Strurdevant's Art and Science of Operative Dentistry* (6 ed.). Philadelphia: Elsevier.
- Lebel, S. Trinkaus, E. (2001). A Carious Neanthertal Molar from the Bau de l' Ausbsier, Valchause, France. *Journal of Archaeological Science*, 29(5), 555–557.
- Rickne, C Scheid. Gabriela, W. (2011). Dental Anatomy: It's Relevant to Dentistry. *Woelf's Dentistry*, 33–50.
- Trinkaus, E. Hillson, S W, Franciscus, R G, Holiday, T. W. (2006). Skeletal and Dental Paleopathology. In S. Trinkaus, E. Svoloda (Ed.), *Early Modern Human Evolution in Central Europe* (hal. 419–458). New York: Oxford University Press.
- Trinkaus, E. Panila, B. (2009). Dental Caries in the Qafzeh 3 Middle Paleolitdhic Modern Human. *Peleorient*, 35, 69–76.
- Trinkaus, E. Smith, R J. Lebel, S. (2002). Dental Caries in the 5 Neanderthal Primary Molar. *Journal of Archaeological Science*, 27(11), 1017–1021.
- Trinkaus, E. (1995). Neanderthals Mortality Patterns. *Journal of Archaeological Science*, 22(1), 121–142.
- Yondri, L. (2005). *Kubur Prasejarah dari Gua Pawon Desa Gunung Masigit, Kabupaten Bandung, Propinsi Jawa Barat*. Universitas Indonesia.