

A rare presentation of multiple talon cusps

Uma rara apresentação de múltiplas cúspides em garra

Lara Eunice CÂNDIDO-SOARES¹
Fabrício PASSADOR-SANTOS¹
Luiz Alexandre THOMAZ¹
Mario Claudio MAUTONI²
Vera Cavalcanti de ARAÚJO¹
Andresa Borges SOARES¹

ABSTRACT

A talon cusp is a relatively rare dental developmental anomaly characterized by the presence of accessory cusp-like structure projecting from the cingulum area or cemento-enamel junction. It is frequently found on the palatal surface of the maxillary anterior teeth in the permanent dentition. The etiology is controversial, but it is suggested that this condition has a multifactorial cause, including both genetic and environmental factors. Radiographically talon cusps are radiopaque structures, in which the enamel, dentin and occasionally the pulp can be seen. The alteration is generally asymptomatic, but it may cause clinical problems eventually. Early diagnosis is important to prevent occlusal interference, irritation of the tongue, pulpal necrosis, caries and periodontal alterations. Clinical management of talon cusps may be either conservative or radical, depending on the size and shape of the affected tooth. We report a rare case of talon cusps involving all six maxillary anterior teeth in a 20-year-old patient.

Indexing terms: *Diagnosis oral. Radiography dental. Tooth abnormalities.*

RESUMO

Cúspide em garra é uma anomalia dental do desenvolvimento relativamente rara caracterizada por uma estrutura acessória em forma de cúspide projetando-se da área do cíngulo ou junção amelocementária. Ela é frequentemente encontrada na face palatina dos dentes maxilares anteriores na dentição permanente. A etiologia é controversa, mas é sugerido que essa condição tem causa multifatorial, incluindo ambos os fatores, genéticos e ambientais. Radiograficamente cúspides em garra são estruturas radiopacas, nas quais o esmalte, dentina e ocasionalmente a polpa podem ser vistos. A alteração é geralmente assintomática, mas pode causar problemas clínicos eventualmente. O diagnóstico precoce é importante para prevenir interferência oclusal, irritação na língua, necrose pulpar, cáries e alteração periodontal. O manejo clínico das cúspides em garra pode ser tanto conservativo quanto radical, dependendo do tamanho e forma do dente afetado. Nós relatamos um raro caso de cúspides em garra envolvendo todos os 6 dentes maxilares anteriores em um paciente de 20 anos de idade.

Termos de indexação: Diagnóstico bucal. Radiografia dentária. Anormalidades dentárias.

INTRODUCTION

A talon cusp is a rare dental developmental anomaly in which an additional cusp-like structure projects from the cement-enamel junction of the maxillary or mandibular anterior teeth, in either the primary or permanent dentition¹. These projections were first described in 1892 by Mitchell². Later Gorlin and Goldman³ defined a talon cusp as a very high accessory cusp, which may connect with the incisal edge to produce a T-form or a Y-shaped crown contour. In 1970 the term talon cusp was first used due to the structure's resemblance to an eagle's talon⁴.

A wide synonymy has been used in the literature to describe talon cusps, including central odontoma, evaginatus

odontoma, tuberculous premolar, Leong's premolar, occlusal enamel pearl, and Eagle's cusp. Dens evaginatus is used to describe an accessory cusp-like elevation present on the posterior teeth⁴⁻⁵.

A talon cusp consists of enamel and dentin, containing various amounts of pulpal tissue⁶. As with other dental abnormalities, talon cusp development occurs during the morpho-differentiation stage of odontogenesis⁷. The etiology is controversial. It is suggested that this condition has a multifactorial cause, including both genetic and environmental factors^{1,6,8}. Other theories include aberrant hyperactivity of dental lamina, outward folding of the inner enamel epithelium, altered endocrine functions and a transient focal

¹ Faculdade São Leopoldo Mandic, Curso de Odontologia, Programa de Pós-Graduação em Patologia. Rua José Rocha Junqueira, 13, Swift, 13045-755, Campinas, SP, Brasil. Correspondência para / Correspondence to: LEC SOARES. E-mail: <laracandidopatologia@gmail.com>.

² Universidade Santa Cecília. Santos, SP, Brazil.

hyperplasia of the mesenchymal dental papilla as possible developers of the anomaly^{1,7}.

We present a rare case of multiple talon cusps on six maxillary permanent anterior teeth.

CASE REPORT

A 20 year old white male was referred to clinic with a complaint of pain in his mandibular left second molar. The patient's medical and family history were irrelevant. Intraoral examination revealed the presence of prominent cusp-like projections on the palatal surface of all six anterior maxillary teeth (Figure 1). These malformations were at the midline of each tooth extending from the cemento-enamel junction (CEJ) to halfway to the incisal edge.

Panoramic radiographs showed V-shaped radiopaque structures on the central incisors, lateral incisors, and canines, superimposed over the normal image of the crown (Figure 2). The clinical and radiographic features suggested the diagnosis of talon cusps.

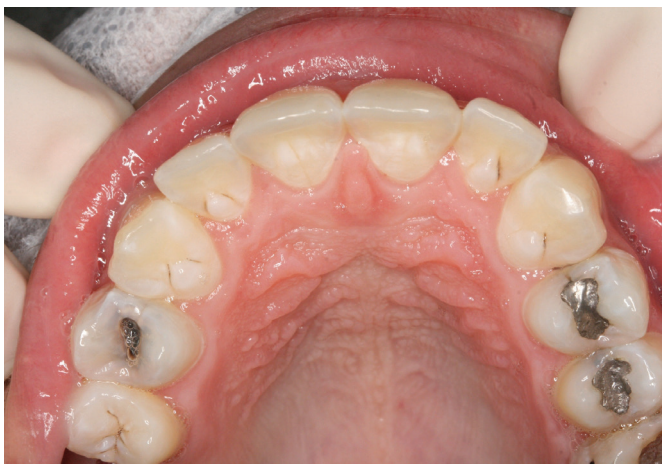

Figure 1. Intraoral view of the maxillary showing the talon cusps on the palatal surface of the six anterior teeth.

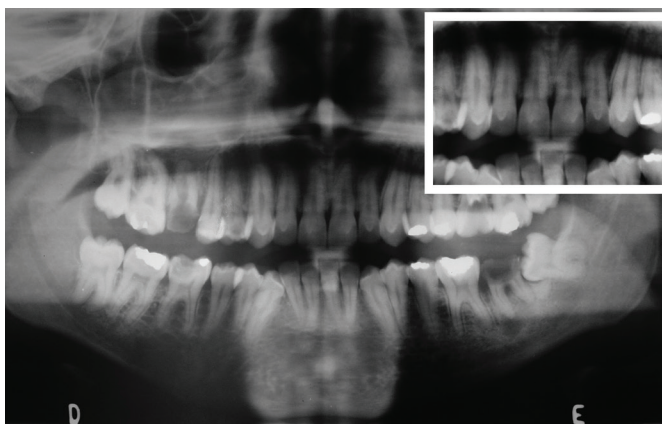


Figure 2. Panoramic radiograph showing the talon cusps on the six maxillary anterior teeth. Insert showing details of the radiopaque structures superimposed on the images of the affected crowns.

The clinical examination of the talon cusps revealed a superficial dark groove in the junction of the cusp and the palatal enamel of the lateral incisors and canines. There were no caries in these grooves. The talon cusps were not related to occlusal interference, irritation on the soft tissue, nor periodontal or periapical alterations.

No treatment was indicated in this case and the patient has been under control for cavities prevention.

Patient has signed a consent form giving permission to use his images.

DISCUSSION

The talon cusp is the accessory cusp-like structure, originates from disturbances in the morpho-differentiation stage of tooth development⁹. The cause of this condition is still unknown, but genetic and environmental factors are thought to be involved in the etiology. Sporadic occurrence of this abnormality is not uncommon¹⁰.

The prevalence of talon cusp has been reported in a range from one to eight percent of the population⁵. There is a predilection for men, however there is variations amongst population groups. It has been reported to occur more frequently in Asians, Mexicans and Eskimos¹¹. A striking predilection of the maxilla has been noted¹². About seventy-seven percent of the affected teeth have been in the permanent dentition. Among them, 67 percent of the cases involved lateral incisors, 24 percent central incisors and 9 percent canines. Most cases are unilateral, however, 20% are bilateral^{11,13-14}. Rare cases of multiple talon cusps have been related in the literature. In the present study we describe an uncommon case of talon cusps on six maxillary anterior teeth of a Brazilian man.

Clinically, talon cusps are often described as a nodule or tubercle, shaped as a cylindrical cone with a sharp point or a raindrop, on the palatal surface of anterior teeth⁴. Hattab et al.¹⁰ identified three types of this anomaly. True talon (type I) is an additional cusp that prominently projects from the palatal surface of a primary or permanent anterior tooth, and extends at least half the distance from the cemento-enamel junction to the incisal edge. Semitalon (type II) is an additional cusp of 1 mm or more extending less than the distance from the cemento-enamel junction to the incisal edge. Trace talon (type III) is an enlarged or prominent cingulum and variations namely, conical, bifid, or tubercle-like. According to this classification, the talon cusps presented in our case were characterized as semitalon (type II) on the central incisors and as trace talon (type III) on the lateral incisors and canines.

Radiographically talon cusps are seen as radiopaque structures, in which the enamel, dentin and occasionally the pulp can be seen. Typically the cusp resembles a V-shaped structure superimposed over the normal image of the crown¹². The aid of radiographs is essential to assess whether the accessory cusp contains or is devoid of a pulp horn, as well as to establish the appropriate treatment¹⁵. In this case, radiographic examination did not reveal pulp horn in the talon cusps.

Talon cusps have been associated with several systemic diseases, including Mohr syndrome, Rubinstein-Taybi syndrome and Sturge-Weber syndrome⁶. In addition, the dental literature has also reported the association of talon cusps with other odontogenic anomalies such as supernumerary teeth, congenitally missing teeth, dens invaginatus, complex odontoma and impaction^{1,16-18}. However, in some cases it may appear as an isolated alteration^{8,14,16,19}. In the present case the patient did not have syndromes or other dental anomalies.

Talon cusps are generally asymptomatic, but have clinical significance due to its tendency for caries and the potential for occlusal interference. Early diagnosis and management of talon cusps are important, especially to avoid and prevent pulpal necrosis^{17,19}. Possible consequences of large talon cusps include irritation of the tongue during speech and mastication, displacement of the affected tooth, pulpal necrosis, periapical pathosis, attrition of the opposing tooth and periodontal problems due to excessive occlusal forces¹.

Clinical management of talon cusps may be either conservative or radical, depending on the size and shape of the affected tooth¹⁶. Treatment procedure may include fissure sealants, sequential grinding, pulp therapy, restorative treatment, full crown coverage and extraction of the affected tooth¹³. However, some cases require no treatment. In this case, no treatment was necessary because the talon cusps were a clinical finding with no associated pathological manifestation.

CONCLUSION

Although talon cusps are rare, it is important to establish an early diagnosis and, if necessary, prompt treatment is required to prevent future complications. Moreover, it is important to note that this alteration may be associated with other systemic and dental anomalies.

Acknowledgment

The authors would like to thank DDS Ali Pourian for the linguistic assistance.

Collaborators

LE CÂNDIDO-SOARES, F PASSADOR-SANTOS, VC ARAÚJO and AB SOARES were involved in manuscript writing. LA THOMAZ e MC MAUTONI were in charge of patient clinical management and manuscript writing.

REFERENCES

- Hattab FN, Hazza'a AM. An unusual case of talon cusp on geminated tooth. *J Can Dent Assoc.* 2001;67(5):263-6.
- Mitchell WH. Case report. *Dental Cosmos.* 1892;34:1036.
- Gorlin RJ, Goldman HM. *Thomas oral pathology.* St. Louis: Mosby Co.; 1970.
- Mellor JK, Ripa LW. Talon cusp: a clinically significant anomaly. *Oral Surg Oral Med Oral Pathol.* 1970;29(2):225-8. doi: 10.1016/0030-4220(70)90089-7.
- Dankner E, Harari D, Rotstein I. Dens evaginatus of anterior teeth: literature review and radiographic survey of 15,000 teeth. *Oral Surg Oral Med Oral Pathol Oral Radiol Endod.* 1996;81(1):472-5. doi: 10.1016/S1079-2104(96)80027-8.
- Oredugba FA. Mandibular facial talon cusp: case report. *BMC Oral Health.* 2005;8(5):9. doi:10.1186/1472-6831-5-9.
- Rantanen AV. Talon cusp. *Oral Surg Oral Med Oral Pathol.* 1971;32(3):398-400.
- Sumer AP, Zengin AZ. An unusual presentation of talon cusp: a rare report. *Br Dent J.* 2005;199(7):429-30. doi:10.1038/sj.bdj.4812741.
- Yoon RK, Chussid S. Dental management of a talon cusp on a primary incisor. *Pediatr Dent.* 2007;29(1):51-5.
- Hattab FN, Yassin OM, al-Nimri KS. Talon cusp in permanent dentition associated with other dental anomalies: review of literature and reports of seven cases. *ASDC J Dent Child.* 1996;63(3):368-76.
- Buenviaje TM, Rapp R. Dental anomalies in children: a clinical and radiographic survey. *J Dent Child.* 1984;51(1):42-6.
- Hattab FN, Yassin OM. Bilateral talon cusps on primary central incisors: a case report. *Int J Paediatr Dent.* 1996;6(3):191-5.
- Balcioglu HA, Keklikoglu N, Kokten G. Talon cusp: a morphological dental anomaly. *Rom J Morphol Embryol.* 2011;52(1):179-81.

14. Chinni S, Nanneboyina M, Ramachandran A, Chalapathikumar H. A facial talon cusp on maxillary permanent central incisors. *J Conserv Dent*. 2012;15(1):87-8.
15. Segura JJ, Jimenez-Rubio A. Talon cusp affecting permanent maxillary lateral incisors in 2 family members. *Oral Surg Oral Med Oral Pathol Oral Radiol Endod*. 1999;88(1):90-2. doi: 10.1016/S1079-2104(99)70199-X.
16. Cogulu D, Oncag O. Management of a case with bilateral talon cusp in primary dentition. *J Dent Child*. 2006;73(3):183-5.
17. Vardhan TH, Shanmugam S. Dens evaginatus and dens invaginatus in all maxillary incisors: Report of a case. *Quintessence Int*. 2010;41(2):105-7.
18. Nagaveni NB, Umashanikara KV, Vidyullatha BG, Sreedevi S, Radhika NB. Permanent mandibular incisor with multiple anomalies - report of a rare clinical case. *Braz Dent J*. 2011;22(4):346-50. doi: 10.1590/S0103-64402011000400015.
19. Soares AB, de Araújo JJ, de Sousa SM, Veronezi MC. Bilateral talon cusp: case report. *Quintessence Int*. 2001;32(4):283-6.

Received on: 28/6/2012

Final version resubmitted on: 9/10/2012

Approved on: 5/2/2013