



UNIVERSITY OF AMSTERDAM

UvA-DARE (Digital Academic Repository)

Subacute narrowing of the left main coronary artery following directional atherectomy for proximal obstructive coronary artery disease

Piek, J.J.; Koch, K.T.; van der Wal, A.C.; Becker, A.E.

Published in:
Catheterization and Cardiovascular Diagnosis

[Link to publication](#)

Citation for published version (APA):

Piek, J. J., Koch, K. T., van der Wal, A. C., & Becker, A. E. (1997). Subacute narrowing of the left main coronary artery following directional atherectomy for proximal obstructive coronary artery disease. *Catheterization and Cardiovascular Diagnosis*, 40, 361-363.

General rights

It is not permitted to download or to forward/distribute the text or part of it without the consent of the author(s) and/or copyright holder(s), other than for strictly personal, individual use, unless the work is under an open content license (like Creative Commons).

Disclaimer/Complaints regulations

If you believe that digital publication of certain material infringes any of your rights or (privacy) interests, please let the Library know, stating your reasons. In case of a legitimate complaint, the Library will make the material inaccessible and/or remove it from the website. Please Ask the Library: <https://uba.uva.nl/en/contact>, or a letter to: Library of the University of Amsterdam, Secretariat, Singel 425, 1012 WP Amsterdam, The Netherlands. You will be contacted as soon as possible.

UvA-DARE is a service provided by the library of the University of Amsterdam (<http://dare.uva.nl>)

Subacute Narrowing of the Left Main Coronary Artery Following Directional Atherectomy for Proximal Obstructive Coronary Artery Disease

Jan J. Piek,^{1*} MD, Karel T. Koch,¹ MD, Allard C. van der Wal,² MD, and Anton E. Becker,² MD

Directional atherectomy is an alternative device for treatment of highly eccentric or proximal coronary lesions considered less suitable for balloon angioplasty. We report a patient with exuberant neointimal proliferation, extending into the left main coronary artery, following directional atherectomy of the proximal target site in the left circumflex artery. This observation indicates that patients with mild left main disease have an increased risk to develop this complication following directional atherectomy. *Cathet. Cardiovasc. Diagn.* 40:361–363, 1997. © 1997 Wiley-Liss, Inc.

Key words: left main coronary stenosis; directional atherectomy; restenosis

INTRODUCTION

Directional atherectomy has been introduced for the treatment of highly eccentric or proximal coronary lesions considered less suitable for balloon angioplasty. We report a patient who died after coronary bypass surgery for a proximally located restenotic lesion following directional atherectomy. Postmortem examination provided insight into the morphological vascular wall changes after intracoronary intervention with the use of this device with potential clinical implications for patient management.

CASE REPORT

A 73-year-old man was referred because of recurrent anginal complaints after balloon angioplasty of a proximal stenosis in the left circumflex coronary artery. Coronary angiography revealed severe coronary renarrowing at the primary site in the left circumflex coronary artery and mild obstructive coronary artery disease of the left main coronary artery and left anterior descending coronary artery (Fig. 1A). After successful directional atherectomy (Fig. 1B), the patient was asymptomatic. His anginal complaints relapsed after 2 months due to a rerestenotic lesion in the left circumflex coronary artery (Fig. 1C). The coronary narrowings of the left main coronary artery and left anterior descending coronary artery were considered non-significant and the patient was scheduled for elective coronary bypass grafting of the first marginal branch. The operation was performed 6 weeks after coronary angiography; awaiting surgery, the patient's anginal complaints progressed.

The operative procedure was uneventful. However, the first 12-lead electrocardiogram made upon arrival at the

intensive care unit revealed ST-segment depression in all leads. The patient became hypotensive followed by asystole and death.

Postmortem examination revealed a transmural posterolateral infarct and a circumferential subendocardial infarct. The venous bypass graft was patent. Histological examination of the coronary arteries demonstrated exuberant neointimal proliferation at the initial target site proximal in the left circumflex coronary artery (Fig. 2). The neointimal tissue was superimposed on preexistent atherosclerotic plaque. The tissue extended proximally into the left main coronary artery and into the most proximal part of the anterior descending coronary artery.

DISCUSSION

Subacute left main coronary stenosis, consequent to balloon angioplasty of a target lesion proximal in the left circumflex artery, has been documented. However, the limited number of reports suggests that this is a rare event [1–3]. To the best of our knowledge this is the first report of this complication following directional atherectomy.

What mechanisms can be involved? First, neointimal proliferation may spread to adjacent sites of the primary

¹Department of Cardiology, Academic Medical Center, University of Amsterdam, Amsterdam, The Netherlands

²Department of Cardiovascular Pathology, Academic Medical Center, University of Amsterdam, Amsterdam, The Netherlands

*Correspondence to: Dr. Jan J. Piek, Department of Cardiology, Academic Medical Center, University of Amsterdam, P.O. Box 22700, 1100 DE Amsterdam, The Netherlands.

Received 17 June 1996; Revision accepted 30 October 1996

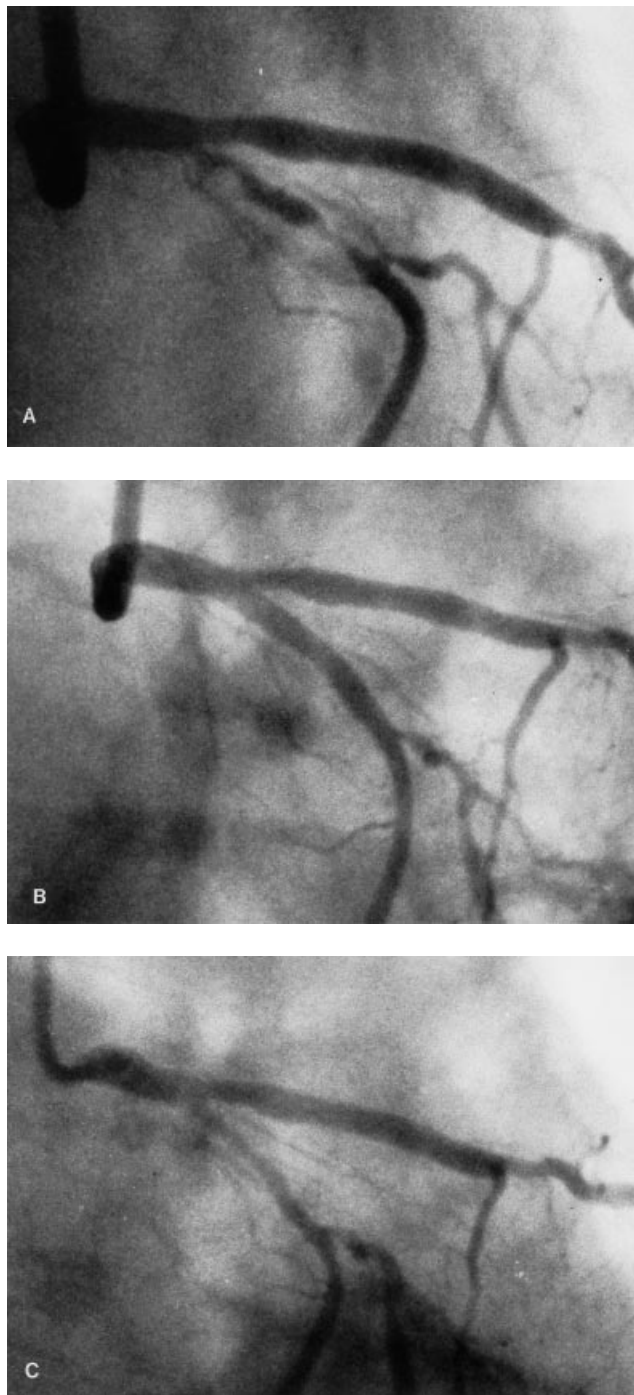


Fig. 1. Coronary angiograms of the left circumflex coronary artery before (A) and after (B) directional atherectomy and at repeat angiography 2 months after the procedure (C). The narrowing of the left main coronary artery and that of the proximal part of the left anterior descending coronary artery at follow-up were considered mild (40% diameter stenosis on visual assessment).

coronary lesion, as part of the wound healing process, despite the fact that the atherectomy per se is limited to a well-defined segment. Second, neointimal proliferation in the left main coronary artery could be a response to local mechanical trauma induced by the atherectomy device. The latter hypothesis is supported by reports demonstrating subacute left main coronary artery stenosis as the result of coronary cannulation for aortic valve replacement [4,5]. The observation that the tissue at the primary site and that in the left main coronary artery is of similar age may be of further support. Moreover, patients with mild left main disease are prone to develop this complication after balloon angioplasty, irrespective of the prime site of the target lesion within the left system [3]. This observation also could indicate susceptibility to mechanical injury. Zamorano et al. [6] recently reported progressive intimal thickening proximal to—and remote of—the target site after percutaneous transluminal coronary angioplasty, a phenomenon which occurred only in patients who developed restenosis. Their observation suggests that these “remote” and focal neointimal changes are a response to mechanical trauma, induced by the balloon or guiding catheter, rather than part of an exuberant repair process initiated at the original target site.

Despite the fact that the overall incidence of left main stem progression after balloon angioplasty may be underestimated angiographically [3], it is remarkable that this complication has not yet been reported after directional atherectomy. The relatively rigid device under these conditions, compared with the currently used balloon and guiding catheters, would favor mechanical trauma at sites other than the target site. Be that as it may, awareness of this phenomenon has potential clinical implications for patient management and, possibly, in particular for patients with known preexistent mild left main coronary artery disease.

REFERENCES

1. Graf RH, Verani MS: Left main coronary artery stenosis: A possible complication of transluminal coronary angioplasty. *Cathet Cardiovasc Diagn* 10:163–166, 1984.
2. Slack JD, Pinkerton CA: Subacute left main coronary stenosis: An unusual but serious complication of percutaneous transluminal coronary angioplasty. *Angiology* 36:130–136, 1985.
3. Kells CM, Miller RM, Henderson MA, Lomnicki JM, MacDonald RG: Left main coronary artery disease progression after percutaneous transluminal coronary angioplasty. *Am J Cardiol* 65:513–514, 1990.
4. Bashour TT, Hanna ES, Edgett J, Geiger J: Iatrogenic left main coronary artery stenosis following PTCA or valve replacement. *Clin Cardiol* 8:114–117, 1985.
5. Sievert H, Winkelmann B, Eckel L, Blum U, Sarai C, Scherer D, Spies H, Storger H, Kaltenbach M, Satter P: Left main stenosis after aortic valve replacement. *Z Kardiol* 80:431–434, 1991 (in German).
6. Zamorano J, Erbel R, Ge J, Gorge G, Kearney P, Scholte A, Meyer J: Vessel wall changes in the proximal non-treated segment after PTCA: An in vivo intracoronary ultrasound study. *Eur Heart J* 15:1505–1511, 1995.

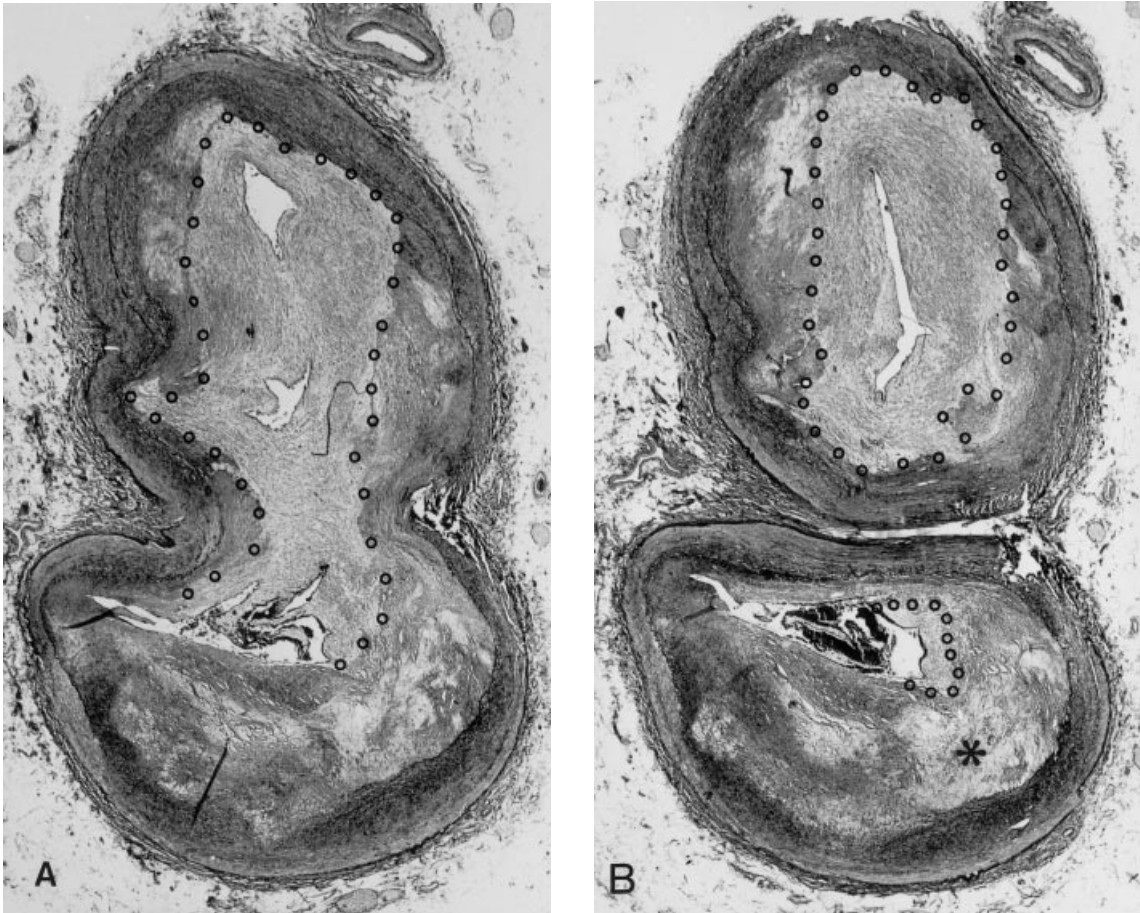


Fig. 2. Microscopic examination of the left main coronary artery (A) and the proximal part of the left circumflex coronary artery (B) shows extensive neointimal proliferation. The areas within the stippled lines contain the fibrocellular proliferative repair tissue causing restenosis. The asterisk in B is in the left anterior descending coronary artery.