

Hindawi Publishing Corporation
ISRN Minimally Invasive Surgery
Volume 2013, Article ID 989727, 4 pages
<http://dx.doi.org/10.1155/2013/989727>



Clinical Study

Lift-Assisted Laparoscopy in Hysterectomy: A Retrospective Study of 32 Consecutive Cases

Bo S. Bergström

Department of Obstetrics & Gynecology, Nordfjord Hospital, 6770 Nordfjordeid, Norway

Correspondence should be addressed to Bo S. Bergström; bosbergstrom@comhem.se

Received 14 August 2013; Accepted 19 September 2013

Academic Editors: F. Agresta and A. Tinelli

Copyright © 2013 Bo S. Bergström. This is an open access article distributed under the Creative Commons Attribution License, which permits unrestricted use, distribution, and reproduction in any medium, provided the original work is properly cited.

A large uterus is the most commonly reported obstacle to laparoscopic hysterectomy. It reduces the intra-abdominal free space, limits visualization and instrumentation, causes technical difficulties, and increases the potential for complications. The logical solution to this dilemma is to address the underlying problem and increase the intra-abdominal free space. This can be done readily by supplementing the conventional pneumoperitoneum by concurrent mechanical lifting of the abdominal wall using the camera trocar as an anchoring device. Such lift-assisted laparoscopy augments the intra-abdominal free space formation, and lifts the laparoscope to a higher position to give a panoramic view, even when the uterus is large. This retrospective study of 32 consecutive cases of laparoscopic hysterectomy indicates that the use of lift-assisted laparoscopy is safe for the patient and that a large uterus is not a contraindication. The operations were long, but complications were few. Lift-assisted laparoscopy is an option to improve patient care by modifying surgical procedures. Operating time, per se, is not a valid measure of quality in laparoscopic hysterectomy. The more traumatic abdominal hysterectomy procedures need not be selected in preference over lengthy minimally invasive techniques. Other techniques, such as solo surgery and in-office surgery, are also discussed.

1. Introduction

In contrast to open abdominal hysterectomy (AH), minimally invasive techniques such as laparoscopic hysterectomy (LH) and vaginal hysterectomy (VH) cause little or no trauma to the abdominal wall and less postoperative pain. Studies have shown that minimally invasive techniques for benign hysterectomy are safe for the patient and give reduced morbidity, shorter hospital stay, and a faster return to normal activities compared with open procedures. Open techniques increase the risk of intra-abdominal adhesions, wound infection and hernias, and often leave an aesthetically unacceptable scar. The trauma is worse for patients with a large uterus and a thick abdominal wall.

Despite its potential for greater short- and long-term morbidity, open AH continues to be the surgical approach used most commonly in the USA and Sweden [1, 2]. The Swedish Gynop Register for Hysterectomy 2011, which included 45 clinics, shows that surgery was performed abdominally in 19%–97% of cases (2/3 of all registered hysterectomies), laparoscopically in 0%–62% (1/10), and vaginally in 3%–65% (1/4), with great variation between clinics.

The American Association of Gynecologic Laparoscopists (AAGL) states that AH for benign disease should be performed only rarely and that a minimally invasive approach should be presented as an option to all appropriate candidates. Furthermore, if a surgeon cannot safely perform a hysterectomy vaginally or laparoscopically, then he/she should refer the patient to a gynecological surgeon who can. When VH is not possible because of the size of the uterus or other coexisting surgical considerations, LH is a safe alternative, retaining most of the advantages of VH over AH. Continued efforts should be made to facilitate the use of minimally invasive approaches [3].

An enlarged myomatous uterus frequently produces adverse symptoms and is the most common indication for hysterectomy. A large uterus is also the most commonly reported obstacle to LH and VH [4, 5]. Many gynecological surgeons report that they would prefer a minimally invasive approach for themselves or their spouses [4]. Nevertheless, LH and VH are still used far less commonly than AH. In LH, a large uterus reduces the intra-abdominal free space, limits visualization and instrumentation, causes technical difficulties, and increases the potential for complications.

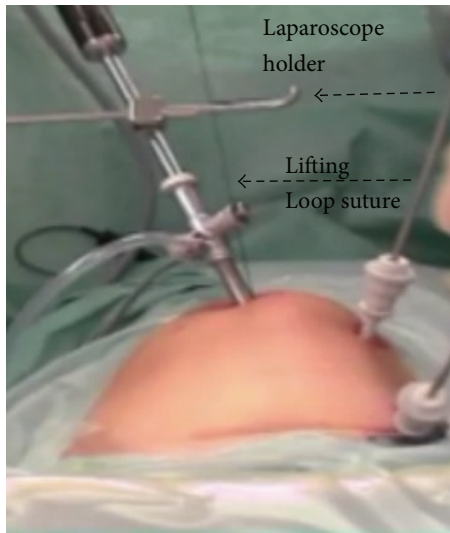


FIGURE 1: Lift-assisted laparoscopy and solo surgery.

The logical solution to this dilemma is to address the underlying problem and increase the intra-abdominal free space. Supplementing the conventional pneumoperitoneum by concurrent mechanical lifting of the abdominal wall using the camera trocar as an anchoring device (camera trocar lifting) augments the intra-abdominal free space formation and gives a panoramic view even when the uterus is large and the abdominal wall is thick. Lift-assisted laparoscopy is an option for improving patient care by modifying surgical procedures.

2. Materials and Methods

In this retrospective study of 32 consecutive cases of LH, we evaluate whether camera trocar lifting is safe for the patient and whether operating time, per se, is a valid measure of quality in laparoscopic hysterectomy. Between 2003 and 2005, the author performed 24 laparoscopically assisted vaginal hysterectomies and eight laparoscopic subtotal hysterectomies, all for benign disease. A large uterus was not a contraindication in any patient. All procedures were performed with three abdominal trocar sites, including that for the laparoscope. A mechanical laparoscope holder (stepless motion with one hand, no locking/unlocking mechanism, and set-up time < 1 min) replaced an assistant surgeon.

A conventional pneumoperitoneum was combined with mechanical lifting of the abdominal wall, using the camera trocar (laparoscope site) as an anchoring device (Figure 1). The combined trocar/abdominal wall was lifted with a loop of polydioxanone suture (PDS no. 1) snared around the shaft of the trocar with a hang knot and with a needle driven through the fascia, the cutaneous tissue, and the skin at the lower end of the abdominal wall incision. The loop suture was attached to a horizontal metal arm mounted on the operating table and placed above the woman, for example, an ordinary anesthesia frame with the horizontal arm draped in a sterile sleeve [6].

The operations were evaluated for the size of the uterus, operating time (op-time) in minutes, postoperative care time (p-time) in days, blood loss in milliliters, complications at discharge, and patient's complaints at followup.

3. Results

No complication related to the mechanical lifting arrangement was observed in this study. Thirty-one operations were completed as planned. The uterine size range was 100–950 g, with half of them ≥ 250 g. The median op-time was 175 min, with a mean of 193 min; no operation lasted less than 120 min (two values are missing). Analysis of p-time showed that 28/31 (90%) of the patients were hospitalized for two days or less and 22/31 (71%) for one day or less, with a median p-time of 1.0 days and a mean p-time of 1.5 days. The blood loss range was 100–1500 mL, with a median blood loss of 200 mL and a mean of 370 mL. 24 operations < 500 mL (24/32, 75%) and two operations > 1000 mL (these applied to uterine sizes of 950 g and 750 g). The complication rate was 3/32 (9.4%). One bladder rift was detected and sutured intraoperatively (p-time one day, bleeding 100 mL), and two cases of port site hematoma in the lower left quadrant of the abdominal wall were detected some hours after surgery and treated with a compression bandage. One of these patients required a blood transfusion and both had a p-time of three days. There was one case of aspiration pneumonia, which the author does not consider a complication attributable to the surgical technique (uterus < 250 g, op-time 140 min; the patient was transferred to another clinic after two days). One operation was converted to AH (uterus > 250 g, p-time two days, blood loss 350 mL, no complications). One woman returned to the hospital the same evening because of insufficient pain relief. There was no other readmission or recorded complication after discharge from the hospital. Benchmarking against the Swedish Gynop Register for Hysterectomy 2011 showed the following rankings in relation to the registered values: complications, 2nd out of 41 clinics; p-time, 4th out of 45 clinics; blood loss, 38th out of 42 clinics; and op-time, last out of 42 clinics.

4. Discussion

The long operating times and high rate of blood loss can be explained, in part, by large uterine sizes and time-consuming morcellation. There was no negative relation between long op-times and p-times or complication rates. A short hospital stay was consistently observed, regardless of the time spent in the operating theatre. Long op-times and greater blood loss were both related to a large uterine size (Figure 2).

Although a small trocar causes little trauma to the abdominal wall, a large trocar and lengthy transabdominal morcellation of the uterus present a high risk of traumatizing the abdominal wall and causing bleeding, either by the contusion of the muscles or the direct puncture of the inferior epigastric vessels. The detection of bleeding is often delayed and manifests as a postoperative hematoma. The hospital stay is frequently prolonged. After lengthy morcellation, it

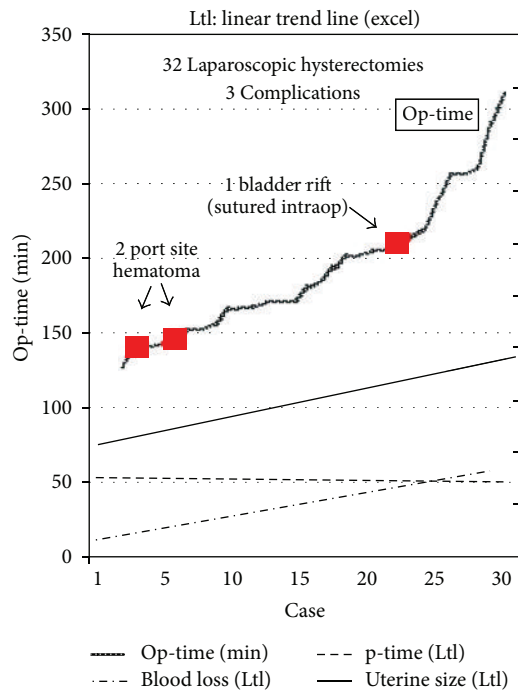


FIGURE 2: Op-times and trend lines for p-time, blood loss, and uterine size.

is wise to install a counter-pressing balloon Foley catheter across the abdominal wall to prevent hematoma formation or more insidious extensive bleeding into the abdominal cavity. The catheter should be left in place for some hours [7]. This catheter technique was not used in this study.

The benefits of the mechanical lifting arrangement cannot be overestimated. In combination with standard gas pressure, it enlarges the intra-abdominal free space, lifts the abdominal wall/camera trocar complex to a high position, gives a panoramic view, even when the uterus is large and the abdominal wall is thick, and fixes the trocar to the abdominal wall so that there is no trocar sliding or gas leakage. In high-risk patients, surgery under low gas pressure is possible with a sustained adequate view, and, if necessary, this procedure allows the surgeon to take temporary measures under “gasless” conditions. Lifting the skin and the subcutaneous tissue 6–8 cm above the symphysis pubis using a towel clamp further improves the intra-abdominal free space. A special slit trocar facilitates the shifting maneuver between gas-based and gasless techniques [6].

Because the abdominal wall is lifted to a higher position, the camera trocar is preferably placed in or above the umbilicus. This ensures that the slope of the laparoscope does not become too steep and positions the camera trocar more cephalically to permit better inspection of a uterus that reaches the umbilicus. The mechanical lifting procedure introduces no extra devices into the peritoneal cavity, causes no trauma to the peritoneal surface, and does not interfere with surgical movement. The set-up time for camera trocar lifting is less than 1-2 min.

Is op-time a factor that predicts complications? If a long op-time results from complex circumstances, such as reduced intra-abdominal free space and restricted visualization or instrumentation, the risk of complications is probably increased. However, if a long op-time results from the meticulous implementation of procedures to prevent surgical mishap in a situation with adequate intra-abdominal free space and unrestricted visualization and instrumentation, the risk of complications is probably not increased [8]. This series of 32 LHs, in which 50% of the uteri were ≥ 250 g and the op-times were long, with few complications, supports this hypothesis. The duration of surgery alone is not a major determinant of postoperative morbidity, and the type of surgery performed and the patient’s general health are more important predictors of outcome than is the duration of surgery [9].

Using a normal operating theatre is very expensive, and long operating times reduce the accessibility to these theatres. Short operating times reduce hospital costs. AH is often completed relatively quickly. From a wider perspective, cost effectiveness favors the less-traumatic laparoscopic technique over the more-traumatic open abdominal approach. The cost incurred by an op-time that is 1-2 h longer than normal is more than balanced by a hospital stay that is 1-2 days shorter than normal, a recovery period that is 1-2 weeks shorter than normal [10], and the future costs of late complications, such as hernias and intra-abdominal adhesions. What the woman wants is particularly important. Which outcomes are preferable: a small wound, little pain, a short hospital stay, and a rapid return to work or a large wound, considerable pain, a long hospital stay, and a late return to work? To make this decision, each woman must be fully informed and her informed consent must be based on all options.

Restricted access to or excessive demands on a normal operating theatre can be a barrier to time-consuming LH. At Nordfjord Hospital in Norway between 2000 and 2005 and at Mora Hospital in Sweden between 1992 and 1998, the use of normal operating theatres was almost halved, despite the increased number of time-consuming laparoscopic procedures used for hysterectomy and adnexal surgery. This is explained by the relocation of many operations from the normal operating theatre to a local anesthetic unit, a low-resource office-based setting. The relocated operations included endometrial curettage, hysteroscopy, abortion, laser surgery (not at Nordfjord Hospital), conization, thermal endometrial destruction (not at Nordfjord Hospital), gasless laparoscopic sterilization, tension-free vaginal tape for incontinence surgery, and prolapse surgery. At Mora Hospital in 1998, 63% of all operations were performed under local anesthesia and mild sedation, including 50 of 96 prolapse surgeries. Gynecological in- and outpatient services increased by 29%, health care spending decreased by 22%, and waiting times for surgery decreased by 80%. The use of laparoscopy instead of open surgery and office-based surgery instead of regular operating room surgery dramatically reduced average length of hospital stay and made it possible to increase the total number of surgeries.

At Nordfjord Hospital, the overall satisfaction rate for office-based surgery performed under local anesthesia and

mild sedation was 100%, 97%, 98%, 99%, and 98% in 2002–2006, respectively, based on submitted outcome questionnaires. The women walked to and from the operating room for all types of surgery, including prolapse surgery. Office-based surgery is safe, convenient for the patient, and inexpensive [11] and leaves the normal operating theatre available for more advanced surgery, such as LH and VH.

An operating assistant or a trained human laparoscope holder is often unavailable at all hospitals, which can be an obstacle to LH. Using a mechanical laparoscope holder is superior in all respects to human assistance. It allows the surgeon to work more easily and increases the accuracy of the procedure by keeping the video image completely stable. It also returns complete procedural control to the surgeon and eliminates frustrating miscommunication between the surgeon and assistant. It also eliminates the excessive personnel costs associated with salaries and overtime and ensures that an “assistant” is available 24 h a day. In the author’s view, such “solo surgery” does not slow the surgeon but allows him/her to plan the operation.

Robot-assisted laparoscopy [12] is another technique that addresses the problems that arise when visualization or instrumentation is difficult. The surgeon is seated alone at a console, a few meters from the patient, and controls two specialized robot-assisted instruments and a 3D camera. Two staff members stand next to the patient and assist the robot. The disadvantages of the robot-assisted system include the enormous costs and the additional time required for the assembly and disassembly of the equipment and its bulkiness.

Many gynecological surgeons want to reduce their AH rates and increase their LH rates [4]. Lift-assisted laparoscopy improves patient care by modifying surgical procedures that would otherwise, for some surgeons, require laparotomy.

5. Conclusion

This study, although small, implies that lift-assisted laparoscopy (i.e., conventional pneumoperitoneum + concurrent camera trocar lifting) is safe for the patient and that a large uterus is not a contraindication for its use. The operations were long but complications were few. Lift-assisted laparoscopy is an option to improve patient care by modifying surgical procedures. The more traumatic abdominal hysterectomy procedures need not be selected in preference over lengthy minimally invasive techniques. Operating time, per se, is not a valid measure of quality in laparoscopic hysterectomy.

Abbreviations

AH:	Abdominal hysterectomy
AAGL:	American Association of Gynecologic Laparoscopists
LH:	Laparoscopic hysterectomy
op-time:	Operating time
p-time:	Postoperative care period
VH:	Vaginal hysterectomy.

Conflict of Interests

The author has invented the laparoscope holder. The author declares that there is no conflict of interests regarding the publication of this paper.

References

- [1] B. N. Giep, H. N. Giep, and H. B. Hubert, “Comparison of minimally invasive surgical approaches for hysterectomy at a community hospital: robotic-assisted laparoscopic hysterectomy, laparoscopic-assisted vaginal hysterectomy and laparoscopic supracervical hysterectomy,” *Journal of Robotic Surgery*, vol. 4, no. 3, pp. 167–175, 2010.
- [2] “Swedish Gynop Register for Hysterectomy 2011,” June 2012, <http://www.gynop.org/rapporter/rapporter/GynopHystraport2012.pdf>.
- [3] AAGL Position Statement, “Route of hysterectomy to treat benign uterine disease,” *Journal of Minimally Invasive Gynecology*, vol. 18, no. 1, pp. 1–3, 2011.
- [4] J. I. Einarsson, K. A. Matteson, J. Schulkin, N. R. Chavan, and H. Sangi-Haghpeykar, “Minimally Invasive Hysterectomies: a survey on attitudes and barriers among practicing gynecologists,” *Journal of Minimally Invasive Gynecology*, vol. 17, no. 2, pp. 167–175, 2010.
- [5] P. Persson, T. Hellborg, J. Brynhildsen, M. Fredrikson, and P. Kjølhedde, “Attitudes to mode of hysterectomy: a survey-based study among Swedish gynecologists,” *Acta Obstetrica et Gynecologica Scandinavica*, vol. 88, no. 3, pp. 267–274, 2009.
- [6] B. S. Bergström, “Camera trocar lifting in office gasless laparoscopic sterilization under local anesthesia,” *Acta Obstetrica et Gynecologica Scandinavica*, vol. 89, no. 7, pp. 975–979, 2010.
- [7] J. Ruiz-Tovar, P. Priego-Jimenez, and G. A. Paiva-Coronel, “Use of Foley’s catheter to control port-site bleeding in bariatric surgery,” *Obesity Surgery*, vol. 22, no. 2, pp. 306–308, 2012.
- [8] A. Liverani, M. Chiarot, M. Bezzi, and L. Angelini, “Is really operative time a complication factor?” *Minerva Chirurgica*, vol. 49, no. 9, pp. 747–750, 1994.
- [9] B. J. Fogarty, K. Khan, G. Ashall, and A. G. Leonard, “Complications of long operations: a prospective study of morbidity associated with prolonged operative time (> 6 h),” *British Journal of Plastic Surgery*, vol. 52, no. 1, pp. 33–36, 1999.
- [10] M. Ellström, J. Ferraz-Nunes, M. Hahlin, and J.-H. Olsson, “A randomized trial with a cost-consequence analysis after laparoscopic and abdominal hysterectomy,” *Obstetrics and Gynecology*, vol. 91, no. 1, pp. 30–34, 1998.
- [11] A. Diez R-Labajo, “Office-based surgery and anesthesia,” *Current Opinion in Anaesthesiology*, vol. 11, no. 6, pp. 615–621, 1998.
- [12] C. Nezhat, N. S. Saberi, B. Shahmohamady, and F. Nezhat, “Robotic-assisted laparoscopy in gynecological surgery,” *Journal of the Society of Laparoendoscopic Surgeons*, vol. 10, no. 3, pp. 317–320, 2006.



Hindawi

Submit your manuscripts at
<http://www.hindawi.com>

