

# Acute bilateral angle closure glaucoma induced by methazolamide

Ahmad A Aref<sup>1,2</sup>  
Fouad E Sayyad<sup>2</sup>  
Bernadete Ayres<sup>2</sup>  
Richard K Lee<sup>2</sup>

<sup>1</sup>Bascom Palmer Eye Institute, University of Miami Miller School of Medicine, Miami, FL, <sup>2</sup>Illinois Eye and Ear Infirmary, University of Illinois at Chicago School of Medicine, Chicago, IL, USA

**Purpose:** To report a case of bilateral acute myopia and angle closure glaucoma after ingestion of methazolamide.

**Methods:** An interventional case report of a 70-year-old male who developed bilateral, acute myopia and angle closure glaucoma after ingesting methazolamide tablets for the treatment of normal tension glaucoma.

**Results:** Bilateral anterior chamber shallowing associated with ciliary body edema, supraciliary effusions, and shallow posterior choroidal effusions were documented with slit-lamp photography and high-frequency ultrasonography. Near complete resolution of these signs after discontinuation of methazolamide were also documented.

**Conclusion:** Methazolamide may be associated with secondary myopia and angle closure glaucoma. Discontinuation of methazolamide leads to resolution of this process, as documented by slit-lamp photography and high-frequency ultrasonography.

**Keywords:** glaucoma, glaucoma pharmacology, angle closure glaucoma

## Introduction

Secondary myopia and angle closure have been associated with a number of sulfonamide-derived medications. Most of these drugs fall into the class of antibiotics (eg, sulfacetamide, sulfadiazine) or antihypertensives (eg, acetazolamide, hydrochlorothiazide). In 2001, topiramate-induced angle closure glaucoma was also described.<sup>1</sup> Recently, a single case of methazolamide-induced angle closure glaucoma was described.<sup>2</sup> This entity may affect any age and appears to affect each gender with equal incidence.<sup>3</sup>

The exact pathophysiology of sulfonamide-induced myopia and angle closure glaucoma has yet to be elucidated. In this case, the occurrence and clinical course of induced myopia and bilateral angle closure glaucoma after ingestion of methazolamide is reported. This represents the second report of methazolamide-induced angle closure glaucoma to be described in the literature.

## Material and methods

This study presents a case report and literature review. This study was conducted in accordance with the tenets of the Declaration of Helsinki.

## Results

A 70-year-old Haitian male presented to the Bascom Palmer Eye Institute (Miami, FL, USA) emergency room complaining of markedly decreased vision and pain in both eyes since the morning of presentation. His past ocular history was significant for medically controlled

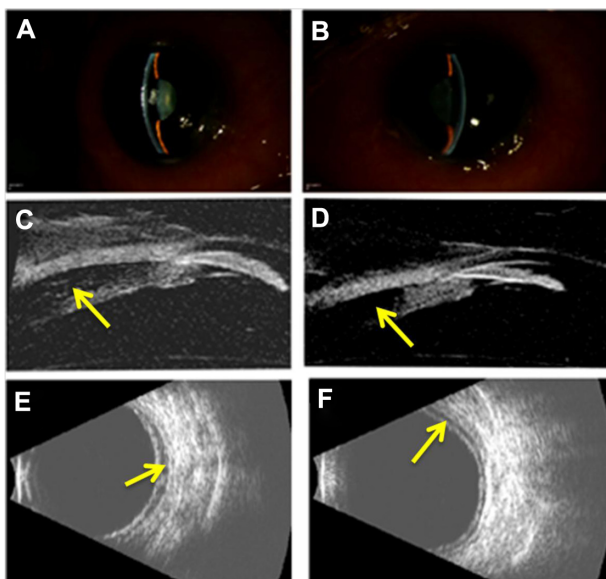
Correspondence: Ahmad A Aref  
Illinois Eye and Ear Infirmary, University of Illinois at Chicago School of Medicine, 1855 W Taylor St, Suite 3.171, Chicago, IL 60612, USA  
Tel +1 312 996 7030  
Fax +1 312 413 8574  
Email aaref@uic.edu

normal tension glaucoma. The patient's systemic medical history was significant for hypertension and noninsulin dependent diabetes mellitus. His systemic medications included metformin, amlodipine, olmesartan, and aspirin. On the patient's most recent clinic visit to Bascom Palmer Eye Institute 2 days prior to presentation, visual acuity measured 20/30 in each eye and intraocular pressure (IOP) measured 8 mmHg in each eye in the setting of advanced optic nerve cupping. The patient was noted to have a follicular conjunctivitis consistent with brimonidine toxicity. Since the patient had been maximized on tolerated topical IOP-lowering therapy, an oral agent was exchanged with brimonidine. Methazolamide, rather than acetazolamide, was instituted in order to decrease the risk of systemic side effects.<sup>4</sup> Twice daily frequency was initiated according to the drug's package insert.<sup>5</sup> The patient ingested one tablet the night prior to presentation and one tablet the following morning.

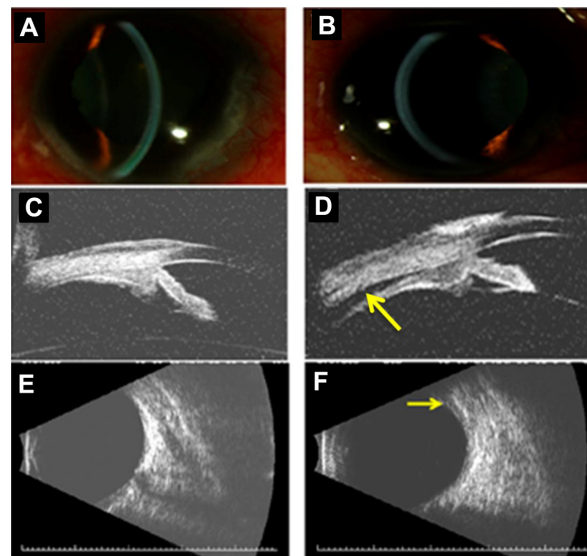
On examination, the patient's best-corrected visual acuity was reduced to 20/200 in the right eye and counting fingers at 2 feet in the left eye. Manifest refraction revealed an error of  $-2.00 + 1.00 \times 135$  in the right eye and  $-2.00 + 1.00 \times 026$  in the left eye. IOP by standard Goldmann applanation tonometry (Model AT 900, Haag-Streit USA, Mason, OH, USA) was 35 mmHg in each eye. Slit-lamp examination (B900, Haag-Streit USA, Mason, OH, USA) revealed marked conjunctival chemosis, mild microcystic

corneal edema, and shallow anterior chamber in each eye (Figure 1A and B). High-frequency (35 MHz) ultrasound biomicroscopy (UBM; Model P60, Paradigm Medical Industries, Salt Lake City, UT, USA) confirmed shallow anterior chambers and also revealed anterior displacement of the lens-iris diaphragm associated with ciliary body edema and a prominent ciliochoroidal effusion in each eye (Figure 1C and D). Posterior B-scan ultrasonography (Eye Cubed, Ellex, Inc., Minneapolis, MN, USA) revealed posterior choroidal effusions (Figure 1E and F).

Methazolamide-induced myopia and angle closure glaucoma were diagnosed and the drug was immediately discontinued. The patient's regular topical ocular hypotensive medical regimen (consisting of 0.1% brimonidine in both eyes twice daily, 2% dorzolamide/0.5% timolol in both eyes twice daily, and 0.005% latanoprost in both eyes every evening) was continued. In addition, the patient was placed on 1% atropine in both eyes twice daily and 1% prednisolone acetate in both eyes four times daily. By the patient's 1-week follow-up examination, best-corrected visual acuity improved to 20/50 in the right eye and 20/60 in the left eye. Manifest refraction revealed an error of plano  $+0.75 \times 075$  D in the right eye and  $+0.50 + 0.75 \times 075$  D in the left eye. IOP now measured 4 mmHg in the right eye and 3 mmHg in the left eye. Slit-lamp examination revealed deepening of each



**Figure 1** Slit-lamp photographs of the right (A) and left (B) eye demonstrating moderate peripheral and central anterior chamber shallowing after recent ingestion of methazolamide. High-frequency (35 MHz) ultrasound biomicroscopy reveals anterior displacement of the lens-iris diaphragm due to ciliary body edema and supraciliary effusion (arrows) in the right (C) and left (D) eye. Anterior chamber depth measured 1.2 mm in each eye and lens thickness measured 4.8 mm and 4.9 mm in the right and left eye, respectively. B-scan ultrasonography revealed shallow posterior choroidal effusions (arrows) in the right (E) and left (F) eye.



**Figure 2** Slit-lamp photographs of the right (A) and left (B) eye demonstrating relative deepening of the anterior chambers after discontinuation of methazolamide. High-frequency (35 MHz) ultrasound biomicroscopy reveals resolution of ciliary body edema and supraciliary effusion in the right eye (C) and near complete resolution (arrow) in the left eye (D). Anterior chamber depth measured 2.7 mm and 2.3 mm in the right and left eye, respectively. Lens thickness measured 4.7 mm and 4.9 mm in the right and left eye, respectively. B-scan ultrasonography reveals complete resolution of the posterior choroidal effusion in the right eye (E) and a small persistent effusion (arrow) in the left eye (F).

anterior chamber (Figure 2A and B) and high-frequency UBM revealed posterior displacement of the lens–iris diaphragm with normal ciliary body architecture (Figure 2C and D). The supraciliary effusion of the right eye had completely resolved while a small supraciliary effusion remained in the left eye. Posterior B-scan ultrasonography also revealed complete resolution of the posterior choroidal effusion in the right eye with a small choroidal effusion noted in the left eye (Figure 2E and F). Slow resolution of the patient's posterior choroidal effusions may have contributed to the patient's reduction in visual acuity compared to baseline levels of 20/30 in each eye. The patient's atropine and brimonidine were discontinued and he was continued on all other topical medications. The patient's topical prednisolone acetate was slowly tapered over several months.

## Discussion

Sulfonamide-induced myopia and angle closure were first described by Korol in 1962.<sup>6</sup> Since then, a number of sulfonamide-derived medications have been associated with secondary myopia and angle closure glaucoma.<sup>1</sup> Lee et al describe a 62-year-old female who awakened with bilateral acute vision loss 1 day after ingesting a prophylactic dose of 250 mg acetazolamide following uncomplicated cataract extraction. She was diagnosed with acute bilateral angle closure glaucoma and the episode resolved upon discontinuation of acetazolamide.<sup>7</sup>

Similar to acetazolamide, methazolamide is a sulfonamide-derived carbonic anhydrase inhibitor. The drug is available as 25 mg and 50 mg tablets, dosed twice daily. Unlike acetazolamide, methazolamide is metabolized by the liver and therefore has a longer, 14-hour half-life. The risk of systemic side effects such as nephrolithiasis and metabolic acidosis is also lessened with methazolamide. Kwon et al recently described the first case of methazolamide-induced angle closure in a 51-year-old male treated with the agent for refractory diabetic macular edema.<sup>2</sup> Sulfonamide-induced angle closure and myopia have not been reported in association with topical carbonic anhydrase inhibitors. In the current case, the patient had tolerated topical dorzolamide for several years. Therefore, this agent was deemed to be safe for long-term IOP control once methazolamide was discontinued.

Two theories prevail regarding the pathophysiology of sulfonamide-induced angle closure glaucoma. Sen et al postulate that an osmotic disturbance within the lens leads to lens hydration, thickening, and anterior displacement of the lens–iris diaphragm.<sup>8</sup> Craig et al proposes a theory of

sulfonamide-induced ciliary body edema with supraciliary effusion leading to forward rotation of the ciliary body and mechanical angle closure.<sup>9</sup> Although both an osmotic disturbance within the lens and ciliary body edema are likely to contribute to this process, the current case supports the latter theory as UBM-measured lens thickness did not change appreciably before and after institution of treatment and subsequent anterior chamber deepening. The entity may be dose dependent as prior cases of topiramate-induced angle closure occurred only upon doubling the dose of the drug.<sup>3</sup> The patient described herein may have indeed tolerated a 25 mg dose of methazolamide, but given his reaction, he was not rechallenged with the agent.

The diagnosis of sulfonamide-induced angle closure glaucoma remains a clinical one, which is aided by the temporal relationship to sulfonamide ingestion. In the current case, the patient's history and UBM findings allowed a Naranjo score of seven to be assigned, indicating a probable adverse drug reaction.<sup>10</sup> Although the magnitude of the patient's induced myopia may have been blunted by corneal edema, resolution of this refractive error with discontinuation of the drug also supported the diagnosis.

The differential diagnosis of acute, bilateral angle closure glaucoma can be divided into pupillary block (eg, anatomically narrow angles, anticholinergic or sympathomimetic use, inflammatory membrane occluding the pupil) and nonpupillary block mechanisms (eg, sulfonamide-induced, plateau iris syndrome, annular choroidal effusion). As demonstrated in the current case, high-frequency UBM is helpful in differentiating between these causes and typically reveals bilateral ciliary body edema and supraciliary effusion with forward displacement of the lens–iris diaphragm.

The mainstay of treatment of sulfonamide-induced angle closure glaucoma is consultation with the prescribing physician and discontinuation of the offending agent as soon as possible. Maximum IOP-lowering therapy (with exception to systemic sulfonamide derivatives and miotic agents) should be instituted. The uveal effusions associated with this process are thought to have an underlying inflammatory mechanism, thus anti-inflammatory treatment is also recommended. Laser iridotomy is not indicated as sulfonamide-induced angle closure does not occur secondary to pupillary block. Topical miotic agents are contraindicated as these may lead to further anteriorization of the lens–iris diaphragm, aggravating the episode.<sup>3</sup>

## Conclusion

In conclusion, sulfonamide ingestion is an important cause of acute, bilateral angle closure. The patient's medication

list should be reviewed carefully in these cases and methazolamide should be considered as a potential cause of this condition.

## Acknowledgments

RKL is supported by NIH NEI grant EY016775. The Bascom Palmer Eye Institute is supported by an unrestricted research grant from Research to Prevent Blindness and NIH center grant EY014801.

## Disclosure

The authors report no conflicts of interest in this work.

## References

- Panday VA, Rhee DJ. Review of sulfonamide-induced acute myopia and bilateral angle-closure glaucoma. *Compr Ophthalmol Update*. 2007;8(5): 271–276.
- Kwon SJ, Park DH, Shin JP. Bilateral transient myopia, angle-closure glaucoma, and choroidal detachment induced by methazolamide. *Jpn J Ophthalmol*. 2012;56(5):515–517.
- Fraunfelder FW, Fraunfelder FT, Keates EU. Topiramate-associated acute, bilateral, secondary angle-closure glaucoma. *Ophthalmology*. 2004;111(1):109–111.
- Lichter PR. Reducing side effects of carbonic anhydrase inhibitors. *Ophthalmology*. 1981;88(3):266–269.
- Fera Pharmaceuticals. Neptazane® (methazolamide tablets) tablet [package insert]. Locust Valley, NY: Fera Pharmaceuticals; 2010.
- Korol EA. [Transitory myopia in combination with transitory glaucoma]. *Zdravookhr Beloruss*. 1962;8:66–67. Belorussian.
- Lee GC, Tam CP, Danesh-Meyer HV, Myers JS, Katz LJ. Bilateral angle closure glaucoma induced by sulphonamide-derived medications. *Clin Experiment Ophthalmol*. 2007;35(1):55–58.
- Sen HA, O'Halloran HS, Lee WB. Case reports and small case series: topiramate-induced acute myopia and retinal striae. *Arch Ophthalmol*. 2001;119(5):775–777.
- Craig JE, Ong TJ, Louis DL, Wells JM. Mechanism of topiramate-induced acute-onset myopia and angle closure glaucoma. *Am J Ophthalmol*. 2004;137(1):193–195.
- Naranjo CA, Busto U, Sellers EM, et al. A method for estimating the probability of adverse drug reactions. *Clin Pharmacol Ther*. 1981;30(2): 239–245.

### Clinical Ophthalmology

### Publish your work in this journal

Clinical Ophthalmology is an international, peer-reviewed journal covering all subspecialties within ophthalmology. Key topics include: Optometry; Visual science; Pharmacology and drug therapy in eye diseases; Basic Sciences; Primary and Secondary eye care; Patient Safety and Quality of Care Improvements. This journal is indexed on

Submit your manuscript here: <http://www.dovepress.com/clinical-ophthalmology-journal>

### Dovepress

PubMed Central and CAS, and is the official journal of The Society of Clinical Ophthalmology (SCO). The manuscript management system is completely online and includes a very quick and fair peer-review system, which is all easy to use. Visit <http://www.dovepress.com/testimonials.php> to read real quotes from published authors.