



# LUND UNIVERSITY

## New score indicating placental vascular resistance.

Gudmundsson, Saemundur; Korszun, Przemyslaw; Olofsson, Per; Dubiel, Mariusz

*Published in:*  
Acta Obstetrica et Gynecologica Scandinavica

*DOI:*  
[10.1034/j.1600-0412.2003.00203.x](https://doi.org/10.1034/j.1600-0412.2003.00203.x)

2003

[Link to publication](#)

*Citation for published version (APA):*  
Gudmundsson, S., Korszun, P., Olofsson, P., & Dubiel, M. (2003). New score indicating placental vascular resistance. *Acta Obstetrica et Gynecologica Scandinavica*, 82(9), 807-812. <https://doi.org/10.1034/j.1600-0412.2003.00203.x>

### General rights

Copyright and moral rights for the publications made accessible in the public portal are retained by the authors and/or other copyright owners and it is a condition of accessing publications that users recognise and abide by the legal requirements associated with these rights.

- Users may download and print one copy of any publication from the public portal for the purpose of private study or research.
- You may not further distribute the material or use it for any profit-making activity or commercial gain
- You may freely distribute the URL identifying the publication in the public portal

### Take down policy

If you believe that this document breaches copyright please contact us providing details, and we will remove access to the work immediately and investigate your claim.

LUND UNIVERSITY

PO Box 117  
221 00 Lund  
+46 46-222 00 00

# New score indicating placental vascular resistance

SAEMUNDUR GUDMUNDSSON, PRZEMYSŁAW KORSZUN, PER OLOFSSON AND MARIUSZ DUBIEL

From the Department of Obstetrics and Gynecology, University of Lund, University Hospital, Malmö, Sweden

Acta Obstet Gynecol Scand 2003; 82: 807–812. © Acta Obstet Gynecol Scand 82 2003

**Background.** Umbilical artery Doppler velocimetry is a routine method for fetal surveillance in high-risk pregnancy. Uterine artery Doppler seems to give comparable information, but it can be difficult to interpret as there are two arteries, which might show notching and/or increased pulsatility index (PI) as signs of increased vascular impedance. Combining the information on vascular resistance on both sides in a new score might simplify and improve evaluation of placental circulation.

**Methods.** Uterine and umbilical artery Doppler velocimetry was evaluated in 633 high-risk pregnancies. The managing clinician was informed only about the umbilical artery flow. The umbilical artery flow spectrum was semiquantitatively divided into four blood flow classes (BFC), expressing signs of increasing vascular resistance. The uterine artery Doppler flow spectrum was divided into five uterine artery scores (UAS), taking into account presence/absence of notching and/or increase in PI. By adding UAS to BFC, a new placental score (PLS) was constructed with values ranging from 0 to 7, indicating general placental vascular resistance. The scores were related to three outcome variables: small-for-gestational age (SGA), premature delivery (<37 weeks), and cesarean section.

**Results.** All three score systems showed a significant relationship between signs of increasing vascular resistance and outcome. The new PLS showed the best association to adverse outcomes, with optimal cut-off at values exceeding score 3.

**Conclusion.** Doppler velocimetry on both sides of the placenta showed a strong relationship to an adverse outcome of pregnancy. The new PLS showed a better relationship to adverse perinatal outcome than the BFC and the UAS. The PLS can simplify evaluation of uteroplacental and fetoplacental Doppler velocimetry.

**Key words:** blood flow, Doppler; growth restriction; placenta; pregnancy

Submitted 07 August, 2002

Accepted 08 January, 2003

Doppler ultrasound has developed to become a valuable tool to evaluate the fetal and uteroplacental circulation and assist in predicting fetal well-being. In pregnancies suspected of intrauterine growth restriction (IUGR), umbilical artery Doppler velocimetry guides in the selection of those cases that need vigilant fetal surveillance and those that most promptly need to be delivered. In comparison with cardiotocography for fetal surveillance, the use of Doppler velocimetry in high-risk pregnancies has substantially helped to reduce the cost of care (1).

Characteristic physiological changes develop in placental bed vessels during normal pregnancy

(2). In early pregnancy, placental trophoblast cells invade the underlying spiral and radial arteries and transform the vessel wall structure with smooth muscle cells to become large flaccid dilated channels without contractile properties. These physiological changes are the basis for the development and increase in uterine artery blood flow during normal pregnancy: from 50 ml/min in early pregnancy to 700 ml/min at term (3,4). The conversion of subplacental vessels is partly or totally absent in pregnancies complicated by IUGR or pre-eclampsia (2,5).

In 1983, Campbell and coworkers (6) first presented data on utero-placental blood flow. They

studied the arcuate arteries. A 'notch' in early diastole was then first described as a marker of increased utero-placental vascular resistance. However, in a prospective study on pregnancies complicated by IUGR, the arcuate artery velocimetry had a lower positive predicted value on adverse perinatal outcome than the umbilical artery velocimetry (7). A contributing factor might be that a single arcuate artery represents only approximately 10% of the placental circulation. Recent research has therefore focused on blood flow in the main uterine arteries. In the early studies, the uterine artery was blindly located by continuous wave Doppler technology. The initial results were, however, disappointing. After the introduction of color Doppler imaging, the uterine arteries can easily be localized and blood velocity recorded by pulsed wave methodology. An increased utero-placental vascular resistance is a significant finding associated with complications like preterm delivery, small-for-gestational age (SGA) newborns, and operative delivery (8).

There have been several attempts to simplify the description of placental vascular resistance for use in clinical practice, describing blood flow on one or both sides of the placenta (7–9). The information provided by vascular resistance indices and presence of a unilateral or bilateral waveform notch can, however, be difficult to grasp and use in routine practice. In order to simplify the description of placental vascular resistance and combine velocimetries in fetal and maternal vessels, a new placental score system was developed and assessed in a prospective study on high-risk pregnancies.

## Materials and methods

The study comprised 633 pregnant women who were referred for Doppler examination as part of perinatal surveillance in high-risk pregnancies: pregnancy-induced hypertension (PIH), defined as a systolic and/or diastolic blood pressure increased by at least 30 and 15 mmHg, respectively, after 20 weeks of gestation, or pre-eclampsia (blood pressure of 140/90 mmHg and proteinuria (>0.3 g/l urine) ( $n = 121$ ), suspected IUGR (fetal weight >2 SD below the expected mean of the reference population) ( $n = 112$ ), vaginal bleeding ( $n = 68$ ), oligohydramnios (amniotic fluid index <50 mm) ( $n = 61$ ), post-term pregnancy (= 42 weeks) ( $n = 62$ ), diabetes mellitus ( $n = 45$ ), decreased fetal movements or history of previous history of perinatal death, IUGR or PIH ( $n = 67$ ).

Examinations were performed with a 3.5-MHz ultrasound 125 XP real-time sector scanner

(Acuson Comp., Mountainview, CA). A pulse-waved Doppler with color Doppler options was used. The umbilical artery blood velocity signals were obtained from a free-floating central part of the cord. Three subsequent blood velocity waveforms were analyzed for pulsatility index (PI) according to Gosling et al. (10). The results were related to reference values (11) with calculation also of the mean +3 SD limit, as shown in Fig. 1. The spectrum of maximum blood velocity in the umbilical artery was divided into four semiquantitative blood flow classes (BFC) based on the waveform pattern, as modified after Laurin et al. (12) (Table I).

Both uterine arteries were localized by color flow mapping in an oblique scan, and blood flow velocity was recorded in the artery just cranial to the crossing of the uterine artery central to the iliac artery. The pattern of an early diastolic notch in the uterine blood velocity spectrum was registered as described by Campbell et al. (6). A notch was defined as a decrease in blood velocity in early diastole, which is below the diastolic peak velocity.

Uterine artery vascular impedance Doppler velocimetry was defined as increased if the PI was >1.20 after 24 weeks of gestation, as according to Hofstaetter et al. (8). The uterine artery blood flow velocity waveforms were divided into five uterine artery scores (UAS) depending on the presence of an increased PI and/or presence of an early diastolic notch, as according to Sekizuka et al. (13) (Table I).

The UAS and the BFC were combined to form a placental score (PLS) as an expression of

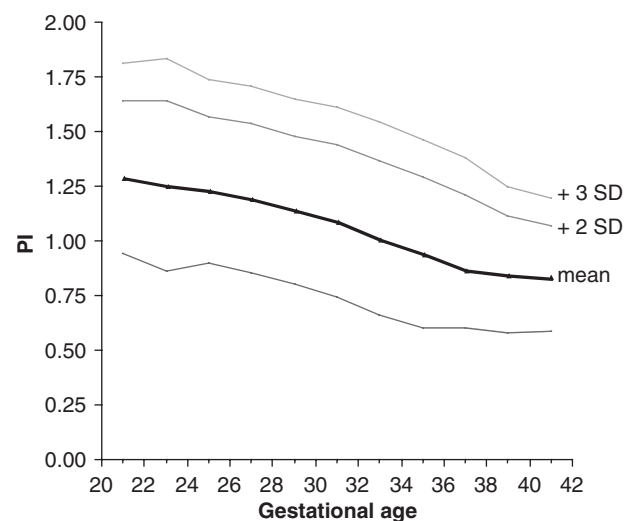


Fig. 1. Normal reference curve for umbilical artery pulsatility index (PI) relative to gestational age. Mean and  $\pm 2$  SD and +3 SD are indicated. Rearranged from Gudmundsson and Marsal, *Acta Obstet Gynecol Scand*, 1988; 67: 347–54.

Table I. Definition of blood flow class and uterine artery score

Blood flow class	
0	= normal umbilical artery blood flow velocity waveforms
1	= PI between 2 and 3 SD above the mean
2	= PI > + 3 SD and forward flow in diastole
3	= absent end-diastolic flow or reversed flow
Uterine artery score	
0	= normal blood velocity waveforms in both arteries
1	= one abnormal parameter present (high PI or notch)
2	= two abnormal parameters present
3	= three abnormal parameters present
4	= four abnormal parameters present (i.e. high PI and notching in both arteries)

PI = pulsatility index; SD = standard deviation.

general placental vascular resistance: PLS = BFC + UAS, with figures in the range 0 to 7. The managing clinician was informed about the result of the umbilical artery Doppler velocimetry, but not of the uterine artery results.

Serial examinations were often performed with intervals of less than 3 weeks. The median gestational age at the last examination was 35 completed weeks (range 23–43) and at delivery 37 weeks (range 27–43). The median time interval between examination and delivery was 1 week (range 0–26 weeks). The result of the last examination before delivery was related to three perinatal outcome variables: premature delivery (birth before 37 completed weeks of gestation), SGA newborns [birthweight less than mean –2 SD of the normals (14)], and delivery by cesarean section (irrespective of elective or emergency operation).

Descriptive statistics in terms of mean and range were calculated. Sensitivity, specificity, positive- and negative-predictive values were also calculated. Receiver operating characteristic (ROC) curves were drawn for each diagnostic test (i.e. BFC, UAS and PLS) to evaluate its ability to discriminate the likelihood of developing adverse perinatal outcome (15). Area under the curve and 95% confidence intervals (CI) were calculated using the statistical computer program MedCalc version 6.00.014. If the lower limit of the CI for the area under the ROC curve was more than 0.5, the diagnostic test was considered to be able to predict adverse perinatal outcome (16,17).

## Results

Of 633 cases in total, 92 (14.1%) had an increased PI in the umbilical artery (BFC 1–3) and 348 (55%) showed signs of a high vascular resistance in the uterine arteries (UAS 1–4). Table II illustrates the distribution of cases according to UAS and BFC. A normal umbilical artery blood vel-

Table II. Case distribution of umbilical blood flow class and uterine artery score

	UAS				
BFC	0	1	2	3	4
0	275	67	108	73	18
1	3	2	15	14	11
2	7	6	9	9	8
3	0	0	1	3	4

BFC = blood flow class; UAS = uterine artery score.

ocity waveform was found in 266 cases with signs of increased vascular resistance in the uterine circulation. Only 10 out of 92 cases with increased vascular resistance in the umbilical artery (BFC 1–3) had normal uterine artery waveform.

At delivery there were 178 (28%) SGA newborns and 60 (9.4%) preterm deliveries. There were a total of 221 cesarean sections (34.5%). Table III gives the distribution of complications within PLS. Figures 2–4 illustrate the relationship between the occurrences of SGA newborns, premature delivery, cesarean section, and the different blood flow scores.

Figure 5 illustrates the ROC areas for the different scores in relationship to SGA. The areas under the curve for PLS (0.76; CI = 0.72–0.79) and UAS (0.73; CI = 0.69–0.76) were significantly larger than those for the BFC (0.66; CI = 0.62–0.70);  $p < 0.0001$  and  $p < 0.002$ , respectively. For cesarean section and prematurity, the PLS had only a significantly larger area under the curve (0.71; CI = 0.68–0.75) than the BFC (0.63; CI = 0.59–0.67);  $p < 0.002$  and  $p < 0.002$ , respectively.

## Discussion

The present prospective observational study results indicate that evaluating vascular flow resistance on both sides of the placenta may improve the diagnostic power when evaluating fetal growth restriction. Signs of an increased

Table III. Adverse perinatal outcome in relationship to placental score

PLS	<i>n</i> 633	SGA 175	C-section 224	Premature 146
0	281	33	60	33
1	67	12	24	15
2	112	36	32	21
3	95	35	42	27
4	43	28	33	27
5	21	19	19	11
6	10	8	10	8
7	4	4	4	4

PLS = placental score; SGA = small-for-gestational age; premature = delivery < 37 weeks.

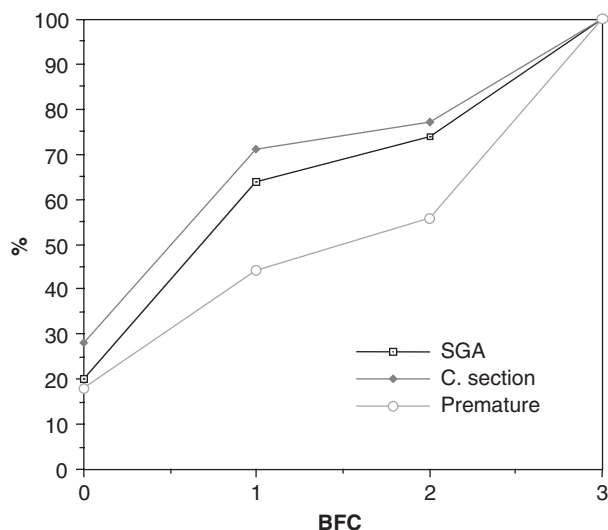


Fig. 2. Umbilical artery blood flow class (BFC) relative to adverse outcome of pregnancy, defined as small for gestational age (SGA), cesarean section, and preterm birth (<37 weeks).

vascular flow resistance were four-fold more common on the maternal side than on the fetal side of the placenta. An increase in fetoplacental vascular resistance was nearly four-fold more frequent in the uterine than umbilical artery. This might suggest that an increase in vascular flow resistance might develop and be detected earlier in the uteroplacental circulation than in the fetoplacental circulation. In our experience, the uterine artery Doppler spectrum is usually unchanged from 24 weeks of gestation. Umbilical artery Doppler spectrum, however, often shows signs of increasing vascular resistance with time,

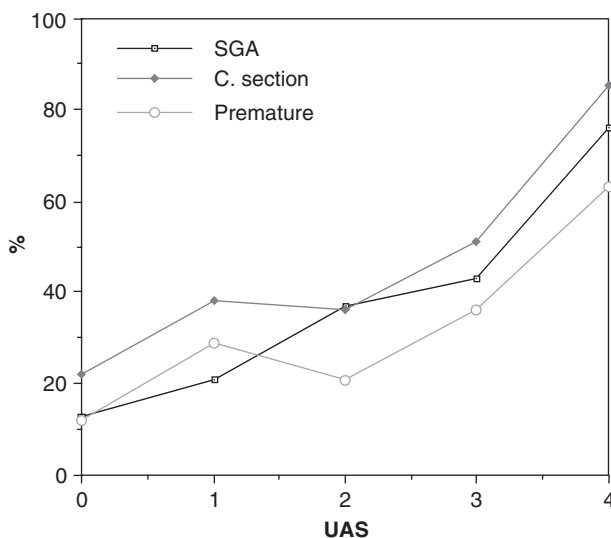


Fig. 3. Uterine artery score (UAS) relative to adverse outcome of pregnancy, defined as small for gestational age (SGA), cesarean section, and preterm birth.

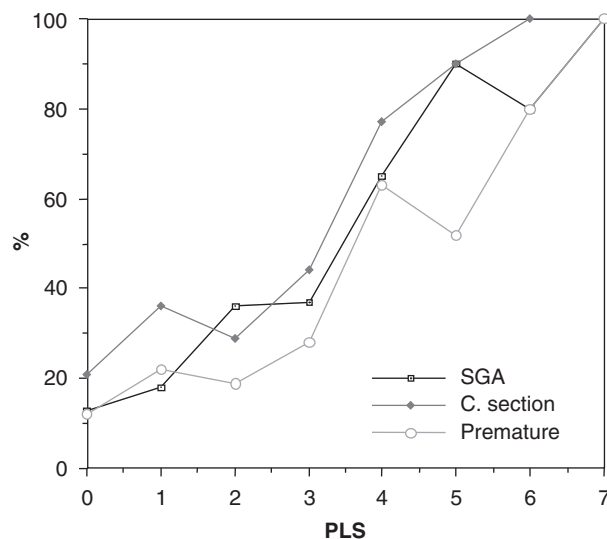


Fig. 4. Frequency of small for gestational age (SGA), cesarean section, and preterm birth relative to placental score (PLS).

signs strongly related to worsening fetal condition. The information provided by uterine artery Doppler velocimetry alone can thus not replace the umbilical artery Doppler velocimetry. Although, the highest score of increased uteroplacental vascular resistance (UAS 4) was found to be comparable to absent or reversed end-diastolic (ARED) flow in the umbilical artery (Figs 3 and 4).

The present study comprises a heterogeneous group of high-risk pregnancies. The aim was to relate the new scores to well-defined outcome

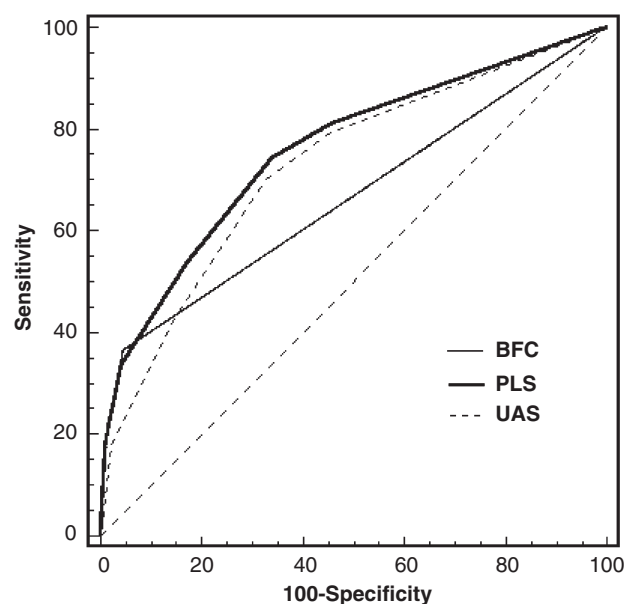


Fig. 5. Receiver operating characteristic curves for placental score (PLS), uterine artery score (UAS) and blood flow class (BFC) relative to SGA.

variables of clinical surveillance for high-risk pregnancies. Although the vast majority were complicated by pre-eclampsia and/or intrauterine growth restriction, less heterogeneous study material might give even better results.

The new uterine artery score does not take into account the location of the placenta. This is based on our previous results (8), suggesting that the mean of both vessels is as reliable. Defining placenta location by ultrasound is not always easy because it might be somewhat more on one side. Not taking the location of the placenta into account makes evaluation easier in the clinical setting.

The grouping of the umbilical artery blood velocity waveform patterns into the BFC is a semiquantitative grouping that has the advantage of being easy to grasp and use in everyday clinical work. The vascular flow resistance in the umbilical artery is usually grouped into normal blood velocity waveforms, increased PI with forward flow in diastole, and ARED flow. In our unit, the umbilical artery waveform has been grouped into four categories, with inclusion of a fourth intermediate class (BFC 2), describing a  $PI > 3$  SD above the mean, and forward flow in diastole. This class describes a severe increase in fetoplacental vascular resistance, although considerably less severe than ARED flow (BFC 3).

The spectrum of uterine artery blood velocity is usually analyzed for the presence of an early diastolic notch and for pulsatility or resistance indices. It is controversial which of the uterine arteries best represents the placental bed circulation on the placental or nonplacental side. Attempts have previously been made to classify uterine artery vascular resistance (7–9). The UAS was first proposed in 1997 (13). As for the umbilical artery BFC, this score system is easy to use in clinical practice. In the present study we tried to further develop the evaluation of placental vascular resistance. The PLS is a measure of general placental vascular resistance, which simplifies the evaluation of Doppler velocimetry on both sides of the placenta. This is a new classification that might further improve fetal surveillance.

In conclusion, Doppler ultrasound is an invaluable tool for understanding the physiologic and pathophysiologic changes in the maternal and fetal circulation in pregnancy. Its use, notably examination of blood flow in the umbilical artery, is already an established part of clinical practice. The present study further supports the clinical value of uterine artery Doppler in high-risk pregnancies. Adding uterine artery Doppler velocimetry and creating the PLS for detection of increased placental vascular resistance further improved the detection power.

## Acknowledgments

The Medical Faculty, University of Lund; the Swedish Society of Medicine; funds from the University Hospital Malmö; and Region Skåne funds supported the study. Statistician Jan-Åke Nilsson is gratefully acknowledged for his expert assistance.

## References

1. Almstrom H, Axelsson O, Cnattingius S, Ekman G, Maesel A, Ulmsten U et al. Comparison of umbilical-artery velocimetry and cardiotocography for surveillance of small-for-gestational-age fetuses. *Lancet* 1992; 340: 936–40.
2. Brosens I, Robertson WB, Dixon HG. The physiological response of the vessels of the placental bed to normal pregnancy. *J Pathol Bact* 1967; 93: 569–79.
3. Assali NS, Rauramo L, Peltonen T. Measurement of uterine blood flow and uterine metabolism. *Am J Obstet Gynecol* 1960; 79: 86–98.
4. Metcalfe J, Romney SL, Ramsey LH, Reid DE, Burvell CS. Estimation of uterine blood flow in normal human pregnancy at term. *J Clin Invest* 1955; 34: 1632–8.
5. Olofsson P, Laurini R, Marsal M. A high uterine artery pulsatility index reflects a defective development of placental bed spiral arteries in pregnancies complicated by hypertension and fetal growth retardation. *Eur J Obstet Gynecol Reprod Biol* 1993; 49: 161–8.
6. Campbell S, Diaz-Recasens J, Griffin D, Cohen-Overbeek T, Pearce J, Wilson K et al. New Doppler technique for assessing utero-placental blood flow. *Lancet* 1983; 1: 675–7.
7. Gudmundsson S, Marsal K. Umbilical and uteroplacental blood flow velocity waveforms in pregnancies with fetal growth retardation. *Eur J Obstet Gynecol Reprod Biol* 1988; 27: 187–96.
8. Hofstaetter C, Dubiel M, Gudmundsson S, Marsal K. Uterine artery color Doppler assisted velocimetry and perinatal outcome. *Acta Obstet Gynecol Scand* 1996; 75: 612–9.
9. Hafner E, Schuchter K, Metznerbauer M, Philipp K. Uterine artery Doppler perfusion in the first and second pregnancy. *Ultrasound Obstet Gynecol* 2000; 16: 625–9.
10. Gosling R, Dunbar G, King D, Newman D, Side C, Woodcock J et al. The quantitative analysis of occlusive peripheral vascular disease by a non-invasive ultrasound technique. *Angiology* 1971; 22: 52–5.
11. Gudmundsson S, Marsal K. Umbilical artery and uteroplacental blood flow velocity waveforms in normal pregnancy – a cross-sectional study. *Acta Obstet Gynecol Scand* 1988; 67: 347–54.
12. Laurin J, Lingman G, Marsal K, Persson PH. Fetal blood flow in pregnancies complicated by intrauterine growth retardation. *Obstet Gynecol* 1987; 69: 895–902.
13. Sekizuka N, Hasegawa I, Takakuwa K, Tanaka K. Scoring of uterine artery flow velocity waveform in the assessment of fetal growth restriction and/or pregnancy-induced hypertension. *J Matern Fetal Invest* 1997; 7: 197–200.
14. Marsal K, Persson PH, Larsen T, Lilja H, Selbing A, Sultan B. Intrauterine growth curves based on ultrasonically estimated foetal. *Acta Paediatr* 1996; 85: 843–8.
15. Rickardson DK, Schwartz SJ, Weinbum PJ, Gabbe SG. Diagnostic test in obstetrics: a method for improved evaluation. *Am J Obst Gyn* 1985; 1152: 613–8.

16. Hanley JA, McNeil BJ. A method of comparing the areas under receiver operating characteristic curves derived from the same cases. *Radiology* 1983; 148: 839–43.
17. Hanley JA, McNeil BJ. The meaning and use of the area under a receiver operating characteristic (ROC) curve. *Radiology* 1982; 143: 29–36.

*Address for correspondence:*

Saemundur Gudmundsson  
Department of Obstetrics and Gynecology  
University Hospital MAS  
SE-205 02 Malmö  
Sweden  
e-mail: saemundur.gudmundsson@obst.mas.lu.se