

PDF hosted at the Radboud Repository of the Radboud University Nijmegen

The following full text is a publisher's version.

For additional information about this publication click this link.

<http://hdl.handle.net/2066/23617>

Please be advised that this information was generated on 2021-09-28 and may be subject to change.

Rapid Publication

CYTOGENETIC ABNORMALITIES IN TWO NEW PATIENTS WITH PITT-ROGERS-DANKS PHENOTYPE

M.C. Lindeman-Kusse, A. Van Haeringen, J.J.G. Hoorweg-Nijman, H.G. Brunner,

"De Hartekamp" and "De Hondenberg", Institutions for the Mentally Disabled, Heemstede and Oisterwijk (M.C.L.K.); Department of Clinical Genetics, University Hospital Leiden, Leiden (A.V.H.); Department of Endocrinology, Wilhelmina Childrens' Hospital, Utrecht, current adress: the Free University Hospital Amsterdam (J.J.G.H.N); Department of Human Genetics, University Hospital Nijmegen, Nijmegen (H.G.B), The Netherlands.

We describe 2 patients with a combination of findings strikingly similar to those described by Pitt et al. [1984], consisting of severe mental retardation, pre- and post-natal growth retardation, history of seizures, microcephaly, ocular proptosis, mid-face hypoplasia, short and flat philtrum, and wide mouth.

Our cases included, a total of only 9 patients has been described. One of our patients was treated with growth hormone and responded with a marked increase in growth velocity and skeletal maturation.

Chromosome analysis was performed; both patients have a deletion of 4p as is found in Wolf-Hirschhorn syndrome. A comparison is made between our patients and patients with the Wolf-Hirschhorn syndrome (4p-).

We conclude that the Pitt-Rogers-Danks phenotype is associated with 4p- in our two patients and that the syndromic status of the Pitt-Rogers-Danks status should be reassessed.

KEY WORDS: 4p-, Pitt-Rogers-Danks, Wolf-Hirschhorn, multiple congenital anomalies

INTRODUCTION

In 1984, Pitt et al. described 4 patients with the combination of pre- and postnatal growth retardation, mental retardation, typical facial changes with microcephaly, ocular proptosis, mid-facial hypoplasia, short and flat philtrum, wide mouth and history of seizures. Since

Address reprint requests to:
M.C. Lindeman-Kusse, MD
De Hartekamp
PO box 502, 2100 AM Heemstede
The Netherlands

Received for publication March 3, 1994.

then, 3 additional cases have been reported [Donnai, 1986; Oorthuys and Bleeker-Wagemakers, 1989; Lizcano-Gil et al., 1995].

Cytogenetic abnormalities were not found in any of the reported cases.

In this paper, we describe 2 strikingly similar cases. However, in both patients a deletion was found in the distal short arm of chromosome 4, the same region involved in the Wolf-Hirschhorn syndrome.

CLINICAL REPORTS

Patient A

Patient A (Fig. 1), a girl born in 1982, is the second of 2 children born to nonconsanguineous parents.

Her older brother and parents are healthy and family history is unremarkable. Her physical appearance does not resemble any relative.

During pregnancy ultrasound at 35 weeks showed intrauterine growth retardation for unknown reason. Delivery was normal and occurred at 37 weeks. Birthweight was 1880 g (<3rd centile). The postnatal period was complicated by poor feeding and persistent growth retardation. For this reason she was hospitalized from age 5 to 11 months during which period she was tube-fed. Results of EEG, ultrasound study of the brain and of metabolic tests were normal. At that time G-banded karyotype was normal, 46,XX. From 1986 to 1989 she had 5 seizures during periods of fever. The EEG suggested generalized epilepsy and she was treated with valproic acid.

Because of severe growth retardation (Fig. 2A) she was referred for endocrinologic evaluation at 4 7/12 years, which showed a normal growth hormone response (response to

arginine-HCL: peak 16 mU/L, response to L-Dopa propanolol: peak 93 mU/l). Serum IGF-1 levels were close to the lower normal limit for age (resp 75 and 77 ng/ml). Normal levels of T4, free T4 and TSH were found.

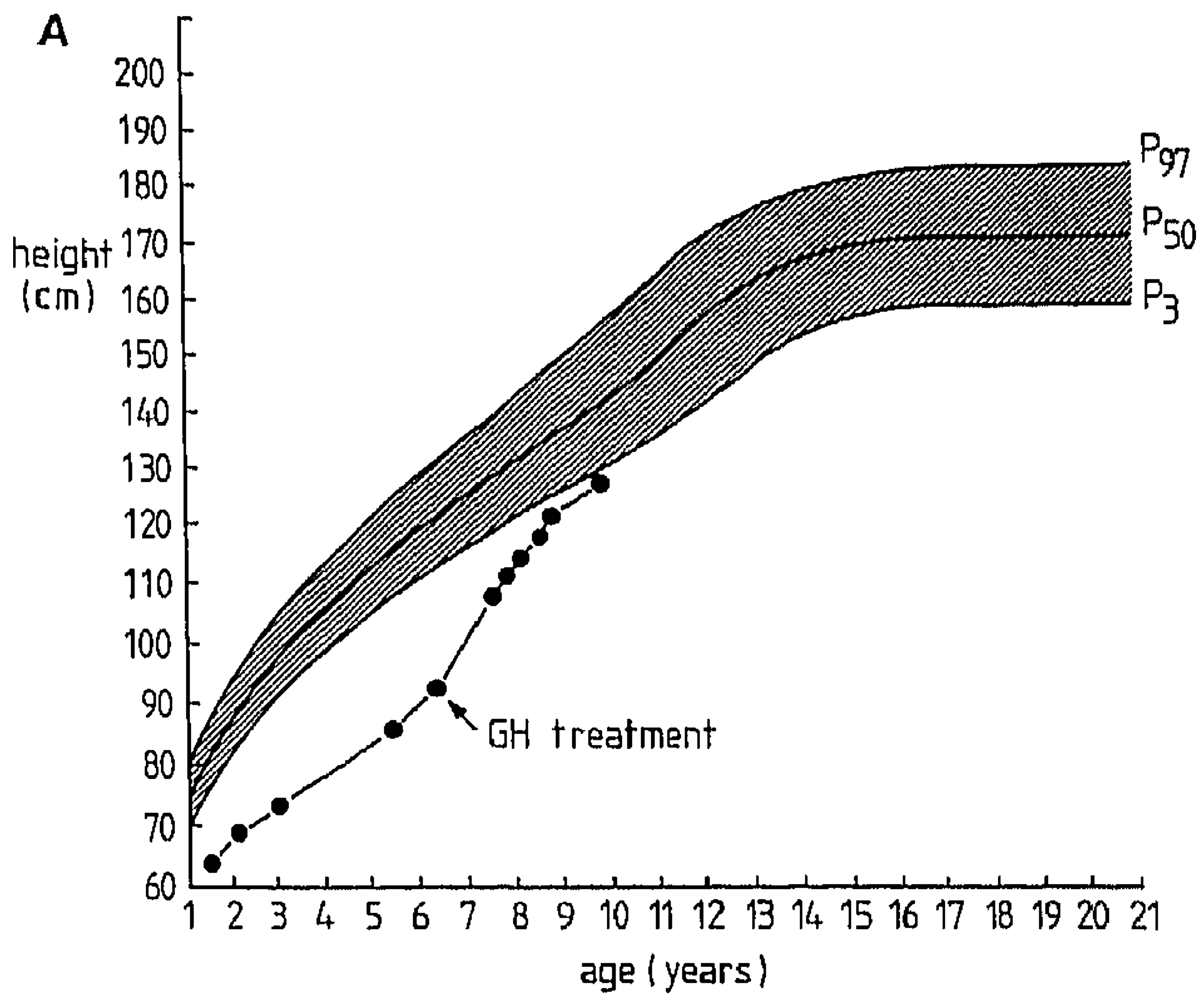
At age 6 4/12 years growth hormone (GH) treatment was initiated (Humatrope, Lilly, Indianapolis, USA) in a dosage of 4.5 IU/m² body surface per day, 6 times a week, in a clinical trial on children with idiopathic short stature [Kamp et al., 1991]. At the onset of GH treatment height was 94.0 cm, equivalent to a standard deviation score (SDS) of -5.3. Bone age was 2.0 years (according to Greulich and Pyle). She responded remarkably well to GH treatment, although bone age progressed rather rapidly as well. At age 9.3 years height was 123.5 cm (SDS -2.39) and bone age 8.3 years (Greulich-Pyle). Shortly thereafter puberty began. At age 10.3 years, height was 131.5 cm (height SDS -1.8) and bone age 9.8 years (Greulich-Pyle). Her predicted adult height increased from 148.9 to 153.1 cm. Despite adequate food intake her weight has always been low for height (Fig. 2C).

On examination she had a typical facial appearance (Fig. 1) with microcephaly (OFC 49 cm, 1 cm <3rd centile), hypertelorism (ICD 33 mm, OCD 90 mm, 90th centile), ocular proptosis, maxillary hypoplasia, a beaked nose, a short and flat philtrum, and a wide mouth with a thin upper lip. She had a preauricular pit on the right side. She had generalised muscular hypotrophy. Hands were small (13.5 cm, <3rd centile), but in contrast to previously reported patients, palmar creases were normal. Both feet had a wide space between first and second toe. On ophthalmological examination irregu-

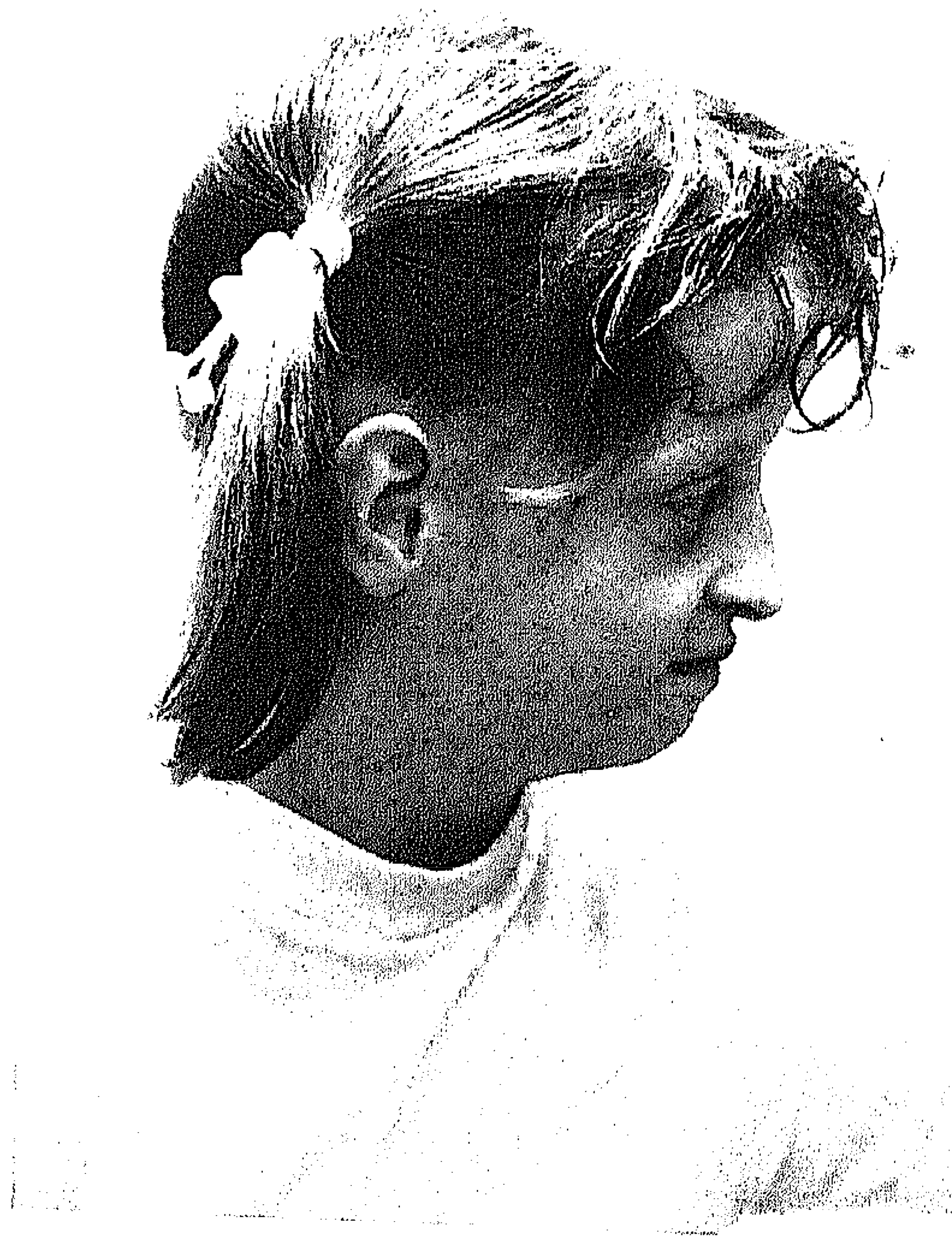
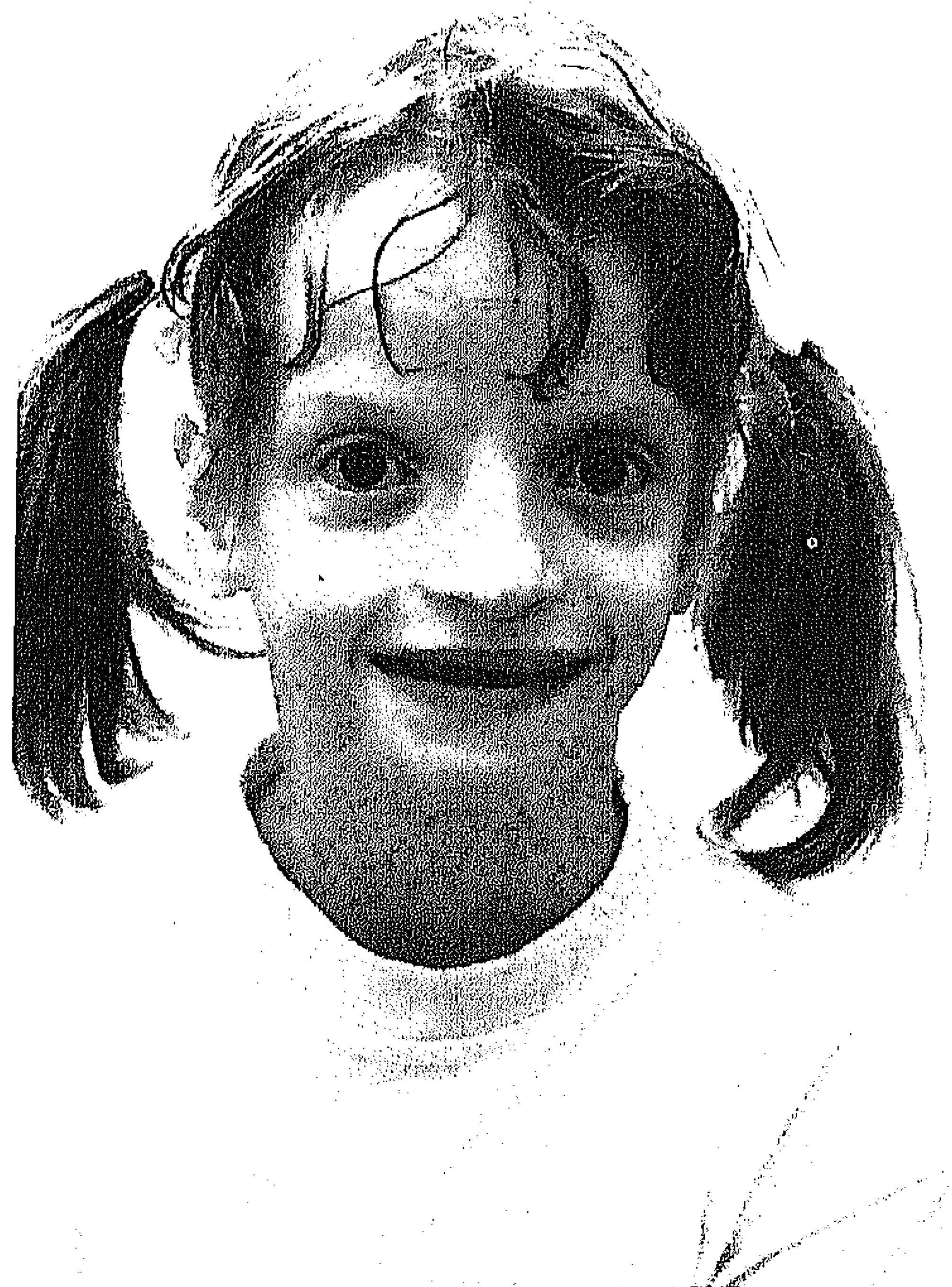
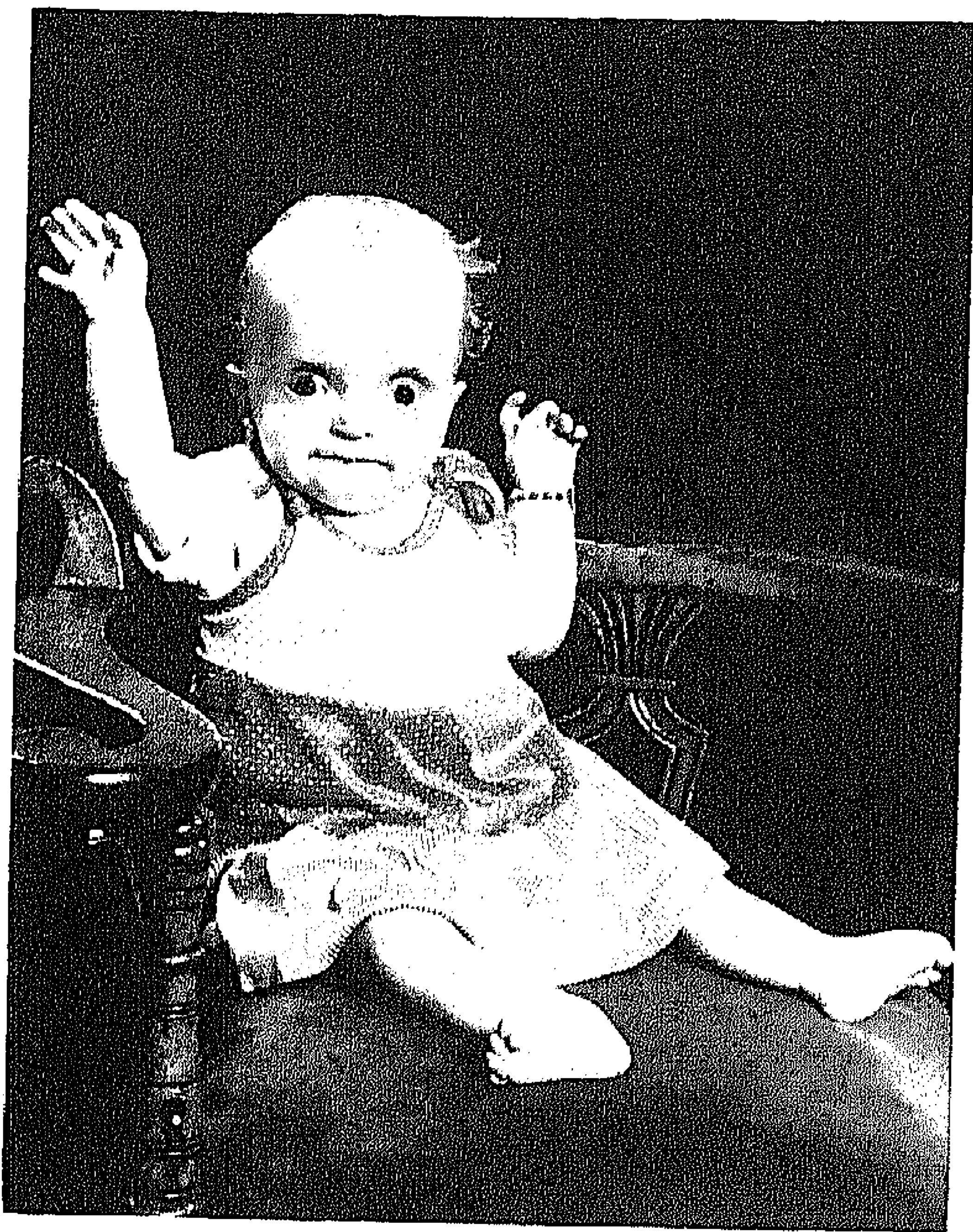Figure 1: Patient A at age 9 months, 3 and 10 years (frontal and side view), respectively

PATIENT A



PATIENT B

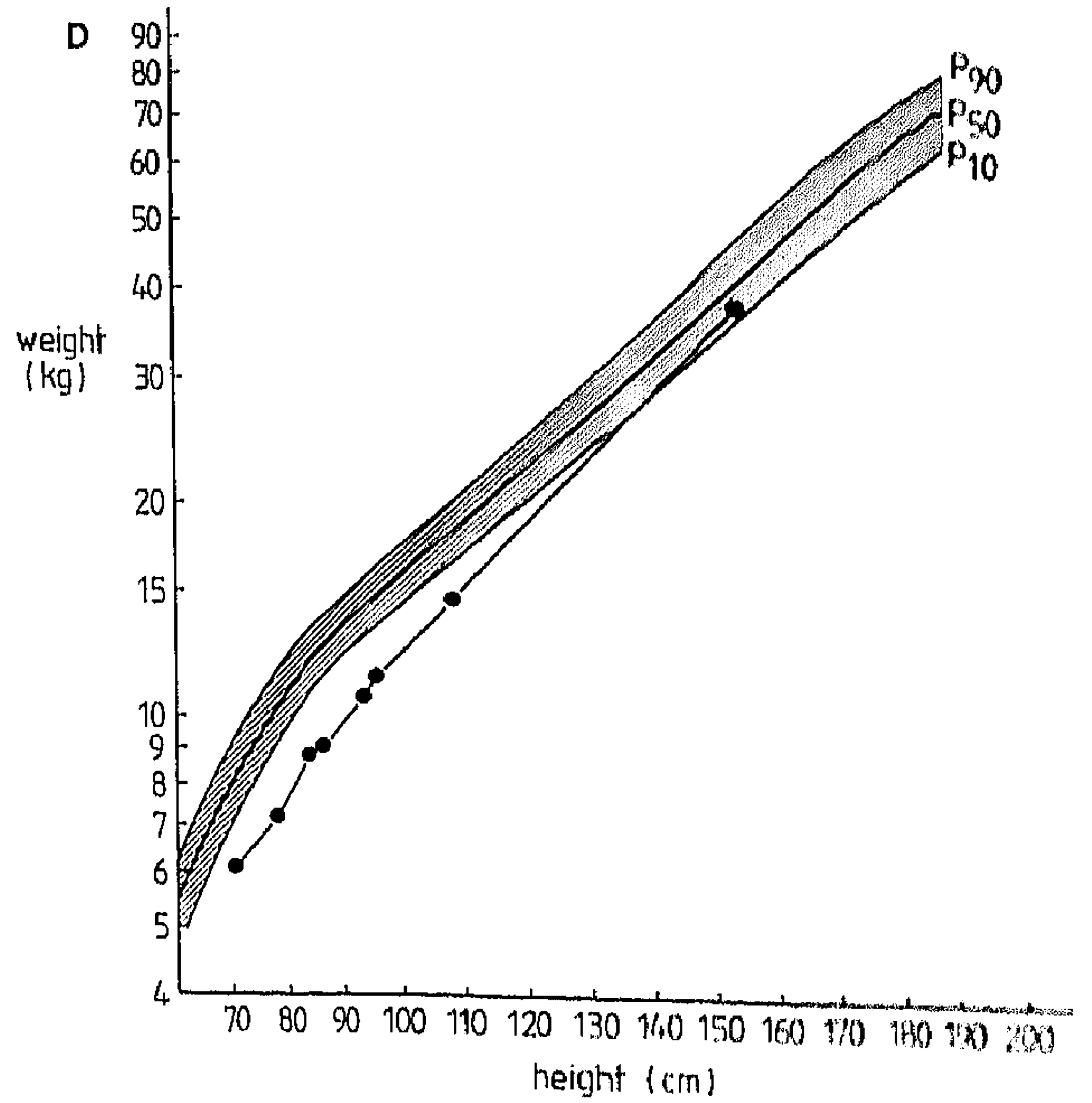
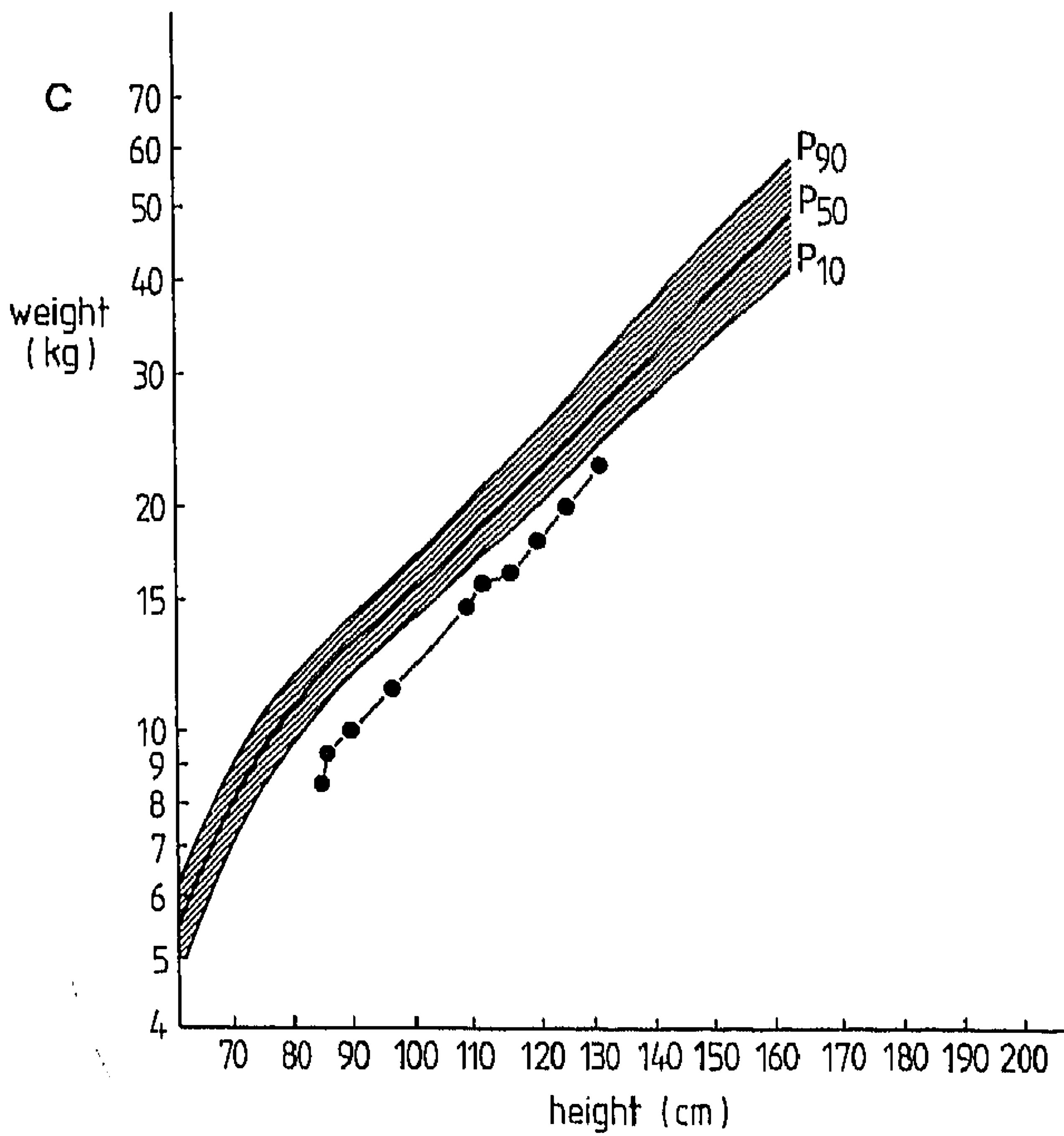
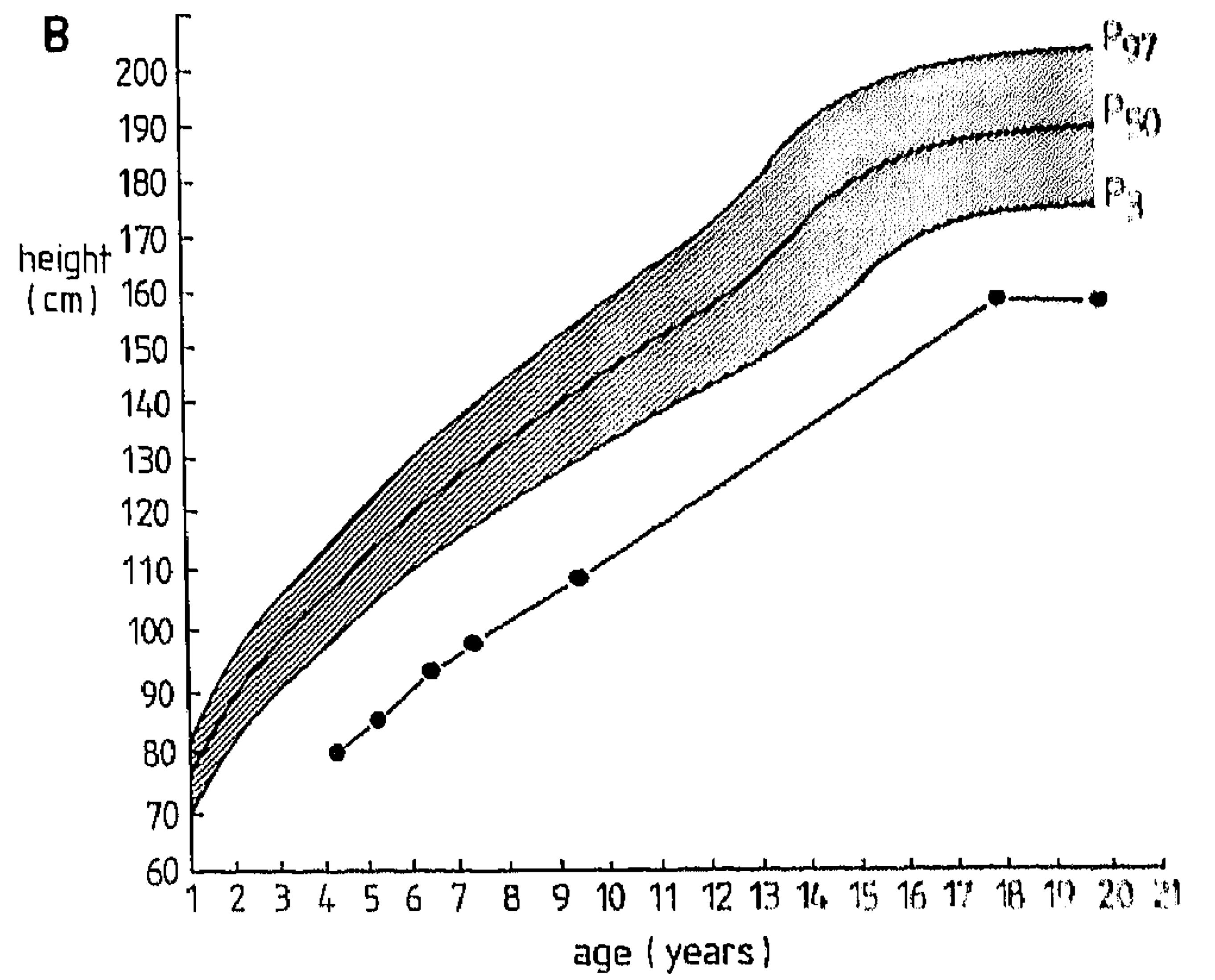


Figure 2: Height and weight for height of patient A and B

lar pigmentation of the retina was noted. Audiometry was normal. On X-rays the long bones were slender without evidence of chondrodysplasia. Magnetic resonance imaging of the brain was normal.

At age 10 she is a cheerful girl who speaks in 2-word sentences with a rather unclear articulation. She is more focussed on adults than on her groupmates and asks much attention for herself. Her performance at school is like a 4-year-old; she does not play much but prefers performing little housekeeping jobs. Her mental retardation is "moderate" (IQ 35-48).

Although results of a chromosome investigation were initially normal, we recently found a deletion by fluorescence *in situ* hybridization of the short arm of chromosome 4, 46,XX del(4)(p16.3-pter).

Patient B

Patient B (Fig. 3), a male born in 1951, is the second of 3 children born to nonconsanguineous parents. His parents, brother and sister are healthy. His mother had 2 healthy daughters from a previous marriage. Family history is normal. The physical appearance of this patient is very different from the other members of the family.

He was born after an unremarkable pregnancy, except for mild toxemia during the third trimester. Delivery at 38 weeks was normal. Birth weight was 2000 g (<3rd centile). During the first year of life he had severe feeding problems. At 10 months he weighed 5090 g (<3rd centile) and was hospitalized for 5 months because of retardation of growth and of psychomotor development. He gained 230 g during this

period. At 2 5/12 years he weighed 6200 g (4.5 kg, <3rd centile) and was referred for evaluation of his psychomotor retardation and his weight status. He was hospitalized for 7 months and gained 1000 g by means of highly fortified food. Function tests of thyroid, liver, kidney and adrenal gland were normal as were blood levels of glucose and insulin.

In an attempt to stimulate growth he was treated with thyroxin supplements without apparent effect; his height remained retarded (Fig. 2B). At 9 6/12 years his bone age was approximately 4 years (Greulich-Pyle). His weight remained low for height until about 15 years old (Fig. 2B).

From 1 6/12 to 8 years he had multiple seizures which were treated with phenobarbitone. It is not clear whether these seizures only occurred during fever. An EEG at 18 years showed a somewhat flattened background pattern (eyes opened), sporadically intervened with a sharp wave in the occipital region. The EEG was not considered epileptogenic. On examination at 41 years, he had a striking facial appearance (Fig. 3) with microcephaly (OFC 51 cm, <3rd centile), ocular proptosis, maxillary hypoplasia, a beaked nose, a short and flat philtrum (1 cm; 0.75 cm <3rd centile) and a wide mouth with normal teeth. Height was 154 cm (15 cm <3rd centile), weight 44 kg. He had small hands, 15.5 cm (1 cm <3rd centile) and feet, 23.5 cm (3rd centile).

Palmar creases were normal. Similar to patient A his feet had a gap between the first and second toe. Extension at the elbows was limited to approximately 55°.

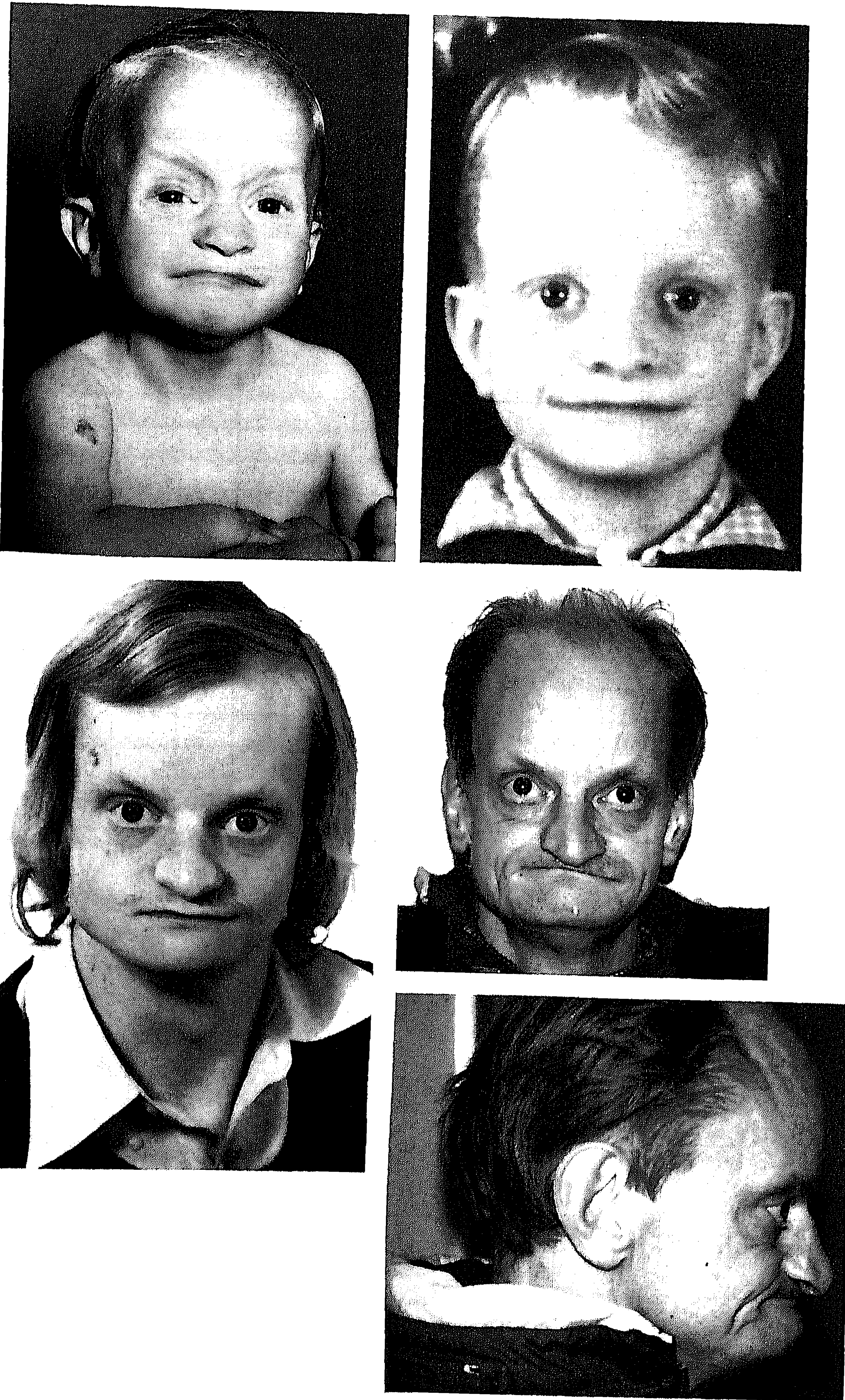


Figure 3: Patient B at age 2, 9, 24 and 41 years, frontal and side view, respectively

TABLE I. Clinical Findings in PRD and WHS Cases

Clinical findings	reported in PRD N=7	patient A	patient B	patient C	reported in WHS ¹ N=39
gestational age 37-42	7 (100)	+	+	+	30 (77)
mental retardation	7 (100)	+	+	+	29 (75)
low birthweight	7 (100)	+	+	+	29 (75)
short stature	7 (100)	+	+	+	10 (26)
microcephaly	7 (100)	+	+	+	13 (33)
prominent eyes	7 (100)	+	+	+	14 (36)
hypertelorism	6 (85)	+	+	+	26 (67)
beaked nose	5 (71)	+	+	+	8 (21)
maxillary hypoplasia	5 (71)	+	+	+	-
short and flat philtrum	7 (100)	+	+	+	+ (41)
wide mouth	7 (100)	+	+	+	-
palmar creases	4 (57)	-	-	-	-
history of seizures	5 (71)	+	+	+	20 (51)
feeding problems	?	+	+	+	?
down turned corner of	1 (14)	-	-	-	19 (49)
small mandible	-	-	-	-	18 (46)
low set ears	3 (43)	-	-	-	18 (46)
epicanthic folds	2 (28)	-	-	-	17 (44)
prominent glabella	1 (14)	-	-	-	16 (41)
palpebral fissures	3 (43)	-	-	-	15 (39)
strabismus	?	-	-	-	13 (33)
clinodactily	1 (14)	-	-	-	10 (26)
consanguinity	-	-	-	-	-

Schinzel [1994]

Ophthalmological status was unremarkable except for myopia. Hearing was normal. A G-banded karyogram was initially normal, but recent examination by high resolution showed a deletion of the short arm of chromosome 4 (46,XY,de-1(4)(p16.3-pter)).

He is a regular fidget, who finds it hard to amuse himself. Living in an institution for the mentally retarded he asks a lot of attention of his caretakers and other adults by asking stereotype questions but is not meddling much with his groupmates. He can only do small jobs for some minutes as it is difficult for him to concentrate. His

mental retardation is severe (IQ 20-35).

DISCUSSION

The combination of mental retardation, pre- and postnatal growth retardation, microcephaly, ocular proptosis, mid-face hypoplasia, short and flat philtrum, wide mouth and history of seizures was described by Pitt et al. [1984], Donnai [1986] and Oorthuys and Bleeker-Wagemakers [1989]. Our 2 patients have the same anomalies with strikingly similar facial findings. Table I summarizes the findings in the published cases and

our patients. In contrast to earlier reports, none of our patients have unusual palmar creases; two showed contractures.

The facial appearance, especially the mid-facial hypoplasia, became more marked with age with a progressive beaking of the nose and a reduction of the length of the philtrum (Figs. 1, 3).

Both our patients had severe feeding problems during the first years of life, with regurgitation of food and inadequate weight gain even on highly fortified food intake. They had a very slender build in childhood, although in patient B this subsequently became normal (Fig. 2).

Patient A originally had a very short stature as had the other patients. No evidence for endocrine dysfunction was detected. She was treated with growth hormone and responded with a spectacular increase in growth velocity. After 4 years of GH treatment her height increased from -5.3 to -1.8 SDS. However, her predicted adult height increased by only 4 cm to 153.1 cm because of a concomitant increase in skeletal maturation.

All patients previously described were reported to have normal chromosomes. Recently another patient with PRD phenotype was referred to Dian Donnai who was deleted for the short arm of chromosome 4 (personal communication). Therefore we tested chromosome 4 by FISH and found a deletion of the short arm of chromosome 4. Our preliminary data suggest that the chromosome 4 deletion could be in the same area as the critical region of Wolf-Hirschhorn syndrome. Although some findings in Wolf-Hirschhorn patients are the same as in Pitt-Rogers-Danks pa-

tients there are some striking phenotypic differences (Table I). Most prominent in Pitt-Rogers-Danks patients is the mid-face hypoplasia with maxillary hypoplasia, beaked nose, short flat philtrum and wide mouth with poorly defined upper lip, whereas in Wolf-Hirschhorn patients the upper face is most striking with high frontal hairline, prominent glabella with downslant of palpebral fissures and high nasal bridge. In Pitt-Rogers-Danks short stature is a constant finding. Moreover, 35% of the Wolf-Hirschhorn patients are reported to die in the first year of life [Gorlin et al., 1990] of cardiac complications, none of the Pitt-Rogers-Danks are known to have cardiac problems. No midline-fusion defects are present in the Pitt-Rogers-Danks cases as seen in Wolf-Hirschhorn syndrome. To our knowledge, the oldest person reported alive is 27 years old [Wilson et al., 1981], our cases are 13, 44 and 52 years old, respectively. The literature suggests that Wolf-Hirschhorn patients all have severe cognitive impairment whereas mental retardation in our first patient is "moderate".

The syndromic status of the Pitt-Rogers-Danks should be reassessed: is it a distinct aneuploidy syndrome or is it a form of Wolf-Hirschhorn syndrome? Further studies are necessary to analyze the cytogenetic abnormalities found, cytogenetic and DNA deletion studies have been performed in order to analyze the kind of the 4p-deletion of the PRD patients in comparison to the WHS critical region. These results will be published shortly in a separate paper.

Note added in proof : recently [Clemens et al., 1995] another pa-

tient with the Pitt-Rogers-Danks phenotype and a del (4p) was described.

ACKNOWLEDGMENTS

We are greatly indebted to D. Donnai, MD, PhD, Dept. of Medical Genetics, St. Mary's Hospital, Manchester, UK for suggesting us to test for 4p- and we thank J.M.Wit, MD, PhD, Dept. of Endocrinology, Wilhelmina Childrens' Hospital Utrecht (currently Professor of Pediatrics, Leiden) for his contributions to this manuscript.

REFERENCES

- Clemens M, McPherson EW, Surti U (1995): 4p microdeletion in a child with Pitt-Rogers-Danks syndrome. Abstract 464, A85, Am.Soc. Hum. Genet.
- Donnai D (1986): A further patient with the Pitt-Rogers-Danks syndrome of mental retardation, unusual face and intra-uterine growth retardation. Am J Med Genet 24:29-32.
- Donnai D (1994): personal communication.
- Kamp GA, Wit JM, Otten BJ, De Muick Keizer-Schrama SMPF, Drayer NM, Delemarre- Van De Waal HA, Oostdijk W, Gons MH (1991): Two year results of three different growth hormone treatment regimens in children with short stature. Hormone Res 35:31.
- Gorlin RJ, Cohen MM, Levin LS, (1990): "Syndromes of the Head and Neck". New York: Oxford University Press 46-47.
- Lizcano-Gil LA, Garcia-Cruz D, Garcia-Cruz O, Sanchez-Corona J (1995): Pitt-Rogers-Danks syndrome: Further delineation. Am J Med Genet 55:420-422.
- Oorthuys JWE, Bleeker-Wagemakers EM (1989): A girl with the Pitt-Rogers-Danks syndrome. Am J Med Genet 32:140-141.
- Pitt DB, Rogers C, Danks DM (1984): Mentalretardation, unusual face and intra-uterine growth retardation: A new recessive syndrome? Am J Med Genet 19:307-313.
- Schinzal A (1994): "Human Cytogenetics Database". Oxford: Oxford University Press.
- Wilson MG, Towner JW, Coffin GS, Ebbin AJ, Siris E, Brager P (1981): Genetic and clinical studies in 13 patients with the Wolf-Hirschhorn syndrome. Hum Genet 59:297-307.